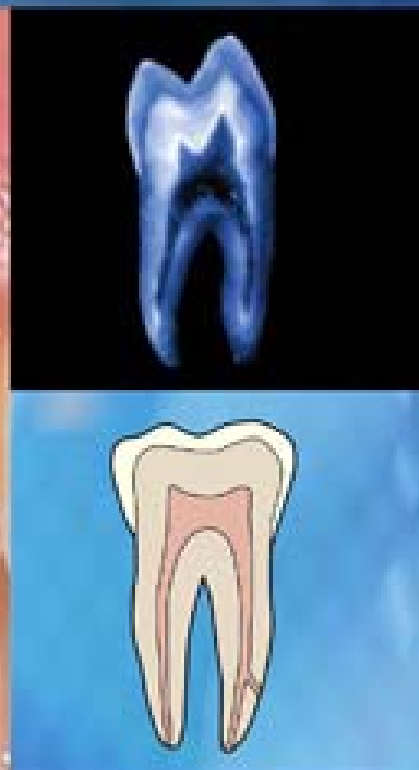
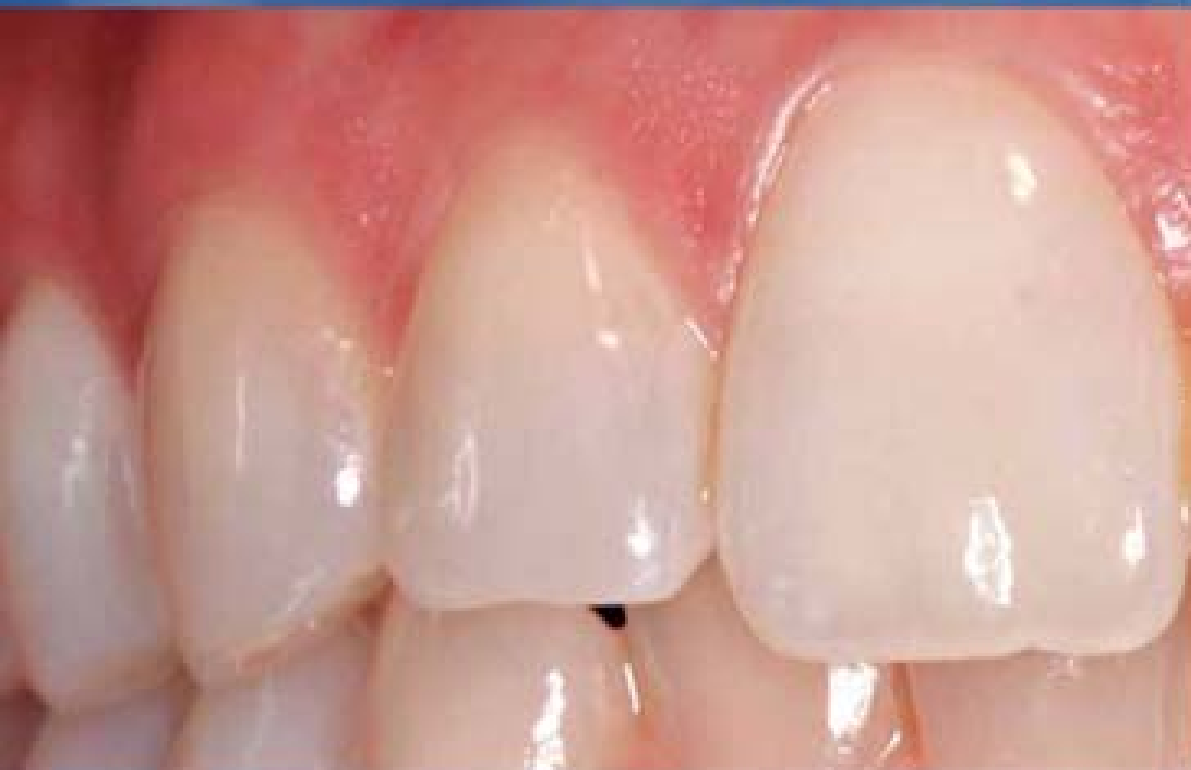
WOELFEL'S  
**DENTAL  
ANATOMY**  
EIGHTH EDITION



**Rickne C. Scheid**  
**Gabriela Weiss**



WOELFEL'S  
**DENTAL  
ANATOMY**  
EIGHTH EDITION

**Rickne C. Scheid, D.D.S., M.Ed.**

Associate Professor Emeritus

The Ohio State University College of Dentistry  
Columbus, Ohio

**Gabriela Weiss, D.D.S.**

Assistant Professor

The Ohio State University College of Dentistry  
Columbus, Ohio



Wolters Kluwer | Lippincott Williams & Wilkins  
Health

Philadelphia • Baltimore • New York • London  
Buenos Aires • Hong Kong • Sydney • Tokyo

*Acquisitions Editor:* Peter Sabatini  
*Product Manager:* Paula C. Williams  
*Marketing Manager:* Shauna Kelley  
*Designer:* Doug Smock  
*Compositor:* SPi Technologies

## Eighth Edition

Copyright © 2012 Lippincott Williams & Wilkins, a Wolters Kluwer business  
Two Commerce Square  
2001 Market Street  
Philadelphia, PA 19103 USA

All rights reserved. This book is protected by copyright. No part of this book may be reproduced or transmitted in any form or by any means, including as photocopies or scanned-in or other electronic copies, or utilized by any information storage and retrieval system without written permission from the copyright owner, except for brief quotations embodied in critical articles and reviews. Materials appearing in this book prepared by individuals as part of their official duties as U.S. government employees are not covered by the above-mentioned copyright. To request permission, please contact Lippincott Williams & Wilkins at Two Commerce Square, 2001 Market Street, Philadelphia, PA 19103, via email at [permissions@lww.com](mailto:permissions@lww.com), or via website at [lww.com](http://lww.com) (products and services).

Printed in China

---

### Library of Congress Cataloging-in-Publication Data

Scheid, Rickne C.

Woelfel's dental anatomy / Rickne C. Scheid. — 8th ed.  
p. ; cm.

Other title: Dental anatomy

Includes bibliographical references and index.

ISBN 978-1-60831-746-2 (alk. paper)

1. Teeth—Anatomy. 2. Mouth—Anatomy. I. Woelfel, Julian B. Dental anatomy. II. Title. III. Title: Dental anatomy.

[DNLM: 1. Tooth—anatomy & histology—Outlines. 2. Jaw—anatomy & histology—Outlines. 3. Mouth—anatomy & histology—Outlines. WU 18.2]

QM311.W64 2010

611'.314—dc22

2010027806

---

### Disclaimer

Care has been taken to confirm the accuracy of the information present and to describe generally accepted practices. However, the authors, editors, and publisher are not responsible for errors or omissions or for any consequences from application of the information in this book and make no warranty, expressed or implied, with respect to the currency, completeness, or accuracy of the contents of the publication. Application of this information in a particular situation remains the professional responsibility of the practitioner; the clinical treatments described and recommended may not be considered absolute and universal recommendations.

The authors, editors, and publisher have exerted every effort to ensure that drug selection and dosage set forth in this text are in accordance with the current recommendations and practice at the time of publication. However, in view of ongoing research, changes in government regulations, and the constant flow of information relating to drug therapy and drug reactions, the reader is urged to check the package insert for each drug for any change in indications and dosage and for added warnings and precautions. This is particularly important when the recommended agent is a new or infrequently employed drug.

Some drugs and medical devices presented in this publication have Food and Drug Administration (FDA) clearance for limited use in restricted research settings. It is the responsibility of the health care provider to ascertain the FDA status of each drug or device planned for use in their clinical practice.

To purchase additional copies of this book, call our customer service department at (800) 638-3030 or fax orders to (301) 223-2320. International customers should call (301) 223-2300.

Visit *Lippincott Williams & Wilkins on the Internet:* <http://www.lww.com>. Lippincott Williams & Wilkins customer service representatives are available from 8:30 am to 6:00 pm, EST.

9 8 7 6 5 4 3 2 1



# About the Authors

## Rickne C. Scheid, D.D.S., M.Ed.



Dr. Rickne Scheid received his D.D.S. in 1972 at The Ohio State University and was inducted into the dental honorary fraternity, Omicron Kappa Upsilon. After serving in the U.S. Navy Dental Corps, he practiced part-time practice and taught at his alma mater from 1974 until 2006 when he retired with Emeriti status.

His appointments at the College of Dentistry were in the Division of Dental Hygiene, the Section of Restorative and Prosthetic Dentistry, and the Section of Primary Care. While teaching, he earned his Masters in Education with honors in 1980. Throughout his teaching career, he authored or coauthored nearly 50 scientific papers and abstracts, and developed and directed twelve courses, including the Dental Anatomy course. He directed this course for 10 years, lecturing to both dental and dental hygiene students. Further, he helped develop and annually codirect numerous continuing education courses including a review course for dental hygienists returning to practice, a dental anatomy review course for dentists and dental auxiliaries, and an expanded functions course for dental auxiliaries. He was inducted into the dental hygiene honorary, Sigma Phi Alpha, in 1989 and has received numerous dental and dental hygiene student teaching awards as well as the peer-evaluated Postle Teaching Award in 1996. In retirement, he continues to present continuing education courses at the university and serves as an evaluator for the Commission on Dental Testing for Expanded Functions Dental Auxiliaries in Ohio.

## Primary Collaborator for the Eighth Edition: Gabriela Weiss, D.D.S



Dr. Gabriela Weiss received her D.D.S. as valedictorian in the 1986 class of the National University of Tucuman in Argentina. After graduation, she completed a clinical fellowship in Occlusion and Oral Rehabilitation when she was awarded the F.A.M.U. (an honor given to the outstanding professional female). In

1988, she moved to the United States where she worked in a private practice in California. In 1994, she moved to Michigan where she pursued her passion for teaching as a faculty member at the University of Michigan Dental School where she taught in Operative and Prosthetic Dentistry courses and directed Dental Anatomy and Occlusion until 1997. Later, she directed the Dental Anatomy course at Pittsburgh University before moving to Ohio in 2002 where she became an Assistant Professor at The Ohio State University College of Dentistry in the Department of Operative and Prosthetic Dentistry. Gabriella has received the Student Government Teaching Award for 8 consecutive years. In 2007, she assumed the directorship of the Dental Anatomy course.

## REVIEWERS

- Trudy Benzel, RDH, BA, Restorative Coordinator, Dental Hygiene, Yakima Valley Community College, Yakima, Washington
- Lindy Bollen, Jr., DDS, Assistant Professor, University of Arkansas for Medical Sciences, Little Rock, Arkansas
- Kay W. Hudak, CDA, CDPMA, Instructor, Dental Assisting, Lancaster County Career and Technology Center, Willow Street, Pennsylvania
- Alan J. Kilistoff, DMD, MET, FCP, Assistant Dean, Clinic Affairs, College of Dentistry, University of Saskatchewan, Saskatoon, Saskatchewan
- Teresa A. Macauley, CDA, EFDA, MS, Regional Program Chair, Dental Assisting, Ivy Tech Community College, Anderson, Indiana
- John T. Mayhall, DDS, AM, PhD, Dr. Odont.(hc), Professor Emeritus, Faculty of Dentistry, University of Toronto, Toronto, Ontario
- Tanya Villalpando Mitchell, RDH, MS, Associate Professor and Director, Graduate Studies, Division of Dental Hygiene, University of Missouri—Kansas City School of Dentistry, Kansas City, Missouri
- Carol A. Nguyen, RDH, MS, Assistant Professor, School of Health Professions, University of Texas Health Science Center at San Antonio, San Antonio, Texas
- Ximena Zornosa, DMD, Assistant Professor, Department of Dental Hygiene, Clayton State University, College of Health, Morrow, Georgia

# Preface to the Eighth Edition

Woelfel's Dental Anatomy is primarily intended as a study guide for dental students, dental hygiene students, dental assistants, and dental laboratory technicians as they master the details of tooth morphology and their usefulness in the dental office. The book provides dental and dental hygiene students with basic knowledge required when answering dental anatomy questions on the national board examinations, but it goes well beyond by discussing the application of tooth morphology and terminology to the practice of dentistry. Chapters are included on periodontics, endodontics, restorative dentistry, and forensic dentistry. The book with its Power Point lecture slides and test items for teachers and its many learning exercises was designed for instructors of dental anatomy courses as a teaching manual during lectures, discussion periods, and laboratory sessions, as well as during early clinical experiences. It is also useful as a reference in the dental office.

## NEW IN THIS EDITION

Most illustrations are now in color to highlight important features better than in past editions, and many new illustrations have been added as well.

The eighth edition is now organized into three parts. Part I, **Comparative Tooth Anatomy**, includes six chapters. The first chapter begins with an introduction to terminology and concepts related to tooth morphology that lays the foundation for the next four chapters on adult tooth traits. In these chapters, the author presents similarities and differences using drawings, photographs, and many summary tables. Primary teeth and their eruption patterns are discussed in Chapter 6. In order to make it easier for students to focus on the most important details of tooth anatomy, specific data from Dr. Woelfel's original research statistics were moved to the end of each chapter but can still be easily referenced by referring to the letters placed as superscripts throughout these chapters. Also, interesting facts related to ethnic variations and animal teeth were moved to separate sections at the end of the chapters.

Part II, **Application of Tooth Anatomy in Dental Practice**, has seven chapters. The first two chapters include a discussion of roots of the adult teeth related to periodontal procedures (with new illustrations on the use of instruments for removing mineralized deposits from unique contours on root surfaces)

and endodontic procedures. Other chapters include a contemporary overview of ideal occlusion, operative and restorative dentistry, and forensic dentistry. Finally, there is an extensive discussion about many commonly encountered dental anomalies as well as a chapter designed to help students draw, carve, and sketch teeth.

Part III, **Anatomical Structures of the Oral Cavity**, includes two chapters. One chapter presents the relationship of the teeth to landmarks of the skull, the temporomandibular joints, and the muscles, nerves, blood supply, and lymph drainage associated with the oral cavity. The other chapter includes a description of normal oral structures observed during a head and neck cancer screening examination, and shows sites for injections for local anesthetic relative to the underlying nerve locations.

## BOOK FEATURES

Each chapter includes methods designed to help you, the reader, master the content and put it to practice immediately.

- **Topic list:** Each chapter begins with a list of topics that are presented within that chapter. The topics are presented in the same order as the section outline headings within that chapter.
- **Learning objectives:** In each chapter, important learning objectives are presented to help you appreciate what you can expect to learn as you read. You can refer to the objectives to ensure that you are mastering the appropriate knowledge and skills.
- **New terms:** As each new term is encountered for the first time, it is highlighted in bold print and is defined within the text at that time, often with references to figures or diagrams to improve understanding. The bold print is helpful when using the text as a reference for understanding terms that can be found within the text's index.
- **Index** (instead of a glossary): The extensive index has been used instead of a glossary since many terms in dentistry are best appreciated by referring to illustrations or photographs for a complete understanding. In most cases, the first page where a term is referenced in the index is the page where you can find the term (in bold) and can refer to the suggested illustrations for the best learning.
- **Pronunciations:** New terms that may be difficult to pronounce have phonetic suggestions placed within brackets [like this] immediately after the word is first encountered.

- **Review questions with answers:** Many chapters or sections end with a series of review questions to test the learner's mastery of the objectives. These questions, in many cases, cover topics similar to those included on past dental and dental hygiene national examinations. For the convenience of quick and convenient feedback, the answers are presented immediately following the questions. Available for instructors who use this edition is a CD that includes a bank of additional test items.
- **Learning exercises:** Practically every chapter provides the reader with a series of learning exercises. These exercises are presented within the body of each chapter at intervals where the authors feel an active learning experience would be helpful for you to understand and/or apply the topic. These exercises may suggest that you examine extracted teeth or tooth models, or skulls (or skull models), or perform specific self- or partner examinations. More advanced exercises (as in Chapter 13) provide methods for drawing and sketching teeth, and carving teeth from wax, thus helping you to become intimately familiar with tooth shape and terminology.
- **Summary Tables:** Throughout the text, the authors have placed numerous tables to summarize the many facts presented within the text. These tables are helpful when reviewing the highlights of content found within each section.
- **Original illustrations and drawings:** For complete understanding and clinical application of each topic, the authors have included a variety of photographs, illustrations, and original colorized drawings selected and designed to illustrate key points and improve learning. A number of new illustrations and summary tables have been added to this edition, and all of the new illustrations are in color. Since a picture is worth a thousand words, it is critical that you refer to figures whenever they are referenced within the text in order to maximize your learning. Many figures are designed so you can cover up the names of structures and test yourself. In some instances, important additional information is presented or clarified in the illustration legends. Also, on the Point companion Web site, there is an image bank for instructors containing all of the illustrations and drawings in the text that can be used when lecturing.
- **Appendix of comparative dental anatomy:** This text's unique appendix is designed to help the learner visualize the many tooth similarities and differences that are often difficult to understand with words alone. Each adult tooth class is referenced on two appendix pages. The first page includes traits (each trait is identified with a different letter) that are common to all teeth within that class. The second page is devoted to the differences (each identified with a letter) between the types of teeth within each class and differences between teeth in each arch. Two additional appendix pages are included that illustrate the unique characteristics of anterior and posterior primary teeth. The layout on these pages makes it easy to compare the differences between teeth because views of each tooth type are lined up on the same page next to other teeth in that class. As each tooth characteristic is described within the chapters on tooth morphology (Chapters 1–6), reference is frequently made to the illustrated representation of that characteristic on an appendix page as follows: The word "Appendix" is followed by the page number and letter denoting items being discussed (for example, "Appendix 1a" refers you to the Appendix, page 1, item "a"). Appendix pages are printed on heavier, perforated paper to permit removal and placement in a separate loose-leaf notebook. When used in this fashion, these pages provide you with increased convenience (since fewer page turns are required when referencing tooth characteristics within each chapter), easier learning (since the complex terminology used to describe each characteristic is best learned by visualizing that characteristic and comparing it to other similar teeth), and a separate study guide (since all labeled characteristics for each type of tooth are described on the back of each appendix page).
- **Research data:** This text is unique in providing you with both original and reviewed research findings based on the study of thousands of teeth, casts, and mouths. Information on crown and root dimensions was obtained from measurements of a convenient sample of 4,572 teeth extracted by Ohio dentists and studied by Dr. Julian Woelfel and his dental hygiene students at The Ohio State University between 1974 and 1979. The data from these studies are presented throughout the text by using superscript letters like this (data<sup>A</sup>) that refer to the statistics listed by letters at the end of the chapters. For example, the text states that a mesial marginal groove is a distinguishing characteristic of the maxillary first premolar<sup>A</sup>, and at the end of the chapter under A, you are told that this occurred in 97% of the 600 premolars studied, which means that, on the average, 3% may not have this groove, whereas only 37% of maxillary second premolars are likely to have this groove.
- The best resource for learning about teeth is a collection of as many intact extracted teeth as you are able to acquire. A dentist, if presented with a quart



jar of bleach, will remember his or her own student days and will probably be glad to put extracted teeth in the jar. Do not expect these teeth to be clean or sorted out; sorting is your job. While handling these teeth, it is critical to follow the guidelines for infection control presented here:

### **GUIDELINES FOR STERILIZING AND STUDYING EXTRACTED TEETH**

Using protective gloves and a mask, tooth specimens should be scraped clean with a knife. Soaking for several hours in hydrogen peroxide before scraping is helpful. After scraping to remove hard deposits and soft tissue, tooth specimens should be further cleansed by soaking for 20 minutes in 4 ounces of household bleach containing 2 tablespoons of Calgon (a water softener). Teeth can then be placed in water (in a beaker covered with tin foil) to be autoclaved for 40 minutes at 121°C and 15 psi (Pantera E, Schuster G. *J Dent Ed* 1990;54[5]:284). Once prepared, teeth should be kept moist, either by soaking in water or, as suggested by Dr. Kim Loos, D.D.S., by soaking in 25% glycerin and 75% water (parentsplace.com, Feb. 28, 2001).

As you begin learning the characteristics that differentiate each type of tooth as described in Part I, you need to be aware of the considerable variation in tooth morphology that can occur from one patient to the next. You must keep in mind that relative tooth sizes and characteristics cited within the text do *not* apply to *all* patients' teeth but are based on average sizes or particular morphology occurring with the greatest frequency.

As you read the description of tooth morphology, not only identify each structure visually but also use a dental explorer on an actual tooth or model to “feel” the contours being described since you will eventually be required to evaluate, reproduce, and/or clean the surfaces of these tooth contours with specific dental instruments. As you become familiar with the many similarities and differences of tooth morphology, you can later apply this information during patient treatment, evaluation, and education.

Hopefully, you will spend some time thinking about and comprehending the concepts as you read. After all, you are learning the “foreign” language of dental

anatomy that you will be using for the rest of your professional lives. Have fun looking at teeth as though you were a tooth detective. Take notes, sketch different views of each tooth, and take advantage of all learning exercises, references to figures, and the appendix. Ask questions until your curiosity is satisfied. Most importantly, the authors hope this book will stimulate your interest and involvement in the wonderful and fascinating field of dentistry and that you will consider it to be a worthwhile addition to your library even after your formal education is complete.

### **ADDITIONAL RESOURCES**

*Woelfel's Dental Anatomy* includes additional resources for both instructors and students that are available on the book's companion Web site at <http://thePoint.lww.com/Scheid8e>.

#### **Instructor Resources**

Approved adopting instructors will be given access to the following additional resources:

- PowerPoint Presentations
- Interactive image bank with the option of displaying images with or without labels
- Test Generator
- Answers to end-of-chapter Critical Thinking Questions

#### **Student Resources**

Students who have purchased *Woelfel's Dental Anatomy* have access to the following additional resources:

- Image labeling exercises
- Interactive image bank with the option of displaying images with or without labels
- PowerPoint Presentations

In addition, purchasers of the text can access the searchable Full Text Online by going to the *Woelfel's Dental Anatomy* Web site at <http://thePoint.lww.com/Scheid8e>.

See the inside front cover of this text for more details, including the passcode you will need to gain access to the Web site.

# Acknowledgments

During my first year teaching at The Ohio State University College of Dentistry in 1974, I was fortunate to be assigned to teach in a laboratory for dental anatomy where I worked with, and was mentored by, Dr. Julian Woelfel. He asked me to contribute the chapter on Operative Dentistry in the third edition in 1984. Little did I realize that in 1994, I would be selected by him to coauthor the fifth edition of a text on the very topic I began teaching in 1974: dental anatomy. During the preparation for the fifth and sixth editions, Julian permitted me great latitude in reorganizing the text to reflect my teaching style since I used this text as I taught over 135 dental and dental hygiene students each year. During this major reorganization, I was careful to maintain the unique aspects that he had incorporated into previous editions. This includes the results of his personal, science-based research, which formed the basis for many of the conclusions presented within this text: on everything from the average mandibular hinge opening to the frequency of Carabelli cusp formation and the comparative sizes of primary and permanent teeth. In the seventh edition, Dr. Woelfel entrusted me to take over the text.

I would like to express my appreciation to all of the contributors to this and previous editions of this book. My thanks goes to Dr. Woelfel for selecting me to take over the book and teaching me to be meticulous, and for his many contributions to this text; to his wife, Marcile, who helped tremendously in typing and editing previous editions; and to Dr. Lewis Claman and Dr. Binnaz Leblebicioglu (who updated the chapter on periodontics), Dr. John Nusstein (who updated the chapter on endodontics), and Dr. Daniel Jolly (who updated the forensic chapter). I would also like to recognize Ms. Dorothy Permar, who conceived and wrote the first edition in 1974, and Dr. Robert Rashid, Dr. Theodore Berg, Jr., Dr. Al Reader, and Ms. Connie Sylvester, who contributed to previous editions. Finally, a special thanks goes to my collaborator, Dr. Gabriella Weiss, who in this edition suggested important changes, additional teaching aids and test items, and helped in the daunting task of editing and proofing each chapter.

*Rickne C. Scheid, D.D.S. M.Ed.*



## About Dr. Julian Woelfel

Professor Emeritus Julian Woelfel, known primarily for his expertise in complete dentures, research, and occlusion, has taught clinical dentistry for 40 years in the College of Dentistry at The Ohio State University, Columbus, Ohio. He served as an Army prosthodontist in Texas for 2 years, conducted clinical research for the American Dental Association at the National Bureau of Standards in Washington, D.C. for 3 years, and was a visiting professor in Japan, Taiwan, England, and Brazil. Dr. Woelfel has lectured in eighteen foreign countries. He has published eighty-five scientific articles, eight editions of this Dental Anatomy textbook, and chapters in five other dental books. Dr. Woelfel also has published scientific dental articles in Japan, Bulgaria, and Brazil. He holds patents on two inventions that are used in Europe and the United States for accurately recording jaw relation. In addition to Dr. Woelfel's love for students and teaching, he had a part-time dental practice limited to partial and complete dentures for 33 years. One of his proudest accomplishments has been this textbook. In 1967, he was the first recipient of the International Association of Dental Research Award for Research in Prosthodontics and was awarded a Life Membership in the Japanese Nihon University Dental Alumni Association. In 1972, the New York Prosthodontic Society selected him for the Jerome and Dorothy Schweitzer Award for Outstanding and Continuing Research in Prosthodontics. In 1992, the Ohio Dental Association chose Dr. Woelfel for the prestigious Callahan Award, and in 2004, he was the recipient of the Distinguished Alumnus Award from the Ohio Dental Alumni Association. He is a Life Member of Sigma Xi, the International Association for Dental Research, the American Prosthodontic Society, Sigma Phi Alpha Dental Hygiene Honor Society, and the ADA, AES, FDI, FICD, and FACD.

*Comments or suggestions may be submitted to Dr. Scheid on e-mail (scheid.2@osu.edu).*

# Contents

About the Author .....	iii
Preface to the Eighth Edition .....	iv
Acknowledgments .....	vii
<b>Part I COMPARATIVE TOOTH ANATOMY .....</b>	<b>1</b>
<b>1</b> Basic Terminology for Understanding Tooth Morphology.....	3
<b>2</b> Morphology of the Permanent Incisors .....	42
<b>3</b> Morphology of the Permanent Canines .....	67
<b>4</b> Morphology of Premolars.....	85
<b>5</b> Morphology of Permanent Molars .....	120
<b>6</b> Primary (and Mixed) Dentition .....	164
<b>Part II APPLICATION OF TOOTH ANATOMY IN DENTAL PRACTICE.....</b>	<b>195</b>
<b>7</b> Periodontal Anatomy .....	197
<b>8</b> Application of Root and Pulp Morphology Related to Endodontic Therapy .....	231
<b>9</b> Functional Occlusion and Malocclusion.....	250
<b>10</b> Treating Decayed, Broken and Missing Teeth.....	291
<b>11</b> Dental Anomalies.....	323
<b>12</b> Forensic Dentistry .....	345
<b>13</b> Guidelines for Drawing, Sketching, and Carving Teeth.....	362
<b>Part III ANATOMIC STRUCTURES OF THE ORAL CAVITY .....</b>	<b>375</b>
<b>14</b> Structures That Form the Foundation for Tooth Function .....	377
<b>15</b> Oral Examination: Normal Anatomy of the Oral Cavity .....	439
Appendix .....	473
Index .....	495

PART

## COMPARATIVE TOOTH ANATOMY

The six chapters in this part of the book provide a detailed description of each type of tooth in an adult and in a child.





# Basic Terminology for Understanding Tooth Morphology

The background terminology and concepts presented in this chapter are divided into nine sections as follows:

- I. Naming teeth based on location within the normal, complete human dentition
  - A. Complete primary dentition
  - B. Complete permanent dentition
- II. Tooth identification systems: Universal, World Dental Federation (International), and Palmer Numbering Systems
- III. Terminology used to describe the parts of a tooth
  - A. Four tissues of a tooth
  - B. Anatomic versus clinical crown and root
- IV. Introduction to the periodontium
- V. Terminology used to define tooth surfaces
  - A. Terms that identify outer surfaces (toward the cheeks or lips) of anterior versus posterior teeth
  - B. Terms that identify inner surfaces (toward the tongue) of maxillary versus mandibular teeth
  - C. Terms that differentiate biting surfaces of anterior versus posterior teeth
  - D. Terms that differentiate approximating surfaces of teeth
- E. Terms to denote tooth surface junctions or dimensions
- F. Divisions (thirds) of the crown or root (for purposes of description)
- G. Root-to-crown ratio
- VI. Terminology used to describe the morphology of a tooth
  - A. Morphology of an anatomic crown
  - B. External morphology of the anatomic root
  - C. Cervical line (CEJ) curvature
  - D. Relative size
- VII. Terminology related to the ideal tooth alignment of teeth in dental arches
  - A. Mid-root axis line
  - B. Height of contour on the facial and lingual surfaces
  - C. Contact areas (or proximal heights of contour)
  - D. Embrasure spaces
- VIII. Ideal occlusion: inter (between) arch relationship of teeth
- IX. Tooth development from lobes
- X. Interesting variations in animal teeth compared to human teeth

## OBJECTIVES

This chapter is designed to prepare the learner to perform the following:

- Based on location in the normal, complete primary dentition, name all 20 teeth by dentition, arch, quadrant, type (when applicable), and class.
- Based on location in the normal, complete permanent dentition, name all 32 teeth by dentition, arch, quadrant, type (when applicable), and class.
- Use the Universal Numbering System to identify permanent and primary teeth.
- Use the Palmer and International Tooth Numbering Systems to identify teeth, and “translate” them to the Universal System.
- Identify and describe the supportive structures of the teeth (periodontium).
- Identify and describe the four tissues of a tooth and their location, mineral content, and function.
- Differentiate an anatomic crown and root from a clinical crown and root.
- Name each tooth surface for anterior and posterior teeth.
- From all views, divide a tooth crown and root into thirds and label each third.
- Define terms used to denote a specific dimension of a tooth.
- Describe and identify (by name) common tooth rounded elevations, ridges, depressions, and grooves for each type of tooth.
- Describe and recognize the parts of a root.
- Describe and identify the attributes of ideal tooth alignment and embrasure spaces relative to other teeth within the arch, including the cusp or incisal edge position relative to the tooth’s mid-root axis line (proximal view), location of heights of contour and proximal contacts (facial or lingual views), and relative sizes of embrasure spaces (facial, lingual or occlusal/incisal views).
- Describe and identify the ideal interarch relationship of teeth in class I occlusion, especially the relationship of first molars and canines.
- Identify the number of developmental lobes that form each tooth, and recognize the anatomic landmarks of a tooth that form from these lobes.



When we enter into any new field of study, it is initially necessary to learn the particular language of that field. Without an adequate vocabulary, we can neither understand others nor make ourselves understood. Definitions and explanations of terms used in descriptive

tooth morphology are the basic foundation for understanding subject matter presented in subsequent chapters of this text. You need to learn some basics, similar to learning a foreign language. You will soon become familiar with these dental terms as you continue to use them throughout your professional dental career.

## SECTION I

### NAMING TEETH BASED ON LOCATION WITHIN THE NORMAL, COMPLETE HUMAN DENTITION

This section is designed to introduce you to terms used when naming teeth based on their normal location in the mouth. All of the teeth in the mouth together are referred to as the **dentition** [den TISH un]. Humans have two dentitions throughout life: one during childhood, called the **primary dentition**, and one that will hopefully last throughout adulthood, called the **permanent** (also known as **secondary**) **dentition**. The teeth in the upper jawbones (called the maxillae [mak SIL ee]) collectively form an arch shape known as the **maxillary** [MACK si lair ee] **arch**, and those teeth in the lower jawbone (called the mandible) collectively form the **mandibular** [man DIB yoo ler] **arch**. Each arch can further be divided into the left and right halves (also known as left and right quadrants since each **quadrant** contains one fourth of all teeth in that dentition).

#### A. COMPLETE PRIMARY DENTITION

The complete primary dentition is normally present in a child from the ages of about two to six years. There are 20 teeth in the entire primary dentition (shown in *Fig. 1-1*): ten in the upper maxillary arch and ten in the lower mandibular arch. This dentition is also called the **deciduous** [de SIDJ oo us] **dentition**, referring to the fact that all of these teeth are eventually shed by age 12 or 13, being replaced sequentially by teeth of the permanent dentition. The complete primary dentition has five teeth in each quadrant. The primary teeth in each quadrant are further divided into **three classes**: incisors [in SI zerz], canines, and molars. Based on location, starting on either side of the midline between the right and left quadrants, the two front teeth in each quadrant of the primary dentition are **incisors** (I), followed by one **canine** (C), then two **molars** (M). Using these abbreviations for the classes of teeth, followed by a ratio composed of a top number representing the number of teeth in each upper quadrant and the bottom number representing the number

of teeth in each lower quadrant, a formula can be used to represent the teeth in the human primary dentition as follows:

$$I\frac{2}{2}C\frac{1}{1}M\frac{2}{2} = 5 \text{ upper and 5 lower teeth in each quadrant; 20 teeth in all}$$

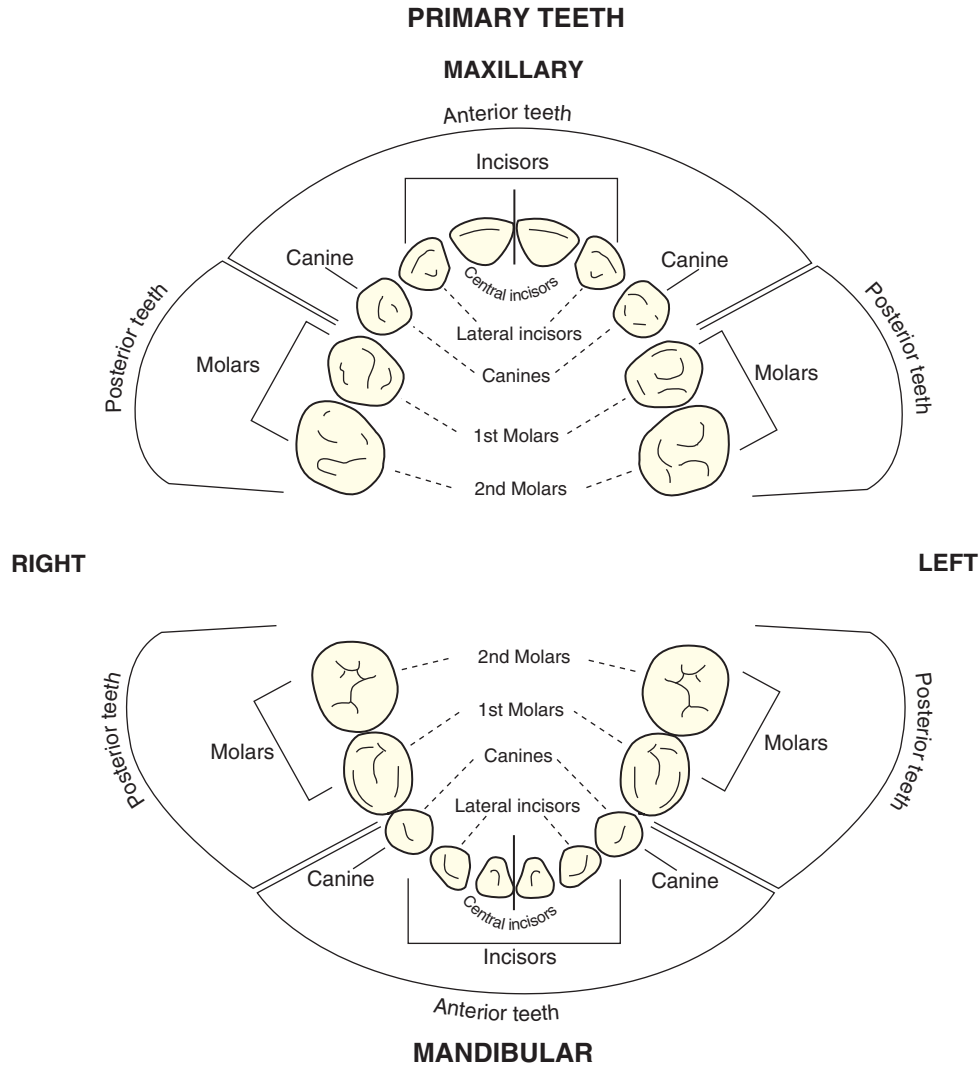
The classes of primary teeth containing more than one tooth per quadrant (incisors and molars) are subdivided into **types** within each class. Each type can also be identified by its location within the complete quadrant. The primary incisor closest to the midline separating the right and left quadrants is called a **central incisor**. The incisor next to, or lateral to, the central incisor is called a **lateral incisor**. Next in each quadrant is a canine, followed by two types of molars: a **first molar** behind the canine and then a **second molar**.

#### LEARNING EXERCISE

Using either models of the complete primary dentition or *Figure 1-1* while covering up the labels, identify each primary tooth based on its location in the arch. Include, in order, the dentition, arch, quadrant (right or left), type (when applicable), and class. For example, the tooth next to the midline in the lower left quadrant would be identified as the primary mandibular left central incisor.

#### B. COMPLETE PERMANENT DENTITION

The complete permanent (or secondary) dentition is present in the adult. It is composed of 32 teeth: 16 in the upper maxillary arch and 16 in the lower mandibular arch (shown in *Fig. 1-2*). The permanent dentition has eight teeth in each quadrant, which are divided into



**FIGURE 1-1.** Maxillary and mandibular primary dentition.

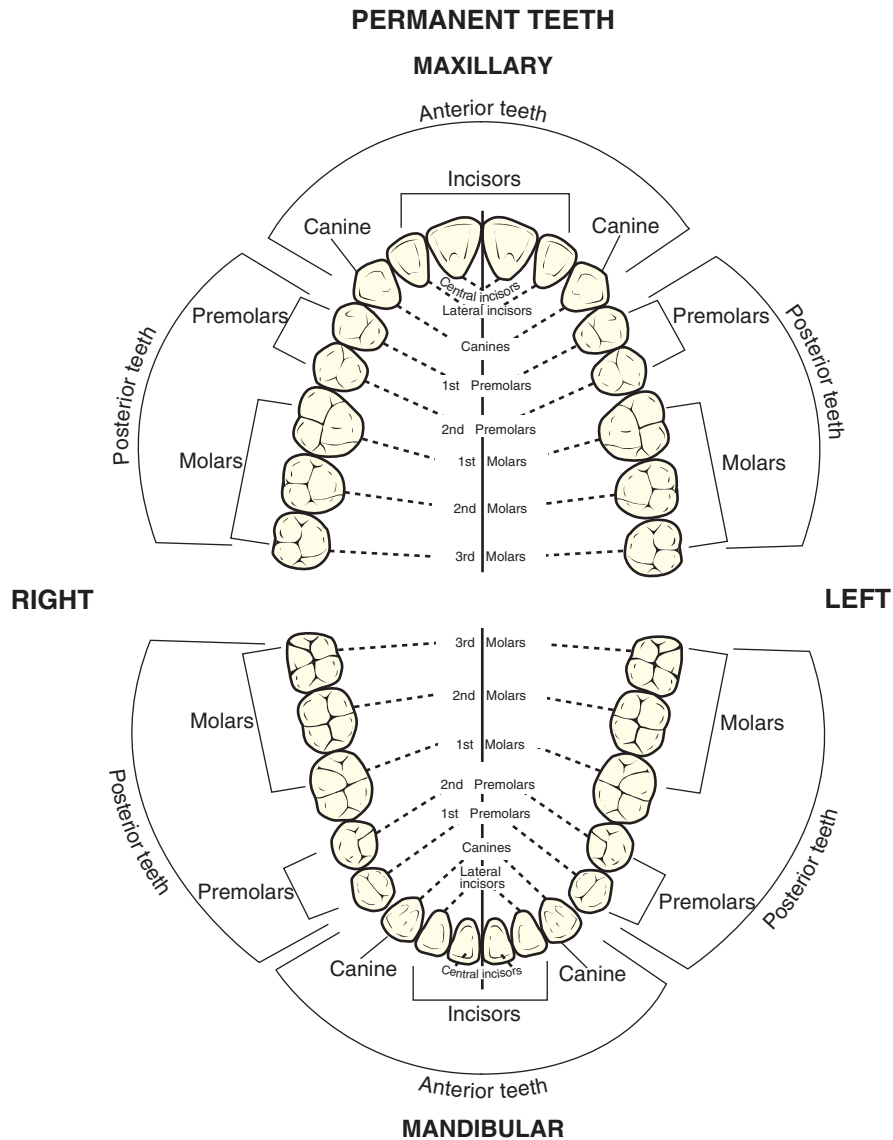
*four classes*: incisors, canines, **premolars** (PM; a new class for permanent teeth), and molars. Based on location, the two permanent front teeth in each quadrant are incisors (I), followed by one canine (C), then two premolars (PM), and finally three molars (M). The dental formula for the human permanent dentition is as follows:

$$I_{\frac{2}{2}}C_{\frac{1}{1}}PM_{\frac{2}{2}}M_{\frac{3}{3}} = 8 \text{ upper and } 8 \text{ lower teeth} \\ \text{on either side, } 32 \text{ teeth in all}$$

The classes of permanent teeth containing more than one tooth per quadrant (namely, incisors, premolars, and molars) are subdivided into **types** within each class. Each type can be identified by location within the quadrant. As in the primary dentition, the permanent incisor closest to the midline between the right and the

left quadrants is called a **central incisor**; the incisor next to, or lateral to, the central incisor is called a **lateral incisor**. Next in the arch is a **canine**, followed by a **first premolar**, then a **second premolar**. Continuing around toward the back in each quadrant are three molars: a first molar, a second molar, and finally a third molar (sometimes referred to as a wisdom tooth).

As noted by comparing the formulas for primary and permanent teeth, differences exist. Although central and lateral incisors and canines are similarly positioned in both dentitions, permanent dentitions have a new category of teeth called **premolars**, which are located between canines and molars. Premolars are positioned in the spaces left where the primary molars were located earlier in life. Behind the premolars, there are three instead of two molars.



**FIGURE 1-2.** Maxillary and mandibular permanent dentition.

Two other terms are used to categorize or distinguish groups of teeth by their location: anterior and posterior teeth. **Anterior teeth** are those teeth in the front of the mouth, specifically, the incisors and the canines. **Posterior teeth** are those in the back of the mouth, specifically, the premolars and the molars.

### LEARNING EXERCISE

Using either models of the complete permanent dentition or Figure 1-2 while covering up the labels, identify each permanent tooth based on

### Learning Exercise, cont.

its location in the arch. To identify each tooth accurately, include in order, the dentition, arch, quadrant, type (if applicable) and the class. For example, the last adult tooth in the lower right quadrant is correctly identified as the permanent mandibular right third molar.

## Review Questions

Select the one best answer.

- How many teeth are present in one quadrant of a complete adult (permanent) dentition?
  - 5
  - 8
  - 10
  - 20
  - 32
- What class of teeth is present in the permanent dentition that is NOT present in the primary dentition?
  - Incisors
  - Canines
  - Premolars
  - Molars
- In a permanent dentition, the fifth tooth from the midline is a
  - Canine
  - Premolar
  - Molar
  - Incisor
- Posterior teeth in the permanent dentition include which of the following?
  - Premolars only
  - Molars only
  - Premolars and molars only
  - Canines, premolars, and molars
- Which permanent tooth erupts into the space previously held by the primary second molar?
  - First molar
  - Second molar
  - First premolar
  - Second premolar

ANSWERS: 1—b, 2—c, 3—b, 4—c, 5—d

## SECTION II

### TOOTH IDENTIFICATION SYSTEMS: UNIVERSAL, WORLD DENTAL FEDERATION (INTERNATIONAL), AND PALMER NUMBERING SYSTEMS

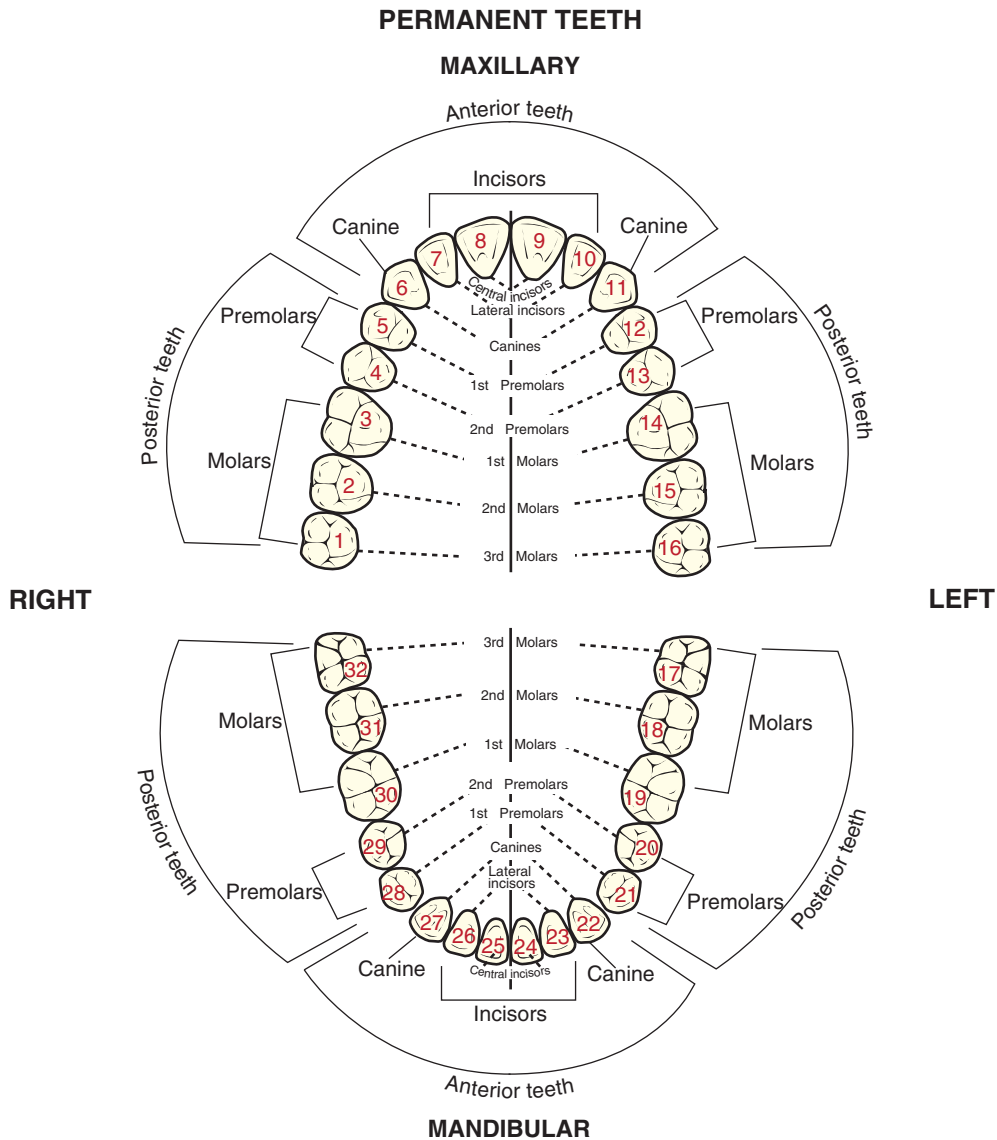
The making and filing of accurate dental records is an important task in any dental practice. To do so expeditiously, it is necessary to adopt a type of code or numbering system for teeth. Otherwise, for each tooth being charted, one must write something like “maxillary right second molar mesio-occlusodistal amalgam restoration with a buccal extension” (11 words, or 81 letters). Simplified by using the Universal Numbering System (and other standard abbreviations to denote tooth restoration surfaces described later in Chapter 10), this same information would be “2MODBA” (only six symbols).

The **Universal Numbering System** was first suggested by Parreidt in 1882, and officially adopted by the American Dental Association in 1975. It is accepted by third-party providers and is endorsed by the American Society of Forensic Odontology. Basically, the Universal Numbering System uses No. 1 through 32 for the 32 teeth in the permanent dentition, starting with 1 for the maxillary right third molar, going around the arch to the maxillary left third molar as 16; dropping

down on the same side, the left mandibular third molar becomes 17, and then the numbers increase around the lower arch to 32, which is the lower right third molar. This numbering system is used for each permanent tooth in the illustration in *Figure 1-3*.

For the 20 teeth in the primary dentition, 20 letters of the alphabet are used from A through T. The letter A represents the maxillary right second molar, sequentially around the arch and through the alphabet to J for the maxillary left second molar, then dropping down on the same side to K for the mandibular left second molar, and then clockwise around the lower arch to T for the mandibular right second molar. This system is used to identify each primary tooth in the illustration in *Figure 1-4*.

There are also two other numbering systems, the Palmer Tooth Notation System, and the World Dental Federation (International) System used in other countries. The **World Dental Federation** notation (also known as the **Federation Dentaire Internationale** or **FDI System**) uses two digits for each tooth, permanent



**FIGURE 1-3.** The occlusal and incisal surfaces of the maxillary and mandibular **adult dentition** are shown here. The Numbers 1 to 32 on the teeth represent the **Universal Numbering System** commonly used for record keeping in the United States, and used in this book.

or primary. The *first digit* denotes the quadrant (right or left) and arch (maxillary or mandibular) and dentition (permanent or primary) as follows:

#### PERMANENT DENTITION

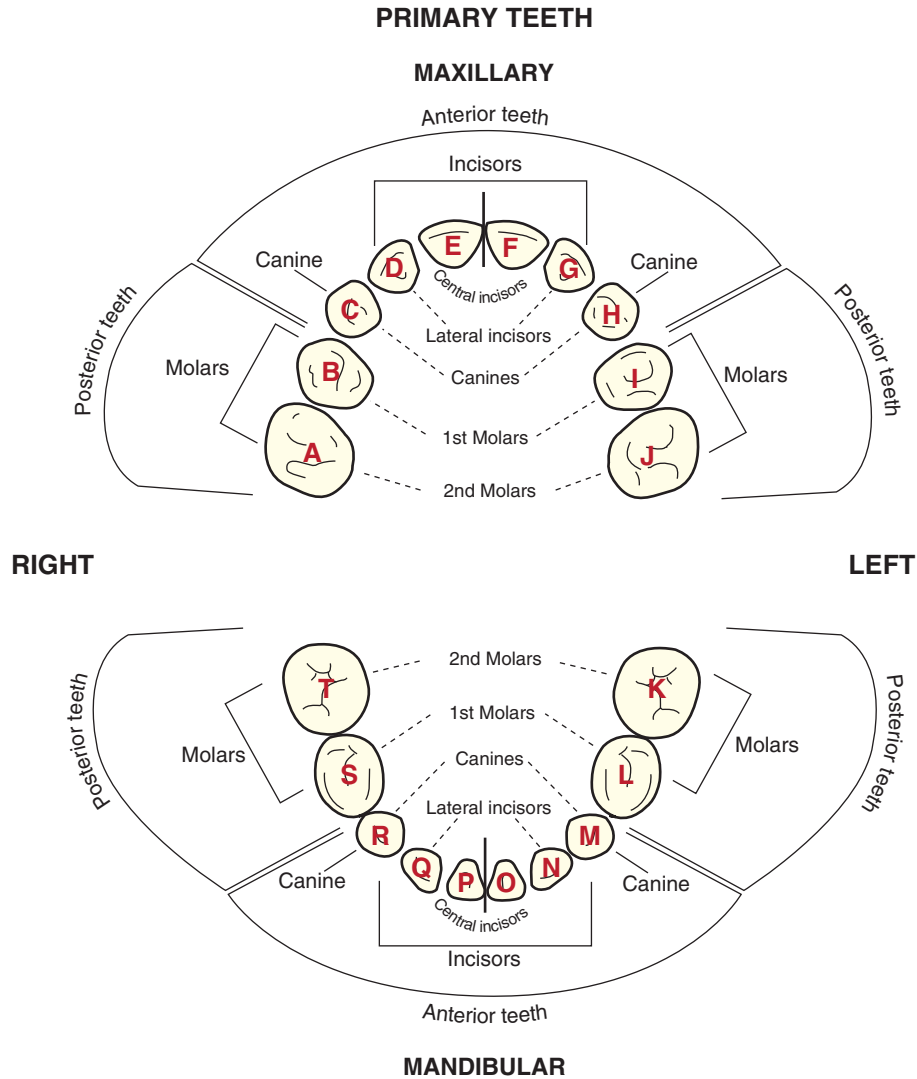
- 1 = Permanent dentition, maxillary, right quadrant
- 2 = Permanent dentition, maxillary, left quadrant
- 3 = Permanent dentition, mandibular, left quadrant
- 4 = Permanent dentition, mandibular, right quadrant

#### PRIMARY DENTITION

- 5 = Primary dentition, maxillary, right quadrant
- 6 = Primary dentition, maxillary, left quadrant
- 7 = Primary dentition, mandibular, left quadrant
- 8 = Primary dentition, mandibular, right quadrant

The *second digit* denotes the tooth position in each quadrant relative to the midline, from closest to the midline to farthest away. Therefore, the second digits 1 through 8 stand for the permanent central incisor (1) through the permanent third molar (8) and 1 through 5 stands for the primary central incisor (1) through the primary second molar (5). The adult tooth Numbers 1 to 8 within each quadrant (1 through 4) are illustrated in *Figure 1-5*. Combining the first and second digits, numbers within the range 11 through 48 represent permanent teeth. For example, 48 is a permanent mandibular right third molar since the first digit, 4, indicates the mandibular right quadrant for a permanent tooth, and the second digit, 8, indicates the eighth tooth from





**FIGURE 1-4.** The occlusal and incisal surfaces of the maxillary and mandibular **primary dentition** are shown here. The letters A to T represent the **Universal Numbering System** for primary teeth commonly used for record keeping in the United States.

the midline in that quadrant, namely, the third molar. Numbers within the range 51 through 85 represent primary teeth. For example, 51 is a primary maxillary right central incisor since the first digit, 5, indicates the maxillary right quadrant for a primary tooth, and the second digit, 1, indicates the first tooth from the midline in that quadrant, namely, the central incisor. If the Universal number for a tooth were 32, the World Dental Federation number would be 48. All of the tooth numbers are shown in *Table 1-1*.

The **Palmer Notation System** is used by many orthodontists and oral surgeons. It utilizes four different bracket shapes to denote each of the four quadrants. The specific bracket surrounds a number (or letter), which denotes the specific tooth within that quadrant.

The specific brackets are designed to represent each of the four quadrants of the dentition, as if you were facing the patient as seen in Figure 1-5.

- ┐ is upper right quadrant
- ┌ is upper left quadrant
- └ is lower right quadrant
- ┘ is lower left quadrant

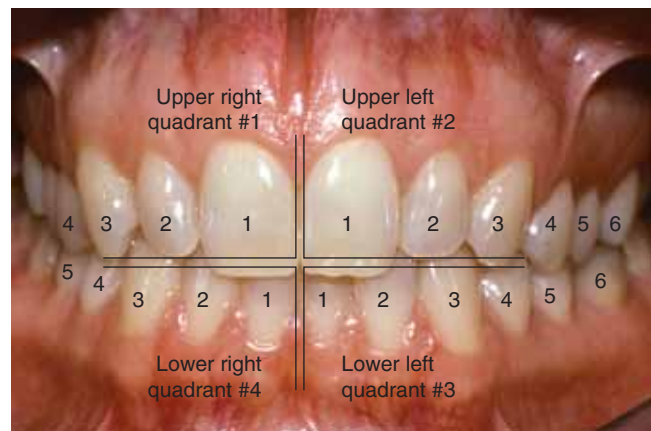
The permanent teeth in each quadrant are numbered from 1 (nearest to the arch midline) to 8 (farthest from the midline) as in the International System. For example, 1 is a central incisor, 2 is a lateral incisor, 3 is a canine, and so forth. The bracket shapes used to identify each quadrant as you are facing a patient, and the tooth numbers (1–8) within each quadrant, are

**Table 1-1 MAJOR TOOTH IDENTIFICATION SYSTEMS**

TOOTH	UNIVERSAL		PALMER NOTATION		INTERNATIONAL (FDI)		
	Right	Left	Right	Left	Right	Left	
PRIMARY DENTITION MAXILLARY TEETH	Central incisor	E	F	Ⓐ	Ⓐ	51	61
	Lateral incisor	D	G	Ⓑ	Ⓑ	52	62
	Canine	C	H	Ⓒ	Ⓒ	53	63
	First molar	B	I	Ⓓ	Ⓓ	54	64
	Second molar	A	J	Ⓔ	Ⓔ	55	65
PRIMARY DENTITION MANDIBULAR TEETH	Central incisor	P	O	Ⓐ	Ⓐ	81	71
	Lateral incisor	Q	N	Ⓑ	Ⓑ	82	72
	Canine	R	M	Ⓒ	Ⓒ	83	73
	First molar	S	L	Ⓓ	Ⓓ	84	74
	Second molar	T	K	Ⓔ	Ⓔ	85	75
PERMANENT DENTITION MAXILLARY TEETH	Central incisor	8	9	Ⓐ	Ⓐ	11	21
	Lateral incisor	7	10	Ⓑ	Ⓑ	12	22
	Canine	6	11	Ⓒ	Ⓒ	13	23
	First premolar	5	12	Ⓓ	Ⓓ	14	24
	Second premolar	4	13	Ⓔ	Ⓔ	15	25
	First molar	3	14	Ⓕ	Ⓕ	16	26
	Second molar	2	15	Ⓖ	Ⓖ	17	27
	Third molar	1	16	Ⓗ	Ⓗ	18	28
PERMANENT DENTITION MANDIBULAR TEETH	Central incisor	25	24	Ⓐ	Ⓐ	41	31
	Lateral incisor	26	23	Ⓑ	Ⓑ	42	32
	Canine	27	22	Ⓒ	Ⓒ	43	33
	First premolar	28	21	Ⓓ	Ⓓ	44	34
	Second premolar	29	20	Ⓔ	Ⓔ	45	35
	First molar	30	19	Ⓕ	Ⓕ	46	36
Second molar	31	18	Ⓖ	Ⓖ	47	37	
Third molar	32	17	Ⓗ	Ⓗ	48	38	

illustrated in Figure 1-5. To identify a specific tooth, you place the number of the correct tooth within the bracket that indicates the correct quadrant. For example, the lower left central incisor would be  $\overline{1}$ , the lower left second premolar would be  $\overline{5}$ , and the upper right canine would be  $\overline{3}$ . For primary teeth, the same four brackets are used to denote the quadrants, but five letters of the alphabet A through E represent the primary teeth in each quadrant (with A being a central incisor, B a lateral incisor, C a canine, etc.). Comparing the Universal System with the Palmer System, the permanent maxillary right second molar would be No. 2 using the Universal System, but would be  $\overline{2}$  using the Palmer system. If you are confused, refer to Table 1-1 for clarification.

Unless otherwise stated, the Universal System of tooth numbering is used throughout this text. To master the Universal System, it may be helpful to memorize the number or letters for key teeth, possibly the central incisors (Numbers 8, 9, 24, and 25) or the first molars (Numbers 3, 14, 19, and 30).



**FIGURE 1-5.** Two methods are shown for denoting each quadrant of adult dentition. The **Palmer System** uses a different “bracket” shape for each quadrant, as indicated, whereas the **International System** uses the Numbers 1 through 4 to denote each adult quadrant. The numbers on each tooth denote the method for identifying teeth within each quadrant beginning at the midline with No. 1 for the central incisors, No. 2 for lateral incisors, etc.

## SECTION III

## TERMINOLOGY USED TO DESCRIBE THE PARTS OF A TOOTH

## A. FOUR TISSUES OF A TOOTH

The tooth is made up of four tissues: enamel, dentin, cementum, and pulp. The first three of these (enamel, dentin, and cementum) are relatively hard since they contain considerable mineral content, especially calcium (so these tissues can also be described as calcified). Only two of these tissues are normally visible in an intact extracted tooth: enamel and cementum. The other two tissues (dentin and pulp) are usually not visible on an intact tooth. Refer to *Figure 1-6* while reading about each tissue.

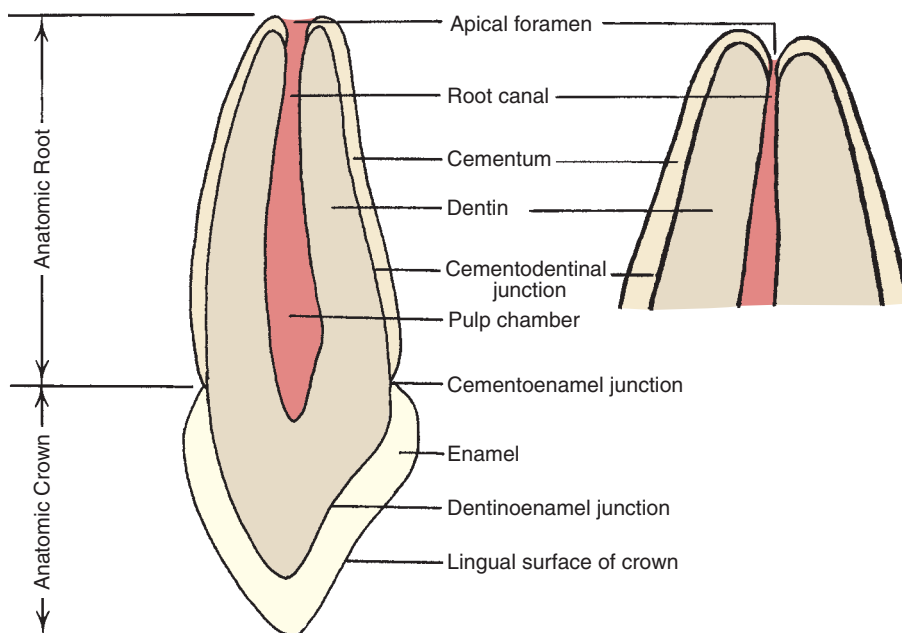
**Enamel** [ee NAM el] is the white, protective external surface layer of the anatomic crown. It is highly calcified or mineralized, and is the hardest substance in the body. Its mineral content is 95% calcium hydroxyapatite (which is calcified). The remaining substances include 5% water and enamel matrix. It develops from the enamel organ (ectoderm) and is a product of specialized epithelial cells called **ameloblasts** [ah MEL o blasts].

**Cementum** [se MEN tum] is the dull yellow external layer of the tooth root. The cementum is very thin, especially next to the cervical line, similar in thickness to a page in this text (only 50–100  $\mu\text{m}$  thick where one  $\mu\text{m}$  is one millionth of a meter). It is composed of 65% calcium hydroxyapatite (mineralized and calcified), 35% organic matter (collagen fibers), and 12% water. (Another author, Melfi, states that the mineral content

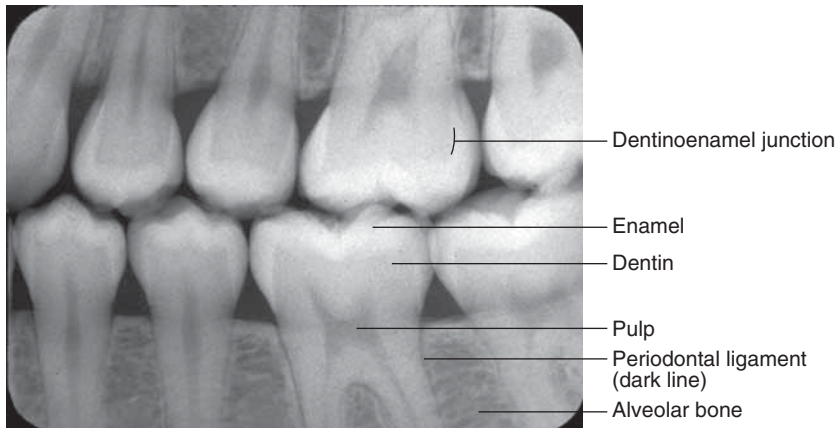
of cementum is about 50%.) Cementum is about as hard as bone but considerably softer than enamel. It develops from the dental sac (mesoderm), and is produced by cells called **cementoblasts** [se MEN toe blasts].

The **cementoenamel** [se MEN toe ehn AM el] **junction** (also called the **CEJ**) separates the enamel of the crown from the cementum of the anatomic root. This junction is also known as the **cervical** [SER vi kal] **line**, denoting that it surrounds the neck or **cervix** [SER viks] of the tooth.

**Dentin** [DEN tin] is the hard yellowish tissue underlying the enamel and cementum, and makes up the major bulk of the inner portion of each tooth crown and root. It extends from the pulp cavity in the center of the tooth outward to the inner surface of the enamel (on the crown) or cementum (on the root). Dentin is not normally visible except on a dental radiograph, or when the enamel or cementum have been worn away, or cut away when preparing a tooth with a bur, or destroyed by decay. Mature dentin is composed of about 70% calcium hydroxyapatite, 18% organic matter (collagen fibers), and 12% water, making it harder than cementum but softer and less brittle than enamel. Dentin develops from the embryonic dental papilla (mesoderm). The cells that form dentin, called **odontoblasts** [o DON toe blasts], are located at the junction between pulp and dentin.



**FIGURE 1-6.** A maxillary anterior tooth sectioned longitudinally through the middle to show the distribution of the **tooth tissues** and the shape of the pulp cavity (made up of pulp chamber and root canal). On the right is a close-up of the apical portion depicting the usual expected constriction of the root canal near the apical foramen. The layer of cementum covering the root of an actual tooth is proportionately much thinner than seen in these drawings.



**FIGURE 1-7.** Radiographs (x-rays) showing tooth crowns covered with enamel, and the tooth roots embedded within the alveolar bone. You can distinguish the whiter outer enamel shape from the darker inner dentin, and the darkest pulp chamber in the middle of the tooth. The very thin, dark periodontal ligament can also be seen between the root and the bone, but the cementum cannot be seen.

The **dentinoenamel** [DEN tin o ehn AM el] **junction** is the inner surface of the enamel cap where enamel joins dentin. This junction can be best seen on a radiograph (Fig. 1-7). The **cementodentinal** [se MEN toe DEN tin al] (or **dentinoceamental**) **junction** is the inner surface of cementum where cementum joins dentin. Cementum is so thin that it is difficult to identify this junction on a radiograph.

**Pulp** is the soft (not calcified or mineralized) tissue in the cavity or space in the center of the crown and root called the **pulp cavity**. The pulp cavity has a coronal portion (**pulp chamber**) and a root portion (**pulp canal** or **root canal**). The pulp cavity is surrounded by dentin, except at a hole (or holes) near the root tip (apex) called an **apical** [APE i kal] **foramen** [fo RAY men] (plural **foramina** [fo RAM i na]). Nerves and blood vessels enter the pulp through apical foramina. Like dentin, the pulp is normally not visible, except on a dental radiograph (x-ray) or sectioned tooth (Fig. 1-7). It develops from the dental papilla (mesoderm). Pulp is soft connective tissue containing a rich supply of blood vessels and nerves. Functions of the dental pulp are as follows:

- **Formative:** Dentin-producing cells (odontoblasts) produce dentin throughout the life of a tooth. This is called **secondary dentin**.
- **Sensory:** Nerve endings relay the sense of pain caused from heat, cold, drilling, sweet foods, decay, trauma, or infection to the brain, so we feel it. However, the nerve fibers in a dental pulp are unable to distinguish the cause of the pain.
- **Nutritive:** Blood vessels transport nutrients from the bloodstream to cells of the pulp and the odontoblasts that produce dentin. (Surprisingly, blood in the tooth pulp had passed through the heart only 6 seconds previously.)

- **Defensive or protective:** Pulp responds to injury or decay by forming **reparative dentin** (by the odontoblasts).

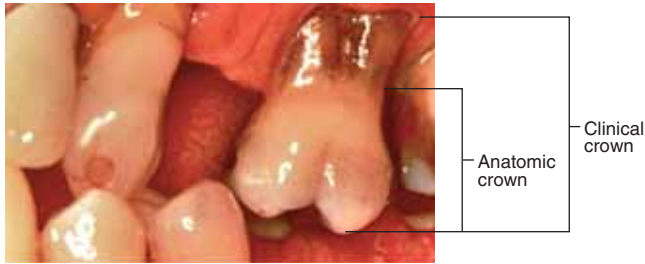
## B. ANATOMIC VERSUS CLINICAL CROWN AND ROOT

### 1. ANATOMIC CROWN AND ROOT DEFINITION

The **anatomic crown** is that part of the tooth (in the mouth or handheld) normally covered by an enamel layer, and the **anatomic root** is the part of a tooth covered by cementum (Fig. 1-6). A **cervical line** (or **cementoenamel junction**) separates the anatomic crown from the anatomic root. This relationship does not change over a patient's lifetime.

### 2. CLINICAL CROWN AND ROOT (ONLY APPLIES WHEN THE TOOTH IS IN THE MOUTH AND AT LEAST PARTIALLY ERUPTED)

The **clinical crown** refers specifically to the amount of tooth visible in the oral cavity, and the **clinical root** refers to the amount of tooth that is not visible since it is covered with gingiva (gum tissue). Clinically, the gingival margin in a 25-year-old patient with healthy gingiva approximately follows the curvature of the cervical line, and under these conditions, the clinical crown is essentially the same as the anatomic crown. However, the gingival margin is not always at the level of the cervical line because of the eruption process early in life or due to recession of the gingiva later in life. For example, the gingiva on a partially erupted tooth of a 10-year-old covers much of the enamel of the anatomic crown of the tooth, resulting in a clinical crown (exposed in the



**FIGURE 1-8.** This maxillary molar has a **very long clinical crown** since all of the anatomic crown and much of the anatomic root are exposed due to recession of the gingiva and loss of bone.

mouth) that is much shorter than the anatomic crown. The clinical root (not visible in the mouth) would be longer than the anatomic root (consisting of the anatomic root plus the part of the anatomic crown covered with gingiva).

In contrast, the gingival margin in a 70-year-old person may exhibit gingival recession, especially after having periodontal disease or periodontal therapy, exposing

more of the anatomic root. This results in a clinical crown that is longer than the anatomic crown since the clinical crown in this mouth consists of the entire anatomic crown plus the part of the anatomic root that is exposed (*Fig. 1-8*). In this situation, the clinical root is shorter than the anatomic root.

### LEARNING EXERCISE

Examine the mouths of several persons of different ages to see if the cervical line of the anatomic tooth is visible or hidden. As the individual grows older, the location of the margin of the gingiva may recede toward the root tip (apically) because of periodontal disease or injury (such as from the faulty use of oral hygiene aids). Of course, the location of the cervical line on the tooth remains the same. In other words, the distinction between the anatomic crown and root does not change over a lifetime.

## SECTION IV

## INTRODUCTION TO THE PERIODONTIUM

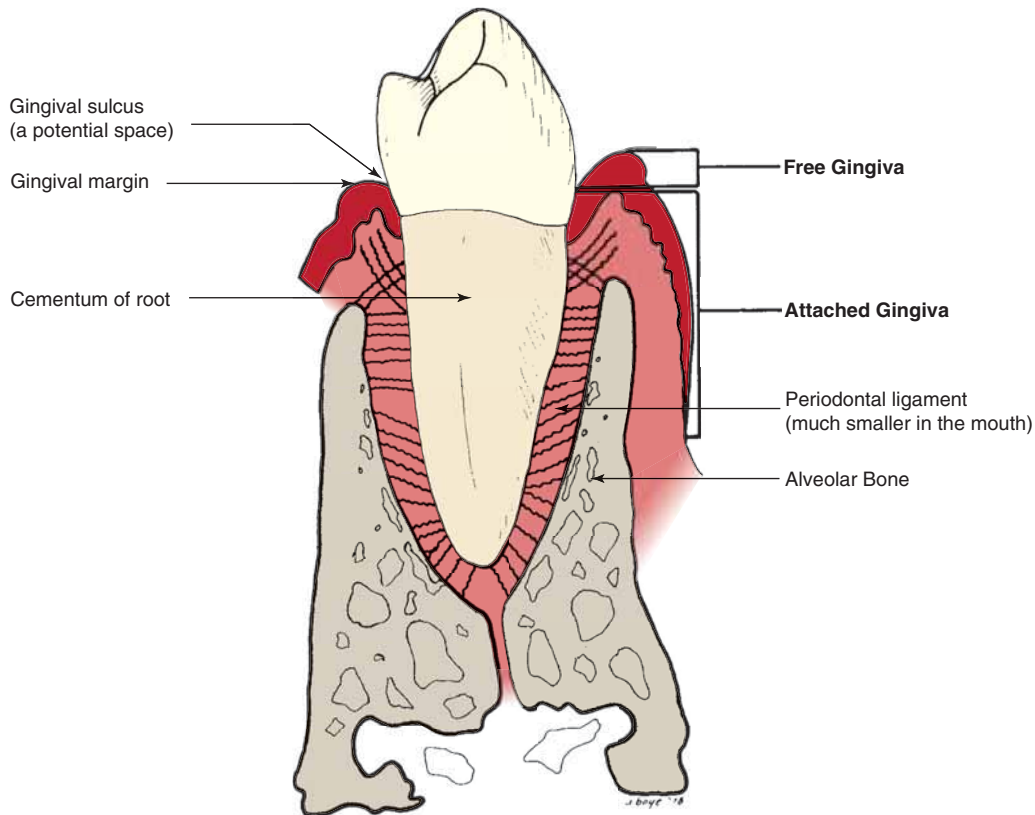
The **periodontium** [per e o DON she um] is defined as the supporting tissues of the teeth in the mouth, including surrounding alveolar bone, the gingiva, the periodontal ligament, and the outer, cementum layer of the tooth roots (*Fig. 1-9*). **Alveolar bone** is the portion of the upper (maxillary) or lower (mandibular) bones that surrounds the roots of the teeth. The gingiva is the part of the soft tissue in the mouth that covers the alveolar bone of the jaws, and is the only part of the periodontium that is visible in a healthy mouth. Part of it is firmly bound to the underlying alveolar bone and is called **attached gingiva**. The other part is **free gingiva** (or marginal gingiva) which is a collar of thin gingiva that surrounds each tooth and, in health, adapts to the tooth but provides access into the potential space between the free gingiva and the tooth which is called a **gingival sulcus** (crevice). The **gingival margin** (or free gingival margin) is the edge of the gingiva closest to the biting or chewing surfaces of the teeth (*Fig. 1-10*).

The gingival sulcus is not seen visually but can be evaluated with a periodontal probe, since it is actually

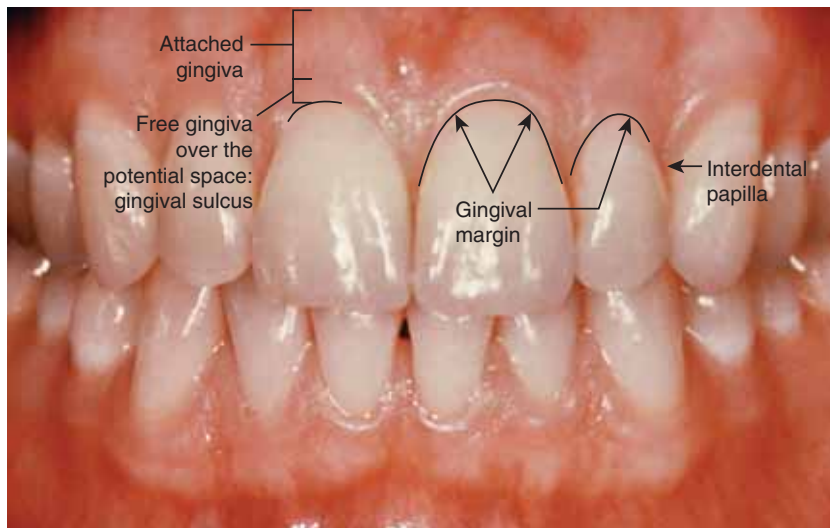
a space (or potential space) between the tooth surface and the narrow unattached cervical collar of free gingiva. If you insert a thin probe into this sulcus, it should extend only 1 to 3 mm deep in a healthy person. The **interdental (interproximal) papilla** [pah PILL ah] (plural is papillae [pa PILL ee]) is that part of the collar of free gingiva that extends between the teeth. A healthy papilla conforms to the space between two teeth (interproximal space), so it comes to a point near where the adjacent teeth contact. The papilla also has a hidden sulcus where dental floss can fit once it passes between the teeth.

The **periodontal ligament** is a very thin ligament composed of many tissue fibers that attach the outer layer of the tooth root (covered with cementum) to the thin layer of dense alveolar bone surrounding each tooth. The groups of fibers of the periodontal ligament represented in *Figure 1-9* are greatly enlarged. The entire thickness of the ligament would only be about as thick as a page or two in this text.





**FIGURE 1-9.** This diagram is a tooth supported within the **periodontium**. The healthy periodontium is made up of **alveolar bone** which surrounds the anatomic root, **gingiva** (gum tissue) which covers the bone, **cementum** which covers the tooth root, and the **periodontal ligament** which connects the bone to the cementum of the tooth.



**FIGURE 1-10.** Gingiva surrounds each tooth forming a characteristic scalloped shape **gingival margin**. **Interproximal papillae** fill the spaces between most teeth. The **potential space** between the **free gingiva** and the tooth can be accessed with a thin periodontal probe. The **attached gingiva** is the gingiva which is firmly attached to the underlying bone.

## SECTION V

## TERMINOLOGY USED TO DEFINE TOOTH SURFACES

All teeth have surfaces that are named according to their usual alignment within the dental arch. Refer to *Figure 1-11* when studying the terms to denote tooth surfaces.

### A. TERMS THAT IDENTIFY OUTER SURFACES (TOWARD THE CHEEKS OR LIPS) OF ANTERIOR VERSUS POSTERIOR TEETH

The **facial surface** of a tooth is the surface toward the face, that is, the surface of a tooth in the mouth resting against or next to the cheeks or lips. Facial may be used to designate this surface of any tooth, anterior or posterior. Another name for the facial surface of *posterior* teeth is **buccal** [BUCK k'l], located next to the cheek (labeled on tooth No. 3 in Fig. 1-11). It is incorrect to use this term when speaking about the incisors or canines because they do not approximate the cheeks. The facial surface of *anterior* teeth is properly called a **labial** [LAY bee al] surface, located next to

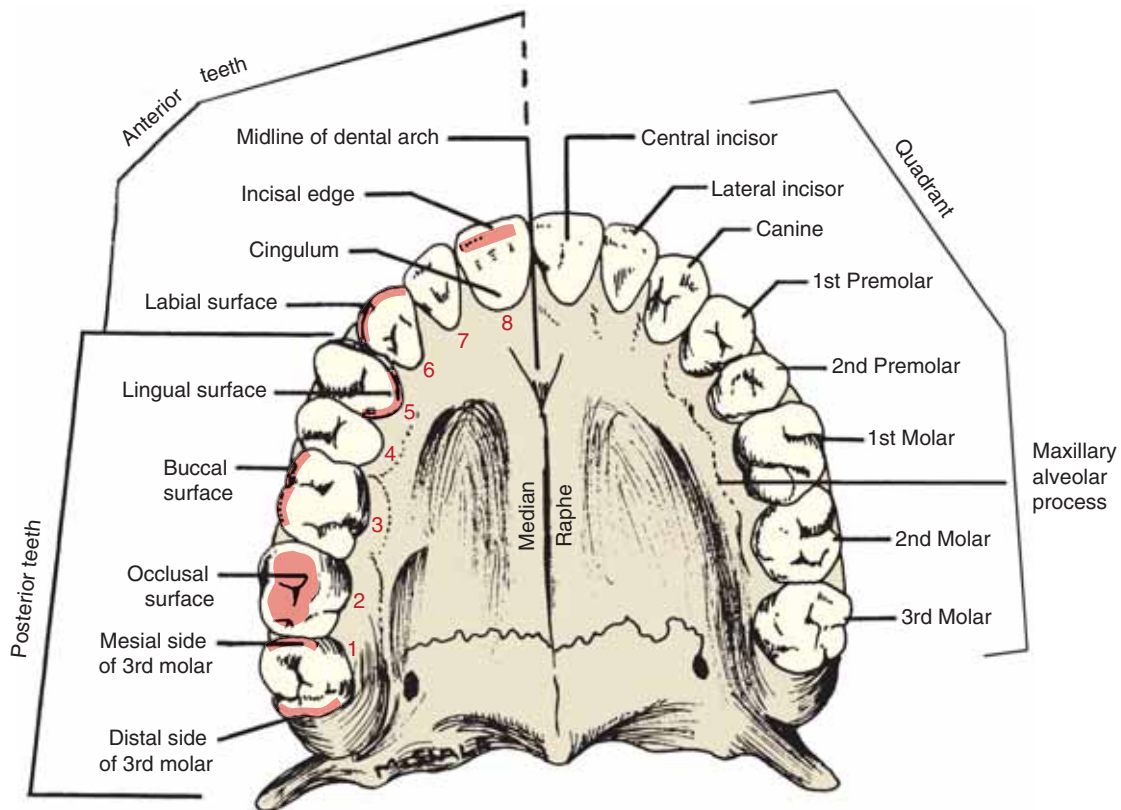
the lips (labeled on tooth No. 6 in Fig. 1-11). This term should not be used when referring to the premolars or the molars.

### B. TERMS THAT IDENTIFY INNER SURFACES (TOWARD THE TONGUE) OF MAXILLARY VERSUS MANDIBULAR TEETH

The **lingual** [LIN gw'al] surface is the surface of a maxillary or mandibular tooth nearest the tongue. In the maxillary arch, this surface can also be called the **palatal surface** due to its proximity with the palate (labeled on tooth No. 5 in Fig. 1-11).

### C. TERMS THAT DIFFERENTIATE BITING SURFACES OF ANTERIOR VERSUS POSTERIOR TEETH

The **occlusal** [ahk KLOO zal] surface is the chewing surface of a posterior tooth (labeled on tooth No. 2 in



**FIGURE 1-11.** Maxillary dental arch of teeth with a sampling of **tooth surfaces** labeled. Remember that the labial surface of an anterior tooth and the buccal surface of a posterior tooth are both referred to as facial surfaces. Also, the mesial and distal sides or surfaces are both correctly called proximal surfaces.



Fig. 1-11). Anterior teeth (incisors and canines) do not have an occlusal surface but do have a cutting incisal edge or ridge (labeled on tooth No. 8 in Fig. 1-11).

### D. TERMS THAT DIFFERENTIATE APPROXIMATING SURFACES OF TEETH

The **proximal** [PROCK se mal] surfaces are the sides of a tooth generally next to an adjacent tooth. Depending on whether the tooth surface faces toward the arch midline between the central incisors or away from the midline, it is either a **mesial** [MEE zi al] surface (closer to the midline) or a **distal** [DIS tal] surface (farther from the midline). Mesial and distal surfaces are labeled on tooth No. 1 in Figure 1-11. Note that the mesial surface of a tooth touches, or is closest to, the distal surface of an adjacent tooth EXCEPT between the central incisors where the mesial surface of one central incisor faces another mesial surface. Also, the distal surface of the last molar in each arch does not approximate another tooth. Proximal surfaces are not *naturally* cleaned by the action of the cheeks, lips and tongue when compared to most of the facial or lingual surfaces which are more self-cleansing.

### E. TERMS TO DENOTE TOOTH SURFACE JUNCTIONS OR DIMENSIONS

The junction line where two tooth surfaces meet is called an external **line angle**. To name a line angle, combine the names of the two surfaces, but change the “al” ending of the first surface to an “o.” (A guideline has been suggested for the order used when combining terms. Use the following order: mesial is used first, then distal, facial, lingual, and lastly occlusal or incisal. Using this guideline, it is better to say mesio-occlusal than occlusomesial, and it is better to say distolingual than linguodistal.)

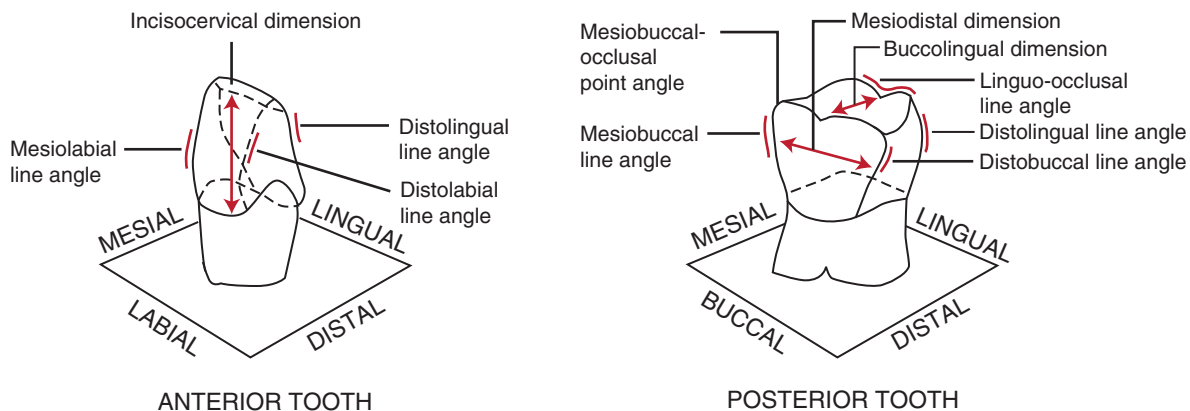
Examples of external line angles of a molar crown include mesio-occlusal, mesiolingual, mesiofacial, disto-occlusal, distolingual, distofacial, bucco-occlusal, and linguo-occlusal. **Point angles** are the junctions of three tooth surfaces at a point, such as a mesio-bucco-occlusal point angle. Examples of these external line angles and point angles are seen in Figure 1-12.

To describe a **dimension of a tooth**, terms can be combined to denote the direction over which a dimension is taken. For example, the length of an incisor crown from the incisal edge to the cervical line is called the incisocervical dimension or the dimension incisocervically (Fig. 1-12). Other similar terms used to describe a crown dimension include mesiodistal, faciolingual or buccolingual, and occlusocervical. The length of a root could be described as its cervicoapical dimension.

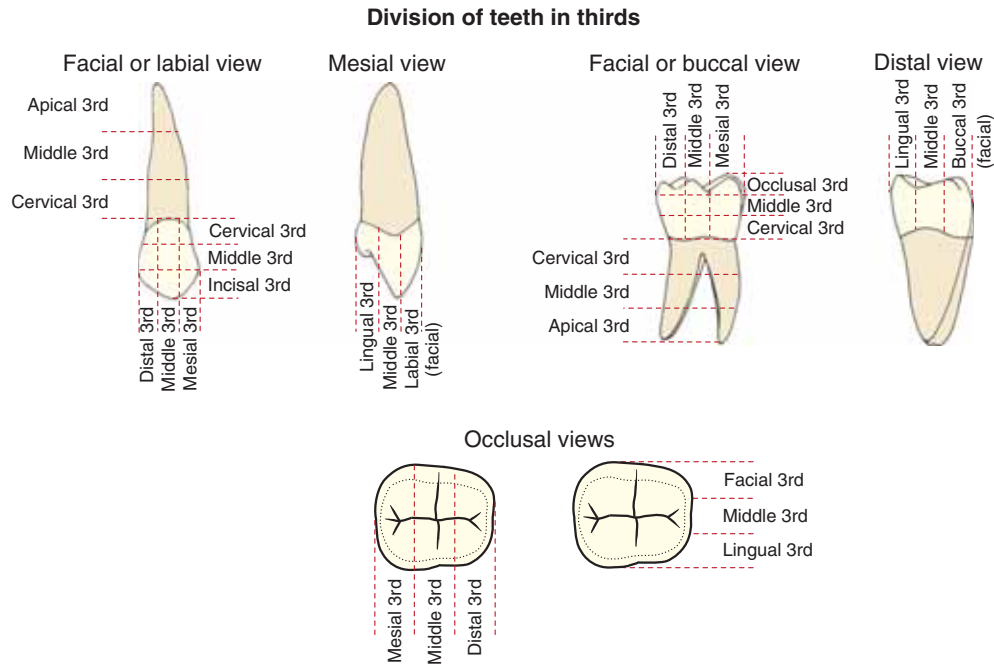
### F. DIVISIONS (THIRDS) OF THE CROWN OR ROOT (FOR PURPOSES OF DESCRIPTION)

A tooth can be divided into **thirds** in order to define more precisely the location of its specific landmarks (Fig. 1-13). When viewing a tooth from the facial, lingual, mesial, or distal surface, *horizontal* lines can divide the tooth *crown* into the following thirds: cervical, middle, and occlusal (or incisal). Similarly, *horizontal* lines can divide the *root* into thirds: cervical, middle, and apical (toward the root tip or apex).

When viewing a tooth from the facial (or lingual) surface, *vertical* lines can be used to divide the crown or root into mesial, middle, and distal thirds. When viewing a tooth from the proximal (mesial or distal) surface, *vertical* lines can be used to divide the crown or root into facial, middle, and lingual thirds. When viewing a tooth from the occlusal (or incisal) surface, lines running mesiodistally can be used to divide the crown



**FIGURE 1-12.** Diagrammatic representation of an incisor and molar crown shows some external tooth **line angles** and **point angles**. Three examples to denote **dimensions** are also included.



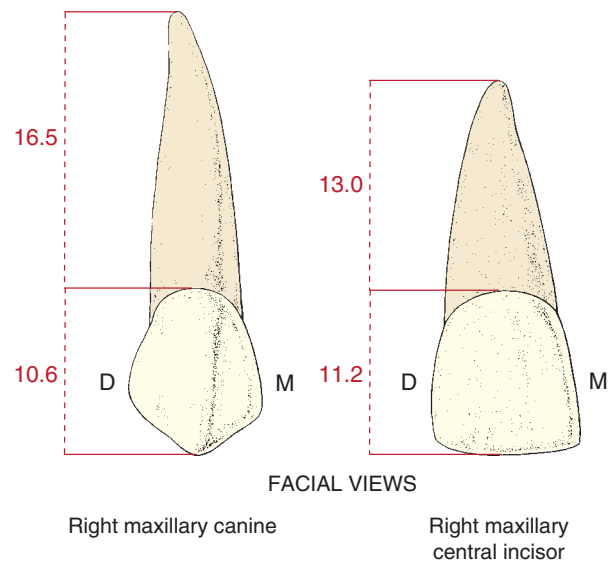
**FIGURE 1-13.** Diagrams of a maxillary canine and mandibular molars to show how a crown or root may be divided into **thirds** from each view for purposes of describing the location of anatomic landmarks, contact areas, and so forth.

into facial, middle, and lingual thirds, and lines running faciolingually can be used to divide the tooth into mesial, middle, and distal thirds.

### G. ROOT-TO-CROWN RATIO

If we know the length of a tooth root from the cervical line to the tip of the root (or tip of the longest buccal root of teeth with multiple roots) and the length of the crown (from the cervical line to the tip of the longest cusp or highest part of the incisal edge), we can calculate a root-to-crown ratio. The **root-to-crown ratio** is the root length divided by crown length. Since the roots of teeth are normally longer than their crowns, the root-to-crown ratios for teeth are normally  $>1.0$ . For example, the average root length of a maxillary central incisor is only 13.0 mm and the crown length is 11.2 mm; these lengths are not that different compared to other teeth. The root-to-crown ratio is 13 divided by 11.2, which equals 1.16. When this number is close to 1, it indicates that the root is not much longer than the crown. Compare this with a maxillary canine, where the average root is much longer, at 16.5 mm, but the crown is only 10.6 mm, for a much larger root-to-crown ratio of 1.56. This larger ratio indicates that the root is over one and a half times (1.56 $\times$ ) longer than the crown. The obvious difference between the root-to-crown ratio on these two teeth is apparent in *Figure 1-14*. The ratio can be clinically significant, since a tooth with a small root-to-crown ratio (closer to 1)

is not the best choice for attaching and supporting false teeth, because the additional attached teeth would apply even more force on a tooth that already has a short root compared to its crown length.



**FIGURE 1-14.** Compare the **root-to-crown ratio** of the maxillary central incisor where the root is not much longer than the crown (and the ratio is only 13 divided by 11.2, or 1.16), and the maxillary canine where the root is considerably longer than the crown (and the ratio is much larger: 16.5 divided by 10.6, or 1.56).

**SECTION VI**

**TERMINOLOGY USED TO DESCRIBE THE MORPHOLOGY OF A TOOTH**

**A. MORPHOLOGY OF AN ANATOMIC CROWN**

Teeth are made up of many rounded elevations, ridges, depressions, and grooves. Specific tooth structures that occur with some frequency on teeth within a class have been assigned specific names. To identify the following anatomic structures, reference will be made to representative drawings of various teeth seen in figures throughout this section.

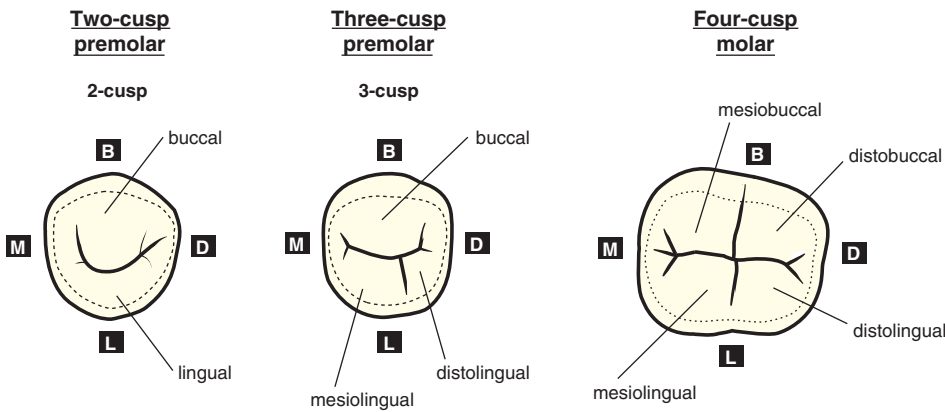
**1. ELEVATIONS (ROUNDED) AND RIDGES (LINEAR)**

A **cuspid** (with a cuspid tip or apex) is a pyramidal elevation, or peak, located on the occlusal surfaces of molars and premolars, and on the incisal edges of canines.

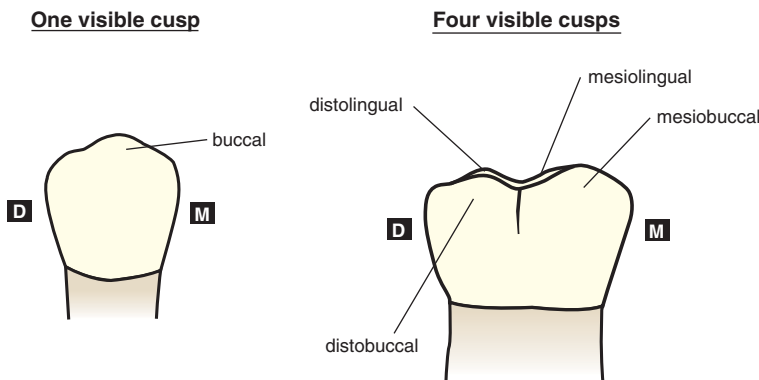
A cuspid is named according to its location on the tooth. For example, on a two-cuspid premolar, the two cusps are named after the surface adjacent to each cuspid: buccal or lingual. On a four-cuspid molar, the four cusps are named after the adjacent line angles: mesiobuccal, distobuccal, mesiolingual, and distolingual. Refer to *Figure 1-15* for examples of cuspid names on teeth with two, three, and four cusps.

Each cuspid has **four cuspid ridges** (linear prominences of enamel) converging toward the cuspid tip. These four ridges form the shape of a four-sided, somewhat rounded pyramid. If you drew a line along the greatest linear bulge of each of these four ridges, the lines would intersect at the cuspid tip (indicated by the "X" on *Fig. 1-16*). On this example, three of the ridges are named after the circumferential tooth surface they

**VIEWED FROM OCCLUSAL**

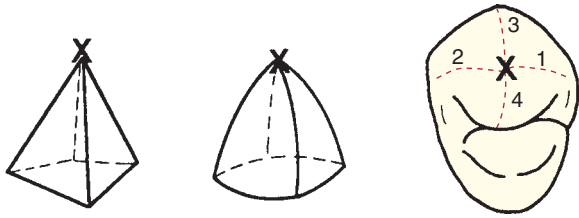


**VIEWED FROM BUCCAL**



**FIGURE 1-15.** Cuspid names on teeth having two, three, and four cusps, viewed from the occlusal and buccal views. Notice that the cusps are named after the adjacent surface or line angle.

All cusps are basically a gothic pyramid:



The cuspal gothic pyramid produces 4 ridges:

1. Mesial cusp ridge
2. Distal cusp ridge
3. Buccal cusp ridge (labial ridge on canines)
4. Triangular ridge on posterior teeth (lingual ridge on canines)

**FIGURE 1-16.** Buccal cusp of a two-cusped premolar showing the pyramidal design (actually, the pyramid with rounded sides is called a gothic pyramid) formed by the **four cusp ridges** that make up each cusp. These are numbered 1 to 4 and converge at the cusp tip (X). (Courtesy of Drs. Richard W. Huffman and Ruth Paulson.)

extend toward: the more subtle facial (buccal or labial) ridge actually extends onto the facial surface, the mesial cusp ridge extends from the cusp tip toward the mesial surface, and the distal cusp ridge extends from the cusp tip toward the distal surface. The fourth ridge from the cusp tip to the faciolingual middle of the tooth is called a triangular ridge.

The **mesial** and **distal cusp ridges** are also known as cusp slopes or cusp arms. When viewed from the facial or lingual aspect, they are the inclined surfaces or slopes that converge toward the cusp tip to form an angle (seen on the facial cusps of a premolar and molar in *Fig. 1-17*, and on the lingual cusp of a premolar from the occlusal view in *Fig. 1-19A*). For some teeth, the sharpness or bluntness of a cusp angle could be an important trait.

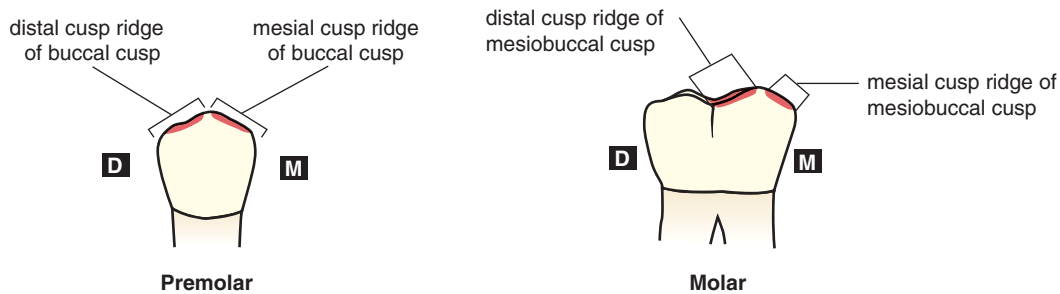
On *anterior* teeth, mesial and distal **marginal ridges** are located on the mesial and distal border of the *lingual* surface and converge toward the cingulum seen on the lingual surface of an incisor in *Figure 1-18*. On *posterior* teeth, marginal ridges are located on the mesial and dis-

tal borders of the *occlusal* surface. The mesial marginal ridge on a premolar is shaded red in *Figure 1-19A*.

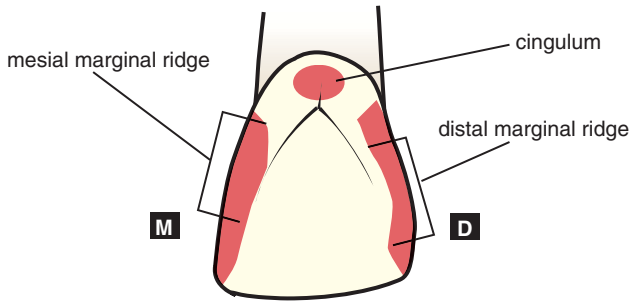
**Triangular ridges** are located on each major cusp of posterior teeth. Each triangular ridge extends from a cusp tip toward the depression (sulcus) in the middle of the occlusal surface faciolingually (*Fig. 1-19A and B*). When a triangular ridge from a facial cusp joins with a triangular ridge from an adjacent lingual cusp, the two ridges together form a longer ridge called a **transverse ridge**. A **transverse ridge** crosses the occlusal surface of posterior teeth in a more or less buccolingual direction, running between the buccal and lingual cusps on a premolar (*Fig. 1-19*) or connecting the buccal and lingual cusps that are lined up across from one another on a molar (seen on the two-cusped premolar and on a mandibular molar in *Fig. 1-20*). An **oblique ridge** is found only on maxillary molars. It crosses the occlusal surface obliquely (diagonally) and is made up of one ridge on the mesiolingual cusp joining with the triangular ridge of the distobuccal cusp (seen in *Fig. 1-20* on the maxillary molar). According to Ash,<sup>1</sup> the ridge of the mesiolingual cusp that forms the lingual half of the oblique ridge is the *distal cusp ridge* of the mesiolingual cusp.

Perhaps the most indistinct ridge emanating from the cusp tip is the facial (labial or buccal) ridge. The **buccal (cusp) ridge** is a subtle ridge running cervico-occlusally in the middle third of the buccal surface of premolars (*Fig. 1-19A*). Similar in appearance to a buccal ridge on posterior teeth, a canine has a **labial ridge** that runs cervico-incisally and can be very prominent on maxillary canines.

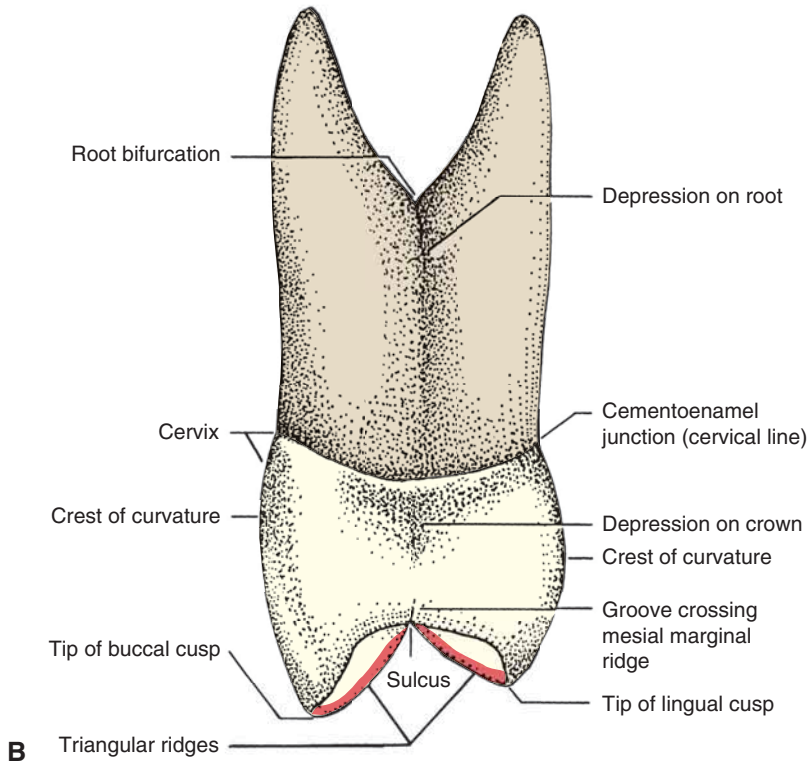
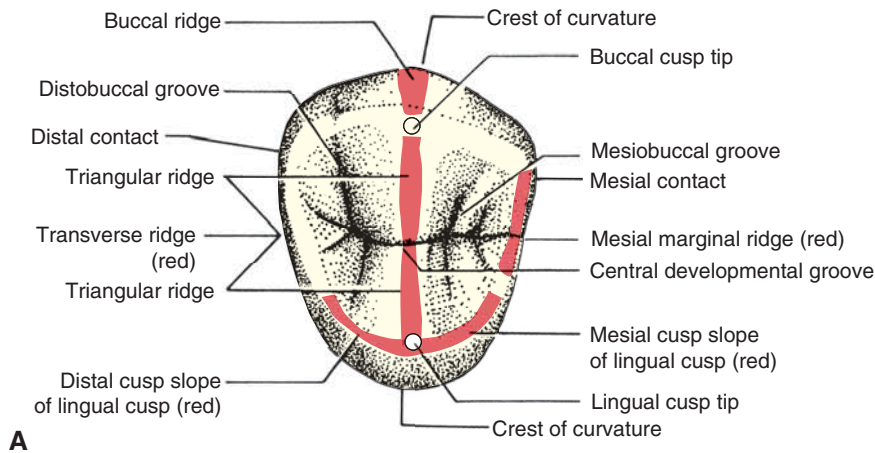
When viewing posterior teeth from the occlusal view, it is important to distinguish the crown outline of an entire tooth from the occlusal table of that tooth. The **crown outline** is the outer outline of the entire tooth crown from the occlusal view, whereas the **occlusal table** is the outline of the smaller occlusal surface that is bounded by adjoining mesial and distal cusp ridges and marginal ridges that surround it (*Fig. 1-21*).



**FIGURE 1-17.** Cusp ridges (cusp slopes) are labeled on the facial cusp of a premolar, and on the mesiobuccal cusp of a four-cusped molar.

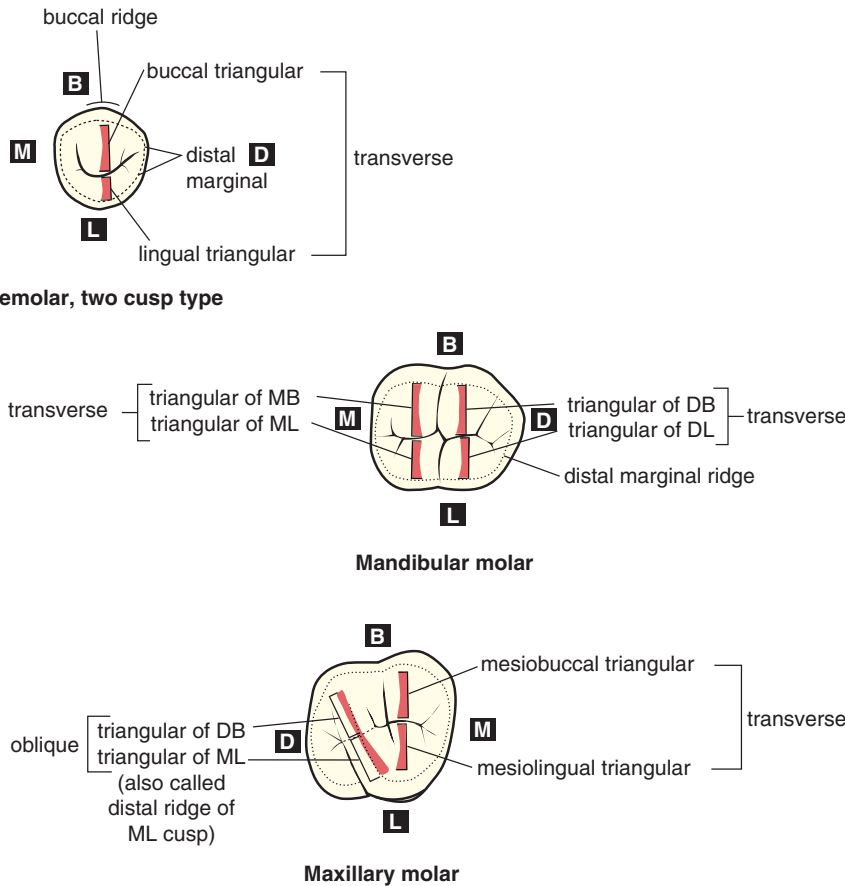


**FIGURE 1-18.** The mesial and distal **marginal ridges** and **cingulum** shaded red on the lingual surface of an incisor.



**FIGURE 1-19.** **A.** Occlusal surface of a two-cusped premolar. Notice the **cusp ridges**: the buccal and triangular ridges shaded red on the buccal cusp, and the mesial and distal cusp ridges and triangular ridge shaded red on the lingual cusp. One marginal ridge (the mesial) is also shaded red. The two connecting triangular ridges form one transverse ridge. **B.** Mesial surface of a two-cusped premolar. The two **triangular ridges** join at the depth of the occlusal sulcus to form one **transverse ridge**.

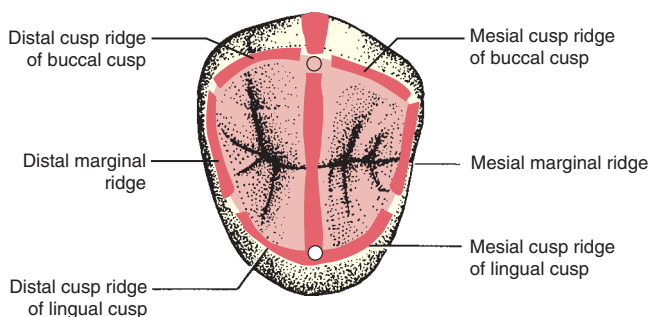




**FIGURE 1-20.** Three teeth show **transverse** and **oblique** ridges. **A.** Two triangular ridges on a two-cusped premolar form **one transverse** ridge. **B.** Two pairs of triangular ridges on a mandibular molar form **two transverse** ridges. **C.** One pair of triangular ridges on a maxillary molar is aligned buccolingually and forms **one transverse** ridge, and another pair of ridges is aligned obliquely (diagonally) to form an **oblique** ridge.

Other bulges or ridges can be seen on the cervical third of certain teeth facially or lingually. On the lingual of all anterior teeth, a **cingulum** [SING gyoo lum] is the enlargement or bulge on the cervical third of the lingual surface of the crown on anterior teeth (incisors and canines) (Figs. 1-18 and 1-23).

On the facial surface of permanent molars (and all primary teeth), the subtle ridge running mesiodistally in the cervical one third of the facial surface of a crown is called the **cervical ridge**. It is most pronounced on the outline of the mesiobuccal cusp of mandibular second molars as seen in *Figure 1-24*.

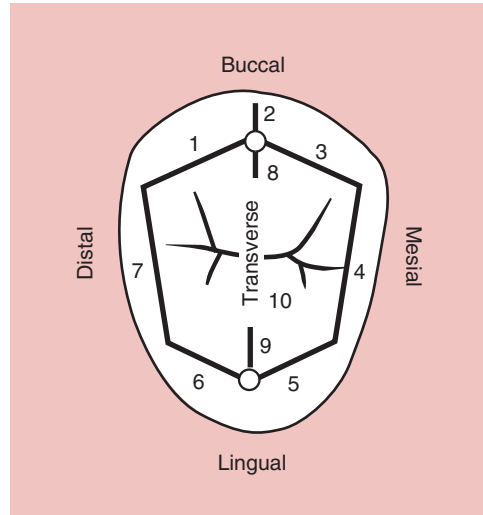


**FIGURE 1-21.** Occlusal view of a two-cusp premolar showing the difference between the outer **occlusal outline**, and the smaller red **occlusal table** (or occlusal chewing surface).

**Mamelons** are three small tubercles or scallops, each formed from one of the three facial developmental lobes on the incisal edges of newly erupted incisors (*Fig. 1-25*). (Lobes will be described in more detail in the last section of this chapter.) Usually mamelons are not evident on adult dentition since they are worn off after the tooth comes into functional contact with its opposing teeth. If you have the opportunity, observe a 7-year-old smile to see these mamelons on newly erupted incisors. When mamelons remain on an adult, it is because these teeth do not contact opposing teeth in function, as may occur when maxillary and mandibular anterior teeth do not touch together during function (called an anterior open-bite relationship). When a patient desires, the dentist can reduce the mamelons to make the incisal edge more uniformly curved.

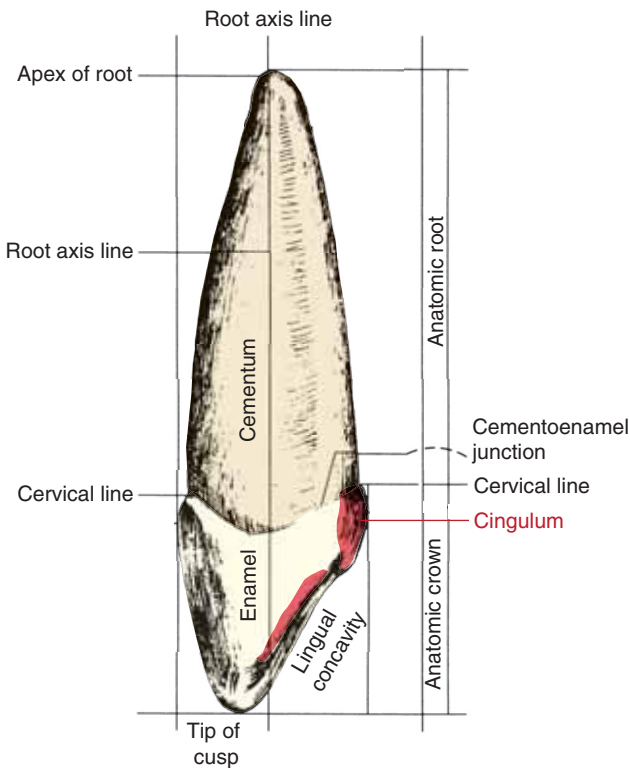
Finally, **perikymata** [pear i KY mah tah] are the numerous, minute horizontal ridges on the enamel of newly erupted permanent teeth (*Fig. 1-26*). They form from the overlapping of layers of enamel laid down during tooth formation. These lines are closer together in the cervical third of the crown than in the incisal third. Perikymata are more prominent on the teeth of young people than on the teeth of older persons because perikymata, like mamelons, wear away from ongoing abrasion due to eating and even tooth brushing with abrasive toothpastes.

1. \_\_\_\_\_
2. \_\_\_\_\_
3. \_\_\_\_\_
4. \_\_\_\_\_
5. \_\_\_\_\_
6. \_\_\_\_\_
7. \_\_\_\_\_
8. \_\_\_\_\_
9. \_\_\_\_\_
10. Transverse



**ANSWERS:** 1—distal cusp ridge of buccal cusp; 2—buccal (cusp) ridge; 3—mesial cusp ridge of buccal cusp; 4—mesial marginal ridge; 5—mesial cusp ridge of lingual cusp; 6—distal cusp ridge of lingual cusp; 7—distal marginal ridge; 8—triangular ridge of buccal cusp; 9—triangular ridge of lingual cusp; 10—Transverse

**FIGURE 1-22.** Identify the ridges numbered on this maxillary premolar.



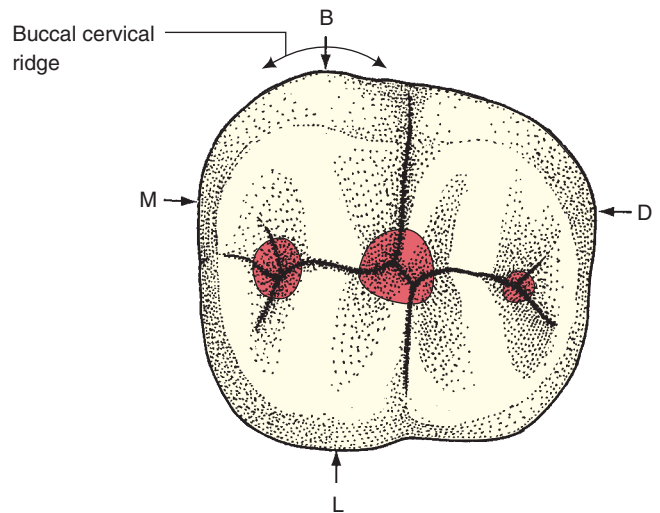
**FIGURE 1-23.** Maxillary canine with a **cingulum** bulge located on the lingual surface in the cervical third.

**2. DEPRESSIONS AND GROOVES**

A tooth **sulcus** [SUL kuss] (plural sulci [SUL sye]) is a broad V-shaped depression or valley running mesiodistally on the occlusal surfaces of posterior teeth.

**LEARNING EXERCISE**

The diagram in Figure 1-22 represents the ridges seen from the occlusal view that bound the occlusal table of a two-cusped premolar. Name each ridge next to its corresponding number. (Note that ridges labeled 1, 3, 4, 5, 6, and 7 form a continuous outline around the occlusal surface. The area inside of this line is called the occlusal table.)



**FIGURE 1-24.** A mandibular four-cusped molar has a **buccal cervical ridge** (most prominent on the outline of the mesiobuccal cusp).

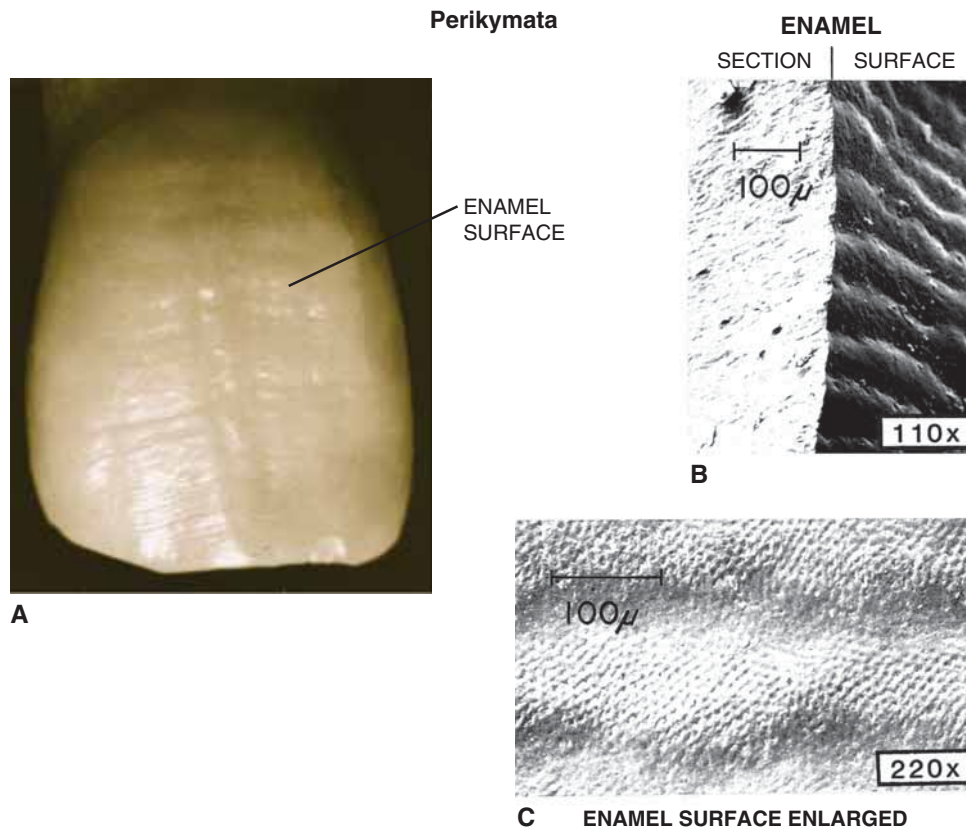




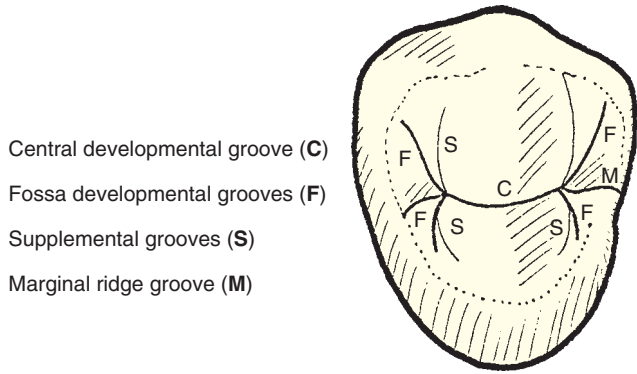
**FIGURE 1-25.** Example of three distinct unworn **mamelons** present on the incisal edge of a mandibular incisor.

The buccal and lingual “sides” that form the sulcus are the triangular ridges that often converge toward a developmental groove in the depth of the sulcus (see Fig. 1-19B). Grooves and their sulci are important escape-ways for food morsels when the teeth of the lower jaw move from side to side and protrude forward against the upper teeth during chewing. Partially chewed food squirts out through grooves toward the tongue and cheeks.

**Developmental grooves** are the major, sharply defined narrow, linear depressions formed during tooth development and usually separating the lobes or major portions of a tooth (described in the last section of this chapter). Like cusps, the major grooves are named according to their location. For example, on the premolar in *Figure 1-27*, the **central groove** is located in the buccolingual center of the tooth sulcus and runs mesiodistally. At each end of the central groove both mesially and distally, **fossa developmental grooves** (or **triangular fossa grooves**) may be found splitting off toward the line angles of the tooth. These grooves can be named for



**FIGURE 1-26.** **A. Perikymata** are the small ridges visible on the labial surface of this incisor. **B.** Magnified cross section of enamel shows perikymata ridges on the tooth surface (on the right) and the long, tightly packed enamel rods of the enamel (on the left). **C.** Higher magnification (220 $\times$ ) of the enamel surface shows enamel rod ends on the perikymata waves. Enamel rods are about 4  $\mu\text{m}$  in diameter. (These scanning electron micrographs were kindly provided by Dr. Ruth B. Paulson, Associate Professor Emeritus, Division of Oral Biology, The Ohio State University.)



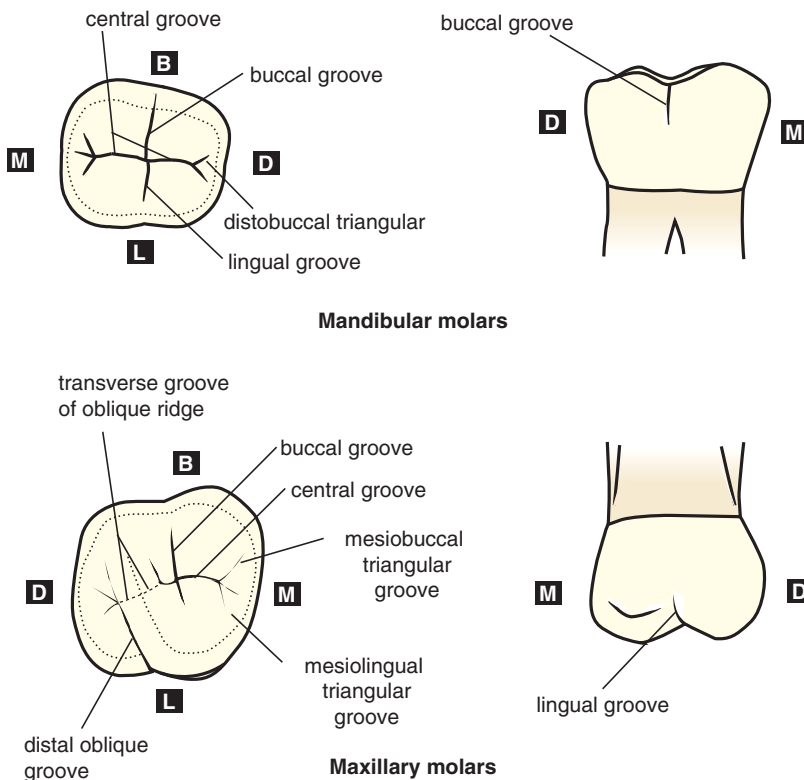
**FIGURE 1-27.** This occlusal surface of a two-cusped premolar has **developmental** (major) and **supplemental** (extra) occlusal grooves. (Courtesy of Drs. Richard W. Huffman and Ruth Paulson.)

the line angles of the tooth toward which they aim, for example, the mesiobuccal fossa developmental groove (sometimes just called mesiobuccal groove). On many molars and three-cusped premolars, major developmental grooves separate adjacent cusps. For example, on mandibular molars, a **buccal groove** runs from the central groove onto the buccal surface separating the mesiobuccal from distobuccal cusps, and on maxillary molars, a **lingual groove** extends from the central sulcus onto the lingual surface separating the mesiolingual from the distolingual cusps (Fig. 1-28).

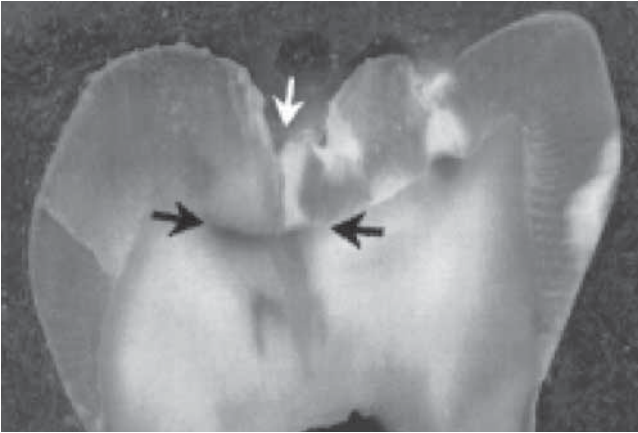
Additional grooves that are not developmental grooves are called **supplemental grooves**. These small irregular (extra) grooves on the occlusal surface do not occur at the junction of the lobes or major portions of the tooth (Fig. 1-27).

A **fissure** is a very narrow cleft or crevice at the depth of any groove, caused by the incomplete fusion of enamel during tooth development (the white arrow in Fig. 1-29). Tooth decay (also called dental **caries** [CARE eez]) often begins in the deepest part of a fissure (seen in dentin as the dark area between the two black arrows in Fig. 1-29) and described in more detail in the Operative Dentistry chapter.

A **fossa** [FAH sah] (plural, fossae [FAH see]) is a small hollow or depression found between the marginal ridges on the lingual surfaces of anterior teeth (particularly maxillary incisors, Fig. 1-30), and at specific locations on the occlusal surfaces of posterior teeth (denoted by the circles in Fig. 1-31). **Pits** often occur at the depth of a fossa where two or more grooves join. For example, within the distal fossa on a premolar, there is a distal pit at the junction of the central groove with the distobuccal and distolingual fossa grooves (Fig. 1-31). Like fissures that are found at the depth of grooves, pits are enamel defects where dental decay may begin. Most two-cusped premolars have two fossae (mesial and distal), whereas most molars and three-cusped premolars have at least three fossae (mesial, central, and distal) seen in Figure 1-32.

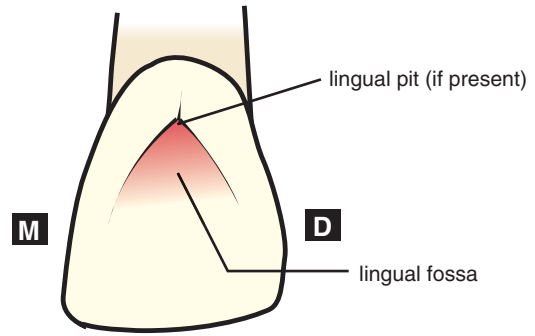


**FIGURE 1-28.** Grooves labeled on two molars. The **buccal, lingual, and central grooves** are considered **developmental**. The buccal (developmental) groove extends onto the buccal surface on the mandibular molar, and the lingual (developmental) groove extends onto the lingual surface of the maxillary molar.



**FIGURE 1-29.** A cross section of a mandibular molar shows an occlusal groove (*white arrow*), which actually has a **fissure** (crack-like fault) extending through the outer enamel and into the dentin. The *black arrows* show how the **dental decay** spreads out once it reaches softer dentin at the depth of the fissure.

Hint: In summary, if you compare tooth morphology to a mountain range, the mountain peak would be the cusp tip. Ridges emanating from the mountain peak are like the cusp ridges and triangular ridges. The depression between the mountains (or cusps) is a valley, like the tooth occlusal sulcus. The dried river bed at the bottom of the valley (sulcus) is like a groove, and if it is cracked open, it is like a fissure. Where river beds converge (grooves or fissures converge), the whirlpools and eddies may have formed a depression, like a fossa, possibly with a pit at its depth. Needless to say, it is hard to define exactly where a mountain stops and the valley starts, just as it would be hard to define exactly where a tooth cusp stops and a sulcus or fossa begins. Just realize that these terms are not precise, but that they are helpful when learning how to reproduce tooth form during construction of crowns and placement of fillings, or when learning to finish and polish an existing filling.

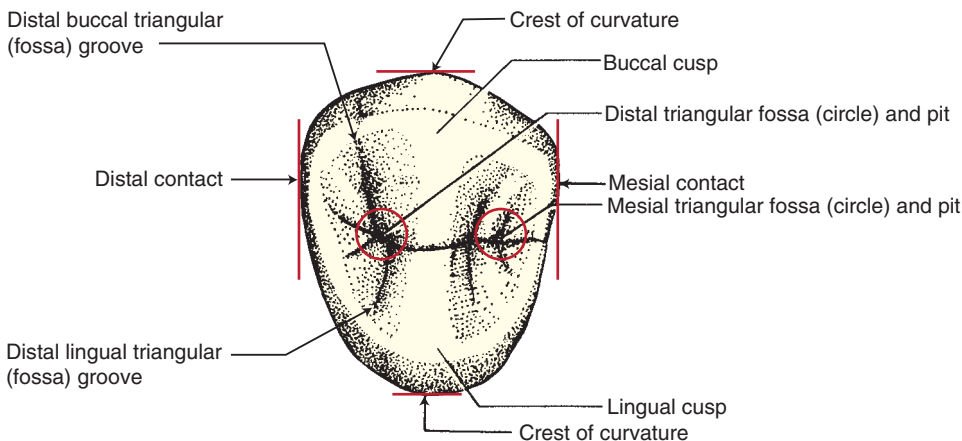


**FIGURE 1-30.** The lingual surface of an incisor shows the shallow **lingual fossa** and an adjacent **lingual pit**.

## B. EXTERNAL MORPHOLOGY OF THE ANATOMIC ROOT

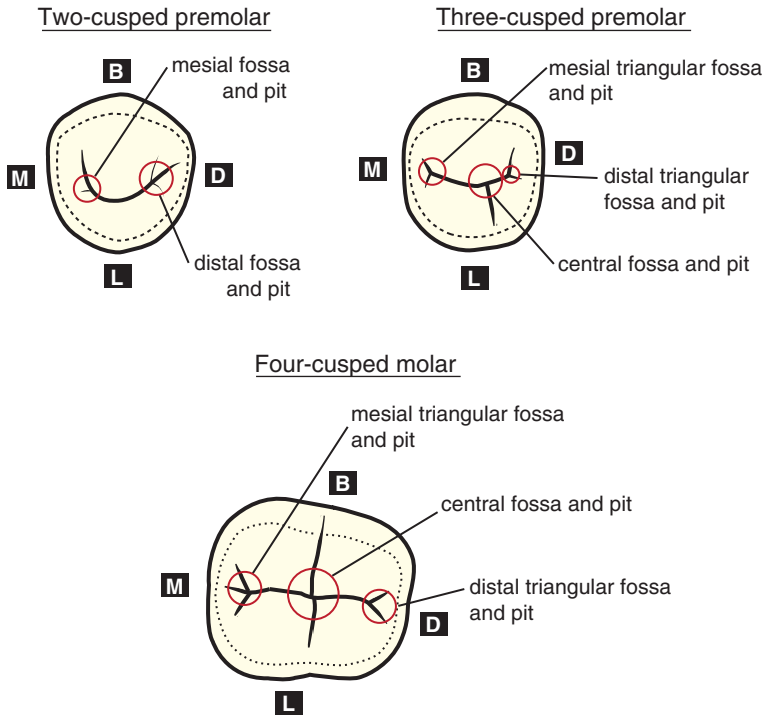
Refer to *Figure 1-33* while studying the external morphology of tooth roots. Recall that the anatomic root is the part of a tooth that is covered with cementum. The **apex** of the root is the tip or peak at the end of the root, often with visible openings called **apical foramina**, where the nerves and blood vessels enter into the tooth pulp. The **cervix** [SUR viks] or neck of the tooth is the slightly constricted region of union of the crown and the root.

Some new terms apply to multi-rooted teeth (*Fig. 1-33B*). The **root trunk** or trunk base is the part of the root of a multi-rooted molar or two-rooted premolar next to the cemento-enamel junction that has not yet split (like a stubby tree trunk before it gives off branches). The **furcation** [fur CAY shun] is the place on multi-rooted teeth where the root trunk divides into separate roots (called a **bifurcation** on two-rooted teeth and a **trifurcation** on three-rooted teeth). The **furcal region** or interradicular space is the region or space between two or more roots, apical to the place where the roots divide from the root trunk.

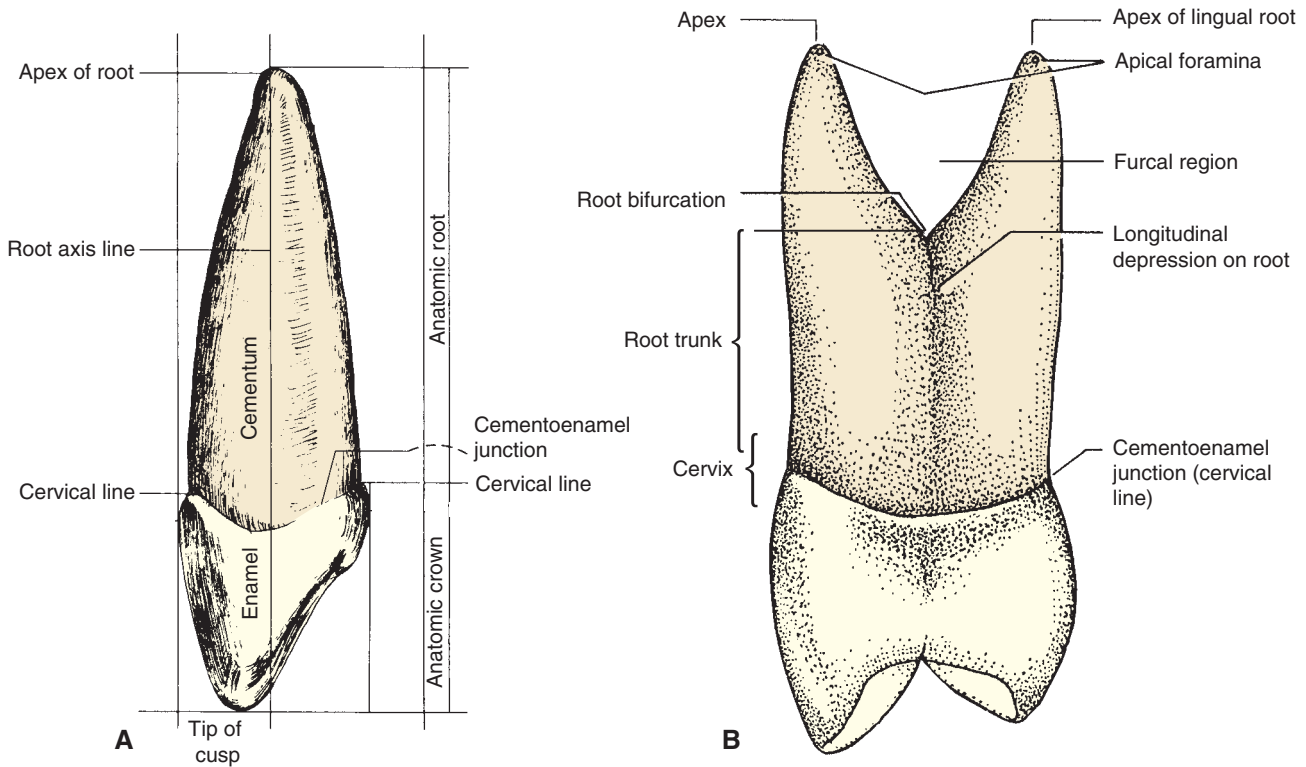


**FIGURE 1-31.** The **mesial and distal fossae** are circled in red on this two-cusped premolar.

### FOSSAE AND PITS



**FIGURE 1-32.** Fossae labeled on teeth with two, three, and four cusps. Two-cusped teeth have two fossae (mesial and distal), while three- or four-cusped teeth are more likely to have three fossae (mesial, central, and distal). (Maxillary molars have four fossae and will be discussed later.)



**FIGURE 1-33.** A. Root anatomy on a single-rooted canine. B. Bifurcated (split) root of a maxillary first premolar.

**Table 1-2 SUMMARY OF CURVATURES OF THE CEMENTOENAMEL JUNCTION****CERVICAL LINE  
(CEMENTOENAMEL  
JUNCTION) CURVATURES**

Proximal surfaces: mesial curvature vs. distal curvature

Proximal surfaces: anterior teeth vs. posterior teeth

Posterior teeth: facial vs. lingual surface

Generally, teeth have a greater proximal cervical line curvature on the mesial than the distal.

Proximal cervical line curvatures are greatest on the mesial surfaces of central incisors, and for most teeth tend to get smaller when moving from the anterior teeth toward the last molar where there may be no curvature at all.

On many posterior teeth, the cervical line is in a more occlusal position on the lingual than on the facial.

**Table 1-3 IMPORTANT TOOTH DIMENSIONS****IMPORTANT TOOTH DIMENSIONS TO MEMORIZE**

Tooth with longest crown

Longest tooth overall

Widest tooth mesiodistally

Widest tooth buccolingually

Narrowest tooth mesiodistally

Mandibular canine (Woelfel research: maxillary incisor)

Maxillary canine

Mandibular first molar

Maxillary first molar

Mandibular central incisor

**C. CERVICAL LINE (CEJ) CURVATURE**

When viewed from the mesial or distal aspect, the cervical line of a tooth curves (is convex) toward the incisal or occlusal surface (Fig. 1-33). In general, the amount of curvature is greater on the mesial surface than on the distal surface of the same tooth, and the amount of curvature is greatest for central incisors and diminishes in size for each tooth when moving distally around each quadrant (Table 1-2).

**D. RELATIVE SIZE**

In order to document the relative sizes of tooth crowns and roots, Dr. Woelfel studied a convenient sample of 4572 extracted teeth. His findings are presented in Tables 1-7 at the end of this chapter. This table should not be memorized, but it can be useful when comparing the average dimensions of each tooth, and appreciating the wide range of dimensions for each tooth. A summary of the most important highlights of that data is presented in Table 1-3.

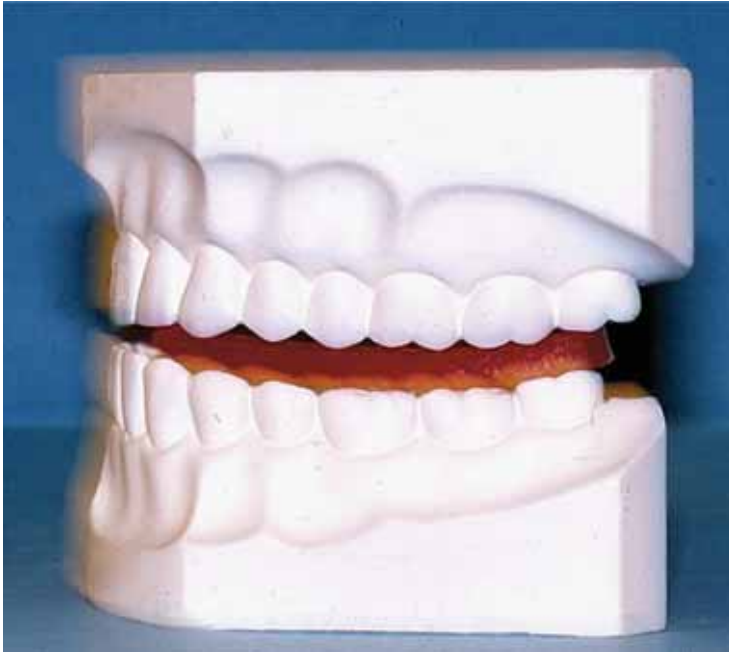**SECTION VII****TERMINOLOGY RELATED TO THE IDEAL TOOTH ALIGNMENT OF TEETH IN DENTAL ARCHES**

When viewed from the occlusal aspect, each dental arch is somewhat U-shaped or parabolic like the famous landmark in Missouri, the St. Louis Arch (recall Fig. 1-2). The incisal edges and the buccal cusp tips follow a curved line around the outer edge of the dental arch; the lingual cusp tips of the posterior teeth follow a curved line nearly parallel to the buccal cusp tips. Between the buccal and lingual cusps is the **sulcular groove**, which runs anteroposteriorly the length of the posterior teeth in each quadrant.


When the arches are viewed from the buccal aspect, an **anteroposterior curve** (curve of Spee) is evident where the cusp tips of posterior teeth follow a gradual curve anteroposteriorly (see Fig. 1-34). The curve that connects the cusp tips in the maxillary arch is convex, while the curve in the mandibular arch is concave.

Maxillary posterior teeth are tilted with the crowns more facial, and mandibular posterior teeth are tilted with the crowns more lingual (Fig. 1-35). Therefore, in the mouth, lingual cusps of maxillary posterior teeth





**FIGURE 1-34.** A wax strip placed between stone models of the maxillary and mandibular teeth demonstrates the **anteroposterior curve** (curve of Spee), which is concave in the mandibular arch and convex in the maxillary arch.



**FIGURE 1-35.** Dental stone casts viewed from the distal with a wax strip used to demonstrate the **mediolateral curve** (of Wilson). It is convex in the maxillary arch, but concave in the mandibular arch. Note the lines that denote posterior tooth alignment within each arch: *maxillary* molar crowns tilt toward the *facial*, and *mandibular* molar crowns tilt toward the *lingual*.

appear longer than the buccal cusps, and the lingual cusps of mandibular posterior teeth appear shorter than the buccal cusps due to their alignment (lingual tilt) within the mandible. When a line connects the buccal and lingual cusps of the same type of molars and premolars on opposite sides of the arch, this side-to-side curve is the **mediolateral curve** (of Wilson). The mediolateral curve of the maxillary arch is convex, whereas that of the mandibular arch is concave.

### A. MID-ROOT AXIS LINE

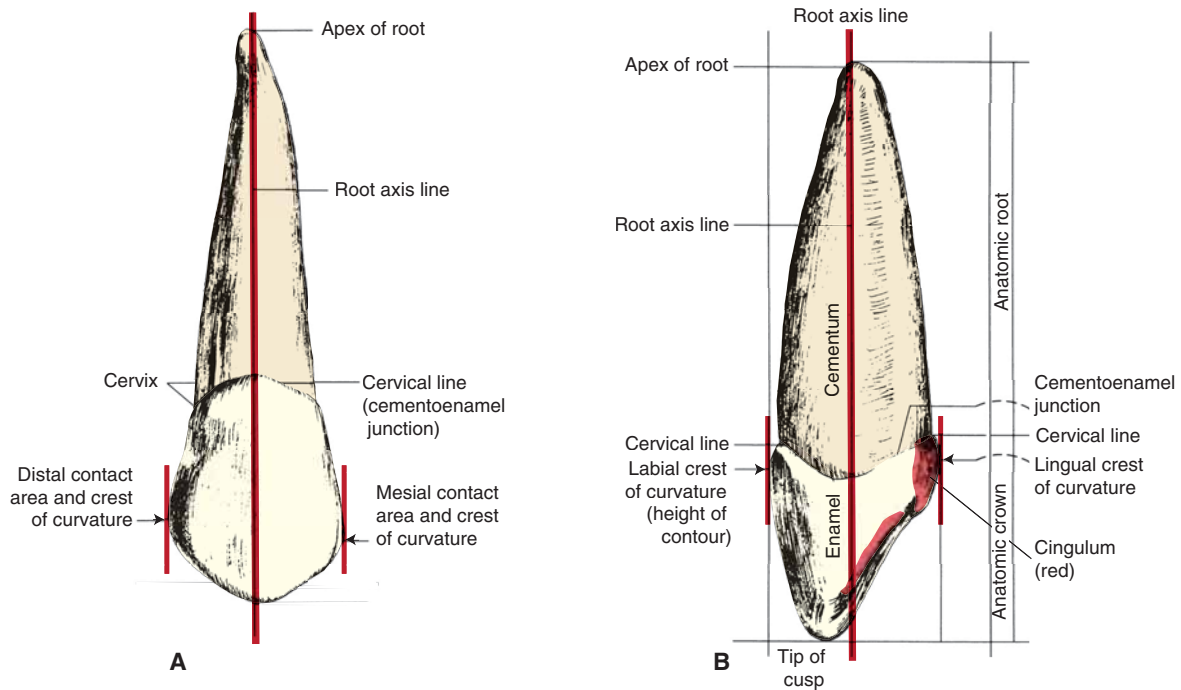
The **mid-root axis line** (or root axis line) is an imaginary line through the center of the tooth root. It can be visualized on the *facial* or *lingual* surface as a line that divides the tooth at the cervix into mesial and distal halves (Fig. 1-36A). When viewing the *mesial* or *distal* surface, it divides the tooth at the cervix into facial and lingual halves (Figs. 1-36B). It is an important reference line for describing the location of tooth landmarks. For

example, you will learn that the incisal edge of a mandibular canine is more likely to be lingual to the mid-root axis line, whereas the incisal ridge of a maxillary canine is more likely to be labial to the mid-root axis line (as seen in Fig. 1-36B).

### B. HEIGHT OF CONTOUR (CREST OF CURVATURE) ON A FACIAL OR LINGUAL SURFACE

The shape and extent of the greatest bulge on the facial and lingual crown surfaces help determine the direction that food particles are deflected in as they are pushed cervically over the tooth surfaces during mastication. When we chew food, these natural tooth convexities divert food away from the thin free gingiva and gingiva sulcus surrounding the cervix of the tooth, and toward the firmer tissues of the mouth, thus minimizing trauma to the gingiva. If teeth were flat facially and lingually, food could more likely damage the gingiva (Fig. 1-37). Needless to



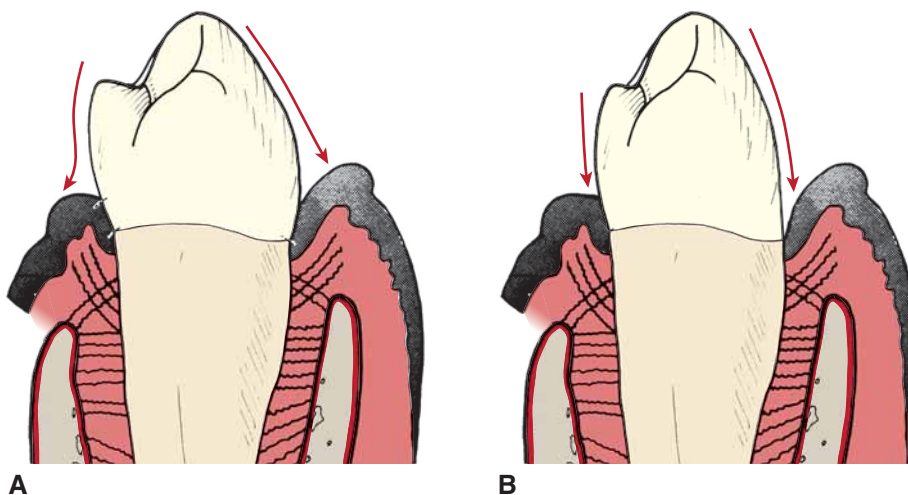


**FIGURE 1-36.** A. *Mesial and distal heights of contour* that touch lines parallel to the root axis line are essentially the same as the **contact areas** of these teeth. On the facial view of this canine, the contact areas are positioned more incisally on the mesial surface than on the distal. B. The *facial and lingual heights of contour* are the part of the crown outline from the proximal view that touch lines that are parallel to the root axis line. They are located in the *cervical third* on both the facial surface, and on the lingual surfaces (on the cingulum), for *all anterior teeth*.

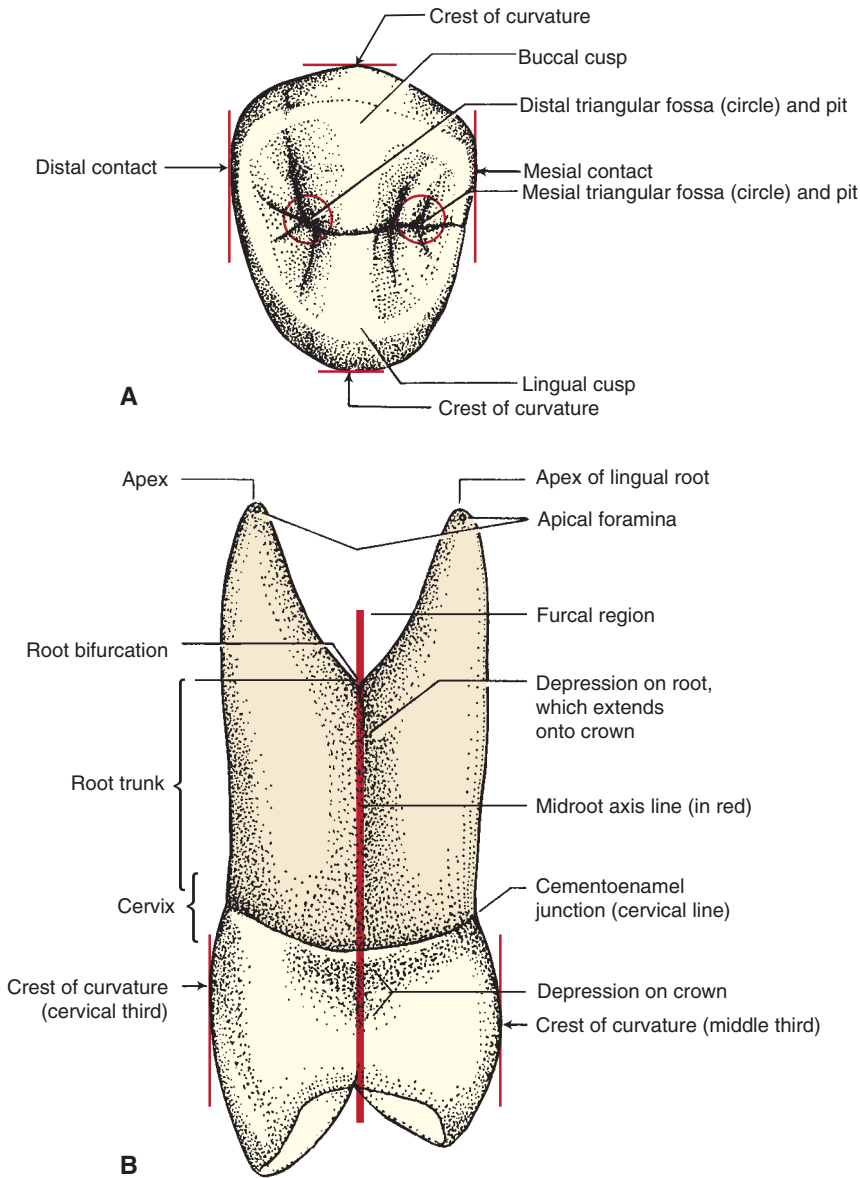
say, it is best for the dentist, dental hygienist, and/or dental technician to reproduce and maintain these natural convexities when restoring a tooth, when finishing and polishing fillings near the gum line, or when replacing a tooth with a bridge or dental implant.

The *facial or lingual height of contour (crest of curvature)* is the point on a crown outline where a line drawn parallel to the mid-root axis line touches the

greatest bulge (Fig. 1-36B). It is usually located in either the cervical third or the middle third (not normally in the occlusal or incisal third). The location of the height of contour on the *facial* surface of most crowns is located in the *cervical third*. The location of the *lingual* height of contour depends on whether the tooth is anterior or posterior. The *lingual* height of contour on *anterior* teeth is in the *cervical third*, on the cingulum



**FIGURE 1-37.** A. Normal *facial and lingual* heights of contour help divert food away from the gingival sulcus. B. When heights of contour are not adequate, food can more readily damage the gingival sulcus.



**FIGURE 1-38.** **A.** The mesial and distal **contact areas** seen on the occlusal view of this two-cusped premolar are located buccal to the center of the tooth buccolingually, which is typical of most posterior teeth. **B.** On the proximal view of this premolar, the **buccal height of contour** (crest of curvature) is located in the cervical third, while the **lingual height of contour** is located more occlusally, in the middle third. This is typical of most *posterior* teeth.

Table 1-4	SUMMARY OF THE LOCATION OF FACIAL AND LINGUAL HEIGHTS OF CONTOUR (GREATEST BULGE) OF THE CROWN (BEST SEEN FROM THE PROXIMAL VIEW)	
	FACIAL (HEIGHT OF CONTOUR)	LINGUAL (HEIGHT OF CONTOUR)
Anterior teeth (incisors and canines)	Cervical third	Cervical third (on cingulum)
Posterior teeth (premolars and molars)	Cervical third	In or near middle third

General learning guidelines:

1. **Facial** crest of curvature for all teeth is in **cervical** third.
2. **Lingual** crest of curvature for all **anterior** teeth is in the **cervical** third (on the cingulum).
3. **Lingual** crest of curvature for **posterior** teeth is in the **middle** third (slightly more occlusal in mandibular teeth due to lingual tilt).

(Fig. 1-36B). The *lingual* height of contour on *posterior* teeth is most often located in the *middle* third (Fig. 1-38B). Refer to *Table 1-4* for a summary of the location of the facial and lingual heights of contour for anterior teeth compared to posterior teeth.

### C. CONTACT AREAS (OR PROXIMAL HEIGHTS OF CONTOUR)

When the teeth are in normal, ideal alignment within an arch, the location of the mesial or distal height of contour (when viewed directly from the facial or lingual sides) is essentially the same location as contact areas (seen from the facial view in Fig. 1-36A and from the occlusal view in Fig. 1-38A). **Contact areas** are the greatest heights of contour or location of the greatest bulges on the proximal surfaces of tooth crowns, where one tooth touches an adjacent tooth. Floss must pass through contact areas to clean the proximal surfaces, which are otherwise inaccessible to the toothbrush.

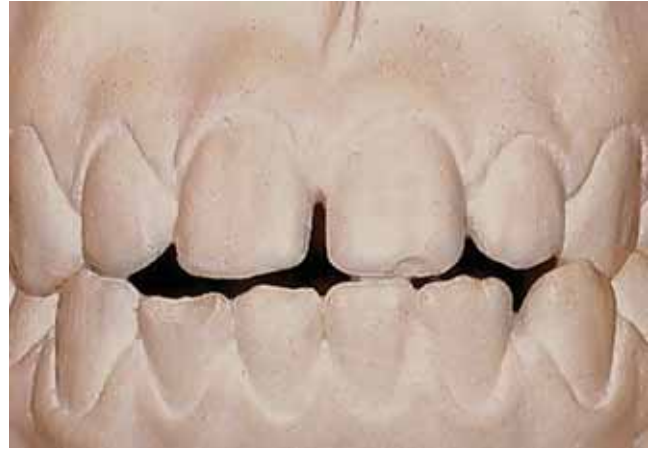In a young person, contact areas on teeth start off between recently erupted teeth as *contact points*. Then, as the teeth rub together in function, these points become somewhat flattened and truly become *contact areas*. (It has been shown by careful measurements that, by age 40 in a healthy mouth with a complete dentition, 10 mm of enamel has been worn off the contact areas of the teeth in an entire arch. This averages 0.38 mm per contact area on each tooth and certainly emphasizes the amount of proximal wear that occurs. Therefore, we would expect contact areas on teeth of older people to be large and somewhat flattened.)

The proximal contact of each tooth with the adjacent teeth has important functions:

- The positive contact of all teeth within each dental arch stabilizes the position of teeth within each arch.
- Contact helps prevent food impaction which can contribute to decay and gum and bone disease (periodontal disease).
- Contact protects the interdental papillae of the gingiva by diverting food buccally and lingually.

A **diastema** [di ah STEE mah] is a space that exists between two adjacent teeth in the same arch that is not the result of a missing tooth. It is most commonly seen between the maxillary right and left central incisors, but can occur between any teeth (Fig. 1-39).

Before learning the location of the **proximal contacts** for each type of tooth, it will be helpful to learn the following general guidelines that apply to most permanent teeth. Exceptions to these general rules will be presented in later chapters.



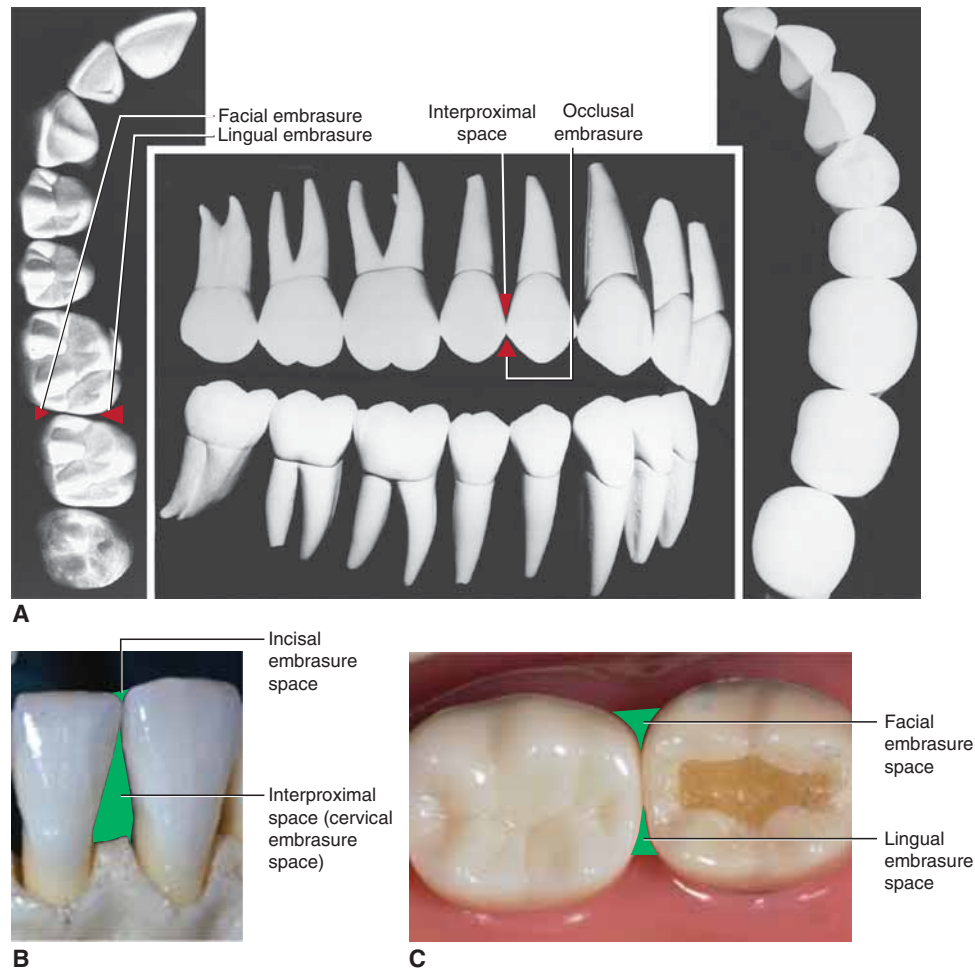
**FIGURE 1-39.** This maxillary stone model has a space between maxillary central incisors called a **diastema**.

- When viewing teeth from the facial, contact areas are located in one of three places: in the incisal (or occlusal) third, at the junction of the incisal (or occlusal) and middle thirds, or in the middle third of the crown. Contact areas are not normally located in the cervical third.
- On most teeth, the distal contact is more cervical than its mesial contact (Fig. 1-36A).
- Mesial contact areas of the central incisors are positioned most incisally, and contacts are located more cervically (in or near the middle third) on molars.
- When viewing posterior teeth from the occlusal view, contacts are often located slightly to the facial of the tooth midline buccolingually (Fig. 1-38A).
- When viewing anterior teeth from the incisal view, contacts are nearly centered faciolingually.

### D. EMBRASURE SPACES

When adjacent teeth contact, the continuous space that surrounds each contact area can be divided into four separate triangular **embrasure spaces** (Fig. 1-40). These spaces are narrowest closest to the contact area where the teeth are in tight contact, and widen facially to form a buccal or labial embrasure, widen lingually to form a lingual embrasure, and widen occlusally (or incisally) to form an occlusal or incisal embrasure. The fourth space, cervical to the contact area and between two adjacent teeth, is properly called the **interproximal space**.

The interproximal space, when viewed from the facial or lingual, is a triangular embrasure space between adjacent teeth located cervical to their contact areas. The sides of the triangle are formed by the proximal surfaces of adjacent teeth, with the apex of the triangle at the contact between two teeth. This space is



**FIGURE 1-40.** Embrasure spaces. **A.** These photographs are of large plastic tooth models and give an indication of the location of **contact points** between adjacent teeth. The quadrant of teeth on the left contains the occlusal and incisal surfaces of the permanent *maxillary* dentition; on the right is the *mandibular* dentition. Red triangles can be seen from the occlusal view filling a smaller *facial* and larger *lingual embrasure space*, and from the facial view, filling an occlusal (incisal) embrasure space and an **interproximal space** (sometimes called a gingival embrasure space). **B.** This close-up of mandibular incisors in a skull (without tissue) shows the **interproximal space** below the proximal contact (**gingival embrasure space**). In a person with gingival health, this space would be filled with the gingival papilla. The very small triangular space above the proximal contact is the **incisal embrasure space**. **C.** This occlusal view of two contacting molars shows a triangular-shaped space buccal to the proximal contact called the **buccal embrasure space**, and another (normally larger) space lingual to the contact called the **lingual embrasure space**.

completely filled with the **interdental papilla** in periodontally healthy persons (see Fig. 1-42). Sometimes this interproximal space is referred to as the cervical or gingival embrasure.

The lingual embrasure is ordinarily larger than the facial embrasure because most teeth are narrower on the lingual side than on the facial side, and because their contact points are located facial to the faciolingual midline of the crown. The triangles in Figure 1-40 illustrate these embrasure spaces.

The occlusal or incisal embrasure is usually shallow from the occlusal surface or incisal edge to the contact areas and is narrow faciolingually on anterior teeth but broad on posterior teeth. The occlusal embrasure is the

area between the marginal ridges on two adjacent teeth and occlusal to their contact area. This is where we place the dental floss before passing it through the contact area to clean tooth surfaces in the interproximal space.

Embrasures surrounding well-formed proximal contact areas serve as spillways to direct food away from the gingiva. When the embrasures are incorrectly shaped (as with a poorly contoured dental restoration), or when there is a space between the teeth, fibrous food may readily lodge in the interproximal spaces requiring dental floss for its removal. This food impaction is not only an annoyance, but it can contribute to the formation of dental decay and periodontal disease (bone loss).

## SECTION VIII

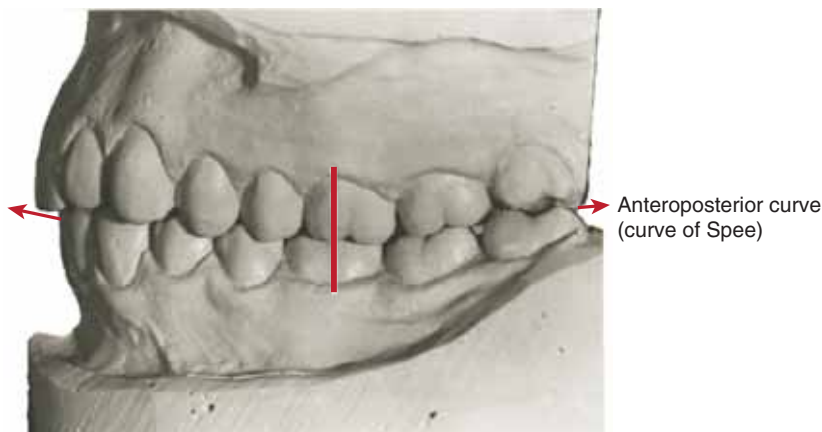
IDEAL OCCLUSION: INTER (BETWEEN) ARCH  
RELATIONSHIP OF TEETH

It is important to learn the relationships of teeth in ideal occlusion in order to identify malocclusions that could contribute to dental problems. **Occlusion** [ah KLOO zhun] is the contacting of occlusal or incisal surfaces of opposing maxillary and mandibular teeth. To occlude literally means to close, as in closing your teeth together. The importance of proper occlusion cannot be overestimated. It is essential for both dental health and general health, and for a patient's comfort and ability to speak, chew, and enjoy food. Understanding occlusion requires not only a knowledge of the relation of the mandible to the maxillae, but also of the jaw joints, their complexities, and the muscles, nerves, ligaments, and soft tissues that affect the position of the mandible. These topics will be covered in much more depth later in this book. The arrangement of teeth within the dental arches (alignment, proximal contacts, and embrasure spaces) was discussed in the previous section of this chapter, and the ideal relationship of the mandibular dental arch of teeth to the maxillary dental arch of teeth will be presented in this section.

**Ideal tooth relationships** were described and classified in the early 1900s by Edward H. Angle. He classified ideal occlusion as **class I** and defined it based on the relationship between the maxillary and mandibular dental arches. When closed together, the teeth are in their **maximum intercuspal position**, or best fitting together of the teeth, as shown in *Figure 1-41*. This relationship can be achieved on handheld models when the maxillary teeth fit as tightly as possible against the mandibular teeth (that is, are most stable).

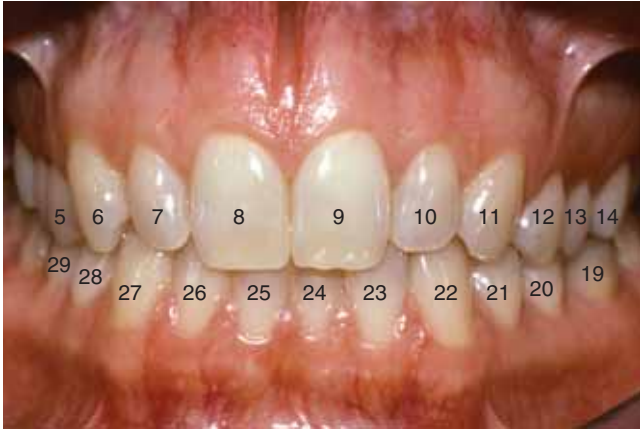The following specific tooth relationships define class I ideal occlusion:

- **Horizontal overlap of anterior teeth:** The incisal edges of maxillary anterior teeth overlap the mandibular teeth such that the incisal edges of maxillary teeth are labial to the incisal edges of mandibular teeth (best seen in *Fig. 1-41*).
- **Vertical overlap of anterior teeth:** The incisal edges of the maxillary anterior teeth extend below (overlap vertically) the incisal edges of the mandibular teeth so that, when viewed from the facial, the incisal edges of mandibular incisors are hidden from view by the overlapping maxillary incisors (*Fig. 1-42*).
- **Relationship of posterior teeth:** The maxillary posterior teeth are positioned slightly buccal to the mandibular posterior teeth (*Fig. 1-43*) so that:
  - The buccal cusp tips and buccal surfaces of the maxillary teeth are buccal to those in the mandibular arch.
  - The lingual cusps of maxillary teeth rest in occlusal fossae of the mandibular teeth.
  - The buccal cusps of the mandibular teeth rest in the occlusal fossae of the maxillary teeth.
  - The lingual cusp tips and lingual surfaces of the mandibular teeth are lingual to those in the maxillary arch.
- **Relative alignment:** The vertical (long) axis midline of each maxillary tooth is slightly distal to the vertical axis of its corresponding mandibular tooth type so that:
  - The tip of the mesiobuccal cusp of the maxillary first molar is aligned directly over the mesiobuccal

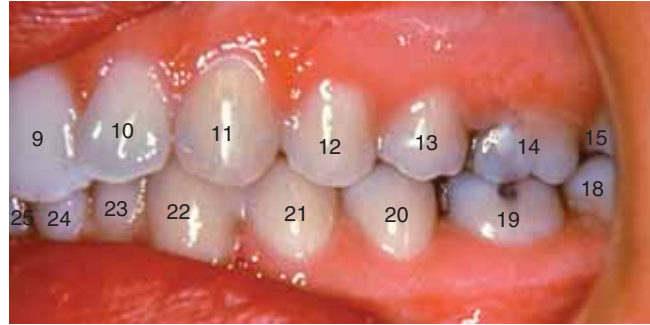

**FIGURE 1-41.** Dental stone casts with adult teeth fitting together in the **maximum intercuspal position** (tightest fit). Notice that, from this view, each tooth has the potential for contacting two opposing teeth except the maxillary third molar. The vertical red line marks the relationship of first molars in **class I occlusion**: the mesiobuccal cusp of the maxillary first molar occludes in the mesiobuccal groove of the mandibular first molar.

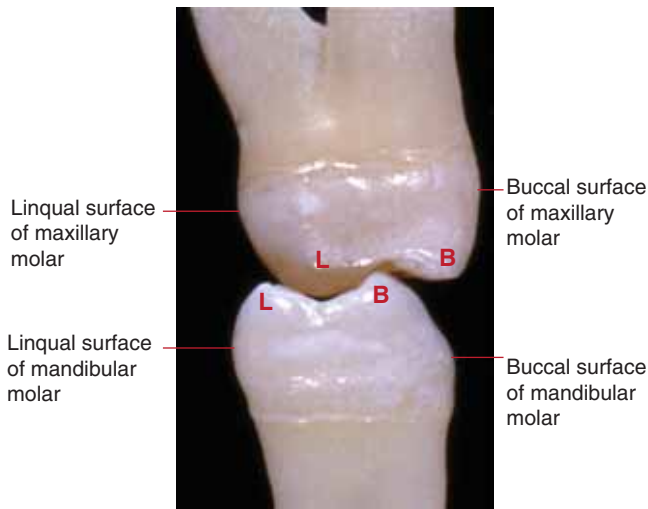




**FIGURE 1-42.** Maxillary and mandibular teeth of the permanent dentition are in the maximum intercuspal position. Observe the **interproximal spaces** filled with the **interdental papillae** between each pair of teeth. Notice how each tooth is in contact with its adjacent teeth. Note how the incisal edges and cuspal tips of maxillary teeth overlap and hide the incisal edges and cuspal tips of the mandibular teeth, and how the wide maxillary central incisors overlap not only the mandibular central incisor, but also half of the mandibular lateral incisor.



**FIGURE 1-44.** The left cheek has been drawn back to reveal how each of these maxillary teeth occlude with two opposing mandibular teeth. Tooth No. 19 has two buccal grooves: mesiobuccal (with the buccal filling) and distobuccal (not visible).



**FIGURE 1-43.** This proximal view of a maxillary and mandibular molar in normal interarch alignment reveals the alignment and position of buccal and lingual cusps in **ideal occlusion**.

groove (the mesial of two buccal grooves) on the mandibular first molar (Fig. 1-44). This relationship of first molars (the first permanent teeth to erupt) is a **key factor in the definition of class I occlusion**. Further, the maxillary canine fits into the facial embrasure between the mandibular canine and first premolar.

- Most teeth in an ideal dental arch have the potential for occluding with two teeth in the opposing arch. For example, the distal surface of the maxillary first molar in Figure 1-41 is posterior to the distal surface of the mandibular first molar and therefore occludes with both the mandibular first and second molar. Exceptions include the mandibular central incisor which, due to its size and location, only occludes with the maxillary central incisor (as seen in Fig. 1-42) and the maxillary third molar which only occludes with the mandibular third molar.

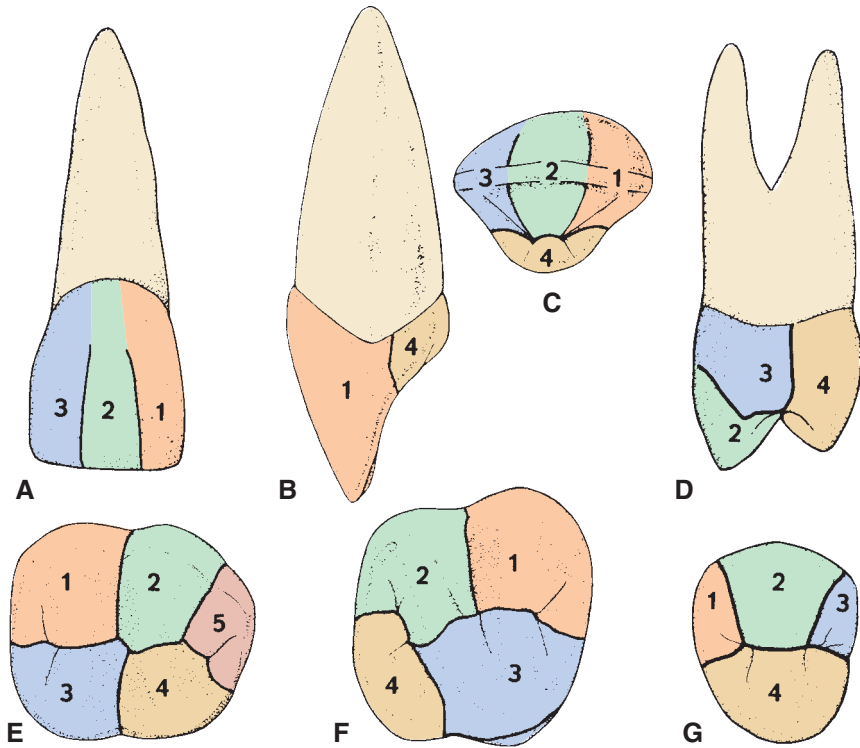
To summarize, ideal occlusion involves a class I relationship between the maxillary and mandibular first molars in maximum intercuspal position. Also, there should be no large facets and/or bruxing habits, bone loss, crooked teeth, loose teeth, or joint pain.<sup>1</sup> Other classes of occlusion (malocclusion) will be discussed in detail in Chapter 9.

## SECTION IX TOOTH DEVELOPMENT FROM LOBES

Tooth crowns develop from lobes or primary growth centers (Fig. 1-45). All normal teeth show evidence of having developed from three or more lobes. As a general rule, the facial portion of incisors, canines and premolars forms from three lobes, and the cingulum area or lingual cusp(s) each form from one lobe. Therefore, **incisors** develop from four lobes: three facial lobes

(forming three incisally located mamelons) and one lingual lobe forming the cingulum area. **Canines, and premolars** with one buccal and one lingual cusp, also develop from four lobes: three facial lobes forming the facial portion, and one lingual lobe forming the cingulum area on the canine or the one lingual cusp on the premolar. Premolars with one buccal and two lingual





**FIGURE 1-45.** Lobes or primary anatomic divisions on teeth. Drawings A, B, and C show the facial, mesial, and incisal views of a maxillary central incisor that, like all anterior teeth, forms from four lobes. The lingual cingulum develops from one lobe (labeled 4) seen in views B and C. Mamelons may appear on the incisal edge of newly erupted incisors, an indication of the three labial lobes. Drawings D and G are the mesial and occlusal view of a two-cusped premolar that also forms from four lobes. As with anterior teeth, the facial cusp forms from three lobes, and one lingual lobe forms the lingual cusp. The divisions between the facial and lingual lobes are evidenced by the marginal ridge developmental grooves. **Each cusp of a molar is formed by one lobe.** Drawing E is a mandibular first molar with five lobes, three buccal, and two lingual, which is one lobe per cusp. Drawing F is a maxillary first molar with three larger lobes and one smaller lobe, or one per cusp. A very small fifth (Carabelli) cusp, when present, may form from a part of the large mesiolingual lobe, or may form from a separate lobe.

cusps (mandibular seconds), form from five lobes: three forming the facial cusp, and two forming the two lingual cusps (one lobe per cusp). Three very subtle vertical ridges separated by two subtle depressions provide evidence that three lobes form the facial surfaces of anterior teeth and premolars.

As a general rule, each molar cusp forms from one lobe. For example, maxillary or mandibular molars

with five cusps form from five lobes, and those with four cusps form from four lobes. Some maxillary molars have as few as three cusps and form from three lobes. Two types of tooth anomalies, peg-shaped maxillary lateral incisors and some extra teeth (also called supernumerary teeth), form from less than three lobes. Guidelines for determining the number of lobes that form each tooth are presented in Table 1-5.

**Table 1-5 GUIDELINES FOR DETERMINING THE NUMBER OF LOBES FORMING ADULT TOOTH**

ANTERIOR TEETH AND PREMOLARS	TOOTH CLASS	NO. LINGUAL CUSPS OR CINGULUM	NO. OF LOBES
	All incisors	Cingulum	3 + 1 = 4
	All canines	Cingulum	3 + 1 = 4
	Two-cusped premolars	1 lingual	3 + 1 = 4
Three-cusped premolars	2 lingual	3 + 2 = 5	
Guideline for determining the number of lobes for anterior teeth and premolars: Number of lobes = 3 facial lobes + 1 lobe per lingual cusp or cingulum.			
MOLARS	MOLAR NAME	NO. TOTAL CUSPS	NO. OF LOBES
	Three-cusped molars	3	3
	Four-cusped molars	4	4
	Five-cusped molars (including large Carabelli cusps)	5	5
Guideline for determining the number of molar lobes: Number of molar lobes = 1 per cusp (including Carabelli).			

## SECTION X

INTERESTING VARIATIONS IN ANIMAL TEETH  
COMPARED TO HUMAN TEETH

It is interesting to note that the dentition of animals can be represented by the same type of formula as described earlier in this chapter. Look at the formulas for animals in *Table 1-6* and note that cows have no upper incisors or upper canines. They have three upper and three lower premolars on each side. Did you know that dogs have twice as many premolars as humans if you include uppers and lowers, as well as the right and left sides? Did you know that the tusks on an elephant are maxillary central incisors? Elephants have the largest diastema in the world, large enough for the massive trunk between their central incisors.

## LEARNING EXERCISE 1

Sketch a tooth and adjacent gingiva in cross section (similar to Fig. 1-9) and label the following structures: enamel, dentin, cementum, pulp cavity, pulp chamber, apical foramen location, dentinoenamel junction, cementsenamel junction, dentinocemental junction, periodontal ligament space, alveolar bone, gingiva, gingival sulcus, anatomic crown, and anatomic root.

Table 1-6

SOME DENTAL FORMULAE (ORDER OF TEETH PER QUADRANT) AND INTERESTING FACTS ABOUT TEETH IN ANIMALS<sup>2-4</sup>

Humans, Old World monkeys, and apes	$I_{2}^{2}C_{1}^{1}P_{2}^{2}$	$M_{3}^{3}$	Porcupines and beavers	$I_{1}^{1}C_{0}^{0}P_{1}^{1}$	$M_{3}^{3}$
New World monkeys	$I_{2}^{2}C_{1}^{1}P_{3}^{3}$	$M_{3}^{3}$	Bears and pandas	$I_{3}^{3}C_{1}^{1}P_{4}^{4}$	$M_{3}^{3}$
Dogs, wolves, and foxes	$I_{3}^{3}C_{1}^{1}P_{4}^{4}$	$M_{2}^{2}$	Squirrels	$I_{1}^{1}C_{0}^{0}P_{2}^{2}$	$M_{3}^{3}$
Cats	$I_{3}^{3}C_{1}^{1}P_{3}^{3}$	$M_{1}^{1}$	Rabbit <sup>†</sup>	$I_{2}^{2}C_{0}^{0}P_{3}^{3}$	$M_{3}^{3}$
Cows	$I_{0}^{0}C_{1}^{1}P_{3}^{3}$	$M_{3}^{3}$	Mice and rats	$I_{1}^{1}C_{0}^{0}P_{0}^{0}$	$M_{3}^{3}$
Horses and zebra*	$I_{3}^{3}C_{1}^{1}P_{4}^{4}$	$M_{3}^{3}$	Moles	$I_{3}^{3}C_{1}^{1}P_{4}^{4}$	$M_{3}^{3}$
Walrus	$I_{0}^{0}C_{1}^{1}P_{3}^{3}$	$M_{0}^{0}$	Vampire bats	$I_{2}^{2}C_{1}^{1}P_{3}^{3}$	$M_{0}^{0}$
Elephants <sup>†</sup>	$I_{1}^{1}C_{0}^{0}Dm_{3}^{3}$	$M_{3}^{3}$	Shrews	$I_{3}^{3}C_{1}^{1}P_{3}^{3}$	$M_{3}^{3}$

\*Pigs and hippopotami have the same formula, except that they have two or three upper and two or three lower incisors.

<sup>†</sup>Elephants have deciduous molars (Dm) but no premolars. An elephant's skull is not larger than necessary to house its brain. The size is needed to provide mechanical support for the tusks (one third of their length is embedded in the skull) and the enormous molars. Each molar weighs about 9 pounds and is nearly a foot long mesiodistally on the occlusal surface. Tusks (the central incisors) can be as long as 11½ feet and weigh 440 pounds.<sup>5</sup>

<sup>‡</sup>Guinea pigs have the same formula, except that they have only one maxillary incisor.

The beaver has four strong curved incisors. They have very hard, bright orange enamel on the labial surface and much softer exposed dentin on the lingual surface. As the dentin wears off, this leaves very sharp cutting edges of enamel. The incisors continue to grow throughout life. The posterior teeth have flat, rough edges on the occlusal surface, and they stop growing at 2 years of age. There is a large diastema immediately posterior to the incisors, and flaps of skin fold inward and meet behind the incisors to seal off the back part of the mouth during gnawing.

Therefore, splinters are kept out. The flaps of skin relax for eating and drinking.

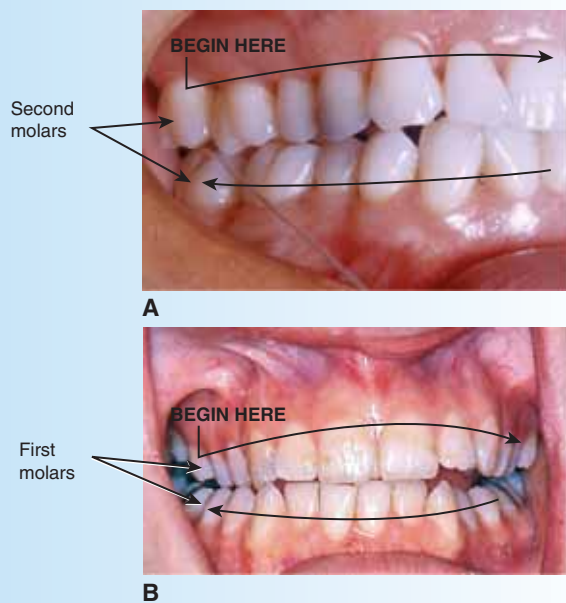
The shrew has two hooked cusps on the upper first incisor. Its primary dentition is shed in utero. The shrew's 1- to 1½-year life span is limited by the wear on their molars. Death occurs by starvation once the molars wear out. Also, their small body can store only enough food for 1 to 2 h, so they must feed almost continually. Their diet consists of small invertebrates, woodlice, and fruit.

The vampire bat has large canines, but its highly specialized upper incisors, which are V-shaped and razor-edged, are what remove a piece of the victim's skin. The bat's saliva contains an anticoagulant, and its tongue rolls up in a tube to suck or lap the exuding blood.

Some vertebrates do not have any teeth (complete anodontia) but have descended from ancestors that possessed teeth. Birds have beaks but depend on a gizzard to do the grinding that molars would usually perform. Turtles have heavy jaw coverings, which are thin edged in the incisor region and wide posteriorly for crushing. The duck-billed platypus has its early-life teeth replaced by keratinous plates, which it uses to crush aquatic insects, crustaceans, and molluscs. The whale-bone whale and anteaters also have no teeth, but their diets do not require chewing.

## LEARNING EXERCISE 2

Identify the teeth visible in *Figure 1-46A* using the Universal Numbering System. Remember that as you are viewing this mouth, the left side of the photograph is the right side of the mouth. Begin with the second molar in the maxillary arch and continue to the central incisor. Then drop to the mandibular central incisor and continue numbering back to the mandibular second molar. Compare your responses to the answers that follow. Then identify the same teeth using the International System, and finally the Palmer System.



**FIGURE 1-46.** Identify all visible teeth using the Universal number as per the directions for this Learning Exercise. Then identify the same teeth using the International System, then the Palmer System. **A.** Teeth visible on a person's right side when the cheek and lips are retracted. **B.** Most teeth visible in a person with cheeks and lips retracted.

Then do the same thing for the teeth visible in *Figure 1-46B*, beginning with the maxillary first molar on the left side of the photograph, continue numbering through the maxillary first molar on the right side. Then drop down to the mandibular first molar and continue numbering through the first molar on the other side.

**Answers for teeth in Figure 1-46A. Universal tooth numbers for teeth in order:** 2,3,4,5,6,7,8; 25 for central incisor, 26,27,28,29,30,31. The correct numbers using the International System are 17,16,15,14,13,12,11; 41 for central incisor, 42,43,44,45,46,47. Then use Table 1-1 to

## Learning Exercise 2, cont.

confirm the correct method for identifying each of these teeth using the Palmer system.

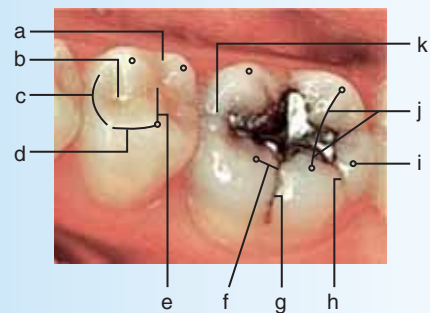
### Answers for teeth in Figure 1-46B.

#### Universal tooth numbers for teeth in order:

3,4,5,6,7,8,9,10,11,12,13,14; then 19 for mandibular first molar, 20,21,22,23,24,25,26,27,28,29,30. The correct numbers using the International System are: 16,15,14,13,12,11,21,22,23,24,25,26; then 36 for mandibular left first molar, 35,34,33,32,31,41,42,43,44,45,46. Then use Table 1-1 to confirm the correct method for identifying each of these teeth using the Palmer system.

## LEARNING EXERCISE 3

One tooth in *Figure 1-47* is a mandibular left second premolar with three cusps (cusp tips are indicated by the three small circles), and the other tooth is a mandibular left first molar with five cusps (cusp tips indicated by five small circles). Based on this information, you should be able to identify each of the structures (except maybe i) indicated in *Figure 1-47*. Confirm your answers below.



**FIGURE 1-47.** As per the directions for this Learning Exercise, name each structure on this mandibular left second premolar with three cusps (cusp tips denoted by three small circles) and this mandibular left first molar with five cusps (cusp tips denoted by five small circles).

**Answers for structures in Figure 1-47:** (a) lingual groove; (b) mesial pit; (c) mesial marginal ridge; (d) mesial cusp ridge of the buccal cusp; (e) triangular ridge of the buccal cusp; (f) distal cusp ridge of the mesiobuccal cusp; (g) mesiobuccal groove; (h) distobuccal groove; (i) distal cusp tip; (j) transverse ridge made up of the triangular ridges of the distobuccal cusp and the distolingual cusp; (k) mesial marginal ridge groove.

## Review Questions

These questions were designed to help you confirm that you understand the terms and concepts presented in this chapter. Answer each question by circling the letter (or letters) of the correct answer (or answers). More than one answer may be correct.

- If you read an article in a British dental journal that refers to tooth No. 48, you would suspect that the authors were using the International Numbering System. What universal number (or letter) would they be talking about?
  - 25
  - J
  - 30
  - T
  - 32
- Using the Universal Numbering System, what numbers are used to identify maxillary canines?
  - 6
  - 8
  - 10
  - 11
  - 27
- Which tooth junctions are NOT normally visible on a handheld intact tooth?
  - Cementoenamel junction
  - Dentinoenamel junction
  - Dentinocemental junction
  - Dentinopulpal junction
- Which statement(s) is (are) likely to be true on a person with a barely erupted tooth No. 9?
  - The clinical crown is larger than the anatomic crown
  - The clinical crown is smaller than the anatomic crown
  - The clinical root is larger than the anatomic root
  - The clinical root is smaller than the anatomic root
- Which tooth surface(s) face(s) the lips or cheeks?
  - Facial
  - Distal
  - Buccal
  - Occlusal
  - Labial
- Which pairs of teeth have a mesial surface touching a mesial surface?
  - 25 and 26
  - 16 and 17
  - 7 and 8
  - 1 and 32
  - 8 and 9
- When viewing tooth No. 8 from the distal view, it can be divided into thirds from the incisal to the cervical and from the facial to the lingual. Which third is NOT possible to see from the distal view?
  - Facial
  - Cervical
  - Middle
  - Mesial
  - Incisal
- If you were observing the faciolingual dimension of a tooth, what surface(s) could you be viewing?
  - Mesial
  - Occlusal
  - Proximal
  - Labial
  - Distal
- If the root-to-crown ratio of a maxillary molar (No. 14) is 1.72 and that of another molar, No. 16, is 1.49, which tooth has the longest root relative to its shorter crown?
  - No. 14
  - No. 16
  - More information is required in order to answer this question
- Which of the following bumps or ridges is NOT likely to be found on a maxillary premolar?
  - Oblique ridge
  - Cingulum
  - Mesial marginal ridge
  - Transverse ridge
  - Triangular ridge
- Which ridges surround the perimeter of the occlusal surface (occlusal table) of a two-cusped premolar?
  - Mesial marginal ridge
  - Distal marginal ridge
  - Mesial cusp ridge of the buccal cusp
  - Distal cusp ridge of the lingual cusp
  - Transverse ridge
- What is the correct order of anatomic landmarks of a tooth with two roots from the cementoenamel junction to the root tip?
  - Cervix, trunk, furcation, apex
  - Trunk, cervix, furcation, apex
  - Trunk, furcation, cervix, apex
  - Cervix, trunk, apex, furcation
  - Furcation, trunk, cervix, apex

13. When viewed from the proximal views, what is the location of the greatest bulge (crest of curvature or height of contour) on the facial surface of all teeth?
- Occlusal third
  - Lingual third
  - Buccal third
  - Middle third
  - Cervical third
14. Which space(s) contain(s) the part of the gingiva known as the interdental papilla?
- The buccal embrasure
  - Occlusal embrasure
  - Lingual embrasure
  - Cervical embrasure
  - Interproximal space
15. Ideal class I occlusion involves an important first permanent molar relationship where the mesiobuccal cusp of the maxillary first molar is located within the
- Mesiobuccal groove of the mandibular first molar
  - Distobuccal groove of the mandibular first molar
  - Buccal groove of the mandibular second molar
  - Mesiobuccal groove of the mandibular second molar
  - Distobuccal groove of the mandibular second molar
16. Where do lingual cusps of maxillary teeth occlude in ideal class I occlusion?
- In the buccal embrasure space between mandibular teeth
  - In the lingual embrasure space between mandibular teeth
  - In occlusal fossae of mandibular teeth
17. How many developmental lobes form a premolar with two cusps (one buccal cusp and one lingual cusp)?
- 1
  - 2
  - 3
  - 4
  - 5

ANSWERS: 1—e; 2—a, d; 3—b, c, d; 4—b, c; 5—a, c, e; 6—e; 7—d; 8—a, b, c, e; 9—a; 10—a, b; 11—a, b, c, d; 12—a; 13—e; 14—d, e; 15—a; 16—c; 17—d

## Critical Thinking

- A. Using good light source (like a small flashlight), a large mirror (magnifying if possible), and a small, clean disposable dental mirror (which can be purchased from most drug stores), evaluate the facial and lingual surfaces of a **maxillary right lateral incisor** in your own mouth. Describe the tooth in as much detail as possible trying to use as many of the terms presented in this chapter as possible. Underline each term you use. For example, “There is a **pit** on the **lingual** or **palatal** surface in the **cervical** or **gingival third** in the **lingual fossa** adjacent to the **cingulum** that is deeply stained.”

B. Repeat this exercise for the maxillary left lateral incisor, the maxillary right central incisor, and the maxillary left central incisor.
- This exercise is designed to assure student mastery of the three common systems used to identify teeth.

A. In the chart that follows record the **universal tooth number** to identify each of the four permanent first molars. Next identify each of these teeth using the **International System**. Finally, use the **Palmer System**.



	Maxillary Right First Molar	Maxillary Left First Molar	Mandibular Left First Molar	Mandibular Right First Molar
Universal				
International				
Palmer				

B. In this chart, record the correct answers for each of the four permanent central incisors.

	Maxillary Right Central Incisor	Maxillary Left Central Incisor	Mandibular Left Central Incisor	Mandibular Right Central Incisor
Universal				
International				
Palmer				

## REFERENCES

1. Ash MM. Wheeler's dental anatomy, physiology, and occlusion. 7th ed. Philadelphia, PA: W.B. Saunders, 1993.
2. Osborn JR, ed. Dental anatomy and embryology. Oxford: Blackwell Scientific Publications, 1981:133.
3. Palmer RS. Elephants. World book encyclopedia. Vol 6. 1979:178C. Chicago: World Book Inc.
4. Brant D. Beavers. World book encyclopedia. Vol. 2. 1979:147. Chicago: World Book Inc.
5. Zoo Books: Elephants. Wildlife Education Limited. San Diego: Frye & Smith, 1980:14.

## GENERAL REFERENCES

- Jordan R, Abrams L, Kraus B. Kraus' dental anatomy and occlusion. St. Louis MO: Mosby Year Book, 1992.
- Melfi RC. Oral embryology and microscopic anatomy, a textbook for students in dental hygiene. 10th ed. Philadelphia PA: Lippincott Williams & Wilkins, 2000.
- Renner RP. An introduction to dental anatomy and esthetics. Chicago IL: Quintessence Publishing, 1985.



## Dr. Woelfel's Original Research Data

Data obtained from Dr. Woelfel's original research on tooth dimensions were used to draw conclusions throughout this book. Average measurements obtained

on a sample of 4572 extracted teeth obtained from dentists in Ohio from 1974 through 1979 are presented here in *Table 1-7*.



**Table 1-7** AVERAGE MEASUREMENTS ON 4572 EXTRACTED TEETH OBTAINED FROM OHIO DENTISTS DURING A STUDY BY DR. WOELFEL AND HIS FIRST-YEAR DENTAL HYGIENE STUDENTS OF THE OHIO STATE UNIVERSITY COLLEGE OF DENTISTRY, 1974–1979

	CROWN LENGTH (mm)	ROOT LENGTH (mm)	ROOT-TO-CROWN RATIO	OVERALL LENGTH (mm)	CROWN WIDTH MD (mm)	CERVIX WIDTH MD (mm)	CROWN WIDTH FL (mm)	CERVIX WIDTH FL (mm)	MESIAL CERVICAL CURVE (mm)	DISTAL CERVICAL CURVE (mm)
<b>MAXILLARY TEETH</b>										
Central incisor (398)	11.2 <sup>A</sup>	13.0	1.16	23.6	8.6	6.4	7.1	6.3	2.8 <sup>G</sup>	2.3
Lateral incisor (295)	9.8	13.4	1.37	22.5	6.6	4.7	6.2	5.8	2.5	1.9
Canine (321)	10.6	16.5	1.56	26.3 <sup>C</sup>	7.6	5.6	8.1	7.6	2.1	1.4
First premolar (234)	8.6	13.4	1.56	21.5	7.1	4.8	9.2	8.2	1.1	0.7
Second premolar (224)	7.7	14.0	1.82	21.2	6.6	4.7	9.0	8.1	0.9	0.6
First molar (308)	7.5	12.9	1.72	20.1	10.4	7.9	11.5 <sup>F</sup>	10.7	0.7	0.3
		MB root								
		12.2 DB								
		13.7 L								
Second molar (309)	7.6	12.9	1.70	20.0	9.8	7.6	11.4	10.7	0.6	0.2
		MB root								
		12.1 DB								
		13.5 L								
Third molar (305)	7.2	10.8	1.49	17.5	9.2	7.2	11.1	10.4	0.5	0.2
		MB root								
		10.1 DB								
		11.2 L								
Avg. for 2392 upper teeth	8.77	13.36	1.55	21.59	8.23	6.11	9.20	8.48	1.40	0.97
<b>MANDIBULAR TEETH</b>										
Central incisor (226)	8.8	12.6	1.43	20.8	5.3 <sup>P</sup>	3.5	5.7	5.4	2.0	1.6
Lateral incisor (234)	9.4	13.5	1.43	22.1	5.7	3.8	6.1	5.8	2.1	1.5
Canine (316)	11.0 <sup>B</sup>	15.9	1.45	25.9	6.8	5.2	7.7	7.5	2.4	1.6
First premolar (238)	8.8	14.4	1.64	22.4	7.0	4.8	7.7	7.0	0.9	0.6
Second premolar (227)	8.2	14.7	1.80	22.1	7.1	5.0	8.2	7.3	0.8	0.5
First molar (281)	7.7	14.0 M root	1.83	20.9	11.4 <sup>F</sup>	9.2	10.2	9.0	0.5	0.2
		13.0 D								
Second molar (296)	7.7	13.9 M root	1.82	20.6	10.8	9.1	9.9	8.8	0.5	0.2
		13.0 D								
Third molar (262)	7.5	11.8 M root	1.57	18.2	11.3	9.2	10.1	8.9	0.4	0.2
		10.8 D								
Avg. for 2180 lower teeth	8.62	13.85	1.62	21.61	8.17	6.24	8.22	7.44	1.20	0.80

Size ranges are shown in tables in each chapter.

KEY FOR TOOTH SURFACE ABBREVIATIONS: D, distal; DB, distobuccal; FL, faciolingually; L, lingual; M, mesial; MB, mesiobuccal; MD, mesiodistal.

A, longest crown by Woelfel; B, longest crown by Kraus; C, longest tooth overall; D, narrowest crown mesiodistally; E, widest crown mesiodistally; F, widest crown faciolingually; G, greatest cervical line curve.

## Morphology of the Permanent Incisors

Topics covered within the three sections of this chapter include the following:

- I. General description of incisors
  - A. Functions of incisors
  - B. Morphology of incisors
  - C. Class traits for all incisors
  - D. Arch traits that distinguish maxillary from mandibular incisors
- II. Maxillary incisor type traits: similarities and differences useful to distinguish maxillary central incisors from maxillary lateral incisors (from all views)
  - A. Maxillary incisors from the labial view
  - B. Maxillary incisors from the lingual view
  - C. Maxillary incisors from the proximal views
  - D. Maxillary incisors from the incisal view
- III. Mandibular incisor type traits: similarities and differences useful to distinguish mandibular central incisors from mandibular lateral incisors (from all views)
  - A. Mandibular incisors from the labial view
  - B. Mandibular incisors from the lingual view
  - C. Mandibular incisors from the proximal views
  - D. Mandibular incisors from the incisal view
- IV. Interesting variations and ethnic differences in incisors

**W**hile using the maxillary right lateral incisor as a representative example for all incisors, refer to page 1 of the Appendix while reading Section I of this chapter. Within this text, the word “Appendix” followed by a number and letter (e.g., Appendix 1a) is used to denote the appendix page (number 1) and item (letter a) being referenced. Tear out the perforated appendix pages to facilitate study and minimize page turns as you read the main text. This chapter will focus on Appendix pages 1 and 2. Notice that the trait being demonstrated by each letter on the appendix pages is described on the back of each appendix page.

Further, in the study of any type of human tooth, you should be aware that each tooth varies in form in different people as much as facial features vary from one person to another. One study of a collection of 100 maxillary central incisors showed considerable difference in such characteristics as size, relative proportions, and color.<sup>1</sup> Also, statistics obtained from Dr. Woelfel’s original research on teeth have been used to draw conclusions throughout this chapter, and are referenced with superscript letters like this (data<sup>A</sup>) that refer to data presented at the end of this chapter.

### SECTION I

### GENERAL DESCRIPTION OF INCISORS

#### OBJECTIVES

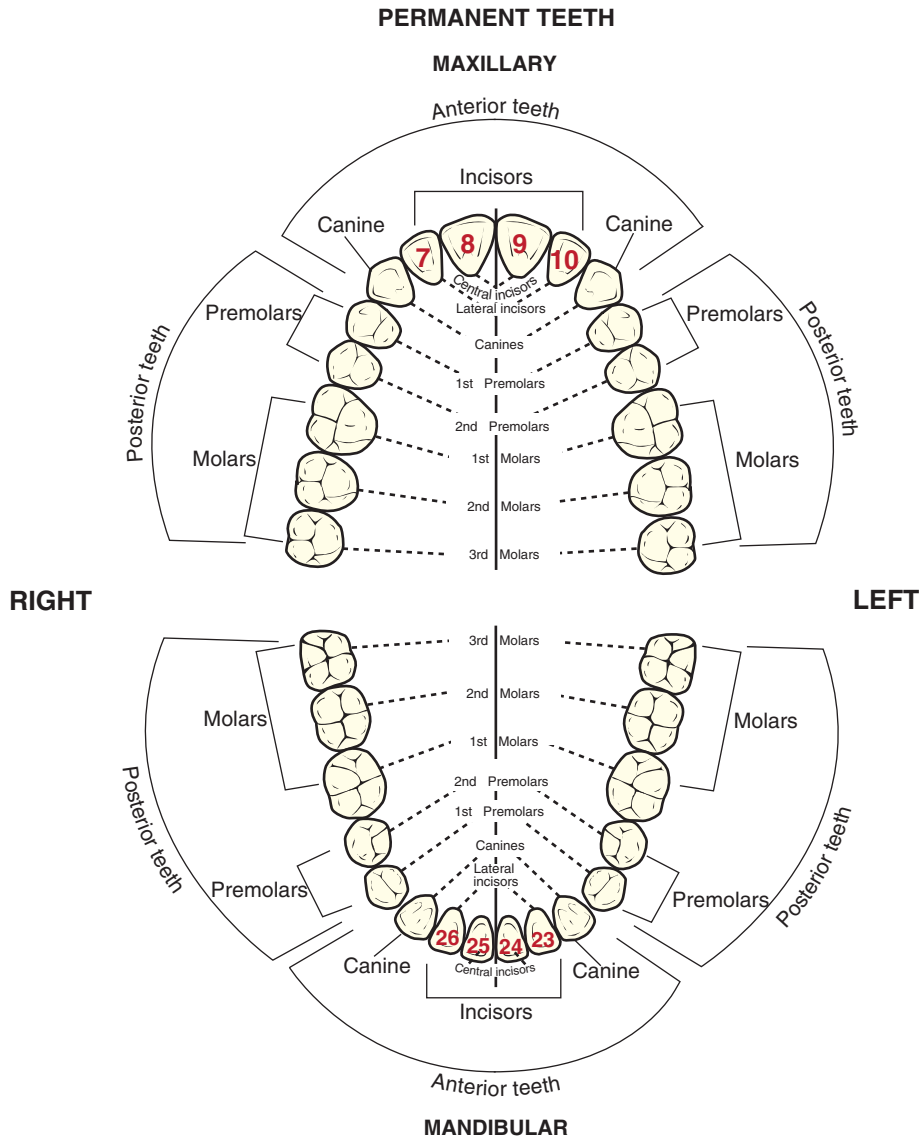
This section is designed to prepare the learner to perform the following:

- Describe the functions of incisors.
- List class traits common to all incisors.
- List arch traits that can be used to distinguish maxillary from mandibular incisors.
- From a selection of all teeth, select and separate out the incisors.
- Divide a selection of all incisors into maxillary and mandibular (using arch traits).

Refer to *Figure 2-1* or, better yet, to a model of the complete set of permanent teeth while becoming familiar with the location and universal number of each incisor. There are four maxillary incisors: two central incisors (first maxillary incisors: universal Numbers 8 and 9) and two lateral incisors (second maxillary incisors: Numbers 7 and 10). There are four mandibular

incisors: two central incisors (first mandibular incisors: Numbers 24 and 25) and two lateral incisors (second mandibular incisors: Numbers 23 and 26).

Central incisors are located on either side in their respective arch (maxillary or mandibular) with their mesial surfaces next to one another at the midline, usually in contact. Their distal surfaces contact the



**FIGURE 2-1.** Adult dentition with Universal numbers on the incisors highlighted in red.

mesial surfaces of the lateral incisors. Lateral incisors are therefore just distal to central incisors, while their mesial surfaces are in contact with the distal surfaces of the adjacent central incisors. Their distal surfaces contact the canines.

### A. FUNCTIONS OF INCISORS

The mandibular incisors function with the maxillary incisors to (a) cut food (mandibular incisors are moving blades against the maxillary incisors), (b) enable articulate speech (consider the enunciation of a toothless person), and (c) help to support the lip and maintain an esthetic appearance. By current standards, a person lacking one or more incisors has an undesirable appearance. (Did you ever hear the song “All I want for Christmas are my two front teeth”?) Their fourth function, by fitting

the incisal edges of the mandibular incisors against the lingual surfaces of the maxillary incisors, is to (d) help guide the mandible posteriorly during the final phase of closing just before the posterior teeth contact.

### B. MORPHOLOGY OF INCISORS

The morphology, or anatomy, of a tooth can best be studied by considering the shape (outline) and contours (ridges and grooves) visible on each tooth surface. *All tooth crowns* have five surfaces, that is, four side surfaces plus a chewing or cutting surface or edge, depending on whether it is a posterior tooth where chewing occurs or an anterior tooth where cutting occurs. In the study of tooth morphology, the description and location of the ridges, grooves, convexities, and concavities on each tooth surface should be well fixed in your mind in order

to describe and identify teeth by arch, class, type, and side of the mouth; to reproduce tooth contours when constructing crowns, bridges, and fillings; to skillfully remove deposits (tartar and calculus) from crowns and roots; or to finish and polish existing restorations.

When discussing traits, the external morphology of an incisor is customarily described from each of five views: (a) facial (or labial), (b) lingual (tongue side), (c) mesial, (d) distal, and (e) incisal. Due to similarities between the mesial and distal, these surfaces will be discussed together in this text under the heading of proximal surfaces.

### C. CLASS TRAITS FOR ALL INCISORS

First, consider the class traits of incisors, that is, traits that apply to all incisors.

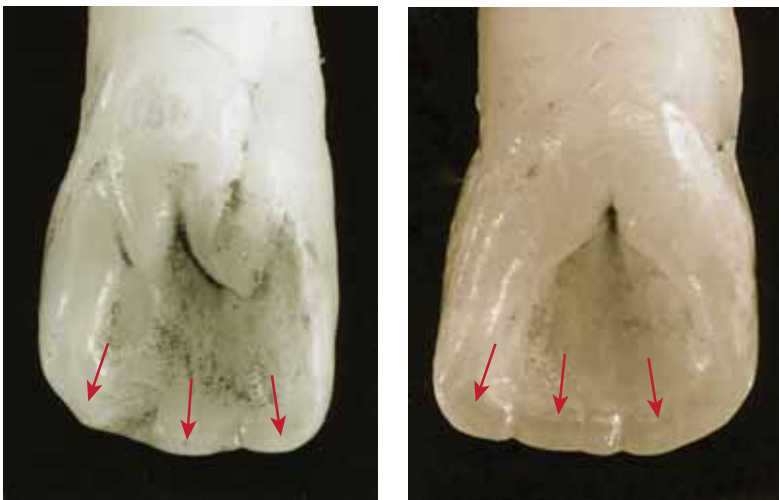**Developmental lobes:** Recall from Chapter 1 that the facial surface of all anterior teeth forms from three labial lobes: the mesial, middle, and distal lobes. Incisors usually have two shallow vertical developmental depressions separating the three lobes that form the facial surfaces. Subtle shading highlights these depressions on the drawings in Figure 2-5. The three lobes also contribute to three rounded elevations on the incisal edge called **mamelons**, located on the incisal edges of newly erupted incisor teeth (Fig. 2-2). Finally, remember that a fourth (lingual) lobe forms the lingual bulge called a **cingulum**. See Table 2-1 for a summary of the number of lobes forming each type of incisor.

#### 1. GENERAL SIMILARITIES OF MOST INCISORS FROM THE FACIAL VIEW

Refer to page 1 of the Appendix while studying the similarities of most incisors. Note that there may be exceptions to the general incisor traits presented here, and these are noted in capital letters.

All **incisor crowns**, when viewed from the facial, have a relatively straight or slightly curved incisal edge (vs. all other teeth that have one or more pointed cusp tips). Their crowns are relatively *rectangular*, longer incisogingivally than wide mesiodistally (Appendix 1a). They taper (narrower) from the widest mesiodistal areas of proximal contact toward the cervical line, and are therefore narrowest in the cervical third and broader toward the incisal third (Appendix 1b). Incisor crown outlines are more convex on the distal than on the mesial surfaces EXCEPT on mandibular central incisors, which are symmetrical (Appendix 1c). Incisor mesioincisal angles are more acute (sharper) than distoincisal angles EXCEPT on the symmetrical mandibular central incisors, where the angles are not noticeably different (Appendix 1d). Incisor crown contact areas (greatest height of contour proximally) on mesial surfaces are located in the incisal third. On the distal surfaces, the contact areas are more cervical than the mesial EXCEPT on the distal of the mandibular central, which is at the same level as the mesial due to its symmetry (Appendix 1e). Before wear, the incisal edge of all incisors EXCEPT the symmetrical mandibular central slopes cervically (appears shorter) toward the distal. Finally, the cervical line curves toward the apex in the middle of the facial (and lingual) surfaces (Appendix 1l).

**Incisor roots**, when viewed from the facial, taper (become more narrow) from the cervical line to the apex (Appendix 1f). They are wider faciolingually than mesiodistally EXCEPT on maxillary central incisors, where the mesiodistal width is approximately the same as the faciolingual thickness (observe this difference in root widths by comparing the facial and mesial root views in Appendix 1g). Incisor roots may bend in the apical one third EXCEPT maxillary central incisor roots, which are not as likely to bend; this bend is more often toward the distal (Appendix 1h). All incisor roots are longer than the crowns (Appendix 1i).



**FIGURE 2-2.**

Left and right maxillary central incisors, *lingual views*. Both teeth are “shovel shaped” due to their deep lingual fossae along with pronounced lingual marginal ridges and cingula. Both teeth have three rounded protuberances on their incisal edge called **mamelons** (arrows). The right tooth has a stained **pit** on the incisal border of the cingulum where caries can penetrate without being easily noticed.

**Table 2-1** GUIDELINE FOR DETERMINING THE NUMBER OF LOBES FOR INCISORS

TOOTH NAME	CINGULUM?	NO. OF LOBES
Maxillary central incisor	Yes	3 + 1 = 4
Maxillary lateral incisor	Yes	3 + 1 = 4
Mandibular central incisor	Yes	3 + 1 = 4
Mandibular lateral incisor	Yes	3 + 1 = 4

Number of lobes = 3 facial lobes + 1 lobe per cingulum.

## 2. CHARACTERISTICS OF ALL INCISORS FROM THE LINGUAL VIEW

**Incisor crowns**, when viewed from the lingual, have a narrower lingual surface because the mesial and distal surfaces converge lingually (best appreciated from the incisal view, Appendix 1j). The mesial and distal marginal ridges converge toward the lingual cingulum (Appendix 1k).

## 3. CHARACTERISTICS OF ALL INCISORS FROM THE PROXIMAL VIEWS

**Incisor crowns**, when viewed from the proximal, are wedge shaped or *triangular* (Appendix 1m). They have a facial outline that is more convex cervically than incisally, and the facial height of contour (greatest bulge) that is in the cervical third, just incisal to the cervical line (Appendix 1n). The lingual height of contour is also in the cervical third, on the cingulum, but the contour of the incisal two thirds of the lingual surface is concave from cingulum area to the incisal edge. Therefore, the lingual outline is S-shaped, being convex over the cingulum and concave from the cingulum nearly to the incisal edge (Appendix 1p). The concave portion of the lingual surface on the maxillary anterior teeth is a most important guiding factor in the closing movements of the lower jaw because the mandibular incisors fit into this concavity and against marginal ridges of the maxillary incisors as maximum closure or occlusion is approached.

The cervical line proximally curves toward the incisal edge. The resultant curve is greater on the mesial surface than on the distal (compare the mesial and distal views in Appendix 1o).

The **incisor roots**, when viewed from the proximal, are widest in the cervical third and gradually taper to a rounded apex (Appendix 1f).

## 4. CHARACTERISTICS OF ALL INCISORS FROM THE INCISAL VIEW

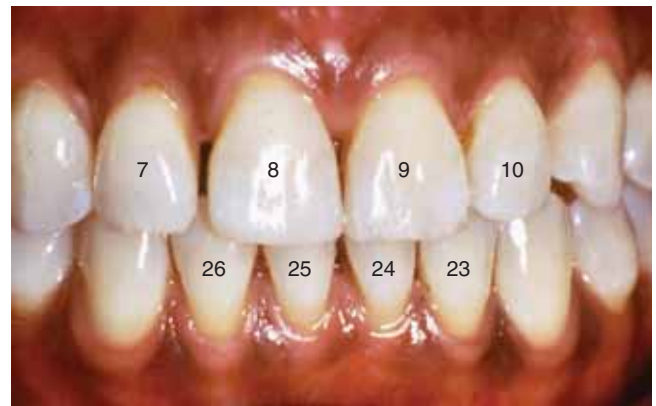Incisor crowns, when viewed from the incisal, have a lingual fossa that is concave just incisal to the cingulum.

They have an incisal ridge that terminates mesiodistally at the widest portion of the crown (Appendix 1q). The labial outline is broader and less curved than the convex lingual outline (Appendix 1r). Marginal ridges converge toward the cingulum (Appendix 1k), and the crown outline tapers from proximal contact area toward the cingulum (Appendix 1j), resulting in a narrower lingual than labial surface.

## D. ARCH TRAITS THAT DISTINGUISH MAXILLARY FROM MANDIBULAR INCISORS

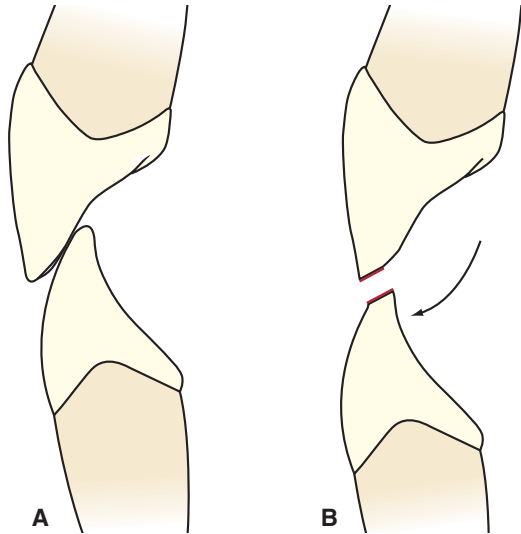
Refer to page 2 of the Appendix while reading about these arch traits that can be used to distinguish mandibular incisors from maxillary incisors.

Mandibular incisors are generally smaller than maxillary incisors. Mandibular central and lateral incisors look more alike and are more nearly the same size in the same mouth, compared to greater differences between maxillary central and lateral incisors (Fig. 2-3). Mandibular incisor crowns are flatter than maxillary incisor crowns on the mesial and distal surfaces (Appendix 2q) and have contact areas located closer to



**FIGURE 2-3.** Relative size and shape of incisors in the mouth show that maxillary central incisors are the largest, followed by maxillary laterals, then mandibular laterals and finally, the narrowest teeth in the mouth, the mandibular central incisors.





**FIGURE 2-4.** **A.** Proximal view of the normal relationship of incisors when *posterior* teeth are biting tightly together. **B.** The arrow indicates the direction of movement of mandibular incisors when the mandible moves forward (protrudes) with the incisors touching until they align edge to edge. The resultant *wear pattern* or facets on the incisal edges of *maxillary* incisors occurs more on the lingual surface (wear facets slope cervically toward the lingual), whereas wear occurs primarily on the facial surface of *mandibular* incisors (wear facets slope cervically toward the labial).

the incisal ridge than maxillary incisors (Appendix 2r and 2i). Mandibular incisor crowns are relatively wider faciolingually than mesiodistally compared to maxillary central incisors, which are wider mesiodistally (Appendix 2h). Mandibular incisor crowns also have smoother lingual surfaces with less prominent anatomy than maxillary crowns, which have deeper fossae and

more pronounced marginal ridges (Appendix 2m). Finally, mandibular incisor roots are longer in proportion to their crowns than are maxillary incisor roots.

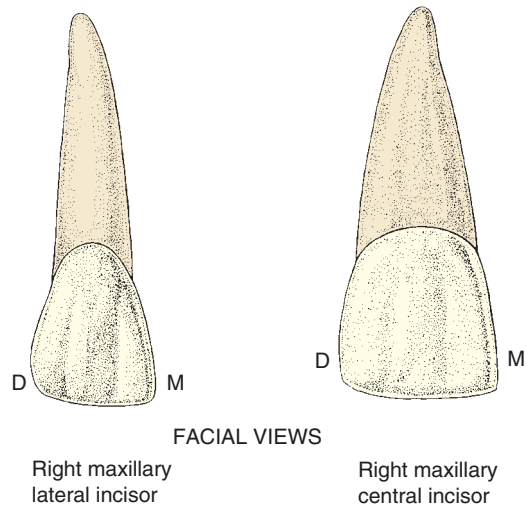
Incisal ridges of mandibular incisors are usually positioned lingual to the mid-root axis line, whereas the incisal ridges of maxillary incisors are more often on or labial to the root axis line (best seen from the proximal views on Appendix 2o). Attrition (wear) on the incisal ridges of incisors that occurs when shearing or incising food results in tooth wear that is in a different location on maxillary incisors compared to mandibular incisors (Fig. 2-4). This wear occurs when the labial part of the incisal edges of mandibular incisors slides forward and downward while contacting the lingual surface and part of the incisal edge of opposing maxillary incisors. The wear results in a shiny, flat, polished surface of enamel on the incisal edge called a **facet** [FAS it]. Assuming a normal tooth relationship, facets that commonly form on mandibular incisors are more on the labial slope of the incisal edge, sloping cervically toward the labial. In contrast, facets on maxillary incisors occur more on the lingual slope of the incisal edge, sloping cervically toward the lingual fossa and may occur on the lingual marginal ridges.

### LEARNING EXERCISE

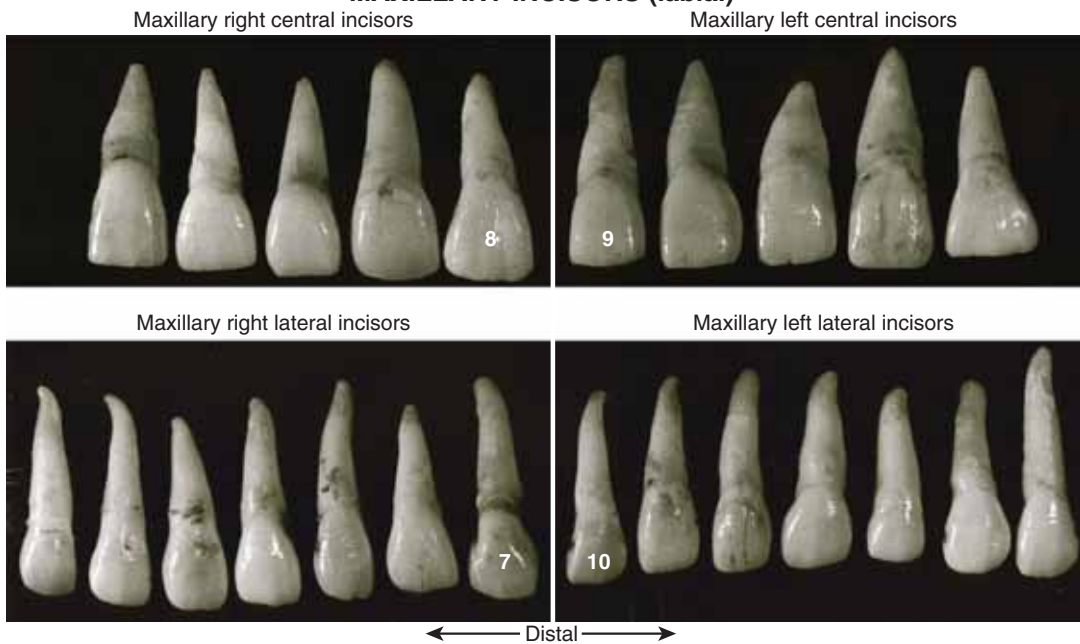
Refer to *Table 2-2* for a summary of the noticeable arch traits that distinguish maxillary from mandibular incisors and see how many of them can be used to differentiate the rows of maxillary and mandibular incisors from various views in *Figures 2-5, 2-6, 2-8, 2-10, and 2-13 through 2-15 and 2-17*.

**Table 2-2 MAJOR ARCH TRAITS THAT DISTINGUISH MAXILLARY FROM MANDIBULAR INCISORS**

	MAXILLARY INCISORS	MANDIBULAR INCISORS
<b>LABIAL VIEW</b>	Wider crowns mesiodistally Less symmetrical crown More rounded mesial and distal incisal angles Contact areas more cervical	Narrower crowns mesiodistally More symmetrical crowns More square mesial and distal incisal angles Contact areas very incisal
<b>LINGUAL VIEW</b>	Lingual anatomy more distinct: Pronounced marginal ridges Deeper lingual fossa Sometimes lingual pits Larger cingulum	Lingual surface smoother: Almost no marginal ridges Shallower lingual fossa No pits Smaller cingulum
<b>PROXIMAL VIEWS</b>	Incisal edge on or labial to mid-root axis line Facets on lingual slope of incisal edge	Incisal edge on or lingual to mid-root axis line Facets on labial slope of incisal edge
<b>INCISAL VIEW</b>	Crowns wider mesiodistally than faciolingually	Crowns wider faciolingually than mesiodistally
	Plus traits seen from lingual view can also be seen from the incisal view	



**MAXILLARY INCISORS (labial)**



**TRAITS TO DISTINGUISH MAXILLARY CENTRAL FROM LATERAL INCISOR: LABIAL VIEW**

**CENTRAL INCISOR**

- Larger crown, wider cervically
- Mesial incisal angle is a right angle
- Distal contact closer to incisal ridge
- Less likely root tip bend to distal
- Incisal edge closer to horizontal

**LATERAL INCISOR**

- Smaller crown, narrower cervically
- Mesial incisal angle is rounder
- Distal contact is near middle third
- Root tip often bends to distal
- Incisal edge slopes cervically to distal

**TRAITS TO DIFFERENT MAXILLARY RIGHT FROM LEFT INCISOR: LABIAL VIEW**

**CENTRAL INCISOR AND LATERAL INCISOR**

- Mesial crown outline flatter, distal more rounded
- Distoincisal angle more rounded than mesioincisal angle
- Distal contact more cervical than mesial contact
- Incisal edge slopes shorter toward the distal

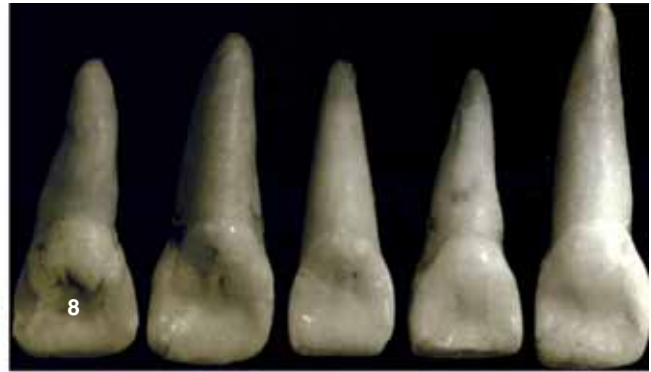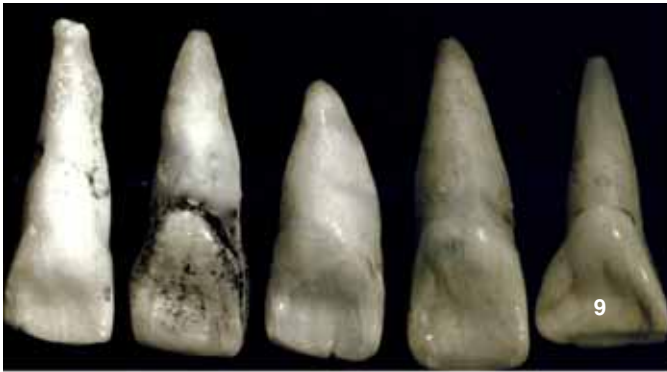**FIGURE 2-5.**

Maxillary central and lateral incisors, **labial views**, with type traits that distinguish maxillary central from lateral incisors, and traits that distinguish right and left sides.

**MAXILLARY INCISORS (lingual)**

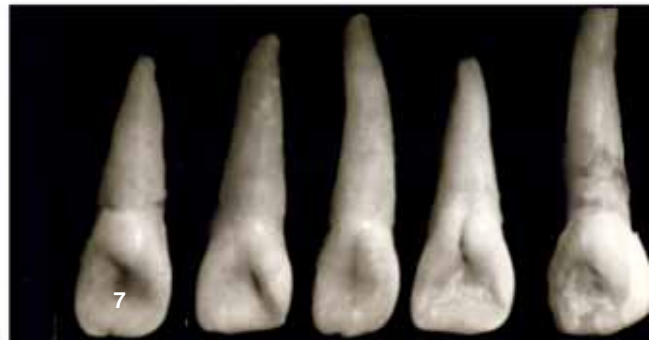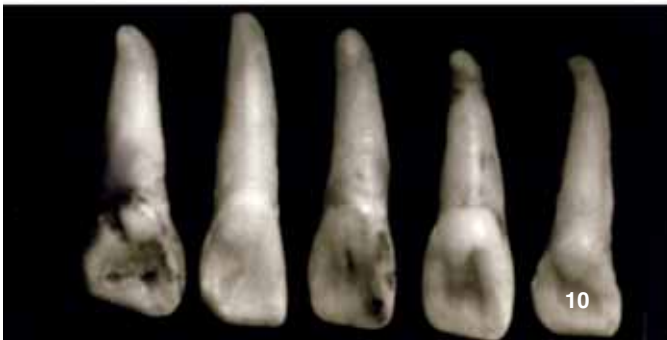Maxillary left central incisors

Maxillary right central incisors



Maxillary left lateral incisors

Maxillary right lateral incisors



← Distal →

**TRAITS TO DISTINGUISH MAXILLARY CENTRAL FROM LATERAL INCISOR: LINGUAL VIEW**

**CENTRAL INCISOR**

- Larger shallow lingual fossa
- Cingulum distally positioned
- Less frequent lingual pit

**LATERAL INCISOR**

- Deep but small fossa
- Cingulum centered
- More common lingual pit

Plus outline characteristics seen from facial apply to lingual outline

**TRAITS TO DIFFERENTIATE MAXILLARY RIGHT FROM LEFT INCISOR: LINGUAL VIEW**

**CENTRAL INCISOR**

- Cingulum toward distal
- Distal marginal ridge more curved than mesial
- Both have longer mesiolingual marginal ridge

**LATERAL INCISOR**

- Longer and straighter mesial marginal ridge

Plus outline characteristics from facial also apply to lingual outline

**FIGURE 2-6.**

Maxillary central and lateral incisors, **lingual views**, with type traits that distinguish maxillary central from lateral incisors, and traits that distinguish right and left sides.

## SECTION II

## MAXILLARY INCISOR TYPE TRAITS: SIMILARITIES AND DIFFERENCES USEFUL TO DISTINGUISH MAXILLARY CENTRAL INCISORS FROM MAXILLARY LATERAL INCISORS (FROM ALL VIEWS)

### OBJECTIVES

This section is designed to prepare the learner to perform the following:

- Describe the type traits that can be used to distinguish the permanent maxillary central incisor from the maxillary lateral incisor.
- Describe and identify the labial, lingual, mesial, distal, and incisal surfaces for all maxillary incisors.
- Assign a Universal number to maxillary incisors present in a mouth (or on a model) with complete dentition. If possible, repeat this on a model with one or more maxillary incisors missing.
- Select and separate maxillary incisors from a selection of all teeth on a bench top.
- Holding a maxillary incisor, determine whether it is a central or a lateral, and right or left. Then assign a Universal number to it.

Within this section, *maxillary* central and lateral incisors are compared for similarities and differences. These traits are presented for each view of the tooth: facial, lingual, proximal (including mesial and distal), and incisal.

### A. MAXILLARY INCISORS FROM THE LABIAL VIEW

#### LEARNING EXERCISE

Examine several extracted maxillary central and lateral incisors and/or tooth models as you read. Hold these teeth root up and crown down, as they are positioned in the mouth. Also, tear out and refer to Appendix page 2 and refer to Figure 2-5 as you study the labial traits of incisors.

#### 1. CROWN SHAPE OF MAXILLARY INCISORS FROM THE LABIAL VIEW

Based on Woelfel's studies, the crown of the **maxillary central incisor** is the longest of all human tooth crowns (although at least two other authors describe the **mandibular canine crown** as the longest crown overall<sup>9,10</sup>). The maxillary central also has the widest crown of all incisors. The crown is usually longer (incisogingivally) than wide (mesiodistally)<sup>A</sup> (Appendix 2a). The crown is narrowest in the cervical third and becomes broader toward the incisal third.

The crown of the **maxillary lateral incisor** is considerably narrower mesiodistally than the crown of the maxillary central incisor, and the root is longer, giving this entire tooth a longer, slender look<sup>B</sup> (Appendices 2a and d). The crown outline is less symmetrical than

on the central incisor. Normally, the labial surface of the maxillary lateral incisor is more convex or less flat mesiodistally than on the maxillary central. Mamelons, and particularly labial depressions, are less prominent and less common than on the central incisor.

#### 2. INCISOPROXIMAL LINE-ANGLES OF THE MAXILLARY INCISOR FROM THE LABIAL VIEW

On the outline of **maxillary central incisors**, the angle formed by the mesial and incisal surfaces (called the mesioincisal angle) is nearly a right angle. The distoincisor angle is more rounded, and the angle is slightly obtuse or greater than a right angle (Appendix 2b).

On **maxillary lateral incisors**, both the mesioincisal and distoincisor angles are more rounded than on the central incisor (Appendix 2b). The mesioincisal angle is more acute than the distoincisor angle, accentuated by the incisal edge sloping cervically toward the distal (more so than on the maxillary central incisor) (Appendix 2c).

#### 3. PROXIMAL CONTACT AREAS OF MAXILLARY INCISORS FROM THE LABIAL VIEW

The mesial contacts of *both* a maxillary central and lateral incisor are in the incisal third, very near the incisal edge for the central and slightly more cervical on the lateral. The distal contacts of both incisors are more cervical than the mesial. For a maxillary central incisor, the distal contact is near the junction of the incisal and the middle thirds; for the maxillary lateral incisor it is even more cervical, in the middle third (making this distal contact the most cervical for any incisor).

#### 4. ROOT-TO-CROWN PROPORTIONS OF MAXILLARY INCISORS FROM THE LABIAL VIEW

On a maxillary *central* incisor, the root is only slightly longer than the crown resulting in a root-to-crown ratio that is the smallest of any permanent tooth (Appendix 2d). The maxillary *lateral* incisor root is longer than on the central.<sup>C</sup> This results in a root that appears longer in proportion to the crown than on the maxillary central incisor.

#### 5. ROOT SHAPE OF MAXILLARY INCISORS FROM THE LABIAL VIEW (COMPARED WITH THE PROXIMAL VIEW)

The root of the **maxillary central incisor** is thick in the cervical third and narrows through the middle to a blunt apex. Its outline and shape is much like an ice cream cone. An apical bend is not common in the maxillary central incisor. The central incisor root is the only maxillary tooth that is as thick at the cervix mesiodistally as faciolingually. Compare the root width seen on the proximal view to the root width seen on the labial view in Appendix 2n. All other types of maxillary teeth have roots that are thicker faciolingually than mesiodistally.<sup>D</sup> Because of its shortness and conical shape, the maxillary central incisor root may be a poor choice to support a replacement tooth as part of a dental bridge (i.e., a replacement tooth crown attached to, and supported by, two adjacent teeth).

The root of a **maxillary lateral incisor** tapers evenly toward the rounded apex, and the apical end is commonly bent distally (seen in 12 of the 14 maxillary lateral incisors in Fig. 2-5, lower row).

### B. MAXILLARY INCISORS FROM THE LINGUAL VIEW

Refer to Figure 2-6 while studying the lingual traits of maxillary incisors.

#### 1. LINGUAL FOSSAE OF MAXILLARY INCISORS FROM THE LINGUAL VIEW

Large lingual fossae are located immediately incisal to the cingulum and bounded by two marginal ridges. The fossae of both maxillary incisors are most often deeper than fossae in mandibular incisors. The lingual fossa of the maxillary lateral incisor, although smaller in area, is often even more pronounced than on the central incisor. Note the deeper lingual fossae on many maxillary lateral incisors compared to central incisors in Figure 2-6.

#### 2. CINGULUM OF MAXILLARY INCISORS FROM THE LINGUAL VIEW

The cingulum on the **maxillary central incisor** is usually well developed and is located off-center, *distal* to

the root axis line that bisects the root longitudinally. (This can also be seen from the incisal view.) The cingulum on the **maxillary lateral incisor** is narrower than on the central, and it is almost centered on the root axis line (Appendix 2e).

#### 3. MARGINAL RIDGES OF MAXILLARY INCISORS FROM THE LINGUAL VIEW

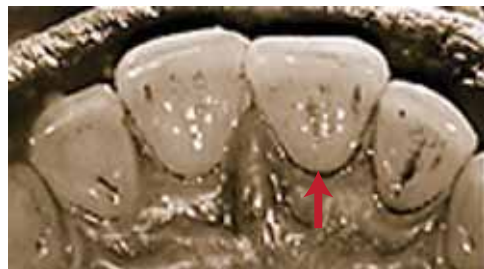The mesial and distal marginal ridges vary in prominence on all maxillary incisors from one person to another. They may be prominent or inconspicuous. Maxillary incisors with a deep lingual fossa and prominent mesial and distal marginal ridges are called “shovel-shaped incisors”<sup>E</sup> (as seen in Fig. 2-2).<sup>2-6</sup> They may also have been worn smooth (forming facets) from attrition or chewing by the mandibular incisors.

On the *both* types of maxillary incisors, *mesial* marginal ridges (from the incisal edge to the cingulum) are longer than distal marginal ridges because of the taper of the incisal edge from mesial to distal (Appendix 2f). This is also accentuated on the maxillary central incisor because its cingulum is off center toward the distal. Also the shorter distal marginal ridges are more curved compared to the mesial marginal ridges that are straighter incisocervically (seen in most incisors in Fig. 2-6).

#### 4. PITS AND ACCESSORY RIDGES OF MAXILLARY INCISORS FROM THE LINGUAL VIEW

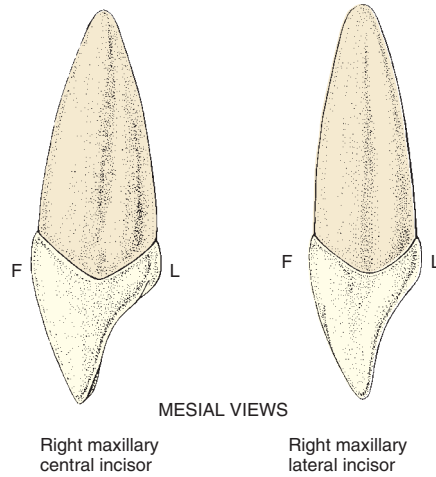
On *both* types of maxillary incisors, but more frequently in lateral incisors, a lingual pit may be detectable at the incisal border of the cingulum where the mesial and distal marginal ridges converge. This pit may need to be restored or sealed in order to prevent or arrest decay. (Notice the deep lingual pits in several maxillary lateral incisors in Fig. 2-6.)

Small, narrow accessory lingual ridges may extend vertically from the cingulum toward the center of the fossa in both types of maxillary incisors (fewer in maxillary laterals). Accessory ridges may be 1, 2, 3, or 4 in number (tooth No. 9 in Fig. 2-7 shows these accessory ridges most clearly). Tiny grooves separate these ridges.<sup>EG</sup>



**FIGURE 2-7.** The lingual surfaces of these maxillary incisors reveal **accessory ridges**, especially on tooth No. 9 (at the *arrow*).





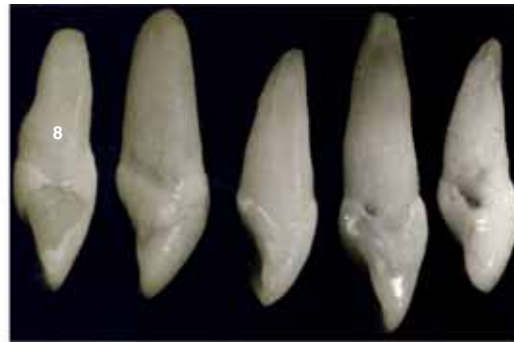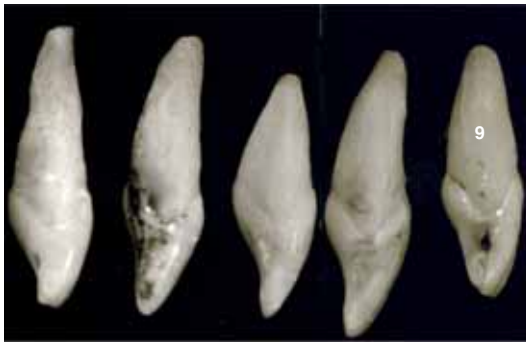Right maxillary central incisor

Right maxillary lateral incisor

**MAXILLARY INCISORS (proximal)**

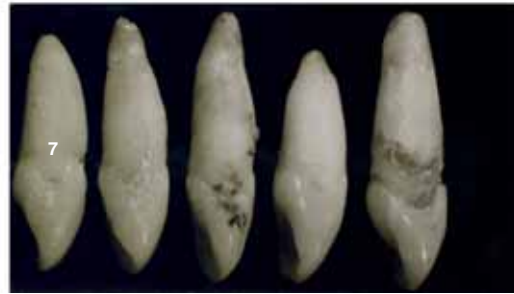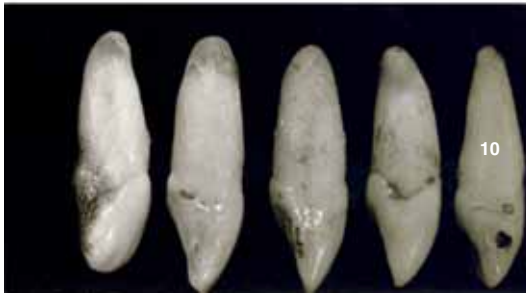Maxillary left central incisors

Maxillary right central incisors



Maxillary left lateral incisors

Maxillary right lateral incisors



MESIAL SURFACES

DISTAL SURFACES

← Lingual

Facial →

**TRAITS TO DISTINGUISH MAXILLARY CENTRAL FROM LATERAL INCISOR: PROXIMAL VIEWS**

**CENTRAL INCISOR**

Deeper lingual crown concavity  
Root outline more curved on lingual than facial

**LATERAL INCISOR**

Slightly shallower lingual crown concavity  
More even root taper facially and lingually

**TRAITS TO DIFFERENTIATE MAXILLARY RIGHT FROM LEFT INCISOR: COMPARING PROXIMAL VIEWS**

**CENTRAL INCISOR AND LATERAL INCISOR**

Larger cervical line curvature on mesial than distal  
Flatter mesial root surface contour than distal contour

**FIGURE 2-8.**

Maxillary central and lateral incisors, **proximal views**, with type traits that distinguish maxillary central from lateral incisors, and traits that distinguish right and left sides.

## 5. ROOT SHAPE OF MAXILLARY INCISORS FROM THE LINGUAL VIEW

The root contour of all maxillary incisors, like all anterior teeth, is convex and tapers, becoming narrower toward the lingual surface (Fig. 2-6).

### C. MAXILLARY INCISORS FROM THE PROXIMAL VIEWS

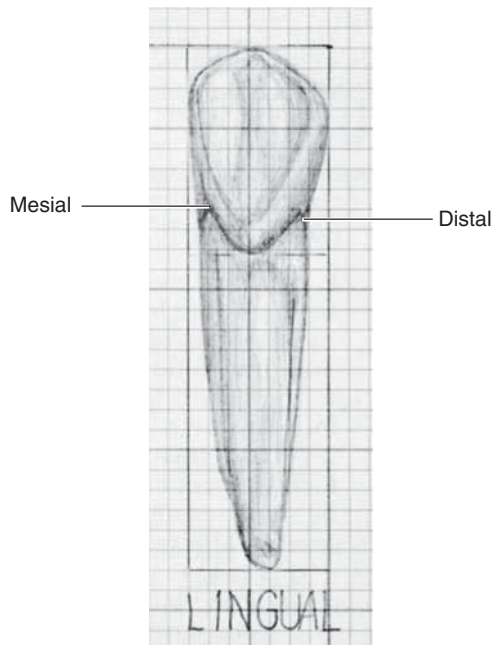
Refer to Figure 2-8 while studying the proximal traits of maxillary incisors.

#### 1. INCISAL EDGE OF MAXILLARY INCISORS FROM THE PROXIMAL VIEWS

On both maxillary incisors, the incisal edge is commonly just labial to the root axis line or may be on the root axis line (Appendix 2o). From the mesial side, the slight distolingual twist of the incisal ridge of the maxillary central incisor places the distal portion at the ridge even somewhat more lingual than on the mesial (barely visible in Fig. 2-8).

#### 2. CERVICAL LINE OF MAXILLARY INCISORS FROM THE PROXIMAL VIEWS

As on all anterior teeth, the cervical line of both types of maxillary incisors curves incisally on the mesial and



**FIGURE 2-9.** Lingual view of a mandibular canine shows the greater amount of curvature of the **cemento-enamel junction (CEJ)** on the mesial versus distal surface of the tooth. This trait is evident on all incisors and canines (and most posterior teeth as well).

distal tooth surfaces, and this curvature is greater on the mesial surface than on the distal surface (as seen in Fig. 2-9 where a drawing of a mandibular canine is used to demonstrate this concept for all anterior teeth). This difference is most pronounced on anterior teeth. The mesial curvature of the cervical line of the **maxillary central incisor** is *larger* than for any other tooth, extending incisally one fourth of the crown length, whereas the distal cervical line curves less. The curvature of the mesial cervical line of the **maxillary lateral incisor** is also considerable but slightly less than on the central.<sup>H</sup>

#### 3. HEIGHT (CREST) OF CONTOUR OF MAXILLARY INCISORS FROM THE PROXIMAL VIEWS

On the labial outline, the height of contour on both types of maxillary incisors is in the cervical third, just incisal to the cervical line. The *labial* outline becomes nearly flat in the middle and incisal thirds. The *lingual* outline is “S” shaped, and the height of contour is also in the cervical third, on the cingulum.

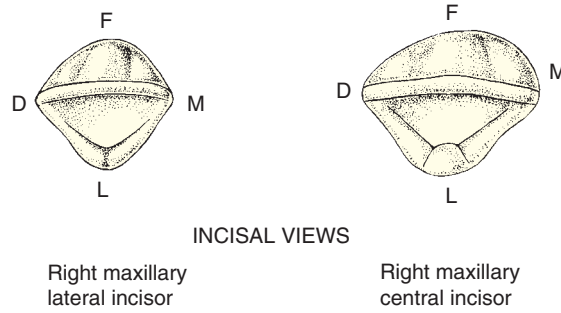
#### 4. ROOT SHAPE AND ROOT DEPRESSIONS OF MAXILLARY INCISORS FROM THE PROXIMAL VIEWS

The root of the **maxillary central incisor** is wide faciolingually at the cervix and tapers to a rounded apex. The lingual outline is nearly straight in the cervical third, and then curves labially toward the tip in the middle and apical thirds. The labial outline is even straighter. In contrast, the root of the **maxillary lateral incisor** tapers more evenly throughout the root toward the blunt apex. From the proximal view, this flatter facial root outline and more convex lingual root outline is evident in many central incisors in Figure 2-8.

The *distal* root surfaces of both types of maxillary incisors are likely to be convex, without a longitudinal depression, but the mesial root surfaces could have a slight depression in the middle third cervicoapically, slightly lingual to the center faciolingually. A slight *mesial* root depression is discernible in the shaded line drawings in Figure 2-8.

### D. MAXILLARY INCISORS FROM THE INCISAL VIEW

Refer to Figure 2-10 when studying the incisal view. To follow this description, a maxillary incisor should be held in such a position that the incisal edge is toward you, the labial surface is at the top, and you are looking exactly along the root axis line. You should see slightly more lingual surface than labial surface if the incisal ridge is



INCISAL VIEWS

Right maxillary lateral incisor

Right maxillary central incisor

**MAXILLARY INCISORS (incisal)**

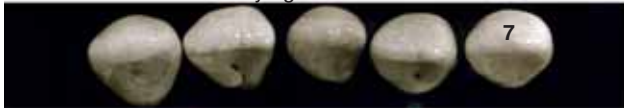Maxillary right central incisors



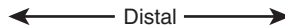Maxillary left central incisors



Maxillary right lateral incisors



Maxillary left lateral incisors



**TRAITS TO DISTINGUISH MAXILLARY CENTRAL FROM LATERAL INCISOR: INCISAL VIEW**

**CENTRAL INCISOR**

- Crown noticeably wider mesiodistally than faciolingually
- Crown outline roughly triangular
- Cingulum off center to distal
- Incisal edge curves mesiodistally

**LATERAL INCISOR**

- Crown minimally wider mesiodistally than faciolingually
- Crown outline more round or oval
- Cingulum centered
- Incisal edge straighter mesiodistally

**TRAITS TO DIFFERENTIATE MAXILLARY RIGHT FROM LEFT INCISOR: INCISAL VIEW**

**CENTRAL INCISOR**

- Cingulum more distal

**LATERAL INCISOR**

- Best to use other views

**FIGURE 2-10.** Maxillary central and lateral incisors, **incisal views**, with type traits that distinguish maxillary central from lateral incisors, and traits that distinguish right and left sides.

located somewhat labial to the root axis line (as in many teeth, especially the lateral incisors, in Fig. 2-10).

**1. CROWN PROPORTION FACIOLINGUALLY VERSUS MESIODISTALLY FOR MAXILLARY INCISORS FROM THE INCISAL VIEW**

The incisal outline of the **maxillary central incisor** is noticeably wider mesiodistally than faciolingually (Appendix 2h). The mesiodistal measurement of the **lateral incisor** crown is also greater than the labiolingual measurement but less so than on the central incisor.<sup>1</sup> On

some lateral incisors, the two dimensions of the crown are almost the same size faciolingually as mesiodistally (Appendix 2h). Notice this difference in the proportion of maxillary central incisors (relatively wider mesiodistally) compared to lateral incisors in Figure 2-10.

**2. OUTLINE SHAPE AND CINGULUM LOCATION OF MAXILLARY INCISOR CROWNS FROM THE INCISAL VIEW**

The incisal outline of the **maxillary central incisor** is somewhat *triangular*. The labial outline is broadly

curved (on some teeth the middle third may be nearly flat) forming the base of the triangle, and the other two sides of the triangle converge toward the cingulum. As was seen from the lingual view, the cingulum of the maxillary central incisor is slightly off-center to the distal, resulting in the mesial marginal ridge measuring longer than the distal marginal ridge (seen best from the lingual view in Appendix 2f).

The crown of the **lateral incisor** resembles the central incisor from this aspect, but its outline is more *round or oval* than triangular since the labial outline is noticeably more convex than on the central incisor. The cingulum of the lateral incisor is nearly centered mesiodistally. Compare the triangular shape of the maxillary central incisor to the more round or slightly oval shape of the maxillary lateral incisor in Figure 2-11. These differences in outline shapes are evident when comparing the more triangular central incisors with the more oval or round lateral incisors in Figure 2-10.

### 3. INCISAL RIDGE CONTOUR OF MAXILLARY INCISORS FROM THE INCISAL VIEW

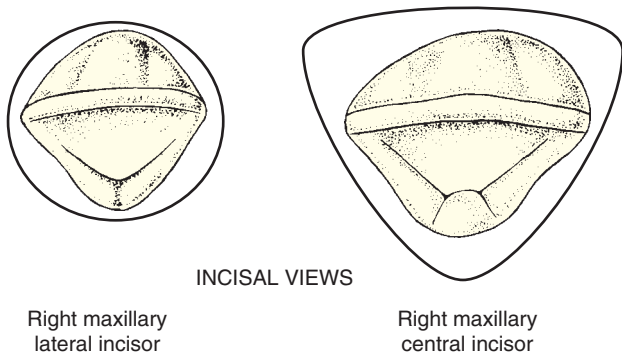
The incisal ridge or edge of the **maxillary central incisor** is 1.5 to 2 mm thick faciolingually and is slightly curved from mesial to distal, the convexity being on the labial side. It terminates mesially and distally at the widest portion of the crown (Appendix 1q). The position of the distoincisor angle is slightly more lingual than the position of the mesioincisor angle, which then gives the incisal edge its slight distolingual twist as though someone took the distal half of the incisal edge and twisted

it to the lingual (Appendix 2g). The incisal ridges on **lateral incisors** are straighter mesiodistally than on the central incisors.

Be aware that for **maxillary central incisors**, the two traits just discussed (the cingulum displaced to the distal and the distolingual twist of the incisal edge) are dependent on how the tooth is held. When viewed from the incisal, the distolingual twist of the incisal edge is more obvious when the cingulum is aligned vertically (Appendix 2g), whereas the displacement of the cingulum to the distal is more obvious when the incisal edge is aligned horizontally (Appendix 2e). This is why these two traits are shown on page 2 of the Appendix, showing two views of the same tooth, each having a slightly different alignment to accentuate the trait being discussed.

### LEARNING EXERCISE

In determining a right from a left central incisor when it is not in the mouth (e.g., on the bracket table with other incisors after multiple extractions), you need to distinguish the mesial from the distal surface. If you look at the facial surface of a tooth with its root aligned correctly for the correct arch and are able to identify the mesial or distal surface, you can place the tooth in its correct quadrant (right or left) and assign its Universal number. Evaluate the photographs of maxillary incisors in the figures in this chapter and, using the chart in each figure, see how many “mesial versus distal” traits can be used to differentiate the mesial from the distal surfaces and therefore right from left incisors. For example, in Figure 2-5 look at the labial surfaces for the shape of the incisal angles (more rounded on distal) and the position of the contact areas (more cervical on distal), or look at Figure 2-8 for the amount of cervical line curvature on the mesial and distal sides (more curved on mesial), as well as the flatter or concave mesial versus convex distal root surfaces. From the lingual view, look at Figure 2-6 for the length of the marginal ridges (mesial is longer, especially noticeable on maxillary lateral incisors), and from the incisal view on the maxillary central (Fig. 2-10), look for the distal location of the cingulum on many maxillary central incisors.



**FIGURE 2-11.** The **outline** of the maxillary lateral incisor (on the left) is almost *round* or slightly *oval* (slightly wider mesiodistally than faciolingually), whereas the outline of the maxillary central incisor is more *triangular* in shape.

## SECTION III

## MANDIBULAR INCISOR TYPE TRAITS: SIMILARITIES AND DIFFERENCES USEFUL TO DISTINGUISH MANDIBULAR CENTRAL INCISORS FROM MANDIBULAR LATERAL INCISORS (FROM ALL VIEWS)

### OBJECTIVES

This section is designed to prepare the learner to perform the following:

- Describe the type traits that can be used to distinguish the permanent mandibular central incisor from the mandibular lateral incisor.
- Describe and identify the labial, lingual, mesial, distal, and incisal surfaces for mandibular lateral incisors, and the labial, lingual, and incisal surfaces for the symmetrical mandibular central incisor (where the mesial may be difficult to distinguish from the distal).
- Assign a Universal number to mandibular incisors present in a mouth (or on a model) with complete dentition. If possible, repeat this on a model with one or more mandibular incisors missing.
- Select and separate mandibular incisors from a selection of all teeth on a bench top.
- Holding a mandibular incisor, determine whether it is a central or a lateral and right or left. Then assign a Universal number to it (which may not be possible for the symmetrical mandibular central incisor which you could identify as No. 24 or 25).

### A. MANDIBULAR INCISORS FROM THE LABIAL VIEW

Examine several extracted teeth and/or models as you read. Also, refer to page 2 of the Appendix and Figure 2-13 while you study the labial surface of mandibular incisors. Hold mandibular teeth with the root down and crown up, the position of the teeth in the mouth.

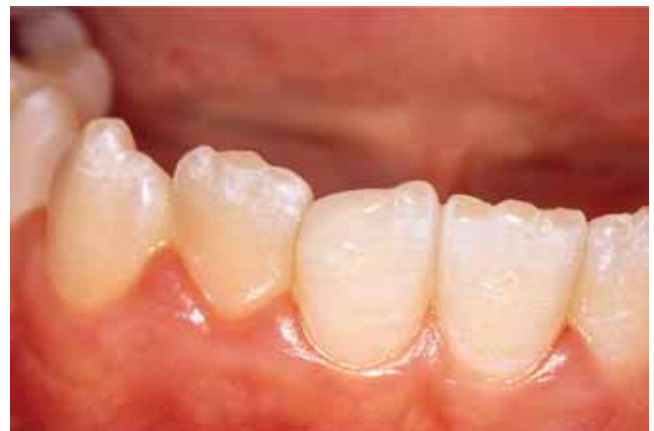#### 1. CROWN SHAPE OF MANDIBULAR INCISORS FROM THE LABIAL VIEW

Mamelons are usually present on newly emerged mandibular incisors and reflect the formation of the facial surface by three labial lobes (Fig. 2-12). Ordinarily, they are soon worn off by functional contacts against the maxillary incisors (attrition).

All mandibular incisor crowns are quite narrow relative to their crown length, but the mandibular central incisor crown is the narrowest crown in the mouth and is considerably narrower than the **maxillary central incisor**.<sup>1</sup> Unlike maxillary incisor crowns in the same mouth where the central is larger than the lateral, the mandibular lateral incisor crown is a little larger in all dimensions than the mandibular central incisor in the same mouth, as seen when comparing many central and lateral incisors in Figure 2-13. Further, the mandibular central incisor is so symmetrical that it is difficult to tell lefts from rights unless on full arch models or in the mouth. About the only notable difference to be found is the greater mesial than distal curvature of the cervical line (normally visible only on extracted teeth). This trait would not be helpful in identifying one remaining central incisor after an orthodontist has realigned the

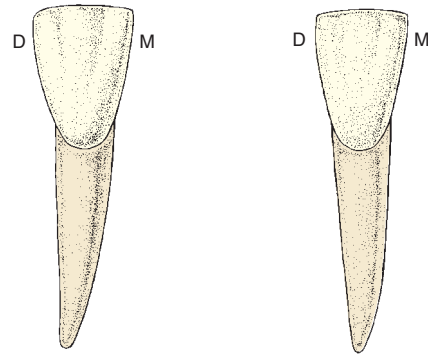
teeth and closed the spaces on either side. The fairly straight mesial and distal crown outlines taper, becoming narrower toward the convex cervical line.

The crown of the **mandibular lateral incisor** resembles that of the mandibular central incisor, but it is slightly wider and is not as bilaterally symmetrical. Its crown tilts distally on the root, giving the impression that the tooth has been bent at the cervix (Appendix 2I). This makes the curved distal outline of the crown (from proximal contact area to cervical line) shorter than the straighter mesial crown outline. Look at the incisors in Figure 2-13 and notice the lack of symmetry of the



**FIGURE 2-12.** These mandibular incisors have remnants of three **mamelons** that reflect the formation of the labial surface of incisors from three labial lobes (plus one lingual lobe forming the cingulum). These mamelons are partially worn away due to these teeth biting against maxillary incisors during function.





FACIAL VIEWS

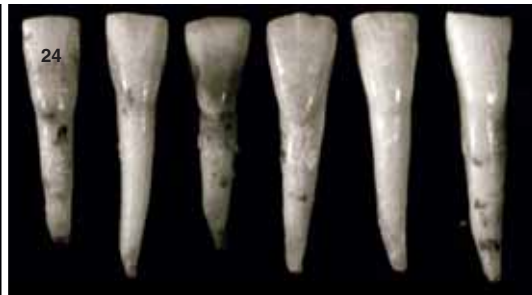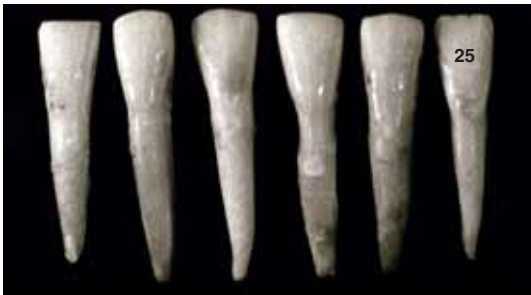
Right mandibular lateral incisor

Right mandibular central incisor

**MANDIBULAR INCISORS (labial)**

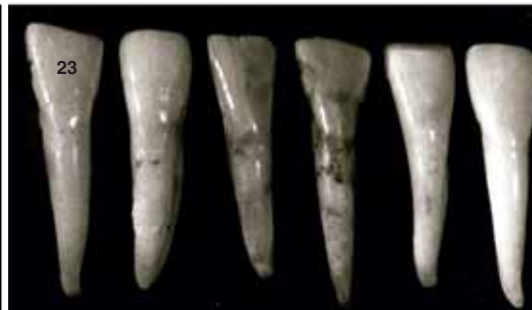
Mandibular right central incisors

Mandibular left central incisors



Mandibular right lateral incisors

Mandibular left lateral incisors



← Distal →

**TRAITS TO DISTINGUISH MANDIBULAR CENTRAL FROM LATERAL INCISOR: LABIAL VIEW**

**CENTRAL INCISOR**

- More symmetrical crown
- Minimal distal and mesial bulge of crown
- Proximal contacts on same level mesial and distal
- Smaller than lateral in the same mouth

**LATERAL INCISOR**

- Less symmetrical crown
- Obvious distal bulge on crown, crown appears to tilt distally
- Mesial proximal contact more incisal
- Larger than central in the same mouth

**TRAITS TO DIFFERENTIATE MANDIBULAR RIGHT FROM LEFT INCISOR: LABIAL VIEW**

**CENTRAL INCISOR**

- Very symmetrical: cannot easily tell right from left

**LATERAL INCISOR**

- Distal crown outline bulges more than mesial
- Distal proximal contact more cervical

**FIGURE 2-13.**

Mandibular central and lateral incisors, **labial views**, with type traits that distinguish mandibular central from lateral incisors, and traits that distinguish right and left sides.

outline of most mandibular lateral incisors relative to the symmetry of the central incisors. When comparing these teeth, be aware that the incisal edges may have worn unevenly.

The labial surfaces of *both* types of mandibular incisors are most often smooth, but could have two shallow developmental depressions in the incisal third if you examine the surface closely.<sup>K</sup>

## LEARNING EXERCISE

Look at your mouth in the mirror while you place your anterior maxillary and mandibular teeth edge to edge, and align the arch midlines (the proximal contacts between central incisors) over one another. Notice that the distal outline of each maxillary central incisor extends distal to its opposing mandibular central incisor because the maxillary central is wider by about 3.3 mm. Also, notice that the maxillary central incisors are wider and larger than the maxillary lateral incisors and wider than both of the mandibular incisors, but that the mandibular central incisors appear narrower and smaller than the adjacent mandibular lateral incisors.

## 2. INCISAL PROXIMAL ANGLES OF MANDIBULAR INCISORS FROM THE LABIAL VIEW

The crown of the **mandibular central incisor** is nearly bilaterally symmetrical, so the mesioincisal and

distoincisal angles are very similar, forming nearly right angles (Appendix 2j). The distoincisal angle may barely be more rounded than the mesioincisal angle. The distoincisal angle of the **mandibular lateral incisor**, however, is noticeably more rounded than the mesioincisal angle (Appendix 2j). This helps to distinguish rights from lefts prior to attrition (wear).

## 3. PROXIMAL CONTACT AREAS OF MANDIBULAR INCISORS FROM THE LABIAL VIEW

The mesial and distal contact areas of the **mandibular central incisor** are at the same level: in the incisal third (Appendix 2i) almost level with the incisal edge. The mesial and distal contact areas of the **lateral incisor** are not at the same level (Appendix 2i). Although both the mesial and distal contacts are in the incisal third fairly close to the incisal edge, the distal contact is noticeably cervical to the level of the mesial contact on lateral incisors. Refer to *Table 2-3* for a summary of the location of proximal contacts for all incisors.

## 4. ROOT-TO-CROWN PROPORTIONS OF MANDIBULAR INCISORS FROM THE LABIAL VIEW

Long incisocervically, mandibular incisor roots appear proportionally longer compared to their crown length than the maxillary incisors. Therefore, the root-to-crown ratio is larger for both mandibular incisors compared to maxillary central and lateral incisors.<sup>L</sup>

Table 2-3

### LOCATION OF PROXIMAL CONTACTS (PROXIMAL HEIGHT OF CONTOUR) ON INCISORS (BEST SEEN FROM FACIAL VIEW)

	MESIAL SURFACE (WHICH THIRD OR JUNCTION?)	DISTAL SURFACE (WHICH THIRD OR JUNCTION?)
MAXILLARY CROWNS	Central incisor	Incisal third (near incisal edge)
	Lateral incisor	Incisal third
MANDIBULAR CROWNS	Central incisor	Incisal/middle junction
	Lateral incisor	Middle third (most cervical of incisor contacts)
MANDIBULAR CROWNS	Central incisor	Incisal third (near incisal edge)
	Lateral incisor	Incisal third (near incisal edge)
		Incisal third (near incisal edge; same as mesial)
		Incisal third (but more cervical)

General learning guidelines for Incisors:

1. On the same incisor, the distal proximal contact is more cervical than the mesial contact EXCEPT on mandibular central incisors, where the mesial and distal contacts are at the same height.
2. All contacts for both types of *mandibular* incisors are in the incisal third, as are the *mesial* contacts on *maxillary* incisors. Distal contacts of maxillary central incisors are near the incisal/middle junction, and the distal contacts on maxillary lateral incisors are most cervical: in the middle third.

**5. ROOT SHAPE OF MANDIBULAR INCISORS FROM THE LABIAL VIEW**

The roots of *both* types of mandibular incisors appear very narrow mesiodistally but wide faciolingually (ribbon-like) (compare proximal to labial surfaces in Appendix 2n) and taper uniformly on both sides from the cervical line to the apex. The apical end may curve slightly to the distal (seen in some incisors in Fig. 2-13).

**B. MANDIBULAR INCISORS FROM THE LINGUAL VIEW**

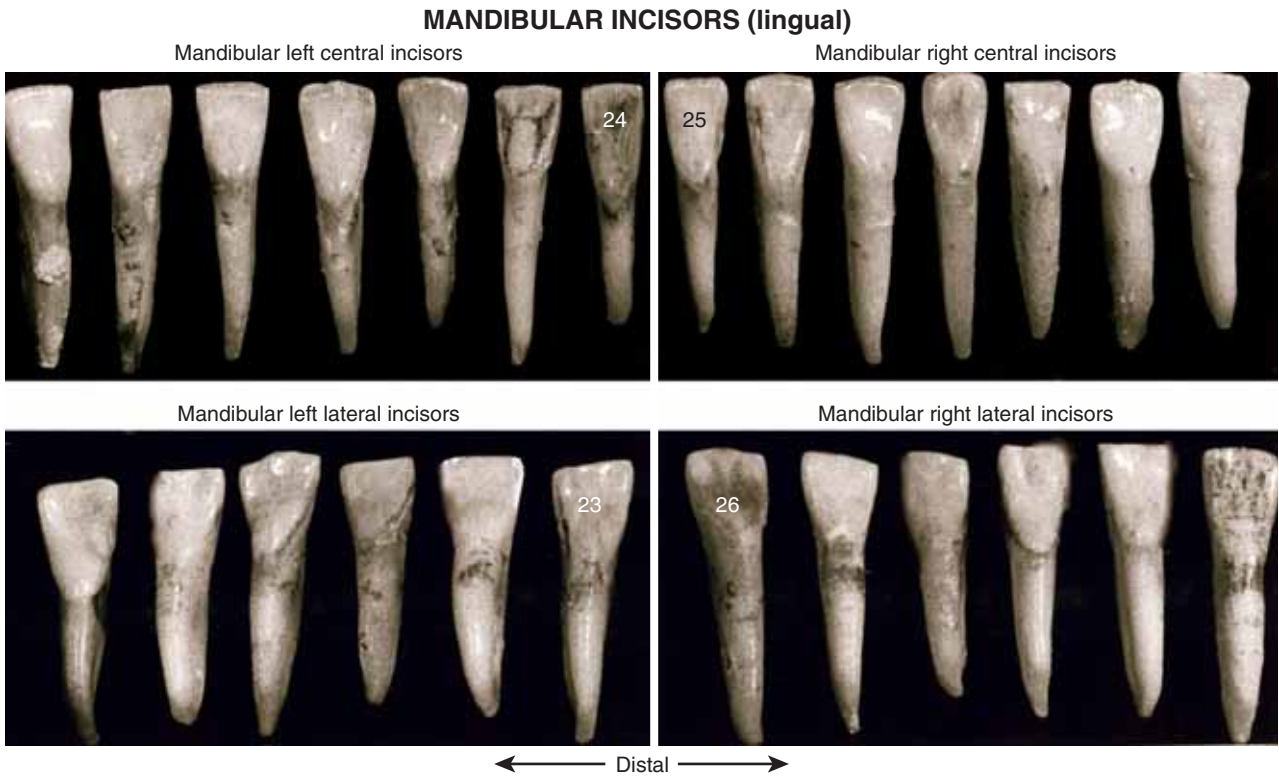
Refer to *Figure 2-14* while studying the lingual surface of mandibular incisors.

**1. CINGULUM OF MANDIBULAR INCISORS FROM THE LINGUAL VIEW**

As seen from the lingual view (or from the incisal view in Appendix 2k), the cingulum of the **mandibular central incisor** is convex, small, and centered on the axis line of the root. The cingulum of the **lateral incisor** lies slightly *distal* to the axis line of the root (similar to the maxillary central incisor).

**2. LINGUAL ANATOMY (MARGINAL RIDGES AND FOSSAE) OF MANDIBULAR INCISORS FROM THE LINGUAL VIEW**

The lingual fossae of *both* types of mandibular incisors are barely visible, smooth (without grooves, accessory



**TRAITS TO DISTINGUISH MANDIBULAR CENTRAL FROM LATERAL INCISOR: LINGUAL VIEW**

**CENTRAL INCISOR**

Cingulum centered  
Same length mesial and distal marginal ridges

**LATERAL INCISOR**

Cingulum distal to center  
Longer mesial marginal ridge

**TRAITS TO DIFFERENTIATE MANDIBULAR RIGHT FROM LEFT INCISOR: LINGUAL VIEW**

**CENTRAL INCISOR**

Very symmetrical: cannot tell right from left

**LATERAL INCISOR**

Cingulum distal to center  
Shorter distal marginal ridge

**FIGURE 2-14.** Mandibular central and lateral incisors, **lingual views**, with type traits that distinguish mandibular central from lateral incisors, and traits that distinguish right and left sides.

ridges, or pits), and shallow, just slightly concave in the middle and incisal thirds (Appendix 2m).

The adjacent marginal ridges, if distinguishable, are scarcely discernible, unlike on maxillary incisors, where they are more likely to be quite prominent. With the length of the incisal edge sloping shorter toward the distal on the mandibular lateral incisors, and the cingulum located to the distal, the mesial marginal ridge on these teeth appears slightly longer than the distal marginal ridge.

### 3. ROOT SHAPE OF MANDIBULAR INCISORS FROM THE LINGUAL VIEW

As with other incisor roots, the roots of *both* types of mandibular incisors are mostly convex and slightly narrower on the lingual side than on the labial side. You may see evidence of mesial and distal longitudinal root depressions from these views.

## C. MANDIBULAR INCISORS FROM THE PROXIMAL VIEWS

Refer to *Figure 2-15* while studying the proximal surfaces of mandibular incisors.

### 1. INCISAL EDGE ON MANDIBULAR INCISORS FROM THE PROXIMAL VIEWS

The incisal edges of *both* types of mandibular incisors are normally located on or lingual to the mid-root axis (Appendix 2o). From the mesial side, the *distolingual twist* of the incisal ridge of the **mandibular lateral incisor** places the distal portion at the ridge even somewhat more lingual than on the mesial (*Fig. 2-16*), unlike the mandibular central that has no twist. Recall that the maxillary central incisor also exhibits a slight distolingual twist of the incisal edge.

### 2. CERVICAL LINE ON MANDIBULAR INCISORS FROM THE PROXIMAL VIEWS

The cervical line on the mesial of *both* types of mandibular incisors normally has a relatively large curvature that extends incisally over one fourth of the short crown length. As on other anterior teeth, the curvature on the distal is less.<sup>M</sup>

### 3. HEIGHT (CREST) OF CONTOUR OF MANDIBULAR INCISORS FROM THE PROXIMAL VIEWS

As on the *labial* outline of maxillary incisors, the labial heights of contour on *both* types of mandibular incisors are in the cervical third, just incisal to the cervical line. The labial outline becomes nearly flat in the incisal third.

The *lingual* outlines are “S” shaped, and the heights of contour are also in the cervical third, on the cingula.

## 4. ROOT SHAPE AND DEPRESSIONS OF MANDIBULAR INCISORS FROM THE PROXIMAL VIEWS

The relatively large faciolingual dimension of the roots at the cervix on *both* types of mandibular incisors is very apparent from the proximal view. The facial and lingual outlines of the roots of all mandibular incisors are nearly straight from the cervical line to the middle third; then the root tapers with its apex on the axis line (seen in most roots in *Fig. 2-15*). The cervical portion of the roots on mandibular incisors is considerably wider faciolingually than mesiodistally.<sup>N</sup>

There is usually a slight longitudinal depression on the middle third of the mesial and distal root surfaces of *both* types of mandibular incisors. The distal depressions are somewhat more distinct. See *Table 2-4* for a summary of incisor root depressions.

## D. MANDIBULAR INCISORS FROM THE INCISAL VIEW

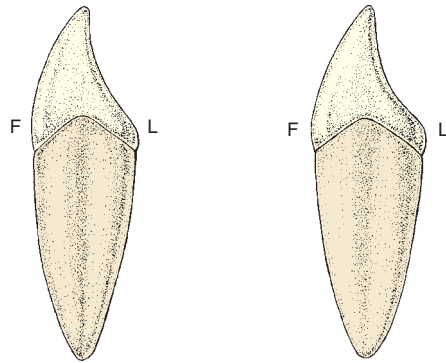
To follow this description, the tooth should be held in such a position that the incisal edge is toward the observer, the labial surface is at the top, and the observer is looking exactly along the root axis line as in *Figure 2-17*. You will see slightly more of the labial than the lingual surface if the incisal ridge is just lingual to the root axis line.

### 1. CROWN PROPORTIONS OF MANDIBULAR INCISORS FROM THE INCISAL VIEW

The crowns of *both* types of mandibular incisor are slightly wider labiolingually than mesiodistally.<sup>O</sup> This is different from the measurements of the maxillary incisors, especially maxillary central incisors, which are considerably wider mesiodistally than faciolingually.

### 2. CROWN OUTLINE OF MANDIBULAR INCISORS FROM THE INCISAL VIEW

The **mandibular central incisor** is practically bilaterally symmetrical with little to differentiate the mesial half from the distal half. The labial height of contour is centered, and the lingual height of contour is centered on the smooth, narrow cingulum. The **mandibular lateral incisor** is not bilaterally symmetrical. If you align the incisal edge of the lateral incisor exactly horizontal, the cingulum of the mandibular lateral incisor is located distal to the mesiodistal midline (*Appendix 2k* and



MESIAL VIEWS

Right mandibular central incisor

Right mandibular lateral incisor

**MANDIBULAR INCISORS (proximal)**

Mandibular left central incisors (distal)

Mandibular right central incisors (mesial)



Mandibular left lateral incisors (distal)

Mandibular right lateral incisors (mesial)



← Facial

Lingual →

**TRAITS TO DISTINGUISH MANDIBULAR CENTRAL FROM LATERAL INCISOR: PROXIMAL VIEWS**

**CENTRAL INCISOR**

No distolingual twist

**LATERAL INCISOR**

Distal of incisal ridge may be more lingual

**TRAITS TO DIFFERENTIATE MANDIBULAR RIGHT FROM LEFT INCISOR: COMPARING PROXIMAL VIEWS**

**CENTRAL INCISOR**

Distal of incisal ridge even with mesial of incisal ridge

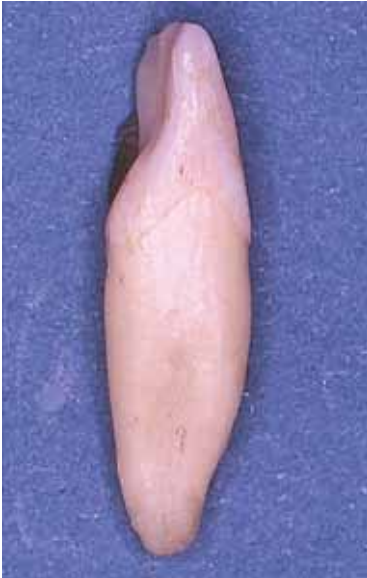**LATERAL INCISOR**

Distal of incisal ridge may be more lingual

Mesial cervical line curve greater than distal on both central and lateral incisors

**FIGURE 2-15.** Mandibular central and lateral incisors, proximal views, with type traits that distinguish mandibular central from lateral incisors, and traits that distinguish right and left sides.





**FIGURE 2-16.** Mesial view of a mandibular left lateral incisor has a pronounced “**distolingual twist**” (i.e., the distal portion of the incisal edge curves lingually) so that some of the lingual surface is visible from this mesial view.

Fig. 2-17). Recall that this was also seen on the maxillary central incisor.

### 3. INCISAL RIDGE CONTOUR (ALIGNMENT) OF MANDIBULAR INCISORS FROM THE INCISAL VIEW

The incisal ridge of the symmetrical **mandibular central incisor** is at right angles to the labiolingual root

axis plane. It is nearly 2 mm thick and runs in a straight line mesiodistally toward both contact areas.

The incisal ridge of *both* types of mandibular incisor is lingual to the mid-root axis. If you hold an extracted mandibular incisor with the root facing directly away from your sight line, slightly more of the labial than lingual surface is visible because of the lingually positioned incisal ridge.

If you were to align a **mandibular lateral incisor** with its lingual cingulum directed exactly downward or vertically (represented roughly by the dotted vertical line with the arrow in Appendix 2k), the distal half of the incisal edge would be perceived as twisted lingually (called a *distolingual twist*). This twist is evident in most mandibular lateral incisors in Figure 2-17 and is an excellent way to distinguish mandibular central from lateral incisors, and to distinguish the right from left mandibular lateral incisors. (Note that the other way to describe this asymmetry is to align the incisal edge exactly horizontally and note that the cingulum is off center to the distal.)

### 4. LABIAL CONTOUR OF MANDIBULAR INCISORS FROM THE INCISAL VIEW

The labial surfaces of *all* mandibular incisors are only slightly convex in the incisal third labial to the incisal edge, but the outline in the cervical third is decidedly convex.

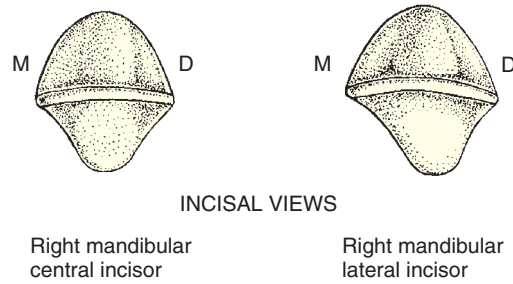
Table 2-4

#### PRESENCE AND RELATIVE DEPTH OF LONGITUDINAL ROOT DEPRESSIONS (“ROOT GROOVES”) ON INCISORS

	TOOTH	MESIAL ROOT DEPRESSION?	DISTAL ROOT DEPRESSION?
MAXILLARY TEETH	Maxillary central incisor	No (or slight or flat)	No (convex)
	Maxillary lateral incisor	Yes (sometimes no)	No (convex)
MANDIBULAR TEETH	Mandibular central incisor	Yes	Yes (deeper)
	Mandibular lateral incisor	Yes	Yes (deeper)

General learning guidelines for incisors:

1. **Maxillary incisors** are not likely to have distal root depressions but could have mesial depressions.
2. **Mandibular incisors** usually have mesial and distal (deeper) root depressions.



INCISAL VIEWS

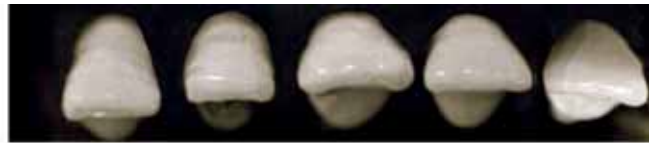Right mandibular central incisor

Right mandibular lateral incisor

**MANDIBULAR INCISORS (incisal)**

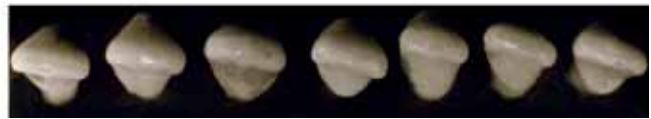
Mandibular left central incisors

Mandibular right central incisors



Mandibular left lateral incisors

Mandibular right lateral incisors



← Distal →

**TRAITS TO DISTINGUISH MANDIBULAR CENTRAL FROM LATERAL INCISOR: INCISAL VIEW**

**CENTRAL INCISOR**

No distolingual twist of incisal edge  
Cingulum is centered

**LATERAL INCISOR**

Distolingual twist of incisal edge  
Cingulum is off center to distal

**TRAITS TO DIFFERENTIATE MANDIBULAR RIGHT FROM LEFT INCISOR: INCISAL VIEW**

**CENTRAL INCISOR**

Very symmetrical: cannot tell right from left

**LATERAL INCISOR**

Distolingual twist of incisal edge  
Cingulum is off center to distal

**FIGURE 2-17.**

Mandibular central and lateral incisors, **incisal views**, with type traits that distinguish mandibular central from lateral incisors, and traits that distinguish right and left sides.

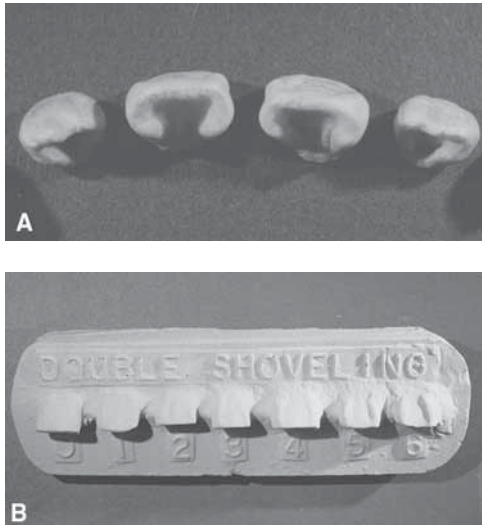
**SECTION IV**

**INTERESTING VARIATIONS AND ETHNIC DIFFERENCES IN INCISORS**

There is great morphologic variation in the **maxillary lateral incisor**. It may be missing altogether; it may resemble a small slender version of a maxillary central incisor; it may be quite asymmetrical; or it may be peg shaped (as seen later in the chapter on anomalies).

Racial differences in the maxillary incisor teeth have been reported in dental literature. **Shovel-shape** is the term commonly used to designate incisor teeth that have prominent marginal ridges and a deep fossa on

their lingual surfaces (*Fig. 2-18A*). A high incidence of shovel-shaped incisors has been observed in Mongoloid people, including many groups of American Indians.<sup>4-9</sup> (**Mongoloid** pertains to a major racial division marked by a fold from the eyelid over the inner canthus, prominent cheekbones, straight black hair, small nose, broad face, and yellowish complexion. Included are Mongols, Manchus, Chinese, Koreans, Arctic coastal populations, Japanese, Siamese, Burmese, Tibetans, and American



**FIGURE 2-18.** **A.** Shovel-shaped permanent incisors from a young Native American dentition (incisal views). Note the prominent marginal ridges on the *lingual* surface. **B.** The range of prominent *labial* ridges on double shovel-shaped incisors varies from barely discernible labial ridges on the left to prominent labial ridges on the right.

Indians.) White and black people are reported to have less frequent occurrences of this characteristic.

A study of the skulls of American Indians who lived in Arizona about 1100 AD has disclosed the occurrence of incisor teeth that have a mesial marginal ridge on the labial surface and a depression, or concavity, on the mesial part of the labial surface just distal to this ridge.<sup>10</sup> In these teeth, the distal part of the labial surface is rounded in an unusual manner. Such teeth have been referred to as “three-quarter double shovel-shaped,” a descriptive, if ponderous, term. Labial “shoveling” has also been reported in some Arctic coastal populations (see Fig. 2-18B).

There is more uniformity of shape in the **mandibular incisor** teeth than in other teeth. In some Mongoloid people, the cingulum of mandibular incisors is characteristically marked by a short deep groove running cervicoincisally. This groove is often a site of dental caries.

Later, in the chapter on anomalies, you will read about more variations: palatal gingival grooves, peg shaped incisors, fused mandibular incisors, congenitally missing central incisors, and even a lateral incisor emerged distally to the canine.

## LEARNING EXERCISE

Assign a Universal number to a handheld incisor:

Suppose a patient just had all of his or her permanent teeth extracted. Imagine being asked to find tooth No. 8 from among a pile of 32 extracted teeth on the oral surgeon’s tray because you wanted to evaluate a lesion seen on the radiograph on the root of that incisor. How might you go about it? Try the following steps:

- From a selection of all permanent teeth (extracted teeth or tooth models), select only the incisors (based on **class traits**).
- Determine whether each incisor is maxillary or mandibular using arch traits. Review Table 2-2 if needed. You should never rely on only one characteristic difference between teeth to name them; rather, make a list of many traits that apply to a maxillary incisor, as opposed to only one trait that makes you think it belongs in the maxilla. This way you can play detective and become an expert at recognition at the same time.
- Once you determine that the tooth is maxillary, position the root up; if it is mandibular, position the root down.
- Use appropriate traits in order to identify the facial surface. This will permit you to view the tooth as though you were looking into a patient’s mouth.
- Next, using type traits, determine the type of incisor you are holding (central or lateral). Refer to the tables and teeth in the figures throughout this chapter as needed.
- Next, determine which surface is the mesial. Refer to figures throughout this chapter as needed. While viewing the incisor from the facial and picturing it within the appropriate arch (upper or lower), the mesial surface can be positioned toward the midline in only one quadrant, the right or left.
- Once you have determined the quadrant, assign the appropriate Universal number for the incisor in that quadrant. For example, the central incisor in the upper right quadrant is tooth No. 8.

## Review Questions

For each of the traits listed below, select the letter(s) of the permanent incisor(s) that normally exhibit(s) that trait. More than one answer may apply.

- a. Maxillary central incisor
- b. Maxillary lateral incisor
- c. Mandibular central incisor
- d. Mandibular lateral incisor

- |  |         |
|--|---------|
| 1. Mesiodistal dimension of the crown is larger than the labiolingual dimension.             | a b c d |
| 2. The incisal ridge exhibits a distolingual twist.  | a b c d |
| 3. The root is very narrow mesiodistally with mesial and distal root depressions             | a b c d |
| 4. The incisal edge is positioned more to the lingual of the root axis line.                 | a b c d |
| 5. The distal proximal height of contour is more cervical than the mesial height of contour. | a b c d |
| 6. This tooth has the widest (mesiodistally) incisor crown.                                  | a b c d |
| 7. This tooth has the shortest root relative to its crown.                                   | a b c d |
| 8. This tooth is the most symmetrical incisor.   | a b c d |
| 9. This tooth has the largest curvature of the mesial cervical line.                         | a b c d |
| 10. This tooth has the narrowest incisor crown (mesiodistally).                              | a b c d |

ANSWERS: 1—a, b; 2—a, d; 3—c; 4—c, d; 5—a, b, d; 6—a, d; 7—a; 8—c; 9—a; 10—c

## Critical Thinking

- You are recording which teeth are present in the mouth of Mrs. Jenny James, and you notice that she has only three mandibular incisors. How might you determine which specific teeth are still present? Think of things you have learned about incisors, and try to recall facts you may already know about landmarks in the mouth.
- Using a good light source (like a small flashlight), a large mirror (magnifying if possible), and a small, clean disposable dental mirror, carefully compare the maxillary and mandibular incisors in your own mouth while referring to the traits in Table 2-2 from the **labial view** and **lingual view** that can be used to differentiate maxillary from mandibular incisors. Write down each trait that can be useful to differentiate the maxillary from the mandibular incisors **in your own mouth**, and also make note of any of the traits in the text book that do not apply in your mouth.

### REFERENCES

- Hanihara K. Racial characteristics in the dentition. *J Dent Res* 1967;46:923–926.
- Ash MM, Nelson SJ. *Wheeler's dental anatomy, physiology and occlusion*. Philadelphia, PA: Saunders, 2003.
- Kraus RE, Abrams L. *Kraus' dental anatomy and occlusion*. Oxford: Wolfe Publishing Ltd., 1992.
- Carbonelli VM. Variations in the frequency of shovel-shaped incisors in different populations. In: Brothel DR, ed. *Dental anthropology*. London: Pergamon Press, 1963:211–234.
- Brabant H. Comparison of the characteristics and anomalies of the deciduous and the permanent dentitions. *J Dent Res* 1967;48:897–902.
- De Voto FCH. Shovel-shaped incisors in pre-Columbian Tasilian Indians. *J Dent Res* 1971;50:168.

7. De Voto FCH, Arias NH, Ringuet S, et al. Shovel-shaped incisors in a northwestern Argentine population. *J Dent Res* 1968;47:820.
8. Taylor RMS. Variations in form of human teeth: I. An anthropologic and forensic study of maxillary incisors. *J Dent Res* 1969;48:5–16.
9. Dahlberg AA. The dentition of the American Indian. In: Laughlin WS, ed. *The physical anthropology of the American Indian*. New York: The Viking Fund, 1949.
10. Snyder RG. Mesial marginal ridging of incisor labial surfaces. *J Dent Res* 1960;39:361.

## GENERAL REFERENCES

- Goose DH. Variability of form of maxillary permanent incisors. *J Dent Res* 1956;35:902.
- Web site: [http://animaldiversity.ummz.umich.edu/site/topics/mammal\\_anatomy/gallery\\_of\\_incisors.html](http://animaldiversity.ummz.umich.edu/site/topics/mammal_anatomy/gallery_of_incisors.html)—University of Michigan Museum of Zoology Animal Diversity Web Gallery of Incisors



## Dr. Woelfel's Original Research Data

Statistics obtained from Dr. Woelfel's original research on teeth have been used to draw conclusions throughout this chapter, and were referenced with superscript letters that refer to the data stated here. Data from his original research is presented in *Tables 2-5A* and *2-5B*.

- A. The crown of the maxillary central incisor averages 11.2 mm long incisocervically making it the longest incisor crown. This crown averages 2.6 mm longer incisogingivally than mesiodistally.
- B. The crown of the maxillary lateral incisor averages about 2.0 mm narrower mesiodistally than on the central incisor, and the root is 0.4 mm longer.
- C. The maxillary lateral incisor root is 0.4 mm longer than on the maxillary central, and its root-to-crown ratio is 1.37 when comparing measurement of 398 maxillary central incisors and 295 lateral incisors.
- D. The maxillary central incisor root at the cervix averages about 6.4 mm wide mesiodistally and faciolingually. All other types of maxillary teeth have roots that are thicker faciolingually than mesiodistally by 1.1 to 3.4 mm.
- E. Dr. Woelfel examined the maxillary incisors on casts of 715 dental hygiene students and found that 32% of the central incisors and 27% of the lateral incisors have some degree of shoveling. The rest had smooth concave lingual surfaces without prominent marginal ridges or deep fossae.
- F. Inspection of 506 maxillary central incisors by Dr. Woelfel revealed 36% with no accessory lingual ridges, 27% with one small ridge, 28% with two accessory ridges, 9% with three ridges, and only three teeth with four small ridges.

**Table 2-5A SIZE OF MAXILLARY INCISORS (MILLIMETERS)**

DIMENSION MEASURED	398 CENTRALS		295 LATERALS	
	Average	Range	Average	Range
Crown length	11.2 longest incisor crown	8.6–14.7	9.8	7.4–11.9
Root length	13.0	6.3–20.3	13.4	9.6–19.4
Overall length	23.6	16.5–32.6	22.5	17.7–28.9
Crown width (mesiodistal)	8.6	7.1–10.5	6.6	5.0–9.0
Root width (cervix)	6.4	5.0–8.0	4.7	3.4–6.4
Faciolingual crown size	7.1	6.0–8.5	6.2	5.3–7.3
Faciolingual root (cervix)	6.4	5.1–7.8	5.8	4.5–7.0
Mesial CEJ curve	2.8 greatest CEJ curve	1.4–4.8	2.5	1.3–4.0
Distal CEJ curve	2.3	0.7–4.0	1.9	0.8–3.7



**Table 2-5B SIZE OF MANDIBULAR INCISORS (MILLIMETERS)**

DIMENSION MEASURED	226 CENTRALS		234 LATERALS	
	Average	Range	Average	Range
Crown length	8.8	6.3–11.6	9.4	7.3–12.6
Root length	12.6	7.7–17.9	13.5	9.4–18.1
Overall length	20.8	16.9–26.7	22.1	18.5–26.6
Crown width (mesiodistal)	5.3 narrowest adult crown	4.4–6.7	5.7	4.6–8.2
Root width (cervix)	3.5	2.7–4.6	3.8	3.0–4.9
Faciolingual crown size	5.7	4.8–6.8	6.1	5.2–7.4
Faciolingual root (cervix)	5.4	4.3–6.5	5.8	4.3–6.8
Mesial CEJ curve	2.0	1.0–3.3	2.1	1.0–3.6
Distal CEJ curve	1.6	0.6–2.8	1.5	0.8–2.4

- G. Inspection of 488 maxillary lateral incisors by Dr. Woelfel revealed 64% with no lingual accessory lingual ridges, 32% with one small accessory ridge, and only 4% with two ridges.
- H. The largest curvature of a proximal cervical line averages 2.8 mm on the mesial of a maxillary central incisor, and the distal curve is only 2.3 mm. The curvature of the mesial of the maxillary lateral incisor averages 2.5 mm or one fourth of the crown length.
- I. The crown of the maxillary central incisor averages 1.5 mm wider mesiodistally than faciolingually. The crown of the maxillary lateral incisor averages only 0.4 mm wider mesiodistally than faciolingually.
- J. The narrowest tooth in the mouth is the mandibular central incisor and averages only five-eighths, or 62% as wide as the maxillary central incisor.
- K. Dr. Woelfel found two shallow developmental depressions on 48% of 793 mandibular central incisors, and on 51% of 787 mandibular lateral incisors.
- L. The root-to-crown ratio for both types of mandibular incisors is 1.43 compared to 1.16 for the maxillary central incisor and 1.37 for the maxillary lateral.
- M. The curve of the CEJ on the mesial of the mandibular central incisor averaged 2.0 mm, which is 0.4 mm greater than on the distal. On the mandibular lateral incisor, the mesial CEJ curvature is 0.6 mm greater than the distal.
- N. The cervix of the root of the both types of mandibular incisor averages 2.0 mm wider faciolingually than mesiodistally.
- O. Both types of mandibular incisor crowns average 0.4 mm wider labiolingually than mesiodistally.

# Morphology of the Permanent Canines

Topics covered within the three sections of this chapter include the following:

- I. General description of canines
  - A. Functions
  - B. General characteristics or class traits (similarities) of canines (both maxillary and mandibular)
- II. Arch traits for canines: how to distinguish maxillary from mandibular canines (from each view)
  - A. Canines from the labial view
  - B. Canines from the lingual view
  - C. Canines from the proximal views
  - D. Canines from the incisal view
- III. Interesting facts and variations in canine teeth



As in Chapter 2, “Appendix” followed by a number and letter (e.g., “Appendix 3a”) refers to the page (number 3) and item (letter a) on that Appendix page. Tear out the appendix pages to facilitate study and minimize page turns as you read the main text. This chapter focuses on Appendix pages 3 and 4.

Also, remember that statistics obtained from Dr. Woelfel’s original research on canines have been used to draw conclusions throughout this chapter and are referenced with superscript letters like this (data<sup>A</sup>) that refer to data presented at the end of this chapter.

## SECTION I

## GENERAL DESCRIPTION OF CANINES

### OBJECTIVES

This section is designed to prepare the learner to perform the following:

- Describe the functions of canines.
- List the class traits that apply to all canines. Include the incisor class traits that also apply to the canines.

- From a selection of all permanent teeth (or from drawings or photographs of all teeth from various views), select and separate out the canines.

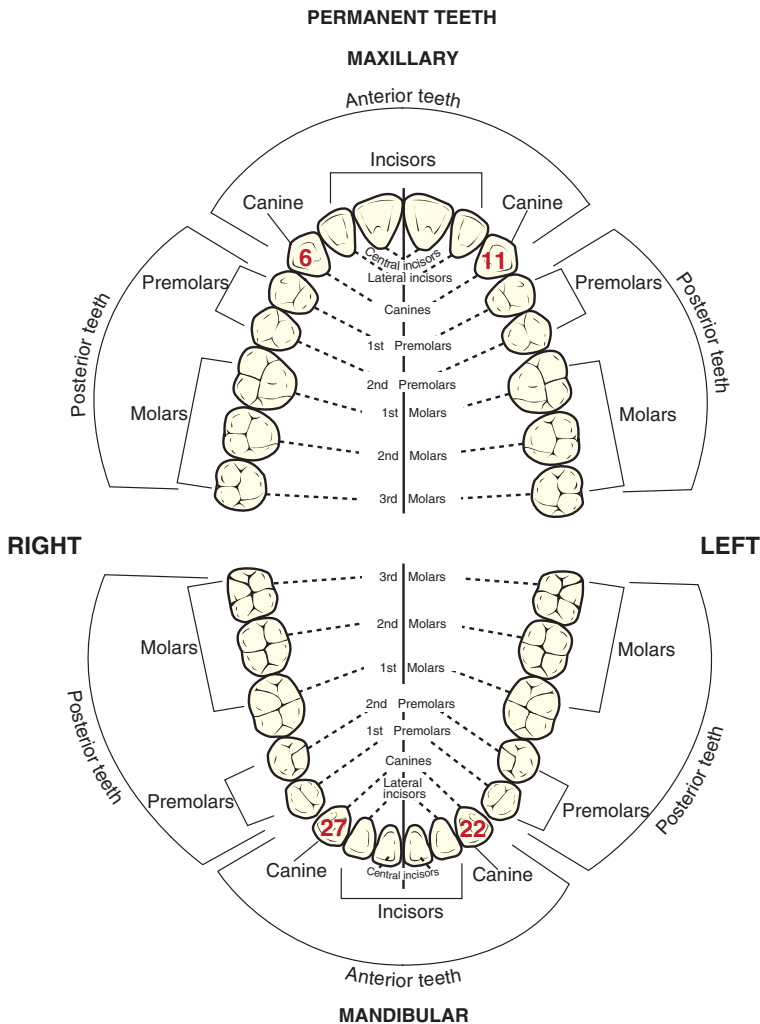
Use a cast of all permanent teeth and/or *Figure 3-1* while studying about the position of the canines within the arch. There are four canines: one on either side in the maxillary arch (Universal Numbers 6 and 11) and one on either side of the mandibular arch (Numbers 22 and 27). They are the longest of the permanent teeth.<sup>A</sup> The canines are distal to the lateral incisors and are the third teeth from the midline. The mesial surface of the canine is in contact with the distal surface of the lateral incisor. The distal surface of each canine contacts the mesial surface of the first premolar.

The four canines are justifiably considered cornerstones of the arches, as they are located at the corners of the mouth or dental arches. They are often referred to as cuspids, eyeteeth, and fangs (nicknames and slang terminology). The use of such slang terminology should be discouraged. Frequently, the canines are often the last teeth to be lost from dental disease (decay and/

or periodontal problems). Have you known or seen an elderly person who is edentulous (toothless), except for one or more of the canines?

### A. FUNCTIONS

In dogs, cats, and other animals with long, prominent canine teeth, the functions of these teeth are catching and tearing food and defense. As a matter of fact, *caninus* in Latin means “dog.” Canines are essential to their survival. In human beings, these teeth usually function with the incisors (a) to support the lips and the facial muscles and (b) to cut, pierce, or shear food morsels. A steep overlap of the maxillary and mandibular canines, when present, serves as (c) a protective mechanism since the longer, opposing canines ride up over each other when the mandible moves to either side, causing all of the posterior teeth to separate. This canine



**FIGURE 3-1.** Adult dentition with the **Universal numbers** for canines highlighted in red.

guidance relieves the premolars and molars from potentially damaging horizontal forces while chewing.

Canines, because of their large, long roots, are good anchor teeth (abutments) to attach replacements for lost teeth as with a fixed dental bridge or removable partial denture. As such, they often continue to function as a solid support for the replacement teeth for many years.

## **B. GENERAL CHARACTERISTICS OR CLASS TRAITS (SIMILARITIES) OF CANINES (BOTH MAXILLARY AND MANDIBULAR)**

Using the maxillary right canine as a representative example for all canines, refer to Appendix page 2 while studying the traits of all canines.

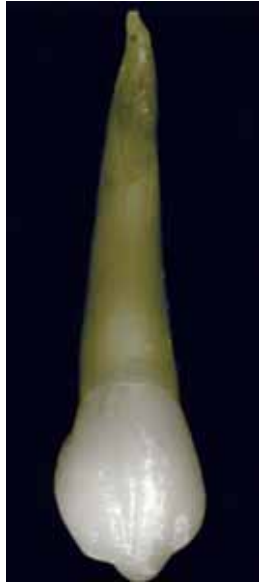### **1. SIZE OF CANINES**

On average, canines are the longest teeth in each arch, and the **maxillary canine** is the longest tooth in the mouth even though the mandibular canine crown is

longer than the maxillary canine crown. (Authors Ash and Kraus state that the mandibular canine crown is the longest crown in the mouth,<sup>1,2</sup> but Dr. Woelfel's study found that the maxillary incisor crown is longest.) Canines have particularly long roots<sup>A</sup> and thick roots (faciolingually) that help to anchor them securely in the alveolar process. Table 3-4 at the end of this chapter provides all canine dimensions.

### **2. INCISAL RIDGES AND CUSP TIPS OF CANINES**

The incisal ridges of a canine, rather than being nearly straight horizontally like on incisors, are divided into two inclines called the mesial and distal cusp ridges (also called cusp slopes or cusp arms). Subsequently, canine crowns from the facial view resemble a five-sided *pentagon* (Appendix 3a). The mesial cusp ridge is shorter than the distal cusp ridge (Appendix 3b). In older individuals, the lengths of the cusp ridges are often altered by wear (attrition). Canine teeth do not ordinarily have mamelons but may have a notch on either cusp ridge, as seen clearly in *Figure 3-2*.



**FIGURE 3-2.** Labial view of a maxillary right canine with a prominent labial ridge and notches on mesial and distal cusp ridges

### 3. LABIAL CONTOUR OF CANINES

The labial surface of a canine is prominently convex with a vertical labial ridge (Appendix 3c and Figure 3-2). Canines are the only teeth with a labial ridge, although premolars have a similar-looking ridge called a buccal ridge.

### 4. CROWN PROPORTIONS OF CANINES

The measurement of a maxillary or mandibular canine crown is greater labiolingually than it is mesiodistally<sup>B</sup> (Appendix 3d). Recall that this proportion (greater labiolingually than mesiodistally) also applied to both types of mandibular incisors. The root cervix measurements are even more oblong faciolingually.<sup>B</sup> (Compare the root widths on the facial and mesial views in Appendix 3i.)

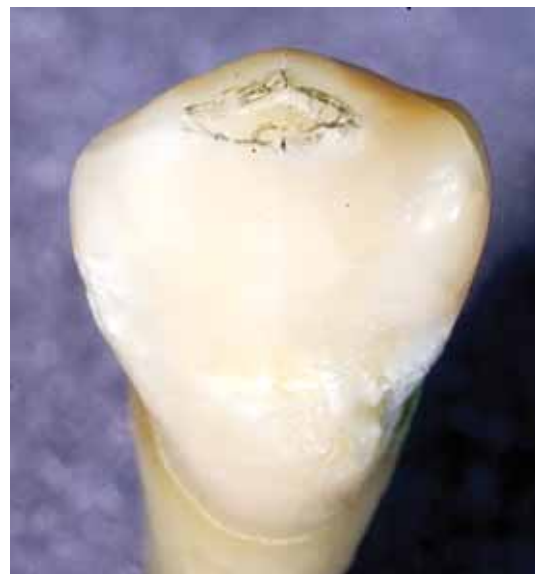### 5. CANINE TRAITS THAT ARE SIMILAR TO INCISOR TRAITS

Similar to most incisors (EXCEPT the mandibular central, where contacts are at the same level), the distal contact area is more cervical in position than the mesial contact area (Appendix 3g), and the crown outline is more convex on the distal than on the mesial surface (Appendix 3f). From the proximal views, canine crowns are wedge, or *triangular*, shaped (Appendix 3o). The height of contour on the facial surface is in the cervical third and on the lingual surface is also in the cervical third on the cingulum (Appendix 3p). The remaining outline of the lingual surface (lingual ridge) is slightly concave in the middle third and is straight or slightly convex in the incisal third. Combined, the entire

lingual outline is S shaped, as on all other anterior teeth (Appendix 3q).

Further similarities with incisors include the following: crowns taper, narrowing from the contact areas toward the cervix (Appendix 3e); cervical lines curve more on the mesial than on the distal surface (compare mesial and distal views in Appendix 3n); and marginal ridges (as well as crowns) taper lingually from the contact areas toward the cingulum (Appendix 3l), so the crown is narrower on the lingual half than on the facial half. From the incisal view, facial outlines are less convex than lingual outlines (Appendix 3s), and the incisal edges extend from mesial to distal contact areas (Appendix 3r). Further, roots taper narrower from the facial toward the lingual and taper narrower from the cervix toward the apex (Appendix 3h). The root tip or apex often bends toward the distal (Appendix 3j). Roots are also longer than crowns<sup>C</sup> (Appendix 3k).

The location of incisal edge tooth wear on canines is similar to wear on incisors. Facets on the mandibular canine cusp tip and cusp ridge normally form more on the labial border, not the lingual border of the cusp ridge as occurs on the maxillary canine. If you find wear facets on the lingual surface of a mandibular canine or on the labial surface of a maxillary canine, it is probably because the teeth were not aligned with the normal overlapping of anterior teeth described in Chapter 1. If needed, refer back to Figure 2-4 for an illustration of this concept on incisors. In addition, maxillary canines viewed incisally often have a characteristic diamond-shaped wear pattern as seen in Figure 3-3 which does not occur on other anterior teeth.



**FIGURE 3-3.** Maxillary canine (incisal view) showing a characteristic pattern of incisal wear that is diamond shaped.

SECTION II

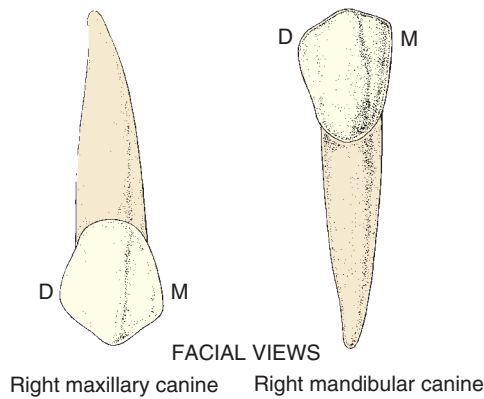
ARCH TRAITS FOR CANINES: HOW TO DISTINGUISH MAXILLARY FROM MANDIBULAR CANINES (FROM EACH VIEW)

OBJECTIVES

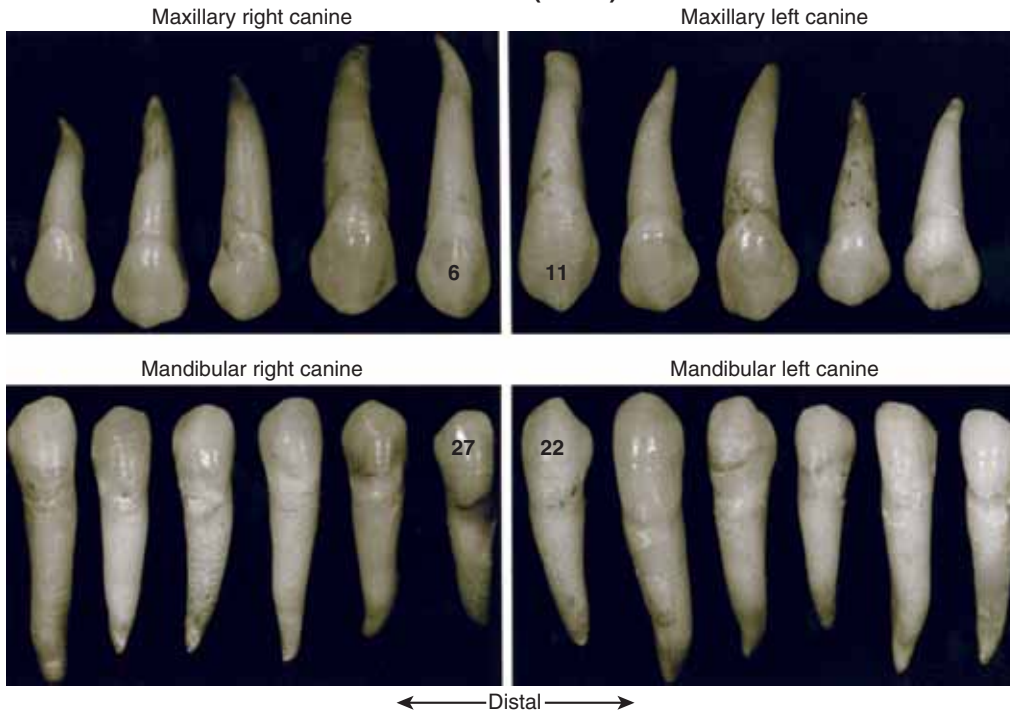
This section is designed to prepare the learner to perform the following:

- Describe the arch traits that can be used to distinguish the permanent maxillary canines from mandibular canines.
- Describe and identify the labial, lingual, mesial, distal, and incisal surfaces for all canines.

- Assign Universal numbers to canines present in a mouth with a complete permanent dentition (or on a model or in an illustration) based on their shape and position in the quadrant.
- Holding a canine, determine whether it is a maxillary or mandibular and whether it belongs on the right or left side. Then picture it within the appropriate quadrant and assign a Universal number to it.



CANINES (labial)



**FIGURE 3-4.** Labial views of canines with traits to distinguish maxillary from mandibular canines, and traits to distinguish rights from lefts.



**TRAITS TO DISTINGUISH MAXILLARY FROM MANDIBULAR CANINE: LABIAL VIEW****MAXILLARY CANINE**

Crown wider mesiodistally  
 Cusp angle sharper, more acute  
 Mesial cusp ridge shorter than distal

Mesial, distal proximal contacts more cervical  
 Mesial of crown bulges beyond root outline

More pronounced labial ridge  
 More pointed root tip

**MANDIBULAR CANINE**

Crown narrower mesiodistally  
 Cusp angle more blunt  
 Mesial cusp ridge *much* shorter than distal  
 Mesial cusp ridge almost horizontal  
 Mesial, distal proximal contacts more incisal  
 Mesial crown outline almost continuous with root with little or no bulge  
 Less pronounced labial ridge  
 More blunt root tip

**TRAITS TO DIFFERENTIATE MAXILLARY RIGHT FROM LEFT CANINE LABIAL VIEW****MAXILLARY CANINE**

Crown outline more convex on distal

**MANDIBULAR CANINE**

Crown outline more convex on distal, mesial crown outline aligns with root  
 Mesial cusp ridge almost horizontal

Distal crown outline is more convex than mesial crown outline.  
 Distal contact is more cervical than mesial contact.  
 Mesial cusp ridge is shorter than distal.

**FIGURE 3-4.** (Continued).

Unlike incisors where there are two types (a central and a lateral), there is only one type of canine. Therefore, type traits do not apply to canines, but arch traits are useful to distinguish maxillary from mandibular canines.

### **A. CANINES FROM THE LABIAL VIEW**

Examine several extracted canines and/or models as you study this section. As you examine them, hold maxillary canines with crowns down and mandibular canines with crowns up. This is the way they are oriented in the mouth.

#### **1. CANINE MORPHOLOGY FROM THE LABIAL VIEW**

Along with the tooth models and the Appendix pages 3 and 4 available, refer to *Figure 3-4* for viewing similarities and the range of differences of canines from the labial view.

The facial side of any canine crown is formed from three labial lobes like the incisors. (The cingulum on the lingual side of the crown forms from the fourth lobe.) The middle lobe on the facial forms the labial

ridge (Appendix 3c), which can be quite prominent on the **maxillary canine**. The labial ridge runs cervicoincisally near the center of the crown in the middle and incisal thirds. Shallow depressions lie mesial and distal to the labial ridge. See *Table 3-1* for a summary of the number of lobes that form canines.

The labial surface of a **mandibular canine** is more smooth and convex. A labial ridge is often present but not as pronounced as on the maxillary canines. In the incisal third, the labial crown surface is convex but slightly flattened mesial to the labial ridge and even a little more flattened distal to the ridge. (Feel it.)

#### **2. CANINE SHAPE AND SIZE FROM THE LABIAL VIEW**

The *mesial outline* of the **maxillary canine** crown is broadly convex in the middle third, becoming nearly flat in the cervical third (Appendix 4b). The outline of the *distal* portion of this crown forms a shallow S shape, being convex in the middle third (over the height of contour or proximal contact area) and slightly concave in the cervical third.

The **mandibular canine** crown appears longer and narrower than the crown of the maxillary canine<sup>D</sup>

(Appendix 4a). The *mesial* outline of the mandibular crown is almost flat to slightly convex, nearly in line with the mesial side of the root, and may not bulge or project beyond the mesial root outline (Appendix 4b). This conspicuous feature is quite evident in most mandibular canines in Figure 3-4 but is not seen on maxillary canines. The *distal* side of the crown may be slightly concave in the cervical third; it is convex in the incisal two thirds. There is noticeably more of the crown distal to the root axis line than mesial to it. This often makes the lower canine crown appear to be tilted or bent distally when the root is held in a vertical position (similar to the mandibular lateral incisor just mesial to it).

### 3. CANINE CUSP TIP AND INCISAL RIDGES FROM THE LABIAL VIEW

Recall that the mesial cusp ridges are normally shorter than the distal ridges for all canines. The cusp and cusp ridges of the **maxillary canine** make up nearly one third of the cervicoincisal length of the crown, because the angle formed by the cusp ridges is relatively sharp, slightly more than a right angle (105degrees) (Appendix 4c). Compare this to the cusp tip of the **mandibular canine**, where cusp ridges form a less sharp, more obtuse (blunt) angle (120degrees) (Appendix 4c). The mesial cusp ridge of the mandibular canine is also almost horizontal compared to its longer distal cusp ridge, which slopes more steeply in an apical direction. Shorter, more horizontal mesial cusp ridges are seen clearly on most mandibular canines in Figure 3-4. Wear on the incisal edge may alter the length of the cusp slopes, sometimes even completely obliterating the cusp, resulting in an appearance from the facial that is similar to an incisor.

### 4. CANINE PROXIMAL CONTACT AREAS FROM THE LABIAL VIEW

The *mesial* contact area of the **maxillary canine** is located at the junction of the incisal and middle thirds.

The *distal* contact area of the maxillary canine, like all anterior teeth, is in a more cervical location on the distal side than on the mesial side. It is located in the middle third, just cervical to the junction of the incisal and middle thirds (recall Appendix 3g). This is the only canine proximal contact area (mesial or distal) located in the middle third, and it is the most cervical contact of all anterior teeth.

The *mesial* contact area of the **mandibular canine** is in a more incisal position than on the maxillary canine due to its nearly horizontal mesial cusp ridge. It is in the incisal third just cervical to the mesioincisal angle. The *distal* contact area is, as expected, more cervical than the mesial, at the junction of the middle and incisal thirds. See Table 3-2 for a summary of the location of contact areas on canines.

### 5. CANINE TOOTH PROPORTIONS FROM THE LABIAL VIEW

The **maxillary canine** crown is nearly as long as the maxillary central incisor crown, but the root of the canine is much longer<sup>E</sup> making the maxillary canine, on average, the longest tooth in the mouth (Appendix 3k). The **mandibular canine** is considerably larger than either of the mandibular incisors, particularly in length and mesiodistal width.<sup>F</sup> It is, on average, the longest mandibular tooth.

### 6. CANINE ROOT CONTOUR FROM THE LABIAL VIEW

The labial surface of a canine root is normally convex. The root of the **maxillary canine** is long, slender, and conical. The apical third is narrow mesiodistally, and the apex may be pointed or sharp. The apical third of the root often bends distally (Appendix 3j).<sup>G</sup> Most maxillary canine roots in Figure 5-4 are seen bending distally.

The **mandibular canine** root tapers apically to a somewhat more blunt apex. The apical end of the root is more often straight rather than curving toward the mesial or distal surfaces.<sup>H</sup> Therefore, on mandibular

**Table 3-1** GUIDELINE FOR DETERMINING THE NUMBER OF LOBES FOR CANINES

TOOTH NAME	CINGULUM?	NO. OF LOBES
Maxillary canine	Yes	3 + 1 = 4
Mandibular canine	Yes	3 + 1 = 4

*Rule:* Number of lobes = 3 facial lobes + 1 lingual lobe per cingulum.

Table 3-2

### LOCATION OF PROXIMAL CONTACTS (PROXIMAL HEIGHT OF CONTOUR) ON CANINES (BEST SEEN FROM FACIAL VIEW)

	MESIAL SURFACE (WHICH THIRD OR JUNCTION?)	DISTAL SURFACE (WHICH THIRD OR JUNCTION?)
MAXILLARY CANINE CROWNS	Incisal/middle junction	Middle third (most cervical of anterior teeth)
MANDIBULAR CANINE CROWNS	Incisal third (just apical to mesioincisal angle)	Incisal/middle junction

General learning guidelines:

1. Distal proximal contacts for canines are more cervical than mesial contacts.
2. Contacts of most anterior teeth are in the incisal third or incisal/middle junction EXCEPT the *distal* of maxillary lateral incisors and distal of maxillary canines, which are in or near the middle third.

canines, the root curvature should not be used to differentiate rights and lefts. Mandibular canine roots are shorter than the roots of maxillary canines.<sup>1</sup>

## B. CANINES FROM THE LINGUAL VIEW

Refer to *Figure 3-5* while studying similarities and differences of canines from the lingual view.

### 1. CANINE LINGUAL RIDGES AND FOSSAE FROM THE LINGUAL VIEW

The **maxillary canine** has a prominent lingual ridge running cervicoincisally from the cusp to the cingulum (Appendix 4d). Mesial and distal lingual fossae lie on either side of the lingual ridge and are usually shallow. Sometimes the lingual surface of the maxillary canine is naturally smooth or worn smooth from attrition so that the lingual ridge and the two fossae on either side of it are not easily discernible.

With normal occlusion, the lingual surface of the **mandibular canine** is not subject to lingual wear as on the maxillary canine, but even without wear, the lingual ridge and fossae are normally less prominent.

### 2. CANINE CINGULUM FROM THE LINGUAL VIEW

The **maxillary canine** cingulum is large. Its incisal border is sometimes pointed in the center, resembling a small cusp or tubercle (seen in the far left maxillary

canine in Fig. 3-5). The cingulum and the tip of the cusp are usually centered mesiodistally (seen best from the incisal view in Appendix 4e). The cingulum of the **mandibular canine** is low, less bulky, and less prominent than on maxillary canines. Unlike maxillary canines, the cingulum lies just distal to the root axis line. This is most apparent from the incisal view in Appendix 4e. (Recall that the distal-to-midline location of the cingulum is also apparent on maxillary central incisors and mandibular lateral incisors.)

### 3. CANINE MARGINAL RIDGES FROM THE LINGUAL VIEW

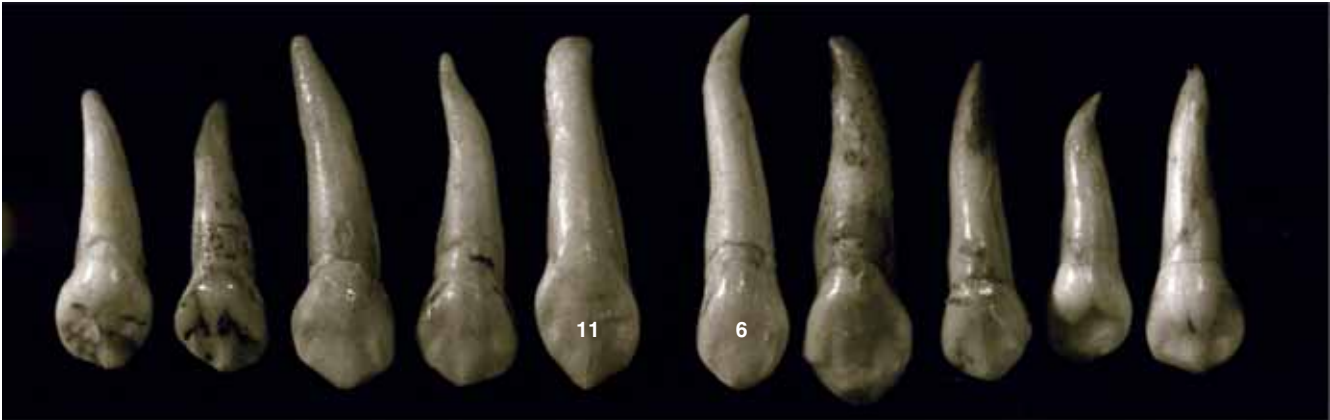The elevated mesial and distal marginal ridges of the **maxillary canines** are usually of moderate size. The lingual ridge is often most prominent, followed by the distal marginal ridge, and then the least prominent mesial marginal ridge (prior to attrition).<sup>J</sup> The mesial marginal ridge (extending from the proximal contact area to the cingulum) is longer than the distal marginal ridge because of the more incisally located mesial contact area.

The marginal ridges and lingual ridge of **mandibular canines** are not prominent, and much of the lingual surface appears smooth when compared to that of the maxillary canines (an arch trait). The somewhat inconspicuous mesial marginal ridge may be longer and straighter than the shorter, more elevated, and curved distal marginal ridge. The indistinct lingual ridge is seldom the most prominent ridge.<sup>K</sup>

**CANINES (lingual)**

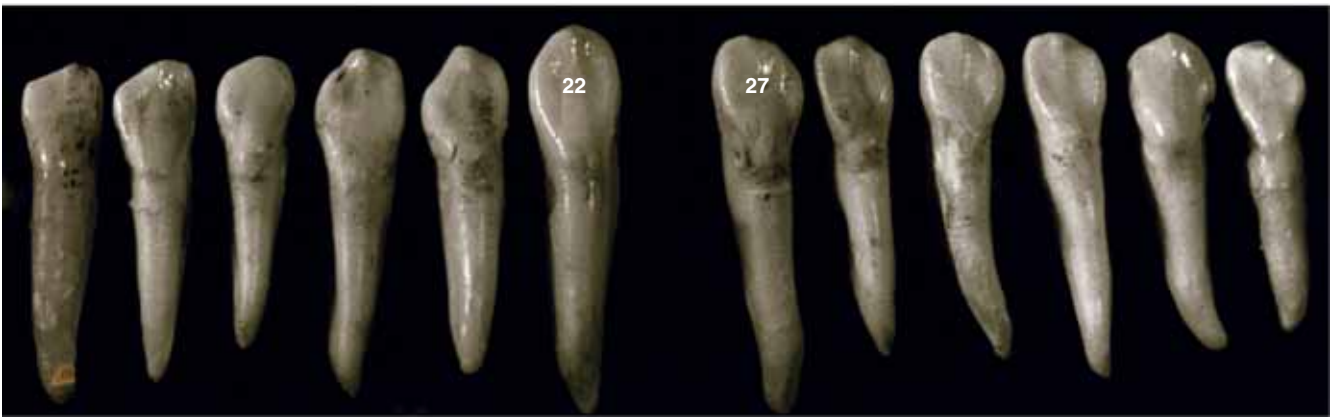Maxillary Left Canine

Maxillary right canine



Mandibular left canine

Mandibular right canine



← Distal →

**TRAITS TO DISTINGUISH MAXILLARY FROM MANDIBULAR CANINES: LINGUAL VIEW**

**MAXILLARY CANINE**

More prominent anatomy on lingual:  
 Lingual marginal ridges pronounced  
 Prominent lingual ridge and fossae  
 Cingulum centered

**MANDIBULAR CANINE**

Smoother lingual surface:  
 Lingual marginal ridges less pronounced  
 Less prominent lingual ridge and fossae  
 Cingulum centered or to distal

**TRAITS TO DIFFERENTIATE RIGHT FROM LEFT CANINES: LINGUAL VIEW**

**MAXILLARY CANINE**

**MANDIBULAR CANINE**

Mesial marginal ridge is longer than distal marginal ridge.  
 Cingulum distal to center

**FIGURE 3-5.** Lingual views of canines with traits to distinguish maxillary from mandibular canines, and traits to distinguish rights from lefts.

#### 4. CANINE ROOTS FROM THE LINGUAL VIEW

Maxillary and mandibular canine roots are usually convex on the lingual surface and are narrower mesiodistally on the lingual half than on the labial half. Therefore, it is often possible to see both mesial and distal sides of the root and one or both of the proximal longitudinal root depressions from this view.

### C. CANINES FROM THE PROXIMAL VIEWS

Refer to *Figure 3-6* while studying the similarities and differences of canines from the mesial or distal views.

#### 1. CANINE OUTLINE FROM THE PROXIMAL VIEWS

The wedge-shaped or triangular-shaped **maxillary canine** crown from this view has a bulky (thick) cusp because of the prominent labial and lingual ridges. The **mandibular canine** crown is also wedge shaped but thinner in the incisal portion than the crown of the maxillary canine because of a less bulky lingual ridge. Observe this difference in cusp thickness in most canines in *Figure 3-6*.

#### 2. INCISAL RIDGE AND CUSP TIP OF CANINES FROM THE PROXIMAL VIEWS

The incisal ridge and cusp tip of a **maxillary canine** are usually located *labial* to the mid-root axis line. The incisal ridge and cusp tip of the **mandibular canine** are most often located slightly *lingual* to the root axis line, but it may be *centered* over it (*Appendix 4h*). This is a good distinguishing trait between mandibular and maxillary canines. Observe this difference in cusp tip location (more labial on maxillary canines and more lingual on mandibular canines) in a majority of canines in *Figure 3-6*. Further, the distoincisor angle of the mandibular canine is slightly more lingual in position than the cusp tip because of the *distolingual twist* of the crown so that more of the lingual surface is visible from the mesial aspect, similar to the adjacent mandibular lateral incisors (best appreciated from the incisal view on *Appendix 4f*).

#### 3. CANINE HEIGHT OF CONTOUR FROM THE PROXIMAL VIEWS

As with all teeth, the *facial* height of contour of the **maxillary canine** is in the cervical third of the crown,

but it may not be as close to the cervical line as the corresponding curvature on the incisor teeth or on the mandibular canine. The labial surface is much more convex than on the incisors. (Feel it and compare the curvatures of the incisors and the canines.)

The height of contour of the *facial* surface of the **mandibular canine** crown is closer to the cervical line than on a maxillary canine. There is an almost continuous crown–root outline on mandibular canines with minimal facial or lingual (cingulum) crown bulge when viewed from the proximal aspects (*Fig. 3-7*). This lack of discernible cervical crown bulge beyond the root facially and lingually is clearly evident in many mandibular canines in *Figure 3-6*. This feature can be helpful when distinguishing mandibular from maxillary canines.

As with all anterior teeth, the *lingual* heights of contour of all canines are usually in the cervical third, on the cingulum.

#### 4. CANINE CERVICAL LINE FROM THE PROXIMAL VIEWS

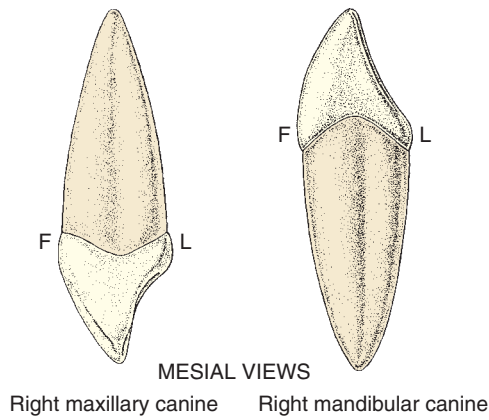
The cervical lines of all canines from the proximal views usually curve incisally quite a bit (over 2 mm on **maxillary canines**). As on incisors, the curvature for all canines is greater on the mesial surface than on the distal surface, but the difference is less on canines than on incisors.<sup>L,M</sup>

The cervical line on **mandibular canines** appears to curve more incisally than on maxillary canines. The fact that the mandibular canine crowns are narrower faciolingually than maxillary canines, and have a greater mesial cervical line curve, accentuates the apparent greater depth of the curve. However, the amount of curvature of the cervical lines of the mandibular canines varies considerably.

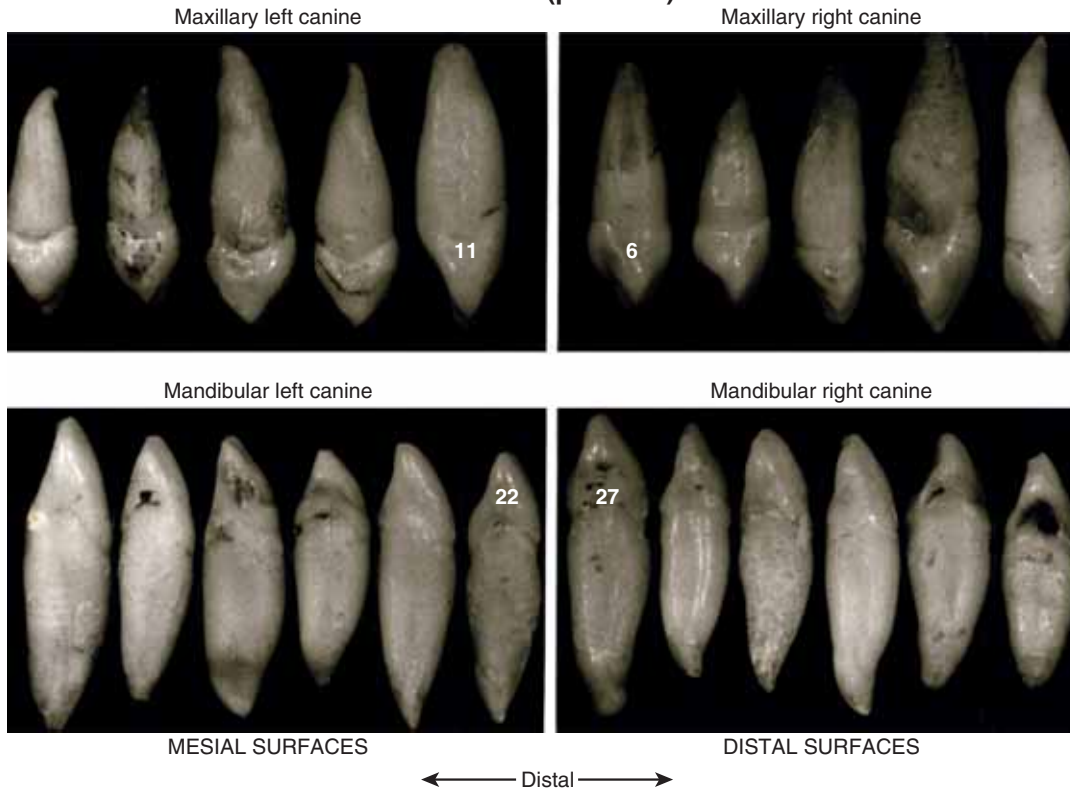
#### 5. CANINE ROOT SHAPE AND DEPRESSIONS FROM THE PROXIMAL VIEWS

The *labial outlines* of the roots of maxillary and mandibular canines are often slightly convex with the lingual outline more convex, although this varies. *Both* maxillary and mandibular canine roots most often have vertical longitudinal (cervicoapical) depressions on the mesial and distal surfaces, and the distal depressions are usually more distinct (deeper), especially on the lowers.<sup>N</sup> A summary of the location and relative depth of root depressions on canines is presented in *Table 3-3*.





**CANINES (proximal)**



**TRAITS TO DISTINGUISH MAXILLARY FROM MANDIBULAR CANINES: PROXIMAL VIEWS**

**MAXILLARY CANINE**

- Cingulum more prominent
- Cusp tip labial to root axis line
- Labial height of contour less cervical
- Labial height of contour more pronounced

- Incisal wear is more lingual, even in fossae
- Cusp tip appears thicker faciolingually

**MANDIBULAR CANINE**

- Cingulum less prominent
- Cusp tip lingual to root axis line
- Labial height of contour closer to cervical line
- Labial height of contour less pronounced, almost continuous with root

- Incisal wear more labial
- Cusp tip appears less thick faciolingually

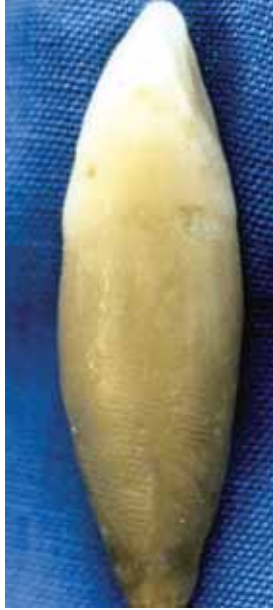**TRAITS TO DIFFERENTIATE RIGHT FROM LEFT CANINES: COMPARING PROXIMAL VIEWS**

**MAXILLARY CANINE**

**MANDIBULAR CANINE**

- Cervical line curves more on the mesial than distal surface
- Distal root depression is more distinct than mesial

**FIGURE 3-6.** Proximal views of canines with traits to distinguish maxillary from mandibular canines and traits to distinguish rights from lefts.



**FIGURE 3-7.** Proximal view of a mandibular canine showing the **minimal** amount of facial or lingual **cervical bulge** of the crown outline beyond the root outline.

## D. CANINES FROM THE INCISAL VIEW

Refer to *Figure 3-8* for a comparison of similarities and differences of canines from the incisal view. To follow this description, the tooth should be held so that the incisal edge (cusp tip) is toward the observer, the labial surface is at the top, and the observer is looking exactly down the mid-root axis line. You should see more of the lingual surface of the maxillary canine since the cusp tip and the cusp ridges are usually labial to the mid-root axis line, and you should see more of the labial surface of mandibular canines where the cusp ridges are lingual to the mid-root axis line, as seen on most canines in *Figure 3-8*.

## 1. CANINE CROWN PROPORTIONS FROM THE INCISAL VIEW

The **maxillary canine** crown outline is not symmetrical. The faciolingual dimension of the maxillary canine crown is slightly greater than the mesiodistal dimension (recall Appendix 3d). This is similar to the mandibular anterior teeth but uncharacteristic of the maxillary incisors, which are usually wider mesiodistally than faciolingually. The labiolingual dimension of the **mandibular canine** crown is also greater than the mesiodistal measurement even more noticeably than on maxillary canines.<sup>o</sup> This characteristic oblong faciolingual outline is seen on many mandibular canines in *Figure 3-8*.

## 2. CANINE INCISAL EDGE (CUSP TIP) CONTOUR FROM THE INCISAL VIEW

The incisal edge (made up of the cusp tip and thick mesial and distal cusp ridges) of the **maxillary canine** is located slightly labial to the labiolingual center of the root, and this edge is aligned almost horizontally (*Appendix 4f*).

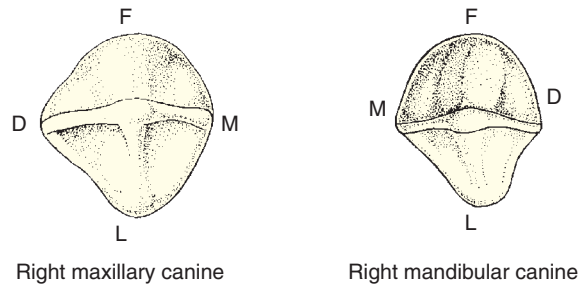
The cusp tip of the **mandibular canine** is near the center labiolingually, or it may be lingual to the center. When the tooth is held with the faciolingual axis of the cervix of the root exactly vertical, the distal cusp ridge is directed slightly lingually from the cusp tip, placing the distoincisor angle in a position somewhat lingual to the position of the cusp tip (*Appendix 4f*). This lingual placement of the distoincisor angle gives the incisal part of the crown a slight *distolingual twist* (similar to the adjacent mandibular lateral incisor and to the maxillary central incisor). From this view, the distolingual twist of the crown appears to “bend” to follow the curvature of the dental arch.

**Table 3-3 PRESENCE AND RELATIVE DEPTH OF LONGITUDINAL ROOT DEPRESSIONS**

	MESIAL ROOT DEPRESSION?	DISTAL ROOT DEPRESSION?
MAXILLARY CANINE TEETH	Yes	Yes (deeper)
MANDIBULAR CANINE TEETH	Yes	Yes (deeper)

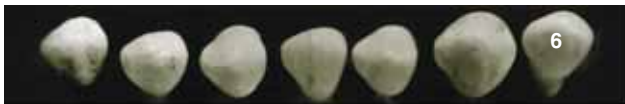General learning guidelines:

1. Canines have root depression on mesial *and* distal surfaces.
2. Canines are likely to have deeper distal surface root depressions.



### CANINES (incisal)

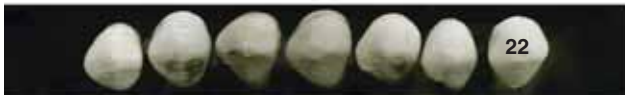Maxillary right canine



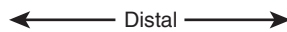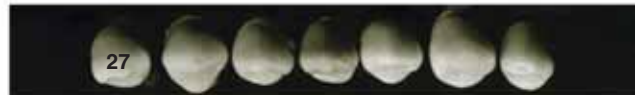Maxillary left canine



Mandibular left canine



Mandibular right canine



### TRAITS TO DISTINGUISH MAXILLARY FROM MANDIBULAR CANINES: INCISAL VIEW

#### MAXILLARY CANINE

More asymmetrical crown outline  
Slightly greater faciolingually than mesiodistally  
Distal half of crown pinched in faciolingually  
Cingulum centered  
Incisal edge more horizontal mesiodistally  
Facets on lingual-incisal or lingual surface

#### MANDIBULAR CANINE

More symmetrical crown outline  
Much greater faciolingually than mesiodistally  
Distal crown faciolingual pinch not as evident  
Cingulum to distal (or centered)  
Incisal edge with distolingual twist  
Facets on labial-incisal of cusp ridge

### TRAITS TO DIFFERENTIATE RIGHT FROM LEFT CANINES: INCISAL VIEW

#### MAXILLARY CANINE

More faciolingual bulk in mesial half  
  
Distal half of crown pinched faciolingually

#### MANDIBULAR CANINE

Cingulum often to distal  
Incisal ridge more lingual on distal half  
Distal half of crown less likely pinched faciolingually

**FIGURE 3-8.**

**Incisal views** of canines with traits to distinguish maxillary from mandibular canines and traits to distinguish rights from lefts.

### 3. CANINE CINGULUM AND MARGINAL RIDGES FROM THE INCISAL VIEW

The **maxillary canine** cingulum is large and is located in the center mesiodistally (Appendix 4e). On the lingual outline of the **mandibular canine**, the height (crest) of contour of the cingulum is centered or slightly distal to the centerline (Appendix 4e).

### 4. CANINE LABIAL CONTOUR FROM THE INCISAL VIEW

The labial outline of the **maxillary canine** is convex, more than either type of maxillary incisor, since the labial ridge is often quite prominent. The mesial half of the labial outline is quite convex, whereas the distal half of the labial outline is frequently somewhat concave, giving this *distal* portion of the crown the appearance that

it has been “*pinched in*” on the facial surface (Appendix 4g). This observation is most helpful and is a reliable guide in determining right from left maxillary canines and is seen on many upper canines in Figure 3-8.

The outline of the **mandibular canine** crown is more symmetrical than that of a maxillary canine crown. However, the labial crown outline mesial to the centerline is noticeably more convex, whereas the labial outline distal to the center is more flat.

## 5. CANINE LINGUAL CONTOUR FROM THE INCISAL VIEW

The lingual ridge of the **maxillary canine** divides the lingual surface in half with a shallow fossa on each side. This ridge and fossae are less evident on the **mandibular canine**.

### LEARNING EXERCISE

Assign a Universal number to a handheld tooth:

A patient just had all of his permanent teeth extracted. Imagine being asked to find tooth No. 6 from among a pile of 32 extracted teeth on the oral surgeon’s tray because you want to evaluate a lesion on the root of that canine. How might you go about it? Try the following steps:

- From a number of extracted teeth or tooth models, select the canines based on **class traits**.

### Learning Exercise, cont.

- Determine whether the canine is maxillary or mandibular. You should never rely on only one characteristic difference between teeth to name them; rather, make a list of many **arch traits** that suggest the tooth is a maxillary canine as opposed to only one trait that makes you think it belongs in the mandible. Refer to the arch traits in Figures 3-4 through 3-8 as needed.
- If you determine that the tooth is maxillary, position the root up; if it is mandibular, position the root down.
- With the tooth aligned correctly, use characteristic traits for each surface to identify the facial surface. This will permit you to view the tooth as though you were looking into a patient’s mouth.
- Finally, determine which surface is the mesial. (Refer to the right/left traits in Figs. 3-4 through 3-8 as needed.) While viewing the tooth from the facial and picturing it within the appropriate arch (upper or lower), the mesial surface can be positioned toward the midline in only one quadrant, the right or left.
- Once you have determined the quadrant, assign the appropriate Universal number for the canine in that quadrant. For example, the canine in the upper right quadrant is tooth No. 6.

## SECTION III

## INTERESTING FACTS AND VARIATIONS IN CANINE TEETH

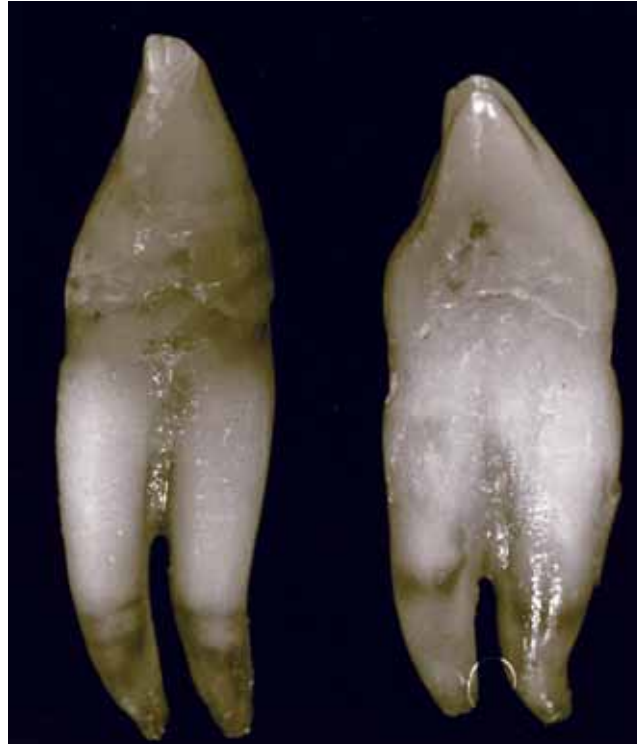The name *canine* is of Greek origin and is found in the writings of Hippocrates and Aristotle of 2350 years ago. Aristotle first described canine anatomy, stressing the intermediate nature of it between incisors and molars. Celsus was the first writer to mention the roots of teeth, saying the canine was monoradicular (that is, normally having one root).<sup>3,4</sup>

Probably the most conspicuous variation in canine teeth is found in the **mandibular canine**. For example, although it is rare to find a mandibular canine tooth with the *root divided*, this division is known to occur. The division results in labial and lingual roots and may be split only in the apical third, or it may extend into the cervical third of the root (Fig. 3-9).

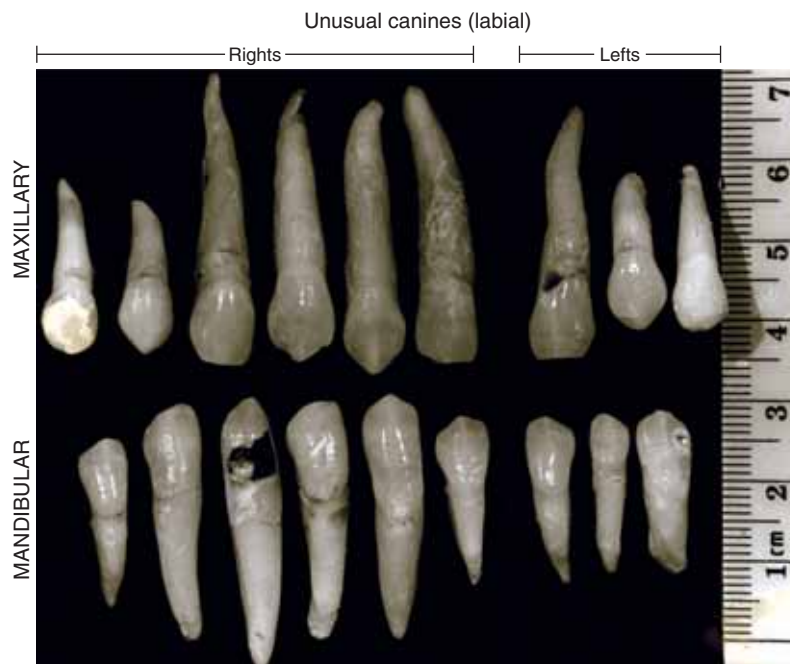
Observe the enormous variation in size and shape among several maxillary and mandibular canines in Figure 3-10.<sup>p</sup>

A maxillary canine with an unusual notch on its mesial cusp slope is seen in Figure 3-11. An unusual canine with a shovel-shaped lingual surface is evident in Figure 3-12. Other anomalies will be described in Chapter 11.

Perhaps the most unique canines of all occur on the male Babirusa (type of wild boar) seen in Figure 3-13. Its two enormous maxillary canines curve backward, piercing the bony snout on each side. Then, they curve in a large arc upward, backward, and finally down toward the forehead. These unusual maxillary canines serve only to protect the boar’s eyes and upper face. The Babirusa’s mandibular canines are also very large and tusk-like, and curve up and back, possibly serving to protect the side of his face and for fighting or piercing food when his jaw is opened wide.

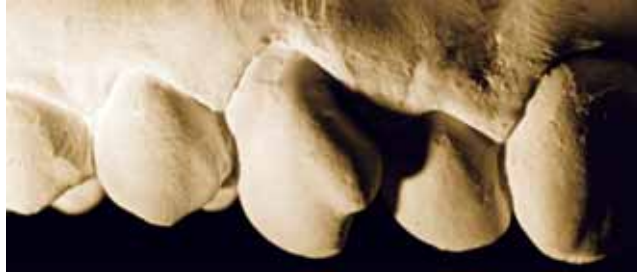

**FIGURE 3-9.** Two unusual **mandibular canines**, each with a **split (bifurcated) root** that has a facial and lingual root tip.

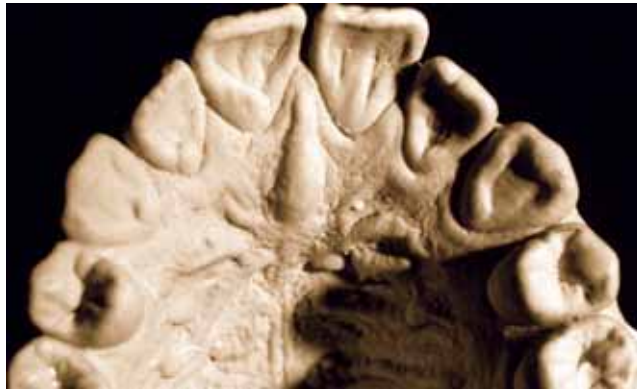


**FIGURE 3-10.** Canines of **differing size** showing tremendous variation.

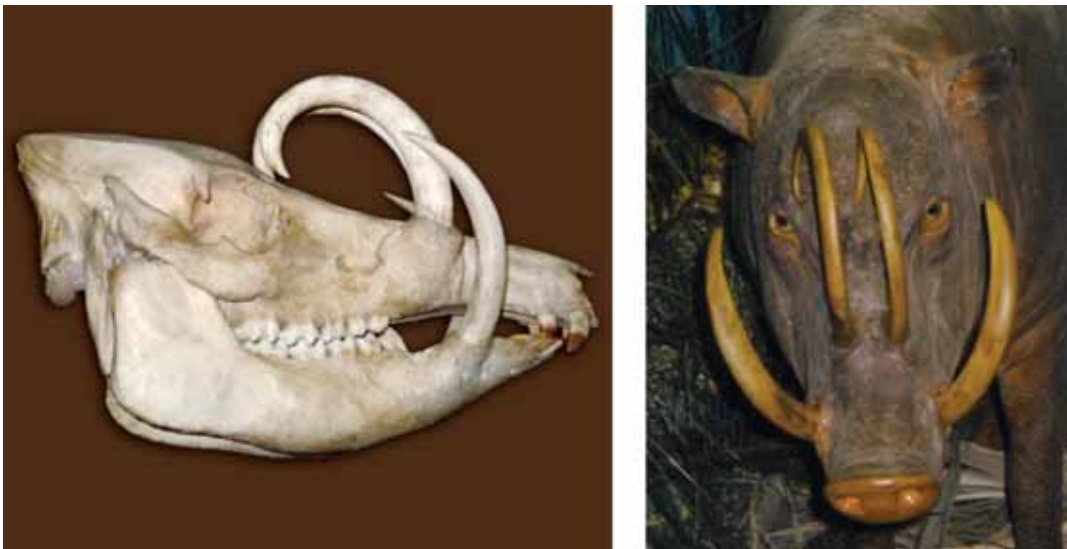



**FIGURE 3-11.** Maxillary right canine with a deep **notch** in the mesial cusp ridge.



**FIGURE 3-12.** Maxillary left canine (*arrow*) with **shovel-shaped** lingual anatomy (very prominent marginal ridges).



**FIGURE 3-13.** A male Babirusa (type of wild boar) with extremely unique canines that actually pierce the upper lip and bony snout on each side.

## Review Questions

For each trait described below, indicate the letter of the best response from the five selections provided. Each trait has only one best answer.

- a. Maxillary central incisor
- b. Maxillary canine
- c. Mandibular canine
- d. All of the above
- e. None of the above

1. This tooth exhibits less cervical line curvature on the distal aspect than on the mesial aspect. a b c d e
2. The cingulum is centered mesiodistally. a b c d e
3. There is an almost continuous crown–root outline on the mesial surface of this tooth. a b c d e
4. The mesial contact area is located more incisally than the distal contact area on the same tooth. a b c d e
5. The cusp tip is positioned lingual to the mid-root axis line from the proximal view. a b c d e
6. Mamelons could be observed on this tooth. a b c d e
7. On which tooth is the cusp angle most acute? a b c d e
8. The mesiodistal width of this tooth is greater than its labiolingual width. a b c d e
9. The mesial and distal marginal ridges are aligned more vertically than horizontally on the lingual surface. a b c d e
10. The teeth (tooth) develop(s) from four lobes. a b c d e
11. The teeth (tooth) develop(s) from three lobes. a b c d e

**ANSWERS:** 1—d; 2—b; 3—c; 4—d; 5—c; 6—a; 7—b; 8—b; 9—d; 10—d; 11—e

## Critical Thinking

1. While viewing a model or a picture of the facial surface of a mandibular left canine, list as many traits as possible that you can use to identify the mesial versus distal half of an intact, extracted **MANDIBULAR LEFT CANINE when viewing its FACIAL surface**, but instead of using the terms mesial or distal, use the terms right or left. For example, when viewed from the facial, a mandibular left canine has a shorter cusp ridge on the left half (which is the mesial half for this view), and a longer cusp ridge on the right half (which is the distal half).
2. Repeat this exercise when viewing the **LINGUAL VIEW** of the **MAXILLARY RIGHT CANINE**.

## REFERENCES

1. Ash MM, Nelson SJ. Wheeler's Dental Anatomy, Physiology and Occlusion. Philadelphia, PA: Saunders, 2003.
2. Kraus RE, Abrams L. Kraus' Dental Anatomy and Occlusion. Oxford: Wolfe Publishing Ltd, 1992.
3. Cootjans G. The cuspid in Greaco-Latin literature. Rev Belge Med Dent 1971;26(3):387–392.
4. Year Book of Dentistry. Chicago: Year Book Medical Publishers, 1973:354.

## GENERAL REFERENCES

- Taylor RMS. Variations in form of human teeth: II. An anthropologic and forensic study of maxillary canines. J Dent Res 1969;48:173–182.
- Web site: [http://animaldiversity.ummz.umich.edu/site/topics/mammal\\_anatomy/gallery\\_of\\_canines.html](http://animaldiversity.ummz.umich.edu/site/topics/mammal_anatomy/gallery_of_canines.html)—University of Michigan Museum of Zoology Animal Diversity Web Gallery of Canines



## Dr. Woelfel's Original Research Data

Statistics obtained from Dr. Woelfel's original research on teeth have been used to draw conclusions throughout this chapter and were referenced with superscript letters that refer to the data stated here. *Table 3-4* has the data for canines from the original research by Dr. Woelfel.

- A. Maxillary canines averaged 26.3 mm long, and mandibular canines averaged 25.9 mm long. Canine roots averaged 16.2 mm long.
- B. Based on 637 teeth, maxillary canine crowns averaged longer faciolingually than mesiodistally by 0.5 mm, and for mandibular canines, by 0.9 mm. At the cervix of the root, this difference was 2.0 mm on maxillary canines and 2.3 mm on mandibular canines.
- C. The root-to-crown ratio on maxillary canines averaged 1.56, and for mandibular canines, averaged 1.45.
- D. The mandibular canine crown averaged 0.4 mm longer and 0.8 mm narrower than the maxillary canine crown based on averages from 637 teeth.
- E. The root of the maxillary canine averaged 3.5 mm longer than the root of the maxillary central incisor based on 719 teeth.
- F. The mandibular canine averaged 4.4 mm longer than the mandibular incisors and 1.3 mm wider mesiodistally.
- G. On 100 maxillary canine roots examined by Dr. Woelfel, 58% bent distally, 24% were straight, and 18% had the apical end of their roots bending slightly toward the mesial.
- H. On 100 mandibular canines inspected by Dr. Woelfel, 45% had absolutely straight roots, 29% had the apical third bending mesially, and 26% bent slightly toward the distal.

Table 3-4

## SIZE OF CANINES (MEASURED BY DR. WOELFEL AND HIS DENTAL HYGIENE STUDENTS, 1974–1979)

DIMENSION MEASURED	321 MAXILLARY CANINES		316 MANDIBULAR CANINES	
	Average (mm)	Range (mm)	Average (mm)	Range (mm)
Crown length	10.6	8.2–13.6	11.0 <sup>a</sup>	6.8–16.4
Root length	16.5 longest root in mouth	10.8–28.5	15.9	9.5–22.2
Overall length	26.4 longest tooth in mouth	20.0–38.4	25.9	16.1–34.5
Crown width (mesiodistal)	7.6	6.3–9.5	6.8	5.7–8.6
Root width (cervix)	5.6	3.6–7.3	5.2	4.1–6.4
Faciolingual crown size	8.1	6.7–10.7	7.7	6.4–9.5
Faciolingual root (cervix)	7.6	6.1–10.4	7.5	5.8–9.4
Mesial cervical curve	2.1	0.3–4.0	2.4	0.2–4.8
Distal cervical curve	1.4	0.2–3.5	1.6	0.2–3.5

<sup>a</sup>Kraus and Ash call this the longest crown in the mouth.

- I. Based on 637 teeth, maxillary canine roots averaged 0.6 mm longer than mandibular canine roots.
- J. Dr. Woelfel's dental hygiene students inspected 455 maxillary canines on dental stone casts. The lingual ridge was found to be the most elevated of the three lingual ridges 46% of the time, the distal ridge was most elevated 36% of the time, and the mesial marginal ridge was most elevated only 18% of the time.
- K. Of 244 mandibular canines on dental stone casts inspected by dental hygiene students, the distal marginal ridge was the most prominent of the three lingual ridges on 63% of the teeth and the mesial marginal ridge was the most prominent on only 18%. The lingual ridge was most prominent only on 19% of these unworn lingual surfaces.
- L. Of the 321 maxillary canines measured by Dr. Woelfel's dental hygiene students, the mesial CEJ (cemento-enamel junction) curvature averaged 2.1 mm, with a range from 0.3 to 4.0 mm; the distal CEJ curvature averaged 1.4 mm, with a range of 0.2 to 3.5 mm. Such wide variability is not unusual.
- M. Based on 637 canines, mandibular canine crowns average 0.4 mm narrower faciolingually than maxillary canine crowns. Cervical line curves on mandibular canines varied from 0.2 mm (almost flat) to 4.8 mm. Based on 316 mandibular canines, the mesial curvature averaged 2.4 mm while the distal curve averaged only 1.6 mm making the curve 0.8 mm less on the distal surface.
- N. Based on 100 maxillary canines examined by Dr. Woelfel, 70% had a longitudinal depression on the mesial root surface (six fairly deep), 23% were flat, and only 8% had convex mesial middle third root surfaces with no depression. On the distal, 90% had a longitudinal depression on the distal surface (20% were rather deep), and only 10% had no distal root depression. On 100 mandibular canines examined, 88% had a longitudinal mesial root depression (28% were fairly deep), 8% were flat, and 4% were considered to be convex. On the distal, 97% had a longitudinal depression on the distal surface (40% were fairly deep), and only 3% had flat distal root surfaces. None of the distal root surfaces was judged to be convex on the middle third of the root.
- O. Based on 316 teeth, the crown of the maxillary canine averages 0.5 mm longer faciolingually than mesiodistally, and the crown of the mandibular canine averages 0.9 mm wider faciolingually than mesiodistally.
- P. Referring to the measurements of 637 canines in Table 3-4 under the range column, maxillary canine crowns from shortest to longest varied by 5.4 mm, root length differed by 17.7 mm, and overall length differed by 18.4 mm. In the 1962 issue of the *Journal of the North Carolina Dental Society* (46:10), there was a report of an extraction, without incident, of a maxillary left canine 47 mm long. On mandibular canines, crown length, root length, and overall length ranges varied by 9.6, 12.7, and 18.4 mm, respectively. Can you imagine one mandibular canine with a crown 9.6 mm longer than another one? The shortest mandibular canine (cusp tip to root apex) was only 16.1 mm long. Two of the mandibular canine crowns in Figure 3-10 are that long. See if you can spot these teeth.

## Morphology of Premolars

Topics covered within the three sections of this chapter include the following:

- I. Overview of premolars
  - A. General description of premolars
  - B. Functions of premolars
  - C. Class traits of premolars (including traits similar to anterior teeth)
  - D. Arch traits that differentiate maxillary from mandibular premolars
- II. Type traits that differentiate maxillary first from maxillary second premolars
  - A. Type traits of maxillary premolars from the buccal view
  - B. Type traits of maxillary premolars from the lingual view
  - C. Type traits of maxillary premolars from the proximal views
  - D. Type traits of maxillary premolars from the occlusal view
- III. Type traits that differentiate mandibular first from mandibular second premolars
  - A. Type traits of mandibular premolars from the buccal view
  - B. Type traits of mandibular premolars from the lingual view
  - C. Type traits of mandibular premolars from the proximal views
  - D. Type traits of mandibular premolars from the occlusal view

### SECTION I

### OVERVIEW OF PREMOLARS

#### OBJECTIVES

This section is designed to prepare the learner to perform the following:

- Describe the functions of premolars.
- List class traits common to all premolars.
- List arch traits that can be used to distinguish maxillary from mandibular premolars.
- From a selection of all teeth, select and separate out the premolars.
- Divide a selection of all premolars into maxillary and mandibular.

Using the maxillary right second premolar as a representative example for all premolars, refer to the Appendix, pages 5 and 6, while reading this chapter. Throughout this chapter, “Appendix” followed by a number and letter (e.g., Appendix 5a) is used to denote reference to the page (number 5) and item (letter a) being referred to on that appendix page. Tear out the appendix to facilitate study and minimize page turns.

Also, remember that statistics obtained from Dr. Woelfel’s original research on teeth have been used to draw conclusions throughout this chapter and are referenced with superscript letters like this (data<sup>A</sup>) that refer to data presented at the end of this chapter.

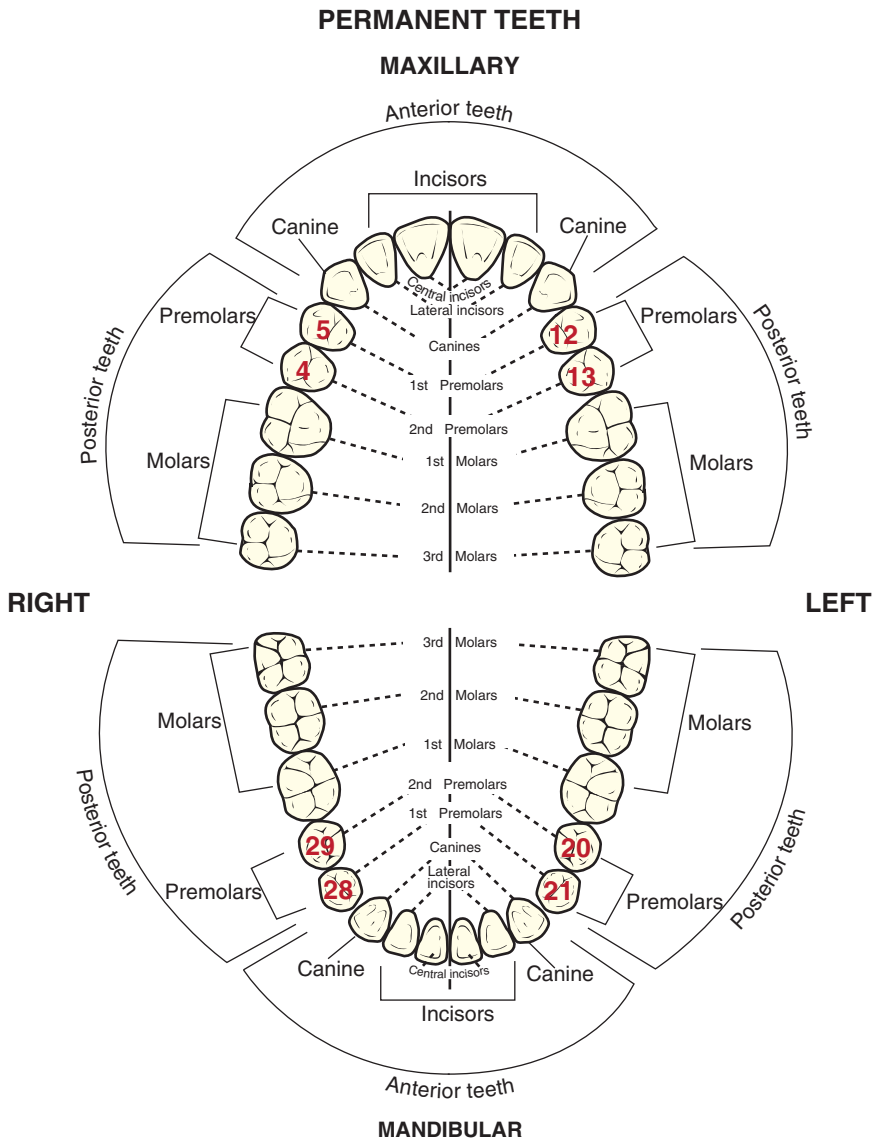
#### A. GENERAL DESCRIPTION OF PREMOLARS

The term premolar is used to designate the teeth in the permanent (secondary) dentition of mammals

that are positioned just in front of molars (and posterior to canines). There are eight premolars: four in the maxillary arch and four in the mandibular arch (Fig. 4-1). They are the fourth and fifth teeth from the midline in each quadrant. Maxillary premolars can be identified by the Universal Numbering System as teeth Numbers 5 and 12 (maxillary right and left first premolars, respectively) and Numbers 4 and 13 (maxillary right and left second premolars, respectively). The mandibular right and left first premolars are Numbers 28 and 21, respectively, with the mandibular right and left second premolars Numbers 29 and 20, respectively.

The mesial surfaces of first premolars contact the distal surfaces of adjacent canines, whereas distal surfaces contact the mesial surfaces of adjacent second premolars. The distal surfaces of second premolars are in contact with the mesial surfaces of adjacent first molars.





**FIGURE 4-1.** Adult dentition with the **Universal numbers** for premolars highlighted in red.

## B. FUNCTIONS OF PREMOLARS

Premolars (upper and lower) function with molars (a) to masticate food and (b) to maintain the vertical dimension of the face (between the nose and chin). First premolars (c) assist the canines in shearing or cutting food morsels, and all premolars (d) support the corners of the mouth and cheeks to keep them from sagging. This is more discernible in older people. Patients who unfortunately have lost all of their molars can still masticate or chew adequately if they still have four to eight occluding premolars. However, it is very noticeable when a person smiles if one or more maxillary premolars are missing.

## C. CLASS TRAITS OF PREMOLARS

### 1. CLASS TRAITS SIMILAR TO ANTERIOR TEETH

Consider first the similarities between premolars and anterior teeth by examining models of the entire maxillary and mandibular arches as you read the following:

**Number of Developmental Lobes:** Like anterior teeth, the facial surfaces of all premolars develop from three facial lobes, usually evidenced by two shallow, vertical depressions separating a buccal ridge on the facial surface of the crown from the mesial and distal portions (Appendix 5a). This centered buccal ridge is more conspicuous on first than second premolars, and

**Table 4-1** GUIDELINE FOR DETERMINING THE NUMBER OF LOBES FOR PREMOLARS<sup>a</sup>

TOOTH NAME	NO. OF CUSPS	NO. OF LOBES
Maxillary first premolar	1 facial and 1 lingual	3 + 1 = 4
Maxillary second premolar	1 facial and 1 lingual	3 + 1 = 4
Mandibular first premolar	1 facial and 1 lingual	3 + 1 = 4
Mandibular second premolar, two-cusp type	1 facial and 1 lingual	3 + 1 = 4
Mandibular second premolar, three-cusp type	1 facial and 2 lingual	3 + 2 = 5

<sup>a</sup>Number of lobes = 3 facial lobes form the facial cusp + 1 lobe per each lingual cusp.

is more pronounced on maxillary than mandibular premolars. The prominent buccal ridge on the maxillary first premolar is similar to the pronounced labial ridge on the maxillary canine. Also, the lingual surfaces of most premolars (like anterior teeth) develop from one lingual lobe. In premolars, this lobe forms one lingual cusp; in anterior teeth, it forms the cingulum (recall Fig. 1-45). An EXCEPTION occurs in a common variation of the mandibular second premolar, the three-cusp type, which develops from three facial and two (not one) lingual lobes, forming two lingual cusps. Due to this variation of the mandibular second premolar with three cusps, the term bicuspid (referring to two cusps) is hardly appropriate for this group of teeth. See Table 4-1 for a summary of the number of lobes forming each type of premolar.

**Crowns Taper Toward the Cervical:** From the facial, crowns are narrower in the cervical third than occlusally (Appendix 5m). This is because the widest proximal heights (crests) of contour (or contact areas) are located in the occlusal to middle thirds on posterior

teeth (similar to the location on anterior teeth in the incisal to middle thirds).

**Cervical Lines:** Similar to all anterior teeth, cervical lines, when viewed from the proximal, curve toward the biting surfaces (occlusal or incisal) (Appendix 5o), and the amount of curvature is slightly greater on the mesial than on the distal surface. When viewed from the facial or lingual, cervical lines are curved toward the apex (Appendix 5n).

**Root Shape:** Like on anterior teeth, premolar roots have convex facial and lingual root surfaces, and taper apically (Appendix 5q). Also, the root tapers toward the lingual, resulting in a narrower lingual side of the root mesiodistally. The apical third is most often bent distally (Appendix 5p). Notice the similarities in root and crown taper and cervical line curvature on incisors, canines, and premolars when the incisal/occlusal third has been removed in Figure 4-2.

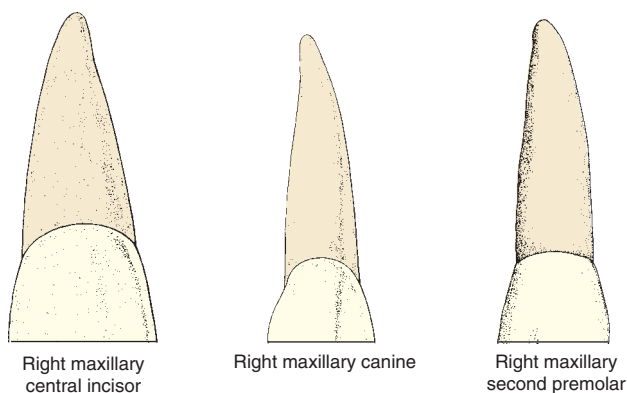
## 2. CLASS TRAITS THAT DIFFER FROM ANTERIOR TEETH

**Tooth Surface Terminology:** Compared to the anterior teeth, the facial surfaces of the posterior teeth are called *buccal* (resting against the cheeks) instead of labial, and posterior teeth have *occlusal* surfaces instead of incisal ridges. These occlusal surfaces have cusps, ridges, and grooves.

**Occlusal Cusps Versus Incisal Edges:** Unlike anterior teeth with incisal edges or ridges and a cingulum, premolars have one buccal (or facial) cusp, and most have one lingual cusp (Appendix 5b). The EXCEPTION is the mandibular second premolar, which over half of the time has two lingual cusps.<sup>A</sup>

**Marginal Ridges:** The marginal ridges of most premolars are oriented in a horizontal plane versus a more lingually sloping plane in the anterior teeth (Appendix 5c). However, an EXCEPTION is the mesial marginal ridge of the mandibular first premolar that is aligned almost halfway between horizontal and vertical (Appendix 6s).

**Crown and Root Length:** Premolar crowns in both arches are shorter than crowns of anterior teeth,<sup>B</sup> and



**FIGURE 4-2.** Facial views of an incisor, canine, and premolar with the incisal/occlusal thirds of the crowns removed. Notice the similarities in **crown taper** toward the cervical line, **root taper** toward the apex, and **cervical line contour** on these three classes of teeth.

first premolar crowns are slightly longer than second premolars. (Just think of the gradation in size as a transition from the longer incisor and canine crowns to the even shorter molar crowns.) However, the *roots* of second premolars are slightly longer than first premolars.

Roots on maxillary premolars are considerably shorter than on maxillary canines, but similar in length to maxillary incisor roots. Roots on mandibular premolars are also shorter than on mandibular canines, but longer than on mandibular incisors.<sup>c</sup> Complete data can be found in Tables 4-6A and 4-6B.

**Height (Crest) of Contour:** From both mesial and distal aspects, the *facial* heights of contour of premolar crowns are in the cervical third, like on anterior teeth. However, the heights of contour are more occlusal in position than the corresponding heights of contour on the anterior teeth (Appendix 5d). In other words, the greatest facial bulge is farther from the cervical line on premolars. An EXCEPTION is the buccal height of contour of the mandibular first premolar, which may be located as far cervically as on anterior teeth. The location of the *lingual* height of contour for premolars is also farther from the cervix relative to anterior teeth. Lingually, it is located in the middle third occlusocervically compared to the cervical third on anterior teeth.

**Contact Areas:** The proximal contact areas are generally more cervically located and broader than on anterior teeth.

### 3. OTHER CLASS TRAITS CHARACTERISTIC OF MOST PREMOLARS

Evaluate the similarities of all premolars while comparing models or extracted specimens of all four types of premolars from the views indicated. Also, use the study pages from the Appendix page 5 to identify the class traits. It is important to note that although general characteristics are described in this book, there is considerable variation from these descriptions in nature.<sup>1-3</sup> Remember when studying the maxillary premolars to hold them with their crowns down and roots up. For mandibular premolars, have the crowns up and the roots down. In this manner, the teeth will be oriented as they were in the mouth.

#### a. Class Traits of Most Premolars from the Buccal View

**Crown Outline Shape of Premolars:** The crown from the buccal view is broadest at the level of the contact areas and narrower at the cervix: shaped roughly like a five-sided pentagon, similar to the canine crown shape

(Appendix 5g). The mesial and distal outlines of the crown are nearly straight or slightly convex from contact areas to the cervical line.

**Location of Most Premolar Contact Areas:** Both mesial and distal sides of the crown are convex around the contact areas, similar to canines. *Mesial* proximal contacts are near the junction of the occlusal and middle thirds, and the *distal* contacts are normally slightly more cervical, in the middle third (Appendix 5e), EXCEPT on mandibular first premolars, where mesial contacts are usually more cervical than the distal contacts.

**Relative Size of Most Premolar Cusp Ridges:** As on canines, when viewed from the facial, the tip of the facial cusp of a premolar is often slightly mesial to the vertical root axis line of the tooth (Appendix 5h), with the mesial cusp ridge of the buccal cusp shorter than the distal ridge (Appendix 5i). The EXCEPTION to this general rule is the maxillary first premolar, where the facial cusp tip is located slightly to the distal of the root axis line and the mesial cusp ridge is longer (Appendix 6e).

#### b. Crown Shape (Outline) of Most Premolars from the Lingual View

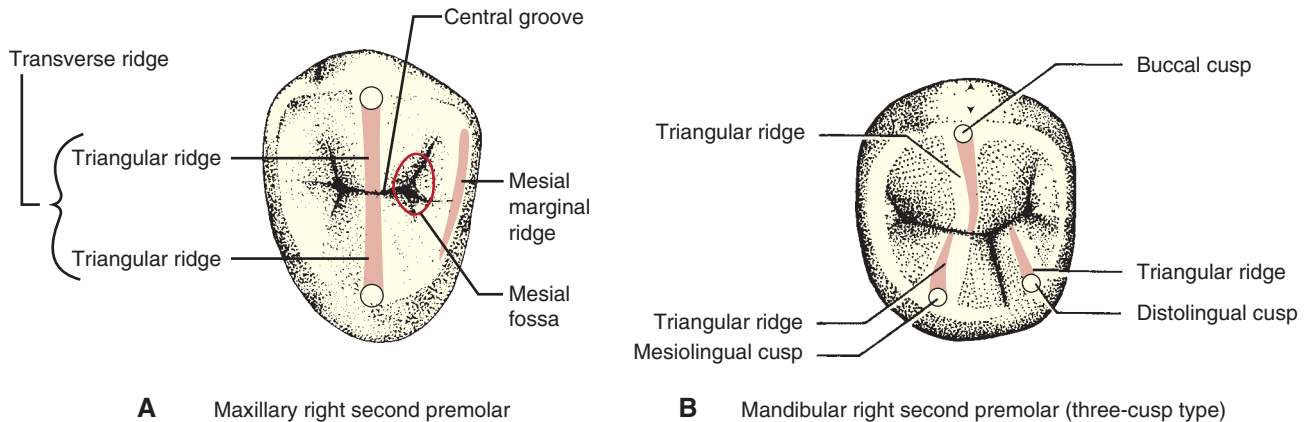
The crown is narrower on the lingual side than on the buccal side, EXCEPT some three-cusped mandibular second premolars (with two lingual cusps) that may be wider on the lingual half. The lingual surface is convex.

#### c. Marginal Ridges of Most Premolars from the Proximal Views

The relative height of the mesial and distal marginal ridge is similar to the relative height of the proximal contact areas. The *mesial* marginal ridge is more occlusally positioned than the distal marginal ridge, so if you first look at the mesial side and compare it to the distal side of this tooth, you should be able to see less of the occlusal surface and triangular ridges from the *distal* view (compare mesial and distal surfaces in Appendix 5j). An EXCEPTION is the mandibular first premolar, where the distal marginal ridge is in a more occlusal position than the mesial marginal ridge.

#### d. Class Traits of Most Premolars from the Occlusal View

**Tooth Proportions:** Like the majority of anterior teeth (except maxillary central and lateral incisors), all types of premolars, on average, are wider faciolingually than mesiodistally<sup>d</sup> (Appendix 5k).



**FIGURE 4-3.** **A.** Typical two-cusp type premolar (maxillary second) with two **triangular ridges** (one on the buccal cusp and one on the lingual cusp) joining to form one longer **transverse ridge**. Notice how the triangular ridges of the buccal and lingual cusps on one side, and the marginal ridge on the other, bind the mesial fossa. **B.** The mandibular second premolar, three-cusp type, is **UNIQUE** since it is the only premolar that has three triangular ridges (one per cusp), and these ridges do **NOT** join to form a transverse ridge.

**Cusp Ridges and Marginal Ridges Bound the Occlusal Table:** Like canine cusps, premolar cusps (buccal and lingual) have mesial and distal cusp ridges. On premolars, the cusp ridges of buccal and lingual cusps merge with the marginal ridges to surround the portion of the tooth known as the occlusal table (inside of the dotted lines on Appendix 5-1).

**Triangular Ridges Form Transverse Ridges:** The triangular ridges of the buccal and lingual cusps slope toward the occlusal sulcus and converge at the central groove (Fig. 4-3A). On premolars with only two cusps, the two triangular ridges (one buccal and one lingual) join together to form a transverse ridge, which can be best observed from the occlusal aspect. An **EXCEPTION:** The three triangular ridges on the three-cusped mandibular second premolar do not meet so *do not form* a transverse ridge (Fig. 4-3B).

**Grooves and Fossae:** A groove (or grooves) runs mesiodistally across the occlusal surface on most premolars. (**EXCEPTION:** the mandibular first premolar has a pronounced transverse ridge, often without a groove running mesiodistally across it.) This groove (or grooves), when present, ends mesially in the mesial fossa and distally in the distal fossa. These fossae are bounded on one side by the buccal and lingual triangular ridges (or transverse ridge) and on the other side by a marginal ridge. A central groove extending from the mesial to distal fossa is labeled in Figure 4-3A.

**Proximal Contacts Viewed from the Occlusal View:** Proximal contacts from the occlusal view are either on or most often slightly buccal to the faciolingual midline of the crown (Appendix 5f).

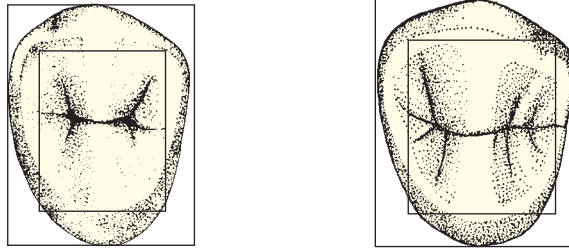
## D. ARCH TRAITS THAT DIFFERENTIATE MAXILLARY FROM MANDIBULAR PREMOLARS

Refer to Appendix page 6 while reading about differences between maxillary and mandibular premolars.

**Relative Shape and Size:** The maxillary first and second premolars appear more alike than the mandibular premolars, yet maxillary first premolar crowns are larger than on seconds in all dimensions.

**Lingual Crown Tilt in Mandibular Premolars:** From either proximal aspect, mandibular premolar crowns appear to be tilted lingually relative to their roots (the first premolar noticeably more than the second). This lingual tilting of the crown is characteristic of all **mandibular posterior teeth** and enables their buccal cusps to fit and function both beneath and lingual to the maxillary buccal cusps. **Maxillary premolar crowns** are aligned more directly over their roots. This difference is easy to recognize when comparing the proximal views of maxillary and mandibular premolars in Appendix 6j for maxillary, and 6a for mandibular.

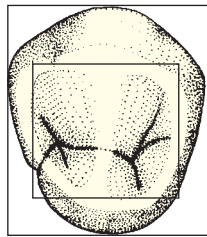
**Cusp Size and Location:** The buccal cusp is longer than the lingual cusp (or cusps) on all premolars (especially on mandibular firsts), but the difference is minimal on maxillary second premolars (compare Appendix 6c, maxillary, and 6p, mandibular). Most premolar lingual cusp tips are positioned off center to the mesial **EXCEPT** on mandibular first premolars and some mandibular second premolars where they may be centered (seen from lingual views in Appendixes 6i and 6q).



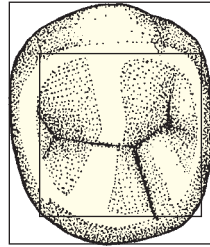
Maxillary right second premolar

Maxillary right first premolar

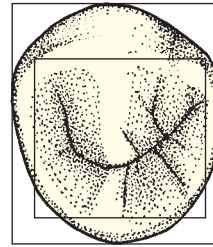
**MAXILLARY PREMOLARS (Occlusal)**



Mandibular right first premolar



Three-cusp type



Two-cusp type

Mandibular right second premolar

**MANDIBULAR PREMOLARS (Occlusal)**

**FIGURE 4-4. Arch differences in the outline of premolars:** All types of premolars with an outer box demonstrating the **proportion** of the entire occlusal outline of each tooth, and an inner box highlighting the proportion of its occlusal table. Notice that even though all premolar types are longer faciolingually than mesiodistally, the shapes of the maxillary premolars are much more rectangular (more obviously longer faciolingually) compared to the shape of mandibular premolars, which are closer to square.

**Buccal Ridge Prominence:** The buccal ridge is more prominent on the maxillary first premolar than on the mandibular first premolar.

**Crown Proportions:** From the occlusal view, maxillary premolars are more oblong or rectangular (considerably wider faciolingually than mesiodistally), whereas mandibular premolars are closer to equal dimension faciolingually as mesiodistally (Fig. 4-4). This difference may be even more apparent when comparing

the outline of the occlusal table (the area bounded by a perimeter of ridges: mesial and distal cusp ridges of each cusp, and mesial and distal marginal ridges). This difference is apparent when comparing the dimensions of the occlusal views of maxillary and mandibular premolars in Appendix 6d.

Now is a good time to review major differences between maxillary and mandibular premolars highlighted in Table 4-2.

Table 4-2		MAJOR ARCH TRAITS THAT DISTINGUISH MAXILLARY FROM MANDIBULAR PREMOLARS	
	MAXILLARY PREMOLARS		MANDIBULAR PREMOLARS
BUCCAL	Buccal ridge is more prominent		Buccal ridge is less prominent
	No distal crown tilt relative to root		Crown exhibits slight distal tilt on root due to greater distal bulge
LINGUAL	Less difference between heights of buccal and lingual cusps (especially seconds)		More difference between heights of buccal and lingual cusps (especially firsts)
PROXIMAL	Occlusal outline aligned over root		Crown tilts to lingual relative to root
	Lingual cusp is just slightly shorter than buccal		Lingual cusp is much shorter than buccal
OCCLUSAL	Crown shape oval or rectangular		Crown shape closer to square or round
	Crown considerably wider faciolingually than mesiodistally		Crown less oblong faciolingually



## SECTION II

## TYPE TRAITS THAT DIFFERENTIATE MAXILLARY FIRST FROM MAXILLARY SECOND PREMOLARS

## OBJECTIVES

This section prepares the reader to perform the following:

- Describe the type traits that can be used to distinguish the permanent maxillary first premolar from the maxillary second premolar.
- Describe and identify the buccal, lingual, mesial, distal, and occlusal surfaces for all maxillary premolars.
- Assign a Universal number to maxillary premolars present in a mouth (or on a model of the teeth) with complete dentition. If possible, repeat this on a model with one or more maxillary premolars missing.
- Holding a maxillary premolar, determine whether it is a first or a second, and right or left. Then assign a Universal number to it.

### A. TYPE TRAITS OF MAXILLARY PREMOLARS FROM THE BUCCAL VIEW

From the buccal view, compare the maxillary first and second premolars in *Figure 4-5*. Compare tooth models and/or extracted maxillary premolars as you read the following characteristics, holding the crowns down and roots up, just as they are oriented in the mouth.

#### 1. RELATIVE SIZE OF MAXILLARY PREMOLAR CROWNS FROM THE BUCCAL VIEW

The crown of the maxillary first premolar is larger than the maxillary second premolar, but the root is shorter overall.<sup>E</sup> The junction of cusp slopes and proximal surfaces (shoulders) appear more broad, bulging, and angular on the first premolar (especially on the mesial) than on the more gently convex second premolar.

The mesial and distal sides of the crown, from the contact areas to the cervical line, converge more noticeably on the maxillary first premolar than second premolar so the cervical portion of the crown of the second premolar appears relatively wider. Observe the more prominent mesial shoulders and increased crown taper on many maxillary first premolars in *Figure 4-5*.

#### 2. LOCATION OF PROXIMAL CONTACTS ON MAXILLARY PREMOLARS FROM THE BUCCAL VIEW

For both types of maxillary premolars, *mesial* contacts are usually in the middle third, near the junction of the occlusal and middle thirds. *Distal* contacts are slightly more cervical, as on anterior teeth, but still in the middle third (recall *Appendix 5e*).

#### 3. LOCATION OF THE BUCCAL CUSP TIP ON MAXILLARY PREMOLARS FROM THE BUCCAL VIEW

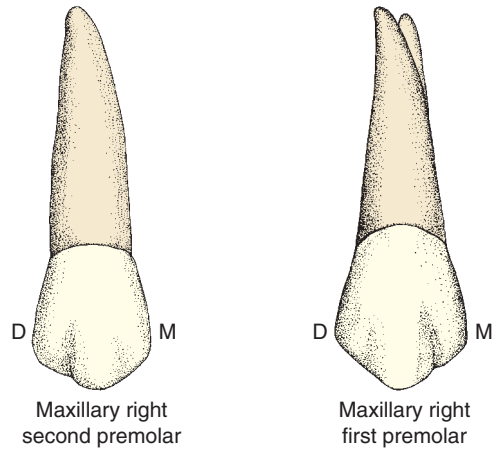
Maxillary second premolars, like canines, have the mesial cusp ridge shorter than the distal cusp ridge. Maxillary first premolars are UNIQUE in that they have the only facial cusp on a premolar (or canine) where the mesial cusp ridge is longer than the distal cusp ridge. This results in a cusp tip that is distal to the vertical mid-root axis (*Appendix 6e* and most maxillary first premolars in *Fig. 4-5*).

#### 4. SHAPE OF THE BUCCAL CUSP OF MAXILLARY PREMOLARS FROM THE BUCCAL VIEW

The buccal cusp of the maxillary first premolar is relatively long and pointed or sharp (*Appendix 6f*), resembling a maxillary canine, with the mesial and distal slopes meeting at almost a right angle (100–110°), compared to the second premolar, which is less pointed and more obtuse (125–130°), as seen on most second premolars in *Figure 4-5*.

#### 5. BUCCAL RIDGE AND ADJACENT DEPRESSIONS OF MAXILLARY PREMOLARS FROM THE BUCCAL VIEW

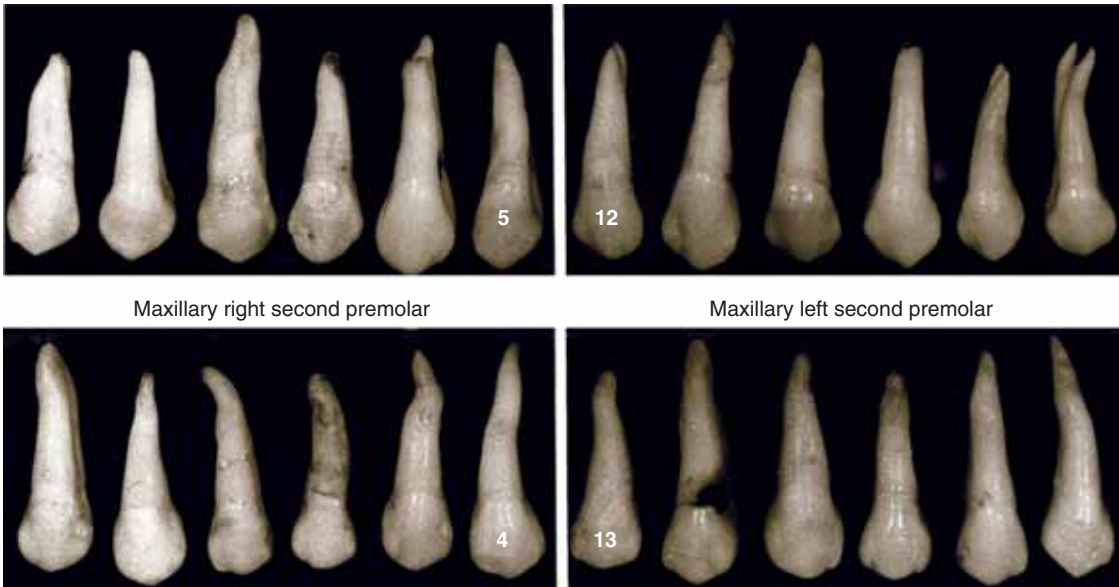
The buccal ridge is more prominent on maxillary first premolars than on maxillary second premolars (*Appendix 6g*). Shallow vertical depressions in the occlusal third may be evident on the buccal surfaces of maxillary premolars located most often mesial to the buccal ridge on maxillary first premolars, and next most frequently, distal to the buccal ridge on maxillary second premolars.<sup>F</sup> The most common location of these depressions is depicted in the drawings in *Figure 4-5*.



**MAXILLARY PREMOLARS (buccal)**

Maxillary right first premolar

Maxillary left first premolar



← Distal →

**TRAITS TO DISTINGUISH MAXILLARY FIRST FROM SECOND PREMOLAR: BUCCAL VIEWS**

**MAXILLARY FIRST PREMOLAR**

- Sharper buccal cusp angle
- Mesial cusp ridge longest
- Prominent buccal ridge
- Bulging shoulders and angular outline
- Tapers more from contacts cervically
- Mesial buccal ridge depression more common

**MAXILLARY SECOND PREMOLAR**

- More blunt buccal cusp angle
- Distal cusp ridge longest
- Less prominent buccal ridge
- Narrow, more rounded shoulders
- Less taper from contacts cervically
- Distal buccal ridge depression more common

**TRAITS TO DIFFERENTIATE MAXILLARY RIGHT FROM LEFT PREMOLARS: BUCCAL VIEWS**

**MAXILLARY FIRST PREMOLARS**

- Longer mesial cusp ridge
- Depression more common mesial to buccal ridge

**MAXILLARY SECOND PREMOLARS**

- Shorter mesial cusp ridge
- Depression more common distal to buccal ridge

Root often, but not always, curves to distal for both  
 Mesial contact more occlusal than distal contact for both

**FIGURE 4-5.** Buccal views of maxillary premolars with type traits to distinguish maxillary first from second premolars, and traits to distinguish rights from lefts.

### 6. ROOTS OF MAXILLARY PREMOLARS FROM THE BUCCAL VIEW

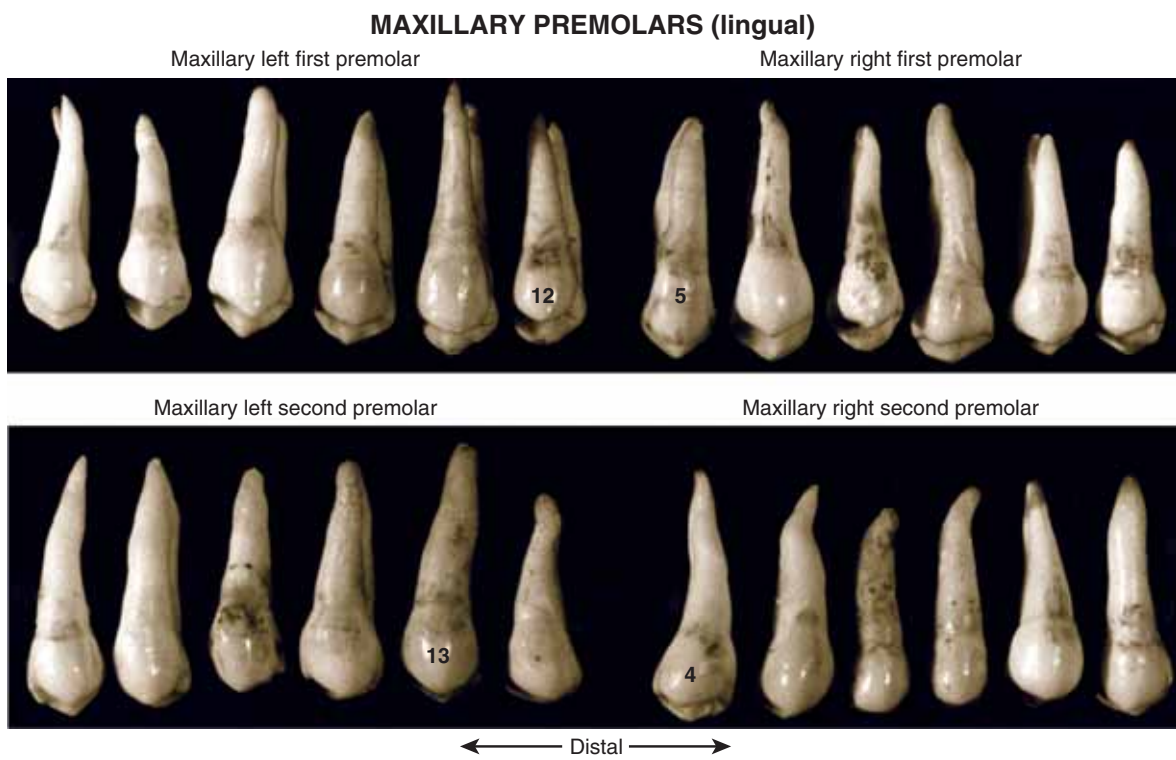
The apical end of the root of all single rooted premolars frequently bends distally, but these roots may also be straight or bend mesially.<sup>16</sup> Most of the time, the maxillary first premolar is divided into a buccal and lingual root splitting off of a common trunk in the apical third<sup>H</sup> (seen best from the proximal view in Appendix 6h). The buccal roots frequently curve distally near the apex so you can see the tip of the lingual root when it is straighter or bends in a different direction than the buccal root. Both roots

are visible in several maxillary first premolars in Figure 4-5.

The single root of the maxillary second premolar is longer than on the first premolar and is nearly twice as long as the crown.<sup>1</sup> The root is 1.8 times longer than the crown which gives this tooth the greatest root-to-crown ratio of any maxillary tooth.

### B. TYPE TRAITS OF MAXILLARY PREMOLARS FROM THE LINGUAL VIEW

Compare the lingual view of maxillary first and second premolars in Figure 4-6.



TRAITS TO DISTINGUISH MAXILLARY FIRST FROM SECOND PREMOLAR: LINGUAL VIEWS	
<b>MAXILLARY FIRST PREMOLAR</b>	<b>MAXILLARY SECOND PREMOLAR</b>
Lingual cusp shorter: two cusps visible Crown tapers toward lingual	Buccal cusps very slightly longer than lingual Slightly less taper toward lingual
TRAITS TO DIFFERENTIATE MAXILLARY RIGHT FROM LEFT PREMOLARS: UNIQUE FROM LINGUAL VIEWS	
<b>MAXILLARY FIRST PREMOLAR</b>	<b>MAXILLARY SECOND PREMOLAR</b>
Mesial cusp ridge longer than distal	Mesial cusp ridge shorter than distal
Lingual cusp tip is mesial to midline for both	

**FIGURE 4-6.** Lingual views of maxillary premolars with type traits to distinguish maxillary first from second premolars, and traits to distinguish rights from lefts.

### 1. RELATIVE CUSP SIZE OF MAXILLARY PREMOLARS FROM THE LINGUAL VIEW

The lingual cusp is shorter than the buccal cusp, considerably more so on the **maxillary first premolar**. The buccal and lingual cusps of the **maxillary second premolar** are nearly the same length.<sup>J</sup> This trait is seen in almost all first premolars in Figure 4-6 and is evident on the lingual views of maxillary premolars on Appendix page 6. The crown is a little narrower on the lingual surface than on the buccal surface, more so on the first premolar than on the second premolar.

### 2. CUSP RIDGES OF MAXILLARY PREMOLARS FROM THE LINGUAL VIEW

The mesial and distal ridges of the lingual cusp of the **maxillary first premolar** meet at the cusp tip at a somewhat rounded angle, but the angle is still sharp or steep compared to molar cusps. The tip of the lingual cusp of the **second premolar** is relatively sharper.

### 3. LINGUAL CUSP POSITION FOR MAXILLARY PREMOLARS FROM THE LINGUAL VIEW

The tips of the unworn lingual cusps of *both* types of maxillary premolars are consistently positioned to the *mesial of the mid-root axis line* (Appendix 6i). This trait is an excellent way to tell rights from lefts, especially for the maxillary second premolar, which is, in many other ways, nearly symmetrical.

### 4. MARGINAL RIDGES OF MAXILLARY PREMOLARS FROM THE LINGUAL VIEW

From the lingual view, differences in marginal ridge heights are apparent on handheld teeth when rotating the tooth just enough one way to see the mesial ridge height, then just enough in the opposite direction to compare the distal ridge height. The distal marginal ridges of both types of maxillary premolars are more cervical in position than the mesial marginal ridge (recall Appendix 5j).

### 5. ROOTS OF MAXILLARY PREMOLARS FROM THE LINGUAL VIEW

The lingual root of a two-rooted maxillary first premolar is usually shorter than the buccal root.<sup>K</sup> Both first and second premolar roots taper narrower to the lingual.

## C. TYPE TRAITS OF MAXILLARY PREMOLARS FROM THE PROXIMAL VIEWS

Compare the proximal views of maxillary first and second premolars in Figure 4-7.

### 1. CROWN SHAPE AND MORPHOLOGY OF MAXILLARY PREMOLARS FROM THE PROXIMAL VIEWS

Both types of maxillary premolars are shaped like a *trapezoid* from the proximal view (Appendix 6b). A trapezoid is a four-sided figure with two parallel sides and two nonparallel sides. Both cusp tips are located over the root and well within the boundary of the root outline, an important relationship imparting good functional support for a large chewing area.

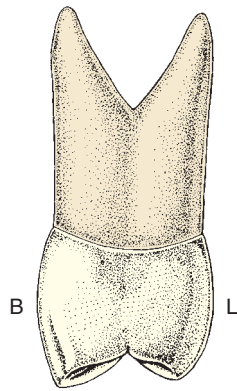
**Maxillary first premolars** have a **UNIQUE** prominent **mesial crown concavity** just cervical to the contact area, whereas **maxillary second premolars** (and mandibular premolars) do not (Appendix 6j). This mesial crown concavity can be seen in almost all maxillary first premolars so it is a consistent and obvious trait of all maxillary first premolars that can be used to distinguish it from a maxillary second premolar, and can be used to confirm the mesial surface on the maxillary first premolar. It is important to remember the presence of this unique mesial crown concavity when restoring the contours of this surface, or when detecting and removing calcified deposits from this crown surface.

### 2. RELATIVE CUSP HEIGHT OF MAXILLARY PREMOLARS FROM THE PROXIMAL VIEWS

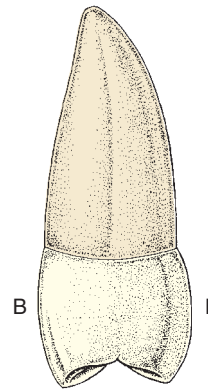
From this view, as from the lingual, the buccal cusp is noticeably longer than the lingual cusp on **maxillary first premolars**, compared to the **second premolar**, which has two cusps of nearly equal length (Appendix 6c). This difference is obvious when comparing first and second premolars in Figure 4-7. From the proximal view, it is often a challenge telling buccal from lingual on the maxillary second premolar based solely on the cusp heights, since the cusp heights are so similar. Differences in the heights of contour, however (described next) will be useful for distinguishing buccal from lingual surfaces on these teeth.

### 3. HEIGHT (CREST) OF CONTOUR OF MAXILLARY PREMOLARS FROM THE PROXIMAL VIEWS

Like all teeth, the *facial* height of contour of maxillary premolars is located in the cervical third. Specifically, it is near the junction of the middle and cervical third. *Lingually* (like other posterior teeth) it is more occlusal, in the middle third (near the center of the crown). This trait helps distinguish the buccal from lingual surfaces on the majority of maxillary premolars from the proximal views in Figure 4-7.



Maxillary right first premolar

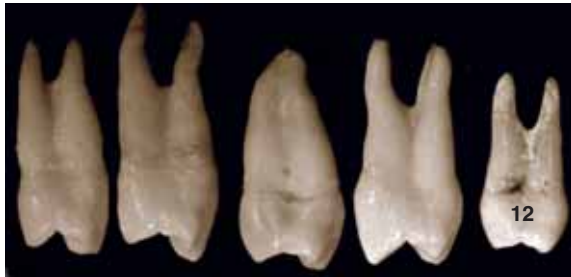

Maxillary right second premolar

MESIAL VIEWS

**MAXILLARY LEFT PREMOLARS**

Maxillary left first premolar (mesial)

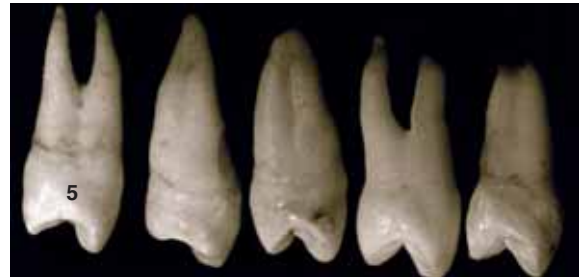

Maxillary left second premolar (mesial)

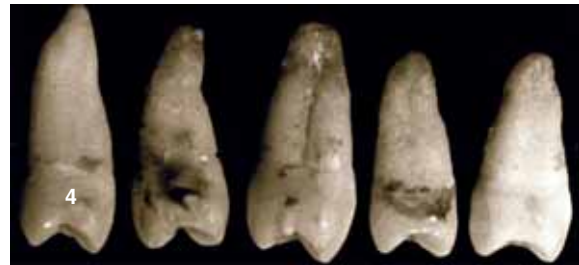

**MAXILLARY RIGHT PREMOLARS**

Maxillary right first premolar (distal)



Maxillary right second premolar (distal)



← Lingual      Buccal →

**TRAITS TO DISTINGUISH MAXILLARY FIRST FROM SECOND PREMOLAR: PROXIMAL VIEWS**

**MAXILLARY FIRST PREMOLAR**

- Two roots or deeply divided single root
- Buccal cusp longer than lingual
- Mesial crown and root depression
- Mesial root depression deeper than distal
- Almost always mesial marginal ridge groove

**MAXILLARY SECOND PREMOLAR**

- Single root
- Buccal and lingual cusps similar length
- Mesial root but not crown depression
- Distal root depression deeper than mesial
- Less likely mesial marginal groove

**TRAITS TO DIFFERENTIATE MAXILLARY RIGHT FROM LEFT PREMOLARS: UNIQUE FROM PROXIMAL VIEWS**

**MAXILLARY FIRST PREMOLAR**

- Pronounced mesial crown (and adjacent root) depression
- Deeper mesial than distal root depression
- Almost always mesial marginal ridge groove

**MAXILLARY SECOND PREMOLAR**

- Deeper distal than mesial root depression

Distal marginal ridge is more cervical than mesial for both  
Greater mesial than distal cervical line curvature for both

**FIGURE 4-7.** Proximal views of maxillary premolars with type traits to distinguish maxillary first from second premolars, and traits to distinguish rights from lefts.



#### 4. DISTANCE BETWEEN CUSP TIPS ON MAXILLARY PREMOLARS FROM THE PROXIMAL VIEWS

The average distance between the buccal and lingual cusp tips of maxillary first and second premolars is about the same.<sup>L</sup>

#### 5. MARGINAL RIDGE GROOVES OF MAXILLARY PREMOLARS FROM THE PROXIMAL VIEWS

Marginal ridge grooves serves as a spillway for food during mastication (best seen from the occlusal view in Appendix 6k). The *mesial* marginal ridge of the **maxillary first premolar** is almost always crossed by a developmental groove called a *mesial marginal ridge groove* that may extend onto the mesial crown surface.<sup>M</sup> The *distal* marginal ridge of this tooth, and the mesial and distal marginal ridges of the **maxillary second premolars**, are less likely to have marginal ridge grooves, and, when present, these grooves are less likely to extend onto the proximal surfaces.

#### 6. CERVICAL LINES OF MAXILLARY PREMOLARS WHEN COMPARING PROXIMAL VIEWS

The cervical line on the mesial side of *both* types of maxillary premolars curves occlusally in a broad, but shallow arc. As on anterior teeth, the mesial curvature is slightly greater than the distal curvature.<sup>N</sup> The cervical line on the *lingual* surface of the **maxillary first premolar** is in a more occlusal position than on the buccal surface. This accentuates the appearance that the lingual cusp is definitely shorter than the buccal cusp.

#### 7. ROOTS AND ROOT DEPRESSIONS OF MAXILLARY PREMOLARS FROM THE PROXIMAL VIEWS

The roots of *both* types of maxillary premolars are likely to have both mesial and distal root depressions of varying depths. Knowledge of the relative location and depth of these depressions can be helpful clinically when using dental instruments in the gingival sulcus to detect and remove calcified deposits that contribute to periodontal disease, and when identifying areas of decay on accessible root surfaces.

Recall that **maxillary first premolars** most often have two roots with the lingual root slightly shorter than the buccal root. The split into two roots (bifurcation) occurs in the apical third of the root. As stated previously, this is the only premolar with an obvious crown concavity or depression on the *mesial* surface of

its crown, and this depression continues onto the root (seen on all teeth studied).<sup>O</sup> On maxillary first premolars with either one or two roots, this *crown* depression is continuous with a prominent mesial *root* depression.<sup>O</sup> This important type trait is seen clearly on the mesial views of all maxillary first premolars in Figure 4-7. There is also a less distinct *distal* root depression found on both double- and single-rooted first premolars. This distal depression is located on the middle third of the undivided portion of the root but does not usually extend close to the cervical line. The root of the maxillary first premolar is **UNIQUE** in that it is the only premolar type where the mesial-side longitudinal root depression is deeper than on the distal surface.

The **maxillary second premolar** usually has one root with longitudinal root depressions located in the middle third of the mesial and distal root surfaces. However, its *mesial* root depression does not extend onto the crown.<sup>P</sup> The *distal* root depression is usually deeper than on the mesial root surface. This feature is the opposite from the maxillary first premolar, where the mesial mid-root depression is deeper.

### D. TYPE TRAITS OF MAXILLARY PREMOLARS FROM THE OCCLUSAL VIEW

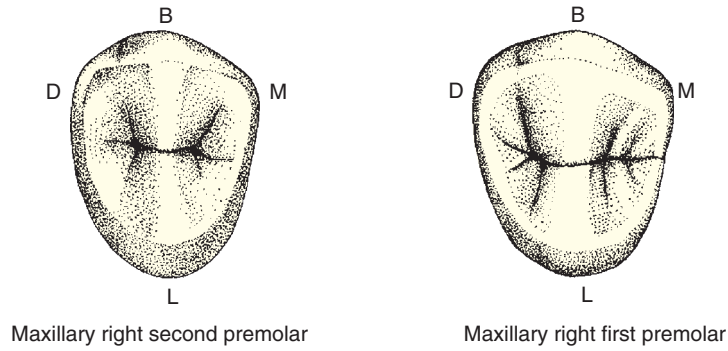
Compare occlusal views of maxillary first and second premolars in Figure 4-8. To follow this description, the teeth or tooth models you are using should be held as those displayed in Figure 4-8, so that the buccal surface is at the top and you are sighting down along the vertical mid-root axis.

#### 1. RELATIVE SIZE OF MAXILLARY PREMOLARS FROM THE OCCLUSAL VIEWS

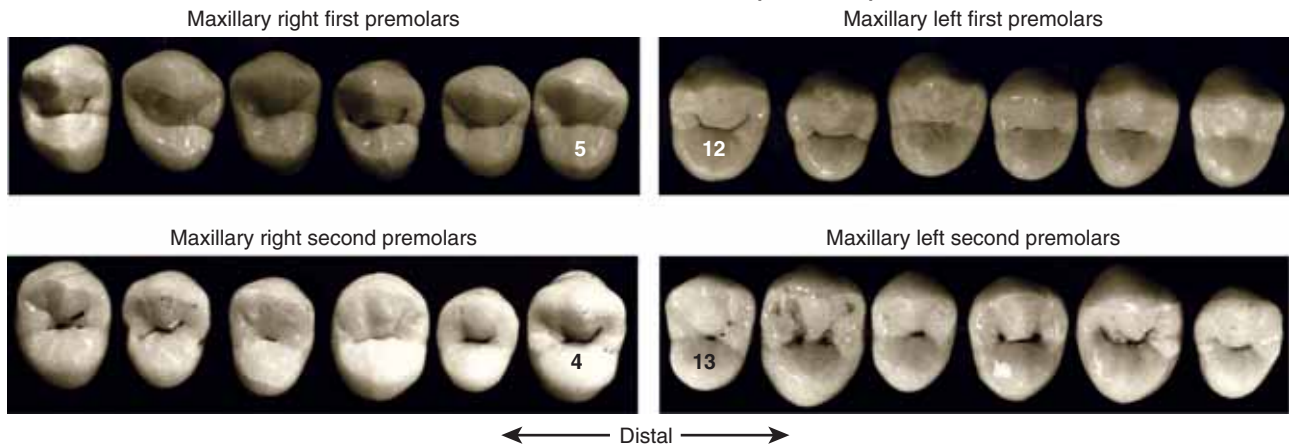
In the same mouth, maxillary first premolars were larger than adjacent second premolars a little over half of the time.<sup>Q</sup>

#### 2. GROOVES AND FOSSAE OF MAXILLARY PREMOLARS FROM THE OCCLUSAL VIEW

Characteristically, central developmental grooves run mesiodistally across the center of both types of maxillary premolars extending from a mesial pit to a distal pit. The length of the central groove of the **maxillary first premolar** is relatively longer (more than one third of the mesiodistal outline width) than the groove on the maxillary second premolar (Appendix 6l).<sup>R</sup> Because the central groove on the maxillary first premolar is longer, the pits are farther apart and are relatively closer to the marginal ridges than on maxillary second premolars.



**MAXILLARY PREMOLARS (occlusal)**



**TRAITS TO DISTINGUISH MAXILLARY FIRST FROM SECOND PREMOLAR: OCCLUSAL VIEWS**

**MAXILLARY FIRST PREMOLAR**

- Crown asymmetrical, more hexagonal
- Mesial surface concave or flat
- Proximal surfaces converge lingually
- Longer central groove so mesial and distal fossae are closer to marginal ridge
- Almost always mesial marginal ridge groove
- More prominent buccal ridge
- Fewer supplemental grooves

**MAXILLARY SECOND PREMOLAR**

- Crown symmetrical and more oval
- Mesial surface more convex
- Little tapering toward lingual
- Shorter central groove so mesial and distal fossae closer to tooth center
- Mesial marginal ridge much less common
- Less prominent buccal ridge
- More supplemental grooves

**TRAITS TO DIFFERENTIATE MAXILLARY RIGHT FROM LEFT PREMOLARS: UNIQUE FROM OCCLUSAL VIEWS**

**MAXILLARY FIRST PREMOLAR**

- Mesial crown outline is concave or flat
- Mesiobuccal line angle is a right angle
- Almost always mesial marginal ridge groove
- Distal contact is more buccal

**MAXILLARY SECOND PREMOLAR**

- Mesial contact is more buccal
- Lingual cusp tip mesial to center for both
- Curved distal marginal ridge longer than mesial for both

**FIGURE 4-8.** Occlusal views of maxillary premolars with type traits to distinguish maxillary first from second premolars, and traits to distinguish rights from lefts.

This longer central groove on maxillary first premolars compared to second premolars is quite obvious when comparing the maxillary premolars in Figure 4-8. This longer central groove on the maxillary first premolar is accentuated by the **mesial marginal ridge groove** that almost always crosses the mesial marginal ridge. It is continuous with the central groove and often crosses onto the mesial tooth surface (seen on the drawing in Fig. 4-8). Marginal ridge grooves are much less common on the mesial marginal ridge of maxillary second premolars and the distal marginal ridges of either type of maxillary premolar.

There are more *supplemental grooves* on **maxillary second premolars** than on maxillary first premolars. These supplementary grooves radiate buccally and lingually from the pits at the depth of each triangular fossa.

On most maxillary premolars, the distal triangular fossae appear larger than, or equal in size to, the mesial fossae.<sup>5</sup>

### 3. RELATIVE PROPORTIONS OF MAXILLARY PREMOLARS FROM THE OCCLUSAL VIEW

The oblong (oval or rectangular) crown outline of *both* types of maxillary premolars are noticeably greater buccolingually than mesiodistally.<sup>7</sup> This is obvious in all maxillary premolars in Figure 4-8.

### 4. OUTLINE OF MAXILLARY PREMOLARS FROM THE OCCLUSAL VIEW

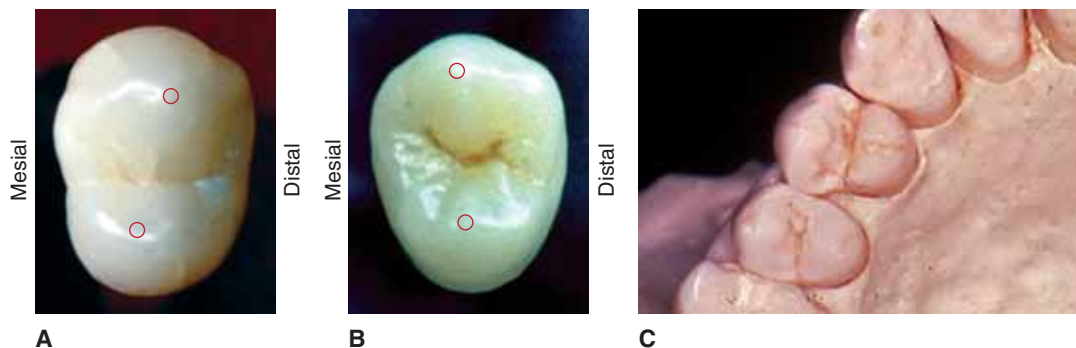
On *both* types of maxillary premolars, the lingual half of the tooth is narrower mesiodistally than the buccal half, more so on first premolars. From the occlusal aspect, the buccal outline of the **maxillary first premolar** is a rounded and almost V-shape because of the

prominent buccal ridge, but this ridge is less prominent on the second premolar as seen in Figure 4-8. On *both* types, the tip of the *lingual* cusp is slightly *mesial* to the center of the tooth.

Seen from the occlusal aspect, the **maxillary second premolar** is typically quite symmetrical (similar shape for the mesial and distal halves). Its occlusal outline is smoother and less angular than that of the first premolar (Fig. 4-9B).

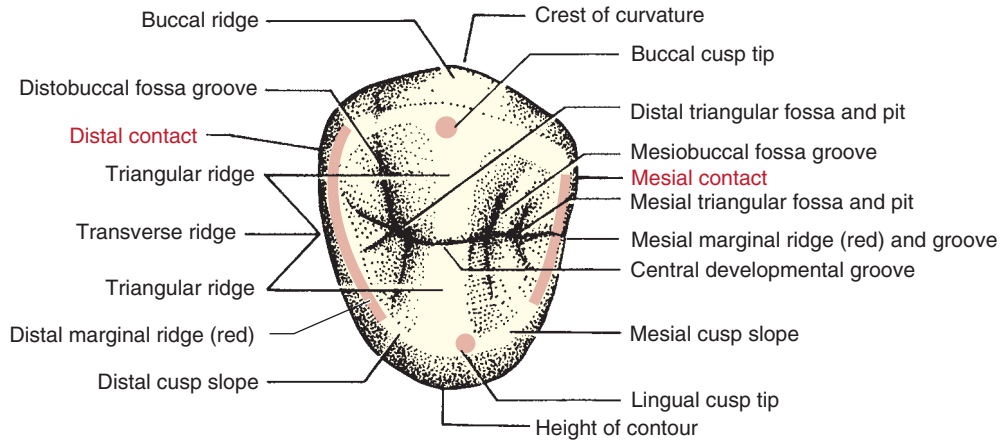
An asymmetrical occlusal outline is a distinguishing feature of the **maxillary first premolar** that distinguishes it from second premolars (compare outline shapes in Appendix 6m). Part of this asymmetry is due to the apparent “twisting” of the lingual half of the tooth to the mesial, with the lingual cusp tip mesial to the midline, and the buccal cusp tip actually located distal to the midline (UNIQUE to the maxillary first premolar with its mesial cusp ridge longer than its distal cusp ridge) (Fig. 4-9A). This twisting results in a mesial marginal ridge that joins the mesial cusp ridge of the buccal cusp at an almost right angle (not so on second premolars), and a mesial surface that forms a nearly straight or concave outline buccolingually rather than a more uniform taper like on the second premolar. This mesial outline concavity may be accentuated by the depression of the mesial marginal ridge groove and mesial crown concavity next to the root. This straighter mesial marginal ridge appears shorter buccolingually than the more convex distal marginal ridge (note this characteristic on the occlusal surfaces of most maxillary first premolars) (Fig. 4-8).

Compare the symmetrical outline of the maxillary second premolar to the asymmetrical outline of the maxillary second premolar in Figure 4-9C.



**FIGURE 4-9.**

**A.** Note the *asymmetrical* outline of the maxillary left *first* premolar, and the location of the buccal cusp tip distal to the tooth center. **B.** The *symmetry* of the maxillary left *second* premolar makes it a challenge to tell rights from lefts from this view, but the slight mesial placement of the buccal and lingual cusp tips is helpful. **C.** In this mouth, the *asymmetry* of the maxillary first premolar is obvious compared to the adjacent symmetrical second premolar.



**FIGURE 4-10.** Maxillary right first premolar, occlusal surface, with anatomic structures that contribute to its **asymmetry**. Notice the proximal contact locations (the distal contact of this tooth is more buccal than the mesial), the relative length of the marginal ridges (mesial is shorter), and the location of the cusp tips where the buccal tip is distal to the middle, making the mesial cusp ridge of the buccal cusp longer than the distal cusp ridge (UNIQUE to maxillary first premolars) and the lingual cusp tip is mesial to the middle.

## 5. CONTACT AREAS AND HEIGHTS OF CONTOUR OF MAXILLARY PREMOLARS FROM THE OCCLUSAL VIEW

Mesial contacts for both types of maxillary premolars are at or near the junction of the buccal and middle thirds (slightly more buccal on first premolars). Recall that one third of the tooth from this aspect means one third of the total buccolingual measurements of the crown outline, rather than one third of the occlusal surface measurement. Distal contacts are in the middle third on maxillary second premolars, located more lingually than mesial contacts. Just the opposite is true on first premolars with their asymmetry, where the distal contact is more buc-

cal than the mesial contact (Fig. 4-10). Picture this asymmetry when viewing the hexagon outline presented in Appendix 6m for the maxillary first premolar, and then to the examples of maxillary first premolars in Figure 4-8.

### LEARNING EXERCISE

See how many traits you can list that differentiate the maxillary first from second premolars, and maxillary right from left premolars. When you have finished, compare your list with traits listed in Figures 4-5 through 4-8.

## SECTION III

### TYPE TRAITS THAT DIFFERENTIATE MANDIBULAR FIRST FROM MANDIBULAR SECOND PREMOLARS

#### OBJECTIVES

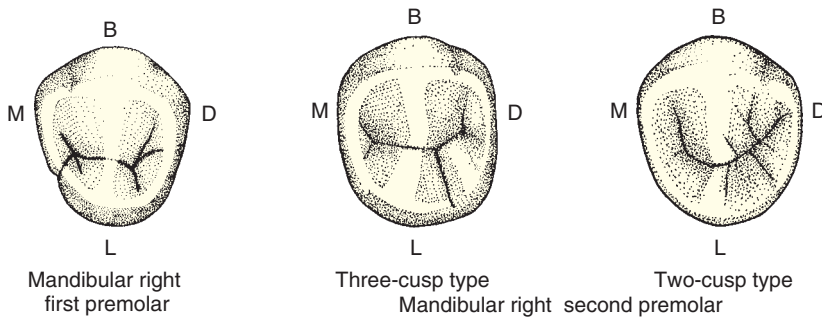
The section prepares the reader to perform the following:

- Describe the type traits that can be used to distinguish the permanent mandibular first premolar from the mandibular second premolar.
- Describe and identify the labial, lingual, mesial, distal, and occlusal surfaces for all mandibular premolars on a photograph, model, or extracted tooth.

- Assign a Universal number to mandibular premolars present in a mouth (or on a model of the teeth) with complete dentition. If possible, repeat this on a model with one or more mandibular premolars missing.
- Holding a mandibular premolar, determine whether it is a first or a second and right or left. Then assign a Universal number to it.

To appreciate differences in mandibular first and second premolars, it is first important to know that there are two common types of mandibular second premolars<sup>3</sup>: a two-cusp type with one buccal and one lingual cusp and

a slightly more common three-cusp type with one buccal and two lingual cusps (seen from the occlusal sketches in Fig. 4-11). The frequency of these two types of mandibular second premolars is presented in Table 4-3.



**FIGURE 4-11.** Occlusal views of three types of mandibular premolars.

## LEARNING EXERCISE

Look in your own mouth and determine whether you have second premolars on both sides and in each arch. For each of your four second premolars, try to determine if each has two, three, or possible even four cusps. Then compare it to the data in Table 4-3 to see how common your findings are.

The morphologic details of mandibular premolars are a challenge to describe because of the great amount of variation. To list all of the frequent variations would lead to confusion rather than to clarification. Bear in mind while studying these teeth that one description will not exactly fit every tooth.<sup>1-3</sup> Descriptions in this chapter are for unworn teeth. Most extracted tooth specimens will have signs of attrition, and some will show evidence of tooth decay (caries).

While reading this section, examine several extracted mandibular premolars or premolar models, and have Appendix pages 5 and 6 available. Hold these mandibular teeth with the crowns up and the roots down.

## A. TYPE TRAITS OF MANDIBULAR PREMOLARS FROM THE BUCCAL VIEW

Refer to views from the buccal of mandibular first and second premolars in Figure 4.12.

### 1. CROWN SIZE AND SHAPE OF MANDIBULAR PREMOLARS FROM THE BUCCAL VIEW

As with all premolars and canines, the shape of premolar crowns (two-cusp or three-cusp type) from the facial view is roughly a five-sided *pentagon* (Appendix 5g). From this view, both types of mandibular premolars appear nearly symmetrical except for the shorter mesial than distal cusp ridge and a greater distal bulge of the crown. (This greater distal bulge may give the appearance of a slight distal tilt of the crown relative to the mid-root axis.)

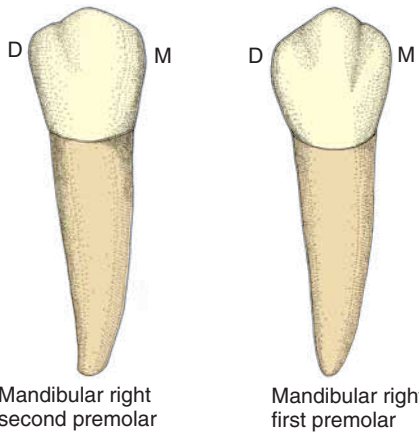
The crown of the **mandibular first premolar** bears considerable resemblance from this aspect to the second premolar, but there are differences that make first premolars distinguishable. Mandibular first premolars are slightly longer overall than second premolars with a noticeably longer crown (resembling a maxillary canine), but a slightly shorter root.<sup>U</sup> Just like on

Table 4-3

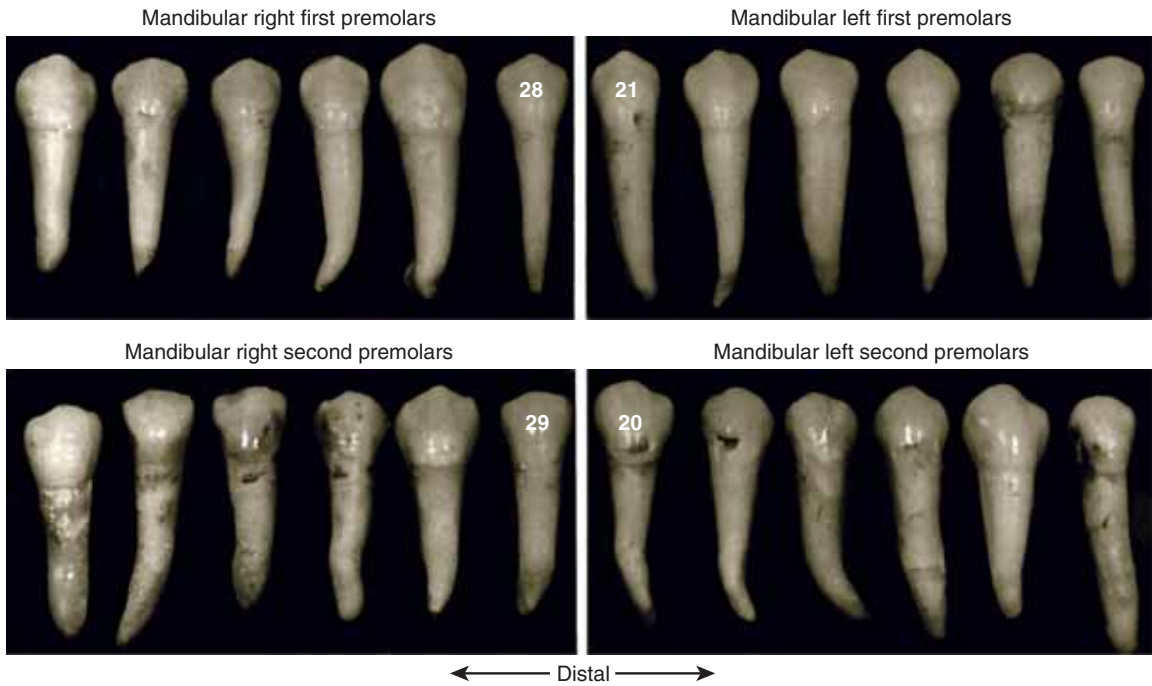
### OCCURRENCE OF LINGUAL CUSPS ON MANDIBULAR SECOND PREMOLARS (808 FEMALES, 1532 TEETH)

NUMBER AND FREQUENCY	PERCENTAGE	COMMENT
Two lingual cusps on both sides	44.2%	Almost half
One lingual cusp on both sides	34.2%	One third
Two lingual cusps on one side	18.2%	One fifth
Three lingual cusps on both sides	1.7%	1 in 29
Three lingual cusps on one side	1.7%	
Overall frequency	3-cusp type 54.2% 2-cusp type 43.0% 4-cusp type 2.8%	1532 teeth
Same type on both sides	80.1%	702 comparisons
Different type on each side	19.9%	





**MANDIBULAR PREMOLARS (buccal)**



**TRAITS TO DISTINGUISH MANDIBULAR FIRST FROM SECOND PREMOLAR: BUCCAL VIEWS**

**MANDIBULAR FIRST PREMOLAR**

- Longer crown
- More crown taper from contact to cervix
- More pointed cusp
- More prominent buccal ridge
- Shorter root with pointed apex

**MANDIBULAR SECOND PREMOLAR**

- Shorter wider crown
- Crown relatively wider at cervix
- Less pointed cusp
- Less prominent buccal ridge
- Longer root with blunt apex

**TRAITS TO DIFFERENTIATE MANDIBULAR RIGHT FROM LEFT PREMOLARS: BUCCAL VIEWS**

**MANDIBULAR FIRST MOLAR**

- Mesial cusp ridge notch more common
- Lower mesial than distal contact

**MANDIBULAR SECOND MOLAR**

- Distal cusp ridge notch more common
- Lower distal than mesial contact

Mesial cusp ridge is shorter than distal on both mandibular premolars

**FIGURE 4-12.** Buccal views of mandibular premolars with type traits to distinguish mandibular first from second premolars, and traits to distinguish rights from lefts.

maxillary premolars, the mandibular first premolar has a relatively sharper buccal cusp ( $110^\circ$ ) than the second.

The crown of the mandibular second premolar appears closer to square than the first premolar because it is shorter overall, it is wider in the cervical third, with a buccal cusp that is less pointed than on the mandibular first premolar, with cusp slopes meeting at an angle of about  $130^\circ$  (Appendix 6n).

## 2. LOCATION OF PROXIMAL CONTACTS ON MANDIBULAR PREMOLARS FROM THE BUCCAL VIEW

Because of the steeper angle formed by the cusp ridges of the buccal cusp, the contact areas on the mandibular first premolar appear more cervical from the cusp tip than they are on mandibular second premolars. On mandibular second premolars, both contact areas are positioned closer to the cusp tip or are in a more occlusal position than on the mandibular first premolars because the second's cusp ridges join at a less steep angle.

Mesial contacts of both types of mandibular premolars are near the junction of the occlusal and middle thirds (slightly more occlusal on second premolars). The distal contact of the mandibular second premolar follows the general rule: distal contact is slightly cervical to the mesial contact area (Appendix 6o). The distal contact area of the mandibular first premolar is an EXCEPTION to most other teeth: the distal contact area is slightly more occlusal in position than the mesial contact (Appendix 6o). The mandibular first premolar is the only adult tooth that has a more occlusally located distal than mesial contact. A summary of the location of contact areas in all types of premolars is presented in Table 4-4.

## 3. CUSP RIDGE NOTCHES AND DEPRESSIONS OF MANDIBULAR PREMOLARS FROM THE BUCCAL VIEW

Buccal ridges with adjacent vertical crown depressions are often seen on both types of mandibular premolars, but are less discernible on mandibular premolars than on the maxillary premolars.

Vertical depressions on the occlusal third on either side of the buccal ridge do not occur with great frequency, but when they do, they are more frequently deeper mesial to the buccal ridge on mandibular first premolars, and distal to the buccal ridge on mandibular second premolars.<sup>v</sup> On unworn premolars, shallow notches are more commonly seen on both the mesial and distal buccal cusp ridges, and like the vertical depressions, are more frequently located on the shorter mesial cusp ridge of the mandibular first premolar, and on the distal cusp ridge of mandibular second premolars<sup>w</sup> as seen in Figure 4-13. These notches serve as spillways for food during mastication (sometimes called Thomas notches, named after Peter K. Thomas, who recommended carving them in all occlusal restorations and crowns because spillways for food are so important).

## 4. ROOTS OF MANDIBULAR PREMOLARS FROM THE BUCCAL VIEW

The roots of mandibular premolars gradually taper to the apex. The roots apices are noticeably more blunt on mandibular second premolars than on first premolars. As with most roots, there is a tendency for the apical third of the root to bend distally, but note that as many as one-fifth may bend mesially.<sup>x</sup>

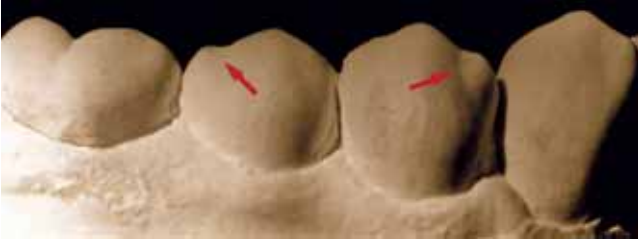Table 4-4

### PREMOLARS: LOCATION OF PROXIMAL CONTACTS (PROXIMAL HEIGHT OF CONTOUR) IN PREMOLARS (SEEN BEST FROM FACIAL VIEW)<sup>a</sup>

	MESIAL SURFACE (WHICH THIRD OR JUNCTION?)	DISTAL SURFACE (WHICH THIRD OR JUNCTION?)
MAXILLARY	First premolar	Middle third or occlusal/middle junction
	Second premolar	Middle third (near occlusal/middle junction)
MANDIBULAR	First premolar	Occlusal/middle junction or middle third
	Second Premolar	Occlusal/middle junction

<sup>a</sup> General learning guidelines:

1. For premolars, the mesial and distal contacts are closer to the middle of the tooth and are more nearly at the same level compared to anterior teeth.
2. Distal proximal contacts of premolars are more cervical than mesial contacts EXCEPT for mandibular first premolars where the mesial contact is more cervical than the distal.



**FIGURE 4-13.** Mandibular first and second premolars depicting the most common location of buccal cusp ridge notches and adjacent longitudinal buccal surface depressions: on the mesial half of the mandibular first premolar, and on the distal half of the mandibular second premolar (see arrows).

The roots of mandibular first premolars are almost as thick but slightly shorter than the roots of the second premolar.<sup>Y</sup> The roots of mandibular second premolars (like maxillary second premolars) are nearly twice as long as the crowns.

## B. TYPE TRAITS OF MANDIBULAR PREMOLARS FROM THE LINGUAL VIEW

For the lingual aspect, refer to lingual views of mandibular first and second premolars in *Figure 4-14*.

### 1. CROWN SHAPE OF MANDIBULAR PREMOLARS FROM THE LINGUAL VIEW

On mandibular first premolars, as on most teeth, the crown is much narrower mesiodistally on the lingual half than on the buccal half. This can also be seen on second premolars with one lingual cusp. However, the width of the lingual half of a second premolar with two lingual cusps is usually as wide or wider mesiodistally than the buccal half. ONLY this three-cusp mandibular second premolar and some maxillary first molars have their crowns wider on the lingual half than on the buccal half.

### 2. LINGUAL CUSPS AND GROOVES OF MANDIBULAR PREMOLARS FROM THE LINGUAL VIEW

The lingual cusp of a mandibular first premolar is quite small and short and is often pointed at the tip. It is nonfunctional, and could be considered a transition between the canine cingulum and more prominent lingual cusp (or cusps) of the second premolar (best appreciated from the proximal views in *Fig. 4-17*). Much of the occlusal surface of this tooth can be seen from the

lingual aspect because of the most obvious shortness of the lingual cusp. This tooth may have almost no lingual cusp or as many as four lingual cusplets.

On mandibular second premolars with one lingual cusp, the single lingual cusp is smaller than the buccal cusp, but it is relatively larger (longer and wider) than the lingual cusp of the first premolar. The single lingual cusp tip is most often just *mesial* to the center line of the root (*Appendix 6q*). In the two lingual cusp variation, there is one large buccal and two smaller lingual cusps. The mesiolingual cusp is almost always larger and longer than the distolingual cusp, but this difference may be little or great.<sup>AA</sup> The mesiolingual cusp tip is *mesial* to the midline of the root, similar to the lingual cusp of a two cusp premolar.

### 3. MARGINAL RIDGES OF MANDIBULAR PREMOLARS FROM THE LINGUAL VIEW

From the lingual view, differences in marginal ridge heights are apparent on handheld teeth when rotating the tooth first enough in one direction to see the mesial marginal ridge height, then enough in the opposite direction to compare the distal ridge height. As with most other posterior teeth, the *distal* marginal ridges of the mandibular second premolars are slightly more cervically located than the mesial marginal ridges as is evident on all mandibular second premolars in *Figure 4-14*. An EXCEPTION to all other adult teeth is the mandibular first premolar, the only tooth where the mesial marginal ridge is more cervically located than the distal marginal ridge as is evident in *Figure 4-14* for many mandibular first premolars. This is similar to the UNIQUE relative location of the mesial *proximal contact* of the mandibular first premolar (more cervical) and the distal proximal contact (more occlusal).

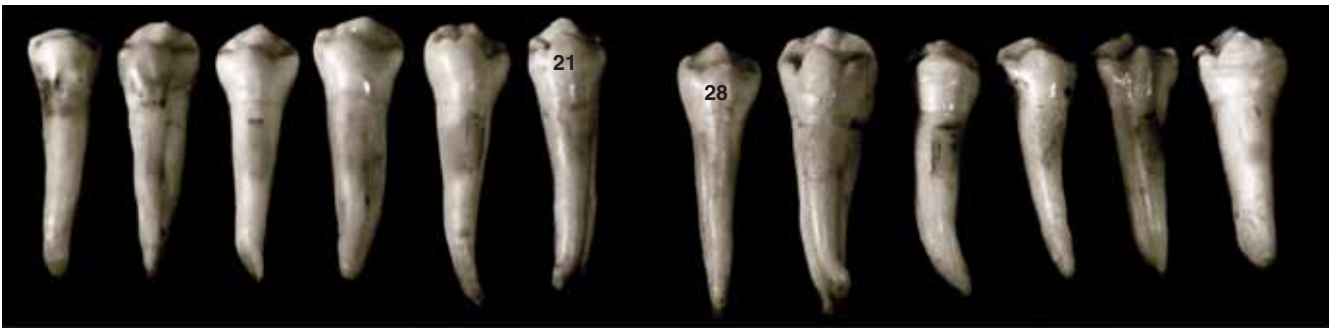### 4. GROOVES ON MANDIBULAR PREMOLARS FROM THE LINGUAL VIEW

This difference in grooves extending onto the lingual surfaces of first and second mandibular premolars is seen best on occlusal views in *Figure 4-15*. On mandibular first premolars, there is frequently a mesiolingual groove separating the mesial marginal ridge from the mesial slope of the small lingual cusp.<sup>BB</sup> (Rarely, a similar groove might be present between the distal marginal ridge and the distal slope of the lingual cusp.) On mandibular second premolars with two lingual cusps, a lingual groove passes between the mesiolingual and distolingual cusps, and may extend slightly onto the lingual surface of the crown.

**MANDIBULAR PREMOLARS (lingual)**

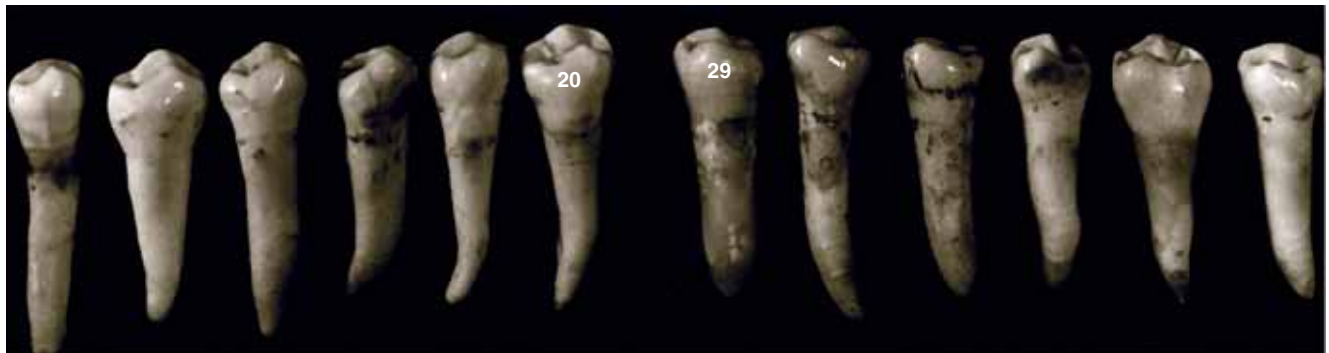Mandibular left first premolars

Mandibular right first premolars



Mandibular left second premolars

Mandibular right second premolars



← Distal →

**TRAITS TO DISTINGUISH MANDIBULAR FIRST FROM SECOND PREMOLAR: LINGUAL VIEWS**

**MANDIBULAR FIRST PREMOLAR**

- One lingual cusp
- Crown much narrower on lingual
- Lingual cusp very short, nonfunctional
- Mesiolingual groove
- Mesial marginal ridge lower than distal

**MANDIBULAR SECOND PREMOLAR**

- Most have two lingual cusps
- Crown quite wide on lingual
- Lingual cusp (or mesiolingual cusp) not as short as on firsts
- Lingual groove between two lingual cusps
- Distal marginal ridge lower than mesial

**TRAITS TO DIFFERENTIATE MANDIBULAR RIGHT FROM LEFT PREMOLARS: UNIQUE ON LINGUAL VIEWS**

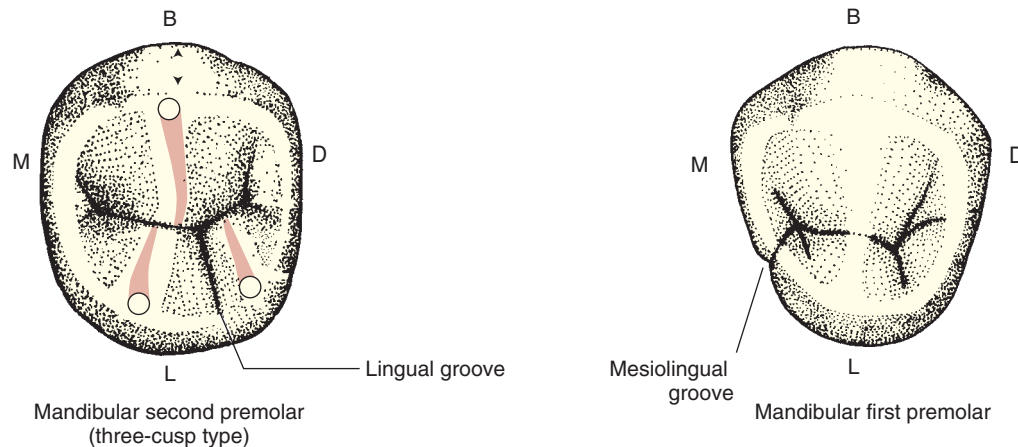
**MANDIBULAR FIRST PREMOLAR**

- Mesial marginal ridge lower than distal
- Mesiolingual groove often present

**MANDIBULAR SECOND PREMOLAR**

- Distal marginal ridge lower than mesial
- If two-cusp type, mesiolingual cusp is longer, larger
- Lingual (or mesiolingual) cusp tip is positioned to the mesial

**FIGURE 4-14.** Lingual views of mandibular premolars with type traits to distinguish mandibular first from second premolars, and traits to distinguish rights from lefts.



**FIGURE 4-15.** Variations in **grooves** extending onto the lingual surfaces of mandibular first and second (three-cusp type) premolars. The three-cusp type **mandibular second premolar** has a **lingual groove** which separates the two lingual cusps, and the **mandibular first premolar** most often has a **mesiolingual groove** that separates the mesial marginal ridge from the lingual cusp, and extends onto the “pushed in” mesiolingual portion of the tooth.

## 5. ROOTS OF MANDIBULAR PREMOLARS FROM THE LINGUAL VIEW

The roots of second mandibular premolars are tapered and only imperceptibly longer than the roots of first premolars.<sup>CC</sup>

### C. TYPE TRAITS OF MANDIBULAR PREMOLARS FROM THE PROXIMAL VIEWS

When studying the proximal views of mandibular first and second premolars, refer to *Figure 4-16*.

#### 1. CROWN SHAPE OF MANDIBULAR PREMOLARS FROM THE PROXIMAL VIEWS

Mandibular premolars are shaped like a *rhomboid* from the proximal view (Appendix 6b). A rhomboid is a four-sided figure with opposite sides parallel to one another, like a parallelogram. As on all mandibular posterior teeth, the crowns of the **mandibular first premolars** tilt noticeably toward the lingual surface at the cervix (much more than any other premolar). This tilt places the tip of the *buccal* cusp almost over the mid-root axis line (obvious on all mandibular first premolars in Fig. 4-16). As was also seen from the lingual aspect, the lingual cusp of the mandibular first premolar is considerably shorter than the buccal cusp by more than one third of the total crown length.<sup>7</sup> Since it is so short, it is considered a *nonfunctioning* cusp (Appendix 6p). The *lingual* cusp tip is so lingually positioned that it is usually aligned vertically with the lingual outline of the cervical portion of the root. The short lingual cusp also

results in an occlusal plane that approaches 45° relative to the long axis of the root.

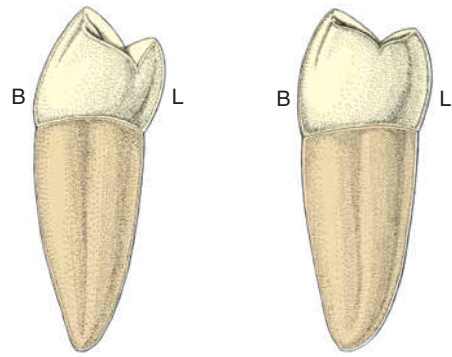
The **mandibular second premolar** crowns (both types) also tip lingually, but not as much as on the mandibular first premolar. The tip of the *buccal* cusp of the mandibular second premolar is usually located at the junction of the buccal and middle thirds. As with the first premolar, the tip of the *lingual* cusp (or of the mesiolingual cusp) of this second premolar is usually about on a vertical line with the lingual surface of the root at the cemento-enamel junction. A comparison of the lingual tilt of a mandibular first and second premolar is seen in *Figure 4-17*.

The lingual cusps (or mesiolingual cusps for three-cusp types) of **mandibular second premolars** are closer in length to the buccal cusp than on first premolars.<sup>DD</sup> When the three-cusp type is viewed from the *mesial*, the longer mesiolingual cusp conceals the shorter distolingual cusp, while viewing from the *distal*, both lingual cusp tips are usually visible (as seen on several mandibular second premolars viewed from the distal in Fig. 4-16).

#### 2. RIDGES OF MANDIBULAR PREMOLARS FROM THE PROXIMAL VIEWS

The *mesial* marginal ridge of the **mandibular first premolar** slopes cervically from the buccal toward the center of the occlusal surface at nearly a 45° angle and is nearly parallel to the triangular ridge of the buccal cusp (Fig. 4-18 and Appendix 6s). The *distal* marginal ridge of the mandibular first premolar is in a more horizontal position than its mesial marginal ridge, making the distal marginal ridge more occlusal than the mesial





MESIAL VIEWS

Mandibular right first premolar

Mandibular right second premolar

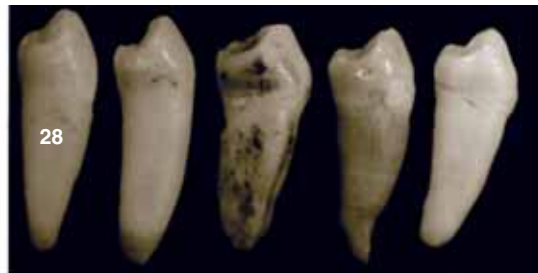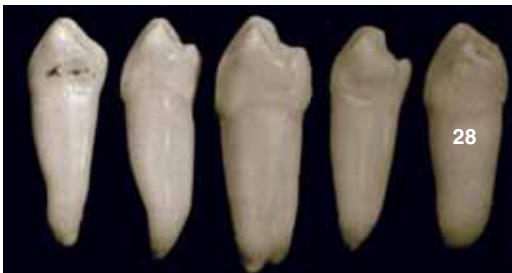**MANDIBULAR RIGHT PREMOLARS (proximal)**

MESIAL SURFACES

DISTAL SURFACES

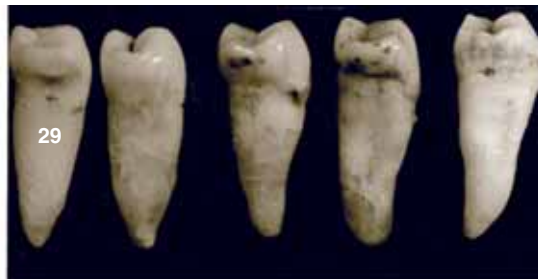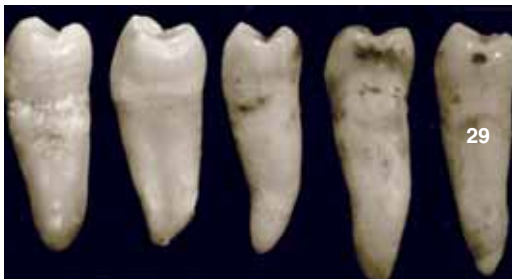Mandibular right first premolars

Mandibular right first premolars



Mandibular right second premolars

Mandibular right second premolars



← Buccal →

**TRAITS TO DISTINGUISH MANDIBULAR FIRST FROM SECOND PREMOLAR: PROXIMAL VIEWS**

**MANDIBULAR FIRST PREMOLAR**

- Mesial marginal ridge lower and parallel to buccal triangular ridge
- Severe lingual crown tilt
- Lingual cusp much shorter than buccal cusp
- Can see much of occlusal from mesial
- Mesiolingual groove on most seen from mesial

**MANDIBULAR SECOND PREMOLAR**

- Mesial marginal ridge higher and more horizontal
- Less lingual crown tilt
- Lingual cusp somewhat shorter than buccal cusp
- Cannot see much of occlusal from mesial
- Two lingual cusps on most visible from distal

**TRAITS TO DIFFERENTIATE MANDIBULAR RIGHT FROM LEFT PREMOLARS: PROXIMAL VIEWS**

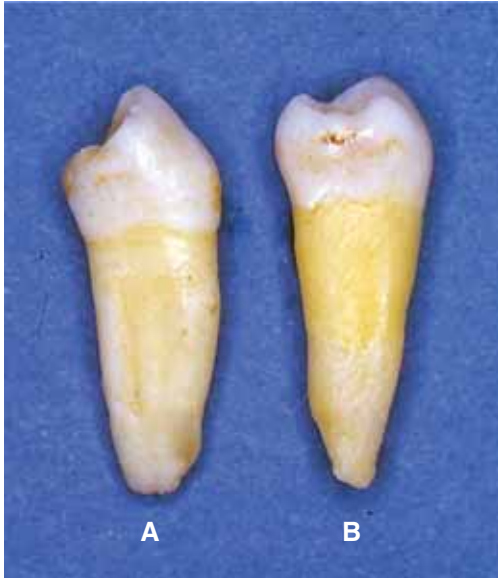**MANDIBULAR FIRST PREMOLAR**

- Mesial marginal ridge is lower than distal
- Mesial marginal ridge parallel to buccal triangle ridge
- More occlusal surface is visible from mesial

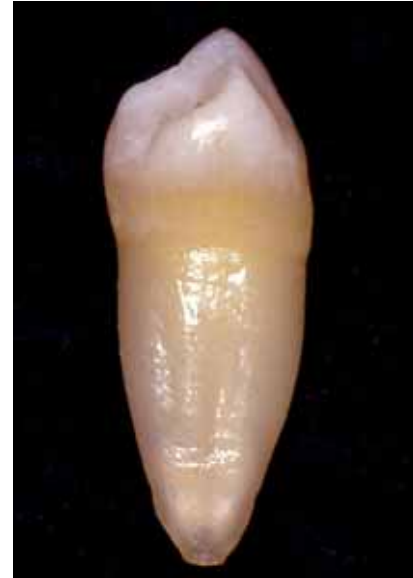**MANDIBULAR SECOND PREMOLAR**

- Distal marginal ridge is lower than mesial
  - Mesiolingual cusp larger than DL on three-cusp type
  - More occlusal surface is visible from distal
- Root depression is deeper on distal on both

**FIGURE 4-16.** Proximal views of mandibular premolars with type traits to distinguish mandibular first from second premolars, and traits to distinguish rights from lefts.



**FIGURE 4-17.** Mesial views of two mandibular premolars showing the obvious lingual tilt of the crown on both teeth. **A.** The tilt is greater on the mandibular *first* premolar, and the lingual cusp is so short that it is functionless. **B.** There is less lingual tilt on the mandibular *second* premolar, and the lingual cusp is not as short as on the first premolar.



**FIGURE 4-18.** Mesial view of a mandibular *first* premolar showing the steep angle of the **mesial marginal ridge** (about 45°). Also note that this marginal ridge is parallel to the steep triangular ridge of the buccal cusp.

marginal ridge, a trait UNIQUE to this tooth. The difference in marginal ridge angle and height is most helpful in differentiating rights from lefts (by identifying the more downward sloping and more cervical mesial marginal ridge). The triangular ridge of the lingual cusp is short and is in a nearly horizontal plane.

The more horizontal mesial marginal ridge of the **mandibular second premolar** is more occlusally located than the distal marginal ridge, which is more concave and definitely in a more cervical position (compare mesial and distal views in Fig. 4-16).

### 3. MARGINAL RIDGE GROOVES AND MESIOLINGUAL GROOVES ON MANDIBULAR PREMOLARS FROM THE PROXIMAL VIEWS

When viewed from the *mesial*, the mesiolingual groove on the **mandibular first premolar**<sup>BB</sup> can be seen separating the mesial marginal ridge from the mesial slope of the lingual cusp (Appendix 6r). When viewed from the *distal*, there is only rarely a groove between the distal marginal ridge and the distal slope of the lingual cusp.<sup>BB</sup>

Mesiolingual grooves are *not* present on **mandibular second premolars**, but the marginal ridges on these teeth may infrequently be crossed by a marginal ridge groove (very rarely on the distal marginal ridge).<sup>EE</sup>

On premolars with two lingual cusps, the shorter distolingual cusp may be seen from the distal view but not the mesial view (Fig. 4-16).

### 4. HEIGHT (CREST) OF CONTOUR OF MANDIBULAR PREMOLARS FROM THE PROXIMAL VIEWS

As on all teeth, the height of contour on the *buccal* surface of both types of mandibular premolar crowns is in the cervical third. On the **mandibular first premolar**, the buccal height of contour of the crown is just occlusal to the cervical line like the mandibular canine next to it, and its buccal crown outline is convex in its occlusal two thirds (Fig. 4-16). The buccal height of contour on the **mandibular second premolar** is near the junction of the cervical and middle thirds, and its buccal crown contour is flatter in its occlusal two thirds.

For *all* mandibular premolars, the height of contour of the *lingual* surface of the crown is in the middle third, about in the center of the total crown length. On the mandibular first premolar, this is not far from the cusp tip of the lingual cusp (clearly seen on mandibular first premolars in Fig. 4-16). Because of the extreme lingual tilting of the crown, the lingual surfaces of all mandibular premolar crowns extend lingually, well beyond the lingual surface of the root.

## 5. CERVICAL LINES OF MANDIBULAR PREMOLARS FROM THE PROXIMAL VIEWS

Similar to other teeth, the occlusal curve of the cervical line on the proximal surfaces of all premolars is slightly greater on the mesial surface than on the distal.<sup>FF</sup> The cervical line is also located more occlusally on the *lingual* than on the buccal. This makes the crowns appear to be quite short on the lingual side.

## 6. ROOTS OF MANDIBULAR PREMOLARS FROM THE PROXIMAL VIEWS

Both types of mandibular premolar roots taper apically, with the least taper in the cervical third.

## 7. ROOT DEPRESSIONS OF MANDIBULAR PREMOLARS FROM THE PROXIMAL VIEWS

Mandibular first premolars have a shallow longitudinal depression in the apical and middle thirds of the *mesial* root surface almost half of the time but are more likely to have a longitudinal depression on the *distal* surface, and this distal depression is most often deeper than on the mesial.<sup>GG</sup> Most mandibular second premolars have no depression on the *mesial* root surface but are likely to have a longitudinal depression in the middle third of the *distal* root surface.

To summarize, *all* types of mandibular and maxillary premolars are, on average, likely to have a more prominent root depression on the distal root surface than on the mesial EXCEPT the maxillary first premolar, which is more likely to have its more prominent root depression on the mesial surface. See *Table 4-5* for a summary of the location and relative depth of root depressions on all types of premolars.

## D. TYPE TRAITS OF MANDIBULAR PREMOLARS FROM THE OCCLUSAL VIEW

For the occlusal view of mandibular first and second premolars, refer to *Figure 4-19*. To follow this description, the teeth or tooth models should be held with the occlusal surface toward the observer and the buccal surface up, and the observer looking exactly along the vertical mid-root axis. Much of the buccal surface is visible from this view since the tip of the buccal cusp is slightly buccal to tooth center from this view (clearly seen in almost all mandibular first premolars in *Fig. 4-19*).

### 1. OUTLINE SHAPE OF MANDIBULAR PREMOLARS FROM THE OCCLUSAL VIEW

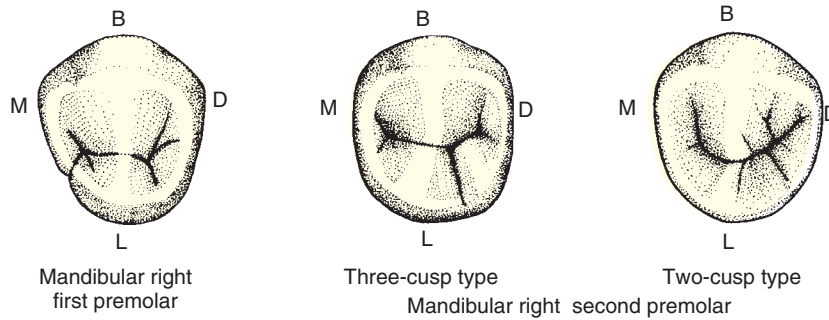
There is much variation in the occlusal morphology of mandibular first premolars.<sup>2</sup> The outline of the crown is usually not symmetrical (more bulk in the distal half) as seen in practically all mandibular first premolars in *Figure 4-19*. It often looks as though the *mesiolingual portion of the crown outline has been pushed in* (*Appendix 6u*). This results in a somewhat *diamond-shaped* outline (also *Appendix 6u*). This “pushed in” mesiolingual portion is a reliable trait to identify a mandibular first premolar, and its mesial surface (*Fig. 4-20*). On these asymmetrical mandibular first premolars, the distal marginal ridge forms close to a right angle with the distal cusp ridge of the buccal cusp, whereas the mesial marginal ridge meets the mesiobuccal cusp ridge at a more acute angle. Sometimes, however, the mesial and distal marginal ridges may converge symmetrically toward the lingual cusp in such a way that the occlusal table (surface) is nearly an equilateral *triangle* with the

**Table 4-5 OCCURENCE AND RELATIVE DEPTH OF LONGITUDINAL ROOT DEPRESSIONS (“ROOT GROOVES”) IN PREMOLARS<sup>a</sup>**

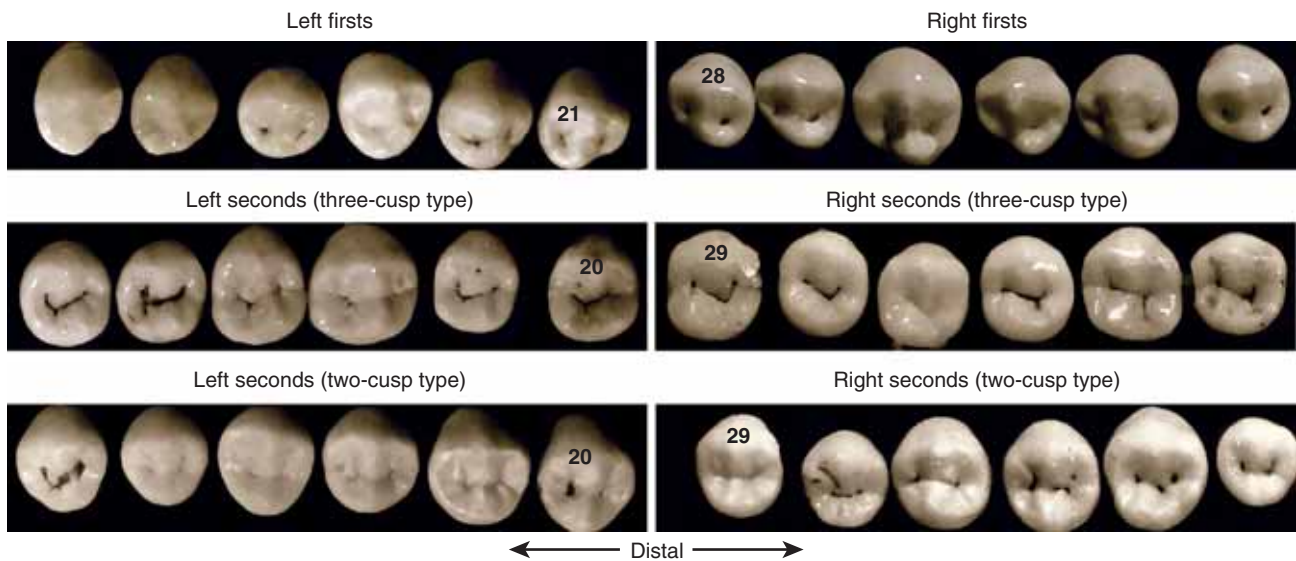
	TOOTH TYPE	MESIAL ROOT DEPRESSION?	DISTAL ROOT DEPRESSION?
MAXILLARY	Maxillary first premolar	Yes (deeper, extends onto mesial of crown which is UNIQUE to this premolar)	Yes
	Maxillary second premolar	Yes	Yes (deeper)
MANDIBULAR	Mandibular first premolar	Yes (or no: about 50%)	Yes (deeper)
	Mandibular second premolar	No (unlikely)	Yes (deeper)

<sup>a</sup>General learning guideline:

Premolars are likely to have deeper distal surface root depressions (EXCEPT maxillary first premolars).



### MANDIBULAR PREMOLARS (occlusal)



#### TRAITS TO DISTINGUISH MANDIBULAR FIRST FROM SECOND PREMOLAR: OCCLUSAL VIEWS

##### MANDIBULAR FIRST PREMOLAR

Outline diamond shaped  
 Smaller occlusal table  
 Outline converges toward lingual, especially on mesial  
 Mesiolingual groove common  
 Two fossae (mesial and distal)

Definite transverse ridge  
 Groove unlikely across transverse ridge

Lingual cusp smaller than buccal

##### MANDIBULAR SECOND PREMOLAR

Outline nearly square or round  
 Larger occlusal table  
 Outline may be wider on lingual on three-cusp type  
 Lingual groove on three-cusp type  
 Two fossae (mesial and distal) on two-cusp type but three fossae on three-cusp type  
 Three-cusp type has no transverse ridge  
 "Y" groove pattern on three-cusp type  
 "H" or "U" groove pattern on two-cusp type  
 Lingual half larger than buccal if two lingual cusps

#### TRAITS TO DIFFERENTIATE MANDIBULAR RIGHT FROM LEFT PREMOLARS: OCCLUSAL VIEWS

##### MANDIBULAR FIRST MOLAR

Crown convex on distal but mesiolingual portion is flat (or pushed in)  
 Mesiolingual groove common

Distal fossa larger than mesial fossa

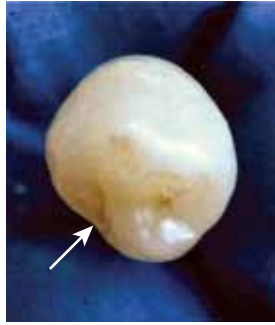##### MANDIBULAR SECOND MOLAR

Often wider faciolingually on distal than mesial

Mesiolingual cusp larger than distolingual (three-cusp)  
 Lingual cusp tip more mesial (two-cusp type)  
 Distal fossa larger (two-cusp type)  
 Distal fossa smallest (three-cusp type)

**FIGURE 4-19.** Occlusal views of mandibular premolars with type traits to distinguish mandibular first from second premolars, and traits to distinguish rights from lefts.





**FIGURE 4-20.** This “pushed in” outline on the mesial half of the lingual cusp (arrow), and an overall diamond-shaped outline, are both traits of many mandibular first premolars.

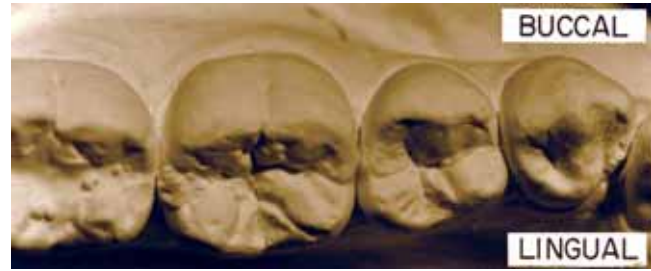base made up of the buccal cusp ridges, and the apex is the lingual cusp tip as illustrated in red on Figure 4-24. On this symmetrical type of mandibular first premolar, it is more difficult to determine right from left by only looking at the occlusal design.

The mesial and distal cusp ridges of the buccal cusp on the **mandibular first premolars** are nearly aligned in a straight line mesiodistally. The contact areas, as seen from the occlusal view, are at the point of broadest mesiodistal dimension just lingual to this line of the buccal cusp ridges. On the mandibular first premolar, the buccal ridge is not prominent, and the buccal crest of contour, like the buccal cusp tip, is slightly mesial to center. The crest of contour of the lingual surface is often distal to the middle mesiodistally of the tooth.

On the **two-cusp second premolars**, the crown outline is *round or oval* shaped, but with a relatively *square* occlusal table. The crown outline tapers to the lingual, so the crown outline is more broadly curved on the buccal side than on the lingual side. The *lingual* cusp tip is often off center toward the *mesial* half of the crown.

On the **three-cusp second premolars**, the occlusal outline is more nearly *square* than is the occlusal outline of the two-cusp type because its crown is wider lingually with two lingual cusps. When the lingual cusps are large, the occlusal surface is broader mesiodistally on the lingual half than on the buccal half (Fig. 4-21). This is an **EXCEPTION** to all types of two-cusp premolars in both arches that normally taper narrower toward the lingual. Further, more than half of the time, three-cusp premolar teeth have greater faciolingual bulk in the distal than mesial half of the crown (tapering smaller from distal to mesial), which is an **EXCEPTION** to the normal taper to the distal<sup>HH</sup> (Fig. 4-21). Examples of differences in crown taper are seen on mandibular second premolars in Figure 4-19.

A summary of the geometric outline shapes of premolars is presented in Figure 4-22.



**FIGURE 4-21.** Mandibular second premolar (three-cusp type) that is *wider mesiodistally in the lingual half than in the buccal half*, and *wider buccolingually in the distal half*, both **UNIQUE** traits of this premolar. Note that the distolingual cusp on this second premolar appears almost as wide as the mesiolingual cusp (which is not common) and that this tooth is larger than the first premolar (a common occurrence on mandibular premolars unlike maxillary premolars). Also observe the pronounced mesiolingual groove on the first premolar.

## 2. OCCLUSAL MORPHOLOGY OF MANDIBULAR PREMOLARS FROM THE OCCLUSAL VIEW

### a. Ridges, Fossae, and Grooves of the Mandibular First Premolars from the Occlusal View

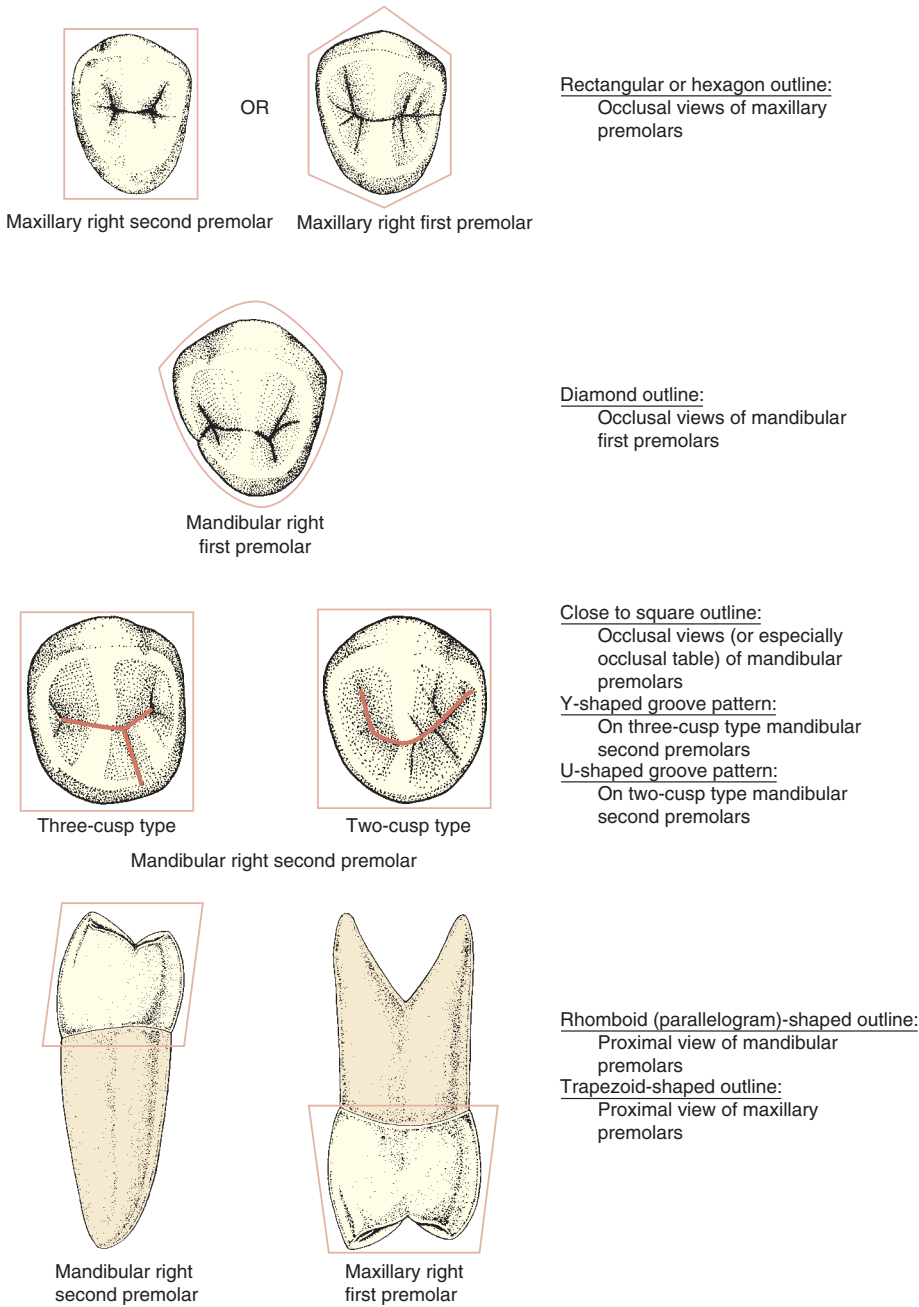
Due to the much larger buccal than lingual cusp on the **mandibular first premolar**, the triangular ridge of the buccal cusp is long and slopes lingually from the cusp tip to where it joins the very short triangular ridge of the lingual cusp. Most often the two triangular ridges unite smoothly near the center of the occlusal surface and form an uninterrupted very prominent transverse ridge that completely separates the mesial and distal fossae. The mesial fossa is more linear buccolingually, but the distal fossa is more frequently larger or deeper.<sup>11</sup> Each fossa has a pit. Both of these deep pits are susceptible to decay (caries) and are therefore often restored with two separate restorations (Fig. 4-23).

Only rarely is the pronounced transverse ridge of the mandibular first premolar crossed by a fissured central groove, which may extend from the mesial pit across the transverse ridge to the distal pit. More commonly, there are mesial and distal developmental grooves running in a nearly buccolingual direction, flaring buccally from the mesial and distal fossae (Fig. 4-24). The mesiolingual groove (when present) may appear to be continuous with this mesial groove.

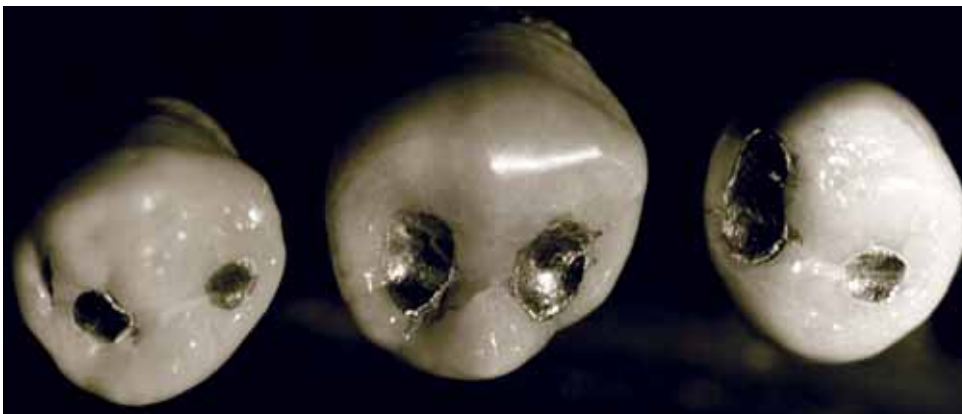### b. Ridges, Fossae, and Grooves of the Two-Cusp Mandibular Second Premolars from the Occlusal View

On the **two-cusp type mandibular second premolar**, as on the mandibular first premolar, the lingual cusp is smaller than the buccal cusp. There is a large triangular

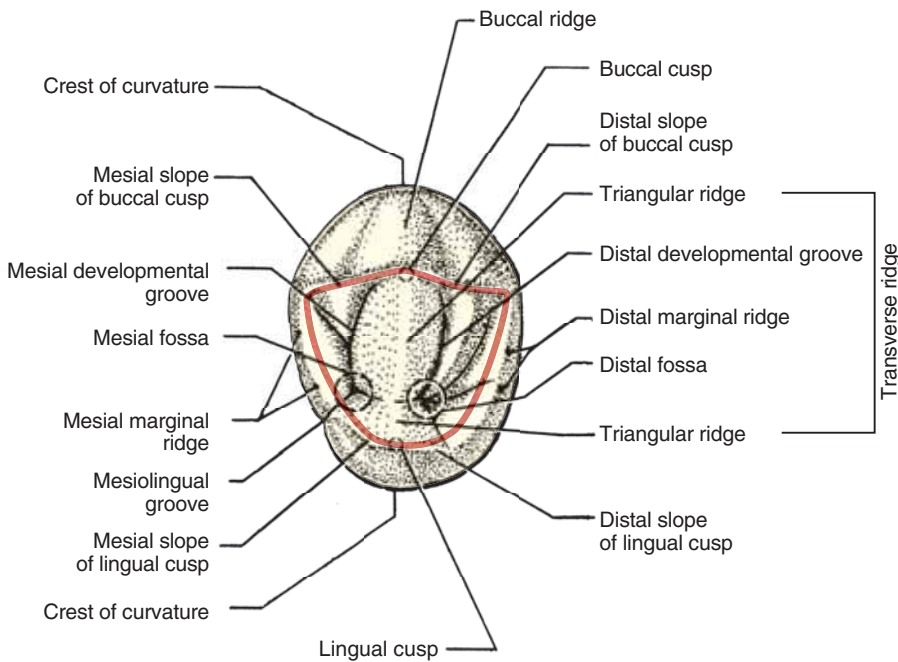




**FIGURE 4-22.** Examples of **geometric outlines** of premolars from the occlusal and proximal views.



**FIGURE 4-23.** Two left and one smaller, right **mandibular first premolars** have **separate restorations** in the mesial and distal pits due to the prominent transverse ridge with no central groove. These restorations are inappropriately nicknamed by dental students as “snake eyes.”



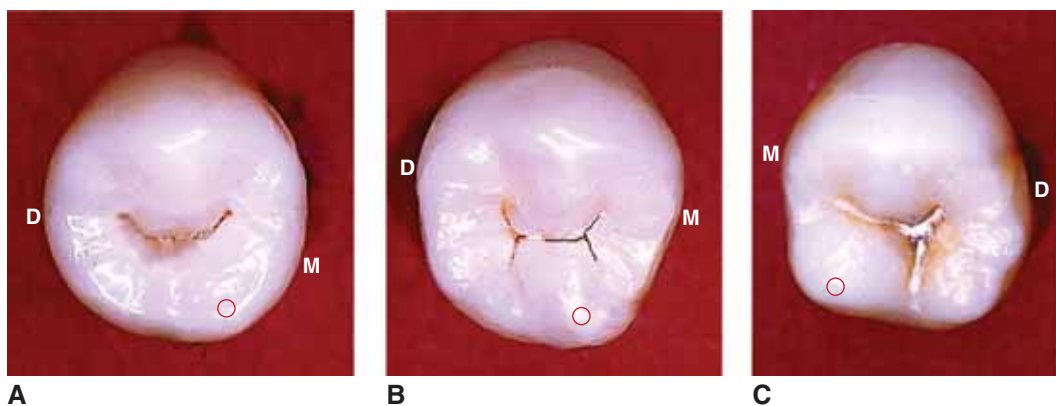
**FIGURE 4-24.** Occlusal surface of a **mandibular right first premolar** with normal landmarks. Notice the flatter (almost concave) mesiolingual outline compared to the more convex distolingual outline. Also notice the somewhat *triangular* shape of the occlusal table (outlined in red).

ridge on the buccal cusp and a correspondingly smaller one on the lingual cusp that join to form a transverse ridge. On this **second premolar**, there is a central developmental groove that extends mesiodistally across the occlusal surface from the larger distal fossa to the mesial fossa but no lingual groove. Sometimes this groove is short and nearly straight, with mesial and distal fossa grooves that together form an “H” shape. Sometimes the curved central groove ends in a mesial and distal fossa, where it often joins a mesiobuccal and distobuccal groove to form a “U” shape (Fig. 4-25).

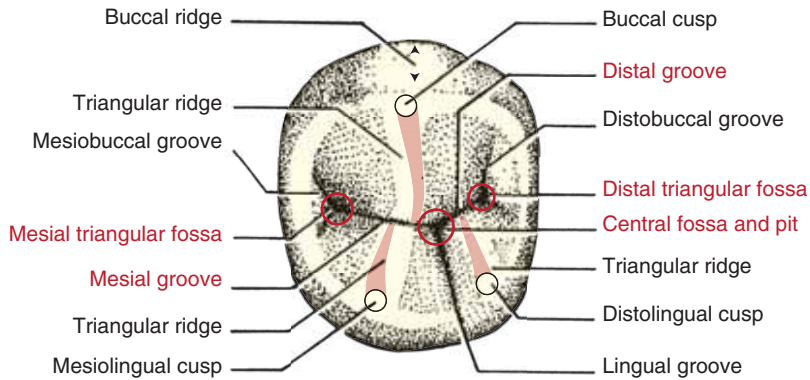
Mandibular second premolars (two-cusp type), as on maxillary second premolars, have more numerous supplemental grooves on their occlusal surfaces than do first premolars.<sup>4</sup>

**c. Ridges, Fossae, and Grooves of the Three-Cusp Mandibular Second Premolar**

The three-cusp mandibular second premolar has a mesial and distal fossa like all other premolars, but it is the only premolar to have a *central fossa*. This fossa is located



**FIGURE 4-25.** Variations in groove patterns, and similarities in lingual cusp placement, on mandibular second premolars (occlusal views). All types of mandibular second premolars are likely to have the lingual cusp tip (or longest lingual cusp tip) located *mesial* to the crown center. **A.** Mandibular left second premolar (two-cusp type). The single *lingual* cusp is *mesial* to the center line, and the central groove is *U-shaped*. **B.** Mandibular left second premolar (two-cusp type) with the *lingual* cusp *mesial* to the center line, and an *H-shaped* groove pattern. **C.** Mandibular right second premolar (three-cusp type) with its larger mesiolingual cusp tip *mesial* to the center line, and a *Y-shaped* groove pattern.



**FIGURE 4-26.** Mandibular right second premolar (three-cusp type) showing common occlusal landmarks. Note that the **three triangular ridges do not join** to form a transverse ridge. Also, the groove that runs between the mesial and distal pits join at a central pit, so the longer groove mesial to the central pit is called **mesial groove** and the shorter groove distal to the central pit is called the **distal groove**.

quite distal to the center of the occlusal surface and in the middle buccolingually. This tooth appears to have a central groove, but it may be more precisely a **mesial groove** (mesial to the central fossa) and a **distal groove** (distal to the central fossa). The longer mesial groove extends from a small mesial triangular fossa to the largest central fossa.<sup>JJ</sup> The shorter distal groove continues from the largest central fossa to the minute distal triangular fossa (Fig. 4-26). The distal triangular fossa is so small that it appears to be at the outer edge of the central fossa.

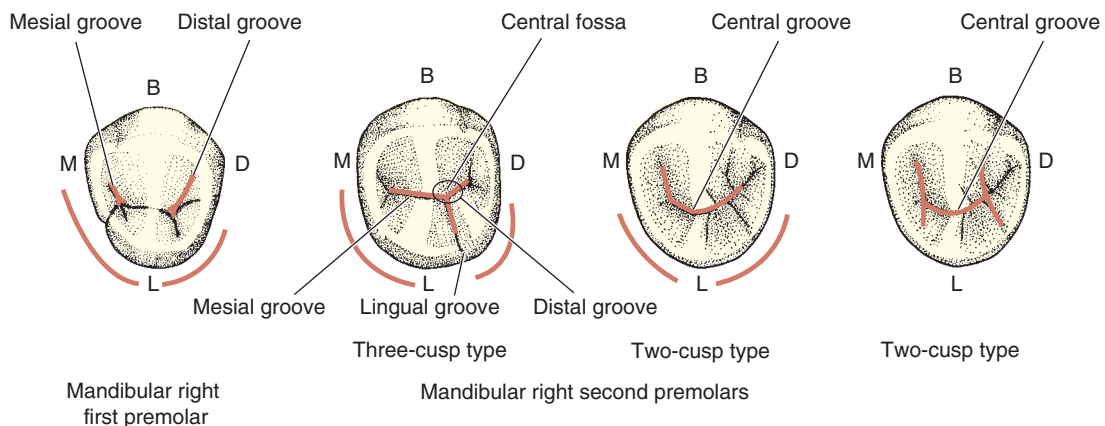
The three-cusp type of mandibular second premolar is the only premolar to have a lingual groove. This lingual groove begins in the central fossa at the junction of the mesial and distal grooves, and extends lingually between the mesiolingual and distolingual cusps and sometimes onto the lingual surface. The mesial, distal,

and lingual grooves join to form a Y-shaped occlusal groove pattern **UNIQUE** to this tooth (Fig. 4-27C). Differences in occlusal groove patterns on mandibular premolars are highlighted in *Figure 4-27*.

There are three triangular ridges: one on each of the two lingual cusps and one on the buccal cusp. These three ridges converge somewhat toward the central fossa (Fig. 4-26) but *do not join* to form a transverse ridge.

#### d. Marginal Ridge Grooves of Mandibular Premolars from the Occlusal View

On both the two-cusp and three-cusp second premolar types, grooves crossing the marginal ridges (that is, marginal ridge grooves) are not common.<sup>KK</sup> The first premolar is much more likely to have a mesiolingual groove.



### MANDIBULAR PREMOLARS (OCCLUSAL)

**FIGURE 4-27.** Red lines accentuate differences in **groove patterns** and **lingual taper** found on different types of mandibular premolars. The **mandibular first premolar** has a lack of symmetry on the lingual half because the mesiolingual portion is “pushed in” or flattened, and is often crossed by a mesiolingual groove. It often has two separate pits that are not joined by a central groove due to the prominence of the transverse ridge. The **three-cusp type mandibular second premolar** can be as wide in the lingual half (or even wider) compared to the buccal half since it has two lingual cusps. The groove pattern is Y-shaped with the mesial, distal and lingual grooves intersecting in the central fossa. The **two-cusp type mandibular second premolar** is the most symmetrical of the three types, and may have a groove pattern that is *U- or H-shaped*.

### LEARNING EXERCISE

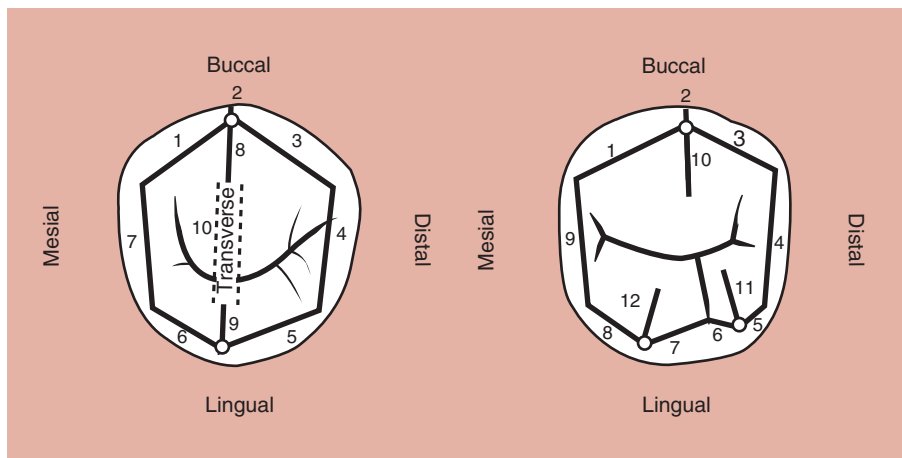
Suppose a patient just had all of his or her permanent teeth extracted and you were asked to find tooth No. 4 from among a pile of 32 extracted teeth on the oral surgeon's tray because you wanted to evaluate a lesion on the root of that premolar that had been seen on the radiograph. How might you go about it? Try the following steps:

- From a selection of all permanent teeth (extracted teeth or tooth models), select only the premolars (based on **class traits**).
- Determine whether each premolar is maxillary or mandibular (based on **arch traits**). You should never rely on only one characteristic difference between teeth to name them; rather, make a list of many traits that suggest the tooth is a maxillary

### Learning Exercise, cont.

lary premolar, as opposed to only one trait that makes you think it belongs in the maxillary arch. This way you can play detective and become an expert at recognition at the same time.

- If you determine that the tooth is maxillary, position the root up; if it is mandibular, position the root down.
- Use characteristic traits for each surface to identify the buccal surface. This will permit you to view the tooth as though you were looking into a patient's mouth.
- Next, using type traits, determine the type of premolar you are holding (first or second).
- Finally, determine which surface is the mesial. While viewing the premolar from the facial and



A. Name the ridges

Ridges	Name
1.	_____
2.	_____
3.	_____
4.	_____
5.	_____
6.	_____
7.	_____
8.	_____
9.	_____
10.	_____

B. Name the ridges

Ridges	Name
1.	_____
2.	_____
3.	_____
4.	_____
5.	_____
6.	_____
7.	_____
8.	_____
9.	_____
10.	_____
11.	_____
12.	_____

**FIGURE 4-28.** Name each ridge on the mandibular second premolar, two-cusp type, in *Figure 4-28A*. Also, name each ridge on the mandibular second premolar, three-cusp type, in *Figure 4-28B*.

**ANSWERS:** A. Ridges for two-cusp type: 1—mesial cusp ridge of buccal cusp; 2—buccal ridge; 3—distal cusp ridge of buccal cusp; 4—distal marginal ridge; 5—distal cusp ridge of lingual cusp; 6—mesial cusp ridge of lingual cusp; 7—mesial marginal ridge; 8—triangular ridge of buccal cusp; 9—triangular ridge of lingual cusp; 10—transverse ridge.

B. Ridges for three-cusp type: 1—mesial cusp ridge of buccal cusp; 2—buccal ridge; 3—distal cusp ridge of buccal cusp; 4—distal marginal ridge; 5—distal cusp ridge of distolingual cusp; 6—mesial cusp ridge of distolingual cusp; 7—distal cusp ridge of mesiolingual cusp; 8—mesial cusp ridge of mesiolingual cusp; 9—mesial marginal ridge; 10—triangular ridge of buccal cusp; 11—triangular ridge of distolingual cusp; 12—triangular ridge of mesiolingual cusp.

**FIGURE 4-28.** (Continued).

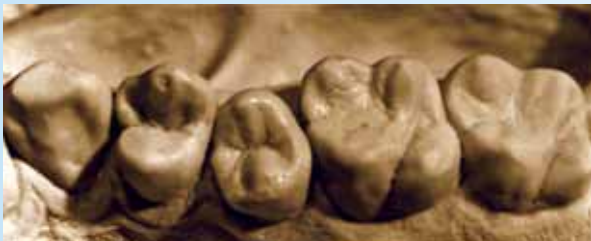#### Learning Exercise, cont.

picturing it within the appropriate arch (upper or lower), the mesial surface can be positioned toward the midline in only one quadrant, the right or left.

#### Learning Exercise, cont.

- Once you have determined the quadrant, assign the appropriate Universal number for the premolar in that quadrant. For example, the second premolar in the upper right quadrant is tooth No. 4.

### LEARNING EXERCISE



**FIGURE 4-29.** What is wrong with the teeth in this photograph?

**ANSWER:** The maxillary second premolar appears rotated so that its lingual surface is facing in a buccal direction. In this person, the buccal half of this maxillary second premolar is narrower mesiodistally than the lingual half, but in both types of maxillary premolars, the lingual half should be narrower mesiodistally (as seen on the adjacent first premolar).

## Critical Thinking

- During an oral examination, you are charting the teeth that are present in Heather's mouth. Heather is a 24-year-old dental hygiene student. All of her teeth are present, except on her left side; there is only one mandibular premolar, not two as expected. How can you go about determining whether this premolar is a first or second? Identify all premolar traits that could be helpful in making this decision. What follow-up procedure may be needed?
- Name as many traits as possible that distinguish a mandibular second premolar (*two-cusp type*) from a mandibular first premolar in the same quadrant. State the views that best show each trait.



## Review Questions

For each of the following traits or statements, circle the letter (or letters) of the premolars (if any) that apply. More than one answer may be correct.

- a. Maxillary first premolar
- b. Maxillary second premolar
- c. Mandibular first premolar
- d. Mandibular second premolar (two-cusp type)
- e. Mandibular second premolar (three-cusp type)

- |  |           |
|--|-----------|
| 1. Mesial cusp ridge of the buccal cusp is longer than the distal cusp ridge.  | a b c d e |
| 2. Has a nonfunctioning lingual cusp.  | a b c d e |
| 3. Two premolars that most frequently have a groove crossing the mesial marginal ridge or one groove just lingual to it. | a b c d e |
| 4. Has a depression in the cervical one third of the mesial side of the crown and root.                                  | a b c d e |
| 5. Maxillary premolar that has the longer sharper buccal cusp.   | a b c d e |
| 6. Largest maxillary premolar.   | a b c d e |
| 7. Mandibular premolar with the longest and sharpest buccal cusp.  | a b c d e |
| 8. Maxillary premolar that is most symmetrical (occlusal view).  | a b c d e |
| 9. Two premolars without a central groove.   | a b c d e |
| 10. Crowns tipped lingually with respect to the root axis line (proximal view).  | a b c d e |
| 11. From buccal view, crown is tipped distally from the root axis.   | a b c d e |
| 12. Mesial marginal ridge is more cervically located than its distal marginal ridge.                                     | a b c d e |
| 13. Has no transverse ridge.   | a b c d e |
| 14. Has the longer central groove.   | a b c d e |
| 15. Has two major cusps almost the same size and length.   | a b c d e |
| 16. Has a central fossa.   | a b c d e |
| 17. Premolars with only two fossae: both are triangular fossae.  | a b c d e |
| 18. Has a central fossa and two triangular fossae.   | a b c d e |
| 19. Has a lingual groove.  | a b c d e |

**ANSWERS:** 1—a; 2—c; 3—a, c; 4—a; 5—a; 6—a; 7—c; 8—b; 9—c; 10—c, d, e; 11—c, d, e; 12—c; 13—e; 14—a; 15—b; 16—e; 17—a, b; 18—e; 19—e

## REFERENCES

1. Morris DH. Maxillary premolar variations among Papago Indians. *J Dent Res* 1967;46:736–738.
2. Kraus BS, Furr ML. Lower first premolars. Part I. A definition and classification of discrete morphologic traits. *J Dent Res* 1953;32:554.
3. Ludwig FJ. The mandibular second premolar: morphologic variations and inheritance. *J Dent Res* 1957;36:263–273.
4. Brand RW, Isselhard DE. *Anatomy of orofacial structures*. St. Louis: C.V. Mosby, 1998.

## GENERAL REFERENCES

- Grundler H. *The study of tooth shapes: a systematic procedure*. (Weber L, trans.) Berlin: Buch-und Zeitschriften-Verlag “Die Quintessenz,” 1976.
- Oregon State System of Higher Education. *Dental anatomy: a self-instructional program*. 9th ed. East Norwalk: Appleton-Century-Crofts, 1982.
- Renner RP. *An introduction to dental anatomy and esthetics*. Chicago, IL: Quintessence Publishing, 1985.



## Dr. Woelfel’s Original Research Data

Statistics obtained from Dr. Woelfel’s original research on teeth have been used to draw conclusions throughout this chapter, and were referenced with superscript letters that refer to the data stated here. *Tables 4-6A and 4-6B* include the original data obtained by Dr. Woelfel.

- A. Fifty-four percent of mandibular second premolars have three cusps (two lingual cusps).
- B. Maxillary premolar crowns average 0.8 to 3.5 mm shorter than anterior tooth crowns, and mandibular premolars average 0.3 to 2.5 mm shorter than anterior tooth crowns.
- C. Based on measurements on 1472 teeth, maxillary premolar roots average within 1 mm of maxillary incisor roots, but were 2.5 to 3.1 mm shorter than maxillary canine roots. Mandibular premolar roots average 1 to 1.9 mm longer than mandibular incisor roots but average 1.3 mm shorter than mandibular canine roots.
- D. Measuring 923 premolars, all types of premolar crowns average 1.2 mm wider faciolingually than mesiodistally, and their roots average 2.8 mm wider faciolingually than mesiodistally.
- E. Based on 458 maxillary premolars, the crowns of firsts average 0.5 mm wider mesiodistally and 0.9 mm longer than on seconds, but the roots of firsts average 0.6 mm shorter.
- F. Buccal longitudinal crown depressions in the occlusal third were more prominent mesial to the buccal ridge on 52% of 452 maxillary first premolars, but distal to the buccal ridge only 2% of the time. On 506 maxillary second premolars, crown depressions were found only 27% of the time, occurring more frequently distal to the buccal ridge.
- G. On 343 maxillary second premolars, 58% of the roots bent distally. On 426 maxillary first premolars, 66% of the roots bent distally.
- H. On 200 maxillary first premolars, 61% had two roots, 38% had one root, and 1% had three roots.

**Table 4-6A** SIZE OF MAXILLARY PREMOLARS (MILLIMETERS) (MEASURED BY DR. WOELFEL AND HIS DENTAL HYGIENE STUDENTS, 1974–1979)

DIMENSION MEASURED	234 FIRST PREMOLARS		224 SECOND PREMOLARS	
	Average	Range	Average	Range
Crown length	8.6	7.1–11.1	7.7	5.2–10.5
Root length	13.4	8.3–19.0	14.0	8.0–20.6
Overall length	21.5	15.5–28.9	21.2	15.2–28.4
Crown width (mesiodistal)	7.1	5.5–9.4	6.6	5.5–8.9
Root width (cervix)	4.8	3.6–8.5	4.7	4.0–5.8
Faciolingual crown size	9.2	6.6–11.2	9.0	6.9–11.6
Faciolingual root (cervix)	8.2	5.0–9.4	8.1	5.8–10.5
Mesial cervical curve	1.1	0.0–1.7	0.9	0.4–1.9
Distal cervical curve	0.7	0.0–1.7	0.6	0.0–1.4

Table 4-6B

**SIZE OF MANDIBULAR PREMOLARS (MILLIMETERS) (MEASURED BY DR. WOELFEL AND HIS DENTAL HYGIENE STUDENTS, 1974–1979)**

DIMENSION MEASURED	238 FIRST PREMOLARS		227 SECOND PREMOLARS	
	Average	Range	Average	Range
Crown length	8.8	5.9–10.9	8.2	6.7–10.2
Root length	14.4	9.7–20.2	14.7	9.2–21.2
Overall length	22.4	17.0–28.5	22.1	16.8–28.1
Crown width (mesiodistal)	7.0	5.9–8.8	7.1	5.2–9.5
Root width (cervix)	4.8	3.9–7.3	5.0	4.0–6.8
Faciolingual crown size	7.7	6.2–10.5	8.2	7.0–10.5
Faciolingual root (cervix)	7.0	5.5–8.5	7.3	6.1–8.4
Mesial cervical curve	0.9	0.0–2.0	0.8	0.0–2.0
Distal cervical curve	0.6	0.0–1.6	0.5	0.0–1.3

- I. The single root on maxillary second premolars averages 0.6 mm longer than the root length on maxillary first premolars.
- J. On 317 maxillary first premolars, lingual cusps average 1.3 mm shorter than buccal cusps (ranging from 0.3 to 3.3 mm shorter). On 300 maxillary second premolars, lingual cusps average only 0.4 mm shorter than buccal cusps.
- K. On 93 two-rooted maxillary first premolars, the lingual root averaged 0.8 mm shorter than the buccal root.
- L. On 243 maxillary premolars, the average distance between the buccal and lingual cusp tips of firsts is 5.9 mm, and 5.7 mm on seconds, or about two thirds of the faciolingual dimension.
- M. On 600 maxillary first premolars, 97% of the mesial marginal ridges had a marginal ridge groove, but only 39% of the distal marginal ridges had a groove. On 641 maxillary second premolars, only 37% of mesial marginal ridges and 30% of distal marginal ridges had a groove.
- N. On 234 maxillary first premolars, the cervical line curvature on the mesial averaged 1.1 mm, and on the distal, averaged 0.4 mm less. On maxillary second premolars, the difference between mesial and distal curvature averages 0.3 mm.
- O. There was an obvious mesial crown depression (that is continuous with a mesial root depression) on 100% of 100 teeth, whether single or double rooted.
- P. On maxillary second premolars, 78% had a mesial root depression (none extending onto the crown surface).
- Q. When 1392 dental stone casts were studied, maxillary first premolars were judged larger than second premolars 55% of the time, and smaller only 18% of the time.
- R. On 408 maxillary first premolars, the central groove averaged 2.7 mm long, and on 818 second premolars, 2.1 mm (shorter than on firsts by 0.6 mm).
- S. The distal triangular fossa was judged larger on 55% of the 184 maxillary first premolars and 53% of 209 maxillary second premolars. The mesial triangular fossa was judged larger on 27% of first premolars and 17% of second premolars.
- T. The crown outline of 234 maxillary premolars measured greater buccolingually than mesiodistally: by 2.1 mm on firsts, and by 2.4 mm on seconds.
- U. On 465 mandibular premolars, crowns were longer on firsts by 0.6 mm, but roots were shorter on firsts by 0.3 mm.
- V. Of 285 mandibular first premolars, 80% had a smooth buccal surface in the occlusal third without depressions, 17% had a deeper depression in the occlusal third of the crown on the mesial side of the buccal ridge, and only 3% had a deeper distal depression. Of mandibular second premolars, 74% had no discernible depressions, 25% had a deeper distal than mesial depression, and only 1% had a deeper mesial depression.
- W. On 1348 mandibular first premolars, the buccal cusp is likely to have a notch on the mesial cusp ridge 65% of the time, and on the distal cusp ridge 46% of the time. On 1522 mandibular second premolars, the buccal cusp is likely to have a notch on the distal cusp ridge 66% of the time, and on the mesial cusp ridge 43% of the time.
- X. On 424 mandibular first premolars, roots bent distally 58% of the time, and on 343 mandibular

second premolars, 62% bent to the distal; the tendency for a mesial bend was 23% and 17% on first and second premolars, respectively.

- Y. Roots of mandibular second premolars average 0.2 mm wider mesiodistally and 0.3 mm longer than roots on mandibular first premolars.
- Z. On 321 mandibular first premolars, lingual cusps averaged 3.6 mm shorter than buccal cusps (ranging from 1.7 to 5.5 mm shorter).
- AA. On 818 mandibular second premolars, 90% had the mesiolingual cusp larger and longer than the distolingual cusp; the two lingual cusps were equal in size on 3%, and the distolingual cusp was larger on only 7%.
- BB. On 609 mandibular first premolars, 67% had a mesiolingual groove; 8% had a similar groove between the distal marginal ridge and the distal slope of the lingual cusp.
- CC. On 465 mandibular premolars, the roots on seconds averaged 0.3 mm longer than on firsts.
- DD. On 317 mandibular second premolars, the lingual cusp (or mesiolingual cusp) averaged 1.8 mm shorter than the buccal cusp, ranging from 0.1 to 3.8 mm.
- EE. On 100 mandibular second premolars, 21% had a mesial marginal ridge groove, and 4% had a distal marginal ridge groove.
- FF. On 238 mandibular first premolars, the cervical line curvature on the mesial averaged 0.9 mm versus 0.6 mm on the distal. On 227 mandibular second premolars, the cervical line curvature on the mesial averaged 0.8 mm versus 0.5 mm (almost flat) on the distal. The cervical line may be located as much as 2 mm more occlusal on the lingual surface than on the buccal.
- GG. On 100 mandibular first premolars, 45% had mesial root depressions and 86% had distal root depressions that were deeper than on the mesial 69% of the time. On 100 mandibular second premolars, 81% had no mesial root depression and 73% had a noticeable distal root depression.
- HH. On 229 mandibular three-cusp second premolars, 56% have greater faciolingual bulk in the distal half, but 38% have greater bulk in the mesial half.
- II. On 100 mandibular first premolars, 82% had a larger distal fossa and 8% had a larger mesial fossa.
- JJ. On 200 mandibular three-cusp second premolars, 65% had a largest central fossa; only 25% had a largest mesial fossa.
- KK. On 200 mandibular second premolars, 24% had mesial marginal ridge grooves, and 11% had distal marginal ridge grooves.

# Morphology of Permanent Molars

Topics covered within the four sections of this chapter include the following:

- I. Overview of molars
  - A. General description of molars
  - B. Functions of molars
  - C. Class traits for molars
  - D. Arch traits that differentiate maxillary from mandibular molars
- II. Type traits that differentiate mandibular second molars from mandibular first molars
  - A. Type traits of mandibular molars from the buccal view
  - B. Type traits of mandibular molars from the lingual view
  - C. Type traits of mandibular molars from the proximal views
  - D. Type traits of mandibular molars from the occlusal view
- III. Type traits that differentiate maxillary second molars from maxillary first molars
  - A. Type traits of the maxillary first and second molars from the buccal view
  - B. Type traits of maxillary molars from the lingual view
  - C. Type traits of maxillary molars from the proximal views
  - D. Type traits of maxillary molars from the occlusal view
- IV. Maxillary and mandibular third molar type traits
  - A. Type traits of all third molars (different from first and second molars)
  - B. Size and shape of third molars
  - C. Similarities and differences of third molar *crowns* compared with first and second molars in the same arch
  - D. Similarities and differences of third molar *roots* compared with first and second molars in the same arch
- V. Interesting variations and ethnic differences in molars

Throughout this chapter, “Appendix” followed by a number and letter (e.g., Appendix 7a) is used within the text to denote reference to the page (number 7) and item (letter a) being referred to on that appendix page. You can tear out the perforated Appendix pages to facilitate study and minimize page turns. Other appendix pages will be referred to throughout this chapter.

Also, remember that statistics obtained from Dr. Woelfel’s original research on teeth have been used to draw conclusions throughout this chapter and are referenced with superscript letters like this (data<sup>A</sup>) that refer to data presented at the end of this chapter.

## SECTION I

## OVERVIEW OF MOLARS

### OBJECTIVES

This section is designed to prepare the learner to perform the following:

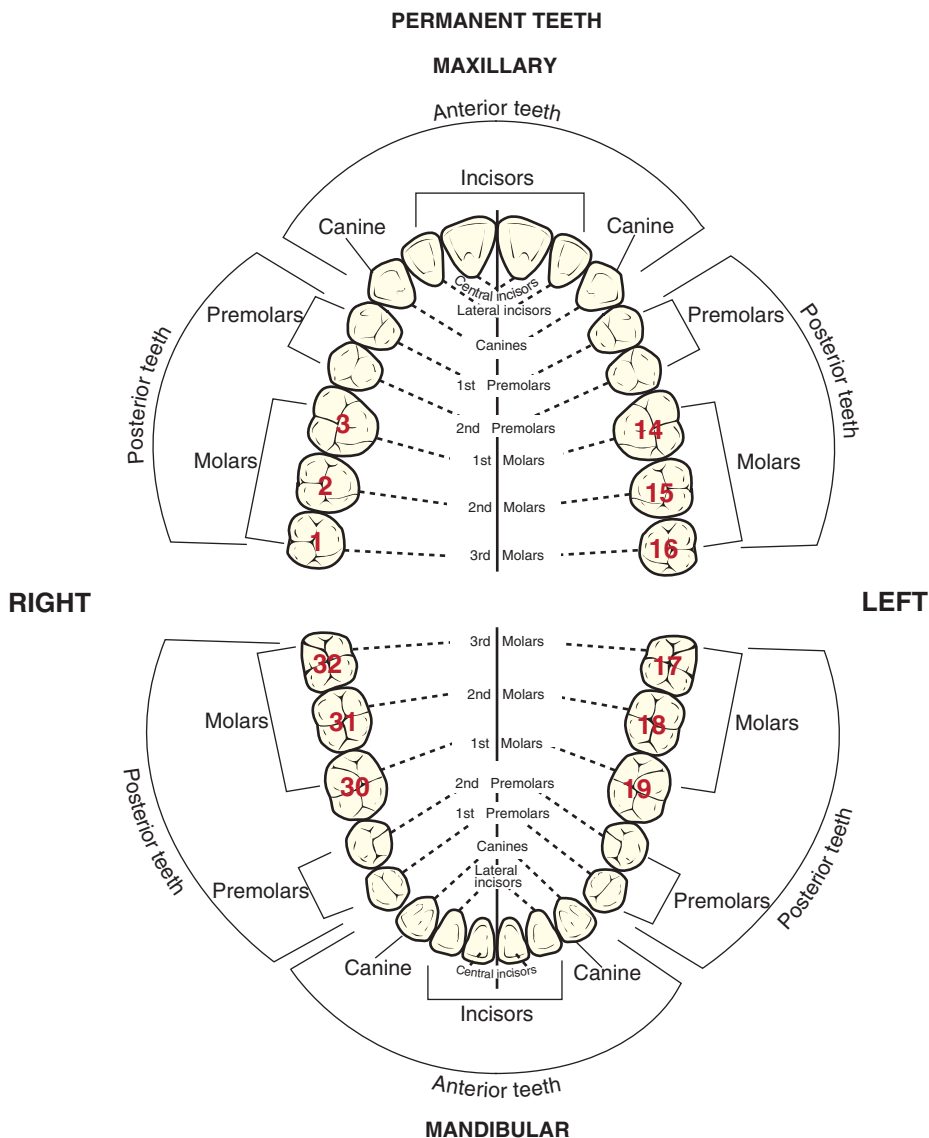
- Describe the functions of molars.
- List class traits common to all molars.
- List arch traits that can be used to distinguish maxillary from mandibular molars.
- From a selection of all teeth, select and separate out all molars.
- Divide a selection of all molars into maxillary and mandibular.



## A. GENERAL DESCRIPTION OF MOLARS

Study a cast of all permanent teeth, or *Figure 5-1*, while learning the position of molars in the arch. There are 12 permanent molars: six maxillary and six mandibular. The six permanent molars in each arch are the first, second, and third molars on either side of the arch. They are the sixth, seventh, and eighth teeth from the midline. Using the Universal Numbering System, the maxillary molars are Numbers 1, 2, and 3 for the right third, second, and first molars and Numbers 14, 15, and 16 for the left first, second, and third molars, respectively. The mandibular molars are Numbers 17, 18, and 19 for the left third, second, and first molars and Numbers 30, 31, and 32 for the right first, second, and third molars, respectively.

In the adult dentition, first molars are distal to second premolars. The permanent first molars are located near the center of each arch, anteroposteriorly. This is one reason that their loss is so devastating to arch continuity (allowing movement and tipping of the teeth on either side). They are the largest and strongest teeth in each arch. The second molars are distal to the first molars, and the third molars are distal to the second molars. Said another way, in the complete adult dentition, the mesial surface of the first molar contacts the distal surface of the second premolar, the mesial surface of the second molar contacts the distal of the first molar, and the mesial surface of the third molar contacts the distal of the second molar. The third molar is the last tooth in the arch, and its distal surface is not in contact with any other tooth.



**FIGURE 5-1.** Adult dentition with the **Universal numbers** for molars highlighted in red.

## B. FUNCTIONS OF MOLARS

The permanent molars, like the premolars, (a) play a major role in the mastication of food (chewing and grinding to pulverize) and (b) are most important in maintaining the vertical dimension of the face (preventing the jaws from closing too far, which could reduce the vertical dimension between the chin and the nose, resulting in a protruding chin and a prematurely aged appearance). They are also (c) important in maintaining continuity within the dental arches, thus keeping other teeth in proper alignment. Further, molars have (d) at least a minor role in esthetics or keeping the cheeks normally full or supported. You may have seen someone who has lost all 12 molars (six upper and six lower) and has sunken cheeks.

The loss of a first molar is really noticed and missed by most people when it has been extracted. More than 80 mm<sup>2</sup> of efficient chewing surface is gone; the tongue feels the huge space between the remaining teeth; and during mastication of coarse or brittle foods, the attached gingiva in the region of the missing molar often becomes abraded and uncomfortable. Loss of six or more molars could even lead to problems in the jaw joints (temporomandibular joints or TMJ).

## C. CLASS TRAITS FOR MOLARS

Refer to Appendix page 7 while reading about the following class traits of all molars.

### 1. CROWN SIZE FOR ALL MOLARS

Molars have an occlusal (chewing) surface with three to five cusps, and their occlusal surfaces are larger than the other teeth in their respective arches. They have broader occlusal surfaces than premolars, both faciolingually and mesiodistally.<sup>A</sup> The combined mesiodistal width of the three *mandibular* molars in one quadrant makes up over half of the mesiodistal dimension of their quadrant. The *maxillary* molars constitute 44% of their quadrant's mesiodistal dimension, still a significant portion. In contrast, both mandibular and maxillary molar crowns are shorter occlusocervically than all other adult crowns and are shorter occlusocervically than mesiodistally (Appendix 7a).

### 2. TAPER FROM BUCCAL TO LINGUAL FOR MOST MOLARS

From the occlusal view, molar crowns taper (get narrower) from the buccal to the lingual. That is, the mesiodistal width on the buccal half is wider than on the lingual half (Appendix 7b), EXCEPT on maxillary first molars with large distolingual cusps, where crowns actually taper narrower from lingual toward the buccal.

### 3. TAPER TO THE DISTAL FOR MOST MOLARS

For both arches, molar crowns from the occlusal view tend to taper distally, so that the distal third is narrower buccolingually than the mesial third (Appendix 7c). This taper may be less apparent on mandibular first molars where the tooth may be widest buccolingually in the middle third. Also, from the buccal (or lingual) views, the occlusal surfaces of all molars slope shorter toward the cervix from mesial to distal (Appendix 7d). This, along with the more cervical placement of the distal marginal ridge, makes more of the occlusal surface visible from the distal aspect than from the mesial aspect (compare mesial to distal views in Appendix page 7).

### 4. HEIGHT (CREST) OF CONTOUR FOR ALL MOLARS

As with premolars, the height of contour on the *buccal* of molars viewed from the proximal is in the cervical third; on the *lingual*, it is most often in the middle third (Appendix 7e).

### 5. CONTACT AREAS FOR ALL MOLARS

The contact areas on all molars viewed from the buccal (or lingual) are at or near the junction of the occlusal and middle thirds mesially and are more cervical on the distal (in the middle third near the middle of the tooth) (Appendix 7f).

## D. ARCH TRAITS THAT DIFFERENTIATE MAXILLARY FROM MANDIBULAR MOLARS

Compare extracted maxillary and mandibular molars and/or tooth models while reading about these differentiating arch traits. Also refer to page 8 in the Appendix.

### 1. CROWN OUTLINE TO DISTINGUISH MAXILLARY FROM MANDIBULAR MOLARS

From the occlusal view, the crowns of **mandibular molars** are oblong: they are characteristically much wider mesiodistally than faciolingually.<sup>B</sup> This is just the opposite of the **maxillary molars**, which have their greater dimension faciolingually. From the occlusal view, maxillary molars have a more square or twisted *parallelogram* shape. **Mandibular molars** have a somewhat *rectangular* shape, and on mandibular first molars, the outline may be *pentagon* shape (compare the outline shapes on Appendix 8k).

**Table 5-1 MOLARS: GUIDELINES FOR DETERMINING NUMBER OF LOBES FOR MOLARS**

MOLAR NAME	NO. OF CUSPS	NO. OF LOBES
Maxillary first molar	4 (or 5 if Carabelli)	4 (or 5 if Carabelli)
Maxillary second molar	4 (or 3)	4 (or 3)
Mandibular first molar	5	5
Mandibular second molar	4	4

Number of lobes = 1 per cusp (including Carabelli).

## 2. NUMBERS AND RELATIVE SIZE OF CUSPS (AND NUMBER OF LOBES)

**Mandibular molar** crowns normally have four or five cusps. Many have four relatively large cusps: two buccal (mesiobuccal and distobuccal) and two lingual (mesiolingual and distolingual). However, most mandibular first molars often have an additional fifth, smaller cusp called a distal cusp that is located on the buccal surface just distal to the distobuccal cusp. The two *lingual* cusps of mandibular molars are of nearly equal size, which is different than on maxillary molars where distolingual cusps are often considerably smaller.

The crowns of **maxillary molars** may have three to five cusps. When they have four cusps, three are larger (the mesiobuccal, distobuccal, and mesiolingual) and the fourth is smaller (the distolingual) or, on many maxillary second molars, it is missing resulting in three cusps. On many maxillary first molars, there is a fifth, much smaller cusp (cusp of Carabelli) located on the lingual surface of the longest and largest mesiolingual cusp (Appendix 8i).

The number of lobes forming molars is one per cusp, including the cusp of Carabelli. See *Table 5-1* for a summary of the number of lobes forming first and second molars.

## 3. CROWN TILT THAT DISTINGUISHES MAXILLARY FROM MANDIBULAR MOLARS

When **mandibular molar** crowns are examined from the proximal views, the crowns appear to be tilted lingually on the root trunk (true for all mandibular posterior teeth), whereas the crowns and cusps of **maxillary molars** are centered over their roots (Appendix 8b). Also, when **mandibular molars** are viewed from the buccal, the considerable bulge of the distal crown outline beyond the cervix of the root, and the slope of the occlusal surface shorter on the distal, may appear as though the crown is tipped distally relative to the long axis of the root. (The greater distal crown bulge can be seen on Appendix 8g.)

**Table 5-2 ARCH TRAITS TO DISTINGUISH MANDIBULAR FROM MAXILLARY MOLARS**

	MAXILLARY MOLARS	MANDIBULAR MOLARS
BUCCAL VIEW	Two buccal cusps: Mesiobuccal and distobuccal Mesiolingual cusp tip visible from buccal	Two or three buccal cusps: Mesiobuccal, distobuccal, and distal (on firsts) Both lingual cusp tips visible from buccal
	One buccal groove	Two buccal grooves on most first molars
	Three roots (two buccal and one lingual) Root trunk longer Crown centered over root	Two roots (one mesial and one distal) Root trunk shorter Crown tipped distally on root
LINGUAL VIEW	Lingual groove off center (toward distal) Mesiolingual cusp larger than distolingual cusp, more than on mandibular molars Cervix of crown tapers more to lingual Cusp of Carabelli (or groove) common on first molars	Lingual groove nearly centered Mesiolingual and distolingual cusps' size and height more equal Cervix of crown tapers less to lingual No Carabelli cusp
PROXIMAL VIEWS	Crown more centered over root Smaller distolingual cusp on most second molars or no distolingual cusp	Crown tipped more lingually over root Smallest distal cusp seen from distal on most first molars

(continued)

**Table 5-2 ARCH TRAITS TO DISTINGUISH MANDIBULAR FROM MAXILLARY MOLARS (Continued)**

	MAXILLARY MOLARS	MANDIBULAR MOLARS
OCCLUSAL VIEW	Crowns wider faciolingually than mesiodistal	Crowns wider mesiodistally than faciolingual
	Oblique ridge present from mesiolingual to distobuccal	No oblique ridge
	One transverse ridge mesiobuccal to mesiolingual	Two transverse ridges mesiobuccal to mesiolingual and distobuccal to distolingual
	Parallelogram (or square) shape crown for four-cusp type	Pentagon shape crown on firsts
	Three-cusp seconds are heart shaped	Rectangular shape crown on seconds
	Four fossae: including large central and cigar-shaped distal	Three fossae: central fossa is large
	Central groove in mesial half does not cross oblique ridge	Central fossa with zigzag or + groove pattern
	First molars have four cusps plus Carabelli cusp/groove	Five cusps on firsts (distal cusp is fifth cusp)
	First molars wider on lingual than buccal	First molars wider on buccal than lingual
	Second molars have four cusps or three cusps (heart shaped)	Second molars have four cusps
Mesiolingual cusp much larger than distolingual	Mesiolingual cusp slightly larger than distolingual	

#### 4. ROOTS TO DISTINGUISH MAXILLARY FROM MANDIBULAR MOLARS

Perhaps the most obvious trait to differentiate extracted maxillary from mandibular molars is the number of roots. Maxillary molars have *three* relatively long roots: mesiobuccal, distobuccal, and lingual (palatal). The lingual root is usually the longest; the distobuccal root is the shortest. The roots converge into a broad cervical root trunk. Mandibular molars have only *two*

roots: a long mesial root and a slightly shorter distal root. Mandibular molars have the longest roots relative to crown length (greatest root-to-crown ratio) of any adult teeth.<sup>c</sup> The root furcation on lower molars is usually close to the cervical line (especially on first molars), making the root trunk shorter than on the maxillary molars (see Appendix 8c).

Table 5-2 includes a summary of arch traits that can be used to differentiate maxillary from mandibular molars.

## SECTION II

### TYPE TRAITS THAT DIFFERENTIATE MANDIBULAR SECOND MOLARS FROM MANDIBULAR FIRST MOLARS

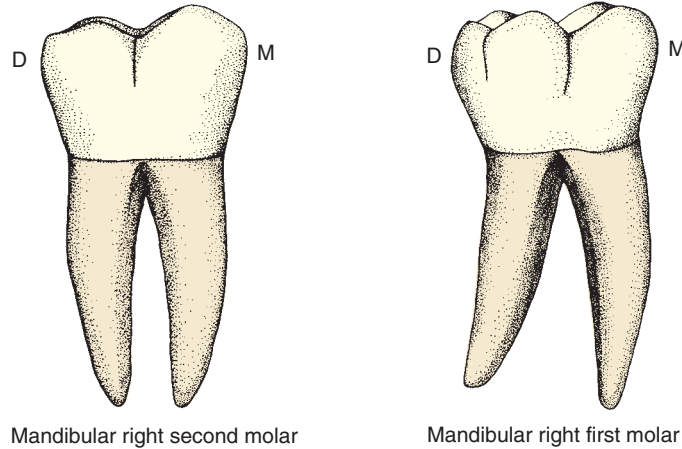
#### OBJECTIVES

This section prepares the reader to perform the following:

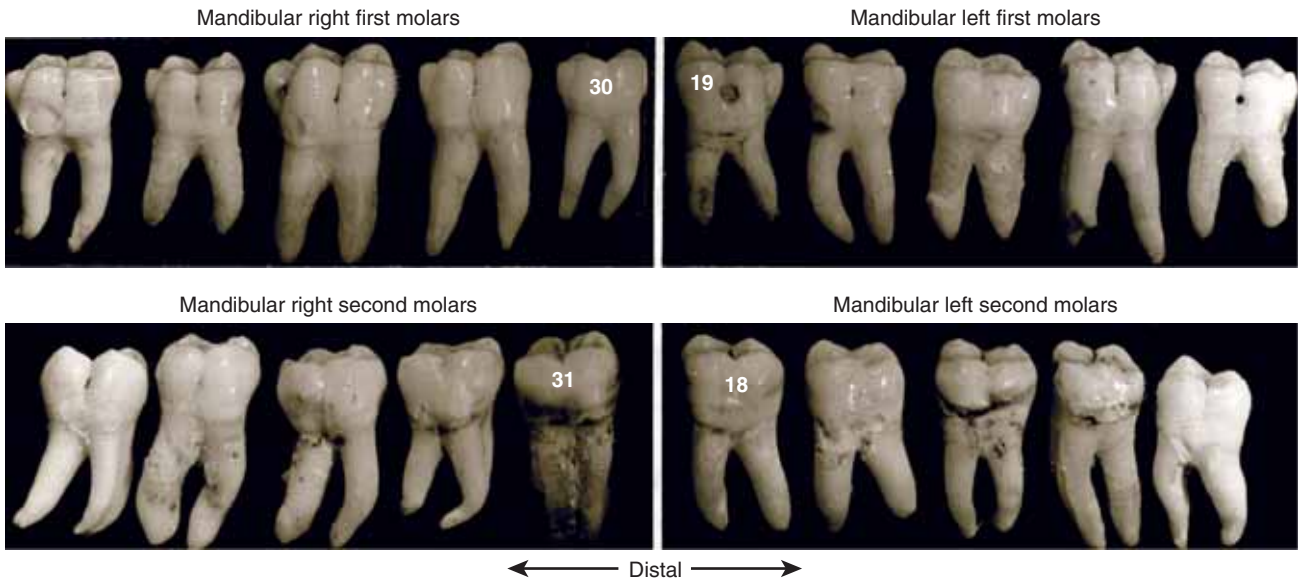
- Describe the type traits that can be used to distinguish the permanent mandibular first molar from the mandibular second molar.
- Describe and identify the buccal, lingual, mesial, distal, and occlusal surfaces for all mandibular molars.
- Assign a Universal number to mandibular molars present in a mouth (or on a model) with complete dentition. If possible, repeat this on a model with one or more mandibular molars missing.
- Holding a mandibular molar, determine whether it is a first or a second, and right or left. Then, assign a Universal number to it.

Mandibular first and second molars have specific traits that can be used to distinguish one from the other. Third molars vary considerably, often resembling a first or a second molar while still having their own unique traits

that will be discussed later in Section IV. For this section, hold a mandibular first and second molar in front of you (with crowns up, roots down) and refer to Appendix page 8 while making the following comparisons.



**MANDIBULAR MOLARS (buccal)**



**TRAITS TO DISTINGUISH MANDIBULAR FIRST MOLARS FROM SECOND MOLARS: BUCCAL VIEW**

**MANDIBULAR FIRST MOLAR**

- Three buccal cusps: mesiobuccal, distobuccal, and distal
- Two buccal grooves: mesiobuccal and distobuccal
- Wider root spread, shorter trunk
- Roots more curved

**MANDIBULAR SECOND MOLAR**

- Two buccal cusps: mesiobuccal and distobuccal
- One buccal groove
- Less root spread, longer trunk
- Straighter roots

**TRAITS TO DISTINGUISH MANDIBULAR RIGHT FROM LEFT MOLARS: BUCCAL VIEW**

**MANDIBULAR FIRST MOLAR**

- Distal cusp is smallest buccal cusp

**MANDIBULAR SECOND MOLAR**

- Distobuccal cusp is smaller than mesiobuccal

- Crown tapers and is shorter toward distal for both
- Distal contact more cervical than mesial contact for both
- Crown has more distal bulge beyond root than on mesial for both
- Mesial root is longer than distal root for both

**FIGURE 5-2.** Buccal views of mandibular molars with type traits to distinguish mandibular first from second molars and traits to distinguish rights from lefts.



## A. TYPE TRAITS OF MANDIBULAR MOLARS FROM THE BUCCAL VIEW

Refer to *Figure 5-2* for similarities and differences between mandibular first and second molars.

### 1. CROWN PROPORTIONS FROM THE BUCCAL VIEW

For both types of mandibular molars, the crowns are wider mesiodistally than high cervico-occlusally but more so on the larger first molars.<sup>D</sup>

### 2. RELATIVE NUMBER AND SIZE OF MANDIBULAR MOLAR CUSPS (AND GROOVES THAT SEPARATE THEM) FROM THE BUCCAL VIEW

The **mandibular first molar** has the *largest mesiodistal dimension* of any tooth.<sup>E,F</sup> It most often has *five cusps*: three buccal and two lingual (*Fig. 5-3*), but the smallest distal cusp may be absent about a fifth of the time (*Fig. 5-4*).<sup>G</sup> Consequently, *not all four-cusp molars are second molars*. Almost one fifth may be mandibular first molars.

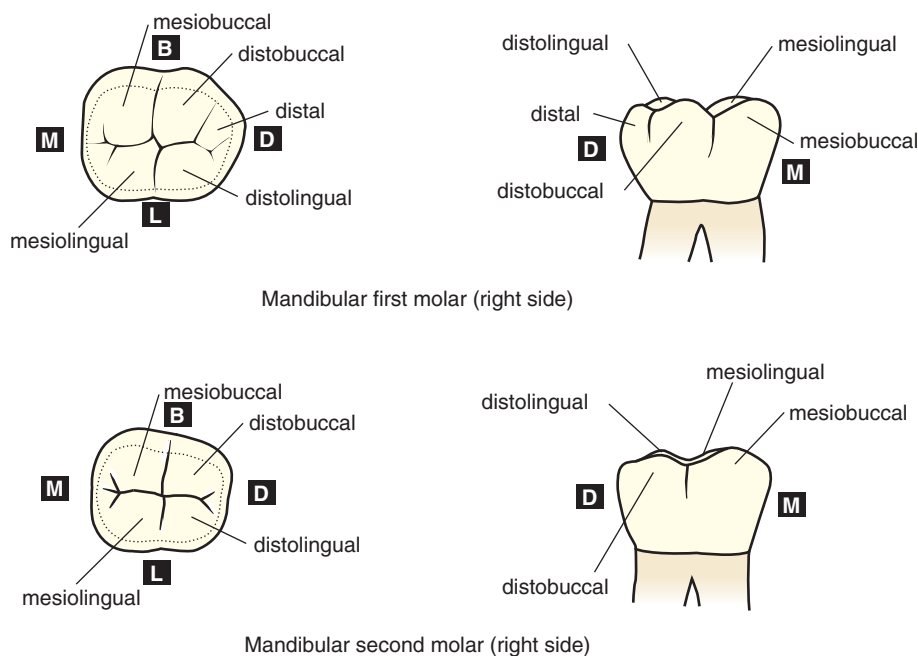
When there are five cusps, their heights, in order from longest to shortest, are mesiolingual, distolingual, mesiobuccal, distobuccal, then the smallest distal cusp (located on the buccal surface near the distobuccal angle). The mesiobuccal cusp is the largest, widest, and highest

cusp on the *buccal* side of the tooth.<sup>H</sup> The distobuccal cusp may be sharper than the mesiobuccal cusp.<sup>I</sup>

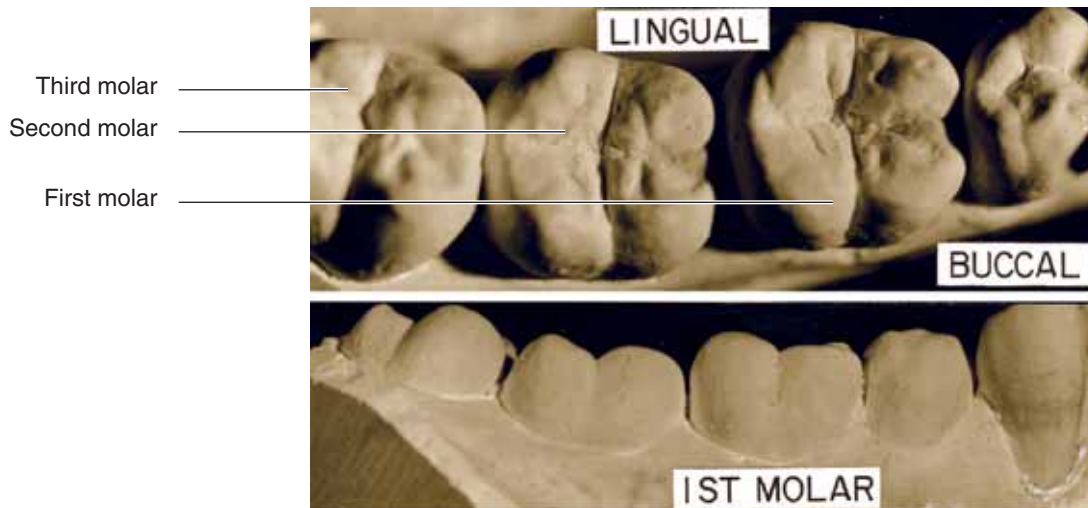
From the buccal view, the mesiolingual cusp of the **mandibular first molar**, which is the highest or longest of all the cusps of the mandibular first molar, is just visible behind the mesiobuccal cusp. The distolingual cusp tip is visible behind the distobuccal cusp and is usually the second highest cusp when the tooth is oriented vertically. This is clearly seen in the first molars in *Figure 5-2*. Even though the lingual cusps are higher than buccal cusps when viewing extracted teeth with the root axis held vertically, the lingual cusp tips are at a lower level than the buccal cusps in the mouth due to the lingual tilt of the root axis in the mandible (creating the curve of mediolateral curve [of Wilson] shown earlier in *Fig. 1-35*).

When there are three buccal cusps on the **mandibular first molar**, there are two buccal grooves: the mesiobuccal and shorter distobuccal. The longer *mesiobuccal groove* separates the mesiobuccal cusp from the distobuccal cusp and may extend onto the buccal surface often ending in a deep pit at its cervical end that is sometimes a site of decay. Six of the mandibular first molars in *Figure 5-2* have pits at the end of the mesiobuccal groove, and a seventh has an amalgam restoration. The shorter *distobuccal groove* separates the distobuccal cusp from the distal cusp and may also end in a pit. One of the mandibular first molars in *Figure 5-2* has a pit at the end of the distobuccal groove; can you find it?

### MANDIBULAR MOLAR CUSP NAMES



**FIGURE 5-3.** Cusp names for mandibular first and second molars showing relative location and size (occlusal and buccal views).



**FIGURE 5-4.** A mandibular first molar with only four cusps (whereas most have five cusps), Buccal view (below) and occlusal view (above).

The mandibular second molar has four cusps: two buccal and two lingual (Fig. 5-3 lower row). These cusps, in order from longest to shortest, are the mesiolingual, distolingual, mesiobuccal, and distobuccal, the same order as for the four larger cusps of the mandibular first molar. As on the mandibular first molar, the lingual cusp tips from the buccal view are visible behind the shorter buccal cusps (seen in most teeth in Fig. 5-2). As on the first molar, the mesiobuccal cusp is usually wider mesiodistally than the distobuccal cusp.<sup>K</sup>

Mandibular second molars have only one buccal groove that separates the mesiobuccal and the distobuccal cusps. The buccal groove may end on the middle of the buccal surface in a pit that is sometimes a site of decay (seen in 2 of the 10 second molars in Fig. 5-2). There is no distobuccal groove as on the first molar.

### 3. PROXIMAL CONTACTS OF MANDIBULAR MOLARS FROM THE BUCCAL VIEW

Both types of mandibular molars (in fact, all molars) have their mesial contact located more occlusally than the distal, close to the junction of middle and occlusal thirds of the crown. The distal contact is located more cervically, in the middle third (near the middle of the tooth cervico-occlusally). This difference in proximal contact height can be seen in most mandibular molars in Figure 5-2.

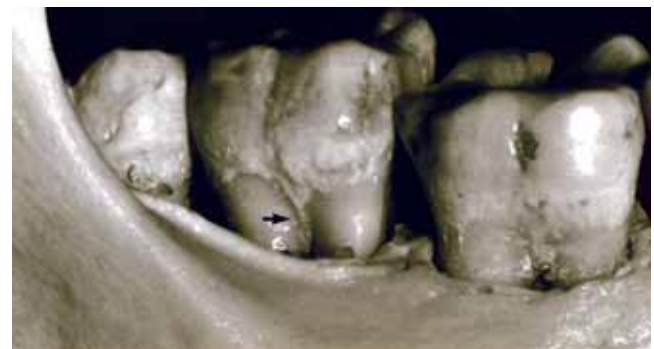
### 4. CERVICAL LINES OF MANDIBULAR MOLARS FROM THE BUCCAL VIEW

The cervical lines of both mandibular first and second molars are often nearly straight across the buccal surface. On mandibular molars, cementum often covers

the root bifurcation surface in a mesiodistal direction,<sup>1</sup> but sometimes there is a point of enamel that dips down nearly into the root bifurcation (Fig. 5-5). There may even be a dipping down of enamel on both the buccal and the lingual surfaces, and these extensions may meet in the root bifurcation.<sup>3,4</sup> Such enamel extensions may cause periodontal problems because of the deep gingival sulcus in these regions.

### 5. TAPER OF MANDIBULAR MOLARS FROM THE BUCCAL VIEW

There is proportionally more tapering of the crown from the contact areas to the cervical line on mandibular first molars than on second molars because of the bulge of the distal cusp (Appendix 8g). Therefore, the crown of the second molar appears to be wider at the cervix than on the first molar.



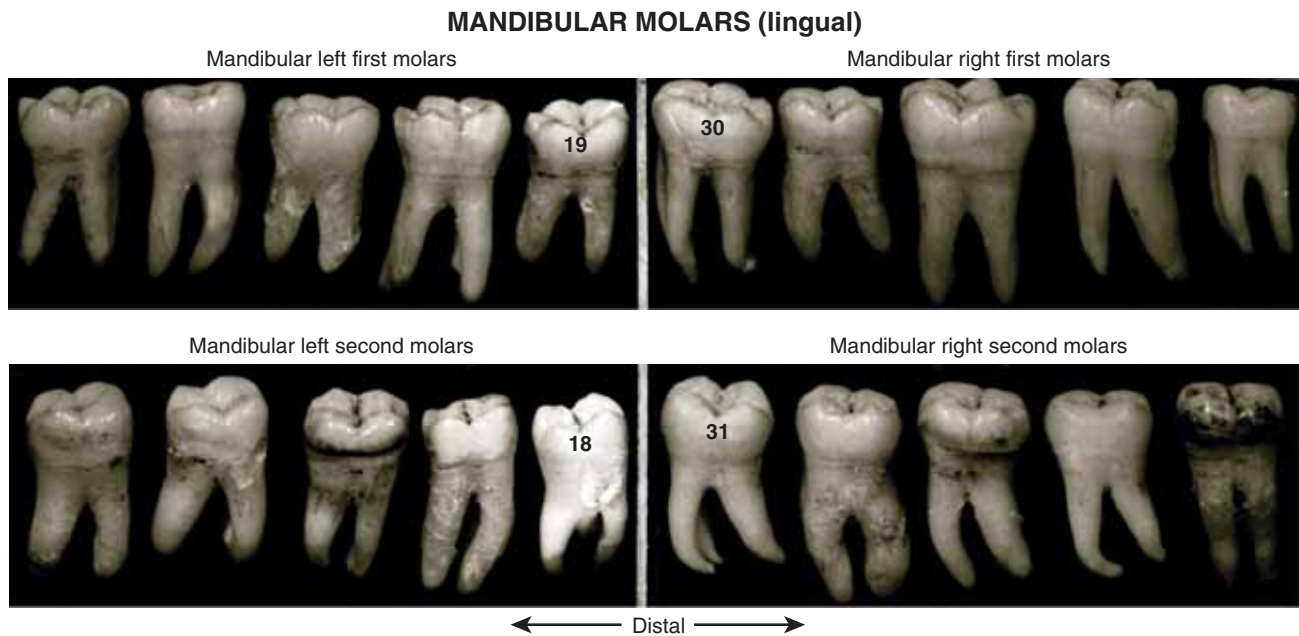
**FIGURE 5-5.** Enamel extension (arrow) downward into the buccal furcation of a mandibular second molar. (Courtesy of Charles Solt, D.D.S., and Todd Needhan, D.D.S.)

Also, from the buccal view, the occlusal outlines of *both* types of mandibular molars slope shorter cervically from mesial to distal (Appendix 7d). This distal taper combined with a greater distal crown bulge beyond the root than mesial bulge causes some people to view the crown as tipped distally on its two roots.

### 6. ROOTS OF MANDIBULAR MOLARS FROM THE BUCCAL VIEW

*Both* mandibular first and second molars have two roots, one slightly longer mesial root and one distal root (Appendix 8c).<sup>1</sup> Both roots are nearly twice as long as the crown.

The root bifurcation of the **mandibular first molar** is near the cervical line, so its root trunk is relatively short compared to second molars. The roots of mandibular first molars are more widely separated than on the seconds. This considerable divergence is evident on the curved *mesial* root, which often bows out beyond the mesial root outline of its crown, and then curves back distally placing its apex in line with the mesiobuccal groove of the crown. The mesial root is twisted, so it may be possible to see the distal surface of this root from the buccal view. The more pointed apex of the straighter *distal* root often lies distal to the distal outline of the crown (seen on the first molar in Appendix 8c, and some first molars in Fig. 5-2).



#### TRAITS TO DISTINGUISH MANDIBULAR FIRST MOLARS FROM SECOND MOLARS: LINGUAL VIEW

MANDIBULAR FIRST MOLAR	MANDIBULAR SECOND MOLAR
Wider root spread, shorter trunk	Less root spread, longer trunk
Roots more curved	Straighter roots
More crown taper to lingual	Less crown taper to lingual

#### TRAITS TO DISTINGUISH MANDIBULAR RIGHT FROM LEFT MOLARS: LINGUAL VIEW

MANDIBULAR FIRST MOLAR	MANDIBULAR SECOND MOLAR
Same outline traits as from buccal view are seen from the lingual view for both	
Mesiolingual cusp is the longest for both	
Distal marginal ridge is more cervical than the mesial marginal ridge for both	

**FIGURE 5-6.** Lingual views of mandibular molars with type traits to distinguish mandibular first from second molars and to help distinguish rights from lefts.

The tapered, pointed roots of **mandibular second molars** are less widely separated, or more parallel, than on first molars. Often the apices of both roots are directed toward the centerline of the tooth, similar in shape to the handle of pliers (2 of the 10 mandibular molars in Fig. 5-2; see if you can find them), or both roots may curve distally. The root trunk is slightly longer than that of the mandibular first molar (Appendix 8f), and the depression of the buccal furcation extends occlusally across the root to the cervical line (Fig. 5-2).

## B. TYPE TRAITS OF MANDIBULAR MOLARS FROM THE LINGUAL VIEW

Refer to *Figure 5-6* for similarities and differences between mandibular molars from the lingual view.

### 1. NARROWER LINGUAL CROWN OF MANDIBULAR MOLARS FROM THE LINGUAL VIEW

As with most teeth, mandibular first and second molar crowns taper from buccal to lingual and thus are narrower on the lingual side.

### 2. RELATIVE SIZE OF MANDIBULAR CUSPS (AND THE LINGUAL GROOVE) FROM THE LINGUAL VIEW

Since the lingual cusps of *both* types of mandibular molars are both slightly longer (and more pointed) than the buccal cusps, only the two longer lingual cusps are visible from the lingual aspect (not evident in Fig. 5-6 because of the camera angle). The mesiolingual cusp is most often slightly wider and longer than the distolingual cusp (noticeably wider on first molars).<sup>M</sup> The lingual cusps were rated about even on cusp sharpness.<sup>N</sup>

The lingual groove that separates the mesiolingual from the distolingual cusp may extend onto the lingual surface and sometimes it may be fissured and form decay on the lingual surface.

### 3. CERVICAL LINE OF MANDIBULAR MOLARS FROM THE LINGUAL VIEW

The cervical line on the lingual surface is relatively straight (mesiodistally) but may dip cervically between the roots over the bifurcation as is also sometimes seen on the buccal side of the crown.

### 4. ROOTS OF MANDIBULAR MOLARS FROM THE LINGUAL VIEW

On **mandibular first molars**, the root trunk appears longer on the lingual than on the buccal side because

the cervical line is more occlusal in position on the lingual than on the buccal surface. Both roots are narrower on the lingual side than they are on the buccal side, and the mesial root is twisted making it possible to see the mesial surface of the mesial root (seen on five mandibular first molars in Fig. 5-6). One may also see the distal surface of the distal root because of its taper toward the lingual.

On *both* first and second mandibular molars, the short root trunk has a depression between the bifurcation and the cervical line.

## C. TYPE TRAITS OF MANDIBULAR MOLARS FROM THE PROXIMAL VIEWS

For proper orientation, as you study each trait, hold the crown so that the root axis line is in a vertical position as seen in *Figure 5-7*.

Recall that *both* types of mandibular molar crowns are relatively shorter cervico-occlusally and wider faciolingually, and that the crowns of both types of mandibular molars are tilted lingually from the root trunk (Fig. 5-8). Remember that this slant is an arch trait characteristic of all mandibular posterior teeth and is nature's way of shaping them to fit beneath and lingual to the maxillary buccal cusps.

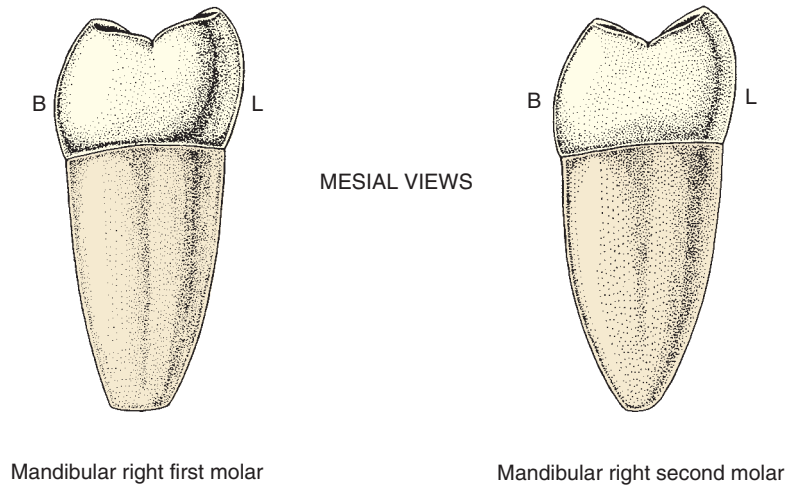
### 1. HEIGHT (CREST) OF CONTOUR OF MANDIBULAR MOLARS FROM THE PROXIMAL VIEWS

As with all molars (and premolars), the convex *buccal* height of contour or greatest bulge is in the cervical third (Fig. 5-8). The buccal height of contour is actually formed by the buccal cervical ridge that runs mesiodistally near the cervical line. It is more prominent on mandibular second molars than on firsts. The *lingual* outline of the crown of both molars appears nearly straight in the cervical third with its height of contour in the middle third. This difference in heights of contour is useful to distinguish buccal from lingual surfaces.

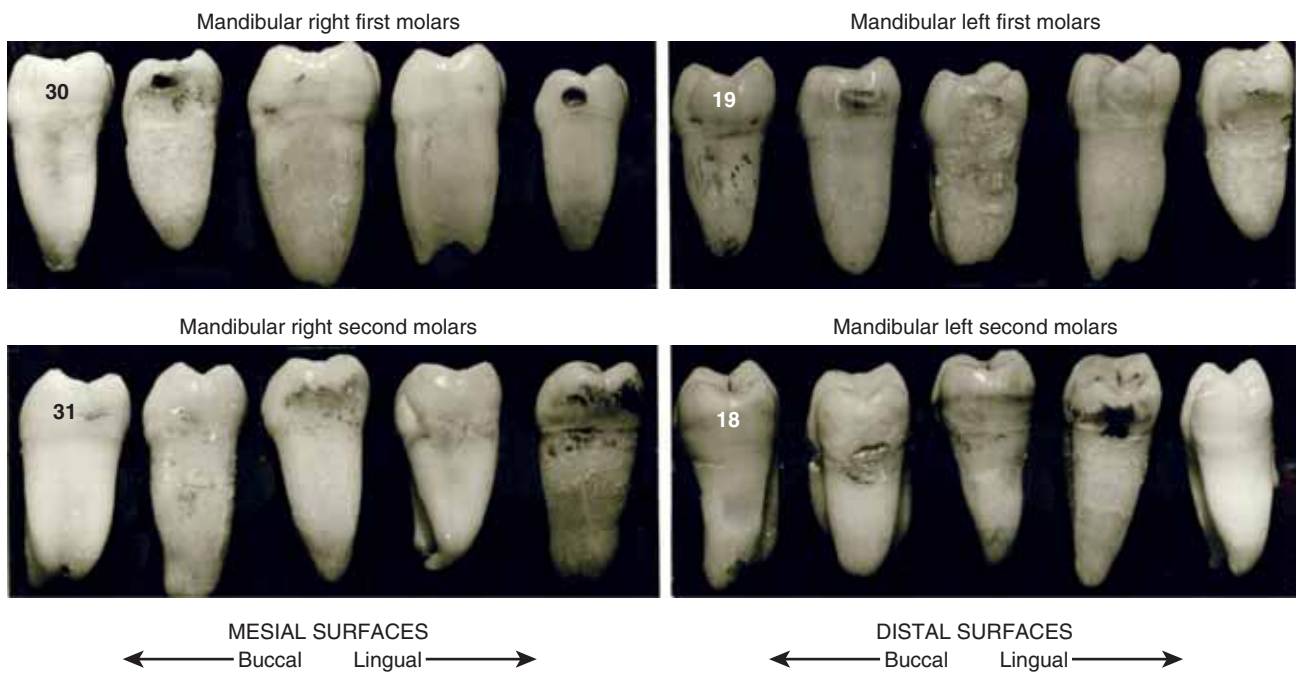
### 2. CUSP HEIGHT OF MANDIBULAR MOLARS FROM THE PROXIMAL VIEWS

In review, on the **four-cusp mandibular molars**, the cusps in order from longest to shortest are mesiolingual, distolingual, mesiobuccal, and distobuccal. Since cusps (and marginal ridges) are shorter on the distal than on the mesial, much of the occlusal surface and all cusp tips can be seen from the distal aspect (as seen on the distal surfaces of all teeth in Fig. 5-7). On the **five-cusp first molar**, the shortest distal cusp is also visible from the distal.





**MANDIBULAR MOLARS (proximal)**



**TRAITS TO DISTINGUISH MANDIBULAR FIRST MOLARS FROM SECOND MOLARS: PROXIMAL VIEWS**

**MANDIBULAR FIRST MOLAR**

Mesial root is wide faciolingually with blunt tip  
Crown is wider faciolingually

**MANDIBULAR SECOND MOLAR**

Mesial root less wide faciolingually with curved tip  
Crown is less wide faciolingually

**TRAITS TO DISTINGUISH MANDIBULAR RIGHT FROM LEFT MOLARS: PROXIMAL VIEWS**

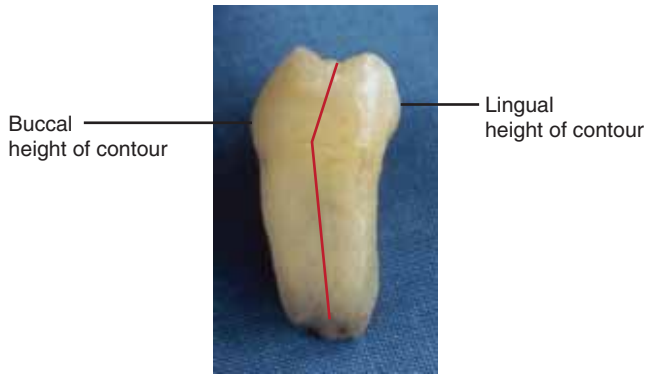
**MANDIBULAR FIRST MOLAR**

**MANDIBULAR SECOND MOLAR**

Mesial root is broader buccolingually, so distal root is not seen from mesial view for both  
Distal marginal ridge is more cervical than mesial marginal ridge for both (best seen from lingual view)

**FIGURE 5-7.** Proximal views of mandibular molars with type traits to distinguish mandibular first from second molars and to help distinguish rights from lefts.





**FIGURE 5-8.** Mesial view of a mandibular first molar shows the **lingual tilt** of its crown relative to its midroot axis line. This tilt is characteristic of mandibular posterior teeth.

Since the lingual cusps of *both* mandibular first and second molars are longer and more conical or pointed than the buccal cusps, the lingual cusps have longer triangular ridges.

### 3. TAPER TOWARD DISTAL OF MANDIBULAR MOLARS FROM THE PROXIMAL VIEWS

On *both* types of molars, the crown is narrower in the distal third than in the mesial third. Therefore, from the *distal* aspect, some of the lingual and the buccal surfaces can be seen (demonstrated clearly on the distal views of mandibular second molars in Fig. 5-7). Proximal contact areas may be seen as flattened areas (facets) caused from wear due to the rubbing of adjacent teeth during functional movements of the jaws. On **mandibular first molars**, the distal contact is centered on the distal surface cervical to the distal cusp.

### 4. CERVICAL LINES OF THE MANDIBULAR MOLARS WHEN COMPARING PROXIMAL VIEWS

*Mesial* cervical lines on *both* first and second molars slope occlusally from buccal to lingual and curve very slightly toward the occlusal surface.<sup>o</sup> The *distal* cervical lines are so slightly curved that they are nearly straight.

### 5. MARGINAL RIDGES OF MANDIBULAR MOLARS WHEN COMPARING PROXIMAL VIEWS

*Mesial* marginal ridges are concave buccolingually. *Distal* marginal ridges of the **first molar** are short and V shaped, located just lingual and distal to the distal cusp.

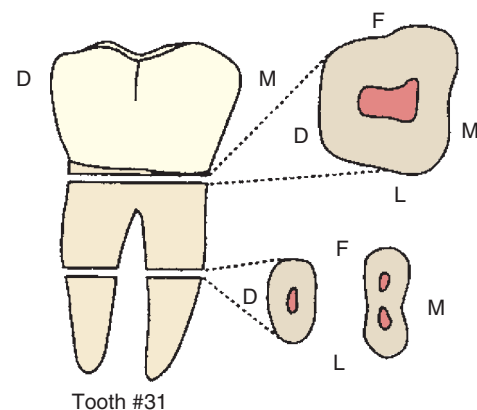
Differences in mesial and distal marginal ridge heights are apparent on handheld teeth when viewing

the crown from the lingual and rotating the tooth, first just enough in one direction to see the mesial marginal ridge height, and then enough in the opposite direction to compare it to the distal marginal ridge height. On mandibular molars, as with all posterior teeth (EXCEPT the mandibular first premolar), *mesial* marginal ridges are more occlusally located than distal marginal ridges so that from the mesial view, the triangular ridges are mostly hidden from view.

## 6. ROOTS AND ROOT DEPRESSIONS OF MANDIBULAR MOLARS FROM THE PROXIMAL VIEWS

From the mesial aspect, the *mesial* root of the **mandibular first molar** is broad buccolingually with a blunt wide apex, compared to the mesial root of the **mandibular second molar** that is often narrower buccolingually, and more pointed at the apex. The *distal* roots of *both* first and second mandibular molars are less broad buccolingually, more pointed at the apex, and shorter than the mesial roots. Therefore, from the *distal* view, the broader mesial root is usually visible behind the narrower distal root, and from the *mesial* view, the narrower distal root is hidden (seen clearly on all but one mandibular second molar from the distal view in Fig. 5-7).

There is usually a deep depression on the *mesial surface of the mesial root* on *both* mandibular first and second molars extending from the cervical line to the apex, indicating the likelihood of two root canals in this broad root, one buccal and one lingual (as seen in cross-section views in Fig. 5-9). Sometimes this root is even divided into a buccal and lingual part<sup>t</sup>

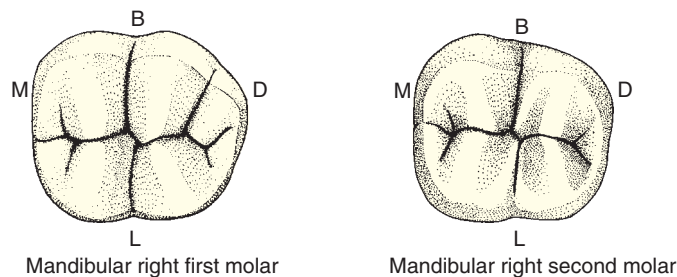


**FIGURE 5-9.** Cross sections through the root of a mandibular second molar: the top section is located at the level of the cervical line (showing the shape of the **pulp chamber** located in the root trunk), and a cross section in the middle third of the bifurcated roots showing the **depressions** on both sides of the mesial root with two root canals, and the distal root with one canal.

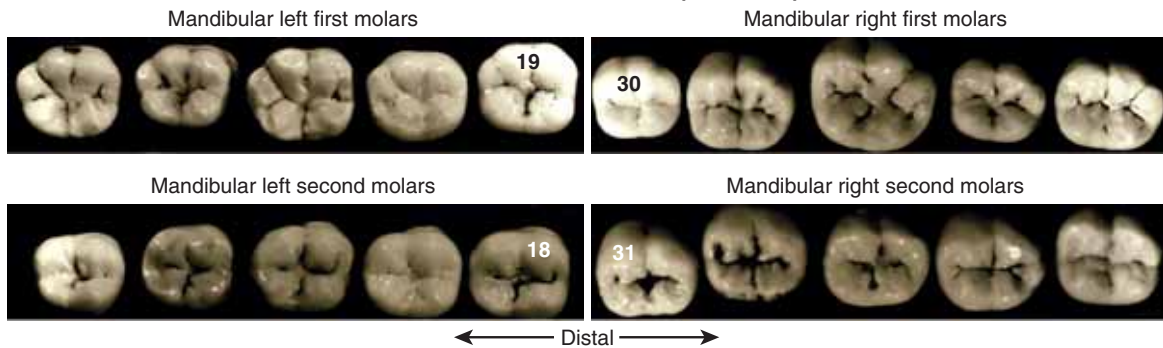
(seen in the partially divided mesial root of two mandibular first molars in Fig. 5-7). The presence of a longitudinal depression on the distal surface of the distal root is variable. The *distal root* most often has one root canal, but a distinct *distal root depression* may indicate the presence of two root canals in that root. Depressions on the inner surfaces of the mesial and distal roots (i.e., the surfaces between the mesial and distal roots) are often deeper than the depressions on the outer surfaces.

### D. TYPE TRAITS OF MANDIBULAR MOLARS FROM THE OCCLUSAL VIEW

To follow this description, the tooth should be held in such a position that the observer is looking exactly along the root axis line. Because of the lingual inclination of the crown, more of the buccal surface should be visible than the lingual surface when the tooth is properly held in this position, similar to mandibular premolars. Refer to *Figure 5-10* for



#### MANDIBULAR MOLARS (occlusal)



#### TRAITS TO DISTINGUISH MANDIBULAR FIRST MOLARS FROM SECOND MOLARS: OCCLUSAL VIEW

**MANDIBULAR FIRST MOLAR**

- Usually five cusps: three buccal and two lingual
- Less prominent buccal cervical ridge
- Pentagon shape (likely)
- More crown taper from buccal to lingual
- Fewer secondary grooves
- Central groove zigzags mesially to distally
- Mesiobuccal and distobuccal grooves do not align with lingual groove

**MANDIBULAR SECOND MOLAR**

- Usually four cusps (two buccal and two lingual)
- Buccal ridge more prominent (mesially)
- More rectangular shape
- Less crown taper from buccal to lingual
- More secondary grooves
- Central groove straighter
- Buccal and lingual grooves align to intersect with central groove like a “+”

#### TRAITS TO DISTINGUISH MANDIBULAR RIGHT FROM LEFT MOLARS: OCCLUSAL VIEW

**MANDIBULAR FIRST MOLAR**

- Crown tapers narrower in distal third
- Large mesiolingual and mesiobuccal cusps for both

**MANDIBULAR SECOND MOLAR**

- Crown wider on mesial due to buccal cervical ridge

**FIGURE 5-10.**

Occlusal views of mandibular molars with type traits to distinguish mandibular first from second molars and to help distinguish rights from lefts.

similarities and differences of mandibular molars from the occlusal view.

### 1. NUMBERS AND SIZE OF CUSPS OF MANDIBULAR MOLARS FROM THE OCCLUSAL VIEW

As stated earlier, most **mandibular second molars** have four cusps: two on the buccal (mesiobuccal and distobuccal) and two on the lingual (mesiolingual and distolingual). Most **mandibular first molars** have five cusps: three on the buccal (mesiobuccal, distobuccal, and the smallest distal cusp closest to the distal marginal ridge) and two on the lingual (mesiolingual and distolingual). On *both* types of mandibular molars, the two mesial cusps (mesiobuccal and mesiolingual) are larger than the two distal cusps (distobuccal and distolingual) (Fig. 5-11), and the fifth, distal cusp on first molars is the smallest.

### 2. OUTLINE SHAPE AND TAPER OF MANDIBULAR MOLARS FROM THE OCCLUSAL VIEW

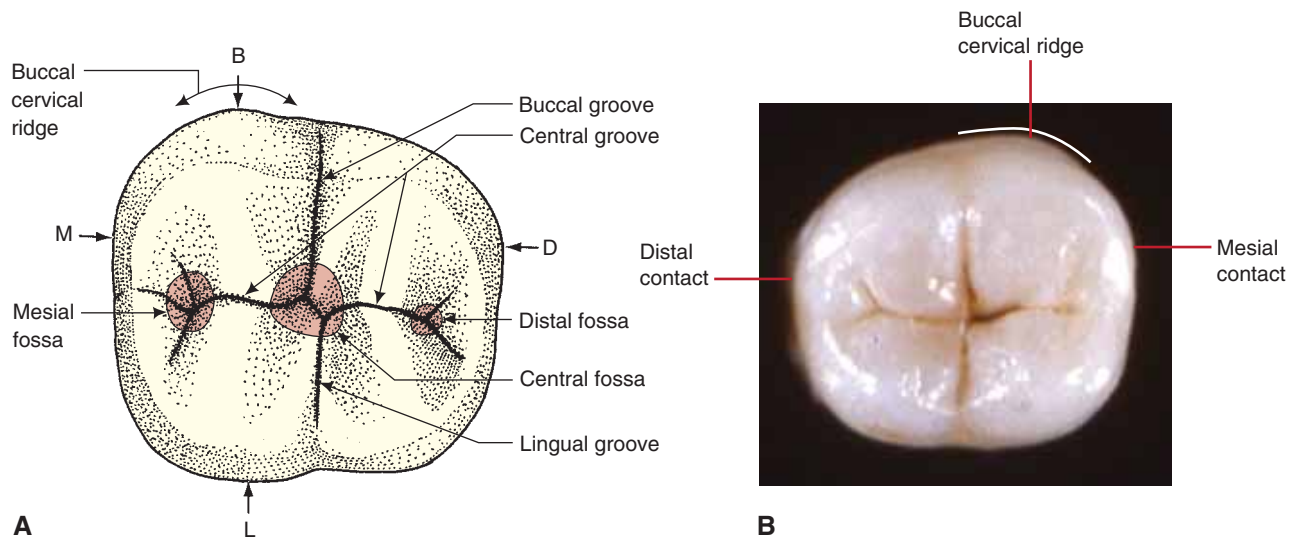
As stated previously, *both* types of mandibular molars are wider mesiodistally than faciolingually.<sup>Q</sup> The **mandibular second molar** outline is roughly a four-sided *rectangle*, whereas on the **first molar**, the widest portion of the tooth may be located in the middle third on

the prominent buccal bulge of its distobuccal cusp, so the outline would be more like a five-sided *pentagon* (Appendix 8k).

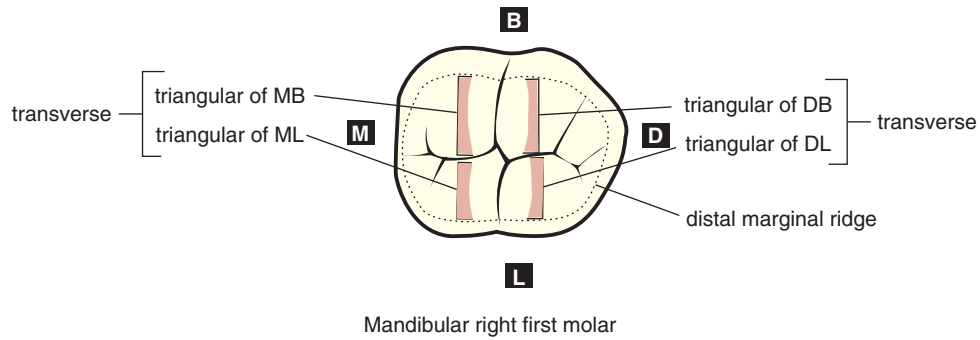
The crown outlines of *both* types of mandibular molars taper lingually, so they are wider mesiodistally on the buccal half than on the lingual half (recall Appendix 7b and c). Mandibular molar crowns also taper narrower from mesial to distal, so they are wider buccolingually on the mesial half than on the distal half. This wider buccolingual dimension on the mesial half of the **mandibular second molar** is due primarily to the prominent buccal *cervical ridge* that is most evident on the *mesiobuccal* cusp outline (Fig. 5-11). This bulge is a consistent landmark useful for identifying the mesiobuccal cusp on the buccal surface of the somewhat symmetrical mandibular second molars in Figure 5-11 and evident on most mandibular second molars in Figure 5-10.

### 3. RIDGES OF MANDIBULAR MOLARS FROM THE OCCLUSAL VIEW

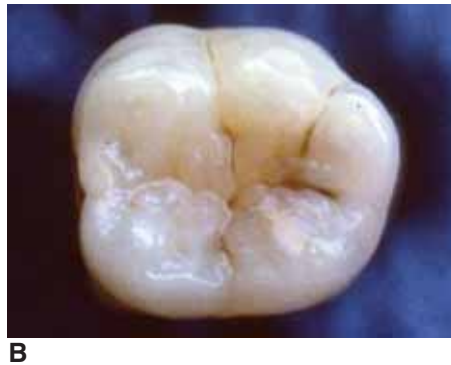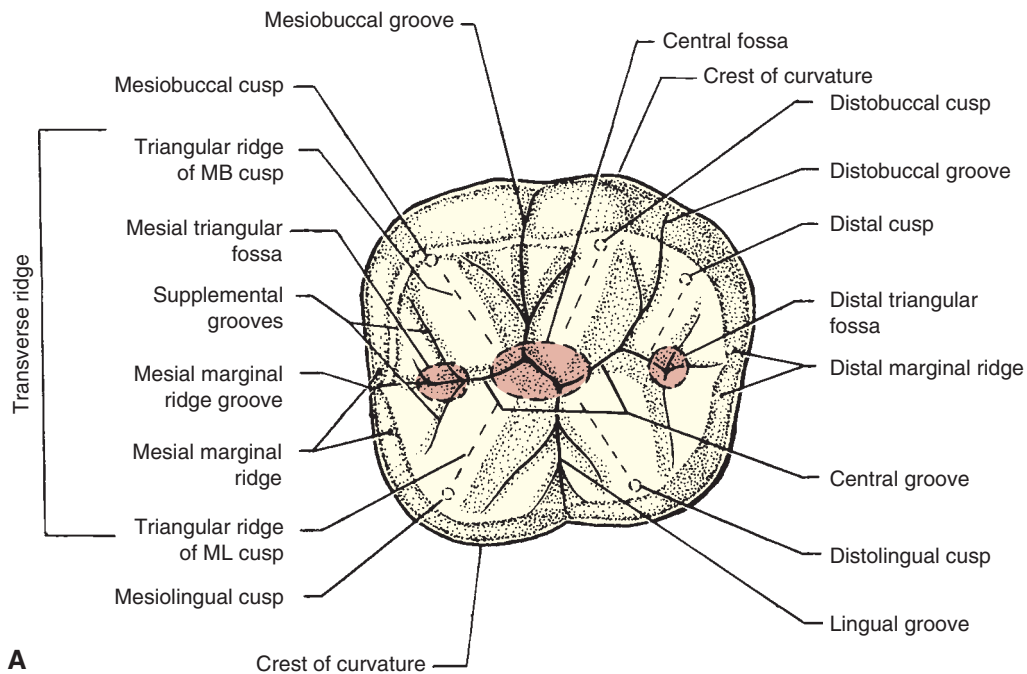
On *both* first and second mandibular molars, the triangular ridges of the mesiobuccal and mesiolingual cusps join to form a (mesial) transverse ridge, and the triangular ridges of the distobuccal and distolingual cusps form a second (distal) transverse ridge (Fig. 5-12).



**FIGURE 5-11.** **A.** Mandibular right second molar with its **three fossae**. Notice the outline bulge on the mesial portion of the buccal surface formed by the buccal cervical ridge. **Heights of contour** (crests of curvature) are indicated by arrows. The mesial and distal crests of curvature would normally coincide with proximal contact areas in the mouth. **B.** The buccal cervical ridge on this mandibular left second molar is most prominent on the **buccal outline of the mesiobuccal cusp**. The mesial contact is more buccal than the distal contact, but both proximal contacts are buccal to the buccolingual middle of the crown.



**FIGURE 5-12.** Mandibular right first molar, occlusal view, showing how the **triangular ridges** of two cusps (mesiobuccal [MB] and mesiolingual [ML]) align to form one **transverse ridge** in the mesial half of the mandibular molar, and another two triangular ridges of the distobuccal (DB) and distolingual (DL) cusps align to form another transverse ridge in the distal half.



**FIGURE 5-13.** **A.** Mandibular right first molar; occlusal view. Observe that the **buccal height of contour** (crest of curvature) is located close to the middle (compared to on a second molar where it is located in the mesial third). There are **three fossae**, with the central fossa largest. Note that the **central groove** zigzags in its course from mesial to distal pit, and the mesiobuccal and lingual grooves are not continuous from buccal to lingual. This pattern is quite common on first molars. **B.** Occlusal anatomy and outline of a mandibular right first molar.

#### 4. FOSSAE OF MANDIBULAR MOLARS FROM THE OCCLUSAL VIEW

There are three fossae on *both* types of mandibular molars: the largest central fossa (approximately in the center of the tooth), a smaller mesial triangular fossa (just inside the mesial marginal ridge), and the smallest distal triangular fossa (just inside the distal marginal ridge; it is very small on second molars). These fossae are shaded red in Figures 5-11 (on a second molar) and 5-13 (on a first molar). There may be a pit at the junction of grooves in the deepest portion of any of these fossae.

#### 5. GROOVES OF MANDIBULAR MOLARS FROM THE OCCLUSAL VIEW

The pattern of major grooves on **mandibular second molars** is simpler than that on first molars. It is made up of three major grooves: a central groove running mesiodistally, plus a buccal and a lingual groove. The *central groove* starts in the mesial triangular fossa, passes through the central fossa, and ends in the distal triangular fossa. Its mesiodistal course is straighter than on mandibular first molars. The *buccal groove* separates the mesiobuccal and distobuccal cusps and extends onto the buccal surface. The *lingual groove* separates the mesiolingual and the distolingual cusps but does not usually extend onto the lingual surface. The buccal and lingual grooves line up to form an almost continuous groove running from buccal to lingual that intersects with the central groove in the central fossa (Fig. 5-11). The resultant groove pattern resembles a cross (or +) (Appendix 8, occlusal view of the mandibular second molar).

Major grooves on the **mandibular first molar** separate five cusps instead of four, so the pattern is slightly more complicated (Fig. 5-13). As on second molars, the central groove passes from the mesial triangular fossa through the central fossa to the distal triangular fossa. The central groove may be more zigzag or crooked in its mesiodistal course. The lingual groove starts at the central groove in the central fossa and extends lingually between the mesiolingual and the distolingual cusps, but it is rare for a prominent lingual groove to extend onto the lingual surface. Instead of one buccal groove, the mandibular first molar has two. Like the buccal groove on mandibular second molars, this *mesiobuccal groove* separates the mesiobuccal and distobuccal cusps. It starts at the central groove, in or just mesial to the central fossa, and extends onto the buccal surface. This groove may be nearly continuous

with the lingual groove, or it may not join with it. The *distobuccal groove*, unique to the first molar, starts at the central groove between the central fossa and the distal triangular fossa and extends between the distobuccal and the distal cusps often onto the buccal surface.

Over half of mesial marginal ridges and over a third of distal marginal ridges of mandibular molars are crossed by marginal ridge grooves.<sup>R</sup> Some mandibular first molars in Figure 5-10 have mesial marginal ridge grooves, but fewer have distal marginal ridge grooves.

On mandibular first and second molars, there may be supplemental (extra, minor) grooves. All grooves provide important escape-ways for food as it is crushed. Supplemental *ridges* are located between supplemental and major grooves and serve as additional cutting blades. Without these ridges and grooves, the teeth would be inefficient crushers and subject to unfavorable forces during chewing. Brand and Isselhard state that mandibular second molars have more secondary grooves than first molars.<sup>5</sup>

#### 6. PROXIMAL CONTACT AREAS OF MANDIBULAR MOLARS FROM THE OCCLUSAL VIEW

The mesial and distal contact areas of mandibular first and second molars are normally slightly buccal to the middle of the tooth. Therefore, when molars are in contact with adjacent teeth, the space (embrasure) lingual to the contact is longer (larger) than the space buccal to the contact. Mesial contact areas on **mandibular first molars** are just buccal to the center buccolingually, whereas distal contacts are just lingual to the distal cusp. On **mandibular second molars**, mesial contacts are near the junction of the middle and buccal thirds, whereas the distal contacts are just buccal to the center buccolingually (Fig. 5-11).

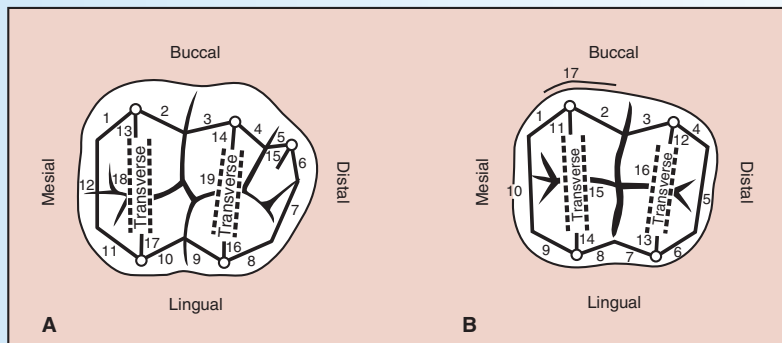
#### LEARNING EXERCISE

Learning exercise related to mandibular molars:

Examine your mouth and the mouths of a few of your associates to determine if the mandibular first molars have four or five cusps, and if the second molars have four cusps. Also, see if their first molars are larger than their seconds, and seconds are larger than their thirds.



### LEARNING EXERCISE



**A.** Name the ridges

**B.** Name the ridges

Ridges	Name
1.	_____
2.	_____
3.	_____
4.	_____
5.	_____
6.	_____
7.	_____
8.	_____
9.	_____
10.	_____
11.	_____
12.	_____
13.	_____
14.	_____
15.	_____
16.	_____
17.	_____
18.	_____
19.	_____

Ridges	Name
1.	_____
2.	_____
3.	_____
4.	_____
5.	_____
6.	_____
7.	_____
8.	_____
9.	_____
10.	_____
11.	_____
12.	_____
13.	_____
14.	_____
15.	_____
16.	_____
17.	_____

**FIGURE 5-14.**

**A.** List all 19 ridges that circumscribe or make up the boundary of the occlusal surface of a mandibular first molar as represented in Figure 5-14A. **B.** List all 17 ridges that circumscribe or make up the boundary of the occlusal surface of a mandibular second molar as represented in Figure 5-14B. In case you wondered, ridge 17 on the second molar is the buccal cervical ridge (sometimes evident, sometimes not).

**ANSWERS:** *A. Mandibular first molar ridges: 1—mesial cusp ridge of mesiobuccal cusp; 2—distal cusp ridge of mesiobuccal cusp; 3—mesial cusp ridge of distobuccal cusp; 4—distal cusp ridge of distobuccal cusp; 5—mesial cusp ridge of distal cusp; 6—distal cusp ridge of distal cusp; 7—distal marginal ridge; 8—distal cusp ridge of distolingual cusp; 9—mesial cusp ridge of distolingual cusp; 10—distal cusp ridge of mesiolingual cusp; 11—mesial cusp ridge of mesiolingual cusp; 12—mesial marginal ridge; 13—triangular ridge of mesiobuccal cusp; 14—triangular ridge of distobuccal cusp; 15—triangular ridge of distal cusp; 16—triangular ridge of distolingual cusp; 17—triangular ridge of mesiolingual cusp; 18—transverse ridge (mesial); 19—transverse ridge (distal)*

*B. Mandibular second molar ridges: 1—mesial cusp ridge of mesiobuccal cusp; 2—distal cusp ridge of mesiobuccal cusp; 3—mesial cusp ridge of distobuccal cusp; 4—distal cusp ridge of distobuccal cusp; 5—distal marginal ridge; 6—distal cusp ridge of distolingual cusp; 7—mesial cusp ridge of distolingual cusp; 8—distal cusp ridge of mesiolingual cusp; 9—mesial cusp ridge of mesiolingual cusp; 10—mesial marginal ridge; 11—triangular ridge of mesiobuccal cusp; 12—triangular ridge of distobuccal cusp; 13—triangular ridge of distolingual cusp; 14—triangular ridge of mesiolingual cusp; 15—transverse ridge (mesial); 16—transverse ridge (distal); 17—mesial (mesiobuccal) cervical ridge*

## Review Questions

Answer the following questions about mandibular molars by circling the best answer(s). More than one answer may be correct.

- Which of the following grooves radiate out from the central fossa in a mandibular second molar?
  - Central
  - Mesiobuccal
  - Distobuccal
  - Lingual
  - Buccal
- Which cusp is the largest and longest on a mandibular second molar?
  - Mesiobuccal
  - Distobuccal
  - Mesiolingual
  - Distolingual
  - Distal
- Which cusp may be absent on a mandibular first or third molar?
  - Mesiobuccal
  - Distobuccal
  - Mesiolingual
  - Distolingual
  - Distal
- When this cusp is absent in question No. 3 above, which groove(s) would not be present?
  - Buccal
  - Lingual
  - Mesiobuccal
  - Distobuccal
  - Lingual
- Which fossae are found on a mandibular first molar?
  - Mesial triangular
  - Distal triangular
  - Buccal
  - Lingual
  - Central
- Which developmental groove connects with the lingual groove running in the same direction on a mandibular second molar?
  - Mesiobuccal
  - Distobuccal
- Which of the following grooves radiate out from the central fossa in a mandibular second molar?
  - Buccal
  - Mesiolingual
  - Distolingual
- From which view is only one root visible on a mandibular first molar?
  - Mesial
  - Distal
  - Buccal
  - Lingual
  - Apical
- Which root may occasionally be divided or bifurcated on a mandibular first molar?
  - Buccal
  - Lingual
  - Mesial
  - Distal
  - Mesiobuccal
- Which cusp triangular ridge does not meet to form a transverse ridge on a five-cusp first molar?
  - Mesiobuccal
  - Distobuccal
  - Mesiolingual
  - Distolingual
  - Distal
- Which ridges form the boundaries of the mesial triangular fossa of a mandibular molar?
  - Triangular ridge of mesiobuccal cusp
  - Triangular ridge of mesiolingual cusp
  - Mesial marginal ridge
  - Buccal cusp ridge of mesiobuccal cusp
  - Lingual cusp ridge of mesiolingual cusp
- Which two pairs of cusp triangular ridges make up or join to form the two transverse ridges on a mandibular second molar?
- List in sequential order the longest to shortest cusps on the mandibular first molar.

**ANSWERS:** 1—a, d, e; 2—c; 3—c; 4—c, d; 5—a, b, e; 6—c; 7—a; 8—c; 9—e; 10—a, b, c; 11—mesio-buccal and mesio-lingual PLUS distobuccal and distolingual, 12—mesio-lingual, distolingual, mesio-buccal, distobuccal, then distal

## SECTION III

## TYPE TRAITS THAT DIFFERENTIATE MAXILLARY SECOND MOLARS FROM MAXILLARY FIRST MOLARS

## OBJECTIVES

This section prepares the reader to perform the following:

- Describe the type traits that can be used to distinguish the permanent maxillary first molar from the maxillary second molar.
- Describe and identify the buccal, lingual, mesial, distal, and occlusal surfaces for all maxillary molars.
- Assign a Universal number to maxillary molars present in a mouth (or on a model) with complete dentition. If possible, repeat this on a model with one or more maxillary molars missing.
- Holding a maxillary molar, determine whether it is a first or a second and right or left. Then assign a Universal number to it.

### A. TYPE TRAITS OF THE MAXILLARY MOLARS FROM THE BUCCAL VIEW

Examine a maxillary first and second molar as you read. Hold the roots up and the crowns down, with the two somewhat parallel buccal roots toward you.

#### 1. RELATIVE CROWN SIZE AND SHAPE FROM THE BUCCAL VIEW

Refer to *Figure 5-15* for similarities and differences of maxillary molars from the buccal view.

Maxillary first molars have the largest occlusal outline of all maxillary teeth followed closely by the second molars in the same mouth. (Third molars are generally the smallest molar.)

The crowns of both the first and second maxillary molars are broad mesiodistally, but the maxillary first molar is most often the widest tooth in the upper arch. The buccal crown height tapers shorter on the distal than on the mesial, which is most helpful in distinguishing rights from lefts. Since the occlusal surface slants cervically from mesial to distal, some have suggested that the crown appears to tip distally at its cervix on its root trunk.

#### 2. NUMBERS AND SIZE OF CUSPS ON MAXILLARY MOLARS (AND ASSOCIATED GROOVE) FROM THE BUCCAL VIEW

As on mandibular molars, *both* first and second maxillary molars have four larger cusps (seen best on an occlusal view in *Fig. 5-16*). The relative heights of the four major cusps of maxillary molars are the *longest* mesiolingual, followed by the mesiobuccal, distobuccal, and the *shortest* distolingual (if present).

Therefore, from the buccal view, the two buccal cusps are prominently visible, but the mesiolingual cusp tip may be visible because it is longer (and even the short distolingual cusp might be seen because it, and the mesiolingual cusp, are positioned slightly to the distal of the buccal cusps).

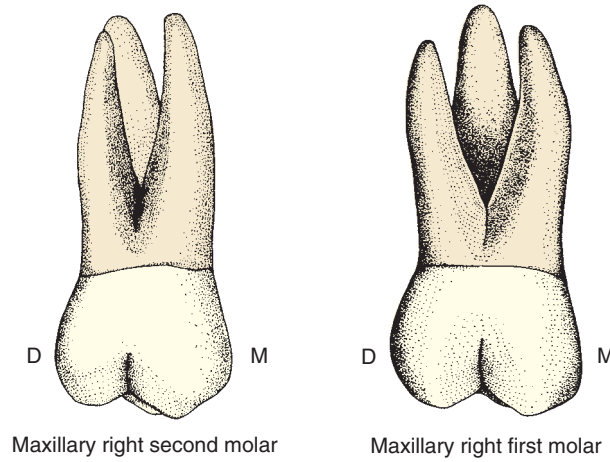
Of the two buccal cusps, the mesiobuccal cusp is normally wider than the distobuccal cusp, but not necessarily sharper.<sup>5</sup> A buccal groove lies between the buccal cusps and may extend onto the buccal surface to the middle third of the crown, but this groove is unlikely to be fissured and form decay on the buccal surface.

#### 3. PROXIMAL CONTACTS OF MAXILLARY MOLARS FROM THE BUCCAL VIEW (SAME FOR ALL MOLARS)

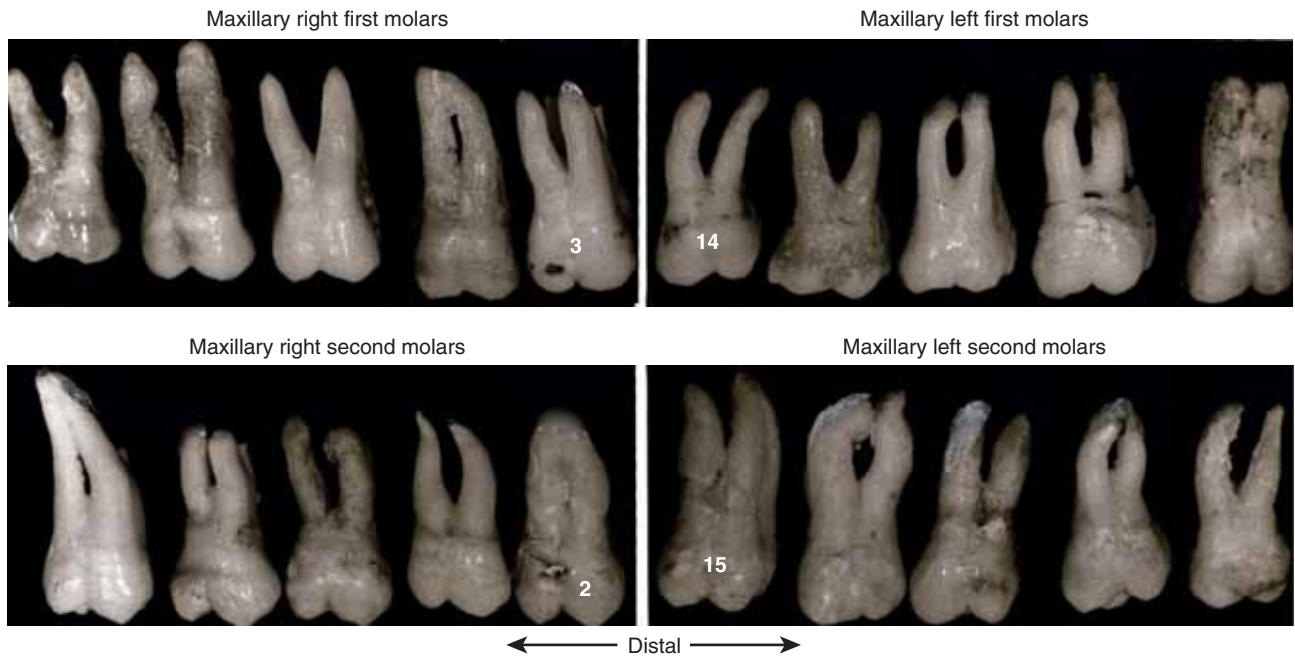
For *most* maxillary (and mandibular) first and second molars, the mesial contact is located near the junction of occlusal and middle thirds. The distal contact is located more cervically in the middle third of the crown. A summary of the location of the proximal contacts of maxillary and mandibular molars is found in *Table 5-3*, and a review for all adult teeth (except thirds) is presented in *Table 5-4*.

#### 4. ROOTS OF MAXILLARY MOLARS FROM THE BUCCAL VIEW

There are three roots on a maxillary molar: the mesiobuccal, the distobuccal, and the lingual. The root trunks are relatively long with the furcation (trifurcation) often near the junction of the cervical and middle thirds. The three roots are close to the same length,<sup>†</sup> but the lingual (palatal) root is the longest, followed by the mesiobuccal root, and then the



**MAXILLARY MOLARS (buccal)**

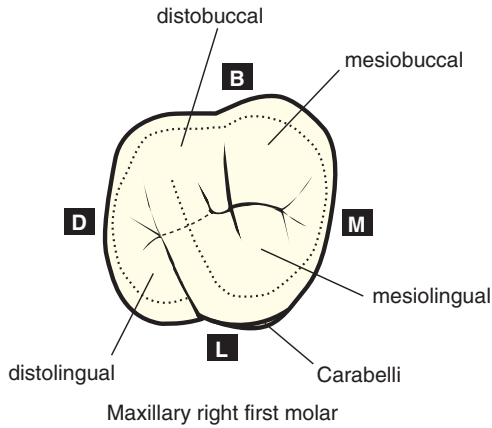


TRAITS TO DISTINGUISH MAXILLARY FIRST MOLARS FROM SECOND MOLARS: BUCCAL VIEW	
<b>MAXILLARY FIRST MOLAR</b>	<b>MAXILLARY SECOND MOLAR</b>
Roots more spread out, shorter trunk	Root less spread out, longer trunk
Roots with less distal bend	Roots with more distal bend
Buccal cusps almost same size	Mesiobuccal cusp larger than distobuccal

TRAITS TO DISTINGUISH MAXILLARY RIGHT FROM LEFT MOLARS: BUCCAL VIEW	
<b>MAXILLARY FIRST MOLAR</b>	<b>MAXILLARY SECOND MOLAR</b>
Distobuccal cusp shorter than wider mesiobuccal cusp	
Mesiobuccal root longer than distobuccal root for both	
Crown tilts distally on its root base with the occlusal surface shorter on distal for both	

**FIGURE 5-15.** Buccal views of maxillary molars with type traits to distinguish maxillary first from second molars and to help distinguish rights from lefts.



**FIGURE 5-16.** Maxillary right first molar, occlusal view, showing the cusp names and relative sizes of cusps.

shortest distobuccal root, so all three may be visible from the buccal view.

There is much variation in the shapes of the roots. On maxillary first molars, the more blunt mesiobuccal root and the distobuccal root are often well separated (Appendix 8j, buccal view). Both buccal roots often bend distally, or they may bend in such a way that they look like pliers handles. The mesiobuccal root may bow out mesially in the cervical half before it curves toward the distal, placing its apex distal to the line of the buccal groove on the crown.

In contrast, maxillary second molar roots are often closer together, less curved, more nearly parallel, and with a longer root trunk. Often both roots bend toward the distal in their apical third. Find the two maxillary second molars in Figure 5-15 that are exceptions.

Table 5-3		MOLARS: LOCATION OF PROXIMAL CONTACTS <sup>a</sup> (PROXIMAL HEIGHT OF CONTOUR; SEEN BEST FROM FACIAL)	
		MESIAL SURFACE (WHICH THIRD OR JUNCTION?)	DISTAL SURFACE (WHICH THIRD OR JUNCTION?)
MAXILLARY CROWNS	First molar	Occlusal/middle junction	Middle of crown
	Second molar	Occlusal/middle junction	Middle of crown
MANDIBULAR CROWNS	First molar	Occlusal/middle junction	Middle of crown
	Second molar	Occlusal/middle junction	Middle of crown

<sup>a</sup>General learning guidelines:  
 1. For molars, the mesial and distal contacts are closer to the middle of the tooth and are more nearly at the same level than on premolars or anterior teeth.  
 2. Distal proximal contacts are slightly more cervical than mesial contacts.  
 Source: Brand RW, Isselhard DE. Anatomy of orofacial structures. 6th ed. St. Louis, MO: C.V. Mosby, 1998.

Table 5-4		SUMMARY OF LOCATION OF PROXIMAL CONTACTS ON ALL TEETH <sup>a</sup> (PROXIMAL HEIGHT OF CONTOUR; SEEN BEST FROM FACIAL VIEW)	
		MESIAL SURFACE (WHICH THIRD OR JUNCTION?)	DISTAL SURFACE (WHICH THIRD OR JUNCTION?)
MAXILLARY CROWNS	Central incisor	Incisal third (near incisal edge)	Incisal/middle junction
	Lateral incisor	Incisal third	Middle third (most cervical of incisor contacts)
	Canine	Incisal/middle junction	Middle third (most cervical of anterior teeth contacts)
	First premolar	Middle third or occlusal/middle junction	Middle third (but more cervical)
	Second premolar	Middle third (near occlusal/middle junction)	Middle third (but more cervical)
	First molar	Occlusal/middle junction	Middle of crown
	Second molar	Occlusal/middle junction	Middle of crown

(continued)



Table 5-4

**SUMMARY OF LOCATION OF PROXIMAL CONTACTS ON ALL TEETH<sup>a</sup> (PROXIMAL HEIGHT OF CONTOUR; SEEN BEST FROM FACIAL VIEW) (Continued)**

	MESIAL SURFACE (WHICH THIRD OR JUNCTION?)	DISTAL SURFACE (WHICH THIRD OR JUNCTION?)	
MANDIBULAR CROWNS	<b>Central incisor</b>	Incisal third (near incisal edge)	Incisal third (near incisal edge; same as mesial)
	<b>Lateral incisor</b>	Incisal third (near incisal edge)	Incisal third (but more cervical)
	<b>Canine</b>	Incisal third (just apical to mesioincisal angle)	Incisal/middle junction
	<b>First premolar</b>	Occlusal/middle junction or middle third	Occlusal third (more occlusal than on mesial = EXCEPTION to the rule)
	<b>Second premolar</b>	Occlusal/middle junction	Middle third (which is more cervical than on mesial)
	<b>First molar</b>	Occlusal/middle junction	Middle of crown
	<b>Second molar</b>	Occlusal/middle junction	Middle of crown

<sup>a</sup>General learning guidelines:

1. On any single tooth, distal proximal contacts are more cervical than mesial contacts EXCEPT for **mandibular central incisors**, where the mesial and distal contacts are at the same height, and **mandibular first premolars**, where the mesial contact is more cervical than the distal.
2. Proximal contacts become more cervical when moving from anterior to posterior teeth.
  - a. For anterior teeth, most contacts are in the incisal third EXCEPT the distal of maxillary lateral incisors and canines, which are more in the middle third.
  - b. For posterior teeth, the mesial and distal contacts are closer to the middle of the tooth and are more nearly at the same level.
3. No proximal contact is cervical to the middle of the tooth.

## B. TYPE TRAITS OF MAXILLARY MOLARS FROM THE LINGUAL VIEW

Refer to *Figure 5-17* for similarities and differences.

### 1. RELATIVE SIZE AND TAPER OF MAXILLARY MOLARS FROM THE LINGUAL VIEW

Little or no mesial or distal surfaces of **maxillary first molar** crowns are visible from the lingual view (except in the cervical third) since these teeth may be as wide or wider on the lingual half than on the buccal half due to a relatively wide distolingual cusp. This is an EXCEPTION (along with the three-cusp mandibular second premolar) to the normal taper toward the lingual for all other posterior teeth. **Maxillary second molars** are narrower in the lingual half due to the relatively smaller or nonexistent distolingual cusp. The lingual surface of the crown on *both* types of maxillary molars is narrower in the cervical third than in the middle third, since the crown tapers to join the single palatal root (seen clearly in the maxillary molars in *Fig. 5-17*).

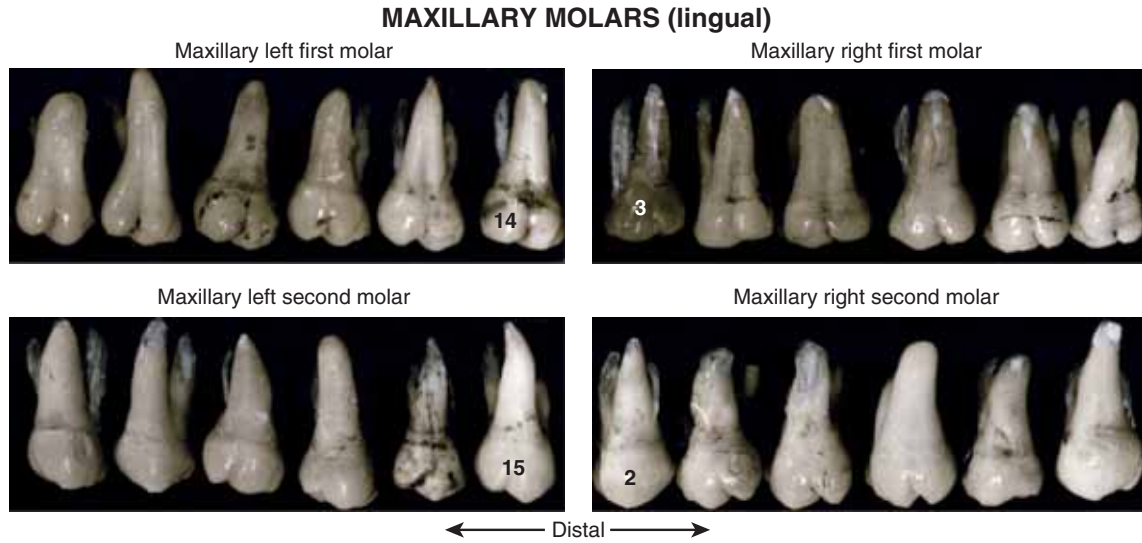
### 2. NUMBERS AND DESCRIPTION OF LINGUAL CUSPS ON A MAXILLARY MOLAR FROM THE LINGUAL VIEW

On the **maxillary first molar**, there are two well-defined cusps on the lingual surface, the larger mesiolingual cusp and the smaller, but still sizeable, distolingual cusp. The mesiolingual cusp is almost always the largest and highest cusp on any maxillary molar (seen on most first molars in *Fig. 5-17*).

Additionally, on over two thirds of maxillary first molars, a small fifth *cuspid of Carabelli* (or a groove or depression in the same area) is found on the *lingual surface of the mesiolingual cuspid*<sup>U</sup> (*Appendix 8i*). This cusp was named after the Austrian dentist who described it, Georg von Carabelli (1787–1842). This cusp varies greatly in shape but is considered to be a nonfunctioning cusp because it is about 2 mm shorter than the mesiolingual cusp tip. Examples of a large cusp of Carabelli and a groove in the same area are seen in *Figure 5-18*.

There are two types of **maxillary second molars** based on the number of cusps (four or three). Slightly less than two thirds of maxillary second molars have four cusps: two buccal and two lingual cusps—a mesiolingual cusp (which is considerably larger) and a smaller distolingual cusp. Over one third of maxillary second molars have only three cusps called a tricuspid form.<sup>V</sup> On these teeth, the distolingual cusp is missing, so it has just one large lingual cusp and two buccal cusps. Normally, there is no cusp of Carabelli on maxillary second molars.

On *both* first and second maxillary molars with *two* lingual cusps, there is a groove separating the mesiolingual and distolingual cusps that extends onto the lingual surface where it is called the lingual groove. This lingual groove may be continuous with the longitudinal depression on the lingual surface of the lingual root. On the **three-cusp type of maxillary second molars**, there is no distolingual cusp, so there is no lingual groove. See if you can identify the maxillary second molars with only one lingual cusp in *Figure 5-17*.



**TRAITS TO DISTINGUISH MAXILLARY FIRST MOLARS FROM SECOND MOLARS: LINGUAL VIEW**

**MAXILLARY FIRST MOLAR**

Buccal roots spread out behind lingual root  
Lingual cusps nearly the same width

**MAXILLARY SECOND MOLAR**

Buccal roots less spread out  
Distolingual cusp narrower than mesiolingual, or absent

**TRAITS TO DISTINGUISH MANDIBULAR RIGHT FROM LEFT MOLARS: LINGUAL VIEWS**

**MAXILLARY FIRST MOLAR**

Cusp of Carabelli present on mesiolingual  
Mesiolingual cusp a little larger than distolingual

**MAXILLARY SECOND MOLAR**

Cusp of Carabelli absent  
Mesiolingual cusp even larger relative to smaller distolingual

The distal half of the crown is shorter than the mesial half for both  
The distal marginal ridge is located more cervically than the mesial marginal ridge

**FIGURE 5-17.**

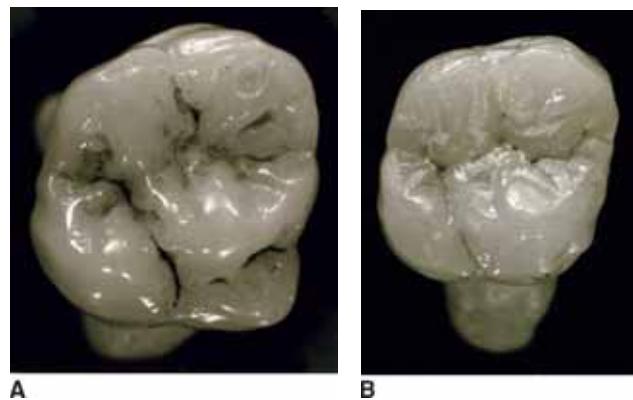
Lingual views of maxillary molars with type traits to distinguish maxillary first from second molars and to help distinguish rights from lefts.

**3. MAXILLARY MOLAR ROOTS FROM THE LINGUAL VIEW**

On both the maxillary first and second molars, the broad, longest lingual root<sup>w</sup> is not curved when seen from the lingual view, but it does taper apically to a blunt or rounded apex. On firsts, there is usually a longitudinal depression on the lingual side of the lingual root (seen in many lingual roots of maxillary first molars in Fig. 5-17). The buccal roots are spread out far enough that they are usually visible behind the lingual root from this view, especially on first molars.

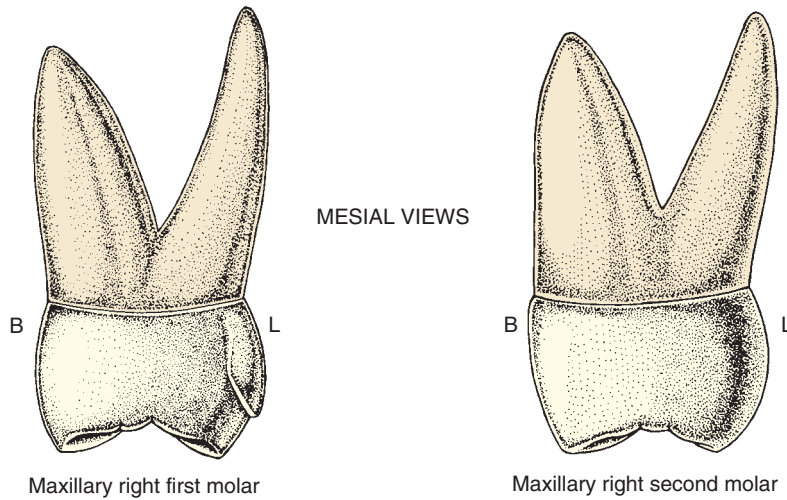
**C. TYPE TRAITS OF MAXILLARY MOLARS FROM THE PROXIMAL VIEWS**

Refer to Figure 5-19 for similarities and differences of maxillary molars from the proximal views.

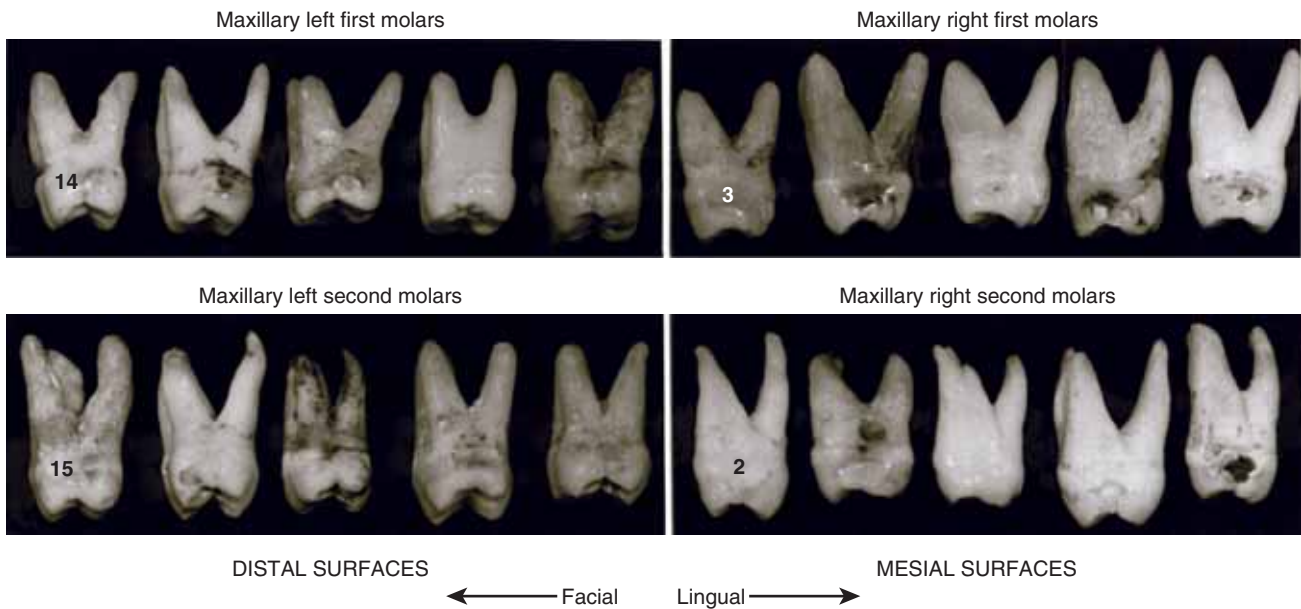


**FIGURE 5-18.**

Two maxillary right first molars with differences in the **mesiolingual cusp**: Molar A has a *very large* cusp of Carabelli, but B has a *slight depression* in the same location. Also, notice the prominent *lingual roots* showing from this view due to the large spread of roots on these maxillary first molars.



**MAXILLARY MOLARS (proximal)**



TRAITS TO DISTINGUISH MAXILLARY FIRST MOLARS FROM SECOND MOLARS: PROXIMAL VIEWS	
<b>MAXILLARY FIRST MOLAR</b>	<b>MAXILLARY SECOND MOLAR</b>
Some root flare beyond crown	Less root flare
Cusp of Carabelli on mesiolingual cusp	No cusp of Carabelli

TRAITS TO DISTINGUISH MAXILLARY RIGHT FROM LEFT MOLARS: PROXIMAL VIEWS	
<b>MAXILLARY FIRST MOLAR</b>	<b>MAXILLARY SECOND MOLAR</b>
Cusp of Carabelli on mesiolingual cusp	Small or absent distolingual cusp
The distal marginal ridge is located more cervically than the mesial marginal ridge (best seen from lingual view)	
The distobuccal root is narrow, so wider mesiobuccal root is visible from distal view	

**FIGURE 5-19.** Proximal views of maxillary molars with type traits to distinguish maxillary first from second molars and to help distinguish rights from lefts.

## 1. MAXILLARY MOLAR CUSPS FROM THE PROXIMAL VIEWS

Like the crowns of a mandibular molar, **maxillary first molar** crowns appear short occlusocervically and broad faciolingually from the proximal view. Recall that the cusps of this first molar from longest to shortest are mesiolingual, mesiobuccal, distobuccal, and distolingual, followed by the functionless cusp of Carabelli. Therefore, from the *distal* view, the distobuccal cusp and smallest distolingual cusp are prominent in the foreground, while the cusp tips of the longer mesiobuccal and longest mesiolingual cusp can be seen behind them. In contrast, only the longer mesial cusps are visible from the *mesial* view. If present, a prominent cusp of Carabelli can be seen on the lingual outline of the mesiolingual cusp (2–3 mm cervical to the mesiolingual cusp tip) from both the mesial and distal views (Fig. 5-19 drawing).

From the mesial and distal views, the crown of the **maxillary second molar** looks much like that of the first molar, except that there is no fifth cusp (Fig. 5-19). Also, the distolingual cusp is absent on more than one third of these teeth.

## 2. HEIGHT OF CONTOUR FOR MAXILLARY MOLARS FROM THE PROXIMAL VIEWS (SAME FOR ALL POSTERIOR TEETH)

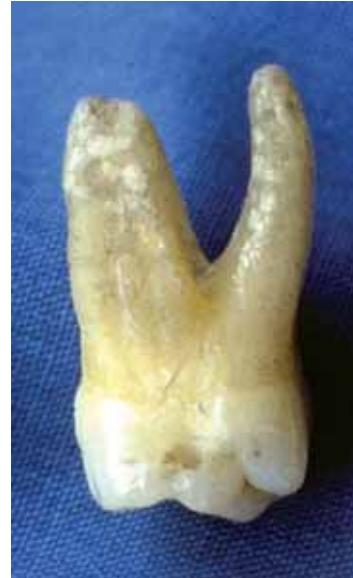As on all posterior teeth, the height of contour of the buccal surface of both first and second maxillary molar crowns is in the cervical third, usually close to the cervical line. The height of contour of the lingual surface of the crown is more occlusal, usually in or near the middle third of the crown. However, the lingual crest of curvature may be located even more occlusally on teeth with a large cusp of Carabelli (Fig. 5-20).

## 3. TAPER TOWARD DISTAL OF MAXILLARY MOLARS FROM THE DISTAL VIEW

From the distal view on *both* maxillary first and second molars, both the buccal surface and the lingual surface of the crown can be seen because the crown tapers toward the distal, so the crown is narrower buccolingually on the distal surface than on the mesial surface (seen on most distal views in Fig. 5-19).

## 4. MARGINAL RIDGES OF MAXILLARY MOLARS FROM THE PROXIMAL VIEWS

As on mandibular molars, *both* first and second maxillary molars have a concave distal marginal ridge that



**FIGURE 5-20.** Maxillary right first molar, mesial view, with an unusually **large cusp of Carabelli** and a lingual height of contour positioned quite occlusally. Also, note that the wide mesiobuccal root hides the narrower distobuccal root.

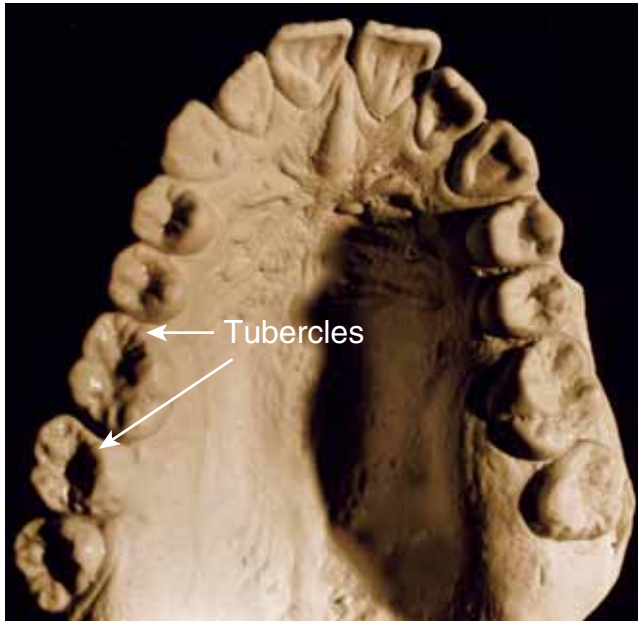
is located more cervically than its mesial marginal ridge, permitting a better view of the occlusal surface (including the triangular ridges) from the distal view than from the mesial view. (Compare mesial and distal views in Fig. 5-19.) This marginal ridge height difference is very helpful in differentiating right from left sides.

In general, *marginal ridge grooves* are found on over two thirds of mesial marginal ridges but fewer than half of distal marginal ridges<sup>x</sup> and are more common on first molars than on seconds. Also, on the unworn marginal ridges of the maxillary molars, there may be one or more projections of enamel called *tubercles*. Like marginal ridge grooves, they are more common on mesial marginal ridges than on the distal (and are more common on first molars than on seconds).<sup>y</sup> These tubercles are seen most clearly on the mesial marginal ridges of the maxillary first and second molars in Figure 5-21.

## 5. CERVICAL LINES OF MAXILLARY MOLARS FROM THE PROXIMAL VIEWS

On *both* types of maxillary molars, the *mesial* cervical line has a slight occlusal curvature.<sup>z</sup> There is less curvature of the cervical line on the distal surface than on the mesial surface, but the difference is hardly discernible, since this cemento-enamel junction is practically flat buccolingually.





**FIGURE 5-21.** Dental stone cast of the maxillary dentition demonstrating **decreasing size** from first to third molars on the left side of this photograph. Both second molars are three-cusp types with only one lingual cusp (tricuspid form). Also note the tubercles on the mesial marginal ridges of the first molars. Tooth No. 16 is missing.

## 6. ROOTS OF MAXILLARY MOLARS FROM THE PROXIMAL VIEWS

On *both* the maxillary first and second molars from the *mesial* view, two roots can be seen: the lingual root and the mesiobuccal root, which is considerably wider buccolingually than the hidden distobuccal root (Appendix 8, mesial views). On the **first maxillary molar**, the convex **buccal** outline of the *mesiobuccal root* often extends a little buccal to the crown outline, but the apex of this root is in line with the tip of the mesiobuccal cusp (Fig. 5-19). The *lingual* outline of the mesiobuccal root is often more convex and, in the apical third, curves sharply facially toward the apex. The longest *lingual* root is bent somewhat like a curved banana (concave on its buccal surface), and it extends conspicuously beyond the crown lingually. Compare the differences in Figure 5-19.

From the *distal* view of *both* maxillary first and second molars, you can see the lingual root, the distobuccal root which is shorter, more pointed, and narrower buccolingually than the mesiobuccal root, and the wider mesiobuccal root behind it (evident on most distal views in Fig. 5-19).

Table 5-5

### SUMMARIES: PRESENCE AND RELATIVE DEPTH OF LONGITUDINAL ROOT DEPRESSIONS (“ROOT GROOVES”)

TOOTH	MESIAL ROOT DEPRESSION?	DISTAL ROOT DEPRESSION?	
MAXILLARY TEETH	Maxillary central incisor	No (or slight or flat)	No (convex)
	Maxillary lateral incisor	Yes (sometimes no)	No (convex)
	Maxillary canine	Yes	Yes (deeper)
	Maxillary first premolar	Yes (deeper = <b>UNIQUE</b> , extends onto mesial of crown)	Yes
	Maxillary second premolar	Yes	Yes (deeper)
	Maxillary first and second molars	<b>Mesiobuccal root:</b> Yes	Variable
		<b>Distobuccal root:</b> variable	No (convex) but root trunk has concavity between cervical line and distobuccal root <sup>10,27</sup>
MANDIBULAR TEETH		Lingual root: lingual surface depression	
	Mandibular central incisor	Yes	Yes (deeper)
	Mandibular lateral incisor	Yes	Yes (deeper)
	Mandibular canine	Yes	Yes (deeper)
	Mandibular first premolar	Yes (or no: about 50%)	Yes (deeper)
	Mandibular second premolar	No (unlikely)	Yes (deeper)
	Mandibular first and second molars	<b>Mesial root:</b> YES	Yes (deeper)
<b>Distal root:</b> variable, but deeper		Variable	

“General learning guidelines:

1. Maxillary incisors are less likely to have root depressions.
2. All mandibular incisors, all canines, and premolars (EXCEPT maxillary first premolars) are likely to have deeper distal surface root depressions.



On the **maxillary second molar**, the roots are much less spread apart than the roots of the first molar so that all three roots are usually confined within the crown width outline (recall Appendix 8j and Fig. 5-19). The banana-shaped lingual root is straighter than on first molars.

The *mesial* surface of the *mesiobuccal root* of the **maxillary first molar** has a longitudinal depression dividing it into buccal and lingual halves (and hidden within this root are two root canals, one buccal and one lingual). The *distal* surface of the *distobuccal root* is convex, without a longitudinal depression (and it usually has only one root canal), but several authors describe a slight *concavity on the distal surface of the root trunk* located between the distobuccal root and the cervical line.<sup>1,5</sup> This concavity may be difficult to keep clean. A summary of the presence and relative depth of root depressions for all teeth is presented in *Table 5-5*.

## D. TYPE TRAITS OF MAXILLARY MOLARS FROM THE OCCLUSAL VIEW

Refer to *Figure 5-22* for similarities and differences. To follow the description of traits from the occlusal view, the tooth should be held in such a position that the observer is looking exactly perpendicular to the plane of the occlusal surface. Because of the spread of the first molar roots, some of each of the three roots (particularly the lingual root) may be visible when the tooth is in this position (characteristic of many maxillary *first* molars in Fig. 5-22).

### 1. NUMBERS AND SIZE OF CUSPS ON MAXILLARY MOLARS FROM THE OCCLUSAL VIEW

As stated earlier in this chapter, most **first maxillary molars** usually have four relatively large cusps and many have the fifth cusp (cusp of Carabelli). Most **second molars** have three relatively large cusps and a noticeably smaller distolingual cusp (and no cusp of Carabelli), while some second molars have only three cusps when the distolingual cusp is absent. The difference in size of the distolingual cusp of maxillary second molars is evident in *Figure 5-23*.

Use *Figure 5-24* when comparing the relative size of major cusps for maxillary first and second molars. The relative cusp size on the four-cusp type of *both*

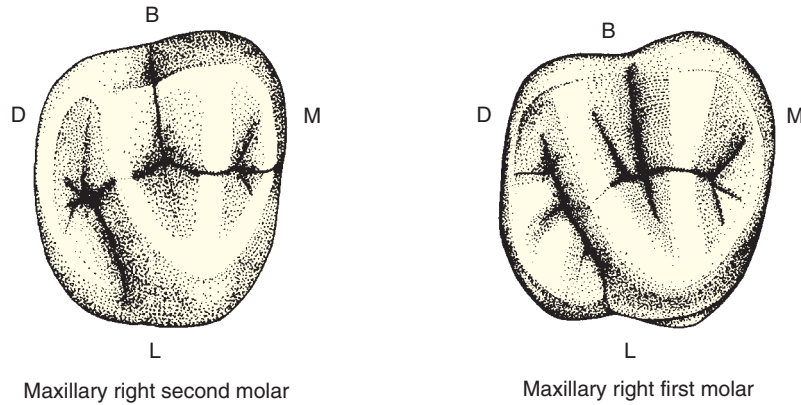
maxillary first and second molars is the same order as for the cusp *heights*: from largest to smallest, the largest mesiolingual, then mesiobuccal, distobuccal, and the smallest distolingual.<sup>AA</sup> On **second molars**, there is usually a greater difference in the size of the buccal cusps, with the mesiobuccal noticeably larger (Fig. 5-24), and the distolingual cusp either smallest or not present. The triangular shape formed by the three cusps found on a three-cusp type maxillary second molar (namely, the mesiolingual, mesiobuccal, and distobuccal cusps) is collectively known as the maxillary molar **primary cusp triangle** (Fig. 5-24).

### 2. OUTLINE OF FIRST MOLAR FROM OCCLUSAL VIEW

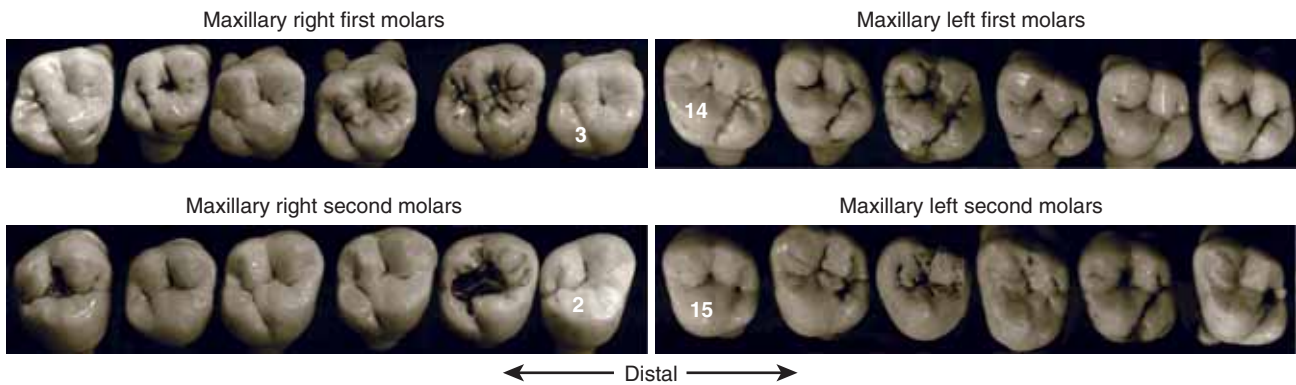
**Maxillary first molars** are slightly larger buccolingually than mesiodistally (arch trait for the maxillary molars) although the outline gives the general impression of squareness when compared to other teeth. Actually, it is more like a *parallelogram*, with two more acute (sharper) and two obtuse (blunter) angles (Appendix 8k). The acute angles are the mesiobuccal and distolingual. Also, on many maxillary first molars, the mesiodistal dimension of the lingual half of the crown is slightly wider mesiodistally than the buccal half due to a relatively large distolingual cusp. In *Figure 5-22*, try to locate one or two maxillary first molars that are not wider on the lingual than on the buccal sides. They are a minority.

The **maxillary second molar** crowns are even wider buccolingually than mesiodistally. There is considerable variation in the morphology of these molars, particularly in the size of the distolingual cusp. When the distolingual cusp is absent (about one third of the time), the tooth has only three cusps (Fig. 5-23C). Four maxillary second molars in *Figure 5-22* have no distolingual cusps. The **three-cusp type** is somewhat *triangular* or heart shaped, the blunt apex of the triangle being the lingual cusp.

The more common four-cusp type of maxillary second molars is less square in appearance than the first molar with a *parallelogram* shape that has a more acute, sharper angle at the mesiobuccal corner due in part to a prominent mesial (or mesiobuccal) cervical ridge (Fig. 5-24). This trait is helpful in differentiating rights from lefts and is vividly apparent on all maxillary second molars in *Figure 5-22*.



**MAXILLARY MOLARS (occlusal)**



**TRAITS TO DISTINGUISH MAXILLARY FIRST MOLARS FROM SECOND MOLARS: OCCLUSAL VIEW**

**MAXILLARY FIRST MOLAR**

- Distolingual cusp slightly smaller than mesiolingual cusp
- Crowns often wider on lingual half
- Crown outline a nearly square parallelogram
- Crown larger (in same mouth)
- More prominent oblique ridge
- Less prominent mesiobuccal cervical ridge

**MAXILLARY SECOND MOLAR**

- Distolingual cusp much smaller than mesiolingual cusp, or distolingual absent
- Crowns narrower on lingual half
- Crown outline more twisted parallelogram
- Crowns smaller (in same mouth)
- Smaller oblique ridge
- More prominent mesiobuccal cervical ridge

**TRAITS TO DISTINGUISH MAXILLARY RIGHT FROM LEFT MOLARS: OCCLUSAL VIEW**

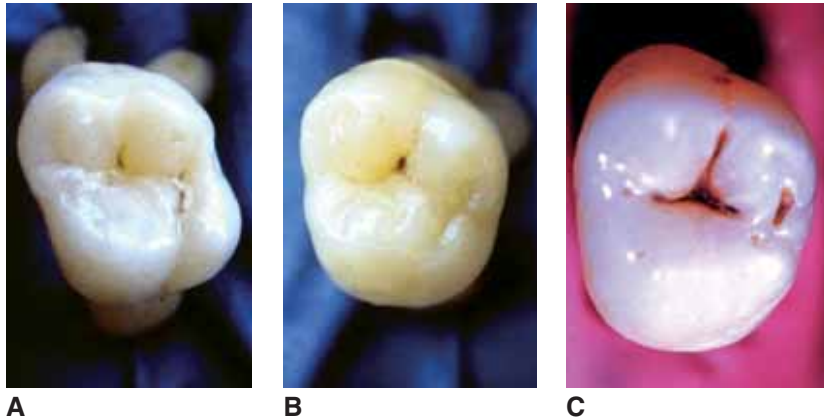
**MAXILLARY FIRST MOLAR**

- Cusp of Carabelli is on mesiolingual
- Mesiobuccal and distolingual angles of crown are more acute for both
- Distolingual cusp is smaller than mesiolingual cusp for both
- A mesiobuccal cervical ridge is visible for both
- The distal half of the crown is smaller faciolingually for both
- Oblique ridge goes from largest mesiolingual diagonally to distobuccal cusp for both

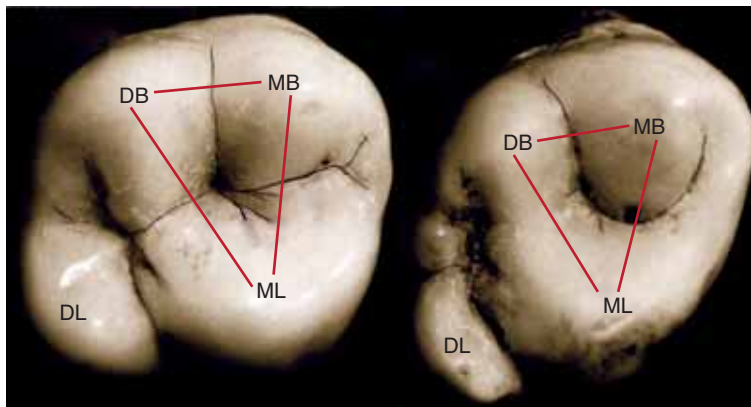
**MAXILLARY SECOND MOLAR**

- Distolingual cusp is smaller than mesiolingual cusp

**FIGURE 5-22.** Occlusal views of maxillary molars with type traits to distinguish maxillary first from second molars and traits to distinguish rights from lefts.



**FIGURE 5-23.** Three maxillary left molars showing variation in the size (or absence) of the **distolingual cusp**. **A.** Maxillary molar with moderate size distolingual cusp. **B.** Maxillary second molar with small distolingual cusp. **C.** Maxillary second molar with only one lingual cusp.



**FIGURE 5-24.** **Left:** maxillary right first molar (without cusp of Carabelli). **Right:** maxillary right second molar. Note how the first molar is much *wider on the lingual half* with a relatively large distolingual cusp, whereas the second molar tapers more toward the lingual surface with a *parallelogram* outline and more acute mesiobuccal and distolingual angles than the first molar. The cusps connected by the red triangle on each of these maxillary molars make up a **primary cusp triangle**.

See Figure 5-25 for a summary of the geometric outlines for all molars.

### LEARNING EXERCISE

Match the tooth with the correct geometric shape for its occlusal outline.

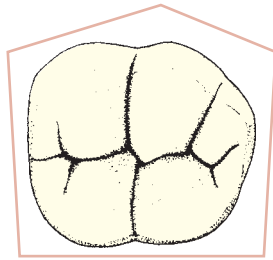
- Trapezoid (tapered rectangle)
  - Parallelogram (rhomboid)
  - Heart shaped or triangular
  - Pentagon
- Maxillary first molar
  - Maxillary second molar (four-cusp type)
  - Maxillary second molar (three-cusp type)
  - Mandibular first molar
  - Mandibular second molar

**ANSWERS:** 1—b, 2—b, 3—c, 4—d, 5—a

### 3. RIDGES OF MAXILLARY MOLARS FROM THE OCCLUSAL VIEW

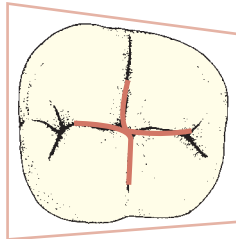
On the four-cusp type of maxillary molars, the larger mesiobuccal, distobuccal, and mesiolingual cusps each have a definite triangular ridge running from the cusp tip toward the middle of the tooth. Triangular ridges of the mesiobuccal and mesiolingual cusps join to form a transverse ridge. The largest mesiolingual cusp also has another ridge. Two texts refer to this second, more distal ridge on the mesiolingual cusp as the distal cusp ridge of the mesiolingual cusp.<sup>6,7</sup> (Other sources have called this a second triangular ridge.) The groove between the two ridges on the mesiolingual cusp is called the Stuart groove named after the late Dr. Charles E. Stuart.

This distal cusp ridge on the mesiolingual cusp crosses the occlusal table diagonally or obliquely to join the triangular ridge of the distobuccal cusp to form an oblique ridge (Fig. 5-26).<sup>6,7</sup> This *oblique ridge* is an *arch trait* on most maxillary molars. The oblique ridge is less prominent on maxillary second molars than on first molars.<sup>8</sup>



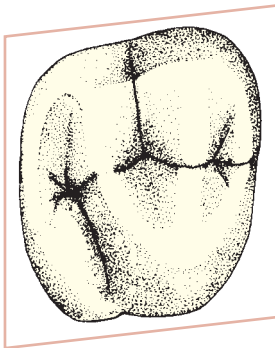
Right mandibular first molar

Pentagon outline:  
Occlusal views of mandibular first molar



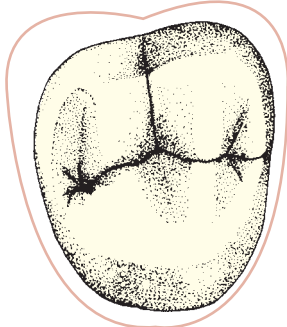
Right mandibular second molar

Rectangular (tapered) or trapezoid outline:  
"+" shaped groove pattern:  
Mandibular second molars



Maxillary right second molar

Rhomboid-shaped (twisted parallelogram) outline:  
Occlusal view of maxillary molars; acute angles are on mesiobuccal and distolingual corners



Maxillary right second molar (Three-cusp type)

Heart-shaped outline:  
Occlusal view of three-cusp type maxillary molars

**FIGURE 5-25.** Geometric outlines of the occlusal surfaces of molars, top to bottom. Mandibular first molars often have a *pentagon* outline. Mandibular second molars have a trapezoid (tapered rectangular) outline with a "+"-shaped groove pattern. Maxillary molars (second shown here) have a *rhomboid or parallelogram* outline with the mesiobuccal and distolingual "corners" forming acute angles. Maxillary molars, three-cusp type, have a *heart-shaped* (or somewhat *triangular*) outline.

#### 4. FOSSAE OF MAXILLARY MOLARS FROM THE OCCLUSAL VIEW

On four-cusp type maxillary molars, there are four fossae on the occlusal surface (Fig. 5-27). Three of these, the mesial triangular, distal triangular and central fossae, are similar in location to the mandibular molars. A small *mesial triangular fossa* is just distal to the mesial marginal ridge. The smallest, *distal triangular fossa*, is just mesial to the distal marginal ridge. The largest *central fossa* is near the center of the occlusal surface. In maxillary molars, this central fossa is bounded distally by the elevation of the oblique ridge, mesially by the mesial transverse ridge, and buccally by the buccal cusp ridges. A fourth fossa, or cigar-shaped depression, is the *distal fossa* that extends between the mesiolingual and distolingual cusps.

On three-cusp type maxillary (second) molars, when the distolingual cusp is missing, the distal (cigar-shaped) fossa is also missing and there are only three fossae remaining (one large central and two very small triangular fossae).

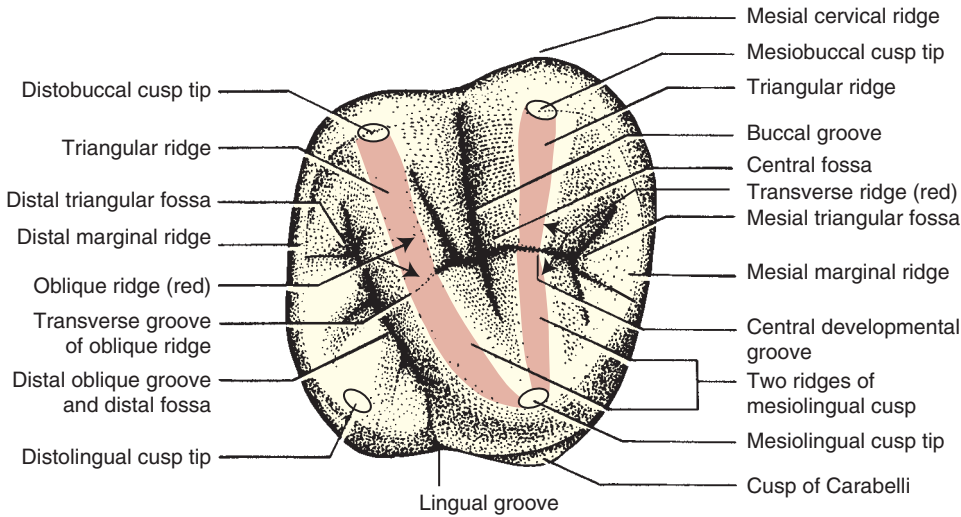
#### 5. GROOVES ON MAXILLARY MOLARS

Refer to Figure 5-26 while studying these grooves. On the four-cusp type of maxillary molar, the prominent oblique ridge plays an important role in defining the pattern of the developmental grooves. This type of maxillary molar has five major grooves: the central, buccal, distal oblique, lingual, and sometimes the transverse groove of the oblique ridge. Unlike the mandibular molar where the central groove extends from the mesial fossa to the distal fossa, the *central groove* on the maxillary molar extends from the mesial fossa over the mesial transverse ridge and ends in the central fossa. The *buccal groove* extends buccally from the central fossa and may continue onto the buccal surface of the crown (Fig. 5-26).

Distal to the central groove is the prominent oblique ridge, which usually has no distinct groove crossing it, but when it does, the groove appears to be a continuation of the central groove and is called the *transverse groove of the oblique ridge*. (One author calls these two grooves the mesial and distal groove, respectively,<sup>5</sup> while another combines these grooves and calls them the central groove.<sup>9</sup>)

Distal to the oblique ridge, a groove begins in the distal triangular fossa, parallels the direction of the oblique ridge through the distal fossa, and then extends onto the lingual surface of the crown. This groove is made up of two parts: the distal oblique groove and the lingual groove. The **distal oblique groove** begins in the distal triangular fossa and passes through the





**FIGURE 5-26.** Occlusal surface of a **maxillary right first molar** (including cusp of Carabelli) with all of the major landmarks named. The landmarks are the same for maxillary four-cusp type maxillary second molars, except seconds do not normally have a cusp of Carabelli.

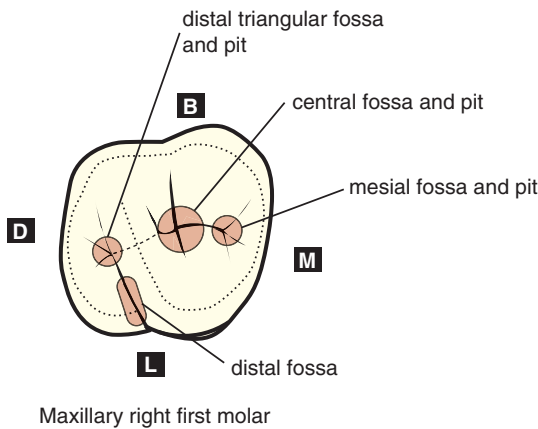
cigar-shaped distal fossa between the distolingual cusp and the mesiolingual cusp. Once it passes onto the lingual surface, it becomes the **lingual groove**. (One author calls these two grooves combined the distolingual groove.<sup>5</sup>) Recall that the lingual groove on a *mandibular* molar begins in the central fossa and is aligned at a right angle to the central groove. When there is a groove separating the fifth cusp (Carabelli) from the mesiolingual cusp, it is called the fifth cusp groove.

As on many premolars and mandibular molars, maxillary molars may have two short grooves that extend from the mesial and distal pits toward the corners (facial and lingual line angles) of the tooth. The short grooves off of the mesial pit are called the mesio-buccal and mesiolingual *fossa grooves* (or sometimes *triangular grooves*), and the short grooves off of the distal

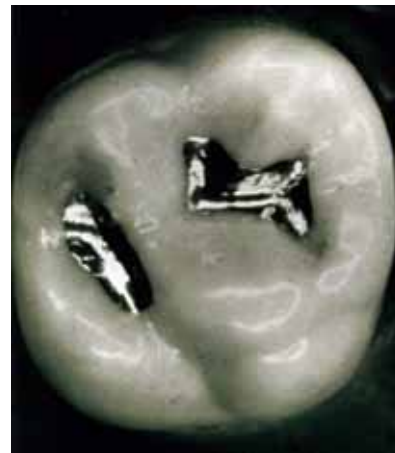pit are called the distobuccal and distolingual fossa (or triangular) grooves. The groove pattern on maxillary second molars may have more supplemental grooves and pits than on the first molar.<sup>8</sup>

On the **three-cusp type of second molar**, the distolingual cusp, the oblique ridge, and the cigar-shaped distal fossa are absent, so the grooves normally found within that fossa are also missing, namely, the distal oblique and lingual grooves.

All grooves may be fissured, so they can become the sites of dental decay. However, since the transverse groove of the oblique ridge is usually not fissured, decay on the occlusal surfaces of maxillary molars normally occurs mesially and distally to the oblique ridge. The result is two separate occlusal fillings (*Fig. 5-28*) similar



**FIGURE 5-27.** Maxillary first molar, occlusal view, showing the **relative size** and location of the **four fossae**.



**FIGURE 5-28.** Occlusal surface of a maxillary right first molar with **two amalgam restorations** prepared separately to avoid crossing over the pronounced oblique ridge that has no fissured groove crossing over it.



to two occlusal fillings found on mandibular first premolars where a prominent transverse ridge separates mesial and distal pit decay.

### 6. PROXIMAL CONTACTS OF MAXILLARY MOLARS FROM THE OCCLUSAL VIEW

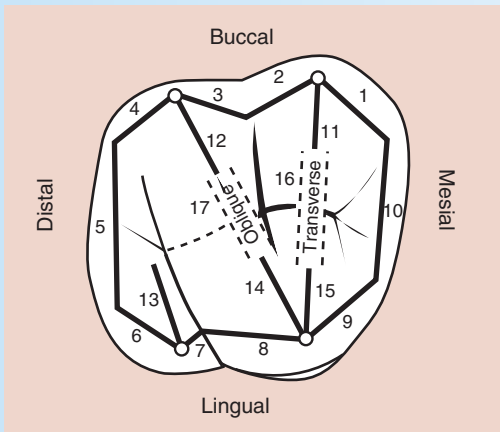
Mesial and distal contact areas of maxillary molars are all slightly to the buccal of the center of the tooth but are near the center buccolingually. The mesial contact is more buccal than the distal contact on maxillary molars, and the distal contact on maxillary first molars is nearly centered buccolingually.

### LEARNING EXERCISE

Visually examine the maxillary first molars in your own mouth and in the mouths of your associates, and notice the variations in the cusp of Carabelli. This little cusp has intrigued many people. It may be somewhat prominent and pointed, small and blunt, or absent, or you may even see a slight depression in that part of the mesiolingual cusp where the cusp of Carabelli would be found.

### LEARNING EXERCISE

Name each of the 17 ridges in *Figure 5-29*.



Name the ridges

Ridges	Name	Ridges	Name
1.	_____	10.	_____
2.	_____	11.	_____
3.	_____	12.	_____
4.	_____	13.	_____
5.	_____	14.	_____
6.	_____	15.	_____
7.	_____	16.	_____
8.	_____	17.	_____
9.	_____		

**FIGURE 5-29.**

Maxillary molar (circles denote cusp tips and lines denote ridges). Write the names of each of the 17 ridges next to the number corresponding to its location. Answers follow.

**ANSWERS:** Maxillary molar ridges: 1—mesial cusp ridge of mesiobuccal cusp; 2—distal cusp ridge of mesiobuccal cusp; 3—mesial cusp ridge of distobuccal cusp; 4—distal cusp ridge of distobuccal cusp; 5—distal marginal ridge; 6—distal cusp ridge of distolingual cusp; 7—mesial cusp ridge of distolingual cusp; 8—distal cusp ridge of mesiolingual cusp; 9—mesial cusp ridge of mesiolingual cusp; 10—mesial marginal ridge; 11—triangular ridge of mesiobuccal cusp; 12—triangular ridge of distobuccal cusp; 13—triangular ridge of distolingual cusp; 14—distal cusp ridge (or triangular ridge) of mesiolingual cusp; 15—(mesial) triangular ridge of mesiolingual cusp; 16—transverse ridge; 17—oblique ridge.

## Review Questions

### Maxillary molars

Circle the correct answer(s) that apply. More than one answer may be correct.

1. Which three grooves radiate out from the central fossa in a maxillary first molar?
  - a. Central
  - b. Distolingual
  - c. Transverse groove of oblique ridge (when present)
  - d. Buccal
  - e. Lingual
2. Which cusp on a maxillary first molar has two ridges: one that forms part of a transverse ridge and the other that forms part of an oblique ridge?
  - a. Mesiobuccal
  - b. Mesiolingual
  - c. Distobuccal
  - d. Distolingual
  - e. Cusp of Carabelli
3. Which cusp is the largest and longest on a maxillary second molar?
  - a. Mesiobuccal
  - b. Mesiolingual
  - c. Distobuccal
  - d. Distolingual
  - e. Cusp of Carabelli
4. Which cusp is most likely to be absent on a maxillary second molar?
  - a. Mesiobuccal
  - b. Mesiolingual
  - c. Distobuccal
  - d. Distolingual
  - e. Distal
5. When the cusp is absent in question 4 above, which groove(s) would not be present?
  - a. Central
  - b. Buccal
  - c. Distal oblique
  - d. Lingual
6. Of the four fossae on a maxillary first molar, which is the largest?
  - a. Mesial triangular
  - b. Distal triangular
  - c. Central
  - d. Distal
7. From which view are only two roots visible on a maxillary first molar?
  - a. Mesial
  - b. Distal
  - c. Buccal
  - d. Lingual
8. Which grooves are likely to radiate out of the mesial triangular fossa on the maxillary first molar?
  - a. Mesiobuccal fossa groove
  - b. Mesiolingual fossa groove
  - c. Mesial marginal ridge groove (when present)
  - d. Central
  - e. Buccal
9. Which two cusps have the ridges that make up or join to form the oblique ridge on a maxillary molar?
  - a. Mesiobuccal
  - b. Distobuccal
  - c. Mesiolingual
  - d. Distolingual
  - e. Cusp of Carabelli
10. Which two cusps have a triangular ridge that make up or join to form a transverse (not oblique) ridge on most maxillary molars?
  - a. Mesiobuccal
  - b. Distobuccal
  - c. Mesiolingual
  - d. Distolingual
  - e. Cusp of Carabelli
11. List in sequential order the largest to smallest cusp area on the maxillary first molar (occlusal view).

**ANSWERS:** 1—a, c, d; 2—b; 3—b; 4—d; 5—c, d; 6—c; 7—a; 8—a, b, c, d; 9—b, c; 10—a, c; 11—mesiolingual, mesiobuccal, distobuccal, distolingual, cusp of Carabelli (if even present)

## SECTION IV

## MAXILLARY AND MANDIBULAR THIRD MOLAR TYPE TRAITS

## OBJECTIVES

After studying this section, the reader should be able to perform the following:

- List the type traits that are unique to all third molars that can be used to distinguish them from first or second molars.
- From a selection of all types of molars, select the mandibular and maxillary third molars and assign each a Universal number.

- In mouths (or casts) of mandibular and maxillary arches with only one or two molars per quadrant, identify which molars are present and which are absent based on crown anatomy and position in the arch. (Remember that molars can change positions in the arch if they drift forward after the extraction of a first or second molar or are moved during orthodontic treatment, so arch position should not be the only way to confirm which molars are present.)

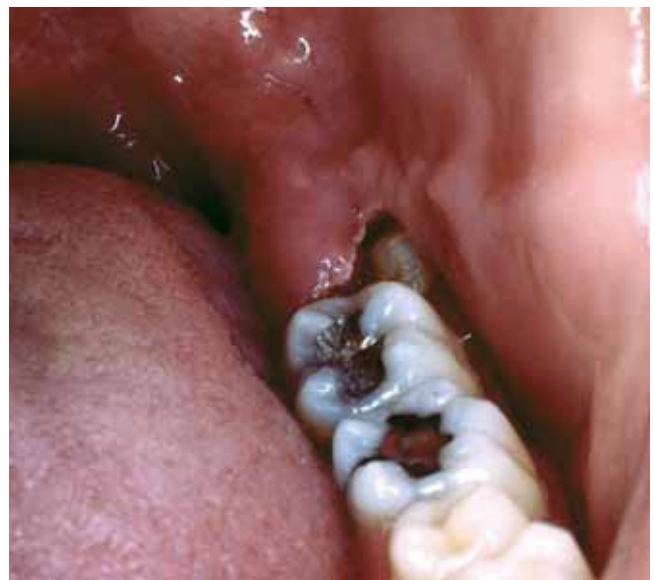### A. TYPE TRAITS OF ALL THIRD MOLARS (DIFFERENT FROM FIRST AND SECOND MOLARS)

Most often, there are four third molars in a mouth, one at the distal position in each quadrant. However, nearly one fifth of the population may have one or more of their third molars congenitally missing (they never developed).<sup>BB</sup> The mesial surfaces of third molars contact the distal surfaces of second molars, but the distal surfaces of third molars are not in proximal contact with any other tooth. In ideal alignment of teeth between arches, maxillary third molars bite against (occlude with) only the mandibular third molars; all other teeth EXCEPT mandibular central incisors have the potential for occluding with two teeth.

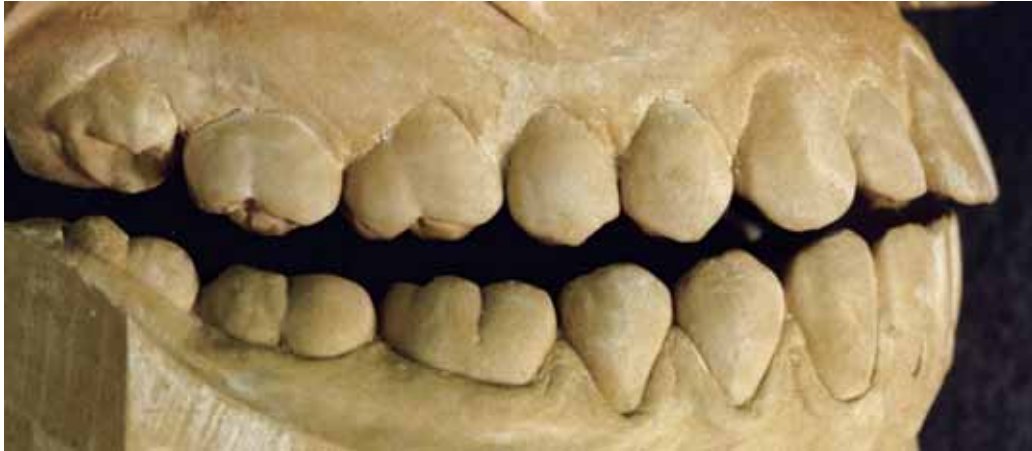Third molars, also known to many as wisdom teeth, have gotten a bad reputation for not serving any function, having soft enamel, readily decaying, and causing crowding of the anterior teeth and other dental problems. The truth is that the posterior location of third molars in the mouth makes it more difficult to keep them clean, and their wrinkled, fissured occlusal surfaces make them more prone to developing decay than other teeth. Further, mandibular third molars often erupt so far distally that there is not room to completely erupt, which compromises the health of the surrounding tissue (gingiva), so dentists often suggest that these teeth be removed to prevent future problems. Inflammation of the tissue around these teeth (called **pericoronitis**) can be a cause of acute pain and spread of infection, resulting in the need for gingival surgery or extraction (Fig. 5-30). This infection is even more likely to occur if the flap of tissue overlying the erupting third molar, called an **operculum**, becomes irritated. However, it is not true that third molars have soft enamel, are useless, or should be routinely extracted. If the dental arches are of sufficient length to permit full eruption of third molars and a person's oral hygiene is

good, third molars can function for a lifetime without problems. Also, healthy third molars can serve as the posterior attachment (abutment) when replacing lost or missing first or second molars.

Some oral surgeons recommend that when third molars have to be extracted, they be removed at an early age (under 25 years old) to facilitate an easier, less traumatic removal, and a quicker, more comfortable recovery period than if they were extracted later in life.<sup>10</sup> Since many third molars are extracted before the roots are completely formed, you can easily look into the open ends of the root apices of these teeth and see the pulp tissue in the root canals.



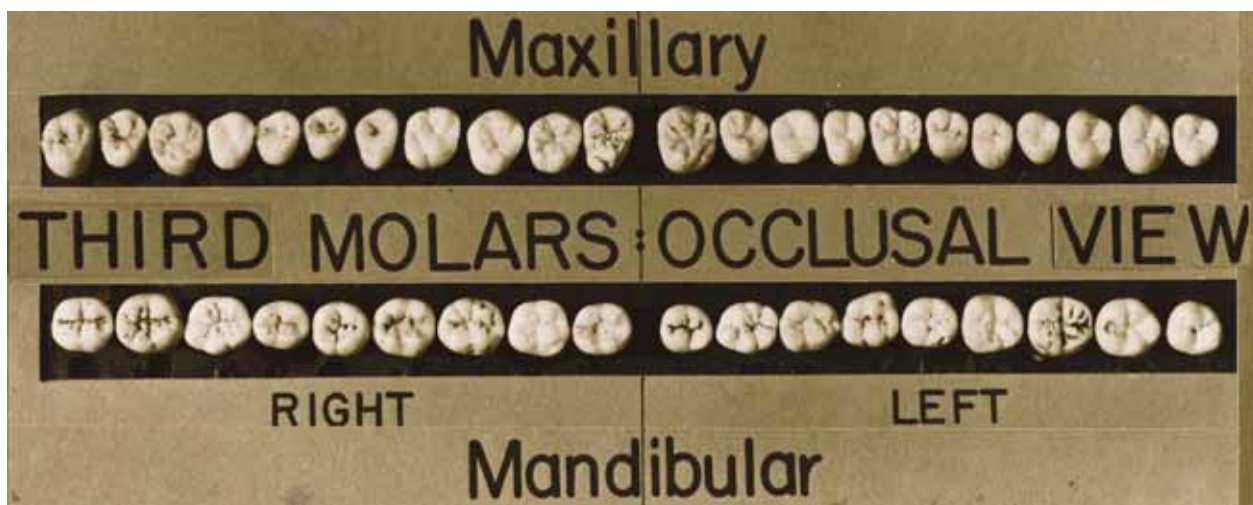
**FIGURE 5-30.** An **operculum** is a flap of tissue that may cover the crown of an erupting, most posterior mandibular molar (especially when there is no room for it to erupt completely). This flap is subject to irritation and infection surrounding the crown known as **pericoronitis**. (Courtesy of Carl Allen, D.D.S., M.S.D.)



**FIGURE 5-31.** Dental stone casts of maxillary and mandibular teeth (facial view) showing the **decrease in size** of molars from first to third molar that is typical in most people. (Model courtesy of Ms. Colleen Seto.)

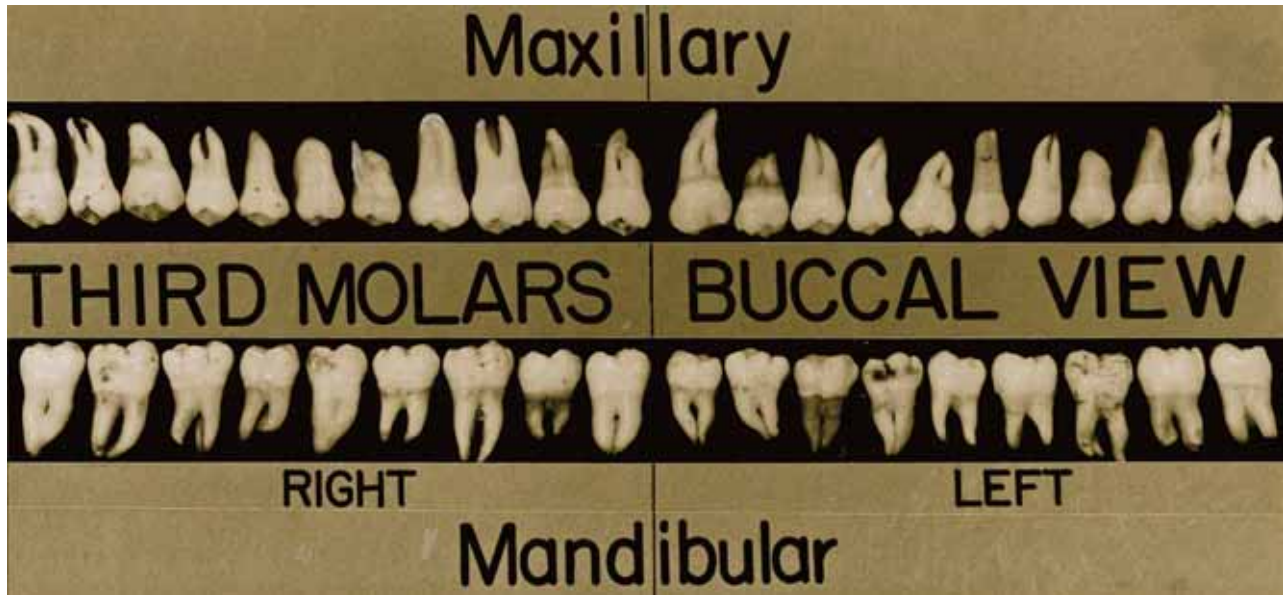
Although third molars may have a number of traits in common with first or second molars, they all have certain type traits in common that set them apart from the first and second molars in their arches. These third molar traits include the following:

1. Normally, third molars are smaller than first or second molars in the same mouth (*Fig. 5-31*). A common exception is the five-cusp third molar, which may have a crown somewhat larger and more bulbous than the second molar.
2. Third molar crowns are bulbous (with fatter contours).
3. Occlusal tables of third molars are relatively smaller compared to first and seconds (i.e., the buccal cusp tips are closer to the lingual cusp tips than on first and second molars).
4. Occlusal surfaces of third molars are quite wrinkled due to numerous supplemental grooves and ridges (*Fig. 5-32*).
5. Third molar roots are short (with small root-to-crown ratio) compared to first and second molars in the same mouth (*Fig. 5-33*).
6. Roots are frequently fused together, subsequently with very long root trunks (*Fig. 5-33*).
7. Roots are pointed and frequently curve distally in the apical third.



**FIGURE 5-32.** Occlusal views of maxillary and mandibular third molars. The buccal surfaces of the maxillary teeth face up, and those of the mandibular teeth face down. All mesial surfaces face the centerline. Observe the wrinkled occlusal designs in both, and try to recognize the similarities to first and second molars in each arch. For example, most of the maxillary third molars are largest faciolingually in contrast to the mandibular third molars, whose greater dimension is mesiodistally.





**FIGURE 5-33.** Buccal views of maxillary and mandibular third molars. Notice the fused roots and long root trunks. The mesial surfaces all face toward the centerline. Notice the tremendous variation among the maxillary third molars. Observe the differences between maxillary and mandibular anatomy. Also, note the similarity of each to the first and second molars found within their respective arches. (Method of comparison and teeth furnished by Kelli Whapham, first-year Ohio State University dental hygiene student, 1978.)

### B. SIZE AND SHAPE OF THIRD MOLARS

Both maxillary and mandibular third molars vary considerably in size, but they are, on average, the shortest teeth in the mouth. Mandibular thirds are the shortest of all mandibular teeth<sup>CC</sup>, and maxillary thirds are the shortest of all permanent teeth. The roots of maxillary molars are, on average, shorter than the roots of the firsts or second molars,<sup>DD</sup> and their root trunks are proportionally longer than the root trunks of the firsts and seconds.<sup>EE</sup>

### C. SIMILARITIES AND DIFFERENCES OF THIRD MOLAR CROWNS COMPARED WITH FIRST AND SECOND MOLARS IN THE SAME ARCH

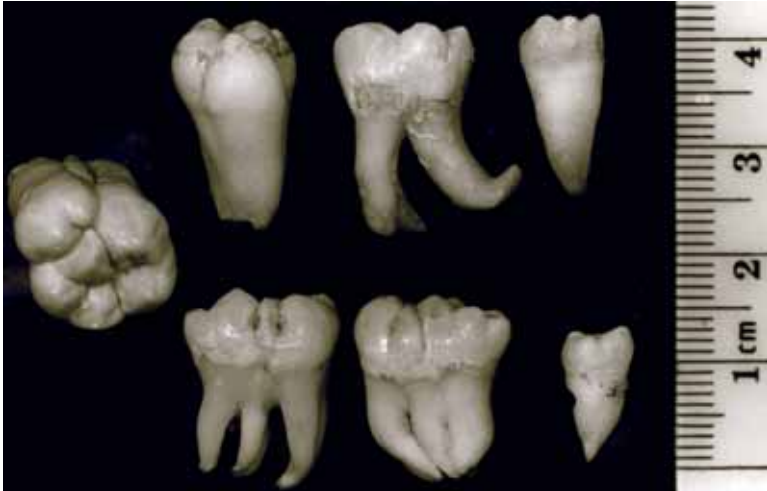Maxillary third molars have the greatest morphologic variance of all teeth. The great amount of variation in maxillary third molars also makes a general description difficult. The crown may have only one cusp or as many as eight,<sup>11</sup> but it also may resemble a small maxillary first molar (complete with cusp of Carabelli) or second molar (without the cusp of Carabelli, and perhaps without the distolingual cusp). Sometimes the form of the maxillary third molar crown is so irregular that it is difficult to identify the mesiobuccal, distobuccal, and lingual cusps.

However, in many ways, maxillary third molars may resemble maxillary second or first molars. For example,

the usual relative cusp size from largest to smallest is the same as in the first and second molars: first, the mesiolingual cusp is largest and longest; followed by the mesiobuccal cusp, which is wider and usually longer than the distobuccal cusp; followed by the smallest distolingual cusp (if present). The oblique ridge is poorly developed and often absent (maxillary molars in Fig. 5-32). From the occlusal view, the maxillary third molar crown outline usually tapers from buccal to lingual, being narrower on the lingual side, and tapers from mesial to distal, being considerably larger faciolingually in its mesial half due to a prominent mesiobuccal cervical ridge and large mesiolingual cusp (Fig. 5-32). Also, the buccal surface can be distinguished from the lingual because the buccal surface is relatively more flat.

Although the crown of a mandibular third molar may exhibit great variance in size and shape and look like no other tooth (as seen in Fig. 5-34), its crown quite often resembles that of the mandibular second molar (with four cusps) or the crown of the mandibular first molar (with five cusps). For example, the occlusal outline of a mandibular third molar crown is rectangular or oval and wider mesiodistally than buccolingually.<sup>FF</sup> The crown of the four-cusp type tapers from mesial to distal and from buccal to lingual (but only slightly) (occlusal aspect).<sup>EE</sup> As on mandibular first and second molars, the lingual cusps of mandibular third molars are often larger and longer than the buccal cusps, with





**FIGURE 5-34. Unusual third molars:** Six unusual mandibular third molars and occlusal view (left side) of one with a small extra tooth (called a paramolar) fused to its buccal surface. Two in the lower row are also double or fused teeth.

the mesiolingual cusp being the largest of all. The mesiobuccal cusp is often the widest and usually highest of the two or three buccal cusps.

#### **D. SIMILARITIES AND DIFFERENCES OF THIRD MOLAR ROOTS COMPARED WITH FIRST AND SECOND MOLARS IN THE SAME ARCH**

As on maxillary first and second molars, maxillary third molars usually have three roots: mesiobuccal, distobuccal, and lingual as on the first and second molars, and mandibular third molars have two roots, mesial and distal. Both maxillary and mandibular third molar roots are noticeably shorter than on firsts or seconds.<sup>DD,GG</sup> They are very crooked, often curving distally, and more commonly fused most of their length resulting in a long root trunk with the furcation located only a short distance from the apices of the roots (Fig. 5-33). Mandibular thirds may have one or more extra roots.

#### **LEARNING EXERCISE**

Suppose a patient just had all of his or her permanent teeth extracted and you were asked to find tooth No. 15 from among a pile of 32 extracted teeth on the oral surgeon's tray because you wanted to evaluate a lesion on the root of that molar that had been seen on the radiograph. How might you go about it? Try the following steps:

- From a selection of all permanent teeth (extracted teeth or tooth models), select only the molars (based on **class traits**).

#### **Learning Exercise, cont.**

- Determine whether each molar is maxillary or mandibular (based on **arch traits**). You should never rely on only one characteristic difference between teeth to name them; rather, make a list of many traits that suggest the tooth is a maxillary molar, as opposed to only one trait that makes you think it belongs in the maxillary arch. This way you can play detective and become an expert at recognition at the same time.
- If you determine that the tooth is maxillary, position the root up; if it is mandibular, position the root down.
- Use traits for each surface to identify the buccal surface. This will permit you to view the tooth as though you were looking into a patient's mouth.
- Next, using **type traits**, determine the type of molar you are holding (first or second).
- Finally, determine which surface is the mesial. While viewing the molar from the facial and picturing it within the appropriate arch (upper or lower), the mesial surface can be positioned toward the midline in only one quadrant, the right or left.
- Once you have determined the quadrant, assign the appropriate Universal number for the molar in that quadrant. For example, the second molar in the upper left quadrant is tooth No. 15.

## SECTION V

## INTERESTING VARIATIONS AND ETHNIC DIFFERENCES IN MOLARS

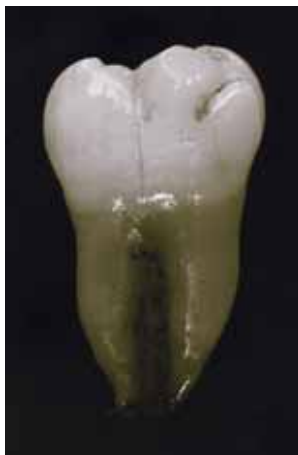This section is included in this chapter to provide the reader with an appreciation of the variation that can occur compared to the average (ideal) molars that have been discussed thus far in this chapter. Also, it should provide the reader with insight into the variations of teeth from ethnic populations that differ from persons in central Ohio in the 1970s whose teeth data served as the basis for many of the statements made in this book.

#### Variation in the Number of Cusps:

As mentioned earlier, nearly a fifth of mandibular first molars have only four cusps.<sup>6</sup> This four-cusp type of mandibular first molar does not taper as much from buccal to lingual as a four-cusp mandibular second molar (occlusal aspect), but it often tapers from distal to mesial, which is unusual.

Mandibular first, second, and most frequently, third molars may have an extra cusp on the buccal surface of the mesiobuccal cusp, about in the middle third of the crown (Fig. 5-35). Studies show this is common in the Pima Indians of Arizona<sup>12,13</sup> and in Indian (Asian) populations.<sup>14,15</sup>

Some mandibular first molars have a sixth cusp, which is named **tuberculum sextum** (too BUR kyoo lum SEKS tum) when located on the distal marginal ridge between the distal cusp and distolingual cusp; it is named **tuberculum intermedium** (too BUR kyoo lum in



**FIGURE 5-35.** Unusual extra cusp: four-cusp mandibular right third molar, buccal surface. Note the bulbous crown and the extra cusplet on the buccal surface of the mesiobuccal cusp. This extra cusp or cusplet is not called a Carabelli cusp.

ter MEE di um) when located between the two lingual cusps (Fig. 5-36).<sup>16</sup> Six cusps (three on the lingual) are common among the Chinese people.

Five-cusp mandibular *second* molars (shaped just like five-cusp first molars with a distal cusp) are not uncommon among the Chinese and Black populations.<sup>16</sup> In Figure 5-37, one is shown from a Caucasian dentition.

#### Cusp of Carabelli:

It is possible, but rare, to see a fifth cusp of Carabelli on maxillary *second* molars (Fig. 5-38). A number of studies have been done concerning the occurrence and size of the cusp of Carabelli.<sup>17-21</sup> One investigator reported that it is extremely rare in the East Greenland Eskimo. In European people, it is usually present. The Carabelli trait was absent on 35.4% of the teeth in 489 Hindu children.<sup>22</sup> On first molars, the presence of a groove in the location of the cusp of Carabelli was more common (35%) than tubercles (26%).<sup>21</sup>

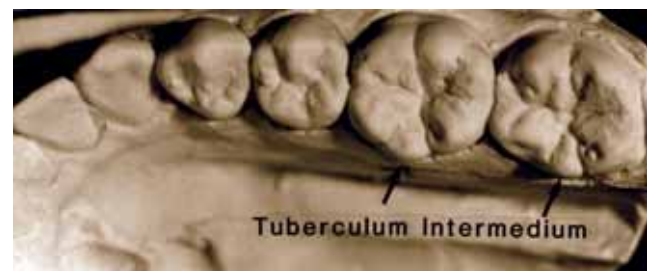
Research data by Dr. Woelfel on the occurrence and type of Carabelli cusp formation on 1558 maxillary first molars of dental hygienists from 1971 to 1983 are presented in Table 5-6.

#### Cusp Position:

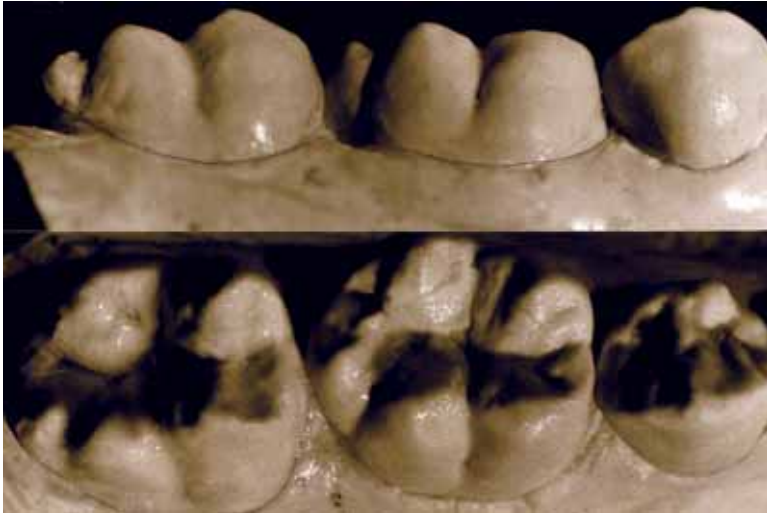
In Mongoloid peoples, the fifth distal cusp on mandibular first molars is often positioned lingually. This cusp may also be split into two parts by a fissure.<sup>2</sup>

#### Grooves:

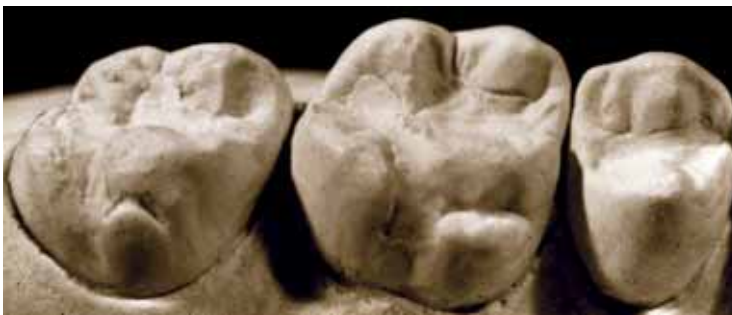Studies on both ancient and modern man on the pattern of the grooves on the occlusal surface of the mandibular molars show considerable variation. Three principal types of occlusal groove patterns have been described: type Y, in which the zigzag central groove forms a Y figure with the lingual groove (seen in Fig. 5-13A); type +,



**FIGURE 5-36.** Mandibular first and second molars with a **third lingual cusps (tuberculum intermedium)**. When an extra cusp is found on the distal marginal ridge, it is called tuberculum sextum.



**FIGURE 5-37. Unusual number of cusps:** mandibular *second* molar with *three* buccal cusps (buccal view above; occlusal view below with buccal surface down).



**FIGURE 5-38. Unusual cusp of Carabelli:** maxillary first and second molars, each with a Carabelli cusp. It is unusual to have this Carabelli cusp on a second molar. (Courtesy of Dr. Jeff Warner.)

in which the central groove forms a + figure with the buccal and lingual grooves (common in four-cusp type of first molars); and type X, in which the occlusal grooves are somewhat in the form of an X.<sup>23</sup>

A deep pit at the cervical end of the mesiobuccal groove of mandibular first molars is common in Mongoloid persons.

**Relative Crown Size:**

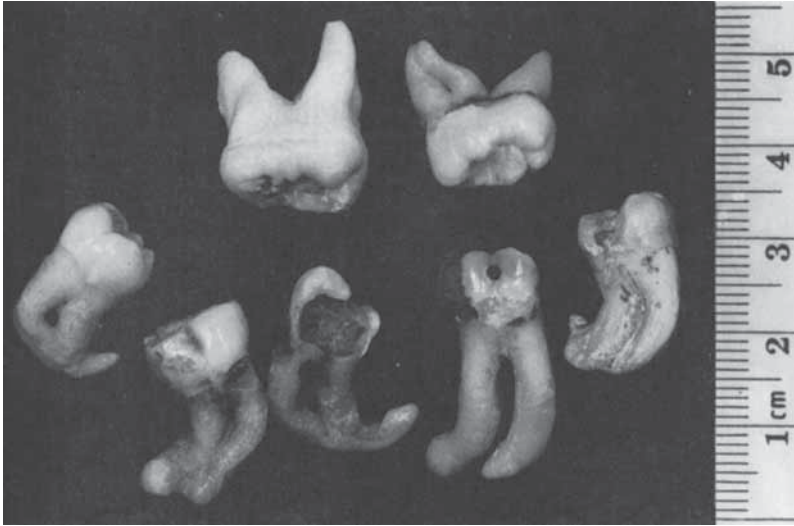
In one study, second mandibular molars were larger than first molars in 10% of Ohio Caucasians but in 19%

of Pima Indians.<sup>24</sup> It is reported that in the Bantu people in Africa, and sometimes in Arctic coastal populations, the mandibular molars often increase in size from first to third so that the third molar is the largest and the first molar is the smallest. This is reported to also occur in Pima Indians.<sup>25</sup> This is not the most frequent order of size found in Western European populations.

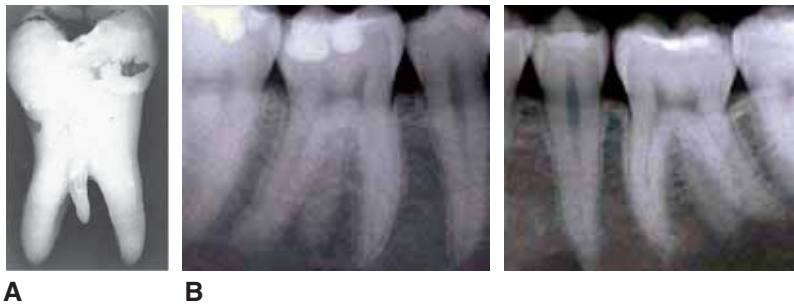Studies on the variability in the relative size of molars revealed that maxillary second molars were larger than first maxillary molars in 33% of a sample of an Ohio Caucasian population, and in 36% of a Pima Indian

Table 5-6		FREQUENCY OF OCCURRENCE AND TYPE OF CARABELLI CUSP FORMATION ON 1558 MAXILLARY FIRST MOLARS*	
Large Carabelli cusp	19%	}	70.5% some type of Carabelli formation
Small Carabelli cusp	27.5%		
Slight depression (groove)	24%		
Nothing	29.5%		
Same type on right and left	76%		
Different on each side (835 comparisons on casts)	24%		

\*Observations from dental stone casts of Ohio dental hygienists made by Dr. Woelfel and his students, 1971–1983.



**FIGURE 5-39. Unusual molar shapes:** buccal aspect of two unusual maxillary third molars (top row) and five unusual mandibular molars (bottom row; left to right: third, second, two firsts, and third molar). The severe bending of the roots is called **flexion**.



**FIGURE 5-40. Unusual roots:** **A.** Mandibular left second molar with an extra small root; buccal view. (Courtesy of Drs. John A. Pike and Lewis J. Claman.) **B.** Radiographs of a right and left mandibular first molar from the mouth of a Caucasian male with unusual, large third roots located between the normal-looking mesial and distal roots. (Brought to the author's attention by Joshua Clark, dental student.)

population.<sup>23</sup> In contrast, Dr. Woelfel found only two casts of young dental hygienists' mouths, from more than 600 sets of complete dentition casts, in which maxillary second molars were larger than the first molars.

#### Variations in Roots:

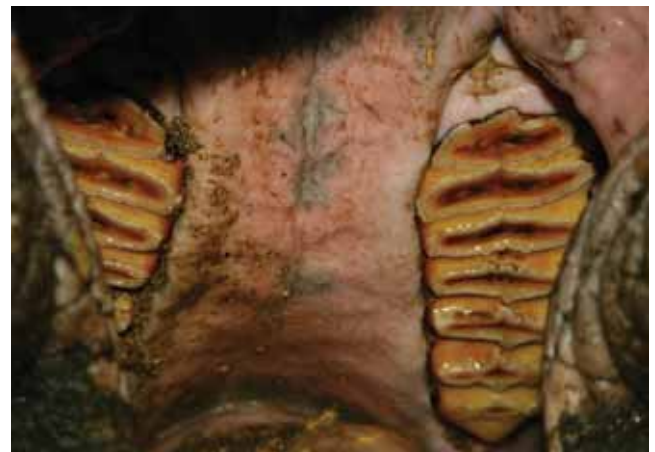Observe the wide variation from the normal in the roots with extreme distal root curvature seen in *Figure 5-39*, lower row. This condition is called **flexion** (FLEK shen) or dilaceration.

Occasionally, the mesial root on mandibular first molars is divided into a mesiobuccal and a mesiolingual root, forming three roots. This condition is found in 10% to 20% of the mandibular first permanent molars in Arctic coastal populations.<sup>26</sup>

Ten percent of mandibular first molars of Mongoloid people have an additional distolingual root, and sometimes the mesial root is bifurcated, resulting in a four-rooted first molar.<sup>4</sup> It is reported that in both primary and permanent dentitions, three-rooted mandibular molars occur frequently in Mongoloid (Chinese) people but rarely in European groups.<sup>2,27,A</sup> A small, third root can be seen in *Figure 5-40A*. This peduncular-shaped extra root is approximately 6 mm long. Also,

in *Figure 5-40B*, a right and left bitewing radiograph from a Caucasian male revealed an unusual long third root bilaterally between normal mesial and distal roots.

In a Japanese study of root formation on 3370 maxillary second molars, 50% had three roots, 49% were



**FIGURE 5-41.** Elephant molars are 12 in. long.



split equally between single and double roots, and 1% had four roots. In the three-rooted second molars, 75% had complete separation of roots (no fusion). The tendency to fuse was higher in the roots of teeth extracted from females. Lingual roots were straight in half of the three-rooted teeth.<sup>28</sup>

A point of enamel dipping into the root furcation is reported to occur in 90% of Mongoloid people studied.<sup>2</sup>

In Mongoloid people, mandibular molars have a long root trunk, and maxillary first molars sometimes have

no furcation at all.<sup>2</sup> See the last maxillary first molar on the upper row, right side, in Figure 5-15.

#### Animal Molars:

Elephants molars weigh about 11 pounds each and are about a foot long (Fig. 5-41). As one set of molars literally fall apart in pieces, they are replaced by new ones six times in their life. After the sixth set is lost, the elephant will probably die of starvation around the age of 50 years old.

## Critical Thinking

1. List the cusps in order from longest to shortest for the most common form of an extracted **MANDIBULAR FIRST MOLAR** with the long axis of the root exactly vertical. Name the cusp tips that would normally be seen when viewing this tooth from each of the following views: buccal view, mesial view, distal view, lingual view, and occlusal view. Do the same thing for the **MANDIBULAR SECOND MOLAR**. Would the longest cusp on the handheld tooth appear to be the longest when the teeth are aligned ideally within a mouth. If not, why not?
2. List the cusps in order from longest to shortest for the most common form of an extracted **Maxillary First Molar with a cusp of Carabelli** (with the long axis of the roots exactly vertical). Name the cusp tips that would normally be seen when viewing this tooth from each of the following views: buccal view, mesial view, distal view, lingual view, and occlusal view. Do the same thing for the **THREE-CUSP FORM OF MAXILLARY SECOND MOLAR**. Would the longest cusp on this handheld tooth appear to be the longest when the teeth are aligned ideally within a mouth. If not, why not?

## REFERENCES

1. Everett FG, Jump EG, Holder TD, et al. The intermediate bifurcation ridge: a study of the morphology of the bifurcation of the lower first molar. *J Dent Res* 1958;37:162.
2. Tratman EK. A comparison of the teeth of people. Indo-European racial stock with Mongoloid racial stock. *Dent Record* 1950;70:31–53, 63–88.
3. Masters DH, Hoskins SW. Projection of cervical enamel into molar furcations. *J Periodontol* 1964;35:49–53.
4. Tratman EK. Three-rooted lower molars in man and their racial distribution. *Br Dent J* 1938;64:264–274.
5. Brand RW, Isselhard DE. *Anatomy of orofacial structures*. 6th ed. St. Louis, MO: C.V. Mosby, 1998:438.
6. Ash MM, Nelson SJ. *Wheeler's dental anatomy, physiology and occlusion*. Philadelphia, PA: Saunders, 2003.
7. Lundeen HC. *Introduction to occlusal anatomy*. Gainesville, FL: L&J Press, 1973.
8. Brand RW, Isselhard DE. *Anatomy of the orofacial structures*. Vol. 159. St. Louis, MO: C.V. Mosby, 1982:163.
9. Bath-Balogh M, Fehrenbach MJ. *Illustrated dental embryology, histology, and anatomy*. Philadelphia, PA: W.B. Saunders.
10. Chiles DG, Cosentino BJ. Third molar question: report of 522 cases. *J Am Dent Assoc* 1987;115:575–576.
11. Jordan R, Abrams L. *Kraus's dental anatomy and occlusion*. St. Louis, PA: Mosby Year Book, 1992.
12. Dahlberg AA. The evolutionary significance of the proto-stylid. *Am J Phys Anthropol* 1950;8:NS:15.
13. Dahlberg AA. The dentition of the American Indian. In: Laughlin WS, ed. *The physical anthropology of the American Indian*. New York, NY: The Viking Fund, 1949.
14. Dahlberg AA. Geographic distribution and origin of dentitions. *Int Dent J* 1965;15:348–355.
15. Hellman M. Racial characters of human dentition. *Proc Am Philos Soc* 1928;67(2), 157–174.
16. Jordan R, Abrams L. *Kraus's dental anatomy and occlusion*. St. Louis, MO: Mosby Year Book, 1992.
17. Carbonelli VM. The tubercle of Carabelli in the Kish dentition, Mesopotamia, 3000 B.C. *J Dent Res* 1960;39:124.
18. Garn SM, Lewis AB, Kerewsky RS, et al. Genetic independence of Carabelli's trait from tooth size or crown morphology. *Arch Oral Biol* 1966;11:745–747.
19. Kraus BS. Carabelli's anomaly of the maxillary molar teeth. Observations on Mexican and Papago Indians and an interpretation of the inheritance. *Am J Hum Genet* 1951;3:348.
20. Kraus BS. Occurrence of the Carabelli trait in the Southwest ethnic groups. *Am J Phys Anthropol* 1959;17:117.
21. Meredith HV, Hixon EH. Frequency, size, and bilateralism of Carabelli's tubercle. *J Dent Res* 1954;33:435.
22. Joshi MR, Godiawala RN, Dutia A. Carabelli trait in Hindu children from Gujurat. *J Dent Res* 1972;51:706–711.
23. Jorgensen KD. The Dryopithecus pattern in recent Danes and Dutchmen. *J Dent Res* 1955;34:195.
24. Garn SM, Lewis AB, Kerewsky RS. Molar size sequence and fossil taxonomy. *Science* 1963;142:1060.



25. Garn SM, Lewis AB, Kerewsky RS. Molar size sequence and fossil taxonomy. *Science* 1963;142:1060.
26. Scott JH, Symons NBB. *Introduction to dental anatomy*. London: E & S Livingstone, Ltd, 1958.
27. Turner CG. Three-rooted mandibular first permanent molars and question of American Indian origin. *Am J Phys Anthropol* 1971;34:239–242.
28. Matsumoto Y. Morphological studies on the roots of the Japanese maxillary second molars. *Shikwa Gakuho* 1986;86:249–276.

## GENERAL REFERENCES

- Oregon State System of Higher Education. *Dental anatomy: a self-instructional program*. East Norwalk: Appleton-Century-Crofts, 1982:403–414.
- Proskaves C, Witt F. *Pictorial history of dentistry* (Cave P, trans.). Koln: Verlag M. Dumont Schauberg, 1962.
- Renner RP. *An introduction to dental anatomy and esthetics*. Chicago, IL: Quintessence Publishing, 1985.
- Ring ME. *Dentistry: an illustrated history*. St. Louis, MO: C.V. Mosby, 1985.



## Dr. Woelfel's Original Research Data

Statistics obtained from Dr. Woelfel's original research on teeth have been used to draw conclusions throughout this chapter and were referenced with superscript letters that refer to the data stated here. Refer to *Tables 5-7* and *5-8* for the average and range in sizes of maxillary and mandibular molars in all dimensions obtained by Dr. Woelfel.

- A. Maxillary molars average 2.2 mm wider faciolingually than maxillary premolars, and 3.0 mm wider mesiodistally, and mandibular molars average 2.1 mm wider faciolingually and 3.2 mm wider mesiodistally.
- B. On 839 mandibular molars, crowns averaged 1.2 mm wider mesiodistally than faciolingually. On 920 maxillary molars, crowns averaged 1.2 mm wider faciolingually than mesiodistally.
- C. The average root-to-crown ratio is 1.72 and 1.70 for the maxillary first and second molars, respectively. The average root-to-crown ratio for mandibular molars is the greatest of all teeth: 1.83 and 1.82 for the first and second molars, respectively.
- D. Mandibular first molar crowns are 3.7 mm wider mesiodistally than occlusocervically, and on mandibular second molar crowns are 3.1 mm wider.
- E. Dr. Woelfel examined more than 600 sets of complete dentition casts of young dental hygienists' mouths and found only a few where mandibular second molars were slightly larger than the first molars. There were a few more in which the mandibular third molar crowns were as large as the first molars and larger than the mandibular second molars.

Table 5-7

**SIZES OF MAXILLARY MOLARS (MILLIMETERS) (MEASURED BY DR. WOELFEL AND HIS DENTAL HYGIENE STUDENTS, 1974–1979)**

DIMENSION MEASURED	308 FIRST MOLARS		309 SECOND MOLARS		303 THIRD MOLARS	
	Average	Range	Average	Range	Average	Range
Crown length <sup>a</sup>	7.5	6.3–9.6	7.6	6.1–9.4	7.2	5.7–9.0
Root length						
Mesiobuccal <sup>a</sup>	12.9	8.5–18.8	12.9	9.0–18.2	10.8	7.1–5.5
Distobuccal	12.2	8.9–15.5	12.1	9.0–16.3	10.1	6.9–14.5
Lingual	13.7	10.6–17.5	13.5	9.8–18.8	11.2	7.4–15.8
Overall length <sup>a</sup>	20.1	17.0–27.4	20.0	16.0–26.2	17.5	14.0–22.5
Crown width (M–D)	10.4	8.8–13.3	9.8	8.5–11.7	9.2	7.0–11.1
Root width (cervix)	7.9	6.4–10.9	7.6	6.2–8.4	7.2	5.3–9.4
Faciolingual crown size	11.5	9.8–14.1	11.4	9.9–14.3	11.1	8.9–13.2
Faciolingual root (cervix)	10.7	7.4–14.0	10.7	8.9–12.7	10.4	7.5–12.5
Mesial cervical line curvature	0.7	0.0–2.1	0.6	0.0–2.2	0.5	0.0–2.0
Distal cervical line curvature	0.3	0.0–1.4	0.2	0.0–1.0	0.2	0.0–1.7

<sup>a</sup>Overall length from mesiobuccal root apex to tip of mesiobuccal cusp. Root length is from cervical line center to root apex. Crown length is from cervical line to tip of mesiobuccal cusp (slanted).

Table 5-8

**SIZES OF MANDIBULAR MOLARS (MILLIMETERS) (MEASURED BY DR. WOELFEL AND HIS DENTAL HYGIENE STUDENTS, 1974–1979)**

DIMENSION MEASURED	281 FIRST MOLARS		296 SECOND MOLARS		262 THIRD MOLARS	
	Average	Range	Average	Range	Average	Range
Crown length <sup>a</sup>	7.7	6.1–9.6	7.7	6.1–9.8	7.5	6.1–9.2
Root length						
Mesial <sup>a</sup>	14.0	10.6–20.0	13.9	9.3–18.3	11.8	7.3–14.6
Distal	13.0	8.1–17.7	13.0	8.5–18.3	10.8	5.2–14.0
Overall length <sup>a</sup>	20.9	17.0–27.7	20.6	15.0–25.5	18.2	14.8–22.0
Crown width (M–D)	11.4	9.8–14.5	10.8	9.6–13.0	11.3	8.5–14.2
Root width (cervix)	9.2	7.7–12.4	9.1	7.4–10.6	9.2	6.4–10.7
Faciolingual crown size	10.2	8.9–13.7	9.9	7.6–11.8	10.1	8.2–13.2
Faciolingual root (cervix)	9.0	7.3–11.6	8.8	7.1–10.9	8.9	7.0–11.5
Mesial cervical line curvature	0.5	0.0–1.6	0.5	0.0–1.4	0.4	0.0–1.4
Distal cervical line curvature	0.2	0.0–1.2	0.2	0.0–1.2	0.2	0.0–1.0

<sup>a</sup>Overall length from mesial root apex to tip of mesiobuccal cusp. Root length is from cervical line center to root apex. Crown length is from cervical line to tip of mesiobuccal cusp.

- F. Based on measurements of 2392 maxillary teeth and 2180 mandibular teeth, the widest tooth is the mandibular first molar averaging 11.4 mm wide.
- G. On dental stone casts of 874 dental hygiene students at the Ohio State University College of Dentistry (1971–1983), 81% of 1327 mandibular first molars without restorations had five cusps, and 19% had only four cusps. Seventy-seven percent of the females had five-cusp first molars on both sides, 16% had four-cusp first molars on both sides, and 3% had one four-cusp and one five-cusp mandibular first molar.
- H. On 1367 mandibular first molars, the mesiobuccal cusp was widest 61% of the time compared to only 17% where the distobuccal cusp was widest.
- I. On 430 teeth, the distobuccal cusp was sharper than the mesiobuccal cusp 55% of the time, compared to only 17% for the mesiobuccal cusp. The rest were equally sharp.
- J. On 720 molars, 70% of the time the distobuccal groove was shorter than the mesiobuccal groove.
- K. On 1514 mandibular second molars examined on dental stone casts, the mesiobuccal cusp was considered wider than the distobuccal cusp on 66%, compared to only 19% with a wider distobuccal cusp.
- L. On 281 mandibular first molars, the mesial root averaged 1 mm longer than the distal root, and on 296 mandibular second molars, 0.9 mm longer. The root-to-crown ratio of mandibular first molars is 1.83 to 1, the highest ratio of any adult tooth.
- M. On 58% of 256 mandibular first molars, the mesiolingual cusp was wider than the distolingual cusp, while on 33% the distolingual cusp was wider. On mandibular second molars, the mesiolingual cusp was wider on 65% of 263 of these teeth, compared to only 30% with a wider distolingual cusp.
- N. When evaluating the lingual cusps of mandibular first molars, 48% had more pointed mesiolingual cusps versus 47% had more pointed distolingual cusps; on mandibular second molars, 44% had more pointed mesiolingual cusps versus 51% had the distolingual cusps wider.
- O. The mesial CEJ curves 0.5 mm on first molars, 0.2 mm on second molars.
- P. Marginal ridge grooves were found crossing the mesial marginal ridge on 68% of 209 mandibular first molars and 57% of 233 mandibular second molars. They were found crossing distal marginal ridges on 48% of 215 first molars and 35% of 233 second molars.
- Q. Mandibular molar crowns were wider mesiodistally than faciolingually by 1.2 mm on 281 mandibular first molars, by 0.9 mm for 296 mandibular second molars.
- R. On 233 mandibular second molars, marginal ridge grooves were found on 57% on the mesial and 35% of the distal marginal ridges. On 209 mandibular first molars, marginal ridge grooves were found on 68% on the mesial and 35% of the distal marginal ridges.
- S. On 1539 maxillary first molars, the mesiobuccal cusp was wider than the distobuccal cusp 64% of the time; on 1545 second molars, the mesiobuccal

cusps was wider 92% of the time. On 468 first molars, the distobuccal cusp was sharper 72% of the time, whereas on 447 second molars, the sharpness of buccal cusps was equal.

- T. The three maxillary molar roots are within 1.5 mm in length.
- U. As data show in *Table 5-6*, 46.5% of 1558 maxillary first molars had some form of Carabelli cusp (large or small), 24% had a depression in this location, and 29.5% were without any type of Carabelli formation.
- V. On 1396 unrestored maxillary second molars from 808 students' casts examined by Dr. Woelfel, 37% of maxillary second molars had only three cusps.
- W. On 308 maxillary first molars, the longest lingual root averaged 13.7 mm long.
- X. On maxillary first molars: 78% of 69 teeth had mesial marginal grooves, but only 50% of 60 had distal marginal ridge grooves; on second molars, 67% of 75 teeth had mesial marginal ridge grooves, but only 38% of 79 teeth had distal marginal ridge grooves.
- Y. On maxillary first molars: 86% of 64 teeth had mesial ridge tubercles, but only 18% had distal ridge tubercles. On maxillary second molars: 38% of 79 teeth had mesial marginal ridge tubercles, but only 9% of 79 teeth had distal ridge tubercles.
- Z. On 308 maxillary first molars, the mesial CEJ curvature averaged only 0.7 and 0.6 mm on the mesial CEJ of maxillary second molars.
- AA. On stone casts of 1469 maxillary first molars, the mesiolingual cusp was largest 95% of the time and the distolingual cusp was smallest 72% of the time.
- BB. Among 710 Ohio State University dental hygiene students, there were 185 maxillary third molars and 198 mandibular third molars congenitally absent. Many students were missing more than one third molar, so the percentage of the population missing one or more third molars might be close to 20%.
- CC. Mandibular third molars average only 18.2 mm long.
- DD. On 303 maxillary third molars, the buccal roots averaged 2.0 mm shorter than on firsts and seconds and the lingual root averaged 2.5 mm shorter.
- EE. On 920 molars, the root trunks on maxillary third molars are, on average, 2.0 mm longer than on maxillary first or second molars.
- FF. On 262 mandibular third molars, the crowns of the four-cusp type were wider mesiodistally than faciolingually by 1.2 mm.
- GG. On 839 mandibular molars, the roots of thirds averaged over 2 mm shorter than on firsts and seconds combined. The average root-to-crown ratio on mandibular third molars is 1.6 compared to 1.8 on mandibular first and second molars.

## Primary (and Mixed) Dentition

- I. Basic concepts about primary teeth
  - A. Definitions
  - B. Dental formulae
  - C. Functions of the primary dentition
- II. Developmental data for primary and secondary teeth
  - A. Important times for tooth eruption
  - B. Crown and root development
- III. Traits of all primary teeth
  - A. Traits of all primary teeth compared to permanent teeth
- IV. Class and type traits of primary teeth
  - A. Primary incisor traits
  - B. Primary canine traits
  - C. Primary molar traits
- V. Pulp cavities of primary teeth
  - B. Traits of all primary anterior tooth crowns
  - C. Root traits of primary *anterior* teeth
  - D. Traits of all primary *posterior* tooth crowns
  - E. *Root* traits of primary posterior teeth

### OBJECTIVES

This chapter is designed to prepare the learner to perform the following:

- Describe the important functions of the primary dentition and the problems that can occur from premature loss of primary teeth.
- List the time ranges for primary and secondary tooth eruption.
- List the time ranges for crown and root formation for primary and secondary teeth.
- Give the order of eruption of primary and secondary teeth.
- Describe the dentition (set) traits that differentiate primary from secondary teeth.
- Describe class and type traits that distinguish the primary incisors, canines, and molars.
- Describe the size and shape of primary tooth pulp chambers.
- Using the Universal Identification System, identify permanent and primary teeth present in the mouth with mixed dentition.
- Establish the estimated “dental age” of a person by studying his or her mixed dentition.

### SECTION I

### BASIC CONCEPTS ABOUT PRIMARY TEETH

Statements that reference specific dimension data are highlighted with superscript letters throughout this chapter like this (data<sup>A</sup>). The letters refer to data presented at the end of this chapter.

#### A. DEFINITIONS

Primary teeth are often called **deciduous** [dee SIJ oo es] teeth. Deciduous comes from the Latin word *decidere* meaning to fall off. Deciduous teeth fall off or are shed (like leaves from a deciduous tree) and are replaced by the adult teeth that succeed them. Common nicknames for them are “milk teeth,” or “temporary teeth,” which, unfortunately, denote a lack of importance. The dentition that follows the primary teeth is called the **permanent dentition** and may also be called the **secondary dentition** (or adult dentition).

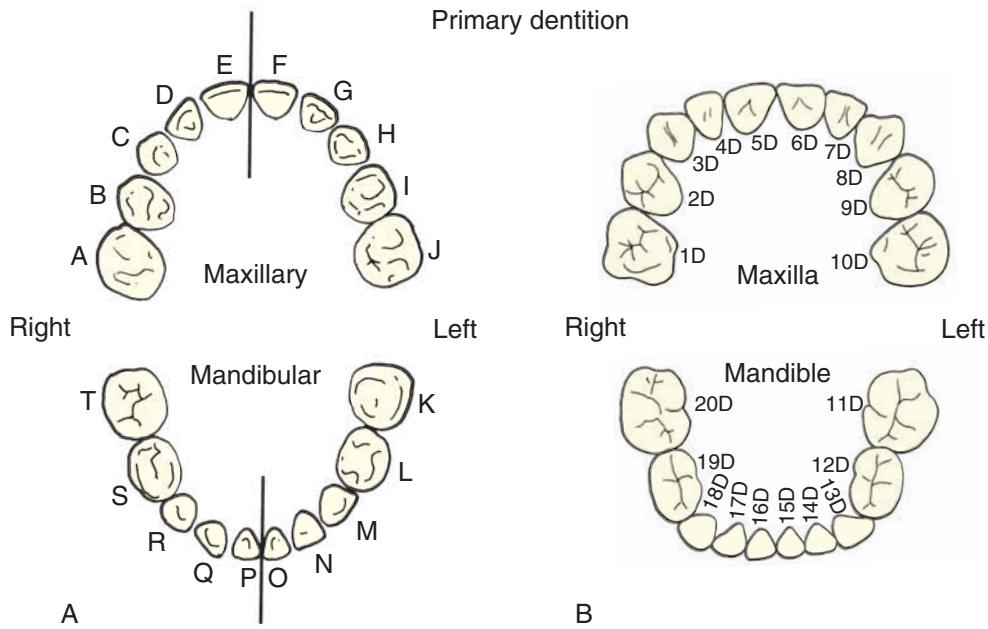
#### B. DENTAL FORMULAE

As stated in Chapter 1, the number and type of primary teeth in each half of the mouth are represented by this formula:

$$\text{Incisors } \frac{2}{2} \quad \text{Canines } \frac{1}{1} \quad \text{Molars } \frac{2}{2} = \frac{\begin{array}{c} 5 \text{ maxillary teeth} \\ \text{per quadrant} \end{array}}{\begin{array}{c} 5 \text{ mandibular teeth} \\ \text{per quadrant} \end{array}}$$

Compare this formula to that for the secondary dentition, and you will be able to draw some interesting conclusions:

$$\text{Incisors } \frac{2}{2} \quad \text{Canines } \frac{1}{1} \quad \text{Premolars } \frac{2}{2} \\ \text{Molars } \frac{3}{3} = \frac{\begin{array}{c} 8 \text{ maxillary teeth per quadrant} \\ 8 \text{ mandibular teeth per quadrant} \end{array}}$$



**FIGURE 6-1.** Diagram of maxillary and mandibular primary dental arches. Two methods of identifying these primary teeth are shown. **A.** The Universal System of assigning letters to each tooth is shown. **B.** A numbering system 1 through 20 followed by “D” for deciduous is shown.

Notice that there are *no primary premolars*. When secondary teeth replace primary teeth, the primary *molars are replaced by premolars*. The 20 secondary teeth that succeed their primary tooth predecessors are called **succedaneous** [suck si DAY nee ous] teeth. The 12 secondary molars, however, have no predecessors in the primary dentition and erupt distal to the primary molars. Therefore, in the strict sense, secondary molars are *not* succedaneous teeth.

Primary teeth exhibit an arch form similar to permanent teeth. Recall from Chapter 1 that the 20 primary teeth can be identified using the universal identification system by assigning letters A (for the primary right maxillary second molar) through T (for the primary right mandibular second molar). Another method that can be used to identify these teeth uses a “D” to denote deciduous preceded by Numbers 1 (1D for the primary right maxillary second molar) through 20 (20D for the primary right mandibular second molar). Both of these systems are seen in *Figure 6-1*. (Two other methods for numbering primary teeth were presented in *Table 1-1*.)

### C. FUNCTIONS OF THE PRIMARY DENTITION

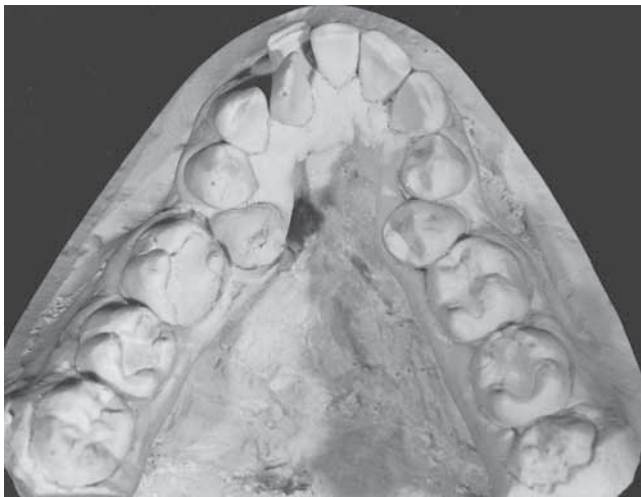
Some parents do not consider the care of the primary teeth of their children to be a priority since they consider them as “temporary” or “baby” teeth, but it is important to remember that primary teeth are the only teeth that children have until approximately their sixth birthday, and some remain functioning until age 12. Primary teeth are actually in the mouth functioning for almost 6 years for mandibular central incisors to almost 10 years for

maxillary canines.<sup>A</sup> When people live to be 70 years of age, they will have spent 6% of their life chewing only with primary teeth. This small proportion of time should not infer a lack of importance of primary teeth, however, because they play a very important role in “reserving” space for the permanent teeth, which ensures proper alignment, spacing, and occlusion of the permanent teeth. Consider the following functions of primary teeth in order to confirm the importance of keeping them healthy:

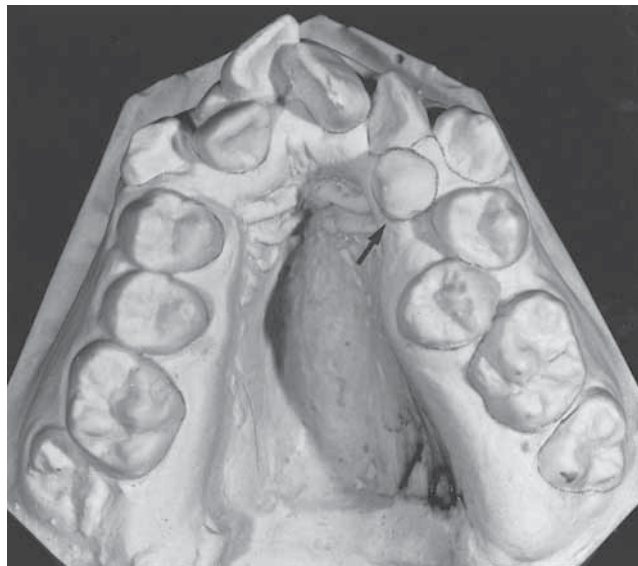
- Primary teeth are needed for efficient chewing (mastication) of food.
- They provide support for the cheeks and lips maintaining a normal facial appearance and smile.
- They are necessary for the formulation of clear speech.
- They are critical for maintaining the space that is required to provide room for the eruption of permanent teeth.

When primary teeth are lost prematurely or are not shed as succedaneous teeth emerge, the results on tooth alignment can be devastating (*Figs. 6-2 and 6-3*). Correction of tooth alignment and deformities in these children would require extensive orthodontic therapy (involving placement of orthodontic appliances, or braces, which can be used to improve tooth alignment). Further, maintenance of a proper diet and good oral hygiene are necessary to avoid dental decay of primary teeth that could lead to infection with pain, possibly making the child reject foods that are difficult to chew. Finally, an abscess from the infection of the pulp of a primary tooth can cause discolored spots (Turner’s spots) on the developing secondary tooth beneath it.





**FIGURE 6-2.** A crowded mandibular permanent dentition caused by the premature loss of primary molars. Notice that the left lateral incisor almost contacts the right central incisor, and that the left first premolar is only 2.5 mm from contacting the first molar.



**FIGURE 6-3.** Extreme crowding of a maxillary permanent dentition in a 12-year-old child. The left primary canine (*arrow*) was not shed because its successor emerged labially to it. Both 12-year molars (three-cusp type) are in the process of emerging.

## SECTION II

## DEVELOPMENTAL DATA FOR PRIMARY AND SECONDARY TEETH

Dental students and dental hygiene students should become familiar with the eruption dates of primary and secondary teeth in order to adequately and correctly inform worried parents and patients about the normal times when teeth emerge or erupt above the gingiva. Expected eruption patterns for primary and secondary teeth from one study are presented in *Table 6-1A*; eruption patterns from another study of only primary teeth are presented in *Table 6-1B*. An emergence time for each type of primary tooth can be considered normal if it is within 4 to 5 months (earlier or later) of the dates in *Table 6-1A*. Secondary tooth eruption can be within 12 to 18 months (early or late) of those dates and still be of no real concern. Early eruption of these teeth usually presents no problems other than a concern about instituting oral hygiene measures.

Dental radiographs (x-ray films) are the best means for determining what is covered up (unerupted) or missing in a dentition when the expected teeth have not emerged, particularly when they are considerably overdue. (See Fig. 6-7 later in this chapter.)

### A. IMPORTANT TIMES FOR TOOTH ERUPTION

Instead of memorizing the specific times of eruption of each tooth (which would be a daunting task), first divide the development of teeth into four time peri-

ods: when there are no teeth, when primary teeth are erupting and are the only teeth present, when the dentition is a **mixed dentition** (that is, made up of primary and permanent teeth), and when there are only adult teeth. If you first learn those time ranges, you will be well on your way to understanding the schedule of tooth eruption for both dentitions.

1. **NO TEETH (EDENTULOUS)**
  - **From birth to 6 months old** (approximately): There are no teeth visible within the mouth.
2. **PRIMARY DENTITION ONLY**
  - **6 months to 2 years old** (approximately): All primary teeth are erupting into the child's mouth over this period.
  - **2 to 6 years old** (approximately): All 20 primary teeth are present; no permanent teeth are yet visible in the mouth.
3. **MIXED DENTITION**
  - **6 years old** (approximately): Permanent teeth start to appear, beginning with the first molars (also called 6-year molars) just distal to the primary second molars. These are followed closely by the loss of the primary mandibular central incisors, which are quickly replaced by the permanent mandibular central incisors.
  - **6 to 9 years old**: All eight permanent *incisors* replace primary incisors that are exfoliated (shed).

Table 6-1A PRIMARY AND SECONDARY TOOTH FORMATION AND EMERGENCE TIMES

		TOOTH	HARD TISSUE FORMATION BEGINS	CROWN COMPLETED	EMERGENCE	ROOT COMPLETED
PRIMARY DENTITION	Maxillary teeth	Central incisor	<b>4 mo in utero (first primary to begin)</b>	4 mo	7½ mo	1½ y
		Lateral incisor	4½ mo in utero	5 mo	9 mo	2 y
		Canine	5 mo in utero	9 mo	18 mo	3¼ y
		First molar	5 mo in utero	6 mo	14 mo	2½ y
		Second molar	6 mo in utero	11 mo	24 mo	3 y
	Mandibular teeth	Central incisor	4½ mo in utero	3½ mo	6 mo	1½ y
		Lateral incisor	4½ mo in utero	4 mo	7 mo	1½ y
		Canine	5 mo in utero	9 mo	16 mo	3 y
		First molar	5 mo in utero	5½ mo	12 mo	2¼ y
		Second molar	6 mo in utero	10 mo	20 mo	3 y
PERMANENT DENTITION	Maxillary teeth	Central incisor	3–4 mo	4–5 y	7–8 y	10 y
		Lateral incisor	10–12 mo	4–5 y	8–9 y	11 y
		Canine	4–5 mo	6–7 y	11–12 y	13–15 y
		First premolar	1½–1¾ y	5–6 y	10–11 y	12–13 y
		Second premolar	2–2¼ y	6–7 y	10–12 y	12–14 y
		First molar	<b>Birth (first secondary to begin)</b>	2½–3 y	6–7 y	9–10 y
		Second molar	2½–3 y	7–8 y	12–15 y	14–16 y
	Mandibular teeth	Third molar	7–9 y	12–16 y	17–21 y	18–25 y
		Central incisor	3–4 mo	4–5 y	6–7 y	9 y
		Lateral incisor	3–4 mo	4–5 y	7–8 y	10 y
		Canine	4–5 mo	6–7 y	9–10 y	12–14 y
		First premolar	1¾–2 y	5–6 y	10–12 y	12–13 y
		Second premolar	2¼–2½ y	6–7 y	11–12 y	13–14 y
		First molar	<b>Birth</b>	2½–3 y	6–7 y	9–10 y
		Second molar	2½–3 y	7–8 y	11–13 y	14–15 y
Third molar	8–10 y	12–16 y	17–21 y	18–25 y		

Chart based on Logan WH, Kronfield R. Development of the human jaws and surrounding structures from birth to age fifteen. JADA 20:379–424, 1933 or 35. Modified by McCall and Schour: Schour I, McCall JO. Chronology of the human dentition. In: Orban B, ed. Oral histology and embryology. St. Louis, MO: C.V. Mosby, 1944:240.

Table 6-1B TOOTH DEVELOPMENT AND ERUPTION: PRIMARY TEETH

		HARD TISSUE FORMATION BEGINS (WEEKS IN UTERO)	ENAMEL COMPLETED (MONTHS AFTER BIRTH)	ERUPTION (MONTHS)	ROOT COMPLETED (YEAR)
Maxillary	Central incisor	14	1½	10 (8–12)	1½
	Lateral incisor	16	2½	11 (9–13)	2
	Canine	17	9	19 (16–22)	3¼
	First molar	15½	6	16 (13–19 boys) (14–18 girls)	2½
Mandibular	Second molar	19	11	29 (25–33)	3
	Central incisor	14	2½	8 (6–10)	1½
	Lateral incisor	16	3	13 (10–16)	1½
	Canine	17	9	20 (17–23)	3¼
	First molar	15½	5½	16 (14–18)	2¼
	Second molar	18	10	27 (23–31 boys) (24–30 girls)	3

From Lunt RC, Law DB. A review of the chronology of deciduous teeth. J Am Dent Assoc 1974;89:872.

- **9 to 12 years old:** All four permanent *canines* and eight *premolars* replace primary canines and molars.
- **12 years old:** Second molars (also called 12-year molars) emerge distal to the permanent first molars.

#### 4. ADULT DENTITION ONLY

- **After 12 years (second)** Molars erupt, 28 permanent teeth are present, and all primary teeth have been exfoliated and replaced.
- **17 to 21 years old:** Third molars (if present) emerge.

## B. CROWN AND ROOT DEVELOPMENT

With these basic time periods in mind, one must not forget that much more is taking place during the development of these teeth than just their eruption into the mouth, or their exfoliation. Prior to eruption, tooth crowns are forming from lobes and are calcifying within the jawbones. After crown calcification is completed, the tooth root starts to form and the tooth moves through bone toward the surface (eruption process) and eventually through the oral mucosa into the oral cavity (eruption or emergence). After eruption, the root continues to form until root formation is completed. At the same time, primary teeth are forming and erupting, permanent teeth are already beginning to form within the jaw bones. As these permanent teeth develop and calcify, they eventually move occlusally to replace the primary teeth.

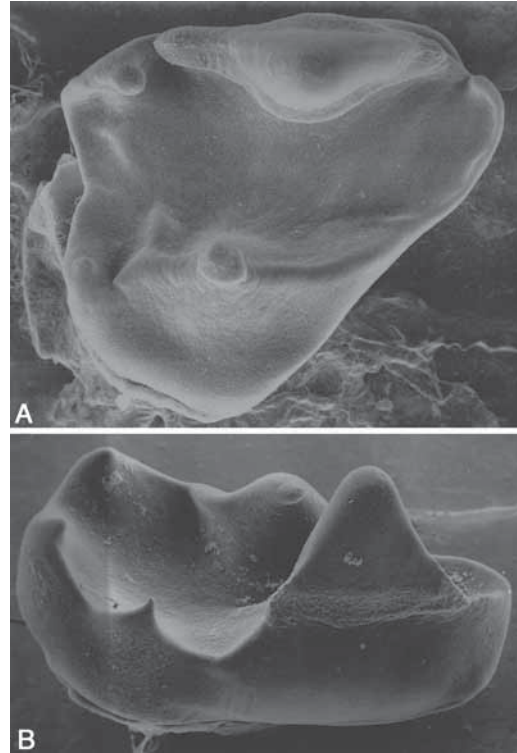
Now let us look at this entire process in more detail, discussing it step by step. All of the following information is derived from Table 6-1A.

### 1. CROWN CALCIFICATION OF PRIMARY TEETH

The crowns of all 20 primary teeth begin to calcify between 4 and 6 months in utero (seen developing in Fig. 6-4). Crown completion of all primary teeth occurs within the first year after birth, taking an average of 10 months from the beginning of tooth calcification.<sup>B</sup>

### 2. ROOT FORMATION AND EMERGENCE OF PRIMARY TEETH

Root formation for primary (and permanent) teeth begins once the enamel on the crown is formed, and at this time, the tooth starts its occlusal movement through bone toward the oral cavity. After the primary tooth crowns erupt into the oral cavity from about age 6 months to 2 years (24 months),<sup>C</sup> they continue to erupt until eventually they occlude with teeth in the opposite arch. These teeth also continue to erupt to compensate



**FIGURE 6-4.** Developing human primary molars. **A.**

Occlusal view of an in utero 19-week *maxillary* right first molar. Note the large, well-developed, mesiobuccal cusp, which is covered with a mineralized enamel cap and is the first formed and largest cusp of the trigon, the early molar form that has three cusps. (Original magnification  $\times 36$ .) **B.** Buccal view of an in utero 20-week *mandibular* right first molar. Note the strongly elevated mesiobuccal cusp that dominates the mesial portion of the tooth. The mesiolingual cusp is the second to differentiate and shows incipient mineralization. (Original magnification  $\times 36$ .) These two examples illustrate that the mesiobuccal cusps of both the maxillary and mandibular molars are the first to form and mineralize.

for wear (attrition) on the incisal or occlusal surface and/or when there are no opposing teeth.

### 3. ORDER OF EMERGENCE OF PRIMARY TEETH (FROM 6 MONTHS TO ABOUT 2 YEARS OLD)

According to one study (shown in Table 6-2), the *first* primary teeth to erupt are the *mandibular central incisors*, at about 6 months of age, followed by the mandibular laterals and then the maxillary incisors (centrals before laterals). (Note the difference in eruption patterns compiled by other researchers in Table 6-1B, where the *mandibular central incisors* erupt first, but they are followed by maxillary central incisors, maxillary lateral incisors, and finally mandibular lateral incisors.) Next to emerge are the primary first molars, then canines,

Table 6-2

**CHART REPRESENTING ORDER OF PRIMARY TOOTH EMERGENCE BASED ON DATA IN TABLE 6-1A**

	CENTRAL INCISOR	LATERAL INCISOR	CANINE	FIRST MOLAR	SECOND MOLAR
Maxillary	Third (7½ mo)	Fourth (9 mo)	Eighth (18 mo)	Sixth (14 mo)	Tenth (24 mo)
Mandibular	First (6 mo)	Second (7 mo)	Seventh (16 mo)	Fifth (12 mo)	Ninth (20 mo)

and finally second molars. Thus, the *last* primary teeth to emerge, thereby completing the primary dentition, are the maxillary second molars, at about 2 years (24 months) of age.

The combined mesiodistal arch space occupied by the primary canines and molars in each quadrant is greater than that occupied by the permanent canines and premolars since the primary molars are wider than the premolars that will replace them. This difference in space is called the **leeway space**. Also, as primary teeth erupt, developmental spaces often occur between anterior teeth, especially as the maxillae and the mandible bones grow larger. These spaces that occur mesial to the maxillary canines and distal to the mandibular canines are called **primate spaces**.<sup>2</sup> These spaces frequently concern parents but are perfectly natural and even beneficial since they provide room for the secondary incisors and canines, which are considerably wider than their predecessors. Refer to *Table 6-3* for differences in sizes between primary and permanent teeth.

#### 4. ROOT COMPLETION OF PRIMARY TEETH

Primary tooth roots are completed between the ages of 18 months to 3 years.<sup>D</sup> The complete primary dentition (with 20 teeth) is in the mouth from about 2 years of age to about 6 years, during which *no permanent teeth* are visible in the mouth, but permanent teeth are forming within the jaws.

#### 5. EXFOLIATION (SHEDDING) OF PRIMARY TEETH WITH THE NEARLY SIMULTANEOUS ERUPTION OF THE PERMANENT TEETH

The roots of primary teeth are complete for only a short period of time (as seen in *Fig. 6-5*). Only about 3 years after completion, primary tooth roots begin to **resorb**, usually at the apex or on one side near the apex. **Resorption** of a primary tooth root is the gradual dissolving away of the root due to the underlying eruption of the succedaneous tooth that will replace it. Root resorption continues as succedaneous teeth move

closer to the surface until deciduous teeth eventually become loose and finally “fall off” (like leaves fall off of deciduous trees). This process of shedding is called **exfoliation**. When a primary tooth is shed, the crown of the succedaneous tooth is close to the surface and ready to emerge (as seen in *Fig. 6-6*).

#### 6. MIXED DENTITION (FROM ABOUT 6 TO 12 YEARS OLD)

When there are both primary and permanent teeth visible in the mouth, the dentition is known as a **mixed dentition**. Mixed dentition begins at about age 6 years old when the first (6-year) molars emerge. Next, the first primary incisors are gradually replaced by their larger successors. The mixed dentition ends at about age 12 when all primary teeth have been replaced. Usually, 24 teeth are seen in the mouth throughout the mixed dentition (20 teeth [primary or their permanent successors], plus the four 6-year first molars). At 12 years old, all succedaneous teeth have replaced their primary predecessors marking the end of mixed dentition. When the 12-year second molars erupt, 28 teeth are present. The full complement of 32 permanent teeth is not reached until the third molars erupt during the late teenage years or early 20s.

Soon after the 6-year first molars erupt, their eruptive forces, along with their tendency to drift toward the mesial, push the primary teeth forward. If this were to continue, there would be insufficient space for the premolars to come in. The flared roots of the primary molars, however, resist the mesial displacement (seen in *Fig. 6-5*). This primary molar root flare, primary molar crown size wider mesiodistally than their premolar successors, and primate spaces all help to preserve sufficient space for the premolars and secondary canines.<sup>3</sup>

#### 7. CROWN FORMATION OF PERMANENT TEETH

The crowns of the first permanent molars begin forming at birth. Other permanent tooth crowns continue

**Table 6-3 PRIMARY TOOTH SIZE COMPARED TO THEIR SUCCESSORS**

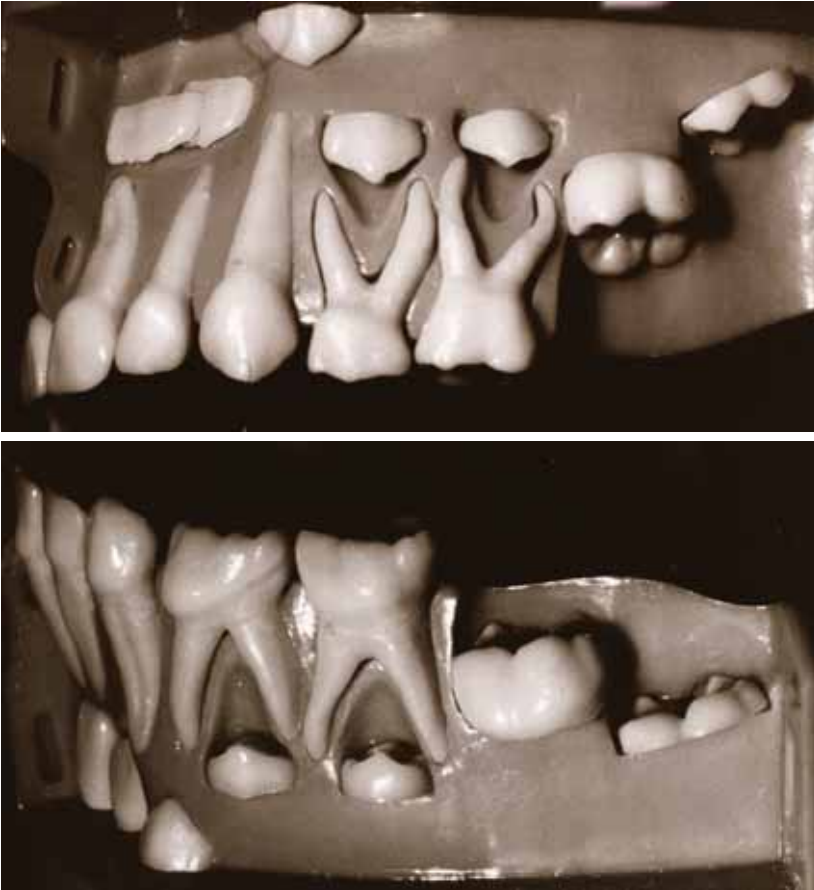
	CROWN LENGTH		ROOT LENGTH		OVERALL LENGTH		MESIODISTAL CROWN		FACIOLINGUAL CROWN		MESIODISTAL CERVIX		FACIOLINGUAL CERVIX		AVERAGE OF ALL MEASUREMENTS	
	mm	%	mm	%	mm	%	mm	%	mm	%	mm	%	mm	%	mm	%
<b>Maxillary teeth</b>																
Central incisor	6.4	57	11.3	82	17.2	73	7.4	86	5.0	70	5.7	89	4.4	70	75.3	
Lateral incisor	7.4	76	10.9	81	16.8	75	5.8	88	4.9	79	4.0	85	4.5	78	80.3	
Canine	7.6	72	13.5	78	20.2	80	7.4	97	5.4	67	5.3	95	5.0	66	78.8	
First molar	6.0	70	12.5	93	17.1	80	8.1	114*	9.5	103	5.9	123	8.9	108	98.7	
Second molar	6.4	83	10.4	74	15.9	75	9.7	147*	10.3	114	7.1	151	9.6	118	108.8	
<b>Mandibular teeth</b>																
Central incisor	6.1	69	10.5	83	16.0	77	4.5	85	4.5	79	3.5	100	4.2	78	81.6	
Lateral incisor	7.3	78	10.6	78	16.5	75	4.9	86	4.8	79	3.7	94	4.5	78	81.4	
Canine	8.2	74	11.7	74	18.7	72	6.1	90	5.7	74	4.2	81	5.0	67	76.0	
First molar	7.1	81	9.7	67	15.9	71	8.7	124*	7.4	96	7.2	150	5.3	78	95.3	
Second molar	6.6	80	10.8	68	15.5	70	10.3	145*	9.2	112	7.6	152	7.1	97	103.4	

Measurements are derived from 2392 maxillary and 2180 mandibular secondary tooth specimens compared to plastic model replicas of primary teeth made by the Shofu Dental Manufacturing Company (Kyoto, Japan) reflecting the size of Japanese primary teeth. In most instances, these measurements on the plastic model teeth were 0.5 to 1 mm larger than measurements made by G.V. Black at the turn of the century (deciduous teeth).

Percentages are based on the average size for the secondary dentition successor as equaling 100%. In instances in which the deciduous tooth dimension is greater than its successor, the percentage is over 100, even as high as 152% on the mandibular second molar mesiodistal cervix dimension, indicating that this part of the deciduous molar is 1.5 times larger than the corresponding region on its successor, the mandibular second premolar.

\*Denotes percentages where primary crown measurements are wider mesiodistally than succedaneous teeth.





**FIGURE 6-5.** Models depicting the stage of development of the dentitions of a 3-year-old child. All primary teeth have emerged into the oral cavity, and they have full roots, prior to resorption. Notice the various amounts of crown development and locations of the partially formed crowns of the permanent dentition. (Models courtesy of 3M Unitek, Monrovia, California.)

to form up to age 16 when crowns of third molars are completed. On average for the adult dentition, crown formation and calcification are completed about 3 to 4 years prior to eruption into the mouth.<sup>E</sup>

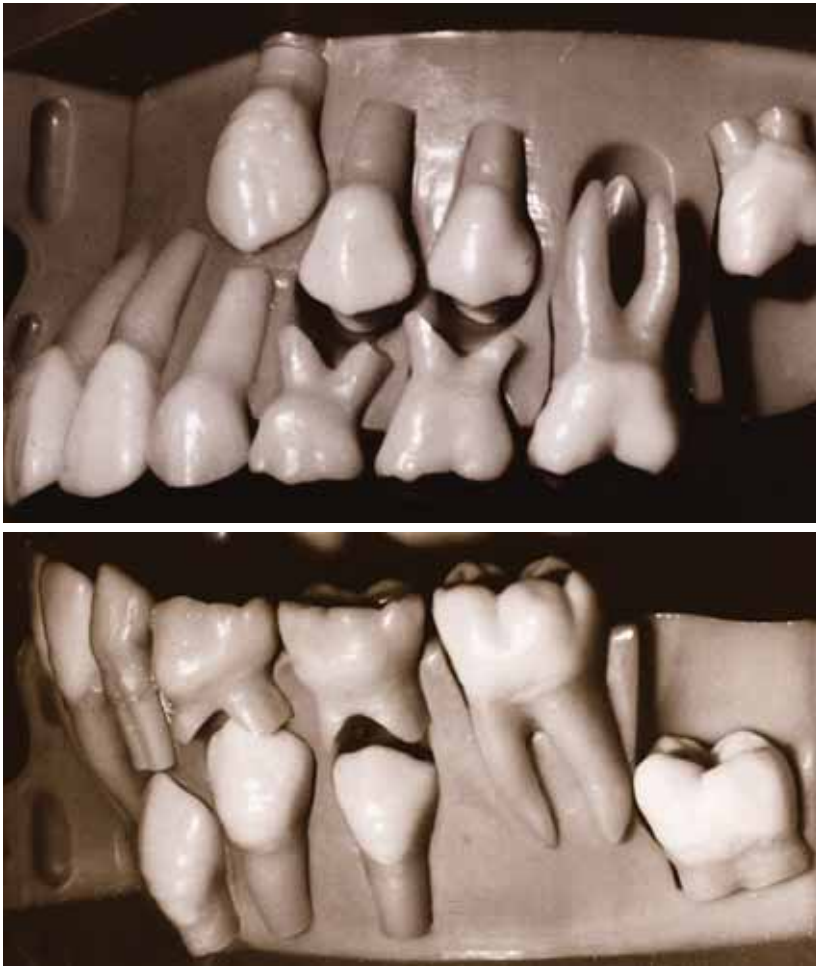
## 8. ORDER OF EMERGENCE FOR SECONDARY TEETH

Table 6-4 shows the sequence of eruption for permanent teeth. After the 6-year molars erupt just prior to the child's sixth birthday, the order of eruption for the succedaneous teeth is essentially the same as the order of exfoliation of the primary teeth they replace. If you know the time range for eruption of incisors (between 6 and 9 years old), or for canines and premolars (between 9 and 12 years old), plus the sequence of eruption within that time range, you can estimate the eruption time for any succedaneous tooth. Remember that centrals erupt before laterals, and mandibular incisors erupt before their maxillary counterpart. The first permanent incisors to erupt are the *mandibular central incisors* (close to 6 years old) and the last incisors to erupt are the maxillary lateral incisors (close to 9 years

old). *Mandibular laterals and maxillary centrals erupt from 7 to 8 years old.*

Next, *adult canines and premolars erupt between ages 9 and 12.* If you know the eruption sequence within this range, you can estimate the eruption time. First, *mandibular canines* replace primary mandibular canines (closer to 9 years old), and then premolars replace primary molars (between 10 and 12 years old). Finally, *maxillary canines are the last primary teeth to be replaced* (closer to 12 years old). This is often evident when the permanent maxillary canines are crowded facially as they erupt (as seen in Fig. 6-3). Note in Table 6-4 that for the adult dentition, most teeth in the mandibular arch erupt slightly earlier than their maxillary counterparts; the ONLY maxillary tooth to emerge before its mandibular counterpart is the maxillary second premolar, which precedes the mandibular second premolar. Knowing the range and sequence of eruption of canines and premolars, you can estimate the emergence time of mandibular canines as close to 9 years, while maxillary canines emerge last within this range, at about 12 years of age.

Roots of secondary teeth are completed *about 3 years* after their emergence into the oral cavity.



**FIGURE 6-6.** Tooth development of a 9-year-old child with mixed dentition. The permanent central and lateral incisors and first molars have emerged into a functional level. The primary canines and molars are still functioning, although much of their roots have resorbed. You can appreciate by the position of the maxillary canine (in the bone) why it is often the last permanent tooth to erupt except for the third molars (not shown). (Models courtesy of 3M Unitek, Monrovia, California.)

**Table 6-4** CHART REPRESENTING THE USUAL ORDER OF SECONDARY DENTITION TOOTH EMERGENCE BASED ON DATA FROM TABLE 10-1A

	CENT INC	LAT INC	CANINE	FIRST PREMOLAR	SECOND PREMOLAR	FIRST MOLAR	SECOND MOLAR	THIRD MOLAR
<b>AGE RANGE</b>	6-9 y			9-12 y		6 y	12 y	
Maxillary	2nd (t) (7-8 y)	3rd (8-9 y)	6th (t) (11-12 y)	5th (t) (10-11 y)	5th (t) (10-12 y)	1st (t) (6-7 y)	7th (t) (12-15 y)	8th (t) (17-21 y)
Mandibular	1st (t) (6-7 y)	2nd (t) (7-8 y)	4th (9-10 y)	5th (t) (10-12 y)	6th (t) (11-12 y)	1st (t) (6-7 y)	7th (t) (11-13 y)	8th (t) (17-21 y)

1st, first tooth to erupt; 2nd, second etc., same number with a “(t)” denotes essentially a tie in eruption time. Mandibular teeth often precede their maxillary counterpart within the time ranges given except for second premolars. (Mandibular first molars are often the first secondary teeth to erupt.)

**SECTION III** TRAITS OF ALL PRIMARY TEETH

Your best specimens for the study of crown morphology of primary teeth can be found in the mouth of a 2 to 6 year old who is willing to open his or her mouth wide, long, and often enough to permit your examination. Extracted or exfoliated primary teeth with

complete crowns and roots are difficult to find since most of these have resorbed roots and severe attrition (occlusal wear). Plastic tooth models, if available, are most helpful and have the added advantage of complete roots.

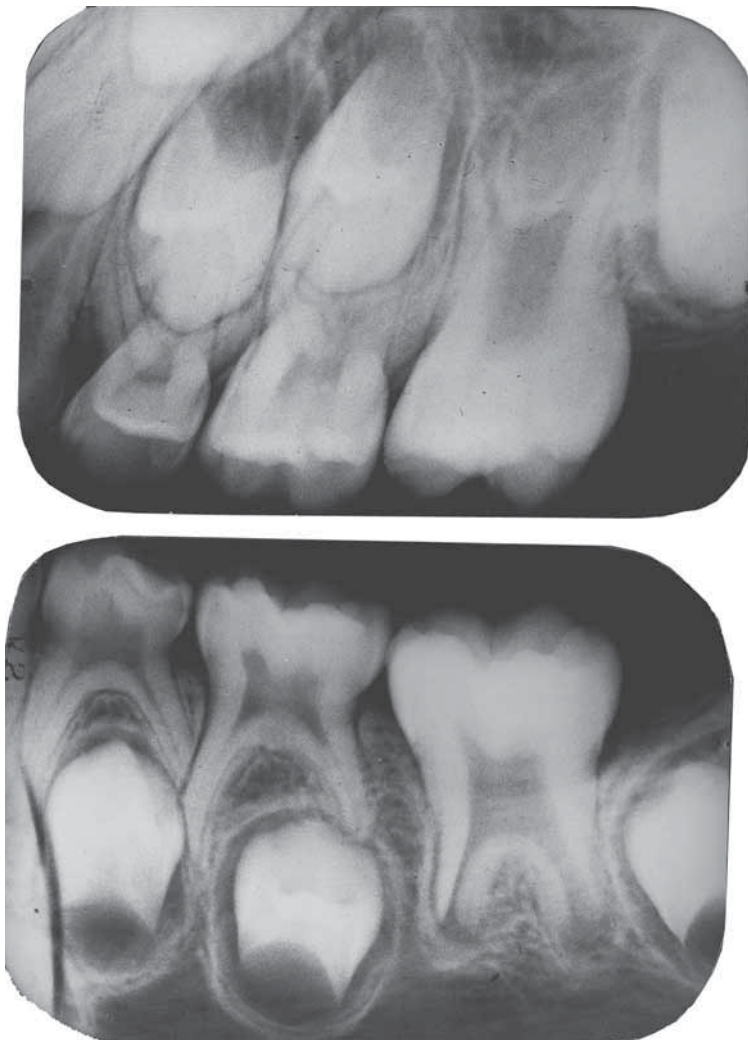
## A. TRAITS OF ALL PRIMARY TEETH COMPARED TO PERMANENT TEETH

First, consider the traits that apply to *all* primary teeth and set them apart from the secondary teeth:

1. Primary teeth are smaller in size than the permanent teeth with the same name (that is, primary incisors and canines are smaller than permanent incisors and canines, respectively, and primary first and second molars are smaller than permanent first and second molars, respectively).
2. The crowns and roots of primary teeth have a marked constriction at the cervix, appearing as if they are being squeezed in around the CEJ. Thus, primary tooth crowns (especially on the facial and lingual surfaces) bulge close to the cervical line forming more prominent labial cervical ridges and lingual

cingula<sup>4</sup> rather than on permanent teeth. This is seen best from the proximal view in Appendices 9a and 10e.

3. Primary teeth have relatively longer roots than their crowns compared to permanent teeth.
4. Primary teeth are less mineralized so become very worn.<sup>4,5</sup> These teeth are prone to considerable **attrition** [at TRISH en] (tooth wear from tooth-to-tooth contact), which is made worse by the shifting relationship of the upper and lower teeth due to expanding growth of the jaws in young children. Attrition, therefore, is not really a dentition trait but a normal occurrence due to function.<sup>4</sup>
5. The layers of enamel and dentin of primary teeth are thinner than on secondary teeth, so the pulp cavities are proportionally larger and therefore closer to the surface (seen in the radiographs in Fig. 6-7). Therefore, decay can progress to the pulp more



**FIGURE 6-7.** Radiographs made of an 8-year-old child showing the first and second primary molars and first adult molars in the mouth. The top radiograph shows maxillary teeth, and the lower radiograph shows mandibular teeth. Notice the premolar crowns between the partially resorbed roots of the maxillary and mandibular primary molars. Part of the 12-year second molar crown is seen on the far right of each radiograph. The smaller size, thinner enamel, and relatively larger pulp cavities are evident in the primary molars compared to the larger secondary molars just distal to them. (Courtesy of Professor Donald Bowers, The Ohio State University.)

quickly through this thinner enamel and dentin than through the thicker adult enamel and dentin, and the dentist must take care not to expose the tooth pulp when preparing primary teeth for fillings since the pulp is closer to the surface.

6. Primary teeth are whiter in color.
7. Primary teeth have more consistent shapes than the permanent teeth (have fewer anomalies).<sup>3</sup>

## B. TRAITS OF ALL PRIMARY ANTERIOR TOOTH CROWNS

---

Consider the unique traits of the primary anterior tooth crowns. Refer to Appendix page 9 while studying these traits.

1. *Prominent cervical ridges* on facial surfaces run mesiodistally in the cervical third (Appendix 9a, facial surfaces).
2. The *prominent lingual cingula* seem to bulge and occupy about one third of the cervicoincisal length (Appendix 9a, lingual surfaces).
3. Usually, there are no depressions, mamelons, or perikymata on the labial surface of the crowns of the primary incisors. These *surfaces are smoother* than on their successors.

## C. ROOT TRAITS OF PRIMARY ANTERIOR TEETH

---

1. The roots of primary anterior teeth are *long* in proportion to crown length (Appendix 9f) and are relatively *narrow* mesiodistally (Appendix 9b).
2. The roots of primary anterior teeth *bend labially* in their apical one third to one half by as much as 10° (Appendix 9c).

## D. TRAITS OF ALL PRIMARY POSTERIOR TOOTH CROWNS

---

Now consider the unique traits of the primary posterior tooth crowns. Refer to Appendix page 10 while studying these traits.

1. The *prominent mesial cervical ridge* or bulge on the buccal surface is exaggerated by the curve of the cervical line apically (best seen when viewed from the buccal) and by the constriction near the cervical line (best viewed from the proximal, Appendix 10e). This

mesial cervical bulge makes it easy to distinguish rights from lefts.

2. Due to the taper of the crown from the cervical bulges toward the occlusal surface, the molar crowns have a *narrow occlusal table* (Appendix 10c). (Recall, the occlusal table is the chewing surface inside the line formed by the continuous mesial and distal cusp ridges for all cusps, and the mesial and distal marginal ridges).
3. As on permanent molars from the buccal view, all molar crowns are wide mesiodistally relative to their height cervico-occlusally (Appendix 10a).
4. The primary molar occlusal anatomy is shallow. In other words, the cusps are short (not pointed or sharp, almost flat) (Appendix 10d), occlusal ridges are not pronounced, and fossae and sulci are correspondingly not as deep as on secondary molars.
5. There are few grooves or depressions in the crowns.
6. In the primary dentition, primary second molars are decidedly larger than primary first molars. This is different in the permanent dentition where first molars are larger than seconds (Appendix page 10, compare firsts to seconds).
7. Microscopically, the enamel rods at the cervix slope occlusally, unlike in permanent teeth where these rods slope cervically.

## E. ROOT TRAITS OF PRIMARY POSTERIOR TEETH

---

1. The root furcations are near the crown, with little or no root trunk (Appendix 10f).
2. The roots are *thin and slender and spread out* beyond the outlines of the crown, more widely on primary second molars than the first molars (the opposite of the adult molars)<sup>7</sup> (Appendix 10g). This root divergence makes room for the developing succedaneous premolars. Extraction of a primary molar when roots are complete and before they have started to resorb may cause the developing portion of the premolar to be removed along with the primary molar.<sup>6</sup>
3. The roots of primary molars are similar to those of permanent molars in relative size (before resorption) and number. Primary maxillary molars have three roots: the palatal (longest), mesiobuccal, and distobuccal (shortest). Primary mandibular molars have two roots: the mesial (largest) and distal.



## SECTION IV

## CLASS AND TYPE TRAITS OF PRIMARY TEETH

## A. PRIMARY INCISOR TRAITS

## 1. PRIMARY INCISORS FROM THE LABIAL VIEW

## a. Outline Shape of Primary Incisor Crowns from the Labial View

The crowns of primary maxillary central incisors are the **ONLY** incisor crowns (primary or secondary) that are *wider mesiodistally* than they are long incisocervically (Appendix 9e). As on *permanent* maxillary central incisor crowns, the distoincisor angle of the incisal edge of the *primary* maxillary central incisor is more rounded than the mesioincisor angle, but the incisal edge is relatively straight.

The **maxillary lateral incisor** crowns are similar in shape to the central incisor, but are longer incisocervically than wide mesiodistally, and are less symmetrical. Distoincisor angles of lateral incisors are even more rounded. Note this difference between the shapes of primary maxillary incisors in *Figures 6-8* and *6-9*. Maxillary laterals are smaller than central incisors in the same dentition.

The crowns of the **mandibular incisors** resemble their replacement incisor crowns but are much smaller. As with permanent mandibular incisors, primary mandibular lateral incisor crowns are a little larger than the crowns of central incisors and less symmetrical (with more rounded distoincisor angles) than the central incisors of the same dentition (*Fig. 6-8*).

The relative locations of proximal contact areas on primary incisors are comparable to those of their successors.

## b. Surface Morphology of Primary Incisors from the Labial View

Labial surfaces of maxillary central incisors are smooth; usually, there are no depressions. Mandibular incisors are also relatively smooth (but may have very shallow depressions on their labial surfaces in the incisal third).

## c. Root-to-Crown Proportion of Primary Incisors from the Labial View

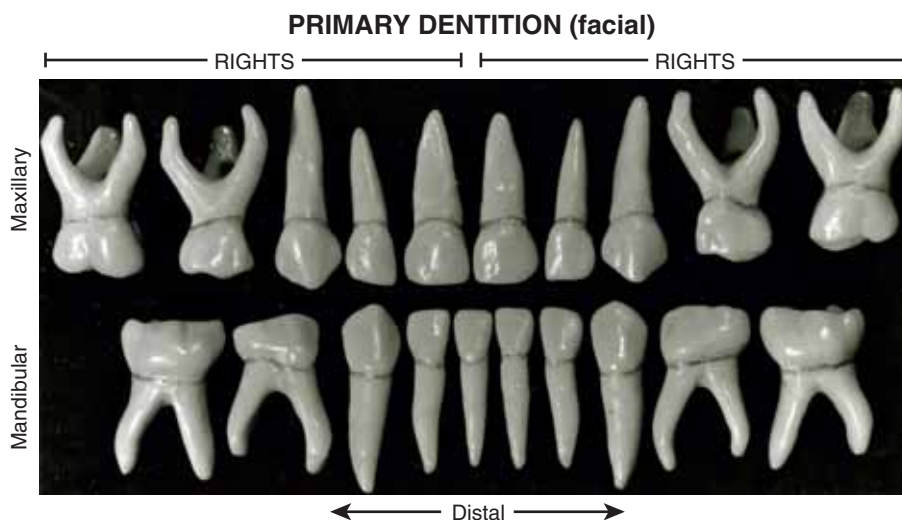
Prior to root resorption, *all* primary incisor roots are much longer relative to the crown length than on secondary incisors (Appendix 9f). Primary incisor roots are about twice the length of the crown. The roots of maxillary lateral incisors appear proportionally even longer. On primary extracted or shed teeth, there is usually some root resorption (evident in *Fig. 6-9B*). Often the entire root is gone.

## 2. PRIMARY INCISORS FROM THE LINGUAL VIEW

Refer to *Figure 6-10*.

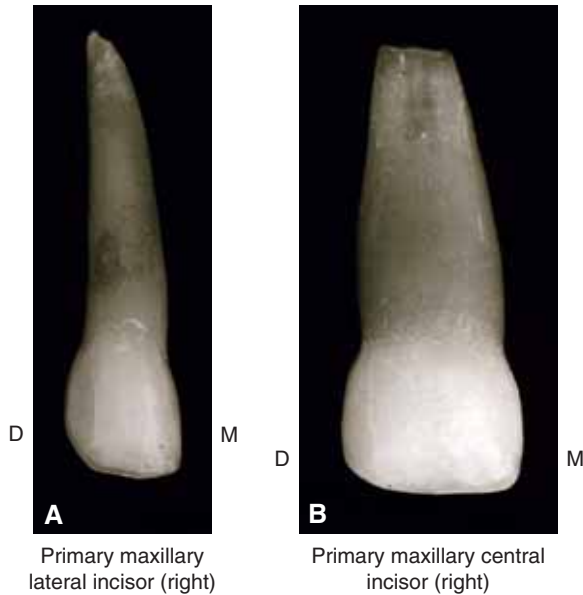
## a. Cingula of Primary Incisors from the Lingual View

The cingula of primary **maxillary central incisors** are often proportionally large, so that prominent lingual fossae are limited to only the incisal and middle thirds of the lingual surface. The lingual surfaces of **mandibular incisors** have a more subtle cingulum and a subtle lingual fossa.



**FIGURE 6-8.** Primary dentition, facial views.





**FIGURE 6-9.** Primary maxillary incisors. **A.** The maxillary right lateral incisor crown is less symmetrical and is longer (incisocervically) than it is wide. **B.** The maxillary right central incisor crown is wider (mesiodistally) than it is high (incisocervically). There has been some resorption of the root tips on both teeth (more so on the central incisor), but even so, the roots are twice as long as the crowns.

### b. Marginal Ridges of Primary Incisors from the Lingual View

On maxillary central incisors, marginal ridges are often distinct and prominent (like shovel-shaped incisors). On mandibular incisors, marginal ridges are more faint (Fig. 6-10).

### 3. PRIMARY INCISORS FROM THE PROXIMAL VIEWS (MESIAL AND DISTAL)

#### a. Crown Outlines of Primary Incisors from the Proximal Views

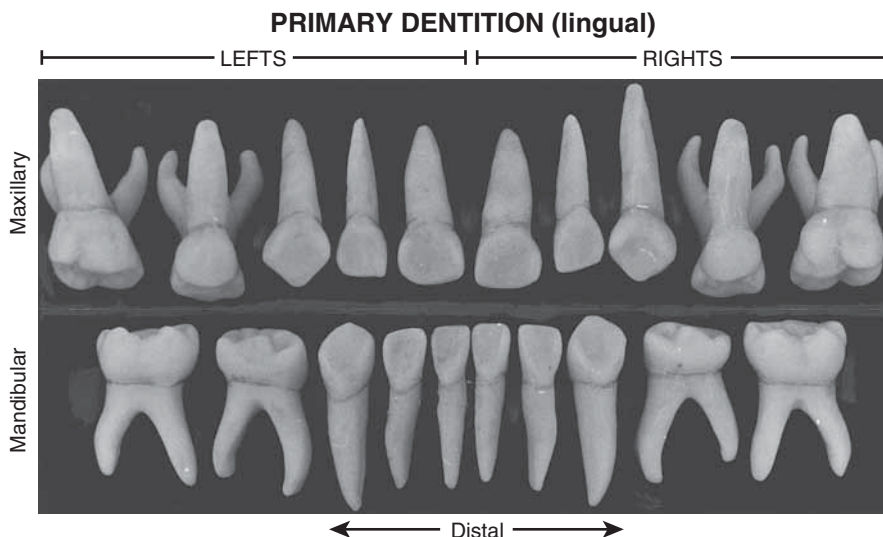
Although the faciolingual dimension of these crowns appears small from these aspects, crowns are wide labiolingually in their cervical one third because of prominent, convex labial cervical ridges and lingual cingula. Similar to their successors, incisal ridges of primary maxillary central incisors are located labial to the root axis line, whereas incisal ridges of mandibular incisors are located on the root axis line (Fig. 6-11).

#### b. Cervical Line of Primary Incisors from the Proximal Views

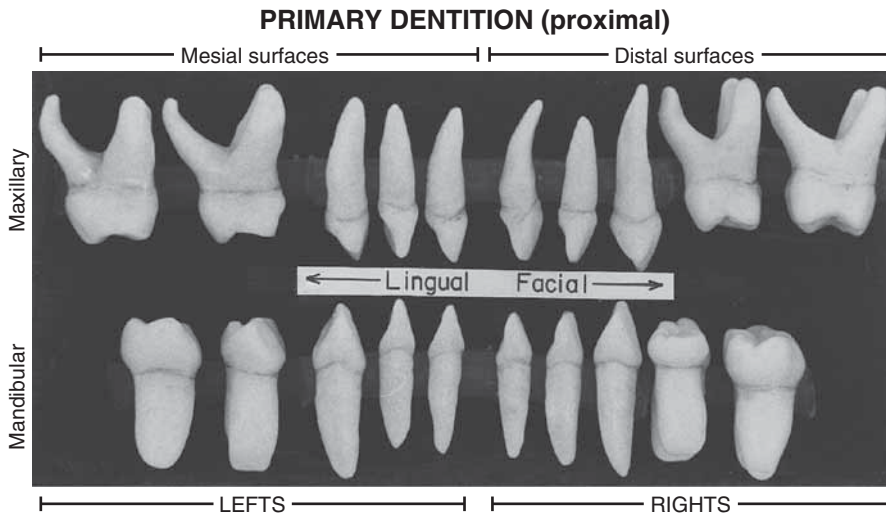
As on permanent incisors, the curve of the cervical line toward the incisal is greater on the mesial than on the distal. The cervical line is positioned more apically on the lingual than on the labial surface.

#### c. Root Shape of Primary Incisors from the Proximal Views

The roots of maxillary incisors are curved from this view, bending lingually in the cervical half (Appendix 9d) and labially by as much as  $10^\circ$  in the apical half (Appendix 9c).<sup>7</sup> Roots of the mandibular incisors, in contrast, are straight in their cervical half but then bend labially about  $10^\circ$  in their apical half (Appendix 9c).<sup>5</sup> This bend helps make space for the developing succedaneous incisors, which should be in a lingual and apical position.



**FIGURE 6-10.** Primary dentition, lingual views. Notice on maxillary molars that the lingual cusps are not as long as the mesiobuccal cusps.

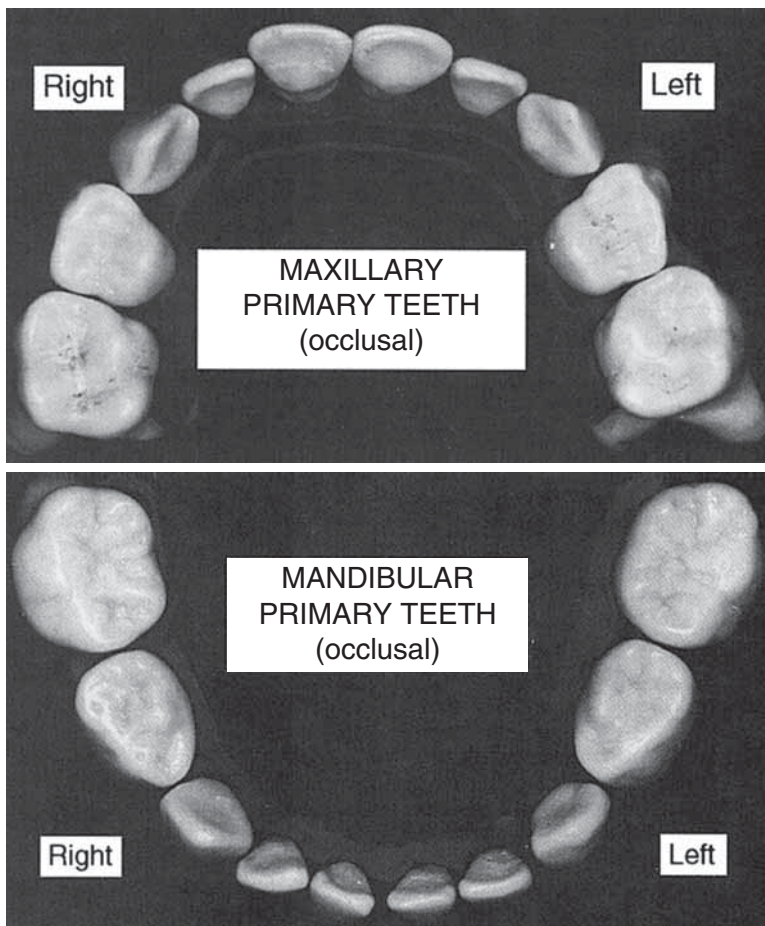


**FIGURE 6-11.** Primary dentition, proximal views. Notice on the molars that more of the occlusal surfaces are visible from the distal views than from the mesial views. Also notice that the apical third of roots of anterior teeth bend labially, especially on the maxillary dentition.

#### 4. PRIMARY INCISORS FROM THE INCISAL VIEW

Incisor crowns have a smoothly convex labial outline. The 1-mm thick incisal ridge is slightly curved mesiodistally. The crowns have lingual surfaces that taper narrower toward the lingual at the cingulum.

Crowns of primary maxillary central incisors are much wider mesiodistally than faciolingually compared to maxillary lateral incisors.<sup>F</sup> These proportions are evident in *Figure 6-12*. Both types of mandibular incisor crowns have mesiodistal and faciolingual dimensions that are almost the same.



**FIGURE 6-12.** Primary dentition, incisal and occlusal views. Notice the striking resemblance of the primary second molars to the secondary first (6-year) molars.

## B. PRIMARY CANINE TRAITS

### 1. PRIMARY CANINES FROM THE LABIAL VIEW

#### a. Outline Shape of Primary Canines from the Labial View

Maxillary canine crowns may be as wide as they are long. They are constricted at the cervix. They have convex mesial and distal outlines, with distal contours more rounded than mesial contours, which are somewhat angular (Fig. 6-13). Mandibular canine crowns, like permanent canines, are longer incisocervically than wide mesiodistally and are narrower mesiodistally than maxillary canine crowns (Appendix 9g).<sup>6</sup>

#### Cusp Ridge Outlines of Primary Canines from the Labial View:

Maxillary canine cusps are often very sharp (pointed) meeting at an acute angle. The cusp ridges of these maxillary canines are UNIQUE in that the *mesial cusp ridge is longer* than the distal cusp ridges (similar to only the permanent maxillary first premolars, but just the opposite of all other premolars and canines, permanent and primary) (Appendix 9h, maxillary canine, and Fig. 6-13B). The mesial cusp ridges are less steeply inclined<sup>8</sup> than the shorter distal ridges. Mandibular

canines have sharp cusp tips pointed like an arrow (Fig. 6-13A). As on permanent mandibular canines, the mesial cusp slope is shorter than the distal cusp slope (Appendix 9h, mandibular canine).

#### Contact Areas of Primary Canines from the Labial View:

Distal contact areas of primary canines rest against the mesial surfaces of primary first molars since there are no primary premolars. Mesial and distal contact areas of primary **maxillary canines** are near the center of the crown cervicoincisally, with the *mesial contact more cervically* located than the distal contact, a condition UNIQUE to this tooth and the permanent mandibular first premolar (Appendix 9i).

#### b. Cervical Lines of Primary Canines from the Labial View

Cervical lines on maxillary canines are nearly straight on the labial surface.

#### c. Roots of Primary Canines from the Labial View

Maxillary canine roots prior to resorption are the longest of the primary teeth tapering to a blunt apex. The roots of **mandibular canines** are more tapered and pointed, and shorter than maxillary canine roots.<sup>H</sup>

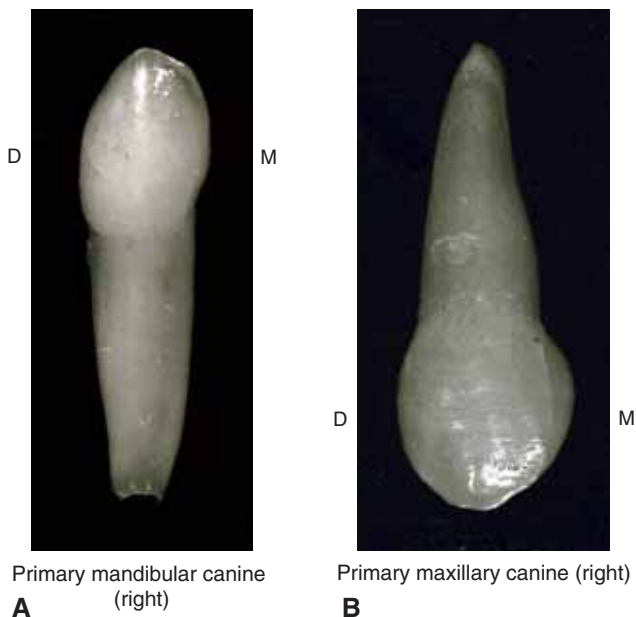
### 2. PRIMARY CANINES FROM THE LINGUAL VIEW

The cingulum on a **maxillary canine** crown is bulky, and the mesial and distal marginal ridges are well developed but not as prominent as on permanent canines (Fig. 6-10). The maxillary canine crown has a lingual ridge that divides a mesial fossa from the distal fossa. Distal fossae on these teeth are narrower and deeper than mesial fossae, which are broader and shallower.<sup>7,8</sup> In contrast, lingual ridges are barely discernible on **mandibular canines**, with faint marginal ridges and usually a single concavity or fossa (Fig. 6-10).<sup>6</sup>

### 3. PRIMARY CANINES FROM THE PROXIMAL (MESIAL AND DISTAL) VIEWS

#### a. Outline of Primary Canines from the Proximal Views

Labial cervical ridges are prominent on *both* maxillary and mandibular canines, bulging similar to lingual cingula, so the cervical third of a primary canine is much thicker than on an incisor. The S-shaped lingual crown outline of maxillary canines is more concave than on permanent canines. On *maxillary* canines, cusp tips are positioned considerably labial to the root axis line



**FIGURE 6-13.** Primary canines, labial views. **A.** Primary mandibular right canine. The root tip has begun to resorb. **B.** Primary maxillary right canine. Notice the UNIQUE traits: the longer mesial cusp ridge and the more cervically positioned mesial contact area. The distal contour is more rounded compared to the more angular mesial contour.

(Fig. 6-11), whereas the cusp tip of *mandibular* canines is most often located slightly lingual to the root axis line.

#### b. Cervical Lines of Primary Canines from the Proximal Views

Cervical lines of *both* maxillary and mandibular canines curve incisally more on the mesial side than on the distal side, just like all other anterior teeth. As on primary incisors, the cervical lines are positioned more apical on the lingual than on the labial.

#### c. Roots of Primary Canines from the Proximal Views

The roots of *both* maxillary and mandibular canines are bulky in the cervical and middle thirds, tapering mostly in the apical third where the apex is bent labially (Appendix 9c and Fig. 6-11).

### 4. PRIMARY CANINES FROM THE INCISAL VIEW

#### a. Crown Outline of Primary Canines from the Incisal View

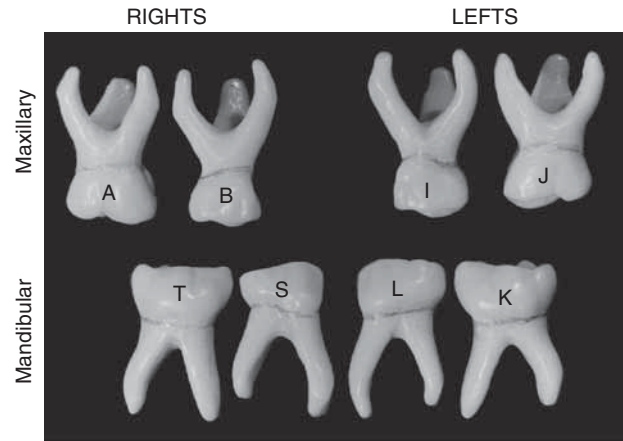
The crown outline of **maxillary canines** tapers noticeably toward the cingulum, which is centered mesiodistally. The distal half of the crown is thinner faciolingually than the mesial half (similar to secondary maxillary canines). From the incisal aspect, **mandibular canine** crowns have a *diamond shape* and are nearly symmetrical, except for the mesial position of the cusp tips, and a slightly bulkier distal half (Fig. 6-12). Cingula are centered or just distal to the center.

#### b. Crown Proportions and Size of Primary Canines from the Incisal View

Primary **maxillary canine** crowns are broader faciolingually than incisor crowns and are considerably wider mesiodistally than faciolingually.<sup>1</sup> The 1.5-mm thick mesial and distal cusp ridges curve toward the lingual at both ends. **Mandibular canine** crowns are only slightly wider mesiodistally than faciolingually.<sup>1</sup> The smallness of these teeth compared to the permanent canines is quite noticeable.

### C. PRIMARY MOLAR TRAITS

As stated earlier, primary molar roots are thin and widely spread to make room for the developing premolar crowns that are forming beneath them (Fig. 6-14). Recall that *primary first molars* are located over the crowns of developing *first premolars* and erupt just distal to primary canines and just mesial to primary second molars. *Primary second molars* form over the crowns



**FIGURE 6-14.** All eight primary molars, buccal views. Each tooth is identified with its Universal letter.

of developing *second premolars*, just distal to primary first molars and, after age 6, just mesial to 6-year first molars. It could be said that these primary molars are saving a place in the arch for the teeth that will succeed them, namely, the first and second premolars, respectively. Both maxillary and mandibular primary second molars are *considerably* wider than the second *premolars* that will replace them.<sup>JK</sup>

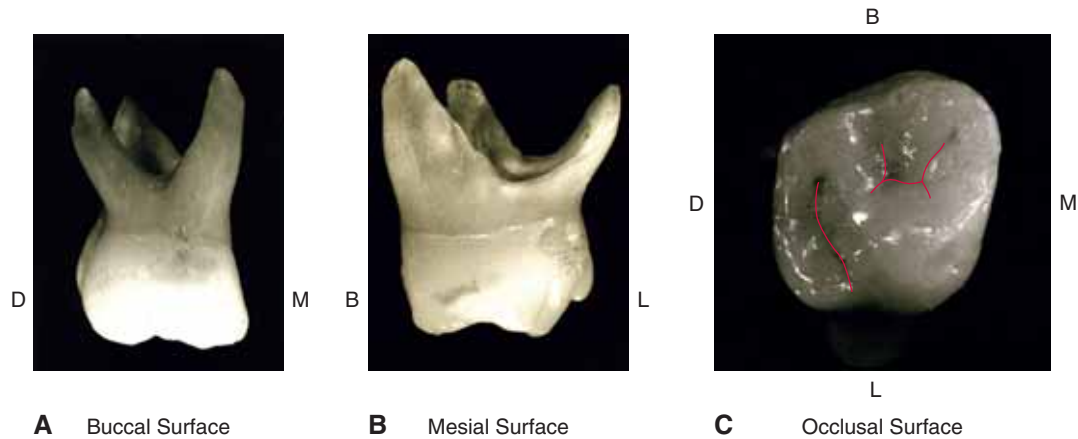
When distinguishing maxillary from mandibular primary molars, consider **arch traits** such as the number of roots. Primary maxillary molars normally have three roots (mesiobuccal, distobuccal, and palatal, as on permanent maxillary molars), whereas primary mandibular molars have only two roots (mesial and distal, as on permanent mandibular molars). Also, like permanent molars, maxillary primary molars tend to be wider buccolingually than mesiodistally, whereas mandibular molars tend to be wider mesiodistally than buccolingually. Compare the occlusal outlines of primary molars in the Appendix on page 10.

Each type of primary molar will be discussed in detail at this time, emphasizing the traits that further differentiate each type. Discussion begins with primary second molars since they are so similar to the permanent first molars discussed previously in Chapter 5.

#### 1. TYPE TRAITS OF PRIMARY SECOND MOLARS

*Both* maxillary and mandibular *primary second molars* resemble the *permanent first molars* that erupt just distal to them, with cusp ridges and fossae corresponding to those of permanent first molars. *Maxillary* primary second molars may even have a cusp of Carabelli (Fig. 6-15B and C).



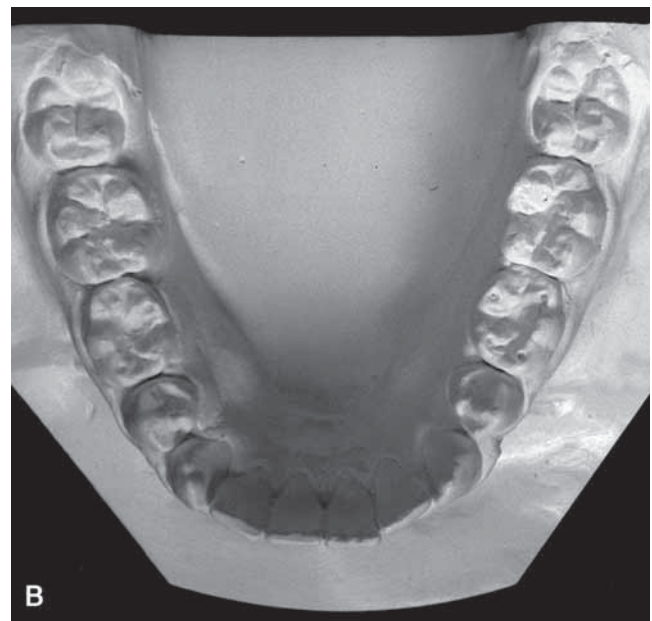
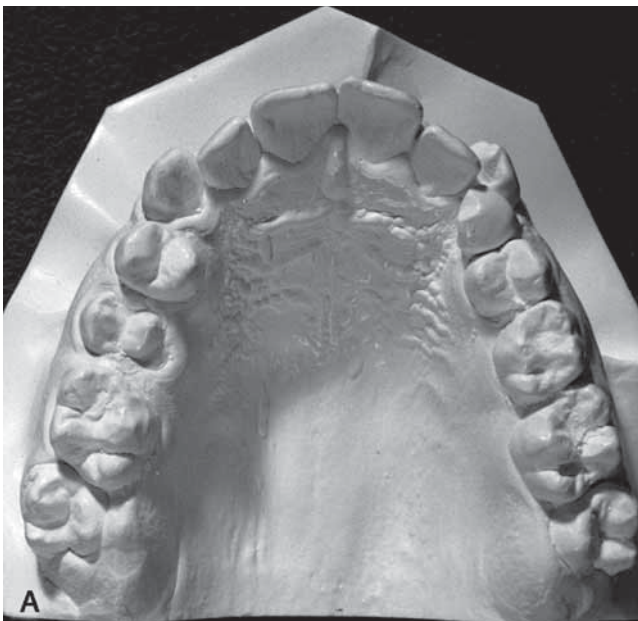


**FIGURE 6-15.** Primary maxillary right second molar. **A.** Buccal surface. **B.** Mesial surface. Notice the spread of the roots.

The crown of the maxillary second premolar develops in the space bounded by these roots. Some root resorption has occurred (especially on the lingual root). **C.** Occlusal surface. From this aspect, the primary maxillary second molar resembles a miniature 6-year first molar (even with a Carabelli cusp).

Since these teeth are adjacent to one another during the time of mixed dentition, it is important to distinguish between a primary second molar and the permanent 6-year first molar that erupts just distal to it. First, consider the tooth position from the midline as

an important clue for tooth identification. *If* there are no missing teeth, the primary second molar is the fifth tooth from the midline, and the permanent first molar is the sixth tooth from the midline. Also, a primary second molar is smaller in all dimensions than the 6-year



**FIGURE 6-16.** Mixed dentition. **A.** In the maxillary arch, the fifth tooth from the midline on the left side of the photograph is a second premolar. On the right side, a retained primary canine is still present and the permanent canine has erupted quite labial to the arch, but if you consider that the third position from the midline is reserved for the permanent canine, then the fifth tooth on the right side is a primary second molar. Notice the similarity of the primary second molar with the larger 6-year molar just distal to it. Also notice the position of the secondary maxillary canine, which is normally the last succedaneous tooth to erupt (positioned just labial to the primary canine, which is still present). **B.** In the mandibular arch, the fifth tooth from the midline on both the right and left sides is a primary second molar. Notice the similarity in morphology with the larger 6-year molar just distal to it (sixth from the midline). (Models courtesy of Dr. Brad Woodford, Ohio State University.)



first molar found just distal to it.<sup>LM</sup> The differences in size and position between primary maxillary second molars and permanent maxillary first molars are evident in *Figures 6-16 and 6-17*.

Another obvious difference between a primary and permanent molar crown is that primary molars have a much more prominent *mesiobuccal cervical ridge* and *constricted crown cervix* compared to permanent molars. Due to the prominent mesiobuccal cervical ridge and considerable taper toward the occlusal, *both* maxillary and mandibular primary second molars have small occlusal tables (best viewed from the proximal in *Fig. 6-18* and Appendix 10c and e).<sup>5</sup> The cervical lines are almost flat on both the mesial and distal sides of the tooth, but slope cervically toward the facial due to the prominent mesial cervical ridge. When viewed occlusally, this prominent

ridge also accentuates the considerable taper narrowing from mesial to distal (seen in the Appendix page 10, occlusal view).

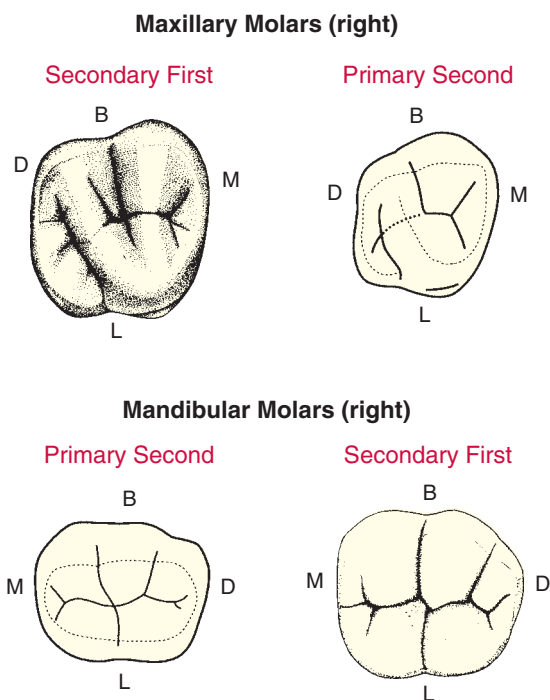
### a. Unique traits of Primary Mandibular Second Molars

As on permanent mandibular first molars, **primary mandibular second molars** have five cusps: three buccal (mesiobuccal, distobuccal, and distal) separated by mesiobuccal and distobuccal grooves. However, the three buccal cusps of the primary mandibular second molars are of nearly equal size (Appendix 10j) with the middle buccal cusp (called the distobuccal) slightly larger. The two lingual cusps (mesiolingual and distolingual) are separated by a lingual groove. These lingual cusps are about the same size and height but slightly shorter than the buccal cusps.<sup>7</sup> From the proximal views, the mesial marginal ridge of a primary mandibular second molar is high and is crossed by a groove that may extend about one third of the way down the mesial surface.<sup>9</sup> The contact area with the primary first molar is located just below the notch of the marginal ridge.<sup>9</sup> Since the crown is shorter on the distal side and the distal marginal ridge is lower (more cervical) than the mesial marginal ridge, all five cusps may be seen from the distal aspect. The distal contact with the mesial side of the 6-year first molar is located just buccal and cervical to the distal marginal groove (furrow) (*Fig. 6-19B*).<sup>9</sup>

**Mandibular second molar** roots are about twice as long as the crowns and are thin mesiodistally. The mesial root is broad and flat with a blunt apex and has a shallow longitudinal depression. The distal root is broad and flat but is narrower and less blunt at the apex than the mesial root.

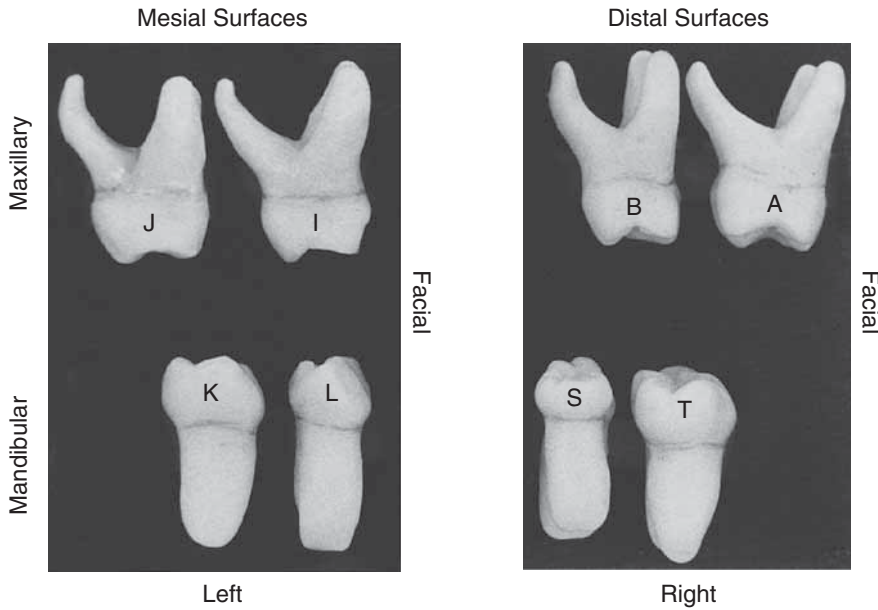
### b. Unique Traits on Primary Maxillary Second Molars

As on permanent maxillary first molars, **primary maxillary second molar** have four major cusps and sometimes a cusp of Carabelli. The distolingual cusp is the smallest (unless there is a cusp of Carabelli), but the mesiobuccal cusp may be almost equal in size to the mesiolingual cusp, or even slightly larger (Appendix 10i) compared to the permanent maxillary first molar where the mesiolingual cusp is largest. Also, from the occlusal view, crowns of primary maxillary second molars taper narrower toward the lingual, especially due to the pronounced taper of the mesial surface, which displaces the mesiolingual cusp more distally than on the permanent first molars (Appendix 10h). This also results in an oblique ridge that is straighter in its course buccolingually<sup>7</sup> and a smaller, oblong distal fossa buccolingually (*Fig. 6-15C*).

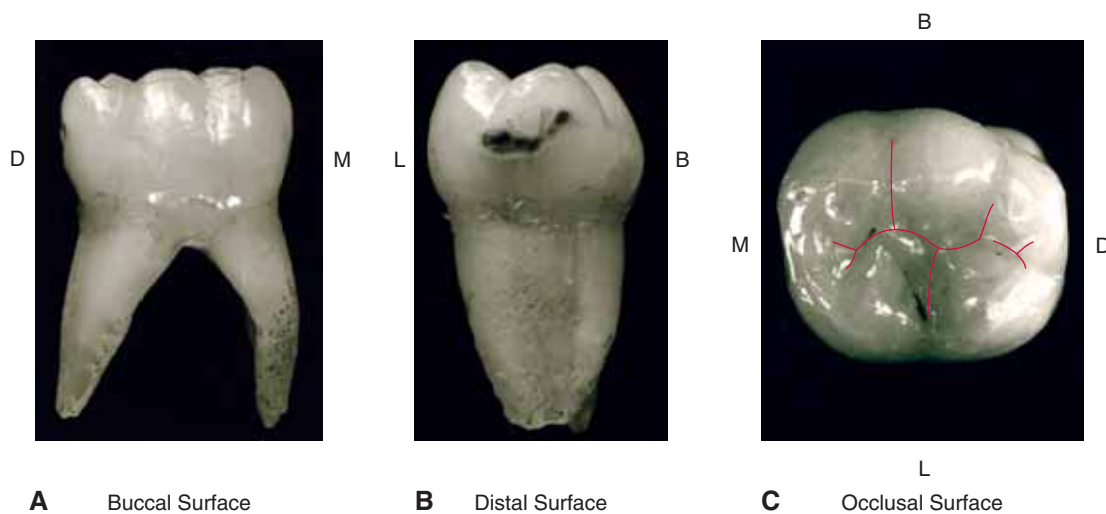


**FIGURE 6-17.** Comparison of occlusal morphology of primary second molars compared to permanent first molars.

The permanent first molars are located just distal to the primary second molars from about age 6 through 11 or 12 years old. **Top:** The *permanent* maxillary first molar is larger but otherwise similar to the *primary* maxillary second molar in overall shape, number of cusps (maybe even a cusp of Carabelli), grooves, ridges (including oblique), and fossae. **Bottom:** The *permanent* mandibular first molar is larger but otherwise similar to the *primary* mandibular second molar in overall shape, number of cusps, grooves, ridges, and fossae. The three buccal cusps, however, are more equal in size on the primary mandibular molar, whereas the distal cusp on the secondary first molar is obviously the smallest.



**FIGURE 6-18.** Proximal views of all eight primary molars. Each tooth is identified with its Universal letter. Notice on mesial views that the wider mesiobuccal root of the maxillary molars hides the narrower distobuccal root, just as in adult maxillary molars.



**FIGURE 6-19.** Primary mandibular second molar (right). **A.** Buccal surface. The short root trunk and the widespread roots, as well as the small size, distinguish this tooth from the secondary mandibular first molar. The mesiobuccal, distobuccal, and distal cusps are often about the same size. **B.** Distal surface. **C.** Occlusal surface.

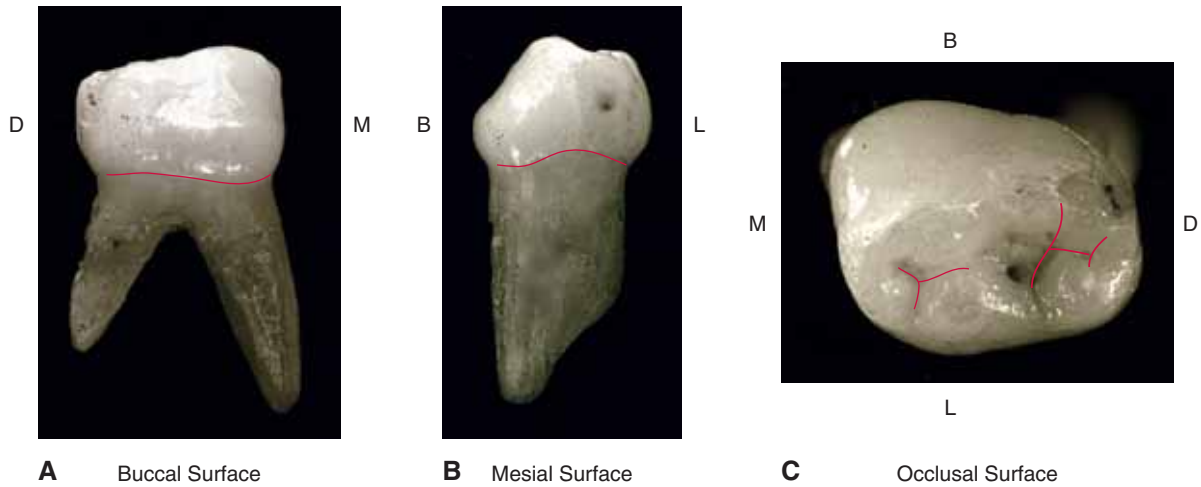
The three roots of the **primary maxillary second molar** (mesiobuccal, distobuccal, and palatal) and the two roots of the primary mandibular second molar (mesial and distal) are thin and slender and widely spread apart, with the root furcation very close to the cervical line, so there is very little root trunk.

## 2. TYPE TRAITS OF PRIMARY FIRST MOLARS

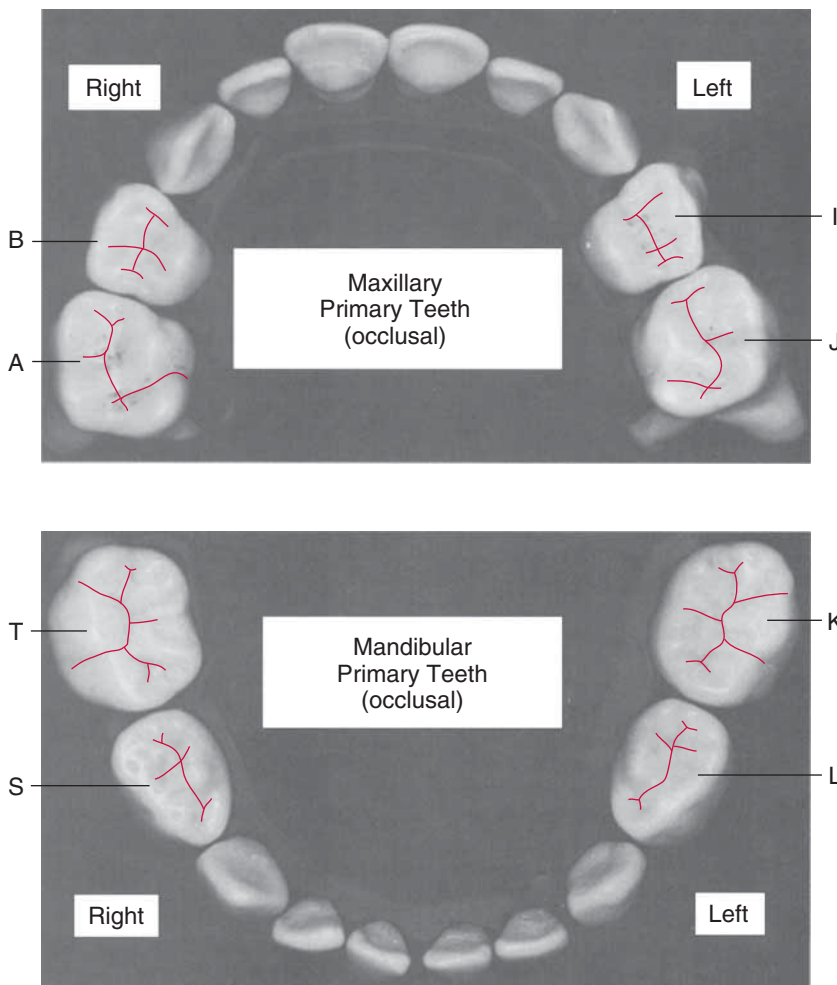
Although the shapes of the primary maxillary and mandibular first molars are quite different, there are a few similarities that apply to all primary first molars. From the facial (or lingual) view, the crowns

of *all primary first molars* (maxillary and mandibular) are wider mesiodistally than high cervico-occlusally<sup>N</sup> (Fig. 6-20A), and their crowns are slightly wider than the first premolars that will replace them.<sup>OP</sup> Facially, their crowns are longer occlusocervically in the mesial half than in the distal half due, in part, to the wide mesiobuccal cervical ridge, and in part due to the shorter distobuccal cusps compared to the longer mesiobuccal cusps (Appendix 10 c,e buccal views).

From the occlusal view, crowns of *all primary first molars* are narrower in the lingual half than in the buccal half (Fig. 6.21) due primarily to the taper of the mesial



**FIGURE 6-20.** Primary mandibular first molar (right). **A.** Buccal surface. The distal root has been considerably shortened by resorption. Notice that the crown is longer occlusocervically on the mesial half (right side) than the distal half. **B.** Mesial surface. The buccal cervical ridge is very prominent. Notice the very narrow occlusal surface and how the crown appears to tilt lingually. If the root apex was not partially resorbed, the root would appear to taper to a more blunt end. **C.** Occlusal surface. The mesiobuccal cervical ridge is conspicuous.



**FIGURE 6-21.** Complete primary dentition, occlusal and incisal views. Notice the groove patterns and outlines of the primary molars from this view.

surface, which does not run straight toward the lingual but rather runs obliquely in a distolingual direction (Appendix 10s). Subsequently, the mesiobuccal angle is acute. This taper is similar to that on the mesiolingual taper in the primary maxillary second molar (Appendix 10n). The distal surface does not taper.<sup>3</sup> Primary first molars are also much wider buccolingually in their mesial half because of the *very* prominent mesial buccal cervical ridge. From the mesial view, this prominent ridge causes the cervical line to slope apically toward the facial (Fig. 6-20B).

Unique traits that differentiate primary maxillary and mandibular first molars are presented next.

### a. Unique Traits of Primary Maxillary First Molars

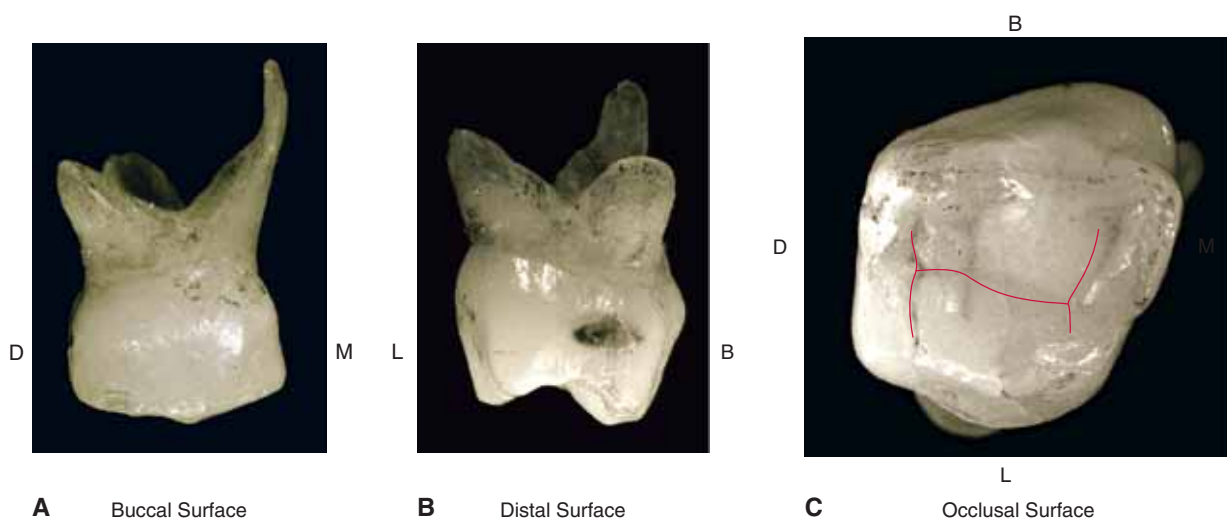
**Primary maxillary first molar crowns** are quite unique in appearance (Fig. 6-22). According to one author, they do not resemble any other molars.<sup>10</sup> According to another author, from the occlusal view, they resemble maxillary first premolars that replace them (Fig. 6-22C).<sup>9</sup>

**Cusp size and shape on primary maxillary first molars:** Primary maxillary first molars usually have four cusps, but they appear *similar to maxillary premolars* from the occlusal view since they have only *two prominent cusps*, a wide mesiobuccal cusp and a narrower, slightly more distinct, mesiolingual cusp. The mesiobuccal cusp is the longest (but second sharpest) cusp.<sup>7</sup> The mesiolingual cusp is the second longest, but

sharpest, cusp. The other two cusps, the distobuccal and distolingual, are relatively small and indistinct and may blend into the distal marginal ridge. Sometimes, as in permanent maxillary second molars, the distolingual cusp is absent (three-cusp type), but when it is present (four-cusp type), it is inconspicuous and may appear as a small nodule on the lingual half of the distal marginal ridge.

**Occlusal outline of primary maxillary first molars:** As on all maxillary molars, primary and permanent (and on premolars), the occlusal outline is wider faciolingually than mesiodistally.<sup>9</sup> Although the mesial surface tapers obliquely toward the lingual, the distal surface and marginal ridge run in a straight direction buccolingually, joining both the buccal and lingual borders at right angles<sup>6</sup> (best seen in Fig. 6-22, occlusal view).

**Fossae, ridges, and grooves on primary maxillary first molars:** There are three fossae on these primary maxillary first molars: a large and deep mesial triangular fossa, a medium-sized central fossa, and a minute distal triangular fossa, each with a pit: central, mesial, and distal, respectively (Appendix 10o). The occlusal grooves of the four-cusp type primary maxillary first molars usually form an “H” pattern (seen in Fig. 6-22). The crossbar of the “H” is the central groove that connects the central and mesial triangular fossae. (Some textbooks say there is no central groove and that the crossbar is made up of a mesial and distal groove instead.<sup>9</sup>) Grooves running buccolingually just inside of the mesial marginal ridge form the mesial side of the



**FIGURE 6-22.** Primary maxillary first molar (right). **A.** Buccal surface. The mesiobuccal root is less resorbed than the distobuccal and lingual roots. The lingual root is barely discernible. **B.** Distal surface. **C.** Occlusal surface. The prominent cervical ridge below the mesiobuccal cusp gives the tooth an angular appearance. Notice the “H”-shaped groove pattern, somewhat resembling the occlusal view of a maxillary premolar.



“H,” and the buccal groove (dividing the buccal cusps) combined with the distolingual groove (between the large mesiolingual and minute distolingual cusps) forms the distal side of the “H.” The buccal groove between the large mesiobuccal cusp and the indistinct distobuccal cusp is just a slight notch and does not extend onto the buccal surface (Appendix 10l). A groove between the two lingual cusps is present only when the distolingual cusp is definite.

**Roots of primary maxillary first molars:** The three roots (mesiobuccal, distobuccal, and palatal) of the primary maxillary first molar are thin and slender and widely spread apart, with the root furcation very close to the cervical line, so there is very little root trunk (Appendix 10f).

### b. Unique Traits of Primary Mandibular First Molars

**Primary mandibular first molars** do not resemble any other primary or secondary tooth (Fig. 6-21, teeth L and S, and Fig. 6-20). According to one author, the chief differentiating characteristic may be an *overdeveloped mesial marginal ridge* (Appendix 10q).<sup>9</sup>

**Cusp size and shape on primary mandibular first molars:** The primary mandibular first molar has four cusps. The cusps are often difficult to distinguish, but careful examination of an unworn tooth will reveal (in order of diminishing size) a mesiobuccal, mesiolingual, distobuccal, and the smallest (also shortest) distolingual cusp. The *mesiobuccal cusp* of the mandibular first molar is always the largest and longest cusp, occupying nearly two thirds of the buccal surface (Appendix 10t; Fig. 6-20A). This cusp is characteristically compressed buccolingually, and its two long cusp ridges extend mesially and distally, serving as a blade when occluding with the maxillary canine.<sup>7</sup> The mesiolingual cusp is larger, longer, and sharper than the distolingual cusp.

**Ridges, grooves, and fossae of primary mandibular first molars:** The mesial marginal ridge is so well developed that it resembles a cusp.<sup>3</sup> This longer, prominent mesial marginal ridge is positioned more occlusally than the short, less prominent distal marginal ridge. (Compare mesial and distal views in Fig. 6-18 for marginal ridge heights and lengths.) There is also a *prominent transverse ridge* between the mesiobuccal and mesiolingual cusps (Appendix 10u and Fig. 6-21, teeth L and S).

A central groove separates the mesiobuccal and mesiolingual cusps and connects with a shallow mesial marginal ridge groove. A short buccal depression (not really a distinct groove) separates the larger mesiobuccal cusp from the smaller distobuccal cusp but does not

extend onto the buccal surface. There is also a slight groove between these two lingual cusps that becomes a shallow depression on the lingual surface ending near the cervix. Both marginal ridges have shallow grooves between them and cusp ridges of lingual cusps<sup>8</sup> similar to the grooves in the triangular fossae of other posterior teeth.

Since the distal half of the occlusal table is wider than the mesial half, the distal fossa is larger, extending almost into the center of the occlusal surfaces (Appendix 10v). It has a central pit and a small distal pit near the distal marginal ridge. The small mesial triangular fossa has a mesial pit. There is no central fossa (Fig. 6-20).

**Proximal view contours and contacts:** From the proximal views, the buccal crown contour is nearly (but not quite) flat from the buccal crest of curvature to the occlusal surface and cervico-occlusally. The lingual surface is more convex cervico-occlusally. There is a slight curve of the mesial cervical line. On the distal or lingual surface, the cervical line is practically flat or horizontal.

**Occlusal outline of primary mandibular first molars:** From the occlusal view, the entire *occlusal outline* is somewhat oval or rectangular and wider mesiodistally than faciolingually as seen in Figs. 6-20 and 6-21C. Also, the *occlusal table* is wider mesiodistally than faciolingually (Appendix 10r).<sup>9</sup> The entire *tooth outline* from the occlusal view appears to be wider faciolingually in the mesial half due to the prominent mesial cervical ridge, but the *occlusal table* width is wider faciolingually in the distal half (Appendix 10v). The tapered mesial crown contour is nearly flat buccolingually, whereas the distal surface is convex; the lingual surface is convex mesiodistally.

**Accentuated lingual tilt of the mandibular first molar:** Recall that the crowns of all mandibular posterior teeth, primary and secondary, appear to tilt lingually, even more so on mandibular primary teeth. This primary mandibular first molar crown appears to lean decidedly toward the lingual accentuated by the very prominent mesiobuccal cervical ridge, placing the buccal cusp tips well over the root base.<sup>8</sup> The lingual cusp tip may even be outside the lingual margin of the root (Fig. 6-20B).

**Roots of primary mandibular first molars:** The two roots (mesial and distal) are thin and slender and widely spread apart, with the root furcation very close to the cervical line, so there is very little root trunk (Appendix 10f). The mesial root is wider (square and flat) and longer than the distal root. The distal root is more rounded, less broad, thinner, and shorter than the mesial root.



## SECTION V

## PULP CAVITIES OF PRIMARY TEETH

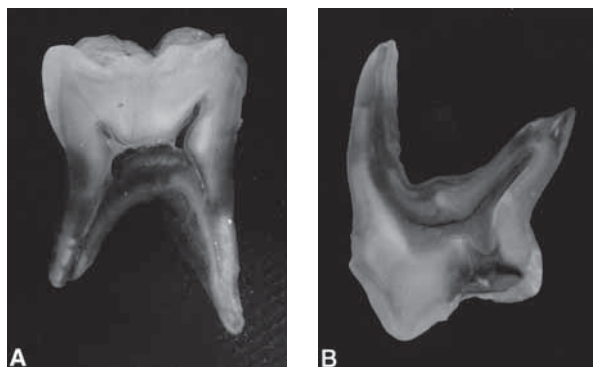Primary *anterior teeth* have pulp cavities that are similar in shape to the pulp cavities of the secondary teeth but are relatively much larger than in permanent molars due to the thinner, more uniform enamel covering, and the thinner dentin in the primary teeth. On anterior primary teeth, there are slight projections on the incisal border corresponding to the lobes, but there is usually no demarcation or constriction between the single canal and the pulp chamber except on the mandibular central incisor.<sup>9</sup>

Primary *molar teeth*, when compared with secondary molars, have little or almost no root trunk, so the pulp chambers are mostly in the tooth crown (Fig. 6-23A). Compare this to secondary molars, where much of the pulp chamber is located in the root trunk. The pulp chambers of primary molars have long and often very narrow pulp horns extending beneath the cusps. The mesiobuccal pulp horn (and cusp) of the primary maxillary second molar is the longest in that tooth, compared to the mesiolingual horn (and cusp)

in the permanent maxillary first molar. Great care must be taken when preparing primary teeth for restorations to avoid cutting into (exposing) the pulp horns during cavity preparation (Fig. 6-23B).

## LEARNING EXERCISE

If you are fortunate to have a collection of primary teeth, study the morphology for variations. Observe differences in the amount of root resorption, examine the occlusal surface for wear facets due to attrition, and evaluate the interior pulp chamber (after sectioning) for size, pulp horns, and thickness of enamel and dentin. Use the distinguishing characteristics in *Tables 6-5* and *6-6* to identify each tooth within your collection of primary teeth. If you do not have any teeth to study, try to recognize these traits as seen in the figures in this chapter.



**FIGURE 6-23.** Cross section of primary molars. **A.** Primary mandibular right second molar, cross section (buccal side ground off to expose pulp cavity). An interesting feature is the long narrow shape of the pulp horns, which often extend more into the crown, even higher or closer to the occlusal surface than seen in this cross section. **B.** Primary maxillary first molar, cross section (mesial side removed). The root canals of the mesiobuccal root and the lingual root (right side of picture) are exposed. An extensive area of decay beneath the enamel of the lingual cusp has reached the prominent pulp horn. Notice the thin enamel.

**Table 6-5** ARCH TRAITS THAT DISTINGUISH PRIMARY MAXILLARY FROM MANDIBULAR TEETH

## MAXILLARY CENTRAL INCISOR

Short, wide, symmetrical crown  
Root bends facially in apical one third  
Root long and bulky  
Large, elevated cingulum

## MAXILLARY LATERAL INCISOR

Crown narrow and oblong  
Root bends facially in apical one third

## MAXILLARY CANINE

Wide crown mesiodistally  
Cusp tip sharp and centered

## MANDIBULAR CENTRAL INCISOR

Long, narrow, symmetrical, very small  
Root straighter but still bends facially in apical one half  
Root long and thin  
Smaller, less prominent cingulum

## MANDIBULAR LATERAL INCISOR

Smaller cingulum  
Root bends facially in apical one half

## MANDIBULAR CANINE

Crown longer, narrower, less symmetrical  
Cusp tip toward mesial

(continued)

Table 6-5

**ARCH TRAITS THAT DISTINGUISH PRIMARY MAXILLARY FROM MANDIBULAR TEETH (Continued)**

<b>MAXILLARY CANINE</b>	<b>MANDIBULAR CANINE</b>
Mesial cusp ridge longer, steeper than distal	Mesial cusp ridge shorter than distal
Cingulum centered	Cingulum distally located
Mesial contact more cervical than distal	Distal contact more cervical than mesial
Root bends facially in apical one third	Root with less facial bend in apical one half
<b>MAXILLARY FIRST MOLAR</b>	<b>MANDIBULAR FIRST MOLAR</b>
3 roots (if intact): mesiobuccal (MB), distobuccal (DB), and lingual	2 roots (if intact): mesial and distal
3–4 cusps: MB largest, DB, mesiolingual (ML), and distolingual (DL) may be absent	4 cusps: MB, DB, ML, and DL
Crown wider faciolingually than mesiodistally; tapers to lingual	Crown much wider mesiodistally than faciolingually
Crown wider faciolingually on mesial than distal; tapers to distal	Occlusal table has small mesial triangular fossa; large distal fossa
H-shaped occlusal grooves	Well-developed mesial marginal ridge and strong transverse ridge
Unique crown shape (or premolar-like)	Unique crown shape (like no other)
<b>MAXILLARY SECOND MOLAR</b>	<b>MANDIBULAR SECOND MOLAR</b>
3 roots (if intact): MB, DB, and lingual	2 roots (if intact): mesial and distal
Crown resembles small permanent maxillary first molar	Crown resembles small permanent mandibular first molar

Table 6-6

**HOW TO TELL RIGHT FROM LEFT PRIMARY TEETH**

<b>MAXILLARY CENTRAL INCISOR</b>	<b>MANDIBULAR CENTRAL INCISOR</b>
90° mesioincisal angle	Difficult to discern
Distal contact more cervical than mesial	
Distoincisal angle more rounded	
Crown outline flatter on mesial	
More cervical line curvature on mesial	
<b>MAXILLARY LATERAL INCISOR</b>	<b>MANDIBULAR LATERAL INCISOR</b>
Flat mesial and rounded distal outline	More rounded distoincisal angle and distal crown bulge
Distal contact more cervical than mesial	Distal contact more cervical than mesial
More rounded distoincisal angle	More rounded distoincisal angle
More cervical line curvature on mesial	
<b>MAXILLARY CANINE</b>	<b>MANDIBULAR CANINE</b>
Longer mesial cusp ridge	Shorter mesial cusp ridge
Deeper and narrower distal than mesial fossa	
Mesial contact more cervical than distal	Distal contact more cervical than mesial
Flat mesial crown outline	
More cervical line curvature on mesial	More cervical line curvature on mesial
<b>MAXILLARY FIRST MOLAR</b>	<b>MANDIBULAR FIRST MOLAR</b>
Crown longer on mesial than distal (facial)	Crown longer on mesial than distal (facial)
Crown wider (faciolingually) on mesial than distal	Occlusal table has small mesial triangular fossa; large distal fossa
Mesial cervical crown bulge	Mesial cervical crown bulge
Distal marginal ridge more cervical than mesial	Distal marginal ridge more cervical than mesial
Distobuccal root (if intact) is smallest; shortest	Mesial root (if intact) longer and wider (faciolingually)
Mesiobuccal cusp is longest	Mesiobuccal cusp largest and longest

(continued)

**Table 6-6** HOW TO TELL RIGHT FROM LEFT PRIMARY TEETH (Continued)**MAXILLARY SECOND MOLAR**

Mesial cervical crown bulge  
 Crown longer on mesial than distal (facial view)  
 Large mesiolingual cusp vs. distolingual  
 Distal marginal ridge more cervical than mesial  
 Distobuccal root shortest and smallest

**MANDIBULAR SECOND MOLAR**

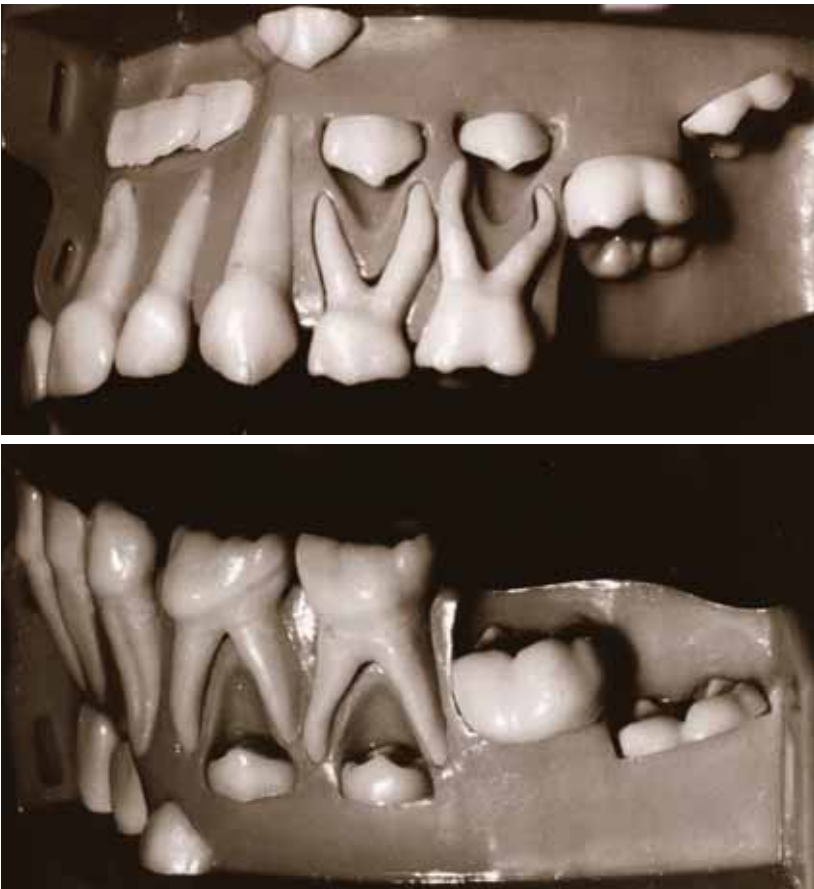
Mesial cervical crown bulge  
 Crown longer on mesial than distal (facial view)  
 Has fifth (distal) cusp  
 Distal marginal ridge more cervical than mesial  
 Mesial root (if intact) longer and wider (faciolingually)

**LEARNING EXERCISES: CASE STUDIES**

In the four cases that follow, first identify each tooth in a mixed dentition and then estimate the “expected dental age” based on average eruption dates as follows: If you have learned the important range of dates for tooth eruption and the sequence of eruption within those ranges, you should be able to estimate the “expected dental age” of a child based on what teeth are present in the mouth.

**Learning Exercise: Case Studies, cont.**

**CASE 1:** Look at *Figure 6-24* and estimate the dental age of the child based on the teeth visible in the mouth and those developing within the bone but have not yet erupted. Then compare your rationale to the answer here.



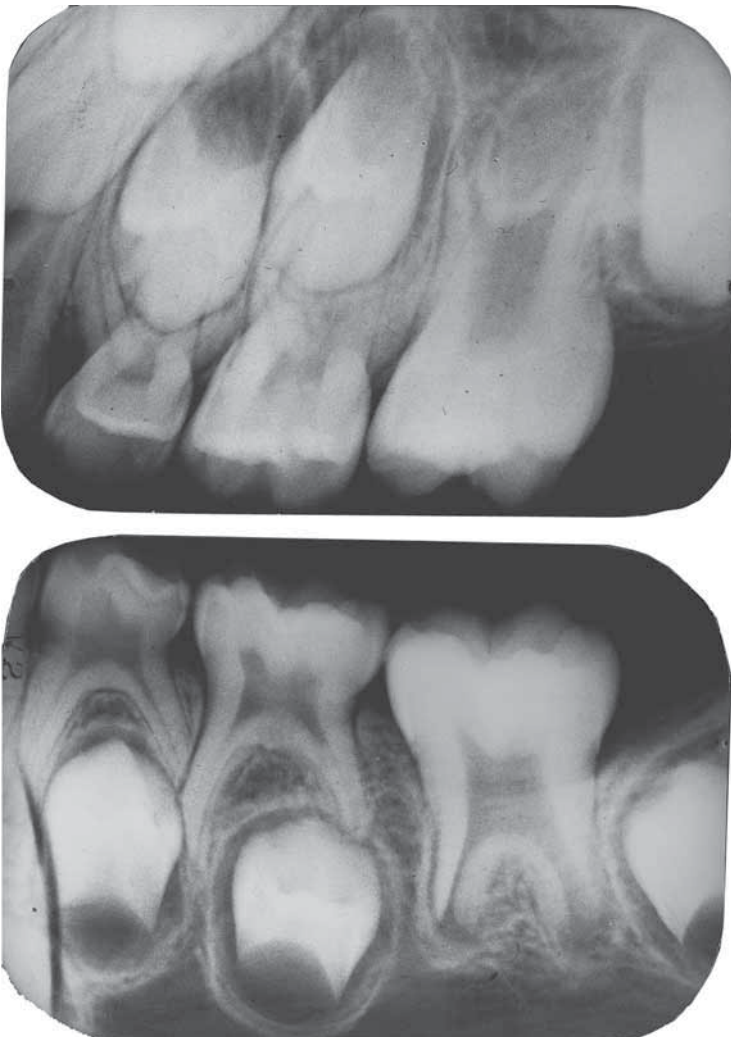
**FIGURE 6-24.** Learning Case 1: Using the guidelines presented in this chapter, estimate the dental age of the child with this mixed dentition.

**Learning Exercise Case 1, cont.**

**Answer:** Let us look at the facts. First, all primary teeth have erupted (which can be deduced based on their relatively small size, thin roots, and the fact that all permanent succedaneous teeth are forming apical to their primary tooth predecessors). Therefore, the child is at least 2 years old. Next, the first permanent molars are not even close to emerging, so the child must be considerably younger than 6 years old. Finally, no resorption has begun on the primary tooth roots, so we can conclude that the child is closer to 3 or 4 years old, rather than to 5 or 6, since primary teeth roots begin to resorb about 3 years after eruption, which for the mandibular central incisors would be about 3 and 1/2 years old.

**CASE 2:** Next, estimate the dental age of the child based on the shapes of teeth in the radiographs in Figure 6-25 before reading the answer.

**Answer:** We see two mandibular premolar-shaped crowns (with no roots) forming under the roots of two primary molars (evidenced by their divergent roots). Distal to the primary second molars are the larger, erupted 6-year molars with incomplete roots. The permanent maxillary canine and maxillary second molar crowns (only partially visible) are still within the bone. By deduction, the child should be over 6 but not yet 12. Since the primary molars' roots are partially resorbed, the succedaneous premolars are close to emerging, making the child closer to 8 or 9 years old. If you could confirm that the succedaneous incisors were all erupted, you could estimate the age at just over 9 years old.



**FIGURE 6-25.** Learning Case 2: Based on these radiographs of mixed dentition, estimate the dental age of this child. (Radiographs courtesy of Professor Donald Bowers, Ohio State University.)

**Learning Exercise cont.**

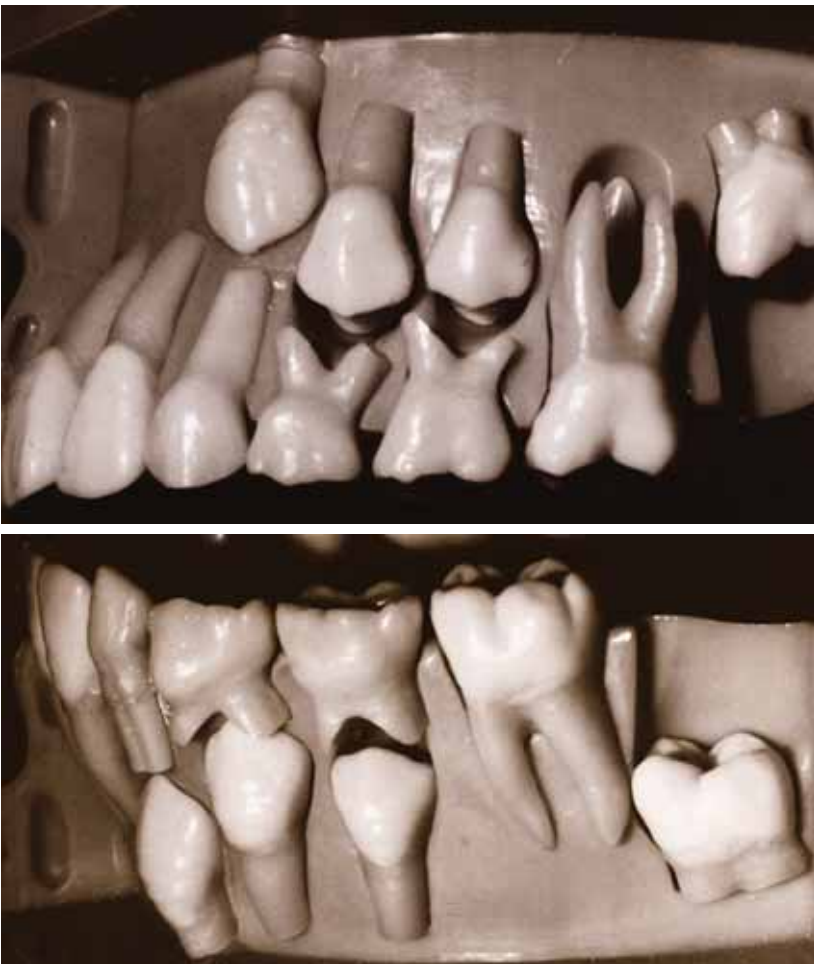
**CASE 3:** Using the logic of deduction, look at the cutaway model in *Figure 6-26* and see if you can estimate the dental age before reading the answer here.

**Answer:** *The permanent first molars have emerged into the mouth, making the child at least 6 years old. The relatively large size of the anterior incisor crowns and lack of succedaneous teeth apical to the roots indicate that the erupted incisors are permanent, which places the age at 9 years old or older. The 12-year molar has not emerged, so the child is between 9 and 12 years old. Since none of the succedaneous canines or premolars have yet emerged, the dental age is around 9.*

**CASE 4:** Finally, examine the unique dentition in *Figure 6-27* to determine which teeth

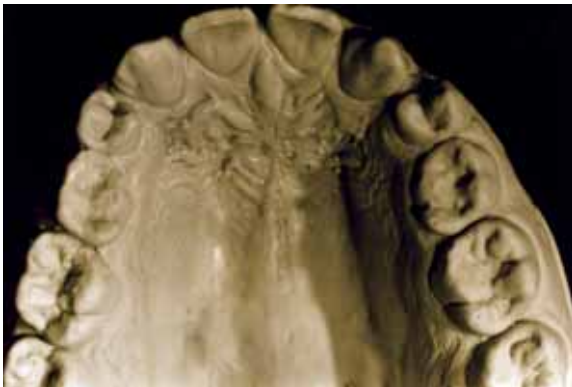**Learning Exercise Case 4, cont.**

are present and which teeth are absent. Use the position from the midline as a guide to look for each tooth you expect to occupy that position, but always remember that the space could be occupied by the primary tooth OR its succedaneous tooth. Also, realize that spaces are not always present when a tooth is missing. The teeth on either side of the space may move together and close the space either through orthodontic treatment or due to a common tendency for teeth distal to a space to move (drift) into, and close, the space. Therefore, if a space is not occupied by the expected primary or secondary tooth, it may be because the tooth has been extracted or is missing, and you will have to adjust your positioning from the midline accordingly.



**FIGURE 6-26.** Learning Case 3: Estimate the dental age of the child with this mixed dentition.





### EXPECTED TEETH BASED ON NORMAL POSITION FROM THE MIDLINE

POSITION FROM MIDLINE	TOOTH EXPECTED IN THAT POSITION (IF THERE ARE NO MISSING OR EXTRA TEETH)
First tooth from midline	Primary central incisor OR Permanent central incisor
Second tooth from midline	Primary lateral incisor OR Permanent lateral incisor
Third tooth from midline	Primary canine OR Permanent canine
Fourth tooth from midline	Primary first molar OR Permanent first premolar
Fifth tooth from midline	Primary second molar OR Permanent second premolar
Sixth tooth from midline	Permanent (6 year) first molar
Seventh tooth from midline	Permanent (12 year) second molar
Eighth tooth from midline	Permanent third molar

**FIGURE 6-27** Learning Case 4: Identify each visible tooth in the unique dentition of this 15-year-old. Use the chart to guide your decision, but notice that some teeth are missing with the spaces filled in by adjacent teeth.

#### Learning Exercise Case 4, cont.

**Answer:** In this case, beginning at the midline, the large incisors appear to be adult central incisors, but the next teeth from the midline do not resemble lateral incisors. Instead, these teeth look like permanent canines, followed distally by first premolars. We, therefore, need to suspect that the lateral incisors are missing or still unerupted (impacted) within the maxillae. The teeth distal to the first premolars, which in an adult dentition should be the second premolars, instead resemble small maxillary first molars, followed by larger maxillary first molars. This leads us to conclude that the smaller molars, in the place of the maxillary second premolars, could be primary second molars (resembling the larger emerged 6-year first molars just distal to them). Since the 12-year second molars are also present (though partially cut off in the photo), the patient would be at least

#### Learning Exercise Case 4, cont.

12 years old. If that is true, we need to ask why there are no secondary lateral incisors or second premolars, and why the primary second molars are still present. Obtain a good history (to determine which teeth have been extracted or have been confirmed as missing) along with excellent radiographs to see whether the secondary lateral incisors or second premolars are still unerupted within the bone (impacted). If the lateral incisors are not present and never formed, they would be considered **congenitally absent** (that is, as a result of factors existing at birth). If the primary second molars were maintained into the adult dentition (usually because the second premolars were congenitally absent), the primary teeth in an adult would be called **retained deciduous teeth**. More on the topic of missing teeth will be presented in the chapter on dental anomalies.

## Review Questions

Circle the correct answer(s). More than one answer may be correct. Unless otherwise stated, teeth are identified using the Universal Identification System.

1. Which primary teeth have crowns that are wider mesiodistally than they are long incisio- or occluso-cervically?
  - a. Maxillary central incisor
  - b. Maxillary first molar
  - c. Mandibular lateral incisor
  - d. Mandibular first molar
  - e. Mandibular canine
2. Which one tooth is adjacent and distal to the primary maxillary second molar in a 7-year-old?
  - a. Maxillary first premolar
  - b. Maxillary second premolar
  - c. Secondary maxillary first molar
  - d. Secondary maxillary second molar
  - e. Primary maxillary first molar
3. How many teeth should be visible in the mouth of a 3-year-old?
  - a. None
  - b. 10
  - c. 20
  - d. 24
  - e. 28
4. How many teeth should be present in the mouth of a 13-year-old?
  - a. 10
  - b. 20
  - c. 24
  - d. 28
  - e. 32
5. Which primary molar most resembles a secondary maxillary right first molar?
  - a. Tooth A
  - b. Tooth E
  - c. Tooth F
  - d. Tooth T
  - e. Tooth B
6. What would you estimate to be the dental age of a child with the following teeth: all primary maxillary incisors, canines, and molars; secondary mandibular incisors and first molars.
  - a. 2 to 4 years
  - b. 5 to 7 years
  - c. 8 to 9 years
  - d. 10 to 11 years
  - e. Over 12 years
7. Which teeth (primary or secondary) have the mesial proximal contact positioned more cervically than the distal proximal contact?
  - a. Mandibular first premolar
  - b. Maxillary first premolar
  - c. Primary maxillary canine
  - d. Primary mandibular canine
  - e. Mandibular second premolar
8. Which teeth (secondary or primary) have the mesial cusp ridge of the facial cusp longer than the distal cusp ridge of the facial cusp?
  - a. Mandibular first premolar
  - b. Maxillary first premolar
  - c. Primary maxillary canine
  - d. Primary mandibular canine
  - e. Mandibular second premolar
9. Which succedaneous tooth erupts beneath tooth J?
  - a. No. 1
  - b. No. 5
  - c. No. 10
  - d. No. 13
  - e. No. 16
10. Which of the following traits can be used to differentiate primary teeth from secondary teeth?
  - a. Primary teeth have greater facial cervical bulges.
  - b. Primary teeth have relatively thinner and longer roots.
  - c. Primary teeth are whiter.
  - d. Primary anterior teeth are larger than their successors.
  - e. Primary teeth have relatively larger pulps.
11. Which of the following secondary teeth would you expect to be erupted in the average 9- to 10-year-old?
  - a. Maxillary lateral incisor
  - b. Maxillary central incisor
  - c. Mandibular canine
  - d. Maxillary canine
  - e. Mandibular second molar
12. Which traits apply to a primary mandibular first molar?
  - a. Its roots are resorbed by the eruption of the 6-year mandibular first molar.
  - b. It resembles a mandibular 6-year first molar.
  - c. It has a prominent buccal cervical bulge.
  - d. It has a prominent mesial marginal ridge.
  - e. It has a prominent transverse ridge.
  - f. It has an occlusal table larger in the mesial half than in the distal half.

**ANSWERS:** 1—a, b, d; 2—c; 3—c; 4—d; 5—a; 6—b; 7—a, c; 8—b, c; 9—d; 10—a, b, c, e; 11—a, b, c; 12—c, d, e

## Critical Thinking

1. Ashley, a 9-year-old child who is almost 10 years old, has 24 teeth in her mouth, some primary and some permanent. Describe in detail how you would go about confirming the identity of the six teeth in one of her maxillary quadrants. That is, how would you identify each tooth in this quadrant of mixed dentition?

### REFERENCES

1. Hellman M. Nutrition, growth and dentition. *Dental Cosmos*, 65:34–49, 1923.
2. Pinkham JR, Casamassino PS, Fields HW Jr. *Pediatric dentistry, infancy through adolescence*. 4th ed. St. Louis, MO: Elsevier Saunders, 2005:191.
3. Brand RW, Isselhard DE. *Anatomy of orofacial structures*. St. Louis, MO: C.V. Mosby, 1998:462–490.
4. Osborn JW, ed. *Dental anatomy and embryology*. Oxford: Blackwell Scientific Publications, 1981:144–151.
5. Huang L, Machida Y. A longitudinal study of clinical crowns on deciduous anterior teeth. *Bull Tokyo Med Dent Univ* 1987;28:75–81.
6. DuBrul EL. *Sicher's oral anatomy*. 7th ed. St. Louis, MO: C.V. Mosby, 1980:238–244.
7. Jorgensen KD. The deciduous dentition—a descriptive and comparative anatomical study. *Acta Odontol Scand* 1956;14(Suppl 20):1–192.
8. Pagano JL. *Anatomia dentaria*. Buenos Aires: Editorial Mundi S.A., 1965:471–540.
9. Finn S. *Clinical pedodontics*. Philadelphia, PA: W.B. Saunders, 1957:54–80.
10. Kraus B, Jordan R, Abrams L. *Dental anatomy and occlusion*. Baltimore, MD: Williams & Wilkins, 1969:115–131.



### Additional Research Data

Specific data presented below have been referenced throughout this chapter by using superscript letters like this (data<sup>A</sup>).

- A. Primary *maxillary* teeth function in the mouth for an average of 8 years, and 7.6 years for *mandibular* teeth.<sup>1</sup>
- B. The time from the beginning of hard tissue formation until complete enamel calcification ranges from a minimum of 9 months for primary incisors to a maximum of 13 months for primary second molars.
- C. The time from completion of primary crown calcification until eruption ranges from about 3 months for mandibular central incisors to about 13 months after calcification for maxillary second molars.
- D. The time from primary tooth eruption until the completion of root ranges from about 10.5 months for maxillary central incisors to about 21 months for upper canines.
- E. The span from the completion of permanent crown calcification until the tooth erupts ranges from 2.7 years for the lower anterior teeth to 4 to 7 years for the lower posterior teeth.
- F. Crowns of primary maxillary central incisors are 2.4 mm wider mesiodistally than faciolingually compared to maxillary lateral incisors that are only 0.9 mm wider mesiodistally.
- G. Primary mandibular canine crowns are 2.1 mm longer incisocervically than wide mesiodistally and are 1.3 mm narrower mesiodistally than primary maxillary canine crowns.
- H. Maxillary canine roots are 13.5 mm long and are 1.8 mm longer than mandibular canine roots.
- I. Primary maxillary canine crowns are 2 mm wider mesiodistally than faciolingually. Mandibular canine crowns are only 0.4 mm wider mesiodistally than faciolingually.
- J. Primary maxillary second molars crowns are 47% wider mesiodistally than the maxillary second premolars that will replace them.
- K. Primary mandibular second molar crowns are wider mesiodistally by 45% than the mandibular second premolars that will replace them.
- L. Primary maxillary second molars are smaller than permanent maxillary first molars by 13.2% when all dimensions are averaged.
- M. Primary mandibular second molars are smaller than permanent mandibular first molars by 17.3% when all dimensions are averaged.
- N. Crowns of primary mandibular first molars are 1.6 mm wider mesiodistally than cervico-occlusally.
- O. Primary maxillary first molars are 14% wider than the premolars that will replace them.
- P. Primary mandibular first molars are 24% wider mesiodistally than the mandibular first premolars that will replace them.
- Q. Primary maxillary first molars are 1.4 mm wider faciolingually than mesiodistally.



PART



# APPLICATION OF TOOTH ANATOMY IN DENTAL PRACTICE





# Periodontal Anatomy



**First contributing author of this chapter:** Dr. Binnaz Leblebicioglu, D.D.S., M.S., Ph.D. is an Associate Professor of Periodontology at The Ohio State University, College of Dentistry, Division of Periodontology. She is a diplomate of the American Academy of Periodontology and currently teaches Periodontology at both predoctoral and graduate levels. Her research is related to periodontal/peri-implant pathogenesis and wound healing.



**Senior contributing author of this chapter:** Dr. Lewis Claman, D.D.S., M.S. is an Associate Professor, Emeritus at the Ohio State University College of Dentistry and has a private practice limited to periodontics. He is a diplomate of the American Board of Periodontology. He was a full time faculty member at Ohio State for 35 years where he was Predoctoral Director of Periodontology from 1997 to 2009. Dr. Claman, who teaches dental photography, has contributed the majority of photographs in this chapter.

**The periodontal considerations related to external morphology and surrounding structures are presented in nine sections:**

- I. Definitions of basic periodontal terms
- II. The healthy periodontium
  - A. Alveolar bone
  - B. Tooth root surface
  - C. Periodontal ligament (abbreviated PDL)
  - D. Gingiva
- III. Anatomy of diseased periodontium
  - A. Gingivitis
  - B. Periodontitis
  - C. Gingival recession
- IV. Periodontal measurements: indicators of disease and conditions
  - A. Tooth mobility
  - B. Probe depths
  - C. Gingival margin level (gingival recession or non-recession)
  - D. Clinical attachment loss (same as clinical attachment level)
  - E. Bleeding on probing
  - F. Furcation involvement
  - G. Lack of attached gingiva (previously called a mucogingival defect)
  - H. The plaque score (index)
- V. Relationship of periodontal disease and restorations (fillings)
- VI. Relationship of tooth support and root morphology
- VII. Influence of root anatomy and anomalies on the progression of periodontal disease
- VIII. Periodontal disease therapies
- IX. The influence of root anatomy on periodontal instrumentation, oral hygiene instruction and periodontal maintenance

## OBJECTIVES

This chapter is designed to prepare the learner to perform the following:

- Identify the components of a healthy periodontium.
- List the functions of gingiva, the periodontal ligament, alveolar bone, and cementum.
- Describe and recognize the signs of gingivitis, periodontitis, and gingival recession.
- Describe the periodontal measurements that can be used to differentiate periodontal diseases from periodontal health and record these findings on a dental chart.
- Describe the relationship of periodontal disease with restorations placed close to the gingival attachment (dentogingival junction).
- Describe the relationship of root morphology with tooth support.
- List contemporary methods of periodontal therapy.
- Describe challenges for periodontal instrumentation relative to root anatomy.



While the anatomy of the crown is significant to tooth function, the *root* morphology and healthy surrounding structures determine the actual support for the teeth. This chapter focuses on how external root morphology affects the prevention and progression of disease of the supporting structures called the periodontium, and how tooth support and stability are affected when the supporting structures of the tooth become

diseased. An emphasis is placed on periodontal disease initiation, the measurements and descriptions that can be used to differentiate periodontal health from disease, and the therapies that can be used to arrest or prevent the disease. The important relationship of periodontal disease relative to the placement of fillings and crowns and the relevance of root anatomy to the removal of harmful deposits that can form on the roots are also introduced.

## SECTION I

## DEFINITIONS OF BASIC PERIODONTAL TERMS

The following definitions are important to the understanding of periodontal disease and related therapies. Complete definitions can be found in the Glossary of Periodontal Terms<sup>1</sup> located on the Web site <<http://www.perio.org/resources-products/Perio-Terms-Glossary.pdf>>.

1. **Periodontium** [pair e o DON she um] (or **Periodontal Ligament Apparatus**): The tissues that surround, envelop, or embed the teeth (Fig. 7-1) including the gingiva, cementum (covering the tooth root), periodontal ligament, the supporting (alveolar) bone, and the alveolar mucosa.
2. **Gingivitis** [jin ji VIE tis]: Inflammation (disease) of the gingiva.
3. **Periodontitis** [per e o don TIE tis]: Inflammation (disease) of the supporting tissues of the teeth called the periodontium. (A spread of inflammation of the gingiva into the adjacent bone and periodontal ligament usually results in a progressively destructive change leading to loss of bone and periodontal ligament.)
4. **Periodontal diseases**: Those pathologic processes affecting the periodontium, most often gingivitis and periodontitis.
5. **Dental plaque** [PLACK] (also known as **biofilm**): An organized layer consisting mainly of microorganisms that adhere to teeth (and other oral structures) and contribute to the development of gingival and periodontal diseases, as well as to tooth decay (dental caries).
6. **Dental calculus** [KAL kyoo les] (**tartar**): A hard mass that forms on teeth (or tooth substitutes) due to calcification of dental plaque.
7. **Periodontics**: That specialty of dentistry that encompasses the prevention, diagnosis, and treatment of diseases of the supporting tissues of the teeth or their substitutes; the maintenance of the health, function, and esthetics of these structures and tissues; and the replacement of lost teeth and supporting structures by grafting or implantation of natural and synthetic devices and materials.
8. **Periodontist**: A dental practitioner who, by virtue of special knowledge and training in the field, limits his or her practice or activities to periodontics.

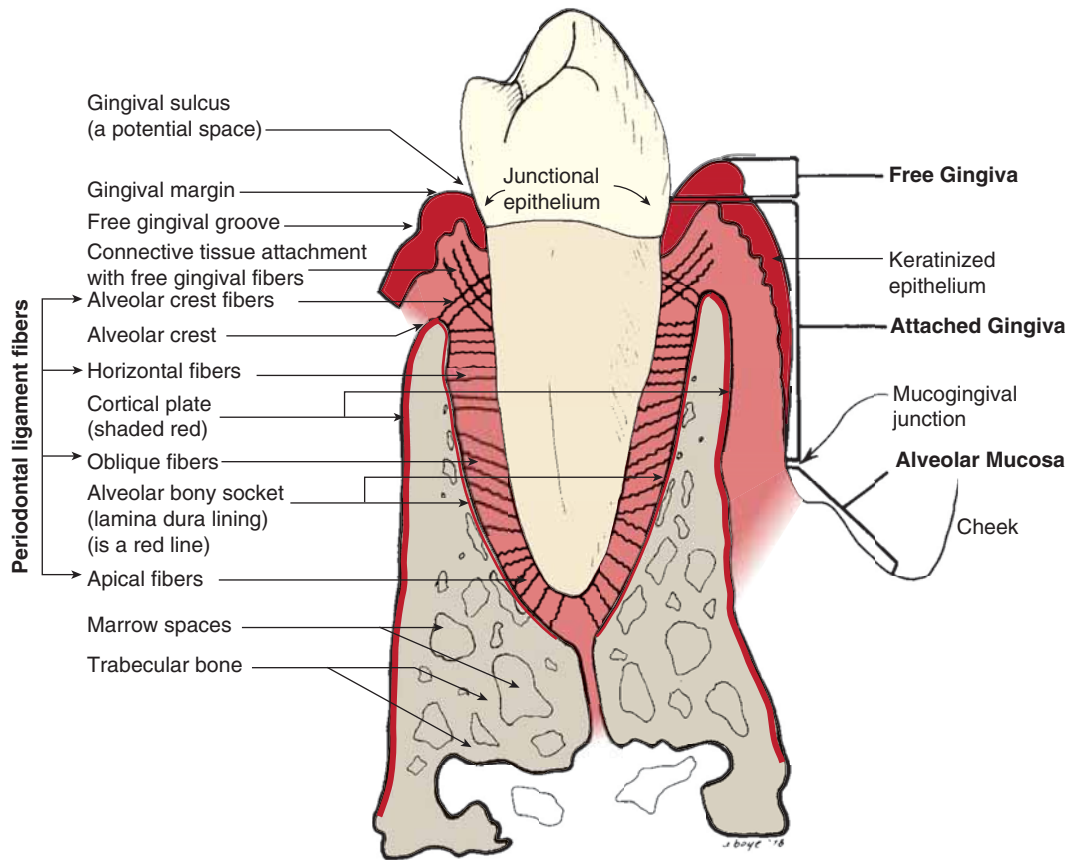


FIGURE 7-1.

**Cross section of a tooth within its periodontium.** Mesial side of a mandibular left first premolar suspended in its alveolus by groups of fibers of the periodontal ligament. Periodontal ligament fibers include the apical, oblique, horizontal, and alveolar crest fibers. Other fibers include free gingival fibers, and a sixth group (not visible in this view) called transseptal fibers that run directly from the cementum of one tooth to the cementum of the adjacent tooth at a level between the free gingiva and alveolar crest fibers. The fibers of the periodontal ligament are *much* shorter than depicted here, averaging only 0.2 mm long.

## SECTION II THE HEALTHY PERIODONTIUM

The periodontium is defined as the supporting tissues of the teeth including surrounding alveolar bone, the gingiva, the periodontal ligament, and the outer layer of the tooth roots (all identified in Fig. 7-1).

### A. ALVEOLAR BONE

The right and left maxillae bones together, and the mandible, both have a process of bone called the **alveolar** [al VEE o lar] **process** that surrounds the roots of all healthy teeth in that arch. The root of each erupted tooth is embedded in an individual **alveolus** [al VEE o lus] (plural alveoli) or tooth socket whose shape corresponds closely with the shape of the roots of the tooth it surrounds. Each alveolus is lined with a thin compact layer of bone seen on a radiograph (x-ray) as the **lamina dura**.

### B. TOOTH ROOT SURFACE

Tooth roots are covered by a thin layer of cementum.

### C. PERIODONTAL LIGAMENT (ABBREVIATED PDL)

The periodontal ligament is a very thin ligament composed of many fibers that connects the outer layer of the tooth root (which is covered with cementum) with the thin layer of dense bone (lamina dura) lining each alveolus or tooth socket. The groups of fibers of the periodontal ligament represented in Figure 7-1 are greatly enlarged. The entire thickness of the ligament would normally be less than one fourth of a millimeter.

## D. GINGIVA

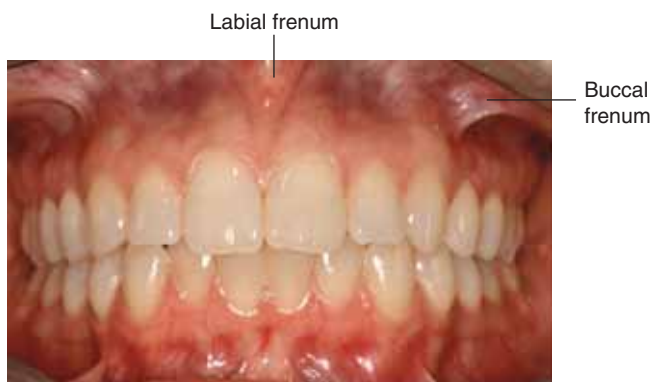The **gingiva** [JIN je va] is the part of the oral tissue (oral mucosa) covered by keratinized epithelium. It covers the alveolar processes of the jaws and surrounds the portions of the teeth near where the root and crown join (cervical portion). The gingiva is the only visible part of the periodontium that can be seen in the mouth during an oral examination.

### 1. APPEARANCE OF HEALTHY GINGIVA

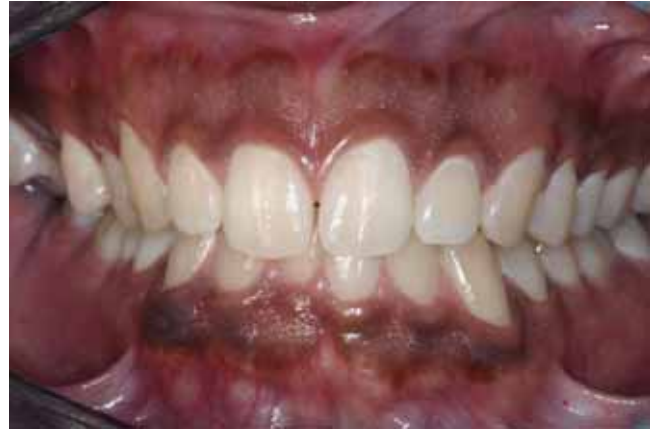Healthy gingiva varies in appearance from individual to individual and in different areas of the same mouth. It is usually pink or coral pink (Fig. 7-2), but in many persons with darkly colored and black skin, and in many persons of Mediterranean origin, healthy gingiva may have brown masking pigmentation (**melanin pigmentation**) (Fig. 7-3). Healthy gingiva is also resilient and firm and does not bleed when probed. Its surface texture is stippled, similar to that of an orange peel. The margins of healthy gingiva are thin in profile and knife edged. The shape of the facial gingival margin around each tooth somewhat parallels the cemento-enamel junction (CEJ), so it is shaped like a parabolic arch (similar in shape to the McDonald's arches). Surface stippling and the parabolic arch pattern around each anterior tooth are evident in Figure 7-4. Characteristics of normal gingiva are listed later in Table 7-1 along with the traits of diseased gingiva.

### 2. ZONES OF GINGIVA

Gingiva can be divided into several zones as shown in Figure 7-5. Beginning at the **gingival margin**, the



**FIGURE 7-2.** Healthy gingiva showing stippling (orange peel texture), knife-edge border of the free gingiva that is scalloped in shape, and interproximal papillae that fill the lingual embrasures (interproximal spaces). Also, notice the labial frenum in the midline, and the two buccal frenums that extend from the alveolar mucosa of the cheeks to the attached gingiva buccal to the maxillary premolars.

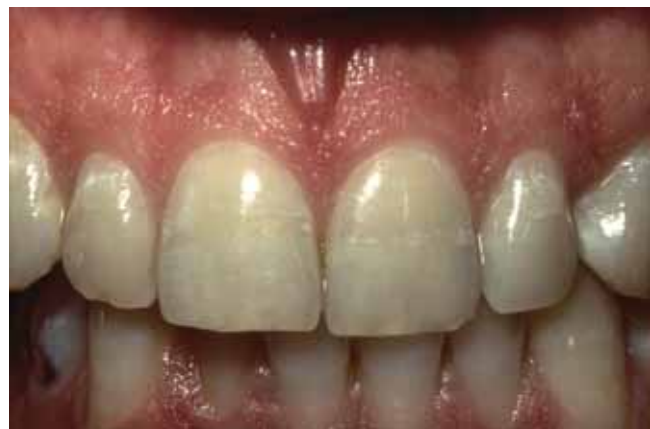

**FIGURE 7-3.** Gingiva with heavy melanin (brownish) pigmentation, normal for many ethnic groups. (Note that there is evidence of slight gingival disease.)

zones include the free gingiva and interdental papilla, the free gingival groove (when present), attached gingiva (highly keratinized and rich in collagen), and the mucogingival junction. The alveolar mucosa is the movable tissue rich in blood vessels that lines the part of the mouth between the attached gingiva and the lips, cheeks, and tongue.

#### a. Free Gingiva

The zone closest to the tooth crown is the **free gingiva**, which is the tissue that is *not* firmly attached to the tooth or alveolar bone. It surrounds each tooth to form a collar of tissue with a potential space or **gingival sulcus** (crevice) hidden between itself and the tooth. Free gingiva extends from the gingival margin (the edge of gingiva closest to the chewing or incising



**FIGURE 7-4.** Close-up view of healthy maxillary gingiva. Note the ideal scalloped contours, knife edges, and stippled (orange peel) surface texture that is usually most noticeable on the maxillary labial attached gingiva.



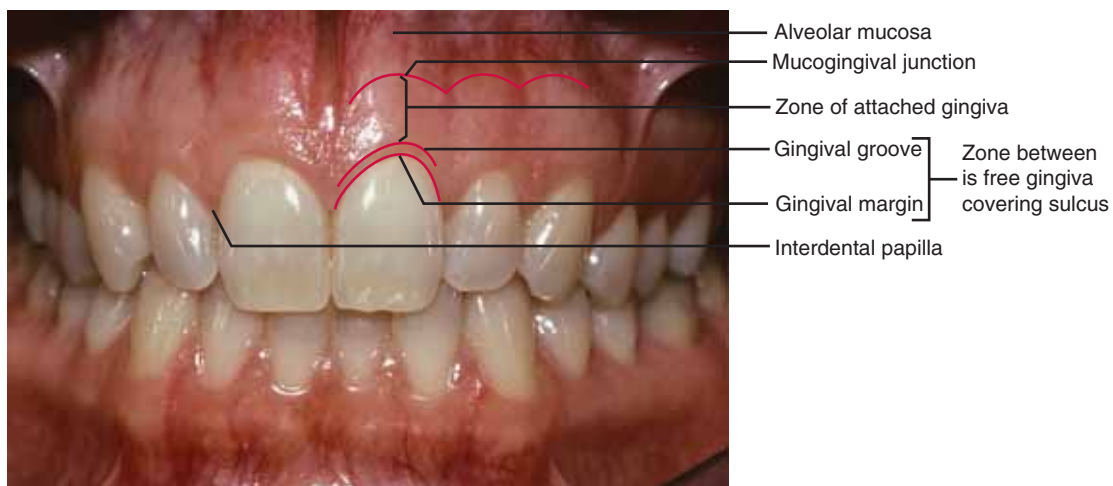
**Table 7-1** CHARACTERISTICS OF NORMAL GINGIVA COMPARED TO DISEASED GINGIVA

GINGIVAL CHARACTERISTICS	NORMAL/HEALTHY TRAITS	NOT NORMAL/DISEASE TRAITS
Size and shape		
Papillae	Fill embrasures, thin	Blunted; bulbous; cratered
Margins	Knife edged in profile	Rolled (thickened) in profile
Scallops	Present and normal, parabolic	Flattened; exaggerated; reversed; clefted
Color	Coral pink, or pink with masking melanin pigmentation	Red, bluish-red cyanotic
Consistency	Resilient, firm, not retractable with air	Soft and spongy, air retractable
Surface texture	Stippled (orange peel); matte (dull)	Smooth and shiny (glazed); pebbled (coarse texture)
Bleeding	None	Upon probing or spontaneous
Mucogingival defect	None (adequate zone of keratinized gingiva)	Pockets traverse mucogingival junction; lack of keratinized gingiva; frenum inserts on marginal gingiva
Suppuration (purulent exudate or pus)	None	Exudate is expressed when the gingival pocket wall is compressed; exudate streams out of the pocket after probing

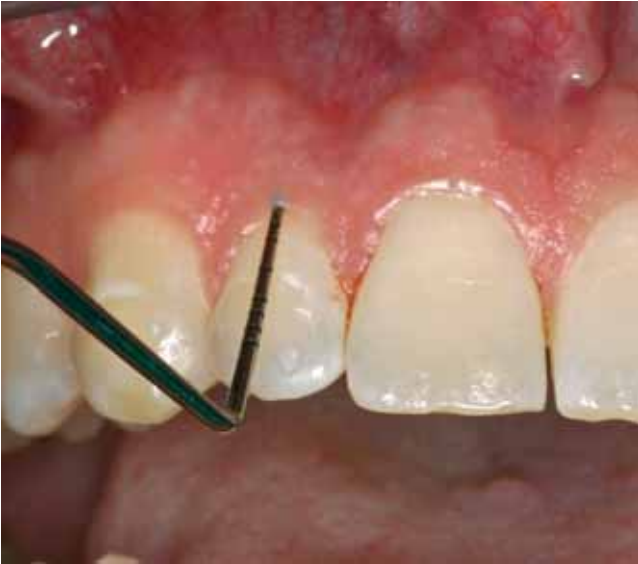surfaces of the teeth) to the **free gingival groove** (visible in about one third of adults) that separates free gingiva from attached gingiva. The **interdental gingiva** or **interproximal papilla** [pah PILL ah] (plural is papillae [pa PILL ee]) is that part of the free gingiva between two adjacent teeth. A healthy papilla conforms to the space between two teeth, so it is very thin near where the adjacent teeth contact. There is a depression in the gingival tissue of the interproximal papilla just apical to the tooth contact called a **col**. The papilla “hides” the interdental portion of the gingival sulcus that surrounds each tooth. Once dental floss is passed through an interproximal contact, it must first be slipped into the sulcus around one tooth in order to remove plaque

from its root, and then must be adapted around the adjacent tooth in order to clean its root. Care must be taken to avoid damaging the papilla in the process.

The **gingival sulcus** is not seen visually but can be evaluated with a periodontal probe since it is actually a potential space between the tooth surface and the narrow unattached cervical collar of free gingiva (Fig. 7-6). The gingival sulcus is lined with the sulcular epithelium. It extends from the free gingival margin to the junctional epithelium (averaging 0.69 mm in depth).<sup>2</sup> **Junctional epithelium** or epithelial attachment (seen in cross section in Fig. 7-1) is a band of tissue at the most apical portion of the gingival sulcus that attaches the gingiva to the tooth. It averages almost 1 mm wide.<sup>2</sup>

**FIGURE 7-5.**

**Clinical zones of the gingiva.** Note that the interdental papillae fill the interproximal spaces. The more heavily keratinized, lighter (pink) **attached gingiva** can be distinguished from the darker (redder), less keratinized **alveolar mucosa**.



**FIGURE 7-6.** Periodontal probe in place in the gingival sulcus. Note that the free gingiva is so thin that the probe can be seen behind the tissue.

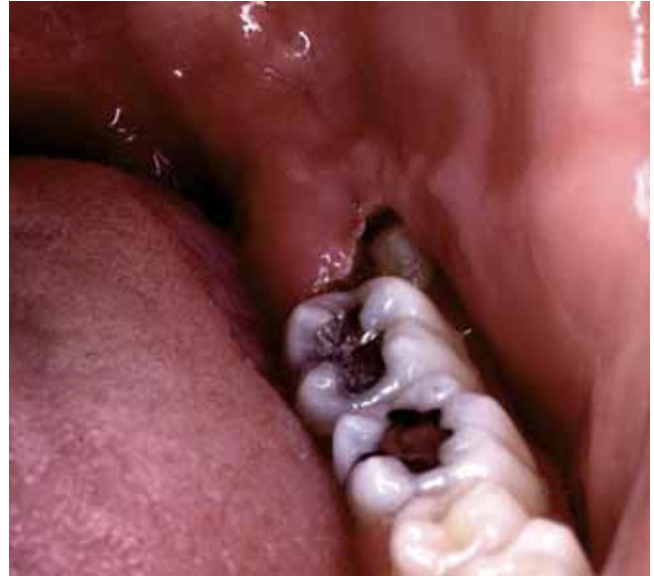Apical to the junctional epithelium, there is a 1 to 1.5 mm **connective tissue attachment** to the root coronal to the osseous (bony) crest of bone.

Clinically, the healthy gingival sulcus ranges in probing depth from about 1 to 3 mm and should not bleed when correctly probed. The periodontal probe usually penetrates slightly into the junctional epithelium, hence the difference between the depth determined through clinical probing and the depth seen on a microscopic cross section.<sup>3</sup> (At the end of this chapter, there are data on sulcus depths obtained by Dr. Woelfel.)

Sometimes, during the process of eruption of the mandibular last molar through the mucosa, a flap of tissue may remain over part of the chewing surface called an **operculum** (Fig. 7-7). This operculum can easily be irritated during chewing and become infected (called **pericoronitis**).

### b. Attached Gingiva

**Attached gingiva** is a band or zone of coral pink, keratinized mucosa that is firmly bound to the underlying bone (Fig. 7-5). It extends from the free gingiva (at the free gingival groove if present) to the readily movable alveolar mucosa. The width of attached gingiva normally varies from 3 to 12 mm. **Keratinized gingiva** is a term used to describe both the free and attached gingiva since they both contain keratin, a protein also found in skin and hair, which provides surface toughness. Attached gingiva is most often widest on the facial aspect of maxillary anterior teeth and on the



**FIGURE 7-7.** Operculum is a flap of tissue over a partially erupted last mandibular molar. This flap is subject to irritation and infection surrounding the crown known as pericoronitis. Courtesy of Dr. Carl Allen.

lingual aspect of mandibular molars. It is narrowest on the facial aspect of mandibular premolars.<sup>4</sup>

### c. Alveolar Mucosa

The **mucogingival junction** (line) (Fig. 7-5) is a scalloped junction between attached gingiva and the looser, redder alveolar mucosa. **Alveolar mucosa** is dark pink to red due to its increased blood supply and a thinner epithelium covering. It is more delicate, nonkeratinized, and less firmly attached to the underlying bone than the attached gingiva, so it is more displaceable. If you palpate these two types of tissues in your own mouth, you will feel the difference in firmness. This movable alveolar mucosa is found in three places: facially next to maxillary attached gingiva, facially next to the mandibular attached gingiva, and lingually next to mandibular attached gingiva. It is not found lingual to maxillary teeth since the hard palate has attached keratinized tissue continuous with the lingual gingiva. Therefore, a mucogingival junction is present on the facial *and* lingual aspects of mandibular gingiva, but only on the facial aspect of maxillary gingiva.

## 3. FUNCTIONS OF HEALTHY GINGIVA

In health, the gingiva provides support and protection to the dentition, as well as esthetics and proper speech (phonetics).

### a. Support

The gingiva supports the tooth by means of attachment coronal to the crest of the alveolar bone that forms a dentogingival junction from tooth to gingiva near the CEJ.<sup>5</sup> It includes the **junctional epithelium** (average width just <1 mm) and the **connective tissue attachment** (average width slightly >1 mm) (Fig. 7-1). The more coronal band (junctional epithelium) attaches gingiva to the tooth by cell junctions (called hemidesmosomes, or half desmosomes), while the more apical band (connective tissue) attaches gingiva to cementum by several gingival fiber groups made up of connective tissue called collagen.

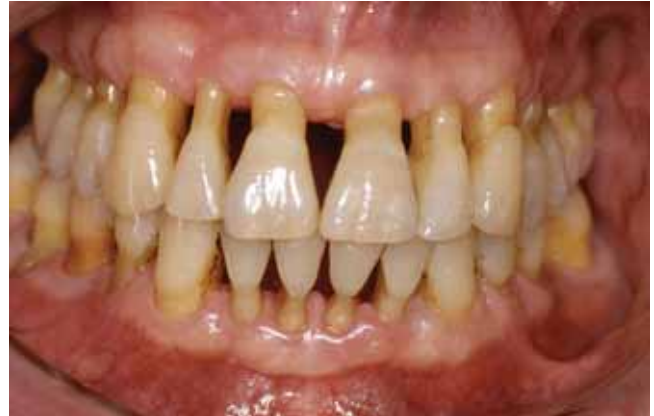### b. Protection

The gingiva protects underlying tissue because it is composed of dense fibrous connective tissue covered by a relatively tough tissue layer called **keratinized epithelium**.<sup>6</sup> It is resistant to bacterial, chemical, thermal, and mechanical irritants. Keratinized gingiva helps prevent the spread of inflammation to deeper underlying periodontal tissues. However, the sulcular lining (epithelium) and junctional epithelium of the marginal gingiva and interdental papillae provide less protection. Since these areas are not keratinized, they are more permeable to bacterial products, providing only a weak barrier to bacterial irritants, and may even allow bacterial penetration in aggressive forms of periodontal diseases.

Healthy gingiva is protected by ideally positioned and contoured natural teeth and well-contoured restorations. The protection provided by ideal tooth contours, including anatomic heights of contour, helps to minimize injury from food during mastication (chewing) since food is diverted away from the thin gingival margin and the nonkeratinized sulcus (recall Fig. 1-37). However, poor tooth or restoration contours, especially overcontoured restorations, contribute to the retention of bacteria-laden dental plaque that may predispose to gingival and periodontal diseases and will be described in more detail later. Ideal proximal tooth contours and contacts help prevent food from impacting between teeth and damaging the interdental papilla or contributing to interproximal periodontal disease. Be aware, however, that even ideal tooth contours do not prevent the formation of bacterial plaque and development of periodontal disease.

### c. Esthetics

In health, gingiva covers the roots of teeth, and the interdental papillae normally fill the gingival embrasure areas between adjacent teeth (Figs. 7-2 and 7-4).



**FIGURE 7-8.** Severe gingival recession on a patient with previous periodontal disease. The gingival margin no longer covers the CEJ, so there is considerable root exposure. Interproximally, the interdental papillae no longer fill the interdental embrasures. Recession may result in tooth sensitivity and alteration in speech (phonetics).

The shape of healthy gingiva contributes to what we consider to be an esthetic smile.<sup>7</sup> For the anterior teeth, the gingival margin of each tooth is almost parabolic in shape with the gingival line for the maxillary central incisors and canines at about the same level, but the gingival line for the lateral incisors is about 1 mm coronal (more gingiva is visible). Symmetry, especially between the maxillary central incisors, is essential. When the patient smiles, the upper lip should ideally be at about the level of the free gingival margin of the central incisors and canines, and the lower lip should just cover the incisal edges. An example of gingiva that is not esthetic is seen in Figure 7-8.

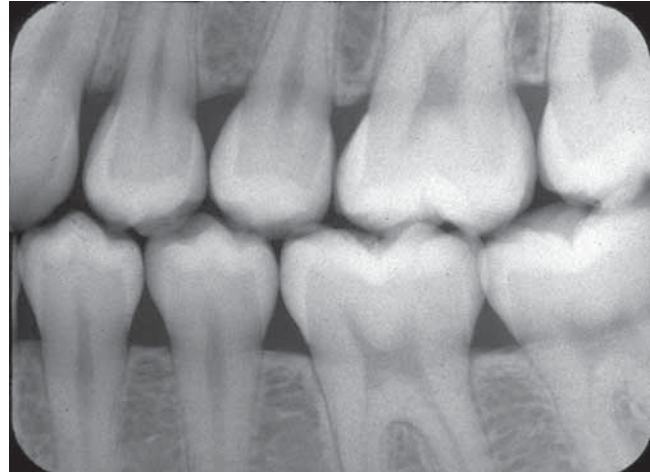
### d. Phonetics

**Phonetics** pertains to the articulation of sounds and speech. Gingival tissues should cover the roots of the teeth, but if exposure of the roots occurs, especially interproximally, speech may be affected as air passes through the open embrasure spaces. Figure 7-8 shows a patient who has had past periodontal disease with severe tissue loss that contributes to poor phonetics as well as poor esthetics.

## 4. FUNCTIONS OF THE HEALTHY PERIODONTAL LIGAMENT, ALVEOLAR BONE, AND CEMENTUM

The entire periodontal ligament consists of numerous collagen fiber bundles, which attach the cementum of the tooth root to the alveolar bony sockets. These fibers, from alveolar crest to the apex, include alveolar

crest fibers, horizontal, oblique, and apical fibers (refer back to Fig. 7-1). Free gingival fibers attach the free gingiva to the cementum. A sixth group, transseptal fibers, is not seen in Figure 7-1 since they run directly from the root (cementum) of one tooth to the cementum of the adjacent tooth at a level between the free gingiva and alveolar crest fibers. The periodontal ligament, especially the oblique fibers, provides the majority of support for the teeth and resistance to forces such as those encountered during chewing (mastication). This ligament is a viable structure that, in health, is capable of adaptation and remodeling. Healthy bone levels can be best appreciated on radiographs. Observe in Figure 7-9 that, in health, the level of the interproximal alveolar bone is 1 to 2 mm apical to the level of the CEJ s of the adjacent teeth.



**FIGURE 7-9.** Radiograph of healthy bone levels showing interproximal (crestal) bone about 1 to 2 mm apical to the CEJ of adjacent teeth. Also note the thin, whiter (more dense) layer of bone surrounding each tooth root called the lamina dura.

## SECTION III

## ANATOMY OF DISEASED PERIODONTIUM

### A. GINGIVITIS

Traditionally, periodontal disease (inflammation in the periodontium) begins as **gingivitis**, an inflammatory condition confined to and altering the gingival tissues. Alterations in the gingiva may reflect gingivitis alone, active slight periodontitis, more advanced disease, or evidence of previous disease that has been arrested. Gingival inflammation results over time from the response of the body to the harmful metabolic products of bacterial colonies within dental plaque that are in close proximity to gingival tissues. The earliest indication of gingivitis on a microscopic level involves an increase in inflammatory cells and breakdown of the connective tissue (collagen) in the gingiva. This leads to an increase in tissue fluids (*edema*, that is *swelling*), proliferation of small blood vessels (*redness*), inflammatory cells, and some loss of the integrity of the epithelium (seen as ulceration). As this breakdown progresses, changes in the tissues can be clinically observed.

Clinically, gingival characteristics that should be evaluated as indicators of gingival health (vs. disease) include its shape and size, color, consistency, and surface texture, and the presence or absence of bleeding and/or **suppuration** (also called purulence, purulent exudate, or pus). Visually, the inflammation and edema of dental plaque-induced **gingivitis** can result in redness; rolled, swollen margins; smooth and shiny surface texture or loss of stippling (Fig. 7-10); and loss of resiliency where gingival tissue can be depressed and free gingiva can be deflected from the tooth when

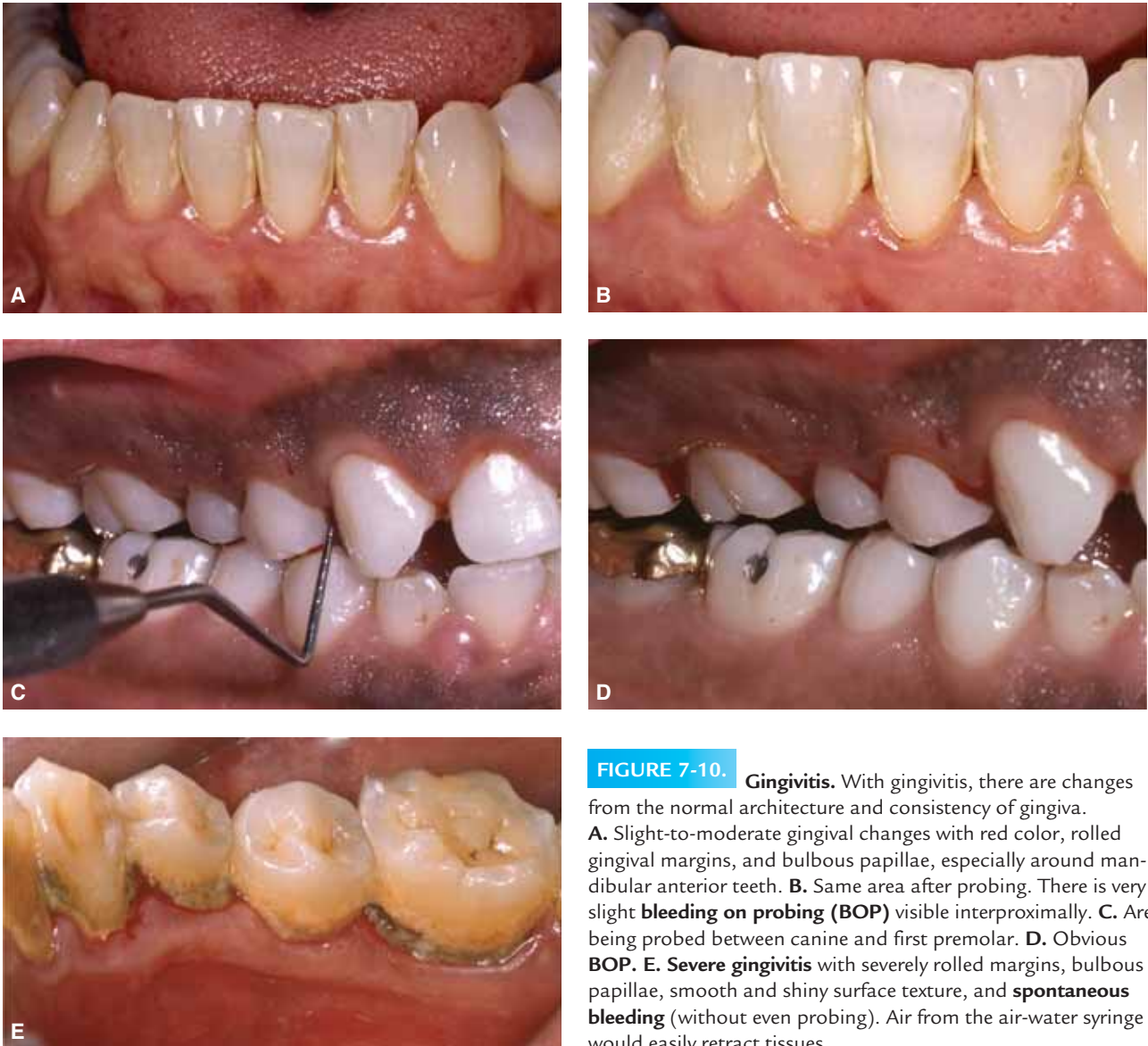a stream of air is directed toward it. Additionally, gingivitis can result in pronounced bleeding upon probing (Fig. 7-10B and especially D), spontaneous bleeding (Fig. 7-10E), and, in some cases, suppuration that can be expressed (squeezed out) from the sulcus. See Table 7-1 for normal gingival characteristics compared to descriptions of tissue exhibiting gingivitis.<sup>8-12</sup>

### B. PERIODONTITIS

In the classic progression of disease, gingivitis, if untreated, may progress to **periodontitis**. As with the gingiva, the adjacent periodontal ligament, bone, and cementum are at risk for breakdown during inflammation with resultant loss of bone height and periodontal ligament. This occurs when inflammatory breakdown extends from the gingiva to the periodontal ligament and bone and when the junctional epithelium (which normally attaches to tooth at the CEJ) migrates apically onto the root because the connective tissue attachment has broken down. Alveolar bone loss associated with periodontal disease is best appreciated in dental radiographs. Although the immune system normally protects the periodontium, a person's immune response against bacteria can also result in the production of host products that stimulate bone loss (breakdown) known as **bone resorption**. In Figure 7-11B, the crestal alveolar bone height in a person with advanced periodontal disease is no longer at predisease levels (Fig. 7-11A).

**Chronic periodontitis** is the most common form of periodontal disease. It usually progresses *slowly*, is most





**FIGURE 7-10. Gingivitis.** With gingivitis, there are changes from the normal architecture and consistency of gingiva. **A.** Slight-to-moderate gingival changes with red color, rolled gingival margins, and bulbous papillae, especially around mandibular anterior teeth. **B.** Same area after probing. There is very slight **bleeding on probing (BOP)** visible interproximally. **C.** Area being probed between canine and first premolar. **D.** Obvious **BOP**. **E.** **Severe gingivitis** with severely rolled margins, bulbous papillae, smooth and shiny surface texture, and **spontaneous bleeding** (without even probing). Air from the air-water syringe would easily retract tissues.

prevalent in adults, and is associated with plaque and dental calculus. A second form of periodontal disease is **aggressive periodontitis** that usually has an earlier age of onset. Features may include *rapid* attachment loss and bone destruction, a familial pattern, and abnormalities in the immune system. Both forms of periodontitis can result in pocket formation and/or exposure of the cementum (which is less mineralized than enamel) making the root susceptible to dental decay (caries).

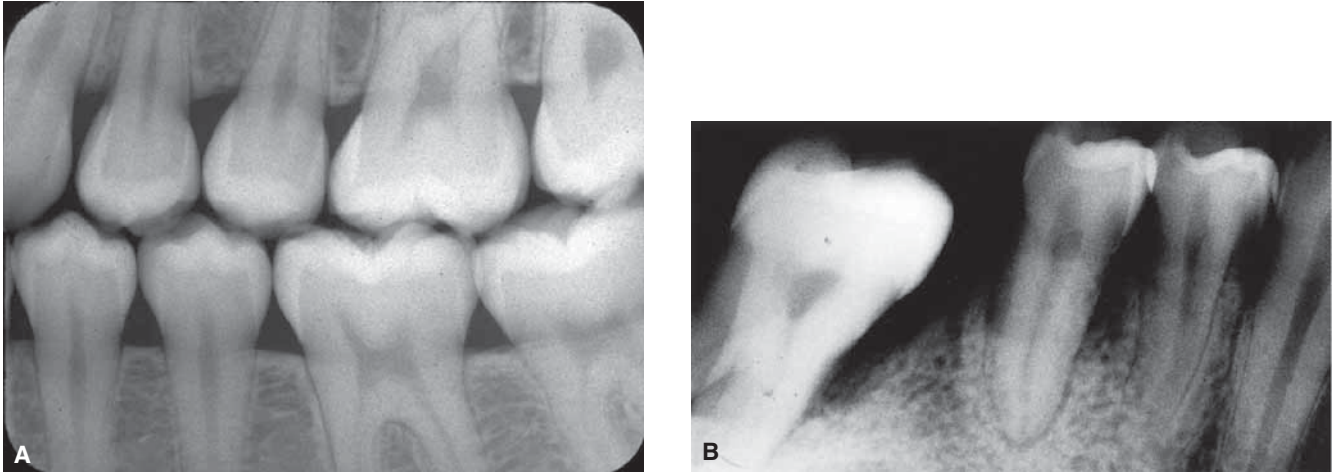
### 1. FACTORS CONTRIBUTING TO PERIODONTITIS

In addition to the primary role of bacteria, there are other factors that contribute to periodontal disease development and progression.<sup>12,13</sup> To date, only two risk factors are proven to increase the odds of periodontal disease

progression and tooth loss: smoking<sup>14</sup> and diabetes.<sup>15</sup> Other factors that may contribute to this disease include specific bacterial pathogens, alterations in the tooth form and surface that influence the accumulation and retention of dental plaque, systemic illnesses or conditions (including genetics and emotional stress) that modify or impair the immune response, and injury to the periodontium resulting from heavy forces during tooth function (such as bruxism or tooth grinding habits).

Breakdown of the periodontium resulting in attachment loss and bone loss usually begins in an inaccessible area (such as adjacent to a root concavity or an exposed furcation) that is neither self-cleansing nor easy for a patient to reach with oral hygiene aids. Therefore, it is paramount that both the dentist and the dental hygienist be thoroughly familiar with root anatomy as they perform a periodontal examination in order to detect





**FIGURE 7-11. Radiographic bone loss.** **A.** Radiograph showing *normal* bone levels relative to the CEJ. **B.** This radiograph shows advanced periodontal disease as indicated by **loss of bone** (especially around teeth Numbers 29 and 31; note tooth No. 30 is missing). Healthy bone level would normally be surrounding all teeth to a level much closer (within 2 mm) to the CEJ.

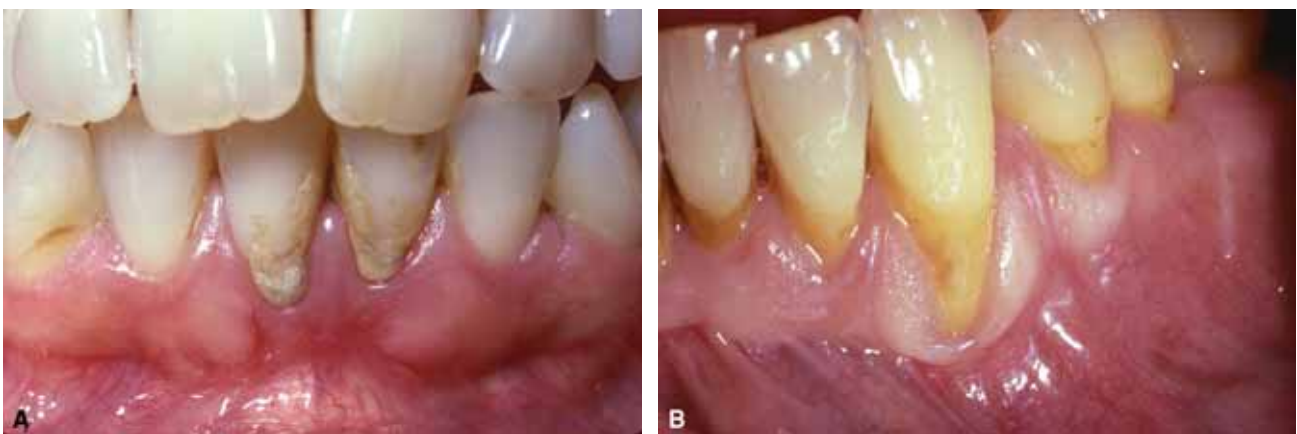periodontal disease in these inaccessible locations that are at greatest risk to breakdown. Further, an essential objective in treating periodontal disease involves using special instruments to remove deposits (plaque and calculus) and to smooth or remove cementum on root surfaces that have become affected by periodontal disease. Knowledge of root morphology also helps to identify sites that are difficult or impossible to reach, or sites that have not responded to treatment, and when providing instructions to patients for the appropriate use of oral hygiene aids.

Periodontitis itself may be a contributing factor for several systemic diseases including cardiovascular disease, stroke, and the control of existing diabetes, as well

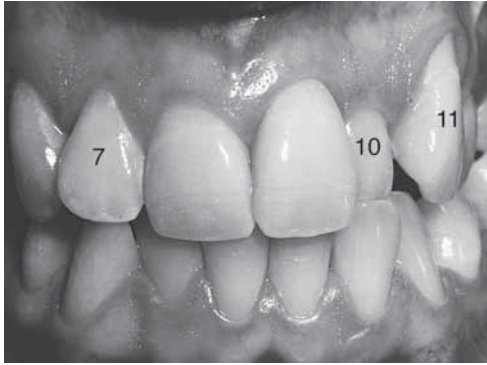
as contributing to low birth weight and preterm babies when the pregnant mother has periodontal disease.<sup>16-18</sup>

### C. GINGIVAL RECESSION<sup>19</sup>

**Gingival recession** is a loss of gingival tissue (usually with loss of underlying bone) resulting in the exposure of more root surface (Fig. 7-12A and B). In gingival recession, the gingival margin is apical to the CEJ, and the papillae may be blunted and/or rounded, and no longer fill the interproximal embrasure. Gingival recession is often seen in older individuals, hence the reference to an older person as being “long in the tooth.” It may be part of an active process of periodontal disease or



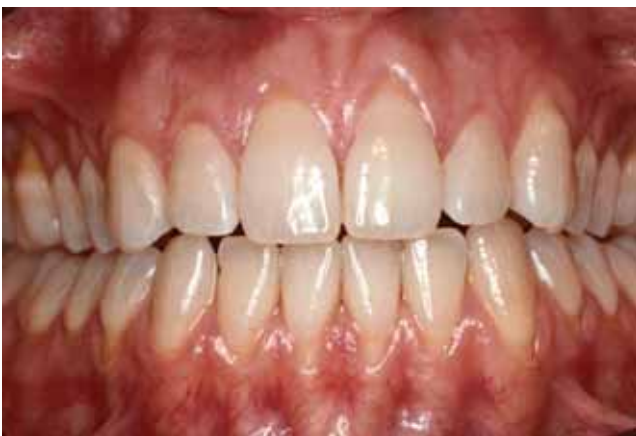**FIGURE 7-12. Gingival recession.** **A.** Area of gingival recession. On the central incisors, the gingiva no longer covers the CEJ, so the root surface is exposed (and covered with calculus). There is no keratinized gingiva over the roots of central incisors compared with lateral incisors. **B.** Severe gingival recession. There is very little keratinized gingiva and no attached gingiva over the canine root. The root prominence, thin tissue, and lack of attached gingiva are factors that may have contributed to the recession. (Courtesy of Alan R. Levy, D.D.S.)



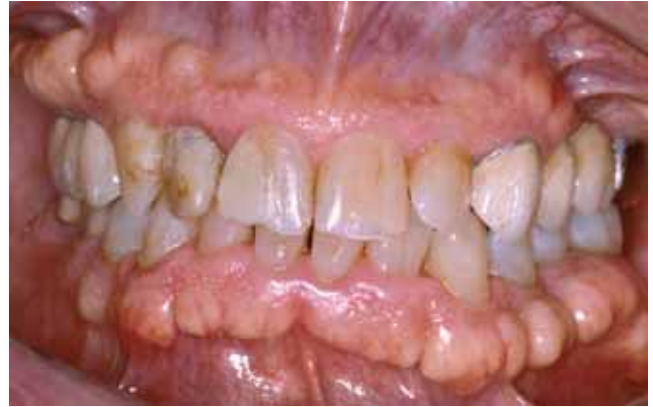**FIGURE 7-13.** Effects of tooth position (alignment) within the arch on gingival shape: Examples of contour variations caused by tooth malpositions. Tooth No. 11 is too labial, showing exaggerated scalloping and thin gingiva with recession. Tooth No. 10, which is in lingual version and crossbite, has flattened gingival contours and thicker tissue. Rotated tooth No. 7 shows V-shaped gingival margin contour on the labial gingiva.

may reflect previous disease that is now under control. However, destruction of the periodontium (including gingival recession) should not be regarded as a natural consequence of aging.<sup>19,20</sup>

Conditions that contribute to gingival recession around individual teeth, especially in the presence of plaque, are poorly aligned teeth within an arch resulting in abnormal tooth and root prominence (the canines in Figs. 7-12B and 7-13), a lack of attached gingiva,<sup>21</sup> or aggressive tooth brushing. Abnormal tooth positions do not necessarily indicate disease, but they do contribute to variations in tissue thickness such as flattened or exaggerated contours. Additionally, patients may exhibit thin or thick periodontal tissues (overlying bone and gingiva).

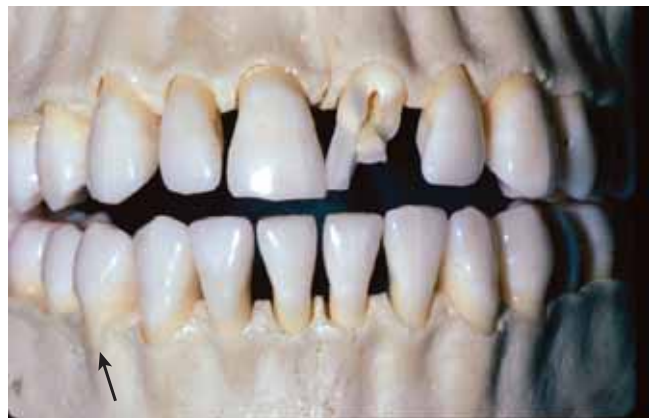

**FIGURE 7-14.** Person with *thin* periodontal tissues. The patient has thin gingival tissues and a considerable portion of the incisor roots is exposed. (Photo courtesy of Dr. Kourosh Harandi.)

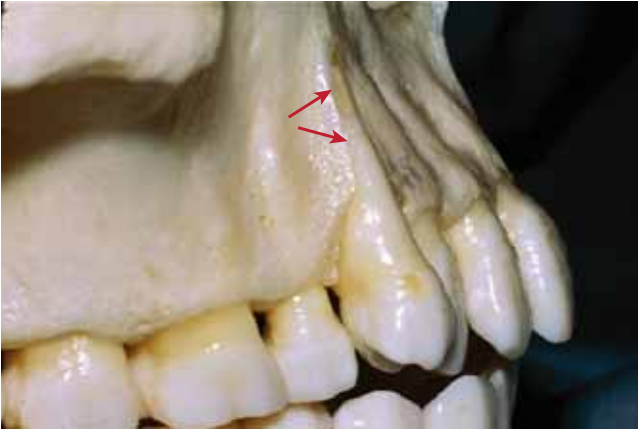

**FIGURE 7-15.** Person with *thick* periodontal tissues. The gingival tissues are generally thick, and there is very thick underlying bone. This thick bone can be called an **exostosis** of bone.

Patients with *thin* periodontal tissues may have prominent roots that are not completely covered with bone (Fig. 7-14). Patients with *thick* periodontal tissues have thicker plates of bone or gingival tissues. The very thick ledges of bone in Figure 7-15 are called **exostoses** [eck sos TOE sis]. Patients with thin periodontal tissues are more at risk for gingival recession. The risk for gingival recession is more apparent when viewing alveolar bone of a skull. Normally, the bone is 1 to 2 mm apical to the CEJ (Fig. 7-16). In prominent teeth, such as canines, there may be no bone covering much of the root, although the patient may not have signs of periodontal disease or gingival recession. An isolated area of tooth root denuded of its bony covering is called root **dehiscence** [dee HISS ens] (seen on the first premolar in Fig. 7-17). Root dehiscence may or may not be covered with soft tissue.



**FIGURE 7-16.** Normal bony architecture. The alveolar crest is normally between 1 and 2 mm apical to the CEJ. The only obvious exception is tooth No. 28 (arrow, mandibular right first premolar), which shows a slight bony dehiscence. (Courtesy of Charles Solt, D.D.S. and Todd Needham, D.D.S.)



**FIGURE 7-17.** **Root dehiscence.** This maxillary first premolar root (*arrows*) is buccal to the alveolar process. There is no bone over most of the buccal aspect of the root, although the bone over the other tooth surfaces is at a normal level. Teeth with prominent roots are prone to gingival recession. (Courtesy of Charles Solt, D.D.S. and Todd Needham, D.D.S.)

## SECTION IV

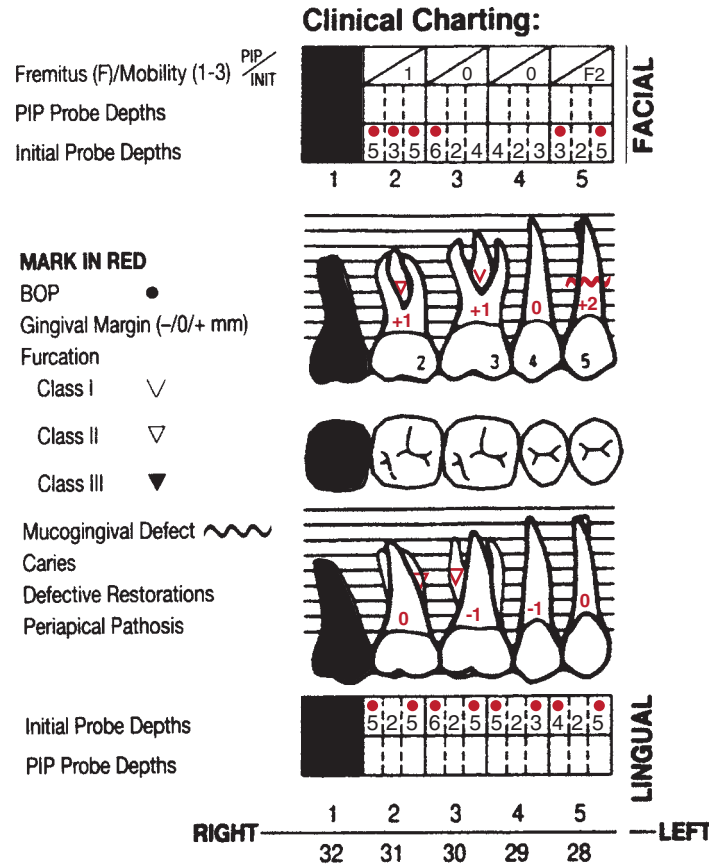
### PERIODONTAL MEASUREMENTS: INDICATORS OF DISEASE AND CONDITIONS

Several clinical measurements are critical when evaluating overall periodontal status. These measurements can be used to describe a tooth's stability and loss of support, and a patient's degree of inflammation and pattern of disease. They also help to establish a diagnosis, guide the development of a treatment plan, and document changes following active therapy. Throughout this discussion, references will be made to documenting this information using the clinical chart obtained from The Ohio State University College of Dentistry (Fig. 7-18).

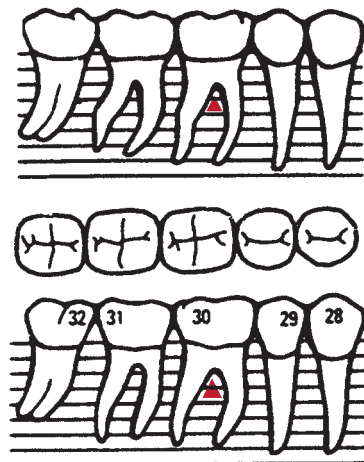
#### A. TOOTH MOBILITY

**Tooth mobility** is the movement of a tooth in response to applied forces.<sup>22</sup> Teeth may become mobile due to repeated excessive occlusal forces, inflammation, and weakened periodontal support (often associated with a widened periodontal ligament space as noted on radiographs). The healthy periodontal ligament is about 0.2 mm wide, decreasing to only 0.1 mm with advanced age. When a tooth is subjected to forces from chewing (mastication) or bruxism (grinding), movements are

**FIGURE 7-18.** **Charting periodontal findings** (on a partial reproduction of the form used at The Ohio State University College of Dentistry). This form provides a logical method for documenting periodontal findings (as well as other findings). **A.** The left column provides the key for recording the following: **Fremitus** is recorded as F as on tooth No. 5; **mobility** is denoted by 1 for tooth No. 2, 2 for tooth No. 5, and 0 (no mobility) for teeth Numbers 3 and 4. **Probe depths** (six per tooth) are recorded during the initial examination (initial probe depths) in the three boxes for three facial depth locations on each facial surface and three boxes for three lingual depth locations. After initial periodontal therapy has been completed, they should ideally be recorded again in four to six weeks. They should also be recorded at regular periodontal maintenance therapy appointments. This permits easy comparison to identify sites that respond to treatment and those that do not respond. **Bleeding on probing (BOP)** is denoted by a red dot over the probe depth readings as on the facial surfaces of teeth No. 2 (mesial, midfacial, and distal), No. 3 (distal), and No. 5 (mesial and distal); and lingually on all mesial and distal surfaces. **Gingival margin position** is recorded as numbers in red on the root of teeth as follows: +1 (1 mm apical to the cementoenamel junction or CEJ) on the facial of teeth No. 2 and No. 3; +2 on the facial of tooth No. 5; 1 (1 mm occlusal to the CEJ) on the lingual of teeth No. 3 and No. 4; and 0 (located at the level of the CEJ) on all other surfaces. **Furcation** classes are seen as red triangular shapes (incomplete, outlined, or solid). Class I involvement is evident on the midfacial of tooth No. 3. Class II involvement is noted midfacial on No. 2, as well as on the mesial (from the lingual) on No. 2, and the distal (from the lingual) on No. 3. Class III involvement is noted on a mandibular molar discussed below. **Loss of attached gingiva** (mucogingival defect) is recorded as a red wavy line seen on the facial of tooth No. 5. **B.** A mandibular molar (No. 30) showing a class III **furcation** evident from the facial and lingual views. Note that the triangle point is directed up toward the furcation in the mandibular arch but was directed down toward the furcation in the maxillary arch as shown in A. **C.** Calculation of **plaque index %** and **BOP %**. The plaque index % can be calculated by dividing the number of surfaces with plaque by the total number of surfaces (four per tooth). When considering only the four teeth in this figure, nine surfaces had plaque divided by 16 possible surfaces = 56%. The BOP % is the number of tooth surfaces that bleed on probing divided by the total number of surfaces (six per tooth). When considering only the four teeth in this figure, 14 surfaces bled divided by 24 total surfaces = 58%.

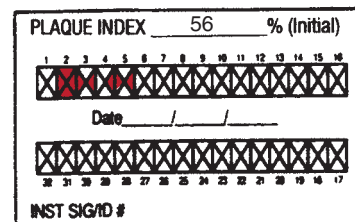


A



B

Init BOP 58 %  
 PIP BOP \_\_\_\_\_ %



C

**FIGURE 7-18.** (Continued). Legend is on previous page.

minimal at the rotational middle of the tooth root (cervicoapically) and greater at either the cervical or apical end of the root. Thus, there is a functional difference in the width of the periodontal ligament in these three regions. At any age, the ligament is wider around both

the cervix and the apex than around the middle of the root, depending upon the amount of rotational movements to which the tooth is subjected. Further, the periodontal ligament of a natural tooth in occlusal function is slightly wider than in a nonfunctional tooth because



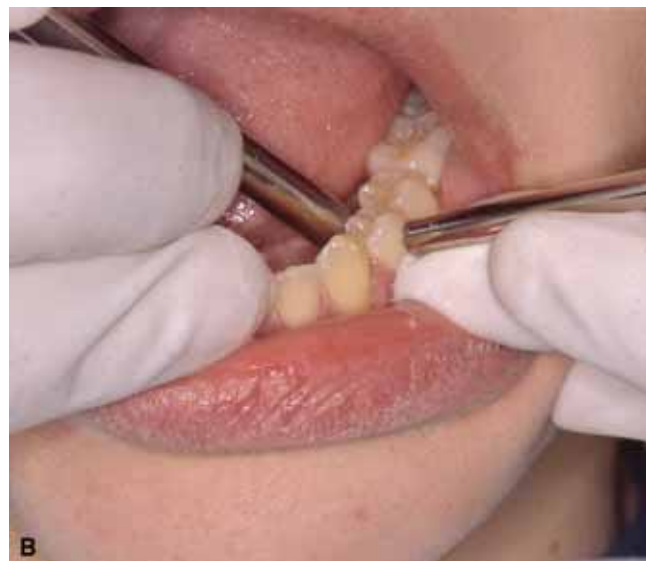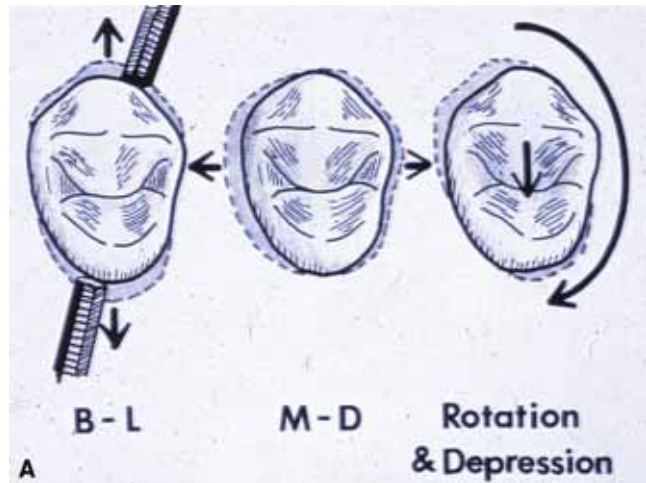
the nonfunctional tooth does not have an antagonist to stimulate the periodontal ligament and bone cells to remodel.<sup>23</sup>

Injury to the periodontium from occlusal forces is known as **occlusal trauma**. It may contribute to destructive changes in the bone, widening of the periodontal ligament, and root shortening (resorption), all of which may contribute to increased tooth mobility. Some of the changes are reversible, meaning that the periodontium can accommodate.<sup>24</sup> Occlusal trauma is a disorder that *does not initiate*, but may influence, the course of inflammatory periodontal disease under specific circumstances.<sup>25</sup>

### 1. TECHNIQUE TO DETERMINE TOOTH MOVEMENT

To determine tooth **mobility**, first, stabilize the patient’s head to minimize movement. Next, view the occlusal surfaces and observe movement of the marginal ridges of the tooth being tested relative to adjacent teeth as you use two rigid instruments (such as the mirror and probe handles) to apply light forces alternating fairly rapidly first one way, then another. Observe the tooth for movement in a buccolingual or mesiodistal direction, as well as for vertical “depressibility.” *Figure 7-19A and B* illustrates the technique to determine tooth mobility. Numbers assigned to denote the extent of mobility are presented in *Table 7-2*. For simplicity, tooth mobility can be recorded as “0” for no mobility, “1” for slight mobility, “2” for moderate mobility, or “3” for extreme mobility that includes depressing the tooth. See *Figure 7-18* for charting examples of mobility (categories 0, 1, 2, or 3).

**Fremitus** is the vibration of a tooth during occlusal contact. It is determined by placing the nail of the gloved index finger at right angles to the facial crown surface using a light force while the patient is asked to tap his or her teeth, or clench and move the mandible from right to left (excursive movements). If definite vibration is felt, fremitus is confirmed and could be noted as an “F” on a patient’s chart for that tooth (as seen for tooth



**FIGURE 7-19.** Method for determining tooth mobility. **A.** Two rigid instrument handles are applied to the tooth to see if it can be displaced either buccolingually or mesiodistally. For teeth with severe mobility, the tooth can be depressed or rotated (which is category 3 mobility). **B.** Technique for determining buccolingual mobility. Light, alternating (reciprocating) buccolingual forces are applied and movement observed relative to adjacent teeth.


Table 7-2 NUMBERS ASSIGNED TO MOBILITY CATEGORIES		
MOBILITY CATEGORY	CLINICAL OBSERVATION	MAGNITUDE
0	No observed movement	
1	Slight movement	<1 mm
2	Moderate movement	>1 mm
3	Extreme movement	Depressible



No. 5 in Fig. 7-18). If tooth displacement is detected, functional mobility is confirmed. **Functional mobility** (biting stress mobility) occurs when teeth move other teeth during occlusal function.

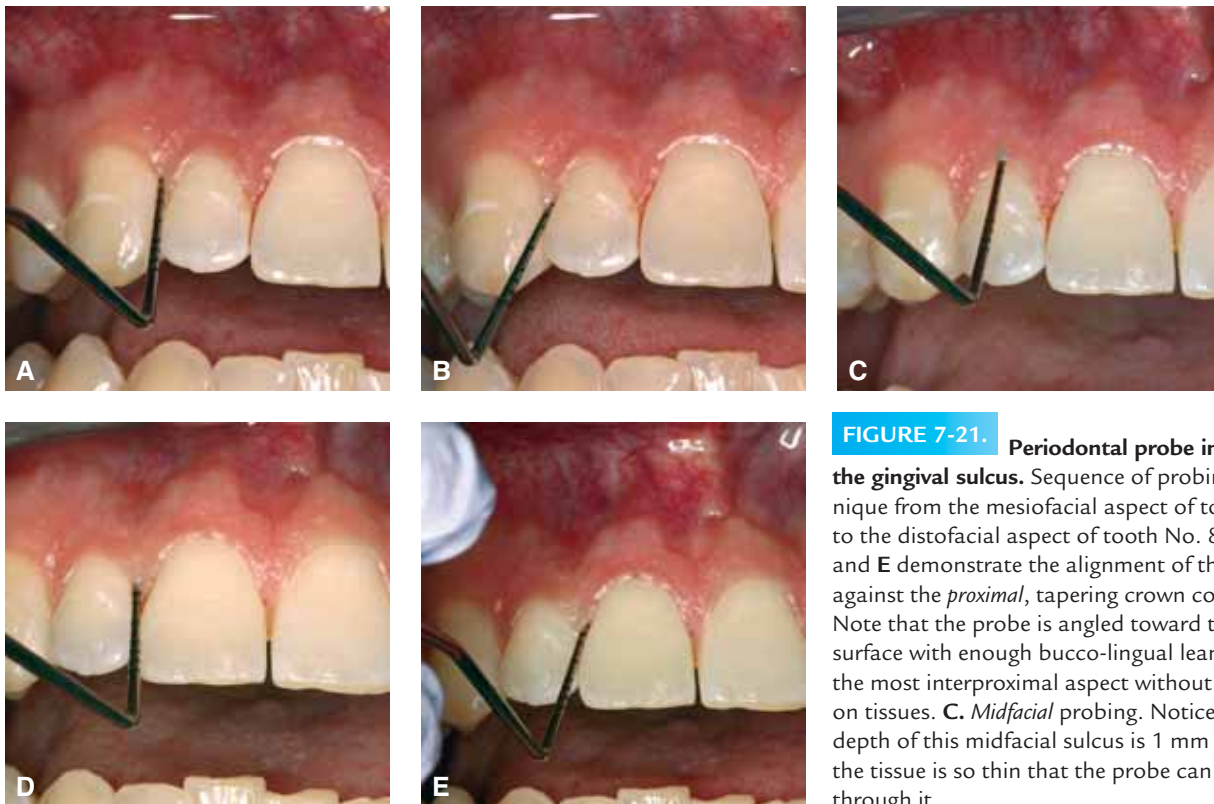## B. PROBE DEPTHS

Probing the depth of the potential space between the tooth and gingiva (called the **gingival sulcus** or **crevice**) is a critical periodontal finding that is routinely performed in dental offices and may indicate the presence of periodontal disease.<sup>26,27</sup> A blunt-tipped instrument with millimeter markings called a **periodontal probe** (Fig. 7-20) is inserted into the gingival sulcus (seen on anterior teeth in Fig. 7-21 and posterior tooth in Fig. 7-22). In the presence of periodontal disease, this gingival sulcus may be called a **periodontal pocket**. **Probing depth** (referred to as pocket depth if periodontal disease is present) is the distance from the gingival margin to the apical portion of the gingival sulcus. Probing depths in healthy gingival sulci normally range from 1 to 3 mm. A depth of greater than 3 mm is a possible cause for concern. However, if gingival tissues are overgrown (as may be seen during tooth eruption, or as a side effect from some medications), a pocket depth reading of 4 mm or greater (called a **pseudopocket**)

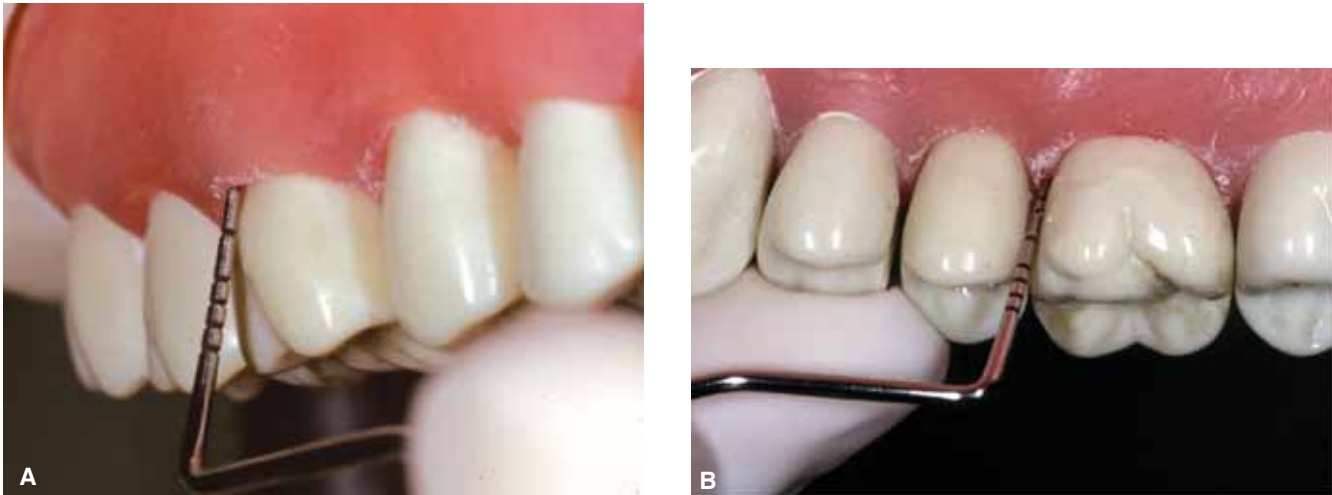

**FIGURE 7-20.** A standard, frequently used **periodontal probe**. To make measurements easier, there are dark bands at 1, 2, 3, 5, 7, 8, 9, and 10 mm.

may be present even in the absence of periodontitis. On the other hand, if there is gingival recession where the gingival margin is apical to the CEJ, there may be shallow probing depths in the presence of true periodontal disease. Therefore, the critical determinant of whether periodontitis has occurred is measured by the amount of **attachment loss** (to be described shortly).



**FIGURE 7-21.** **Periodontal probe in place in the gingival sulcus.** Sequence of probing technique from the mesiofacial aspect of tooth No. 6 to the distofacial aspect of tooth No. 8. **A, B, D,** and **E** demonstrate the alignment of the probe against the *proximal*, tapering crown contours. Note that the probe is angled toward the proximal surface with enough bucco-lingual lean to engage the most interproximal aspect without catching on tissues. **C.** *Midfacial* probing. Notice that the depth of this midfacial sulcus is 1 mm deep, and the tissue is so thin that the probe can be seen through it.



**FIGURE 7-22.** Probe placement technique on models. **A.** Buccal view: Technique for facial (or lingual) probe placement. The probe is guided along the tooth surface, and care is taken not to engage the sulcular gingival tissues. **B.** Palatal view: Interproximal probe placement. The probe is angled slightly distally on the mesial surface of tooth No. 3 as it is guided along the tooth surface, so it is not impeded by the interproximal papilla. Although not easily appreciated from this view, it is also angled 10 to 15° to reach the most direct proximal area.

## 1. PROBING TECHNIQUE

The intent is to probe a sulcus apically *just to* the attachment, although in reality the probe usually broaches (impinges on) some of the attachment, even in health. The probe should be “walked around” the tooth with a light force to ensure a tactile sense and to minimize probing beyond the base of the pocket. When the depth of the sulcus/pocket has been reached, resilient resistance is encountered. The probe should be angled slightly toward the crown or root surface to prevent it from engaging or being impeded by the pocket wall (seen best midfacially in Fig. 7-22A). Probing depths are generally recorded as the deepest measurement for each of the six areas around each tooth. On the *facial* surface, three areas are recorded while moving in very small steps within the sulcus starting in the distal interproximal, stepping around to the midbuccal, and finally stepping around to the mesial interproximal (seen when probing the facial surface of tooth No. 7 in Fig. 7-21B–D). Interproximally, when the teeth are in proximal contact, the probe should progress toward the contact until it touches both adjacent teeth before angling it approximately 10 to 15° buccal (or lingual) to the tooth axis line (seen most clearly in Fig. 7-21A,D and Fig. 7-22B). When there is no adjacent tooth, the probe is not angled. The three facial readings to record are the deepest readings for mesial interproximal, midbuccal, and distal interproximal. Similarly, three areas are recorded while probing around the *lingual* of the tooth.

## C. GINGIVAL MARGIN LEVEL (GINGIVAL RECESSION OR NONRECESSION)

Before any periodontal disease has occurred, the gingival margin level of a young healthy person is *slightly* coronal to the CEJ, which is the reference point. If the gingival margin is apical to the CEJ, there has been **gingival recession**, and the root is exposed (seen most obviously in Fig. 7-12B).

By convention, the following denotes the gingival margin level:

- Negative (–) numbers denote that the gingival margin is coronal to the CEJ. Normally, after tooth eruption is complete, the gingival margin is slightly coronal to the CEJ (about 1 mm on the labial and lingual aspects, and about 2 mm interproximally). If the gingival margin is more coronal to the CEJ than those dimensions, there is an excess (overgrowth) of gingiva or the tooth is partially erupted.
- Zero (0) denotes that the gingiva is at the CEJ. There is no gingival recession.
- Positive (+) numbers denote recession (the gingival level is apical to the CEJ).

### 1. TECHNIQUE TO DETERMINE THE GINGIVAL MARGIN LEVEL

When recession has occurred, the distance between the CEJ and the gingival margin can be visually measured with the periodontal probe. If the gingival margin covers the CEJ, the distance from the gingival margin to the CEJ

may be estimated by inserting the probe in the sulcus and feeling for the CEJ. If this junction is difficult to detect or is subgingival, the probe should be at a 45° angle. The junction between enamel and cementum can be felt with the probe. Gingival margin levels are charted as “0” (margin is at the CEJ), or a “+” number (apical to the CEJ or recession) or a “-” number (coronal to the CEJ), in red on the roots near the CEJ as seen on the chart in Figure 7-18.

#### D. CLINICAL ATTACHMENT LOSS (SAME AS CLINICAL ATTACHMENT LEVEL)

Clinical attachment loss (clinical attachment level) refers to the distance from the CEJ to the apical extent (depth) of the periodontal sulcus. It is a measurement that indicates how much support has been lost and is, therefore, a critical determinant of whether periodontal disease has occurred.

##### 1. TECHNIQUE TO DETERMINE CLINICAL ATTACHMENT LOSS

Add the probing depth and the gingival margin level measurements together to obtain the clinical attachment loss. A patient with a 3 mm pocket and a gingival level of +2 (i.e., 2 mm of recession) has 5 mm of attachment loss. A patient with a 3-mm pocket and a gingival level of -2 mm (the gingiva covers the CEJ by 2 mm) has only 1 mm of attachment loss. Study the example of clinical attachment calculation on the tooth in *Figure 7-23* where the sulcus depth is 1 mm (Fig. 7-23A) and the gingiva has receded 1 mm (+1 mm loss in Fig. 7-23B), so the total attachment loss is +2 mm. Clinical attachment loss can be severe even

with minimal pocket depths if there is considerable gingival recession. On the other hand, there may be no attachment loss even with deep pockets if pseudopockets are present, that is, pockets due to an enlargement of gingiva possibly caused by plaque accumulation next to ill-fitting restoration margins, as a side effect of certain medications, or due to hormonal changes.

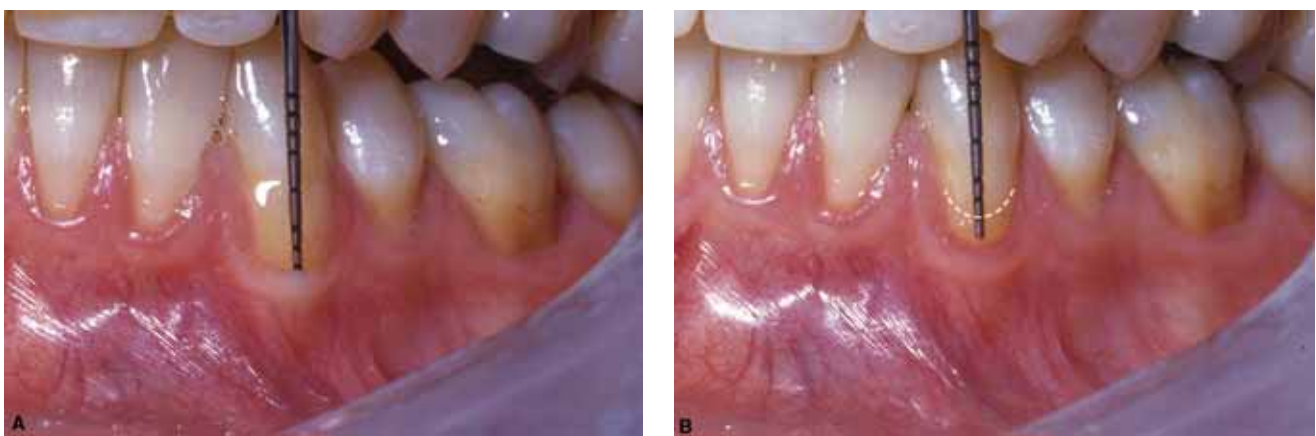Periodontists also make interproximal measurements of the gingival margin level that is a more challenging task. The severity of periodontal disease can therefore be accurately determined at the six sites around each tooth by measurements.

#### E. BLEEDING ON PROBING

Bleeding on probing occurs when bacterial plaque affects the gingival sulcular epithelium, resulting in inflammation in the underlying connective tissue. Bleeding visible from the gingival margin after probing is an important indicator of inflammation (Figs. 7-24A,B and Fig. 7-10B,D,E).

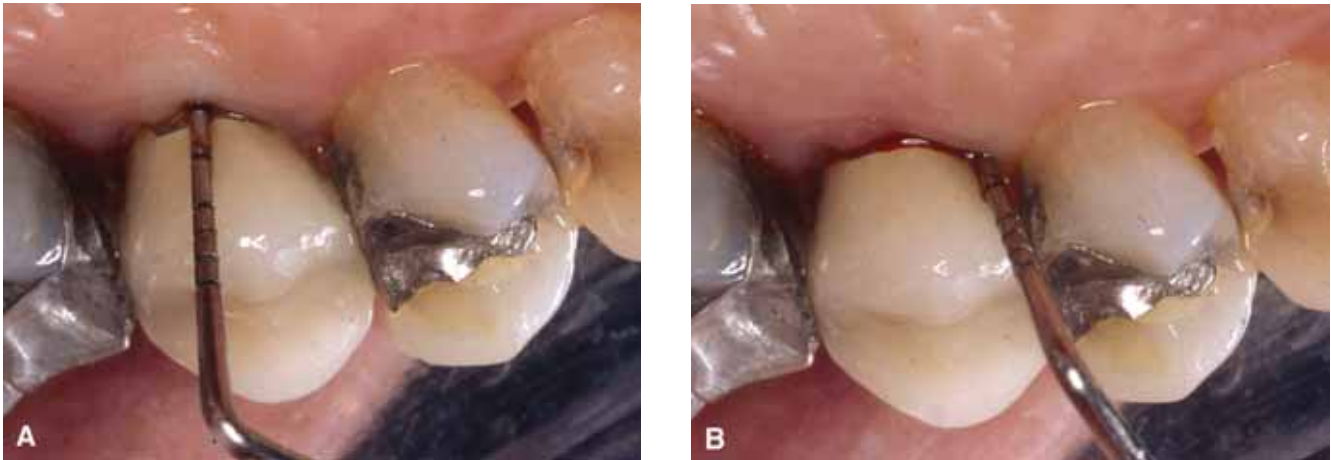##### 1. TECHNIQUE TO DOCUMENT BLEEDING ON PROBING

When bleeding is noted after probing several teeth, teeth that exhibit bleeding can be recorded at each probing site on the chart as a red dot above the probe depth. The percentage of sites that bleed can be calculated by dividing the number of bleeding sites by the number of total sites (where total sites equal the number of teeth present times six probe sites per tooth). Bleeding sites are charted in Figure 7-18, and a percentage has been calculated for four teeth.



**FIGURE 7-23.** Measurements to determine clinical attachment loss (level). **A.** First, the sulcus is probed (at 1 mm). **B.** Next, the level of the gingiva is determined with a positive number indicating gingival recession (at +1 mm from the dotted line, which is the CEJ). When the two numbers are added together, the amount of attachment loss is determined. In this case, the probing depth of 1 mm and the gingival level of + 1 (1 mm recession) results in an attachment loss of 2 mm.





**FIGURE 7-24.** Clinical example of probe placement and bleeding on probing (BOP). **A.** Midlingual (midpalatal) probe placement on tooth No. 13 showing 3 mm sulcus depth. **B.** Mesial probe placement on tooth No. 13 probed into the lingual embrasure. Note a 5 mm pocket at the site, which shows BOP.

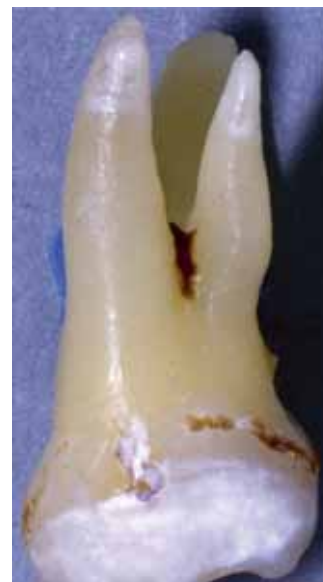## F. FURCATION INVOLVEMENT

A furcation is the branching point between roots on a multirouted tooth. In the absence of disease, furcations *cannot* be clinically probed because they are filled in with bone and periodontal attachment. With advancing periodontal disease, however, attachment loss and bone loss may reach a furcation area resulting in a **furcation involvement**.<sup>28,29</sup> Pockets that extend into the furcation create areas with difficult access for the dentist and dental hygienist to clean during regular office visits, and are a real challenge for patients to reach and clean during their normal home care. Therefore, these areas of furcation involvement readily accumulate soft plaque deposits and mineralized calculus (seen on an extracted tooth in Fig. 7-25). These deposits frequently become impossible to remove and may provide a pathway for periodontal disease to continue to progress.

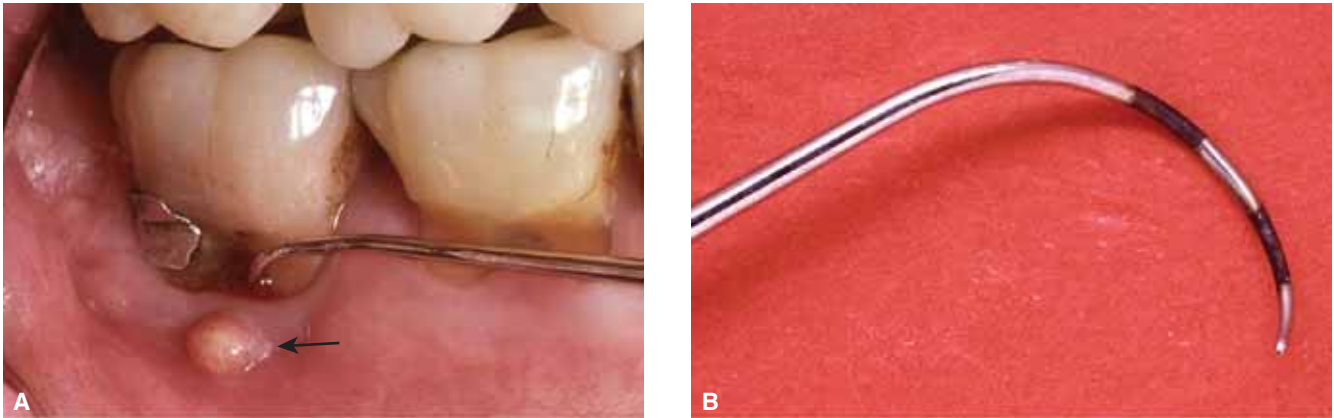
Initially, there may be an incipient (initial or beginning) furcation involvement. As disease progresses into the furcation (interradicular) area, attachment loss and bone loss will begin to progress horizontally between the roots. At that point, a furcation probe (such as a Nabor's probe with a blunt end and curved design) can probe into a subgingival furcation area. It can be used to detect the concavity between roots (Fig. 7-26). The first sign of detectable furcation involvement is termed **grade I** and can progress to a **grade II** involvement when the probe can hook the furcation roof (the part of the root forming the most coronal portion of the furcal area) as demonstrated in Figure 7-27A. In the most extreme circumstances, the furcation probe may actually extend from the furcation of one tooth aspect to the furcation on another tooth aspect. This is referred to as a

through-and-through (**grade III**) furcation involvement (Fig. 7-27B). (A summary of the grades of furcation involvement is presented later in Table 7-4.)

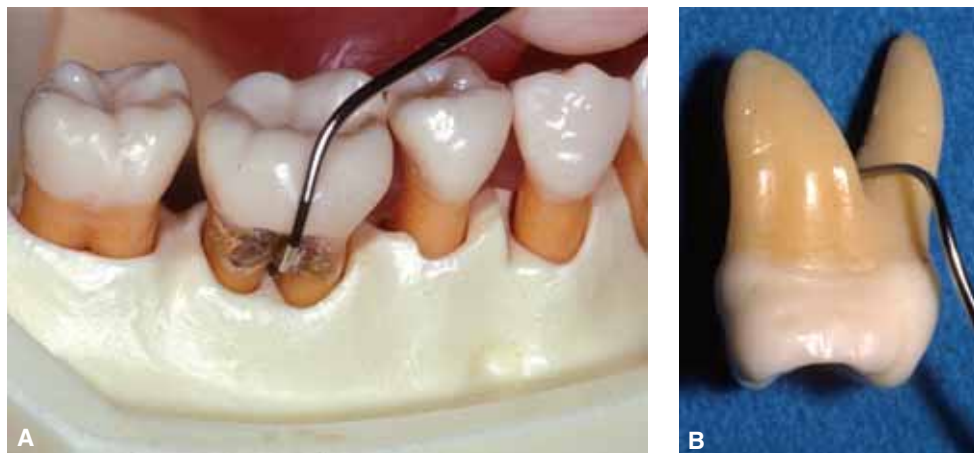
It is important to remember where to insert a probe in order to confirm furcation involvement (summarized in Table 7-3). Recall that *mandibular* molar furcations are located between mesial and distal roots near the middle of the buccal surface (midbuccal) and middle of the lingual surface (midlingual) as illustrated in Figure 7-28A



**FIGURE 7-25.** Calculus in the furcation area and root depressions. This extracted molar has mineralized deposits (calculus) in the furcation. Once disease progresses into the furcation area, access for removal by the dentist or dental hygienist becomes exceedingly difficult.



**FIGURE 7-26. Probing to check for furcation involvement.** **A.** Severe buccal furcation involvement on a mandibular second molar. The furcation probe is able to engage far into the interradicular area because of periodontal destruction. (Note the *arrow* pointing to an *abscessed area* indicating infection.) **B.** The furcation (Nabor's) probe has a rounded point and is curved to allow negotiation into furcations. It frequently has markings at 3-mm intervals (as shown here). This allows estimation of how far the probe horizontally penetrates into the furcation.

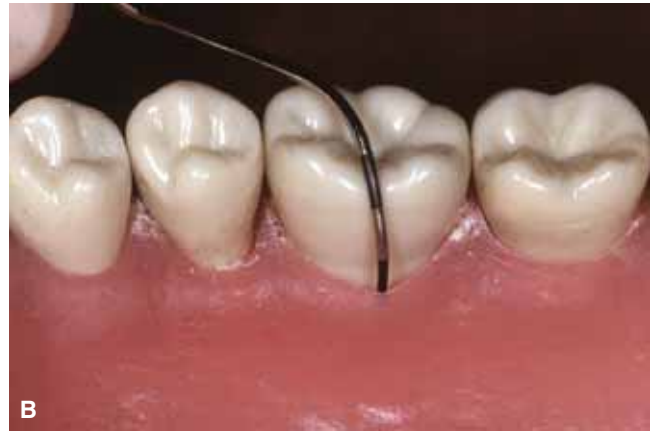
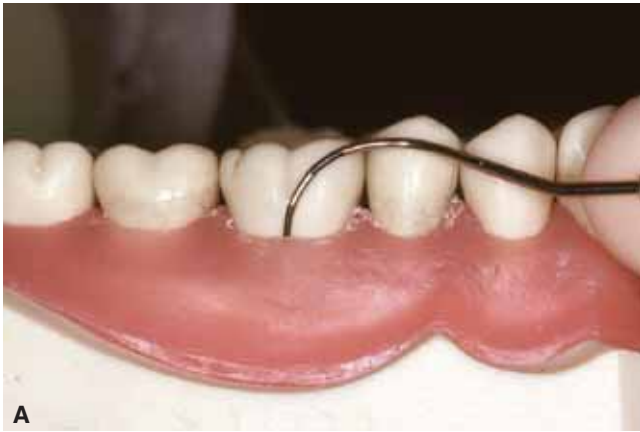
**FIGURE 7-27. Confirming furcation involvement.** **A.** The furcation probe is engaging the roof of a furcation but does not completely penetrate to the lingual entrance of the furcation. This would represent a grade 2 furcation involvement. **B.** The furcation probe engages the mesial furcation on a maxillary first molar. Note how close the furcation is to the mesiolingual (mesiopalatal) line angle of the tooth due to the wide mesiobuccal root.

**Table 7-3**    **NORMAL LOCATION OF FURCATIONS**

TOOTH TYPE	POTENTIAL FURCATIONS
Maxillary molars	Midbuccal Mesial (accessed from the lingual [or palatal]) Distal (accessed from the lingual [or palatal])
Mandibular molars	Midbuccal Midlingual
Maxillary premolars (with buccal and lingual roots)	Middle of mesial Middle of distal

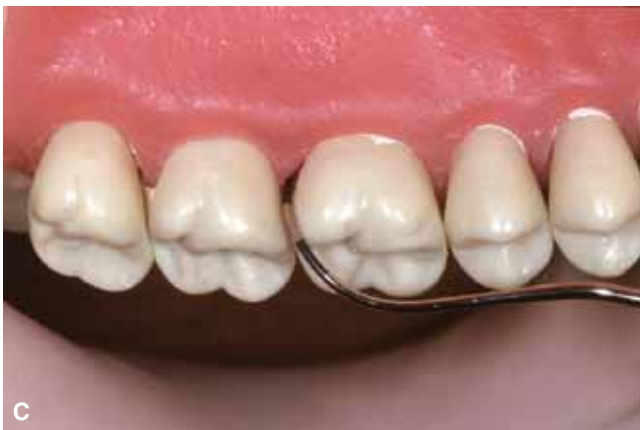
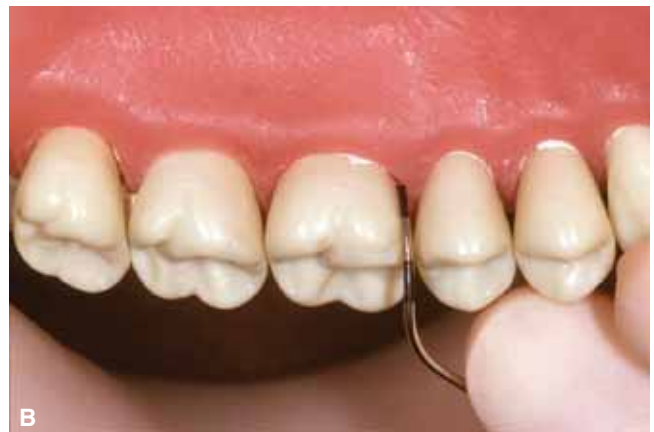
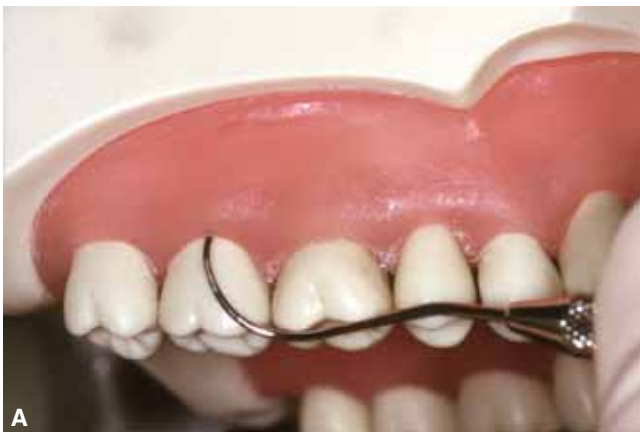

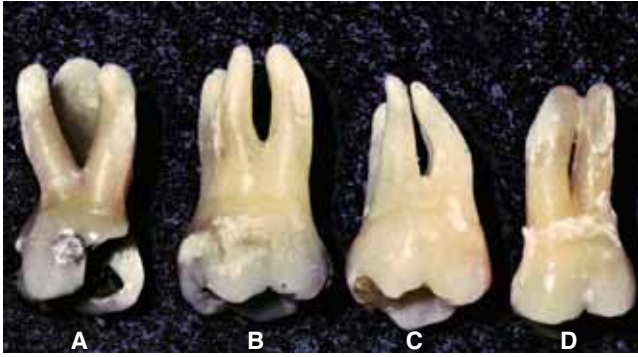
**FIGURE 7-28.** Two locations used to confirm **mandibular molar furcation involvement**. **A.** Buccal view: The mandibular buccal furcation is probed *midbuccally*. The probe is shown at the apical and horizontal extent of the penetration into the facial furcation. **B.** Lingual view: The mandibular lingual furcation is probed near the *midlingual*.

and **B.** Maxillary molar furcations are identified by probing midbuccal (between mesiobuccal and distobuccal roots (as seen in Fig 7-29A), mesially in the palatal (lingual) embrasure between the palatal and mesiobuccal roots as seen in Fig 7-29B, and distally between the palatal and distobuccal roots as seen in Fig. 7-29C.

Clinically, furcations located closer to the CEJ will become involved with periodontal disease more readily than more apically located furcations since less bone destruction is required to expose the more cervical furcation. However, more cervically positioned furcations are more easily treated by traditional periodontal therapy

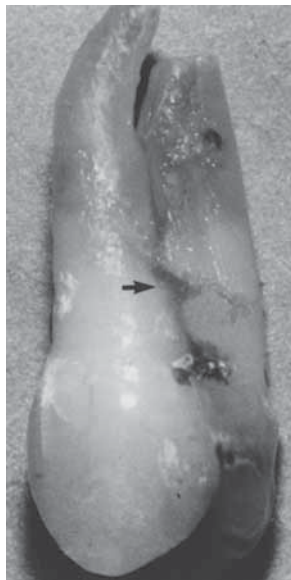


**FIGURE 7-29.** Three locations used to confirm **maxillary molar furcation involvement**. **A.** Buccal view: Buccal furcation is probed midbuccal. The furcation probe is shown as it enters the potential furcation near the middle of the facial surface of this maxillary molar. **B.** Palatal view: The mesial furcation on a maxillary molar is accessed through the palatal embrasure since the mesiobuccal root is wider than the palatal root. **C.** Palatal view: The distal furcation on a maxillary molar is probed through the palatal embrasure here, although the distobuccal root is about as wide as the palatal root.

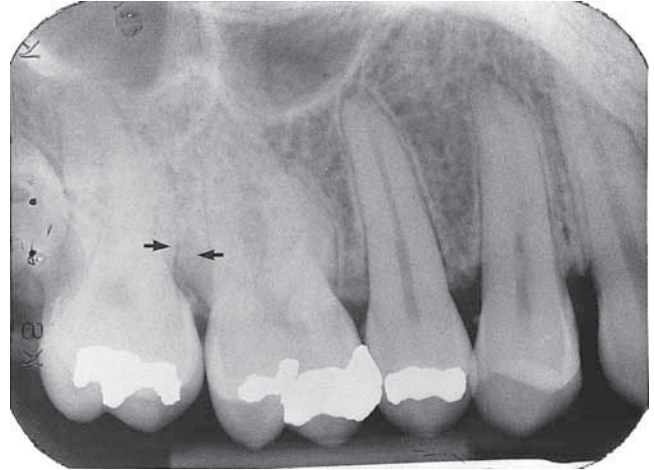


**FIGURE 7-30.** Variations in furcation location for maxillary molars. **A.** Divergent roots with the furcation in the coronal one third of the root with a short root trunk. **B.** Convergent roots with the furcation in the middle one half of the root with a longer root trunk. **C.** Very convergent roots. **D.** Fused roots with the furcation in the coronal one third of the root.

due in part to better access. Recall that furcations are closer to the CEJ on first molars (since their root trunks are shorter) than on second molars and closer to the CEJ on second molars than on third molars (Fig. 7-30). Once involved, the more apical the furcation, the more complex the treatment will become. The maxillary first premolar provides a good example of a furcation that is located nearer to the apex (Fig. 7-31). Proximal furcations, once they are involved with disease, are particularly difficult to gain access to because of vertical longitudinal depressions coronal to the furcation and



**FIGURE 7-31.** Calculus deposit (arrow) in the longitudinal depression on the mesial side of the root of a maxillary first premolar.



**FIGURE 7-32.** Radiograph showing close root approximation between the distal root surface of the maxillary first molar and the mesial root surface of the second molar (arrows). Furcations and concavities like these are virtually inaccessible when destruction occurs at those locations.

close approximation to adjacent teeth (seen in the radiograph in Fig. 7-32).

### 1. TECHNIQUE TO DOCUMENT FURCATION INVOLVEMENT

When probing into a potential furcation area, the furcation probe should be positioned into the gingival sulcus at the location around the tooth where the furcation is suspected. The probe should first be directed apically. When the base of the pocket is reached, the probe should be directed toward the tooth to see if it will engage the roof of the furcation. Figure 7-27A shows a probe engaging the roof of a furcation area. Deep horizontal penetration of the furcation probe indicates severe periodontal disease. The notation used to record each grade of furcation is summarized in Table 7-4, and examples of charting the degree of furcation involvement are presented in Figure 7-18. A caret ( $\vee$  or  $\wedge$ ) denotes beginning (incipient) involvement, an open triangle ( $\Delta$  or  $\nabla$ ) denotes moderate involvement, and a solid triangle ( $\blacktriangle$  or  $\blacktriangledown$ ) over the areas of the root denotes a through-and-through furcation involvement.

### G. LACK OF ATTACHED GINGIVA (PREVIOUSLY CALLED A MUCOGINGIVAL DEFECT)

In health, it is desirable to have at least a minimal width of keratinized gingiva that is firmly bound (attached) to the underlying tooth and/or bone. This band of

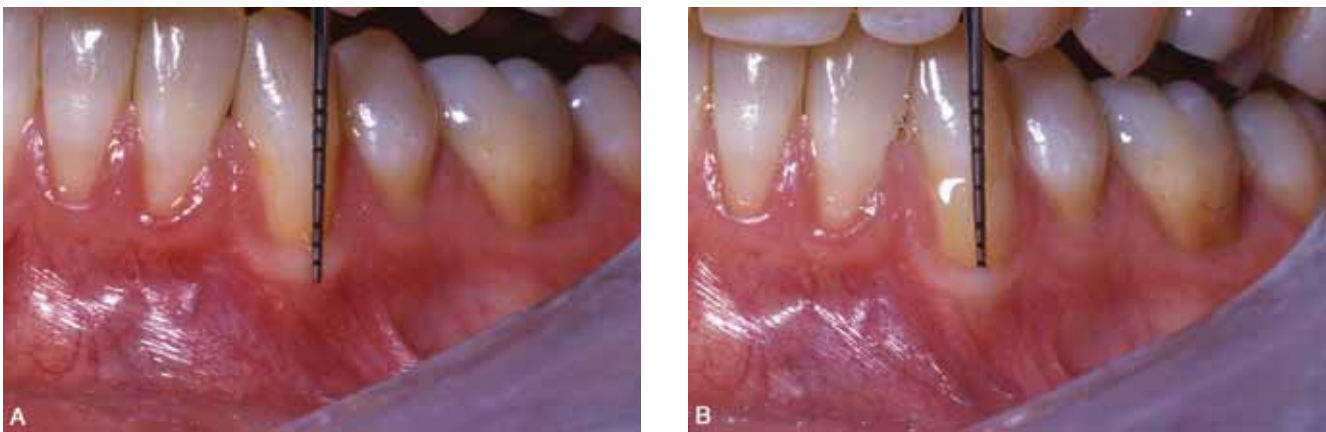Table 7-4 NOTATIONS FOR THREE CATEGORIES OF FURCATION INVOLVEMENT

FURCATION GRADE	NOTATION	BONE/ATTACHMENT LOSS	CLINICAL FINDING	CLINICAL EXPLANATION
Grade I: incipient	Caret: ∨ or ∧	No real bone loss and no attachment loss in furcation	Probe engages concavity	Probe locks horizontally; does not catch furcation roof
Grade II: moderate	Open triangle: Δ or ∇	Definite bone loss or attachment loss	Probe catches furcation roof	Probe hooks onto roof of furcation and must be rotated to disengage, but probe cannot be passed to another tooth aspect
Grade III: (through and through)	Solid triangle: ▲ or ▼	Complete bone loss with clinical attachment loss under the furcation roof	Probe can pass from one tooth aspect to another	

attached keratinized gingiva normally extends from the gingival groove (at the most apical extent of the gingival sulcus) to the mucogingival junction (recall Fig. 7-5). Alveolar mucosa apical to the mucogingival junction can be distinguished since it is readily moveable, more vascular (redder), less firm, and not keratinized. **Lack of attached gingiva** may place a tooth at risk for progressive gingival recession and is confirmed in the following three circumstances<sup>30</sup>:

1. Keratinized gingiva is present, but there is *no attached gingiva*. This condition is confirmed when the periodontal probe depth of the gingival sulcus reaches or exceeds (traverses) the level of the visible mucogingival junction indicating an absence of attached gingiva (Fig. 7-33A and B). In this case, keratinized gingiva may form part of the pocket wall, but it is not attached to the underlying structures as confirmed by the sulcus depth.
2. There is a visual *lack of keratinized gingiva*.
3. A flap of tissue (called a **frenum** seen in Fig. 7-2) that connects the tongue, lips, or cheeks inserts into the gingival tissues. There is a lack of attached gingiva around the tooth if there is *movement or blanching at the gingival margins* when tension is applied to the frenum (Fig. 7-34B).

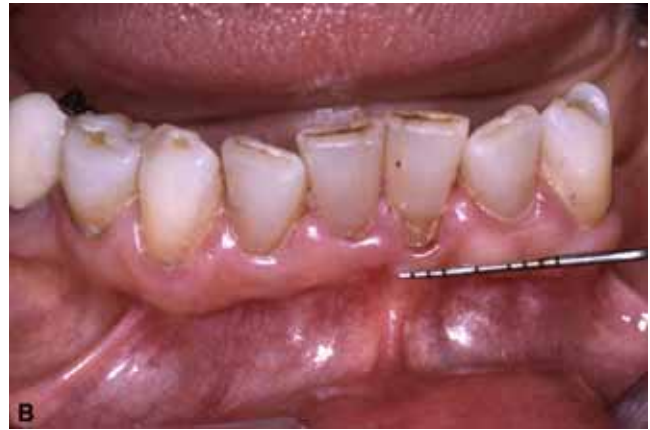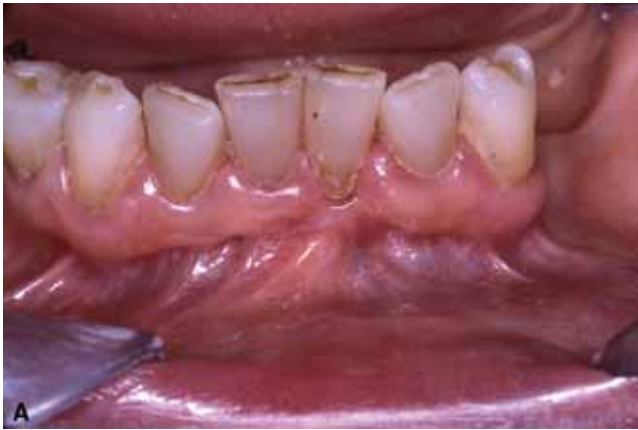Lack of attached gingiva can only occur on the surfaces of teeth where the keratinized gingiva is normally adjacent to movable alveolar mucosa—in other words, on the facial aspects of maxillary teeth and on the facial and lingual aspects of mandibular teeth. It is not likely for mucogingival defects to be present on the palatal aspects of maxillary teeth because the entire hard palate is keratinized and there is no alveolar mucosa. The only exception is when teeth are positioned so far posteriorly that they are near the mucosa of the soft palate.



**FIGURE 7-33.** Measuring to determine a lack of attached gingiva. **A.** The width of keratinized gingiva is measured at 2 mm.

**B.** The probe depth is measured at 1 mm indicating no mucogingival defect. In this case, if the probe depth had reached or exceeded 2 mm (the mucogingival junction), this would confirm that there is no attached gingiva.





**FIGURE 7-34. Visual test for a mucogingival defect.** **A.** A loss of attached gingiva is suspected at tooth No. 24, which has a very narrow zone of keratinized gingiva. **B.** The periodontal probe is positioned *at the mucogingival junction* and moved incisocervically against the mucosa. Blanching or movement *at the gingival margin* is indicative of a mucogingival defect.

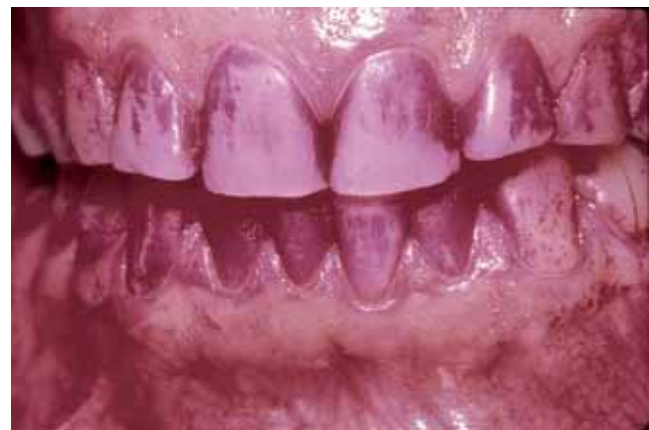### 1. TECHNIQUE FOR DETERMINING LACK OF ATTACHED GINGIVA

Both visual observations and measurements are required for detecting a lack of gingival attachment. In the *visual* method, a mucogingival defect is confirmed when a periodontal probe is moved incisocervically (or occlusocervically) as it is pressed gently against the tissue surface at the mucogingival line, and movement or blanching occurs *at the margin* (Fig. 7-34B). When using *measurements*, first measure the width of keratinized gingiva from the gingival margin to the mucogingival junction. Then place the periodontal probe within the gingival sulcus, and if the periodontal probe depth reaches or exceeds the width of keratinized tissue, a mucogingival defect is confirmed. See a clinical example using measurements to confirm a mucogingival defect in Figure 7-33A and B. This can be charted as a horizontal wavy line placed over the root apical to recession readings (seen in the chart in Fig. 7-18).

### H. THE PLAQUE SCORE (INDEX)

**Bacterial dental plaque** (biofilm) is a thin layer containing organized microorganisms that loosely adheres to teeth, but it can be removed with proper tooth brushing and flossing. It is an almost invisible layer that accumulates on teeth in the absence of excellent oral hygiene. Therefore, utilizing a mechanism to identify the location of this nearly invisible plaque can be helpful when teaching plaque removal techniques, and when monitoring a person's success using specific oral hygiene techniques designed to reduce and eliminate his or her plaque.

The metabolism of these attached, organized colonies of microorganisms contributes to the inflammation of gingival tissue associated with gingivitis, the destruction of bone and periodontal ligament associated with periodontitis, and the destruction of mineralized tooth structure during the formation of dental decay (dental caries). Many factors contribute to plaque retention, including tooth malpositions and malformations, the irregular surface of advancing dental caries (decay), defective restorations, and accumulation of calculus (tartar).



**FIGURE 7-35. Dental plaque.** This photograph shows dental plaque after staining with *disclosing solution*. The patient had voluntarily ceased oral hygiene measures for 4 days. Plaque is most prominent at interproximal sites and the cervical third of crowns, areas that are not self-cleaning (i.e., are not easily cleaned by the natural rubbing action of the cheeks, lips and tongue). Also note the heavy plaque accumulations on the mandibular anterior teeth that are slightly malpositioned.

### 1. TECHNIQUE TO DETERMINE (CALCULATE) A PLAQUE SCORE (INDEX)<sup>31</sup>

Plaque can be stained with **disclosing solution**, a dye that is absorbed by bacterial plaque (Fig. 7-35). When this solution is swished in the mouth, four tooth surfaces of each tooth can be evaluated for the presence of the stained plaque: mesial, facial, distal, and lingual. The **plaque index** is calculated as the percentage of

sites with plaque divided by the total sites (number of teeth times four). Note: Disclosing solutions should not be used until periodontal measurements and the oral physical exam have been made and reviewed since the color change to oral tissues from the solution may influence the ability to observe the initial findings. A charting example of plaque score calculation is presented for four teeth in Figure 7-18.

## SECTION V

### RELATIONSHIP OF PERIODONTAL DISEASE AND RESTORATIONS (FILLINGS)

A healthy **biologic width**<sup>32</sup> of attached gingiva (known as the **dentogingival junction**) includes the junctional epithelium (about 1 mm wide), as well as a band of connective tissue fibers (about 1 mm wide) attaching the gingiva to the cementum. Care must be taken when restoring teeth to protect this biologic width of attachment. If a restoration encroaches into the attachment, it could be a factor in initiating periodontal disease (periodontitis/bone loss/attachment loss), gingival recession, or chronically inflamed gingival tissue. Further, it is usually recommended that the margins of artificial crowns and inlays be kept at least 3 mm from the osseous crest. Therefore, if a restoration is to be placed to restore an area of decay that has destroyed tooth structure very close to bone, it is advisable to perform a surgical

procedure called **crown lengthening** to ensure that the restoration does not encroach on the biologic width. This is especially critical on teeth where esthetics is a factor. **Clinical crown lengthening** is a procedure that increases the extent of supragingival tooth structure by removing gingival tissue or apical positioning gingival tissue, and usually removing some supporting bone.

Further, a defective restoration, especially one that is overcontoured or is not flush with the tooth structure, may retain bacterial plaque more readily, so it could be an initiating factor for periodontal disease. Therefore, it is always important to keep in mind that when teeth must be restored, ideal tooth contours, as have been discussed in the earlier chapters of this text, should be reproduced.

## SECTION VI

### RELATIONSHIP OF TOOTH SUPPORT AND ROOT MORPHOLOGY<sup>33</sup>

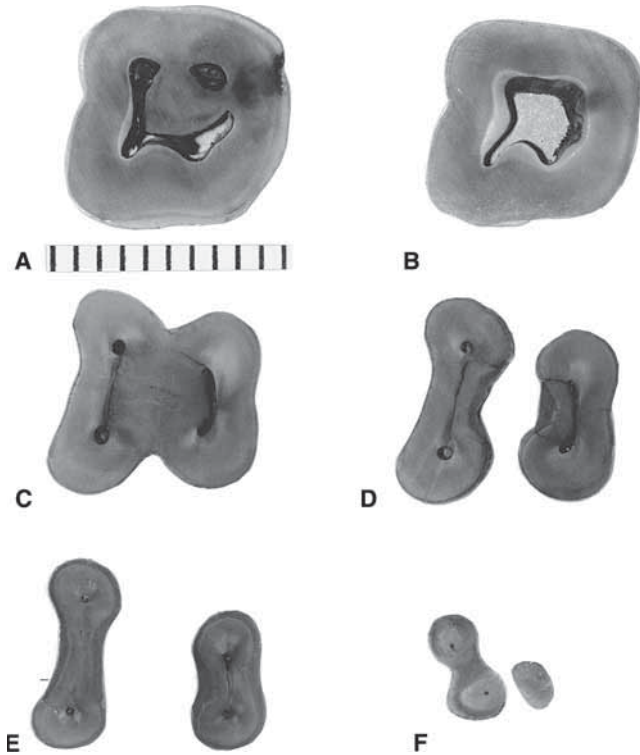
The area of root attachment is of primary importance to the stability and health of a tooth. Root attachment area depends on root length, the number of roots, and the cross-sectional diameter of the root from the CEJ to the apex. It also depends on the presence or absence of concavities and other root curvatures (Fig. 7-36). These features greatly influence the resistance of a tooth to occlusal and other forces, particularly when they are applied in a lateral (buccolingual) direction.

In health, prior to periodontal disease, connective tissue fibers insert into cementum on the entire root surface. This attachment includes the insertion of the gingival fibers (coronal to the bone level) near the CEJ, and periodontal ligament fiber insertions along the majority of the root. Long roots and wide cross-sectional tooth diameters increase support. Concavities and other

root curvatures increase periodontal support in two ways. First, they increase the total surface area. Second, the concave configuration provides multidirectional fiber orientation, which makes the tooth more stable and resistant to occlusal forces. For example, a root with a mesial concavity is more resistant to buccolingual forces than a tooth that is conical or convex (Fig. 7-36). Vertical and longitudinal depressions and concave areas occur commonly on the mesial and distal root surfaces of many anterior and most posterior teeth (as described in earlier chapters). More coronally located root depressions are also found on the mesial surface of maxillary first premolars (both on the root and crown) and on molar root surfaces just coronal to furcations.

Likewise, multirooted teeth have increased support and resistance to applied forces. For those teeth, the

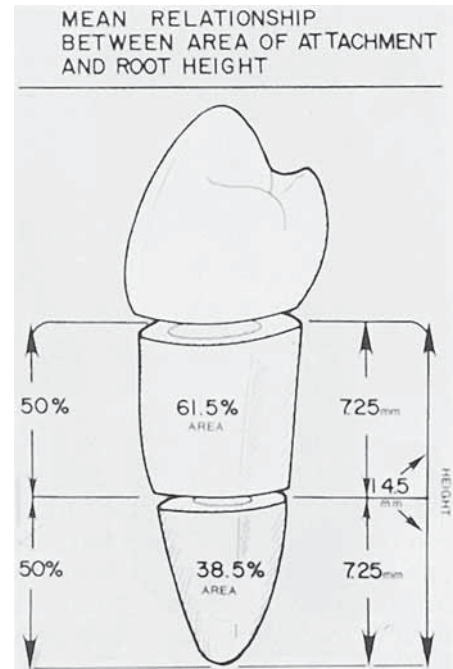




**FIGURE 7-36.** Series of stained **cross sections of a root** of a lower first molar from the crown to near the apices. For each section, the mesial aspect is left, the lingual aspect is at the top, the distal aspect is right, and the buccal aspect is toward the bottom. There is a 10-mm scale between the top and the middle section on the left. **A.** Cross section through the cervical of the crown showing enamel, dentin, and pulp. (Decay is evident distally—on the right.) **B.** Cross section near the CEJ. Note the shape of the pulp chamber. **C.** Cross section of the root trunk slightly coronal to the bifurcation (furcation). Buccal and lingual depressions are coronal to the entrances to the bifurcation. **D.** Cross section of mesial and distal roots slightly apical to the bifurcation. Note the root canals in both roots. Thickened cementum (darkly stained) is apparent on the furcal aspect (between the roots). **E.** Cross section of roots 4 mm apical to the bifurcation. There are pronounced concavities on the mesial aspect of the mesial root and the furcal aspects of both roots. **F.** Cross section of the roots near the apex. The mesial (left) root is longer. The complex shape of molar roots helps provide a greater surface area of attachment and greater tooth stability but becomes a problem to treat during progressive periodontal disease.

location of the furcation is important; the more coronal it is, the more stability is afforded. Additionally, convergence or divergence of roots influences support. Divergent roots increase stability and allow for more interradicular bone support (recall Fig. 7-30).

Another important factor for determining tooth stability is the degree of root taper. Teeth with conical roots, such as mandibular first premolars, tend to have the majority of their root area (>60%) in the coronal



**FIGURE 7-37.** Relationship between the area of attachment and root length for a mandibular first premolar.

Approximately 60% of the root area is present in the coronal 50% (one half) of the root, with only 40% of the area present in the apical one half of the root. These determinations were made by measuring the areas of many serial cross sections of tooth roots similar to those shown in Figure 7.36. (Courtesy of Alan R. Levy, D.D.S.)

half of the root, and much less area (only about 40%) in the apical half of the root (Fig. 7-37).<sup>34</sup> The degree of root taper influences the support once periodontal disease has occurred. A conical root that has lost only 50% of the bone height may have lost more than 60% of its periodontal ligament. This is because a smaller proportion of the root area is present near the apex. For severely conical roots, the apical half of the root may account for even less attachment area than seen in Figure 7-37.

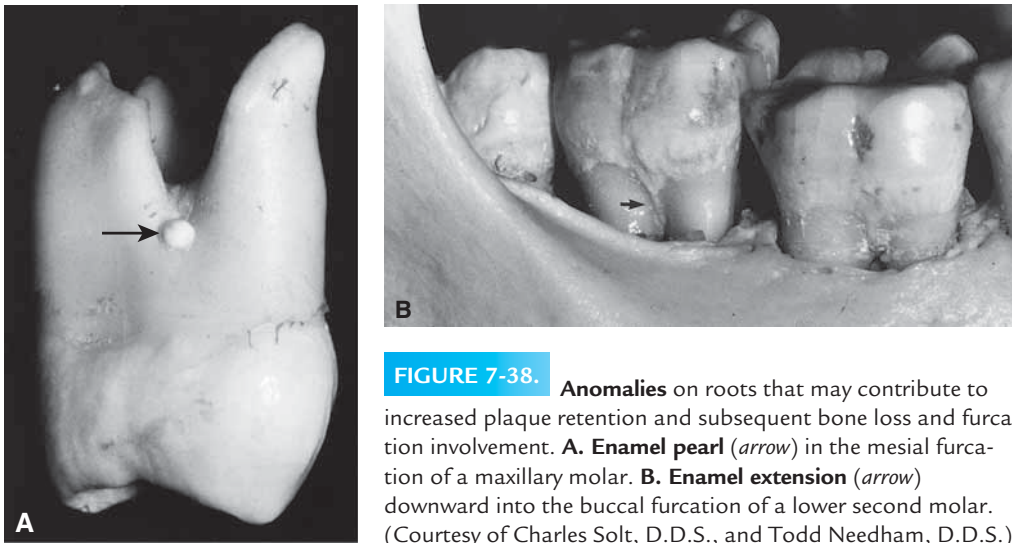
Based on root area alone, one would generally expect to find the maxillary canine to be the most stable single-rooted tooth, and the mandibular central incisors to be the least stable. For posterior teeth, one would expect maxillary first molars, with their three divergent roots, to be more stable than third molars, which frequently have fused roots. While these rules generally apply, additional factors, such as the presence or absence of inflammatory periodontal disease and excessive occlusal forces, may greatly influence tooth stability. Also, the density and structure of the supporting bone have an influence on tooth stability.

## SECTION VII

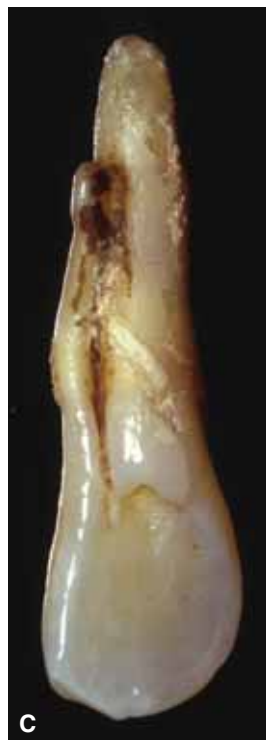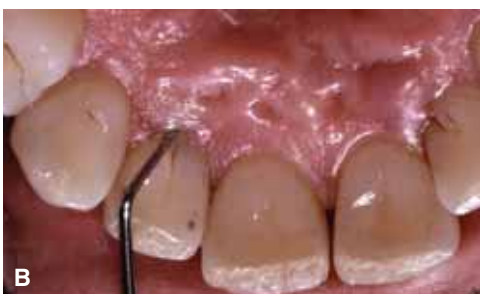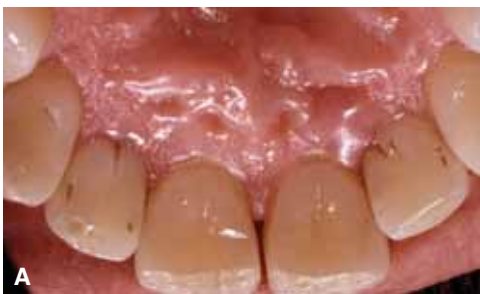## INFLUENCE OF ROOT ANATOMY AND ANOMALIES ON THE PROGRESSION OF PERIODONTAL DISEASE

Although furcations, concavities, vertical depressions (grooves), and other root curvatures tend to increase the area of attachment, making the tooth resistant to occlusal forces, these root anatomy features may also become areas where forces are concentrated. This occurs because the root curvature and the correspond-

ing bone and periodontal ligaments that conform to these areas permit the tooth to compress against periodontal ligament and bone in a variety of directions. Furthermore, these areas are more plaque retentive and more difficult to clean once periodontal disease progression reaches them.



**FIGURE 7-38.** Anomalies on roots that may contribute to increased plaque retention and subsequent bone loss and furcation involvement. **A. Enamel pearl** (arrow) in the mesial furcation of a maxillary molar. **B. Enamel extension** (arrow) downward into the buccal furcation of a lower second molar. (Courtesy of Charles Solt, D.D.S., and Todd Needham, D.D.S.)



**FIGURE 7-39.** Radicular palatal grooves (palatal gingival grooves). **A.** Indentation on the lingual surface of both maxillary lateral incisors. **B.** Periodontal probe in place showing a deep periodontal pocket formed where the groove extends apically on the root. **C.** Groove extending apically on the midpalatal aspect of a maxillary canine. The tooth was extracted because of severe periodontal disease on the palatal aspect. (Courtesy of Leonard K. Ebel, D.D.S.)

There are several types of defects in the root structure that weaken periodontal attachment and are potential areas for periodontal disease to develop.<sup>35</sup> *Enamel pearls* are present most often on maxillary molars, and *enamel extensions* frequently occur on mandibular molars (Fig. 7-38). Both prevent a normal connective tissue attachment and may channel disease

into the furcation area. *Radicular palatal grooves* (palatal gingival grooves) occur on maxillary incisors and readily collect and retain plaque, which can frequently lead to periodontal destruction (Fig. 7-39). Root fractures also predispose periodontal destruction (loss of attachment of the periodontal ligament) along the fracture line.

## SECTION VIII

## PERIODONTAL DISEASE THERAPIES<sup>36-38</sup>

Currently, a wide range of techniques is available to treat periodontal problems. Nonsurgical periodontal therapy traditionally requires effective **root planing** [PLAY ning] (i.e., removal of calculus and smoothing of the root using specially designed dental instruments), oral hygiene instructions, and the use of systemically administered antibiotics. Sustained-release antimicrobial and antibiotic agents can be locally administered to affected sites. Additionally, agents that prevent breakdown in connective tissue (anti-collagenases) are being prescribed for systemic use.

When moderate to severe periodontal disease or lack of attached gingiva are confirmed, periodontal surgery may be indicated. There are several surgical approaches used to treat periodontal disease. Conservative surgical therapy is designed to gain access to the root surface for debridement.<sup>39</sup> **Resective periodontal surgery** is a surgery involving the removal and/or recontouring of the gingiva, supporting bone or root, and is performed to correct some of the results of periodontal diseases by removal of soft and hard tissue components of the pocket wall. Resective techniques include **gingivectomy** (i.e., removal of some gingiva by using either the conventional scalpel or, more recently, the laser<sup>40</sup>), **root resection** to remove periodontally involved roots on multirouted teeth,<sup>41</sup> and **periodontal flaps** with osseous (bone) surgery.<sup>42</sup> Resective periodontal surgery usually results in gingival recession with improved access to previously diseased

sites. **Regenerative periodontal surgery** is intended to form new cementum, new bone, and a new functionally oriented periodontal ligament. Recent advances in the area of periodontal regeneration involve three basic strategies. In **guided tissue regeneration**, a resorbable or nonresorbable membrane (barrier) is placed over periodontal defect to provide a matrix for regenerative cells to migrate from the periodontal ligament and bone. **Bone grafting** materials, both synthetic and from the patient or from donors, create a scaffolding for new bone and may provide growth factors that induce bone regeneration. **Chemical treatment** of the root detoxifies the root surface and may allow the application of growth factors that induce the formation of new cementum.

Periodontal plastic surgery includes soft-tissue reconstructive techniques such as **connective tissue grafts** designed to treat loss of attached gingiva and to cover roots that have been exposed through gingival recession,<sup>43</sup> and **clinical crown lengthening** techniques to create esthetic tooth lengths and ideal gingival contours and to allow for restoration.<sup>44,45</sup>

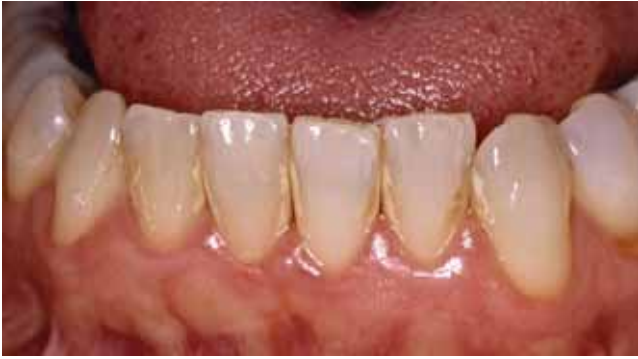The specialty of periodontics also includes preimplant surgery, which includes augmentation and regeneration of hard or soft tissues prior to dental implant placement, placement of dental implants, and treatment of inflammation of tissues surrounding the implant (peri-implant mucositis and peri-implantitis).

## SECTION IX

## THE INFLUENCE OF ROOT ANATOMY ON PERIODONTAL INSTRUMENTATION, ORAL HYGIENE INSTRUCTION AND PERIODONTAL MAINTENANCE

Bacterial plaque *that has just formed* can easily be removed from accessible crown and root surfaces with a toothbrush and dental floss. However, if it is not removed frequently, it can calcify to form a hard, complex mineral layer called **dental calculus** (tartar) that firmly attaches to the tooth. In the supragingival environment (coronal to the gingival margin), saliva

is the calcium source forming a yellow-white mineralized deposit on the teeth (Fig. 7-40). In the subgingival environment, products from blood and tissue fluids contribute to the calcification process and the deposits are dark brown (Fig. 7-41). It is the job of the dental professional to remove these calcified deposits, both supragingivally and subgingivally, and to teach patients



**FIGURE 7-40.** Supragingival calculus (coronal to the gingival margin) has saliva as the calcium source forming a yellow-white mineralized deposit on the teeth.

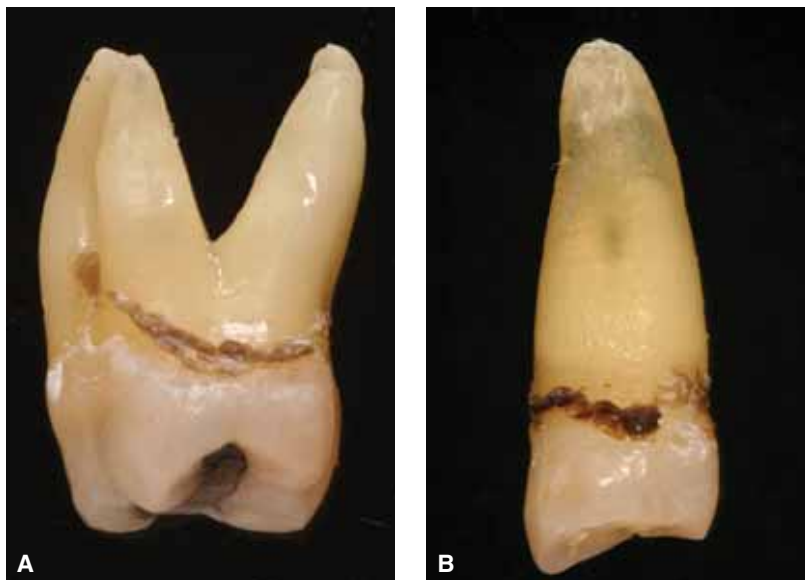
how to prevent formation of these deposits by using excellent oral hygiene techniques.

The objective of **instrumentation** of the *anatomical crown* (called a **dental prophylaxis**) is to use specifically designed dental instruments (such as **scalers** [SKAY lerz] and **curettes** [kyoo RETS]) to remove dental calculus, bacterial plaque, and stain that form on tooth surfaces. Supragingival calculus that forms on the anatomic crown of the tooth is easier to remove than subgingival deposits on roots for several reasons. First, hard deposits on crown surfaces are more visible and are readily accessible when using dental instruments. Soft deposits of plaque are relatively easy to remove on these surfaces by using excellent brushing and flossing techniques. Crown surfaces where calculus forms near the gingiva are *mostly* convex, which are easier to clean than the complex contours of roots, especially those on posterior teeth that are multirooted. Finally, crowns are

covered with enamel that is the hardest substance in the body (95% calcified). Enamel is nonporous, so damage or removal of this tissue during instrumentation is not as likely as removal of cementum that is much less hard (less than about 65% calcified) and more porous.

When periodontal disease progresses to a point where there is attachment loss, the normal insertion of connective tissue fibers into cementum is lost. In this subgingival environment, bacteria and their products, including plaque, dental calculus, and bacterial products, absorb into irregularities on the root surface and hold onto the biofilm, increasing the chance for plaque retention and periodontal disease activity. Loss of periodontal support of the bone and ligament exposes complex root surfaces, creating a challenge for dental professionals to clean (instrument) and for patients to maintain. Areas of *deep* pocketing are difficult to access, and a tight (fibrotic) pocket may impede access to the deepest sites.

**Instrumentation** on the *root surface* requires removal of plaque and calculus on the root and, most significantly, requires the removal of calculus, plaque, and bacterial products that were deposited into the irregularities in cementum exposed to the oral environment during periodontal disease. This may require removal of some, but not all, of the cementum resulting in a cleaner and smoother surface. This process is known as **periodontal scaling and root planing** [PLAY ning]. Periodontal scaling and root planing is a treatment procedure designed to remove cementum or surface dentin that is rough, impregnated with calculus, or contaminated with toxins or microorganisms. While root planing makes the root clean, care must be taken, especially on exposed root surfaces, to avoid overinstrumenting the root resulting in a compromise in root structure (recall Fig. 7-8).



**FIGURE 7-41.** Subgingival calculus. **A.** On a maxillary first molar, calculus that formed in the subgingival environment is dark brown because elements of blood were incorporated during calcification. Additionally, some of the bacteria that are formed in calculus produce pigment. It can be seen here on surfaces where it most commonly forms and is often missed during periodontal instrumentation: near the CEJ, at line angles, in grooves (the concavity just coronal to the buccal furcation) and furcations. **B.** Calculus at and apical to the CEJ on a premolar.



The irregularities in cementum and dentin provide a challenge during instrumentation. This challenge is generally addressed by using **ultrasonic instrumentation**, that is, instruments that use high-frequency vibrations to dislodge calculus and break apart bacterial cell walls. A combination of hand instruments and ultrasonic instruments can be used to remove a small portion of the affected cementum through root planing.

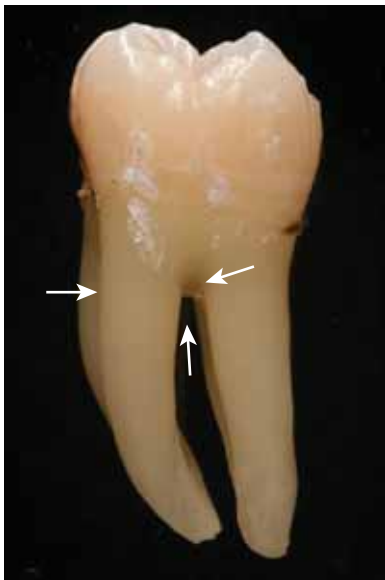Several areas of the root have been identified as the most difficult to instrument and as common areas for dental calculus to be left following periodontal instrumentation.<sup>31</sup>

1. The CEJ is difficult to instrument because, although accessible, the irregularities in the surface where enamel and cementum come together make it plaque retentive. Due to these irregularities, calculus is frequently confused with the CEJ (Fig. 7-41A and B)
2. Concavities (grooves) that appear at numerous locations on the root surface are challenging areas for periodontal instruments to access. Concavities are most prominent on the mesial aspect of the crown and root of maxillary first premolars, the mesial aspects of mandibular first molars, and root areas just coronal to all furcations (Fig. 7-42). Grooves can also be the result of unusual tooth formation (Fig. 7-39).
3. Furcations present very unusual challenges to instrument. Before periodontal disease begins on multirrooted teeth, the periodontal attachment is intact so furcations are not exposed to the oral environment. With advancing periodontal disease

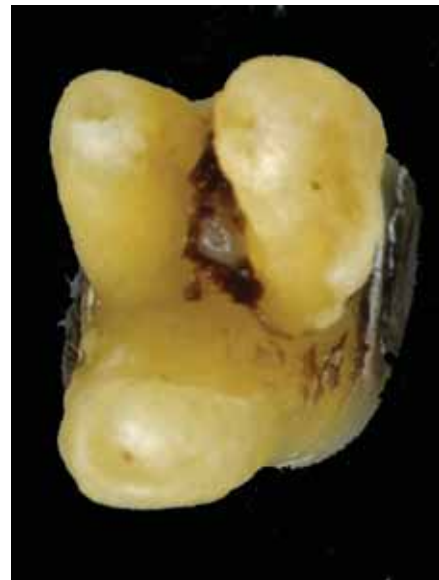and bone loss, once furcations (deep within gingival pockets) become exposed to plaque, it becomes difficult to gain access for root planing. It is frequently impossible to reach these areas with dental instruments, and even ultrasonic instruments may not be able to negotiate into deep furcations. The maxillary trifurcation area is the most challenging site (Fig. 7-43). Additionally, the furcal areas (interior aspects between the roots) of molars frequently have concavities (depressions), further complicating access for instrumentation (Fig. 7-42). Furthermore, sometimes the roots of multirrooted teeth are in close approximation, making access with hand instruments impossible and access with ultrasonic scalers difficult (Fig. 7-44A). Reaching all root surfaces with instruments in order to remove deposits and clean root surfaces that have furcation involvement and concavities requires a special knowledge of root anatomy and advanced clinical skills. Imagine following the sequence and angulations required for thoroughly removing deposits on the roots of a mandibular molar as demonstrated in *Figure 7-45* when the furcation contours and root concavities are “hidden” from view within deep pockets. Periodontal surgery is recommended for teeth with deep periodontal furcations.

4. Tooth contours at the line angles are also difficult to access.

**Follow-up for patients who have had periodontal disease:** Patients who have had periodontal disease are at risk for having recurrent periodontal disease. After

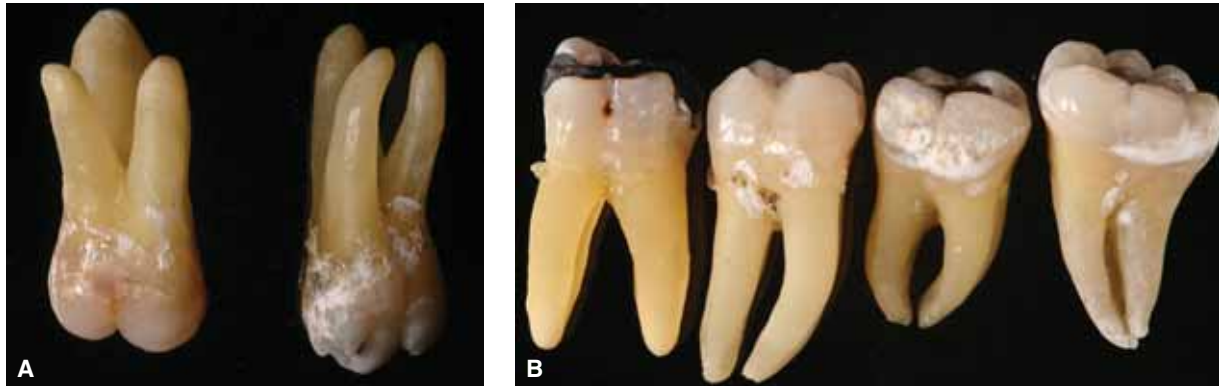

**FIGURE 7-42.** Mandibular first molar showing concavities (arrows) on the distal surface of the distal root, the furcal (interior) aspect, and the root trunk just coronal to the furcation.



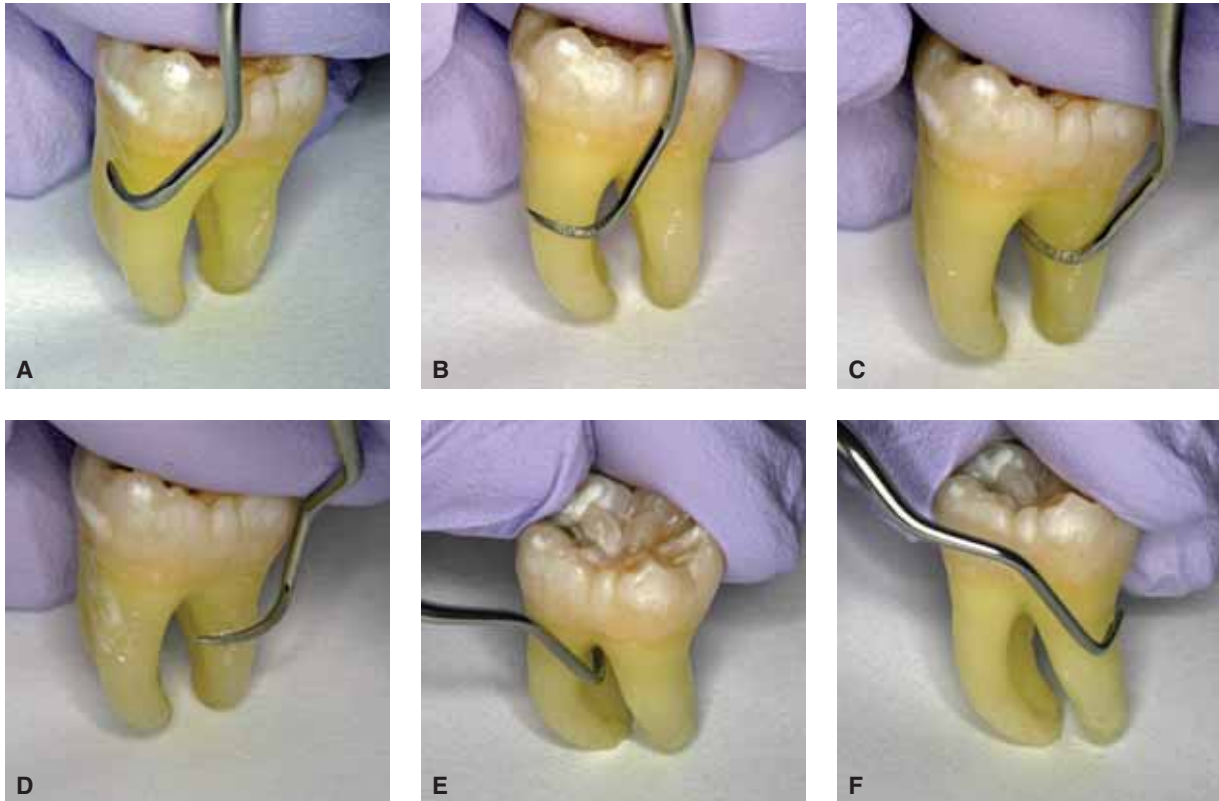
**FIGURE 7-43.** View of the furcation of a maxillary first molar from the root apices. With severe periodontal disease, calculus can form in the trifurcation and would be impossible to remove.





**FIGURE 7-44.** Molars showing varying degrees of divergence. **A.** Maxillary molars with divergent and convergent roots.

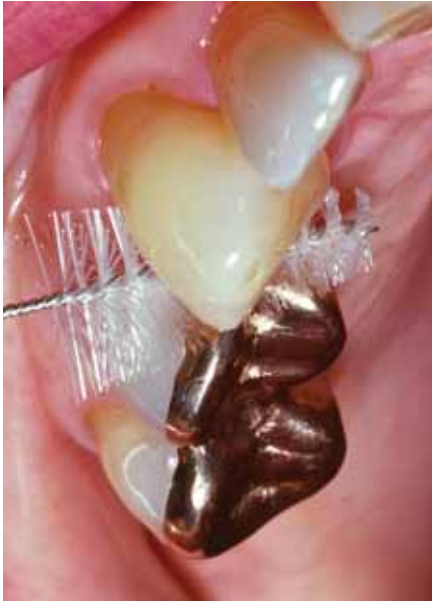**B.** Mandibular molars from left to right: roots divergent, straighter roots, convergent roots, and fused roots. When the distance between roots is less than 1 mm, it is impossible to negotiate into the furcation areas with hand instruments. Ultrasonic instruments are more effective for instrumenting into furcation areas.



**FIGURE 7-45.** Instrumentation of complex root surfaces on a mandibular first molar. (Ultrasonic scalers are more effective in furcation areas.) Imagine cleaning these areas thoroughly if they were hidden deep within a gingival pocket. **A.** Mesial surface of mesial root (using a Gracey 15/16 curette). **B.** Facial aspect of mesial root (Gracey 15/16 curette). **C.** Furcal aspect of distal root (Gracey 15/16 curette). **D.** Facial aspect of distal root (Gracey 15/16 curette). **E.** Furcal aspect of distal root (Gracey 13/14). **F.** Distal aspect of distal root (Gracey 13/14).

periodontal therapy or as a consequence of periodontal disease progression, there may be substantial gingival recession. **Periodontal maintenance** procedures (formerly referred to as supportive periodontal therapy [SPT], preventive maintenance and recall maintenance)

are performed by dental professionals at selected intervals (usually 3 months) to assist the periodontal patient in maintaining oral health.<sup>1</sup> Once exposed to the oral environment, complex root surfaces require more time for dental professionals to clean and a greater challenge



**FIGURE 7-46.** Interproximal brush. When periodontal disease or gingival recession results in loss of interdental papillae, special brushes may be used to cleanse the interproximal areas and help clean tooth concavities.

for patients to keep clean between periodontal maintenance appointments. Exposed root surfaces are more plaque retentive than enamel surfaces and a greater tooth surface area that must be cleaned.

Once periodontal disease has occurred, the patient's ability to clean root surfaces also presents a special challenge. The toothbrush and dental floss cannot reach into deep pockets, tooth concavities, and furcations. Special oral hygiene aids, such as interproximal brushes, end-tufted brushes, and rubber tips, must supplement the basic oral hygiene aids of toothbrush and floss (Fig. 7-46). Even with appropriate aids, patients frequently do not have the motivation or dexterity to maintain these difficult to access areas.

Patients may have tooth sensitivity due to conduction of sensations through the dentinal tubules to the nerves in the pulp (especially through foods and liquids that are cold). Therefore, **desensitizing agents** may need to be used during periodontal maintenance. Additionally, exposed root surfaces are prone to **root decay** (caries), a problem common in older patients, especially those on medications that make the mouth dry and reduce the amount of saliva (xerostomia).

## Review Questions

Unless stated otherwise, each item may have more than one correct answer.

- Which of the following descriptors apply (applies) to normal, healthy gingiva?
  - Coral pink or pink with masking melanin
  - Resilient
  - Stippled
  - Spongy
  - Knife edged in profile
- Which of the following locations is likely to have a root furcation?
  - Buccal of the root of the maxillary molar
  - Buccal of the root of the mandibular molar
  - Mesial of the root of a maxillary molar
  - Distal of the root of a mandibular molar
  - Lingual of the root of a mandibular molar
- Which maxillary tooth has its furcation closest to the cervical line of the tooth (only one correct answer)?
  - First premolar
  - Second premolar
  - First molar
  - Second molar
  - Third molar
- What is the clinical attachment loss of a tooth with +2 mm of gingival recession and a 4 mm pocket? (There is only one correct answer.)
  - +2 mm
  - +6 mm
  - 6 mm
  - 2 mm
- Which of the following periodontal fibers attach to cementum and alveolar bone?
  - Horizontal
  - Oblique
  - Transseptal
  - Apical
  - Alveolar crest
- Which of the following are likely indications of periodontal disease?
  - Bleeding gums
  - Loss of bone
  - Category 3 mobility
  - Mucogingival stress
  - Gingival sulcus readings of 3 mm

7. The furcations are likely to be farthest away from the cervical portion of the tooth in which ONE of the following teeth?
  - a. Mandibular first molar
  - b. Mandibular second molar
  - c. Mandibular third molar
  - d. Maxillary first molar
  - e. Maxillary second molar
8. Which of the following is (are) considered as root anomalies?
  - a. Furcation
  - b. Cingulum
  - c. Radicular palatal groove
  - d. Occlusal fissure
9. What phrase best defines a pseudopocket?
  - a. Gingival margin is located coronal to the CEJ
  - b. Gingival margin is located apical to the CEJ
  - c. The distance between the gingival margin and CEJ
  - d. The distance between the gingival margin and furcation
10. Which of the following may occur with clinical attachment loss?
  - a. Loss of bone
  - b. Exposed root surface
  - c. Furcation involvement
  - d. Exposed root concavities
11. What is (are) included into nonsurgical periodontal therapy?
  - a. Scaling
  - b. Root planing
  - c. Oral hygiene instructions
  - d. Application of local antibiotic agents

ANSWERS: 1—a, b, c, e; 2—a, b, c, e; 3—c; 4—b; 5—a, b, d, e; 6—a, b, c, d; 7—c; 8—c; 9—a; 10—a, b, c, d; 11—a, b, c, d

## Critical Thinking

1. Describe the traits you would expect in a person with **gingival health** (vs. one with gingival disease). You are looking in their mouth, and have access to their radiographs. Use as many terms as possible used in the chapter.
2. A. Describe as many conditions as you can that indicate the presence of periodontal disease. B. Also, describe conditions that may contribute to a worsening of periodontal disease.

## REFERENCES

1. American Academy of Periodontology. Glossary of periodontal terms. 4th ed. Chicago: The American Academy of Periodontology, 2001.
2. Gargiulo A, Wentz F, Orban B. Dimensions and relationships of the dentogingival junction in humans. *J Periodontol* 1961;32:261.
3. Polson A, Caton J, Yeaple R, et al. Histological determination of probe tip penetration into gingival sulcus of humans using an electronic pressure-sensitive probe. *J Clin Periodontol* 1980;7:479.
4. Lang N, Loe H. The relationship between the width of keratinized gingiva and gingival health. *J Periodontol* 1972;43:623.
5. Stern IB. Current concepts of the dentogingival junction: the epithelial and connective tissue attachments to the tooth. *J Periodontol* 1981;52(9):465–476.
6. Squier CA. The permeability of oral mucosa. *Crit Rev Oral Biol Med* 1991;2(1):13–32. Review.
7. Langer L. Enhancing cosmetics through regenerative periodontal procedures. *Compend Suppl* 1994;(18):S699–S705; quiz S714–S717.
8. 1999 International Workshop for a Classification of Periodontal Diseases and Conditions. *The Annals of Periodontology* Chicago: The American Academy of Periodontology, October 30 - November 2, 1999.
9. Savage A, Eaton KA, Moles DR, et al. A systematic review of definitions of periodontitis and methods that have been used to identify this disease. *J Clin Periodontol* 2009;36(6):458–467.
10. Armitage GC. Classifying periodontal diseases—a long-standing dilemma. *Periodontol* 2000 2002;30:9–23.
11. Hugoson A, Norderyd O. Has the prevalence of periodontitis changed during the last 30 years? *J Clin Periodontol* 2008;35(8 Suppl):338–345.
12. Offenbacher S, Barros SP, Beck JD. Rethinking periodontal inflammation. *J Periodontol* 2008;79(8 Suppl):1577–1584.

13. Kinane DF, Mark Bartold P. Clinical relevance of the host responses of periodontitis. *Periodontol 2000* 2007;43: 278–293.
14. Laxman VK, Annaji S. Tobacco use and its effects on the periodontium and periodontal therapy. *J Contemp Dent Pract* 2008;9(7):97–107.
15. Yuen HK, et al. Oral health knowledge and behavior among adults with diabetes. *Diabetes Res Clin Pract* 2009;86: 239–246
16. Bahekar AA, Singh S, Saha S, et al. The prevalence and incidence of coronary heart disease is significantly increased in periodontitis: a meta-analysis. *Am Heart J* 2007;154(5):830–837. Epub Aug 20, 2007.
17. Ebersole JL, Novak MJ, Michalowicz BS, et al. Systemic immune responses in pregnancy and periodontitis: relationship to pregnancy outcomes in the Obstetrics and Periodontal Therapy (OPT) study. *J Periodontol* 2009;80(6):953–960
18. Radnai M, Pal A, Novak T, et al. Benefits of periodontal therapy when preterm birth threatens. *J Dent Res* 2009; 88(3):280–284.
19. Wennström JL. Mucogingival therapy. *Ann Periodontol* 1996;1(1):671–701.
20. Huttner EA, Machado DC, de Oliveira RB, et al. Effects of human aging on periodontal tissues. *Spec Care Dentist* 2009;29(4):149–155.
21. Kennedy J, Bird W, Palcanis K, et al. A longitudinal evaluation of varying widths of attached gingiva. *J Clin Periodontol* 1985;12:667.
22. Hallmon WW, Harrel SK. Occlusal analysis, diagnosis and management in the practice of periodontics. *Periodontol 2000* 2004;34:151–64.
23. Renner RP. An introduction to dental anatomy and esthetics. Chicago: Quintessence Publishing, 1985:162.
24. Zander H, Polson A. Present status of occlusion and occlusal therapy in periodontics. *J Periodontol* 1977;48:540.
25. Ericsson I, Lindhe J. Effect of long-standing jiggling on experimental marginal periodontitis in the beagle dog. *J Clin Periodontol* 1982;9:497.
26. Greenstein G. Current interpretations of periodontal probing evaluations: diagnostic and therapeutic implications. *Compend Contin Educ Dent* 2005;26(6):381–382, 384, 387–390.
27. Mombelli A. Clinical parameters: biological validity and clinical utility. *Periodontol 2000* 2005;39:30–9.
28. Müller HP, Eger T. Furcation diagnosis. *J Clin Periodontol* 1999;26(8):485–498.
29. Renvert S, Persson GR. A systematic review on the use of residual probing depth, bleeding on probing and furcation status following initial periodontal therapy to predict further attachment and tooth loss. *J Clin Periodontol* 2002;29(Suppl 3):82–89; discussion 90–91.
30. American Academy of Periodontology. Parameter on mucogingival conditions. *J Periodontol* 2000;71(5 Suppl):861–862.
31. Lightner LM, O’Leary TJ, Drake RB, et al. The periodontal status of incoming Air Force Academy cadets. *J Am Dent Assoc* 1967;75(1):111–117.
32. Padbury A Jr, Eber R, Wang HL. Interactions between the gingiva and the margin of restorations. *J Clin Periodontol* 2003;30(5):379–385.
33. Leknes KN. The influence of anatomic and iatrogenic root surface characteristics on bacterial colonization and periodontal destruction: a review. *J Periodontol* 1997;68(6): 507–516.
34. Levy A, Wright W. The relationship between attachment height and attachment area of teeth using a digitizer and digital computer. *J Periodontol* 1978;49:483.
35. Blieden TM. Tooth-related issues. *Ann Periodontol* 1999;4(1):91–97.
36. Van Dyke TE. The management of inflammation in periodontal disease. *J. Periodontol* 2008;79(8 Suppl): 1601–1608.
37. Godberg PV, Higginbottom FL, Witson TG. Periodontal considerations in restorative and implant therapy. *Periodontol 2000* 2001;25:100–109.
38. Umeda M, Takeuchi Y, Noguchi K, et al. Effects of nonsurgical periodontal therapy on the microbiota. *Periodontol 2000* 2004;36:98–120.
39. Ramfjord SP, Nissie R. The modified Widman flap. *J Periodontol* 1974;45:601.
40. Zakariasen KL. New and emerging techniques: promise, achievement and deception. *JADA* 1995;126(Feb):163.
41. Basaraba N. Root amputation and tooth hemisection. *Dent Clin North Am* 1969;13:121.
42. Oschenbein C. Current status of osseous surgery. *J Periodontol* 1977;48:577.
43. B, Langer L. Subepithelial connective tissue flap for root coverage. *J Periodontol* 1985;56:15.
44. Esthetics and plastic surgery in periodontics. *Periodontal 2000* 1996;11:1–111.
45. Allen E. Surgical crown lengthening for function and esthetics. *Dent Clin North Am* 1993;37:163–179.

## RESOURCES AND AUTHORITIES FOR PERIODONTICS

The American Academy of Periodontology, Suite 800, 737 North Michigan Avenue, Chicago, Illinois. Website: <http://www.perio.org>

The American Dental Association, 211 East Chicago Avenue, Chicago, Illinois. Website: [www.ada.org](http://www.ada.org)

## ADDITIONAL INTERNET RESOURCES

[www.dental-learninghub.com](http://www.dental-learninghub.com)

<http://www.perio.org/resources-products/Perio-Terms-Glossary.pdf>

## BASIC TEXTBOOKS

Lindhe J, Lang N, Karring T. *Clinical periodontology and implant dentistry*, 2 Vols. 5th ed. Malden, MA: Blackwell Munksgaard, 2008.

Newman M, Takei H, Klokkevold P, et al. *Carranza’s clinical periodontology*. 10th ed. Elsevier Health Sciences publishing, W.B. Saunders Company, 2006.

### RESOURCES FOR THE PATHOGENESIS, DIAGNOSIS, AND RISK FACTORS FOR PERIODONTAL DISEASES AND PERIODONTAL THERAPY

Periodontal literature reviews: a summary of current knowledge. Chicago: The American Academy of Periodontology, 1996.

Proceedings of the 1996 World Workshop in Periodontics, 1996. The Annals of Periodontology. Chicago: The American Academy of Periodontology, 1996.

### RESOURCE FOR PERIODONTAL DISEASE CLASSIFICATION

1999 International workshop for a classification of periodontal diseases and conditions. The Annals of Periodontology. Chicago: The American Academy of Periodontology, 1999.



## Dr. Woelfel's Original Research on Gingival Sulcus Depths

In a survey by Dr. Woelfel, 267 dental hygiene students measured their gingival sulcus depths with a calibrated periodontal probe. The average gingival sulcus depths for mandibular first molars midbuccal were  $1.5 \pm 0.5$  mm; midlingual:  $1.7 \pm 0.6$  mm; mesiolingual and distolingual:  $2.5 \pm 0.5$  mm. These measurements indicate that the

gingival sulcus is usually deeper interproximally. Similar measurements made on the mesiofacial aspect of mandibular canines ( $1.9 \pm 0.8$  mm), maxillary canines (1.8 mm), maxillary first premolars ( $1.9 \pm 0.7$  mm), and maxillary first molars ( $2.1 \pm 0.7$  mm) indicate sulci slightly deeper on posterior teeth than those on anterior teeth.



# Application of Root and Pulp Morphology Related to Endodontic Therapy



**This chapter was contributed and updated by** John M. Nusstein, D.D.S., M.S., Associate Professor and Chair, Division of Endodontics, The Ohio State University. He received his D.D.S. from the University of Illinois at Chicago College of Dentistry in 1987. He joined the Air Force and completed a GPR program at Scott AFB in 1988 and his endodontic training at The Ohio State University in 1995 earning his certificate in endodontics and an M.S. for research involving intraosseous anesthesia. Dr. Nusstein became a diplomate of the American Board of Endodontics in 1999. After 12 years of military service and 1 year of private practice, he became a full-time educator at The Ohio State University College of Dentistry in 2000 where he is now the graduate endodontic clinic director. He received the Edward Osetek award for Outstanding Young Educator from the AAE in 2006 and was named as the William J. Meyers Endowed Chair in Endodontics.

- I. Internal pulp cavity morphology related to endodontic and restorative therapy
  - A. The shape of pulp cavities and configuration of pulp canals
  - B. Shape of pulp cavities in sound young teeth
  - C. Why pulp cavities get smaller in older teeth
  - D. Clinical application of pulp morphology related to restorative dentistry
  - E. Clinical application of pulp morphology related to endodontics
- II. Location of root and cervical crown concavities, furcations, depressions, and canals
  - A. Maxillary central incisors
  - B. Maxillary lateral incisors
  - C. Mandibular central and lateral incisors
  - D. Maxillary canines
  - E. Mandibular canines
  - F. Maxillary first premolars
  - G. Maxillary second premolars
  - H. Mandibular first premolars
    - I. Mandibular second premolars
    - J. Mandibular first and second molars
    - K. Maxillary first and second molars
- III. Ethnic variations in pulp and root canal morphology

## OBJECTIVES

This chapter is designed to prepare the learner to perform the following:

- Describe the four types of root canal configurations I to IV.
- Describe the normal shape and location of the pulp chamber for each class of tooth.
- Identify the number of pulp horns most frequently found within each type of permanent (adult) tooth.
- Identify the number of canals most frequently found within the roots of each type of permanent (adult) tooth.
- Describe the scope of responsibility for a dentist who is an endodontist.
- Describe endodontic therapy.

## SECTION I

### INTERNAL PULP CAVITY MORPHOLOGY RELATED TO ENDODONTIC AND RESTORATIVE THERAPY

**T**hroughout this chapter, specific statistics are referenced with superscript letters like this (data<sup>A</sup>). The statistics are then listed with the referencing letters at the end of this chapter.

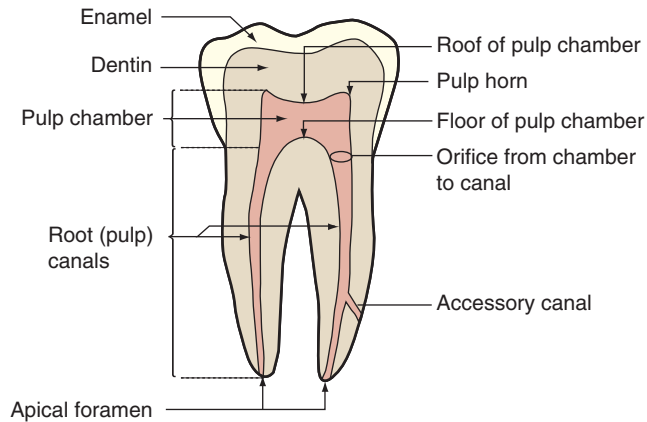
#### A. THE SHAPE OF PULP CAVITIES AND CONFIGURATION OF PULP CANALS

The **pulp cavity** is the cavity in the inner portion of the tooth containing the nerves and blood supply to

the tooth. It is divided into the pulp chamber (more coronal) and the root canals (in the roots).

#### 1. PULP CHAMBER AND PULP HORNS

The **pulp chamber** is the most occlusal or incisal portion of the pulp cavity. There is one pulp chamber in each tooth. It may be located partly in the crown of anterior teeth, but in posterior teeth, it is mostly in the cervical part of the root. Its walls are the innermost



**FIGURE 8-1.** **Parts of a pulp cavity.** The pulp cavity of this mandibular second molar is made up of a coronal pulp chamber with pulp horns and two root (pulp) canals.

surface of the dentin. Each pulp chamber has a roof at its incisal or occlusal border often with projections called **pulp horns**, and the pulp chambers of **multi-rooted teeth** have a floor at the cervical portion with an opening (**orifice**) for each root canal (Fig. 8-1). The number of pulp horns found within each cusped tooth (molars, premolars, and canines) is normally one horn per functional cusp, and in young incisors, it is three (one horn in each of the three facial lobes, which is the same as one lobe per mamelon). An exception is one type of maxillary lateral incisor (called a *peg lateral* with an incisal edge that somewhat resembles one cusp) that has only one pulp horn. Refer to *Table 8-1* for a summary of the number of pulp horns related to

the number of cusps normally found within different tooth types.

## 2. ROOT CANALS (PULP CANALS)

**Root canals** (pulp canals) are the portions of the pulp cavity located within the root(s) of a tooth. Root canals connect to the pulp chamber through **canal orifices** on the floor of the pulp chamber, and pulp canals open to the outside of the tooth through openings called **apical foramina** (singular foramen) most commonly located at or near the root apex (Fig. 8-1). The shape and number of root canals in any one root have been divided into four major anatomic configurations or types (Fig. 8-2). The type I configuration has one canal, whereas types II, III, and IV have either two canals or one canal that is split into two for part of the root. The four canal types are defined as follows:

**Type I**—one canal extends from the pulp chamber to the apex.

**Type II**—two separate canals leave the pulp chamber, but they join short of the apex to form one canal apically and one apical foramen.

**Type III**—two separate canals leave the pulp chamber and remain separate, exiting the root apically as two separate apical foramina.

**Type IV**—one canal leaves the pulp chamber but divides in the apical third of the root into two separate canals with two separate apical foramina.

**Accessory** (or lateral) **canals** also occur, located most commonly in the apical third of the root (Fig. 8-3A and B) and, in maxillary and mandibular molars, are common in the furcation area.<sup>A</sup>

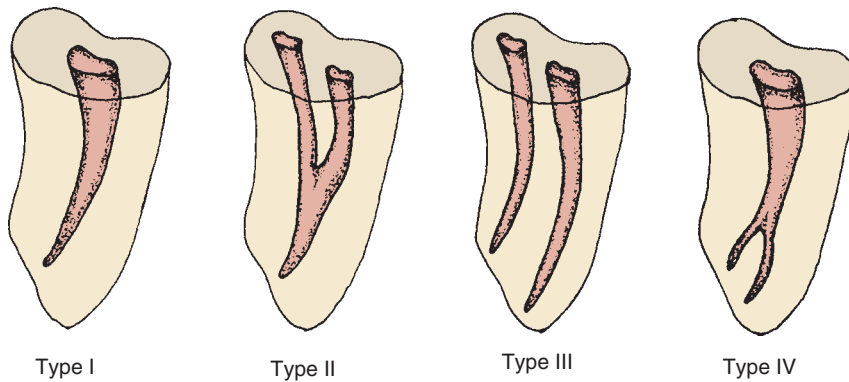
**Table 8-1** GUIDELINES FOR NUMBERS OF PULP HORNS IN ADULT TEETH

	NO. OF CUSPS	NO. OF PULP HORNS
Maxillary central incisor	—	3
Maxillary lateral incisor	—	3 (but only 1 in a peg lateral)
Maxillary canine	1	1
Maxillary first premolar	2	2
Maxillary second premolar	2	2
Maxillary first molar	4 (or 5 if Carabelli)	4 (Carabelli is functionless)
Maxillary second molar	3 or 4	3 or 4
Mandibular central incisor	—	3
Mandibular lateral incisor	—	3
Mandibular canine	1	1
Mandibular first premolar	2	1 or 2 (lingual cusp may be functionless)
Mandibular second premolar	2-3	2-3
Mandibular first molar	5	5
Mandibular second molar	4	4

General learning guidelines:

Incisors have three pulp horns (except maxillary lateral, which could be peg = 1).

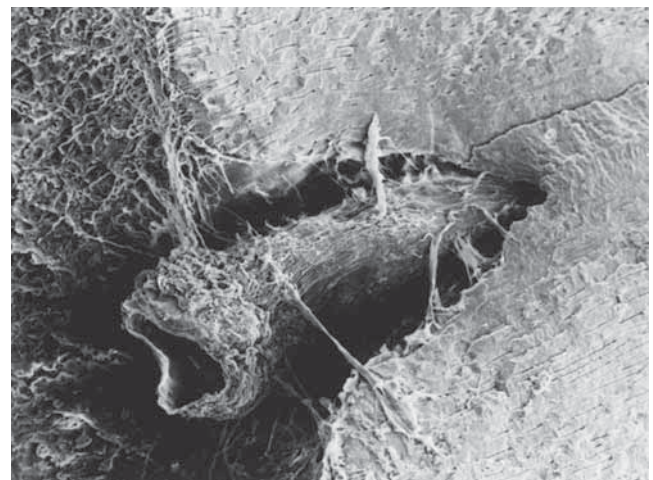
Cusped teeth have one pulp horn under each functional cusp.



**FIGURE 8-2.** Types of canal configurations occurring in one root.



A



B

**FIGURE 8-3.**

**Accessory canals.** **A.** A scanning electron photomicrograph of an instrumented (cleaned) root canal of a maxillary central incisor. After cleaning the root canal, the tooth was split and mounted for viewing with the scanning electron microscope. This view shows the apex of the tooth at the top of the picture and includes the apical third of the root. Near the bottom of the picture (right wall of canal), an accessory canal can be seen at the arrow. This canal contains blood vessels. **B.** A scanning electron photomicrograph at a higher power of the accessory canal is observed in A. The blood vessel can be seen emerging from the dentin. This vessel appears to be a vein due to its thin walls and large size. The adherent “stringy” extensions around the blood vessels are supporting collagen fiber bundles. The dentinal tubules can be observed on the right side of photomicrograph. (Courtesy of Dr. Dennis Foreman, Department of Oral Biology, College of Dentistry, Ohio State University.)

## B. SHAPE OF PULP CAVITIES IN SOUND YOUNG TEETH

### LEARNING EXERCISE

Section extracted teeth to expose the pulp cavity: the size, shape, and variations of pulp cavities are best studied by the interesting operation of grinding off one side of an extracted tooth. Extracted teeth should *always be sterilized* as described in the introduction of this text and kept moist. Wearing a mask and gloves, you can use a dental lathe equipped with a fine-grained abrasive wheel about

### Learning Exercise 1, cont.

3 in. in diameter and 3/8-in. thick to remove any part of the tooth. Simply decide which surface is to be removed, hold the tooth securely in your fingers, and apply this surface firmly to the flat surface of the abrasive wheel. Operating the lathe at a fairly high speed is less apt to flip the specimen from your fingers than operating it at a low speed. If you can devise an arrangement by which a small stream of water is run onto the surface of the wheel as the tooth is ground, you will eliminate flying tooth dust and the bad odor of hot tooth tissue. If such an

**Learning Exercise 1, cont.**

arrangement is not feasible, keep the tooth moist by frequently dipping the surface being ground in water or by dripping water onto the wheel with a medicine dropper. Look often at the tooth surface you are cutting and adjust your applied pressure to attain the plane in which you wish the tooth to be cut. A high-speed dental handpiece and bur will greatly facilitate your exploration of the insides of teeth.

As you examine different sides of each kind of tooth, notice how the external contours of the pulp chamber are similar to the external morphology of the tooth. On incisors and canines, you can remove either the facial or lingual side from some teeth to view the *mesiodistal plane* (as seen in Fig. 8-4A and E) and remove the mesial or distal side from others to view the *faciolingual plane* (as seen in Fig. 8-4B–D). On premolars and molars, the removal of either the mesial or distal side will expose the outline of the roof of the pulp chamber where *pulp horns* can be seen extending beneath the cusps (as seen in premolars in Fig. 8-4C and D). When the buccal or lingual sides are removed to the level of the buccal and lingual cusp tips, pulp cavities can be seen in a mesiodistal plane (as seen in Fig. 8-4E), the view similar to that seen on a dental radiograph. Finally, on molars, the removal of the occlusal surface will reveal the openings (orifices) to the root canals on the floor of the pulp chamber (as seen later in the diagram in Fig. 8-9 and the close-up view in Fig. 8-13).

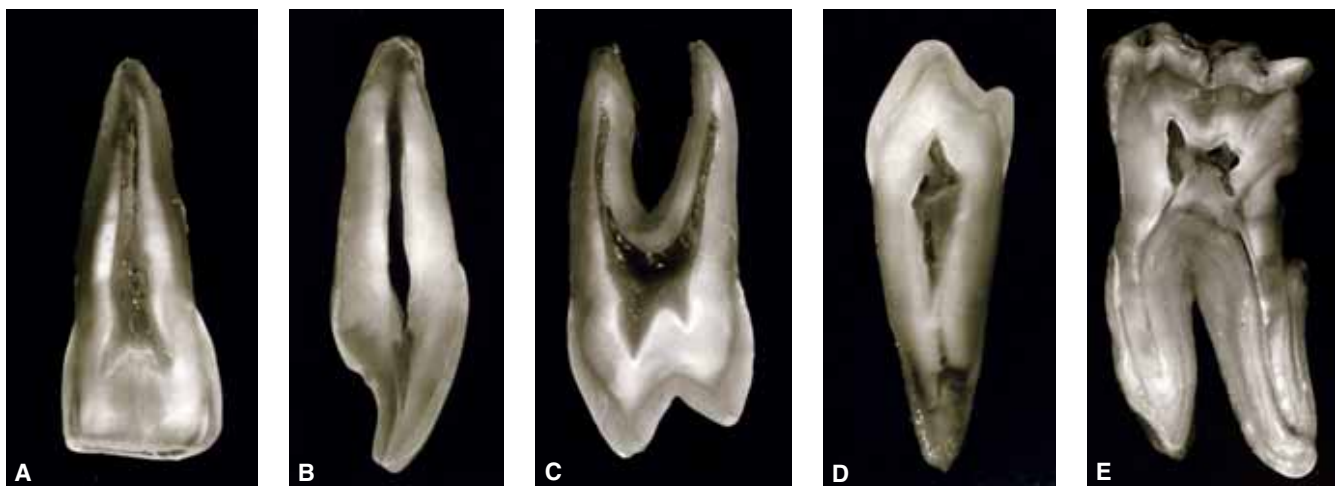
## 1. PULP SHAPE IN ANTERIOR TEETH (INCISORS AND CANINES)

### a. Pulp Chamber and Pulp Horns of Anterior Teeth

When an incisor is *cut mesiodistally* and viewed from the facial (or lingual) (similar to the view on dental radiographs), the pulp chambers are broad and may appear as three pulp horns. Only two horns can be seen in the maxillary central incisors in Figure 8-5. However, the incisal border of the pulp wall (roof of the chamber) of a young tooth may show the configuration of three mamelons, that is, has developed with three pulp horns: located mesially, centrally, and distally. (Recall, however, that there is an unusual *peg lateral incisor* that only has one pulp horn.) Knowing the number and location of these pulp horns becomes important when the tooth is fractured or badly decayed and must be prepared for an incisal restoration. When an anterior tooth is *cut labiolingually* and viewed from the proximal, the pulp chambers taper to a point toward the incisal edge (Fig. 8-6). In maxillary and mandibular canines, the incisal wall or roof of the pulp chamber is often less pointed, having only one pulp horn (Fig. 8-7).

### b. Root Canal(s) of Anterior Teeth

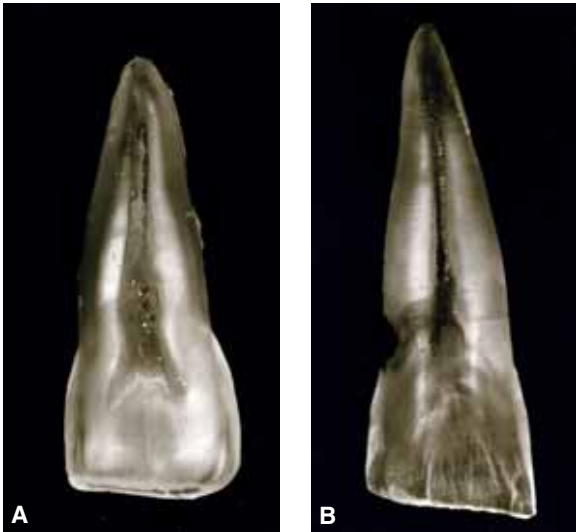
Recall that all anterior teeth are most likely to have *one root*. The number of root canals in each type of anterior tooth is also most frequently *one*. Maxillary central incisors, lateral incisors, and canines almost always have one canal (type I), whereas mandibular anterior teeth, although most likely to have one canal, may have two



**FIGURE 8-4.**

Sectioned teeth showing **pulp cavity shapes** relative to the external tooth surface. **A.** Mesiodistal section of a maxillary central incisor showing only two of its three pulp horns. **B.** Faciolingual section of a maxillary incisor. **C.** Faciolingual section of a maxillary first premolar with two roots and two obvious pulp horns, one under each cusp. **D.** Faciolingual section of mandibular first premolar. **E.** A mandibular first molar sectioned mesiodistally through its three buccal cusps.





**FIGURE 8-5.** Maxillary central incisors sectioned *mesiodistally*.

**A.** Maxillary central incisor (young tooth), facial side removed. The high pulp horns (only two are visible in this tooth section) and the broad root canal indicate that this is a young tooth. This outline of the pulp cavity may be seen on a dental radiograph. **B.** Maxillary central incisor (old tooth), facial side removed. The pulp chamber of this older tooth is partially filled with secondary dentin, and the root canal is narrower than in the tooth shown in A. Also, the incisal edge is worn to a straight line. (The damage to the cervical part of the root on the distal [left] side of the tooth has been there for some time because the underlying dentin has been altered by a defense mechanism of the pulp tissues.)

canals (one facial and one lingual) with the frequency varying depending on the study cited.<sup>1-3,B</sup> The mandibular canine is the anterior tooth most likely to have two roots (though still uncommon), one facial and one lingual, and this configuration would have two root canals, one in each root.

## 2. PULP SHAPE IN PREMOLARS

### a. Pulp Chambers and Pulp Horns in Premolars

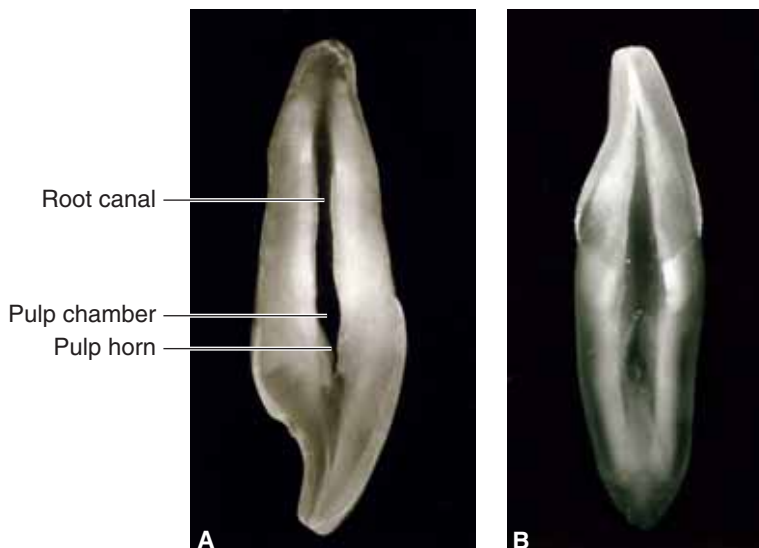
When premolars are cut *mesiodistally* and viewed from the facial (or lingual) similar to the view on dental radiographs (Fig. 8-8A), the occlusal border or roof of the pulp chamber is curved beneath the cusp similarly to the curvature of the occlusal surface. When cut *buccolingually* and viewed from the proximal, the pulp chamber often has the general outline of the tooth surface, sometimes including a constriction near or apical to the

cervix (seen in Fig. 8-8C). The pulp horns on the roof are visible beneath each cusp, and their relative lengths are similar to the relative heights of the cusps. Thus, the buccal horns are longer than the lingual horns.

In general, premolars have one pulp horn per functional cusp. Therefore, the premolars that are the two-cusp type most often have two pulp horns (Fig. 8-4C), but mandibular second premolars that are the three-cusp type have three pulp horns, and the mandibular first premolars that have a functionless lingual cusp may have only one pulp horn (Fig. 8-4D), similar to a canine.

### b. Root Canal(s) and Orifices of Premolars

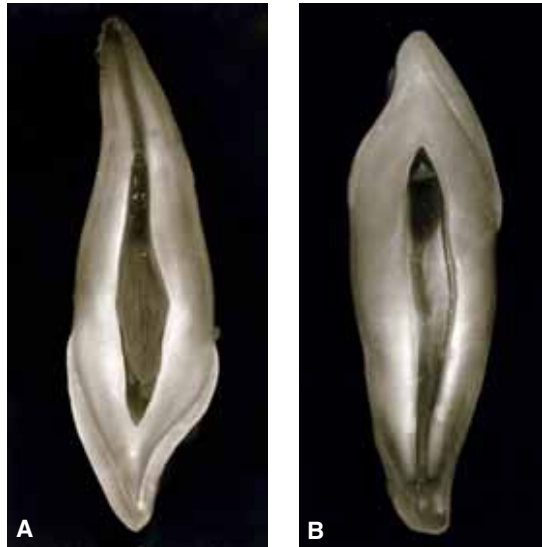
Maxillary first premolars most often have two roots (one buccal and one lingual) and *two* canals (one in each root as seen in Fig. 8-8B). Even maxillary first premolars with a single root almost always have two canals.



**FIGURE 8-6.** Incisors sectioned *faciolingually*.

**A.** Maxillary central incisor, mesial side removed. The root canal is moderately wide. As commonly occurs, much of the pulp chamber is located in the cervical third of the root. It is *not* possible to see this view of the pulp cavity on a dental radiograph. There is wear (attrition) on the incisal edge, and secondary dentin has begun to fill in the incisal part of the pulp chamber. **B.** Mandibular lateral incisor, mesial side removed (young tooth). Curvature of the root prevented cutting the pulp cavity in one plane so that the apical portion of the root canal was lost. Notice how the pulp cavity extends in a narrow point toward the incisal edge. Even extensive attrition on the incisal edge would not likely expose the pulp since secondary dentin would form in the incisal part of the pulp chamber and the pulp would be additionally protected.





**FIGURE 8-7.** Canines sectioned *faciolingually*. **A.** Maxillary canine, mesial side removed (young tooth). There is no attrition evident on the incisal edge, and the pulp cavity is still large. **B.** Mandibular canine, mesial side removed (young tooth). The pulp cavity is large. Only at the incisal tip is there a little evidence of secondary dentin formation. The roof of the chamber is slightly more rounded than on incisors.

The average incidence of two canals, one in the buccal root and one in the lingual root, is 90%<sup>C</sup> although there is a small incidence of three roots.<sup>D</sup> The dentist must know the location of each canal opening on the pulp chamber floor in order to remove diseased pulpal tissue

from the entire pulp cavity. The buccal canal orifice in the maxillary first premolar (viewed through the prepared access opening and the roof of the pulp chamber removed in Fig. 8-9) is located just lingual to the buccal cusp tip. The lingual canal orifice is located just lingual to the central groove.

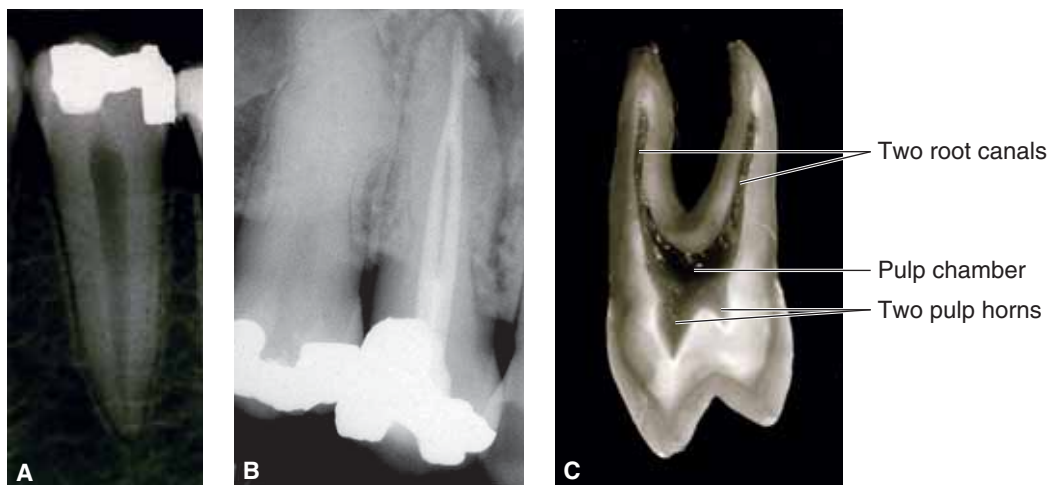
Maxillary second premolars most often have *one* root and *one* canal, but two canals are frequently present.<sup>E</sup> When there is one canal, its orifice on the pulp chamber floor is located in the exact center of the tooth (Fig. 8-9). If the orifice is located toward the buccal or the lingual, it probably means that there are two canals in the root.

Mandibular first and second premolars most frequently have one root and *one* root canal (type I) (Fig 8-10), but mandibular first premolars may have two canals, which are type IV.<sup>F</sup> The single canal orifice is located on the floor of the pulp chamber just buccal to the center of the occlusal surface (Fig. 8-9).

### 3. PULP SHAPE IN MOLARS

#### a. Pulp Chambers and Pulp Horns in Molars

The pulp chamber of **maxillary first and second molars** is broader buccolingually than mesiodistally (like the crown shape) and is often constricted near the floor of the chamber (seen in Fig. 8-11A and B). On **mandibular first and second molars**, the chamber is broader mesiodistally than buccolingually (like the crown shape). This difference in shape of pulp chambers for maxillary versus



**FIGURE 8-8.** **A.** Radiograph of a mandibular left second premolar showing the shape of the root canal as though sectioned mesiodistally. **B.** Radiograph of a maxillary first premolar reveals the two root canals (filled with a filling material that makes the canals appear whiter). This is a similar view as a premolar sectioned *mesiodistally*. **C.** Maxillary first premolar sectioned *faciolingually*, mesial side removed (young tooth). The curvature of the tips of the roots prevented cutting the root canals in one plane. The two pulp horns are sharp; there is little, if any, secondary dentin; and the floor of the pulp chamber is rounded. The buccal pulp horn is considerably longer than the lingual horn. Notice the floor of the pulp chamber, which has two openings, one for each canal. Also, note the constriction of the pulp chamber near the cervix.

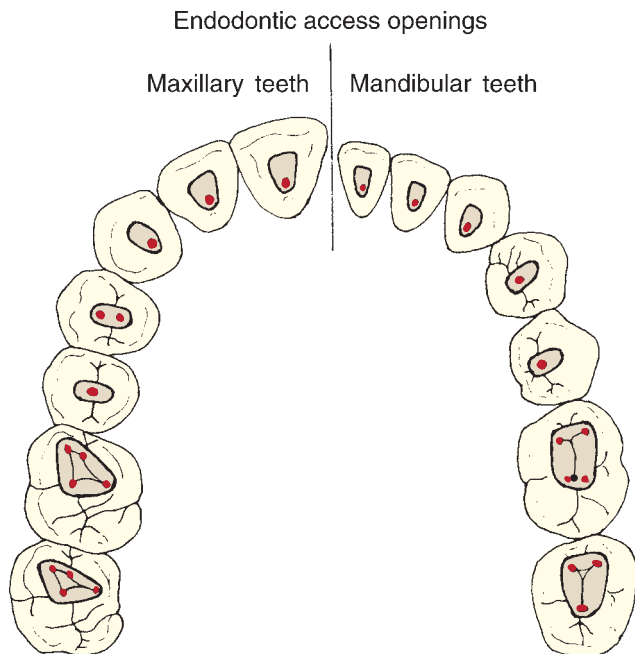


FIGURE 8-9.

**Access preparations** into pulp chambers showing orifices to canals. Ideally shaped openings provide access into the pulp chamber for endodontic treatment. Pulp canal orifices on the floor of each pulp chamber correspond with the number and location of pulp canals in each tooth. The left half of the arch shows *maxillary* teeth; the right half shows *mandibular* teeth.

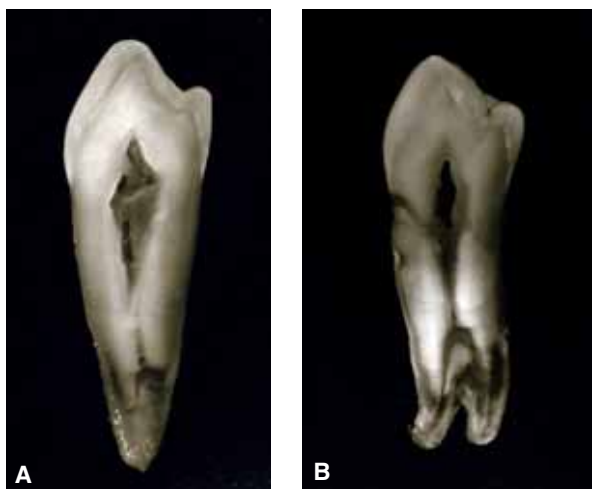

FIGURE 8-10.

**Mandibular first premolars** sectioned *faciolingually*. **A.** Mandibular first premolar, distal side removed. Root curvature prevented cutting the root canal in one plane. The pulp horn in the buccal cusp is large; in the lingual cusp, it is very small, almost nonexistent. It is unusual to observe much of a pulp horn beneath the nonfunctional lingual cusp on mandibular first premolars. **B.** Mandibular first premolar, mesial side removed, with root and root canal divided near the apex (type IV). Only one pulp horn is evident in this sectioned tooth.

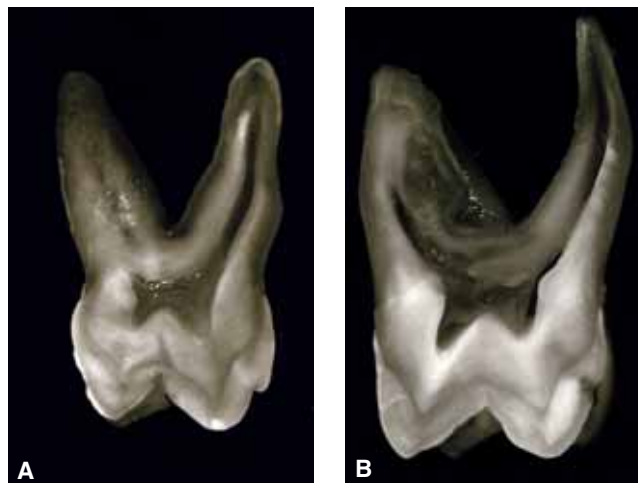
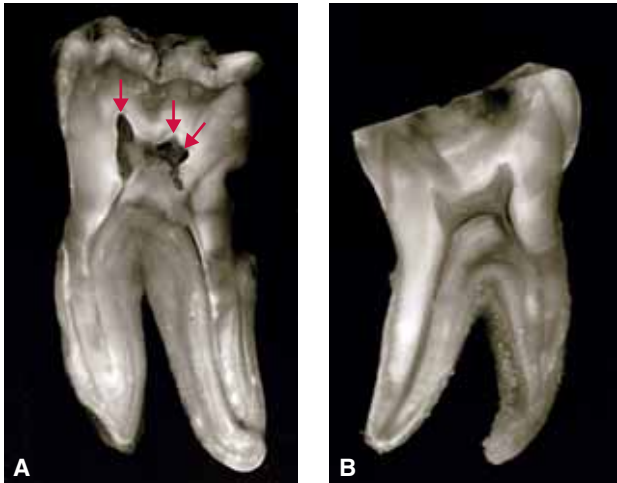

FIGURE 8-11.

**Maxillary first molars** sectioned *buccolingually*.

**A.** Young maxillary molar with mesial side removed; lingual side (with cusp of Carabelli) is on the right. The tooth is sectioned through the center of the lingual root canal but not through the center of the mesiobuccal canal. The pulp chamber opens into the lingual root canal in this view. The floor of the pulp chamber is relatively flat as it often is on young teeth. **B.** Young maxillary molar with mesial side removed; lingual side is on the right. The tooth is sectioned through the mesiobuccal and lingual root canals. The pulp chamber is mostly in the root trunk. Only mesiobuccal and mesiolingual pulp horns extend a little into the anatomic crown. There is an area of dental decay (caries) appearing darker in the groove where the small cusp of Carabelli is attached to the mesiolingual cusp.

mandibular molars can be appreciated by studying the openings used to access the pulp chambers for molars in Figure 8-9. As in all cusped teeth, molars have one pulp horn per functional cusp, and they are located in the roof of the pulp chamber well beneath each cusp. Therefore, if we consider the cusps of Carabelli to be functionless, all four-cusp types of molars have four pulp horns, three-cusp maxillary molars have three pulp horns, and the mandibular first molar with five cusps is the only type of molar to have five pulp horns. Three pulp horns are visible under the three buccal cusps in Figure 8-12A. The pulp chamber is normally deep to, or some distance from, the occlusal surface, actually located within the cervical part of the root trunk (Fig. 8-12). Surprisingly, the dentist does not often penetrate the pulp chamber on a maxillary molar until the drill reaches the level of the gum line. One exception might be the long pulp horn of the longest mesiolingual cusp of the *maxillary* molars (Fig. 8-11A). The floor of the pulp chamber is considerably apical to the cervical line; it is located in the root trunk. The pulp floor has multiple openings (orifices), one for each root canal. The floor is level or flat in young teeth. It may become convex in older teeth with the deposition of additional dentin over time.



**FIGURE 8-12.** Mandibular first molars sectioned *mesiodistally*.

**A.** Buccal side removed (old tooth). The apical foramen of the distal root is on the distal side of the root, not at the root tip. Notice the three pulp horns (at arrows) under the three buccal cusps shown in this section. (The unusual thickening of cementum on the roots is hypercementosis.) **B.** Old tooth (exhibiting considerable occlusal wear) with lingual side removed. Notice that the roof of the pulp chamber is about at the level of the cervical line. Two pulp horns extend occlusal to the cervical line. The rest of the pulp chamber is in the root trunk. The floor of the pulp chamber is convex (a condition founded in older teeth) because of the deposition of secondary dentin. (There appears to be caries in the enamel above the mesiolingual pulp horn, but it has penetrated only slightly into the dentin.)

### b. Root Canal(s) and Orifices of Molars

Maxillary first molars most frequently have three roots (mesiobuccal, distobuccal, and palatal), but *four* canals: one each in the distobuccal and palatal root, and *two* in the *mesiobuccal* root. In the palatal root, a single canal is larger and more easily accessible from the floor of the pulp chamber than for the other two roots,<sup>G</sup> but this root and its canal often curve toward the buccal in the

apical third, requiring skillful procedures to clean and treat it. On maxillary first molars, there are therefore four orifices on the floor of the pulp chamber: one for each canal (Fig. 8-13). Maxillary second molars, like maxillary first molars, most frequently have three roots and four canals. The mesiobuccal root usually has *two* canals.<sup>H</sup> The distobuccal and palatal roots each have one canal. The location of the orifices in the maxillary second molar is similar to the maxillary first molar, except that they are closer together (Fig. 8-9).

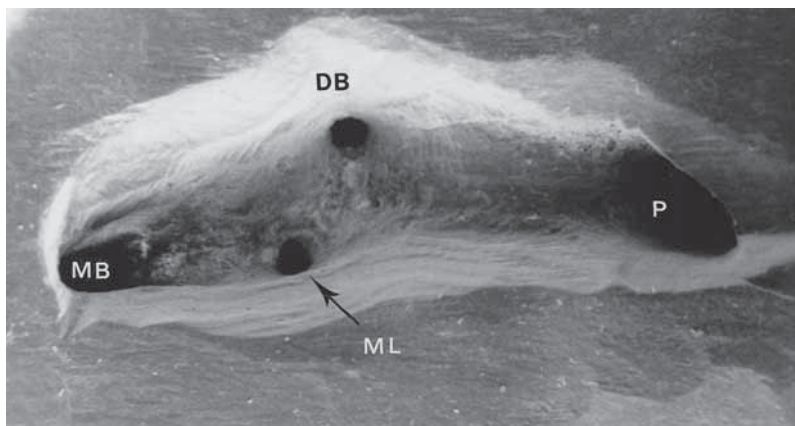
Both mandibular first and second molars most frequently have two roots (mesial and distal) and *three* canals. The wider mesial roots most often have *two* canals: mesiobuccal and mesiolingual.<sup>I</sup> The narrower distal roots most often have only one canal.<sup>J</sup> The roof of the pulp chamber is often at the same level as the cervical border of the enamel, with only the pulp horns extending into the anatomic crown (Fig. 8-12). Most of the pulp chamber is located within the root trunk. Location of the orifices of mandibular molars is shown in Figure 8-9.<sup>K</sup>

Maxillary third molars usually have *three* root canals, and mandibular third molars usually have *two*. However, they do vary considerably in root form. Third molars are 9 to 11 years younger biologically than first molars, completing their development later in life than first and second molars. Therefore, on radiographs (x-ray films), their pulp chambers and root canals are generally larger than in the other molars in the same mouth, especially for persons between the ages of 15 and 35 years.

Refer to Table 8-2 for a summary of the number of root canals related to the number of roots normally found within different tooth types.

### 4. PULP SHAPE IN PRIMARY TEETH

Primary teeth generally have thinner amounts of dentin and enamel, so their pulp cavities are proportionally larger than on permanent teeth, and their pulp horns are closer to the incisal or occlusal surfaces.



**FIGURE 8-13.** Scanning electron photomicrograph of the pulp chamber floor of a maxillary molar with four canal orifices identified for orientation: the palatal (P), distobuccal (DB), and the two orifices into the mesiolingual root called mesiobuccal (MB) and mesiolingual (ML, arrow). (Original magnification  $\times 20$ .) (Courtesy of Dr. James Gilles and Dr. Al Reader.)

**Table 8-2 MOST COMMON NUMBERS OF ROOTS AND CANALS IN ADULT TEETH**

TOOTH NAME	NO. OF ROOTS	NO. OF ROOT CANALS
Maxillary central incisor	1	1
Maxillary lateral incisor	1	1
Maxillary canine	1	1
Maxillary first premolar	2 (buccal and lingual) or 1	2 (even if 1 root)
Maxillary second premolar	1	1 (or 2)
Maxillary first molar	3 (mesiobuccal, distobuccal, and lingual)	4 (2 in mesiobuccal root)
Maxillary second molar	3 (mesiobuccal, distobuccal, and lingual)	4 (2 in mesiobuccal root)
Mandibular central incisor	1	1
Mandibular lateral incisor	1	1
Mandibular canine	1 (but has 2 roots more often than other anterior teeth: buccal and lingual)	1
Mandibular first premolar	1	1
Mandibular second premolar	1	1
Mandibular first molar	2 (mesial and distal)	3 (2 in mesial)
Mandibular second molar	2 (mesial and distal)	3 (2 in mesial)

### C. WHY PULP CAVITIES GET SMALLER IN OLDER TEETH

In a young tooth, the pulp chamber is large and resembles the shape of the crown surface. It has projections called horns extending beneath the cusps or mamelons in the roof of the chamber and is usually constricted somewhat at the cervix. As teeth get older, the pulp chamber becomes smaller and is more apically located because of deposits of **secondary** (additional) **dentin** produced by specialized cells called **odontoblasts** lining the pulp chamber. Dentin formation normally continues as long as the pulp is intact or vital. That is, as dentin forms on the walls of the pulp cavity, the dentin gets thicker making the pulp chamber smaller. The floor of the pulp chamber in molars is nearly flat in young teeth, but later becomes more convex.<sup>1</sup> In some cases, the pulp chamber may become entirely filled. This reduction in size makes finding and accessing the pulp chamber more difficult in an older patient than in the younger patient where the teeth still have larger chambers.

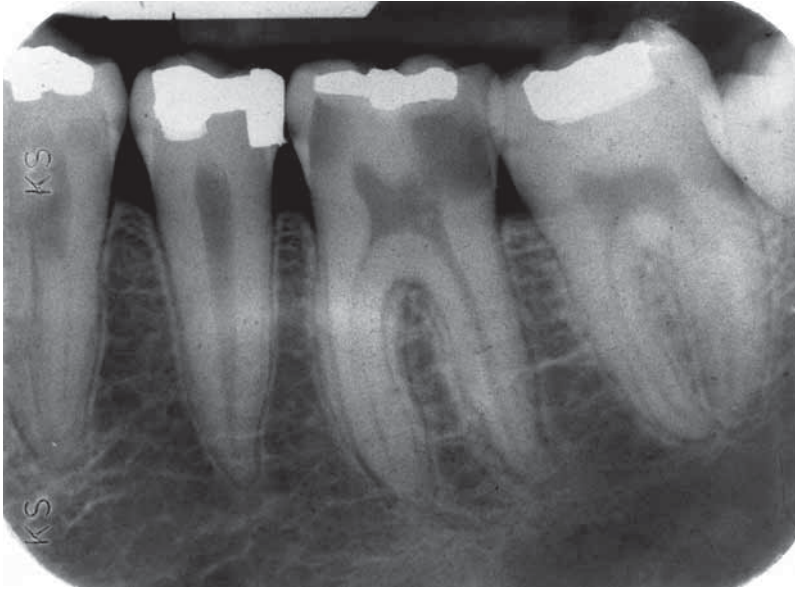Therefore, it is normal that the diameter of a root canal decreases in size with age, getting small in older teeth because of the gradual addition of dentin on the internal walls. On the other hand, teeth (other than third molars) that exhibit *unusually large* pulp chambers on dental radiographs are immediately suspected of having necrotic pulps, that is, pulps that no longer have vital nerve or blood supply. Without vital pulp tissue, dentin formation ceases, and the pulp chamber size remains constant (once the pulp died) rather than continuing to decrease in size as is normal for vital teeth. Necrotic pulps can be a possible source of infection.

When the tooth is subjected to attrition (wear), trauma, or tooth decay, or when a dental material called *calcium hydroxide* is applied on the pulp, additional dentin forms even more quickly and in greater quantity. A **pulp cap** is a term describing a procedure where the dentist places calcium hydroxide on very thin dentin that covers the pulp (an **indirect pulp cap**), or over a small bit of exposed healthy pulp (a **direct pulp cap**) in order to stimulate the formation of a new layer of dentin to help the tooth heal.

### D. CLINICAL APPLICATION OF PULP MORPHOLOGY RELATED TO RESTORATIVE DENTISTRY

The dentist's knowledge of normal pulp shape, size, and depth beneath the enamel is important to him or her when preparing teeth that have deep decay. When the dentist determines that the tooth can be restored without the need to remove the pulp, he or she must prepare the tooth in such a way to avoid disturbing or injuring the pulpal tissues. Whenever possible, the goal is to leave some sound (undecayed) dentin on the floor of the cavity preparation to provide support for the restoration (such as a filling using composite resin or amalgam) and to avoid exposing any part of the pulp cavity with a cutting bur or hand instrument. This is accomplished through knowledge of the shape of the pulp chamber and canals and a careful evaluation of the patient's radiographs to determine the location of the pulp relative to the decay and external surface of the tooth. An example of deep decay that has reached the pulp is seen in *Figure 8-14*. Also, the dentist must avoid





**FIGURE 8-14.** Dental decay (caries) reaches the pulp. Radiograph of a lower left first molar with a very large distal decay (seen as an area of lost enamel and *darkened* dentin) that has reached (exposed) the pulp. There is also mesial decay on this tooth that does not appear to have reached the pulp.

overheating or drying out (desiccating) the tooth during preparation by using water to reduce the heat that is generated when using cutting burs in a high-speed handpiece.

Sometimes, however, signs (what is seen), symptoms (what the patient feels), and diagnostic tests may indicate that a pulp inflammation (pulpitis) is irreversible, that is, cannot be resolved without removing the pulp tissue. When these signs, symptoms, and diagnostic test results indicate a pulp is not likely to respond well by placing just a filling (dental restoration of amalgam or composite), the pulp tissue must be removed and a **root canal filling** placed (endodontic therapy must be performed). The implications of dental anatomy on restorative dentistry are discussed in more detail in Chapter 10.

## E. CLINICAL APPLICATION OF PULP MORPHOLOGY RELATED TO ENDODONTICS

### 1. ENDODONTICS DEFINED

Endodontics is a specialty branch of dentistry concerned with the morphology, physiology, and pathology of human dental pulp and periapical tissues. Its study and practice encompass the related basic and clinical sciences, including biology of the normal pulp; the cause (etiology), diagnosis, prevention, and treatment of diseases and injuries of the pulp; and resultant pathologic conditions that occur around the root.

An **endodontist** is a dentist who specializes in endodontics (root canal therapy). An endodontist is specially trained to provide root canal therapy, including treating patients with more difficult and complex endodontic

situations who may be referred from a general dentist. Treatment may involve difficult root canal anatomy, medically compromised patients, and/or surgical treatments of periapical pathosis and infection.

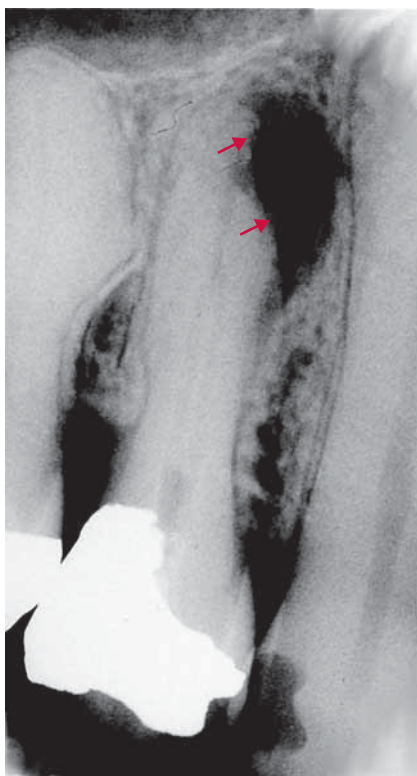
### 2. DIAGNOSIS OF PULPAL AND PERIAPICAL DISEASE

**Irreversible pulpitis** (inflammation of the pulp that cannot be healed) is a condition of the pulp tissue where the pulp will not heal and root canal treatment is indicated. Teeth with irreversible pulpitis are unusually sensitive to cold or hot, and sometimes either stimulus may cause an *exaggerated response* and *prolonged pain*. The patient may also experience *spontaneous* pain in the tooth (i.e., pain felt without provocation of stimuli such as heavy chewing, or exposure to hot or cold). The usual cause of irreversible pulpitis is deep caries [CARE eez] (decay), although deep or poorly adapted restorations may also contribute. The proximity of caries to the pulp can often be evaluated best using dental radiographs (Fig. 8-14). As the caries approaches the pulp, a normal defense reaction will occur involving inflammation and eventually the formation of additional dentin called **reparative dentin**. However, when the caries reaches or exposes the pulp, bacteria can overwhelm the defenses, and the tooth usually becomes painful. This prompts the patient to seek emergency dental treatment. Access to and removal of affected pulp tissue will provide relief from the pain. The pulp tissue cannot be successfully treated with medications alone once the pulp is irreversibly damaged.

**Periapical disease** occurs when the pulp has died (has become **necrotic**). When the disease process in the



crown has overwhelmed the pulp, the pulp tissue in the root canals gradually dies. Once the bacteria and products of pulpal breakdown contained within the root canals reach the apical foramen, the periapical tissue beyond the apical foramen will begin to react to this insult. A chronic inflammatory response in the bone can lead to the formation of a **granuloma** (i.e., a mass of chronic inflammatory tissue enclosed within a fibrous capsule). Since a granuloma is less dense than bone, a radiograph will usually reveal **radiolucency** (a periapical radiolucency is the dark area at end of the root; Fig. 8-15). In some cases, the granuloma undergoes degeneration and a cyst is formed. A cyst is an epithelium-lined sac filled with liquid or semiliquid material. The difference between a granuloma and a cyst cannot be determined on a radiograph. When the bacteria from the root canal overwhelm the defenses of the periapical tissues or the patient's immune system is compromised, bacteria invade through the bone to the surrounding soft tissue, resulting in facial swelling and/or severe



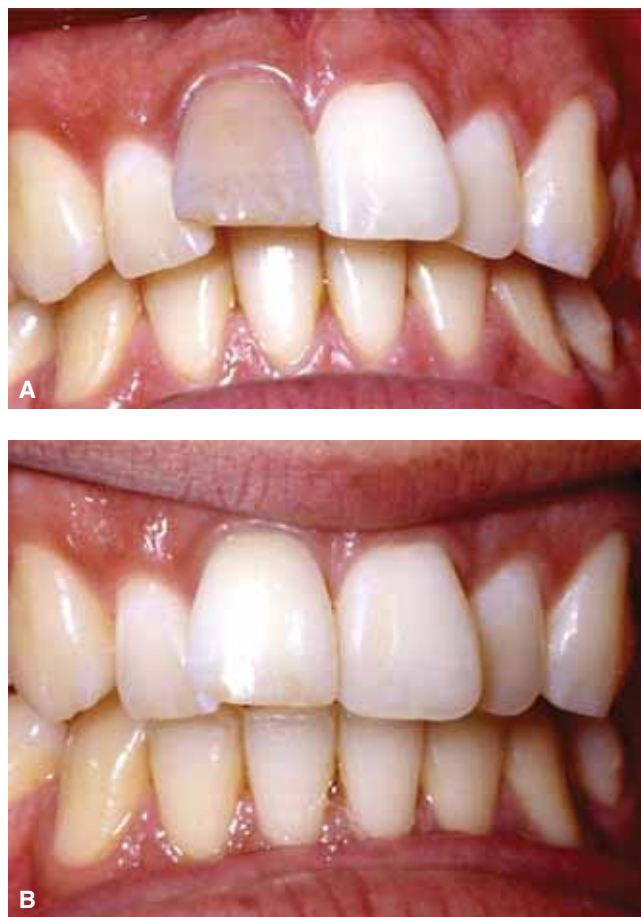**FIGURE 8-15.** **Periapical radiolucency.** Radiograph of a maxillary first premolar with the dark area (*red arrows*) surrounding the root apices indicating the pulp has become necrotic. A **granuloma** or **cyst** has developed in the bone, probably as a result of the exposure of the pulp to deep decay that was removed and restored with a large amalgam filling (seen as a white outline) that covers the distal and occlusal surfaces of this tooth.

pain. Cleaning the root canals and draining the area of infection will usually provide relief within two to three days.

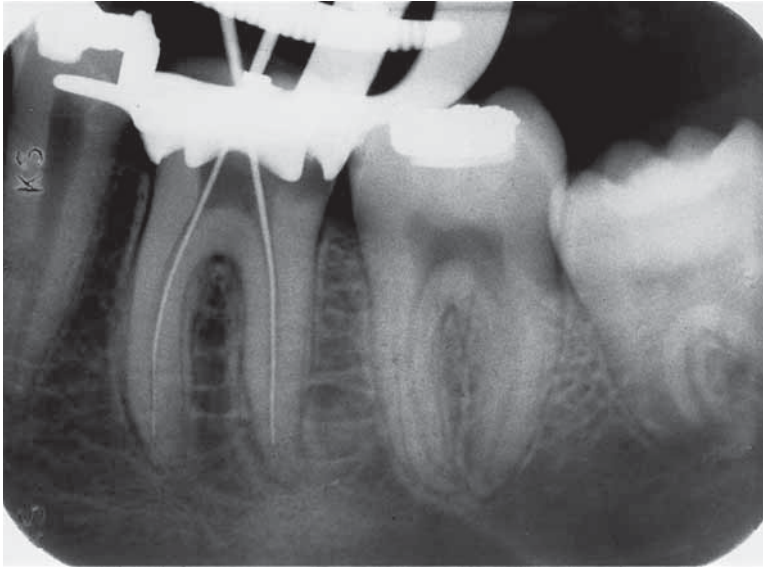
Another result of pulpal trauma (like being hit in the mouth with a baseball) is the *discoloration* of the tooth crown to a gray or brownish color, which indicates damage to the pulp and the need to evaluate the tooth for possible endodontic treatment. After the root canal, the discoloration can be greatly reduced by using an **intracoronary bleaching** technique where the bleach is placed within the pulp chamber for a period of time. See the change of tooth color in Figure 8-16.

### 3. ENDODONTIC THERAPY

The goal of endodontic therapy is to relieve pain, control infection, and preserve the tooth so that it may function normally during mastication. Endodontic treatment is



**FIGURE 8-16.** **Color as an indicator of pulpal pathology.** **A.** Discolored tooth with pulp tissue damaged (tooth is devital) after tooth trauma (such as being hit in the mouth with a baseball). **B.** The same tooth after **bleaching techniques** was used to lighten this devital tooth.



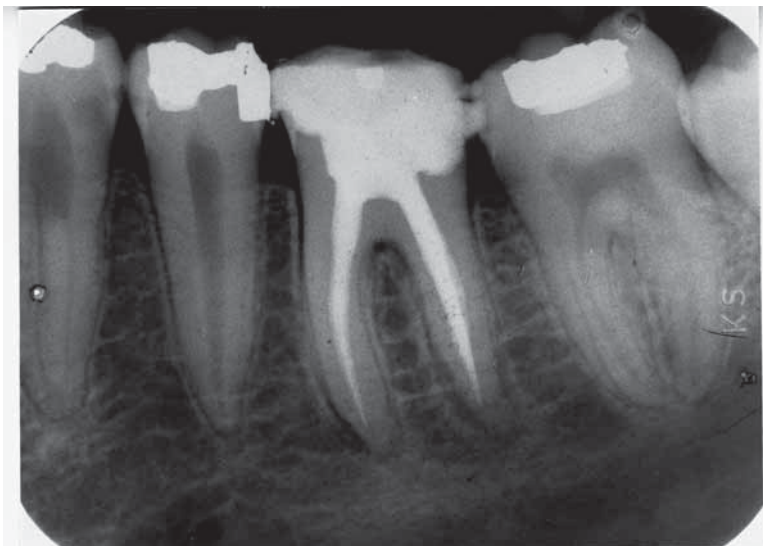
**FIGURE 8-17.** Endodontic files seen on a radiograph. Radiograph of a lower left first molar where endodontic files have been placed within the root canals approaching the cementodentinal junction apically.

normally preferred to extraction because if the tooth were extracted, the patient would be without the tooth throughout the healing process and during the time required to construct and place the replacement tooth. Further, endodontic therapy is less expensive than having a tooth extracted and subsequently replaced with a dental prosthesis (bridge) or an implant.

The first step of the endodontic procedure is for the dentist to *gain access* to the pulp chamber and the root canals of teeth through an **access opening** in the crown of the tooth. On anterior teeth, the opening is made on the lingual surface and on posterior teeth through the occlusal surface. These access openings vary considerably from cavity preparations used in operative dentistry. The shape (outline form), size, and position of the access opening are determined by studying ideal

openings of maxillary and mandibular teeth shown in Figure 8-9, and then modifying them to conform to what is evident on the initial radiograph of the tooth. Finding the pulp may be difficult in older teeth, or teeth that have large or deep restorations, since the formation of secondary or reparative dentin may obliterate the pulp chamber, making endodontic access difficult. Further, if the tooth is covered with a metal crown, the pulp chamber will not be visible on the radiograph.

Once the access opening is complete, the dentist *locates the root canal orifices* on the floor of the pulp chamber. Knowledge of the number of root canals present in teeth is critically important to successful endodontic treatment. Not locating and cleaning all the canals may result in continued discomfort for the patient or unsuccessful endodontic treatment with

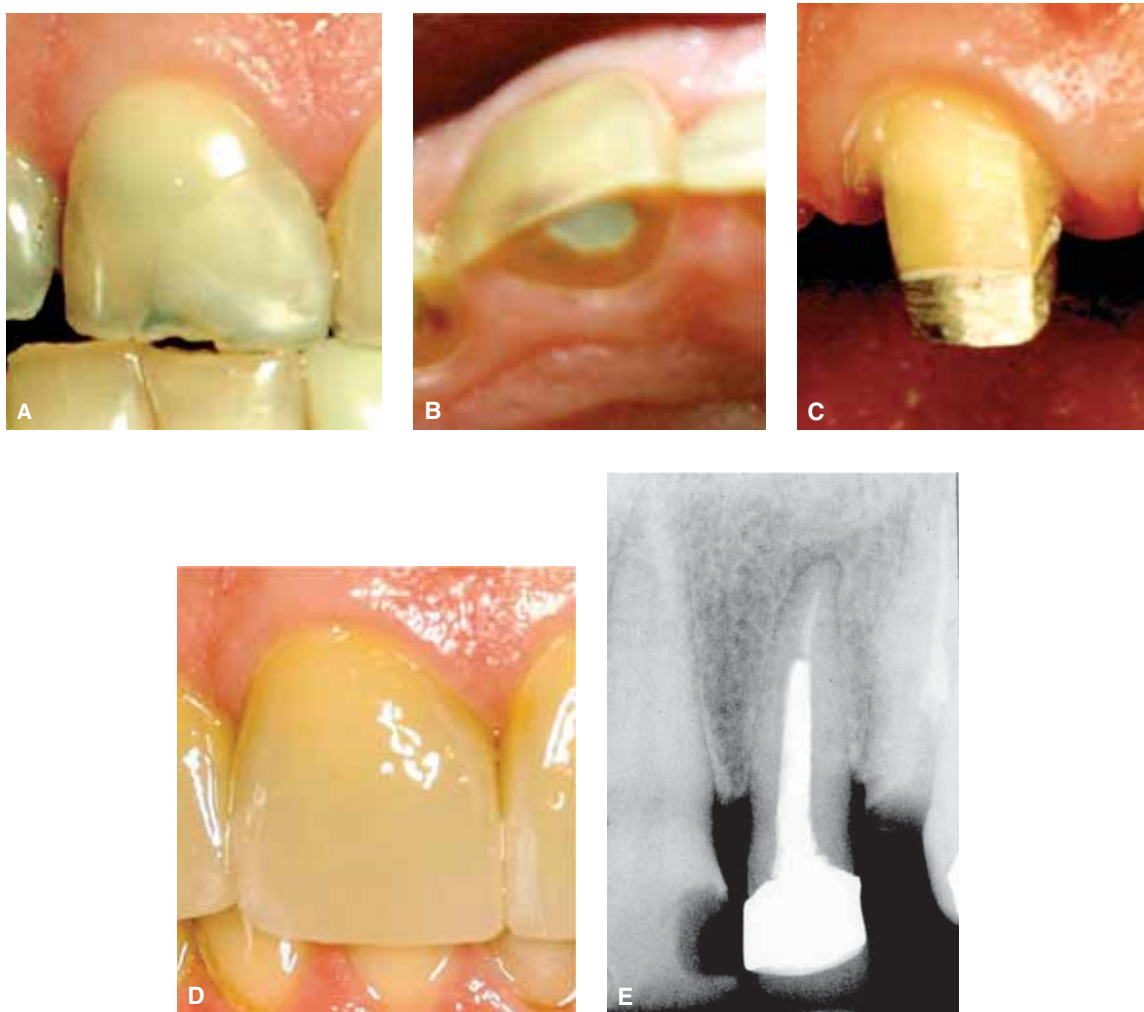


**FIGURE 8-18.** Radiograph of completed endodontic treatment. A lower left first molar where the root canals have been filled with *gutta percha* and *sealer*. The part of the crown that was lost has also been restored with a temporary filling. Both the gutta percha and the temporary filling appear *whiter* than enamel or dentin on the radiograph.

ensuing periapical disease. When the canal orifices have been located, endodontic files are used to remove the diseased pulp tissue and to begin cleaning the canals. In order to approximate the file length, the lengths of the corresponding root and crown are measured using a preoperative radiograph. Then, with the files carefully inserted into the root canals, a radiograph is made with the files in the root (Fig. 8-17). The positions and lengths of the files are adjusted to extend to approximately 1 mm short of the radiographic apex of the root (which corresponds to the natural constriction of the canal at the cementodentinal junction). The

canals are then *cleaned and shaped* at this length using incrementally larger diameter files until the root canal system is ready to be filled.

Following this cleaning procedure, the root canals may be *filled* with gutta percha (a rubber-type material) and a sealer (Fig. 8-18). Examples of sealers used today include resin, glass ionomer, zinc oxide and eugenol, and calcium hydroxide. When there is sufficient tooth structure remaining, the opening through the crown used to access the pulp may be *restored* with a tooth-colored composite or silver amalgam restorative material. Since teeth requiring endodontic treatment usually



**FIGURE 8-19.** Tooth No. 8 treated with a root canal, post and core, and all-ceramic crown. **A.** Tooth No. 8 is very thin faciolingually due to gastric acid reflux and is already fractured incisally. **B.** The lingual **access opening** (cut into the lingual surface of the crown in order to reach and remove the pulp tissue) is filled with a provisional (temporary) restoration. **C.** The tooth is prepared for a crown with the **post and core** cemented in place to provide additional crown support and retention. The **core** is the part of the metal that reproduces lost tooth crown. The attached **post** fits within the preparation in the center of the tooth root. **D.** An all-ceramic crown has been cemented over the tooth and post and core. (A, B, C, and D courtesy of Julie Holloway, D.D.S., M.S., The Ohio State University.) **E.** Radiograph of a post and core with a metal ceramic crown showing the **post** extending over halfway into the endodontically treated root.

have large restorations or are weakened by extensive decay, tooth structure may be restored with a crown. In some instances, a metal filling called a **post and core** can be used for additional retention and crown support. The *post* is the part that fits into the prepared root canal space, and the core reproduces lost tooth structure in order to provide adequate retention for the crown (Fig. 8-19).

Once a tooth has had endodontic therapy and the pulp has been removed, it should not be considered a “dead tooth” even though it no longer has a vital pulp. Although it cannot respond to stimuli like hot or cold, and cannot form reparative dentin, the periodontal support is the same as if it never had endodontic treatment. Therefore, if the periodontium remains healthy, the treated tooth generally can last for the lifetime of the patient.

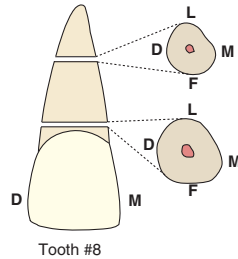
## SECTION II

## LOCATION OF ROOT AND CERVICAL CROWN CONCAVITIES, FURCATIONS, DEPRESSIONS, AND CANALS

The purpose of this section is to summarize the shape of the external root surface and the internal pulp shape at the level of the cemento-enamel junction and halfway down the root toward the apex. The following tooth drawings are labeled with M for mesial, D for distal, F for facial, and L for lingual.

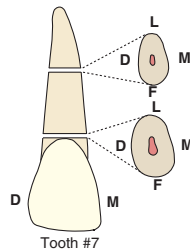
### A. MAXILLARY CENTRAL INCISORS

- The cross section of the root at the cervix is somewhat triangular with the mesial side longer than the distal side, consistent with the slight distal placement of the cingulum.
- There are no root grooves (depressions) on this incisor, though the mesial surface may be flattened or have a *slight* longitudinal depression. The distal root surface is convex.
- It has *one* root canal close to 100% of the time.



### B. MAXILLARY LATERAL INCISORS

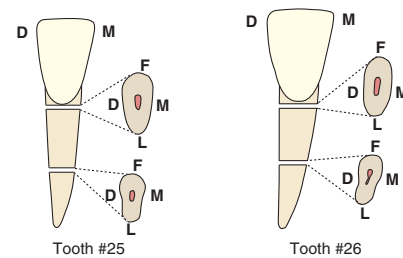
- The cross section of the root at the cervix is “egg shaped” or ovoid, with the widest mesiodistal portion on the labial.
- A shallow longitudinal root depression is sometimes found on the middle of the mesial root surface extending about half of the root length but not on the distal surface.
- There is *one* root canal close to 100% of the time.



### C. MANDIBULAR CENTRAL AND LATERAL INCISORS

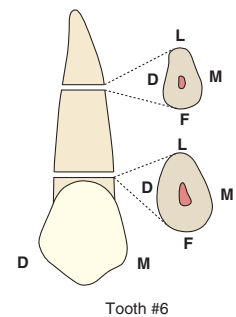
- In cross section, the cervical portion of the root is ovoid, considerably broader labiolingually than mesiodistally.

- Longitudinal root depressions are present on both proximal sides with the distal depression more distinct than the mesial.
- Most often there is *one* root canal.<sup>M</sup>



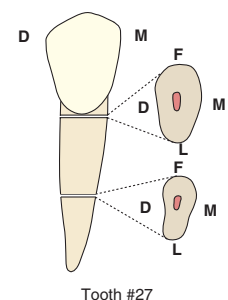
### D. MAXILLARY CANINES

- The cervical cross section is broad labiolingually and appears ovoid.
- Developmental grooves (depressions) are present on both sides, often deeper on the distal.
- As in other maxillary anterior teeth, there is *one* root canal almost 100% of the time.



### E. MANDIBULAR CANINES

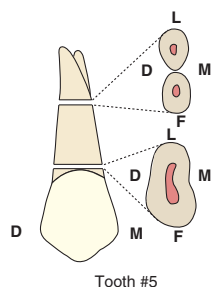
- Roots are wide labiolingually in the cervical half.
- Roots have prominent longitudinal root depressions on both sides, often deeper on the distal, or sometimes clearly separated roots (one labial and one lingual).
- There is most often *one* root canal.<sup>N</sup>



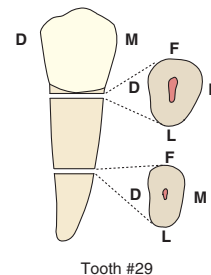


## F. MAXILLARY FIRST PREMOLARS

- There are most often two canals.<sup>o</sup>
- Most maxillary first premolars have two roots (one buccal and one lingual) and *two* canals, and even when only one root is present, two pulp canals are usually found.
- Mesial and distal root depressions occur on both one- and two-rooted first premolars (between the buccal and lingual roots or between the buccal and lingual halves of the single root).
- The prominent *mesial depression of the crown* continues across the cervical line to join the deep mesial root depression.
- When considering all premolars, the maxillary first premolar is **UNIQUE** since it has the only root where the mesial root depression is deeper than the distal root depression.
- When two roots are present, the bifurcation occurs in the apical third to half of the root.

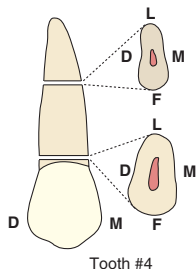


- Longitudinal depressions are not common on the mesial root surface but are frequent on the distal surface in the middle third.
- The cervical cross section of the root of the three-cusp premolars is particularly wide on the lingual, more so than on two-cusp types.
- The root is rarely bifurcated and almost always has *one* root canal.<sup>s</sup>



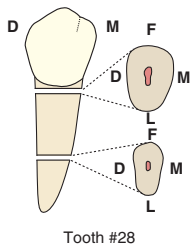
## G. MAXILLARY SECOND PREMOLARS

- Although there is normally only one root, there may be two roots as well.<sup>p</sup>
- There may be a shallow depression (sometimes called a developmental groove) on the mesial side of the root, but it does not extend onto the crown, as was seen on the maxillary first premolar. A root depression can usually be found on the distal side, often deeper than on the mesial.
- There is most often one root canal.<sup>q</sup>



## H. MANDIBULAR FIRST PREMOLARS

- In cross section, the cervical portion of the root is ovoid and is widest buccolingually.
- Longitudinal depressions are often present on both sides, deeper on the distal. Sometimes these depressions may be quite deep and end in a buccolingual apical bifurcation.
- There is usually *one* root canal.<sup>r</sup>

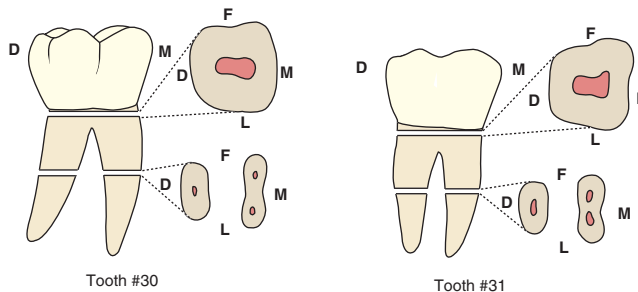


## I. MANDIBULAR SECOND PREMOLARS

- The cross section of the cervical portion of the root is ovoid buccolingually.

## J. MANDIBULAR FIRST AND SECOND MOLARS

- Mandibular molars normally have two roots: mesial (broader and longer) and distal. Both roots are broad buccolingually.
- Mandibular first and second molars normally have *three* root canals, two in the mesial root and one in the distal root.
- The **mesial** root of both molars commonly has prominent root depressions on the mesial and distal surfaces, and there are usually two root canals nearly 100% of the time. This root may even be divided into a buccal and lingual part. The distal root surface contours are more variable but may be convex.
- The **distal** roots in the mandibular first and second molars most often have one canal.<sup>t</sup>
- Access to the root bifurcations in the mouth is located near the midbuccal and midlingual root surfaces.
- The root trunk is shorter on first molars than on second molars; the furcation is nearest to the cervical line on the buccal of first molars. The cervical line is more occlusal on the lingual of first molars. Buccal and lingual depressions are seen on the relatively short root trunk, extending from the cervical lines to buccal and lingual furcations. (Recall that enamel at the buccal and lingual cemento-enamel junction may extend into the bifurcation.)
- First molar roots are broader and more widely separated than second molar roots, which may exhibit a distal inclination.

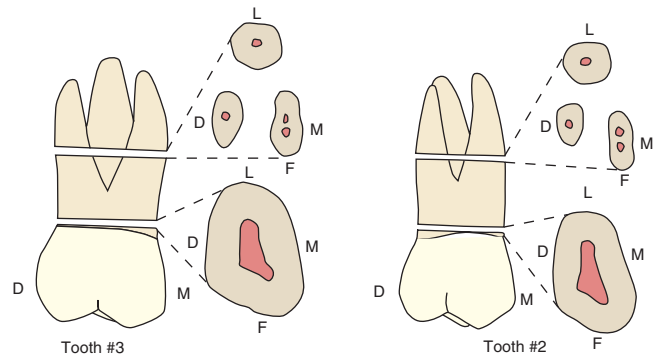




### K. MAXILLARY FIRST AND SECOND MOLARS

- There are normally three roots: mesiobuccal, distobuccal (shortest), and lingual (longest).
- Maxillary first and second molars usually have four root canals: two in the wide mesiobuccal root and one each in the distobuccal and lingual roots.
- The **mesiobuccal root** has mesial and distal side root depressions (and usually has two root canals).
- The distal contour of the **distobuccal root** varies but is normally convex (and normally has one canal).
- There is usually a slight longitudinal depression on the lingual side on the **lingual root** of the maxillary first molar. The lingual root has one canal.
- Access to furcations between the roots is located in the cervical third of the root: on the buccal surface, near the center mesiodistally, and on the mesial and distal surfaces, located slightly lingual to the center buccolingually.
- Often a depression extends from the trifurcation to the cervical line and sometimes into the enamel of the crown on first molars. A distal crown depression is often noted on the distal surfaces of maxillary first molars.

- Separation between roots is more pronounced on first molars than on second molars; on second molars, the buccal roots are more nearly parallel and inclined distally in their apical third.
- The root trunk is broader (longer) than on mandibular molars, so the furcation between the mesiobuccal and distobuccal root may be at the junction of the cervical and middle thirds of the mesiobuccal root, especially on second molars.



A summary of the presence and relative depth of longitudinal root depressions is presented in *Table 8-3*.

Table 8-3 SUMMARY: PRESENCE AND RELATIVE DEPTH OF LONGITUDINAL ROOT DEPRESSIONS (“ROOT GROOVES”)			
	TOOTH	MESIAL ROOT DEPRESSION?	DISTAL ROOT DEPRESSION?
MAXILLARY TEETH	Maxillary central incisor	No (or slight or flat)	No (convex)
	Maxillary lateral incisor	Variable	No (convex)
	Maxillary canine	Yes	Yes (deeper)
	Maxillary first premolar	Yes (deeper, extends onto mesial of crown)	Yes
	Maxillary second premolar	Yes	Yes (deeper)
	Maxillary first and second molars	<b>Mesiobuccal root:</b> Yes	Variable
		<b>Distobuccal root:</b> variable	No (convex) but root trunk has concavity between cervical line and distobuccal root
MANDIBULAR TEETH		<b>Lingual root:</b> lingual surface depression	
	Mandibular central incisor	Yes	Yes (deeper)
	Mandibular lateral incisor	Yes	Yes (deeper)
	Mandibular canine	Yes	Yes (deeper)
	Mandibular first premolar	Yes (or no: about 50%)	Yes (deeper)
	Mandibular second premolar	No (unlikely)	Yes (deeper)
	Mandibular first and second molars	<b>Mesial root:</b> Yes	Yes (deeper)
		<b>Distal root:</b> variable	Variable

General learning guidelines:  
 1. Maxillary incisors are less likely to have root depressions.  
 2. All canines and premolars (EXCEPT maxillary first premolars) and mandibular incisors are likely to have deeper distal surface root depressions.

## SECTION III

## ETHNIC VARIATIONS IN PULP AND ROOT CANAL MORPHOLOGY

Research on root canal and pulp morphology has shown that ethnic variations exist. Root canal variations are more prevalent in maxillary and mandibular premolars and molars, especially in Asian, Pacific, sub-Saharan, Australian, Middle Eastern, and subpopulations within these larger ethnic groups. One of the most frequent variations reported is the incidence of C-shaped root canals in the maxillary and mandibular molars and mandibular premolars in the Asian population.<sup>4</sup> A C-shaped canal is named for the ribbon-shaped, 180° arc morphology viewed in the cross section of a root that replaces the discrete, separate canal openings normally seen.

Another common variation is the incidence of bifurcated root canal systems in **mandibular first premolars**. A review of the literature shows a higher incidence of bifurcated root canals in African-Americans (16 to 33%), Turkish populations (36 to 40%), Kuwaiti populations (40%) and Chinese populations (22 to 36%) as compared to Caucasians (6 to 14%).<sup>5</sup> These variations need to be identified (usually using radiographs) prior to endodontic therapy so that appropriate adjustments to the access opening can be made, and thorough debridement of the root canals can be accomplished.

## Review Questions

Each of the following questions may have more than one correct answer.

- Which teeth are NOT likely to have root depressions on both the mesial and distal surfaces of the root?
  - Maxillary central and lateral incisor
  - Maxillary canine
  - Maxillary second premolar
  - Mandibular second premolar
- Maxillary anterior teeth are most likely to have how many root canals?
  - One
  - Two
  - Three
  - One or two
- Maxillary first molars are most likely to have \_\_\_\_\_ roots and \_\_\_\_\_ root canals?
  - Two, two
  - Two, three
  - Two, four
  - Three, three
  - Three, four
- The one premolar most likely to have two roots (and two root canals) is the
  - Maxillary first premolar.
  - Maxillary second premolar.
  - Mandibular first premolar.
  - Mandibular second premolar.
- The two roots of a maxillary first premolar are called
  - Mesial and lingual.
  - Mesial and distal.
  - Buccal and mesial.
  - Buccal and lingual.
  - Mesiobuccal and distobuccal.
- On a tooth with severe bone loss due to periodontal disease, a probe can access the root furcation of a maxillary first molar on which of the following surfaces?
  - Buccal surface
  - Lingual surface
  - Mesial surface
  - Distal surface

ANSWERS: 1—a, d; 2—a; 3—e; 4—a; 5—d; 6—a, c, d

## Critical Thinking

- Jeremiah Smith requires endodontic therapy on a maxillary first molar. How can the dentist determine how many canals this tooth has that require filling? Optional for a take home assignment: the student may ask a dentist for advice.

## REFERENCES

1. Benjamin KA, Dowson J. Incidence of two root canals in human mandibular incisor teeth. *Oral Surg* 1974;38:123–126.
2. Rankine-Wilson RW, Henry P. The bifurcated root canal in lower anterior teeth. *JADA* 1965;70:1162–1165.
3. Bellizzi R, Hartwell G. Clinical investigation of in vivo endodontically treated mandibular anterior teeth. *J Endod* 1983;9:246–248.
4. Jafazadeh H, Wu YN. The C-shaped root canal configuration: a review. *J Endod* 2007;33:517–23.
5. Cleghorn B, Christie W, Dong C. The root and root canal morphology of the human mandibular first premolar: a literature review. *J Endod* 2007;33:509–16.
6. Perlich MA, Reader A, Foreman DW. A scanning electron microscopic investigation of accessory foramina on the pulpal floor of human molars. *J Endod* 1981;7:402–406.
7. Vertucci FJ, Gegauff A. Root canal morphology of the maxillary first premolar. *JADA* 1979;99:194–198.
8. Bellizzi R, Hartwell G. Radiographic evaluation of root canal anatomy of in vivo endodontically treated maxillary premolars. *J Endod* 1985;11:37–39.
9. Vertucci FJ. Root canal anatomy of the human permanent teeth. *Oral Surg* 1984;58:589–599.
10. Gilles J, Reader A. An SEM investigation of mesiolingual canal in human maxillary first and second molars. *Oral Surg Oral Med Oral Pathol* 1990;70:638–643.
11. Neaverth EJ, Kotler LM, Kaltenbach RF. Clinical investigation (in vivo) of endodontically treated maxillary first molars. *J Endod* 1987;13:506–512.
12. Skidmore AE, Bjorndal AM. Root canal morphology of the human mandibular first molar. *Oral Surg* 1971;32:778–784.
13. Shaw L, Jones AD. Morphological considerations of the dental pulp chamber from radiographs of molar and premolar teeth. *J Dent* 1984;12:139–145.

## OTHER GENERAL REFERENCES

- Estrela C, Pereira HL, Pecora JD. Radicular grooves in maxillary lateral incisor: case report. *Braz Dent J* 1995;6(2):143–146.
- Pecora JD, Saquy PC, Sousa Neto MD, et al. Root form and canal anatomy of maxillary first premolars. *Braz Dent J* 1991;2(2):87–94.
- Pecora JD, Sousa Neto MD, Saquy PC, et al. In vitro study of root canal anatomy of maxillary second premolars. *Braz Dent J* 1992;3(2):81–85.
- Pecora JD, Woelfel JB, Sousa Neto MD. Morphologic study of the maxillary molars. Part I: external anatomy. *Braz Dent J* 1991;2(1):45–50.
- Pecora JD, Woelfel JB, Sousa Neto MD, et al. Morphologic study of the maxillary molars. Part II: internal anatomy. *Braz Dent J* 1992;3(1):53–57.
- Walton RE, Torabinejad M. Principles and practice of endodontics. 3rd ed. Philadelphia, PA: W.B. Saunders Company, 2002.
- Web site: American Association of Endodontists (with information for the professional and for media/public). <http://www.aae.org/media/index.html>



## Original Research Data

Specific facts are referenced throughout this chapter by using superscript letters like this (data<sup>A</sup>). The referenced facts are listed here after each letter.

- A. On the underneath surface of the root in the furcation, accessory canals occur 64% of the time.<sup>6</sup>
- B. Mandibular central and lateral incisors have one root canal 60% of the time. Mandibular central incisors may have two canals with two separate apical foramina (type III) 3% of the time, and two canals converging to one foramen (type II) from 17 to 43% of the time. Mandibular lateral incisors may have two canals from 20 to 45% of the time (usually type II with one foramen or type III with two separate foramina about 3% of the time). Mandibular canines may have two canals from 4 to 22% of the time. When two canals are present, one is facial and one is lingual, often with type IV formation.
- C. Approximately 57% of maxillary first premolars have two roots, but only 39% have one root. When two roots are present, the canals in both roots exhibit a type I configuration, and, when one root is present, the canal configuration is either a type II or type III.<sup>7</sup>
- D. The incidence of three roots is approximately 4%.<sup>7</sup>
- E. According to one researcher, the average incidence of two canals in a maxillary second premolar is close to 50% (type II or type III). Three canals occur about 1% of the time.<sup>8</sup>
- F. Mandibular first premolars have one root and one canal (type I) 70% of the time (Fig. 9-10A) and 98% of the time in second premolars. Mandibular first premolars may have two canals (type IV) 24% of the time (Fig. 9-10B), but mandibular second premolars have two canals only 2.5% of the time.<sup>9</sup>

- G. The mesiobuccal root of the maxillary first molar has two canals 90% of the time, one located more buccally within this root called mesiobuccal canal, and one located more lingually within this root called the mesiolingual canal. Type III canal systems have been reported to occur 33 to 60% of the time.<sup>10</sup> Opening into the palatal root canal, the palatal orifice on the floor of the pulp chamber is located beneath the mesiolingual cusp (Fig. 8-9). Opening into the mesiobuccal root, the mesiobuccal orifice is located slightly mesial to and beneath the mesiobuccal cusp tip. The mesiolingual orifice is located slightly to the palatal aspect of the mesiobuccal orifice. Usually, this orifice is difficult to locate because of an overhanging dentin shelf. Opening into the distobuccal root, the distobuccal canal orifice is located on a line between the palatal orifice and the buccal developmental groove at a point just short of the angle formed by the buccal and distal walls of the pulp chamber.
- H. The mesiobuccal root of the maxillary second molar has two canals 70% of the time.<sup>10</sup>
- I. The mesial roots of mandibular *first* molars have two canals virtually all of the time: a type III canal system is present 60% of the time, and a type II canal system is present 40% of the time.<sup>11</sup> The mesial roots of mandibular *second* molars have two canals 64% of the time: a type II canal system 38% of the time and a type III canal system 26% of the time, but one canal 27% of the time.<sup>9</sup>
- J. In the distal roots of mandibular *first* molars, there are two canals approximately 35% of the time, usually type II configuration,<sup>12</sup> whereas the distal roots of mandibular *second* molars have one canal 92% of the time.<sup>9</sup>
- K. In both mandibular first and second molars, the mesiobuccal canal orifice on the chamber floor is located slightly mesial but close to the mesiobuccal cusp tip (Fig. 8-9). The mesiolingual canal orifice is just lingual to the mesial developmental groove of the mesial marginal ridge. It is not under the mesiolingual cusp tip but is in a more central location. If the distal root has one canal, the distal canal orifice is large and located just distal to the center of the crown. When two canals are present, the distolingual orifice is small and is located centrally just lingual to the central fossa. Careful inspection of the chamber floor toward the buccal will successfully locate the distobuccal orifice.
- L. In a radiographic study of 259 children in England, from their 11th to 14th birthdays, the mesiodistal and roof-to-floor pulp dimensions were recorded with a Lysta-Dent Digitizer. Mesiodistal reduction in size in mandibular first molars over 3 years was minimal (1 to 3.5%) compared to a considerable height reduction (15%) of the pulp chambers. This was mostly the result of secondary dentin deposition on the floor, not the roof, of the chamber.<sup>13</sup>
- M. Mandibular incisors have one canal about 70% of the time for centrals and 55% for laterals.
- N. Mandibular canines have one root canal about 70% of the time.
- O. Maxillary first premolars have two canals about 90% of the time.
- P. Maxillary second premolars have two roots 11% of the time.
- Q. There are two root canals in maxillary second premolars about 50% of the time.<sup>8</sup>
- R. Mandibular first premolars have one root canal 70% of the time.
- S. Mandibular second premolars have one root canal 96% of the time.
- T. The distal roots of mandibular molars have one root canal 65% of the time in the first molar and 92% of the time in the second molar.

## Functional Occlusion and Malocclusion

- I. Ideal occlusion versus malocclusion
  - A. Ideal class I occlusion
  - B. Dental malocclusions of teeth
  - C. Class II malocclusion
  - D. Class III malocclusion
- II. Movements within the temporomandibular joint
  - A. Anatomy of the temporomandibular joint
  - B. Movements within the lower joint space
  - C. Movements within the upper joint space
  - D. Total joint movement
  - E. Dislocation of the mandible
- III. Terms used to describe jaw relationships between the mandible and the maxillae
  - A. Maximal intercuspal position
  - B. Centric relation
  - C. Physiologic rest position
  - D. Jaw relationships during horizontal movements of the mandible
- IV. Functional movements when eating: chewing and swallowing
  - A. Incising
  - B. Mastication (chewing)
  - C. Swallowing (deglutition)
- V. Parafunctional movements and heavy tooth contacts: signs and symptoms
- VI. Treatment methods related to malocclusion
  - A. Patient education and behavior therapy
  - B. Stress management and muscle relaxation
  - C. Changing jaw relationships with an occlusal devise
  - D. Changing tooth shapes to treat symptoms of malocclusion
  - E. Changing tooth location to treat malocclusion
- VII. Advanced topics in occlusion
  - A. Envelope of motion
  - B. Accurate recording of the centric relation jaw position
  - C. Long centric articulation

**A**CKNOWLEDGMENT: This chapter was proofed for current terminology by Dr. Shereen S. Azer, B.D.S., M.Sc., M.S. He graduated from the College of Dentistry, Alexandria University, Egypt, where he obtained a Master's Degree in Conservative Dentistry. He received his Advanced Combined Prosthodontics training at the University of Illinois at Chicago and is currently an Assistant Professor at the Ohio State University College of Dentistry where he directs the Occlusion and TMD course.

An introduction to ideal occlusion was discussed earlier in Chapter 1, Section VII. This chapter includes a more in-depth discussion of occlusion including tooth and jaw relationships during function, as well as the terminology and concepts associated with malocclusion (which literally means “bad” occlusion). Research findings and advanced topics are referenced throughout this chapter using superscript letters like this (data<sup>A</sup>). The referenced data are listed at the end of this chapter.

### OBJECTIVES

This chapter is designed to prepare the learner to perform the following:

- Define Angle's class I, II, and III relationships.
- List and describe types of tooth and jaw malocclusions.
- Describe and locate (on a skull) the articulating parts of the temporomandibular joint (TMJ).
- Describe the location and functions of the articular disc.
- Palpate the lateral and posterior surfaces of the condyle of the mandible during movement of the jaws.
- Describe and demonstrate mandibular movement within the lower joint space (rotation) and within the upper joint space (translation).
- Describe mandibular dislocation (luxation) and demonstrate how to alleviate this problem with appropriate mandibular manipulation.
- List and describe signs and symptoms of malocclusion (including the possible effects of premature contacts and parafunctional movements).
- Describe and recognize the following jaw relationships: maximal intercuspal position (MIP), centric jaw relation, and occlusal vertical dimension.



- Describe and recognize the following horizontal eccentric movements: protrusive movement (including the effect of horizontal and vertical overlap on incisal guidance) and lateral movement (including the effect of canine overlap on canine-protected occlusion).
- Define and recognize tooth relationships during lateral movements on the working and nonworking articulation.
- Describe the relationship of teeth and adjacent oral structures during eating.
- Describe (and sketch) an ideal envelope of motion from the facial and sagittal views and label mandibular tooth positions or movements for each segment of the envelope.
- Define and provide examples of parafunctional movements.
- List and describe possible methods of treatment for bruxing, myofunctional trigger points (pain), and temporomandibular disorders (TMDs) including the steps for construction of an occlusal device (bite guard).
- Describe a method for accurately recording a centric relation (CR) position of the mandible.
- Sketch, from memory, the tooth crown outlines on one side of the mouth in ideal class I occlusion.

## SECTION I

## IDEAL OCCLUSION VERSUS MALOCCLUSION

**Ideal occlusion** is the harmonious static and dynamic relationship of teeth *and* jaws that dentists would like to reproduce when restoring a patient's entire mouth to good form and function. **Malocclusion**, on the other hand, is literally a "bad" occlusion, or a deviation from the ideal. Malocclusion can be due to an improper alignment of the *teeth* within an arch or a lack of harmony between the size and shape of the *jaws* that prevents teeth from fitting together ideally.

Dr. Edward Angle first defined three classes of **jaw relationships** in 1887. An ideal or normal front-to-back (anteroposterior) relationship between the upper and lower jaws is known as class I occlusion. In contrast, persons with class II or class III jaw relationships have a malocclusion because of a considerable difference in size, or the abnormal positional relationship, of the mandible relative to the maxillae. Each class of occlusion is defined by the relationship of the first teeth

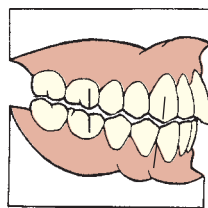
to erupt in the adult dentition, namely, the maxillary and mandibular first molars, or, if the first molars are absent, by the relationship between the maxillary and mandibular canines.

## A. IDEAL CLASS I OCCLUSION

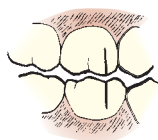
The teeth of a person with **ideal occlusion** are aligned within each arch so that they fit together and function harmoniously, *and* the jaws are in a class I relationship. Recall from Chapter I that **class I occlusion** (also called **neutroclusion** or **normal occlusion**) is defined as the relationship of permanent first molars where the tip of the *mesiobuccal cusp on the maxillary first molar is aligned with the mesiobuccal groove on the mandibular first molar* (Fig. 9-1A and B) and the maxillary canine fits into the facial embrasure between the mandibular canine and the first premolar (Fig. 9-1A).

## Class I (72%)

Normal



A




B

Normal



C

Orthognathic profile



D

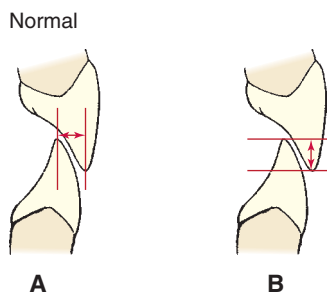
FIGURE 9-1.

**Angle's class I occlusion:** occurs in approximately 72% of the population. **A.** Lateral view of tooth models with the teeth aligned in class I occlusion. **B.** The first molar relationship showing the mesiobuccal cusp of the maxillary first molar aligned with the mesiobuccal groove of the mandibular first molar. **C.** Normal anterior relationship of incisors. **D.** The normal, **orthognathic profile** of a person having class I tooth relationships.

The facial profile of a person with class I occlusion tends to form a rather straight line from the top half of the face to the anterior border of the mandible and is called **orthognathic** [OR thog NA thik], where “gnathic” pertains to the jaw and “ortho” means a straight or normal jaw profile in Fig. 9-1D). (Compare the word *orthognathic* that refers to a straight jaw profile, and *orthodontics* that means tooth straightening.) This profile may also be called **mesognathic** (not mesognathic), and is characterized by a lack of obvious protrusion or retrusion of the resting mandible relative to the maxillae.

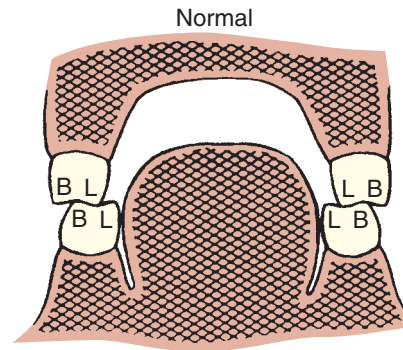
*Ideal occlusion* also required the perfect fitting together (interdigitation) of the upper and lower teeth as described here.

- The incisal edges of maxillary teeth are labial to the incisal edges of mandibular teeth. An example of this **normal horizontal overlap** or **normal overjet** is shown in *Figure 9-2A*.
- The incisal edges of mandibular incisors are hidden from view by the overlapping maxillary incisors. An example of this **normal vertical overlap** or **normal overbite** is shown in *Figure 9-2B*.
- *Buccal* cusps and buccal surfaces of the maxillary posterior teeth are buccal to those in the mandibular arch, whereas the *lingual* cusps and lingual surfaces of the mandibular posterior teeth are lingual to those in the maxillary arch (Fig. 9-3).
- *Lingual* cusps of maxillary posterior teeth rest in occlusal fossae of the mandibular teeth, whereas the *buccal* cusps of the mandibular teeth rest in occlusal fossae of the maxillary teeth (Fig. 9-3).



**FIGURE 9-2.** Angle's class I occlusion: incisor relationship.

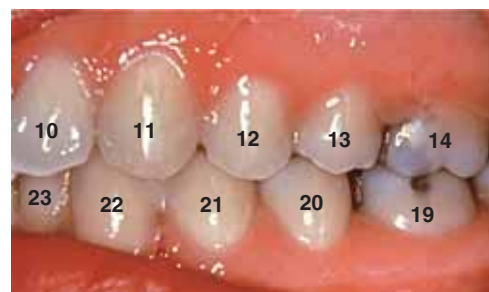**A.** Normal *horizontal* alignment has the incisal edge of the maxillary incisors anterior to the incisal edge of the mandibular incisors, also known as **normal overjet** (denoted by the horizontal arrow). **B.** Normal *vertical* alignment has the incisal edge of the maxillary incisors overlapping (hiding from view) the incisal third of the mandibular incisor, also known as **normal overbite** (denoted by the vertical arrow).



**FIGURE 9-3.** Normal molar relationship in cross section.

The buccal cusps of maxillary molars are facial to the buccal cusps of the mandibular molars, and the lingual cusps of the mandibular molars are lingual to the lingual cusps of the maxillary molars. Also notice that the lingual cusps of maxillary molars occlude with the fossae in mandibular molars, and the buccal cusps of mandibular molars occlude with fossae in maxillary molars.

- The vertical (long) axis midline of each maxillary tooth is positioned slightly distal to the vertical axis of the corresponding mandibular tooth. For example, in *Figure 9-4*, the center of the maxillary canine (No. 11) is distal to the mandibular canine (No. 22), the center of the maxillary first premolar (No. 12) is distal to the mandibular first premolar (No. 21), and so forth.
- Perfect interdigitation of the upper and lower teeth also requires that teeth in each arch be aligned with other teeth in each arch. Therefore, a person with a class I jaw relationship does not have ideal occlusion if one or more teeth are not aligned with others to form an ideal arch shape.<sup>1</sup> Examples of poor alignment within the arch are described next.



**FIGURE 9-4.** Ideal tooth alignment in Angle's class I occlusion. The center axis of the teeth in the maxillary arch is aligned just distal to the center axis of the same type of tooth in the mandibular arch. For example, look at the two opposing canines: No. 11 is just distal to No. 22.

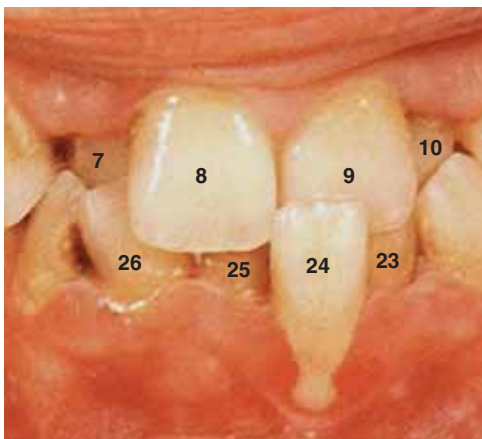
## B. DENTAL MALOCCLUSIONS OF TEETH

Malocclusion can be detrimental if it adversely affects appearance, comfort, or function. Dental malocclusion of individual teeth can occur in mouths with class I, II, or III jaw relationships.

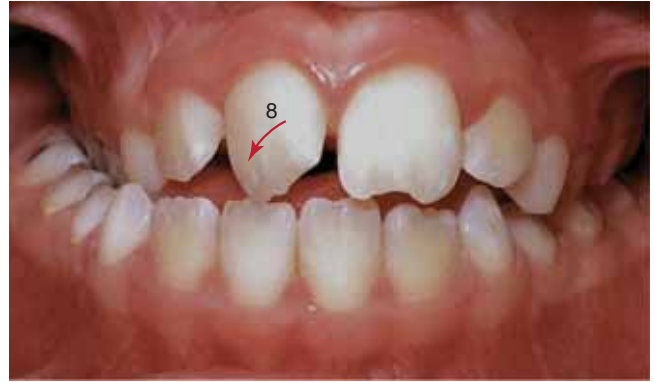### 1. TERMS DEFINING POOR ALIGNMENT OF TEETH WITHIN AN ARCH

Malocclusion can occur when individual teeth or groups of teeth are not aligned to fit into an ideal parabolic arch form and/or do not form a level occlusal plane.

- A tooth that is out of alignment to the labial or buccal compared to the ideal arch form of other teeth is in **labioversion** (also labial version), a term used for an anterior tooth like tooth No. 24 in *Figure 9-5* or **buccoversion** (also buccal version) if referring to a posterior tooth.
- A tooth that is out of alignment to the lingual compared to other teeth in the arch is in **linguoversion** (also lingual version), a term used to describe teeth Numbers 7 and 10 in *Figure 9-5*.
- A tooth that is twisted (rotated) around its tooth axis is described as **torsiversion**, a term used to describe tooth No. 8 in *Figure 9-6*.
- A tooth that is overerupted is abnormally long relative to the rest of the occlusal surfaces, and it exhibits **supraeruption** or **extrusion**, terms that can be used to describe the maxillary third molar in *Figure 9-7*.
- If a tooth is abnormally short relative to the rest of the occlusal plane, it is in **infraocclusion** (or infraversion).



**FIGURE 9-5.** Crowding of anterior teeth. Notice that the mandibular left central incisor (No. 24) is in **labial version** (positioned labial to the normal arch form), whereas the maxillary lateral incisors (Numbers 7 and 10) are in **lingual version**. This poor alignment has resulted in these three teeth being in a cross-bite relationship with their opposing teeth.

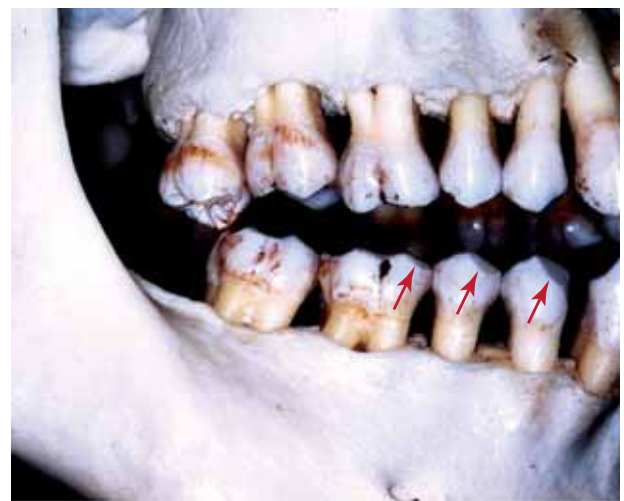

**FIGURE 9-6.** Torsiversion (twisting) of tooth No. 8, the maxillary right central incisor. Also notice that the posterior teeth on the patient's right side (left side of photo) are in cross-bite, and on the patient's left side, the premolars in the shadows appear to be in an end-to-end relationship.

This may occur when a short primary tooth is retained into adulthood or when a primary or secondary tooth loses its periodontal ligament and the cementum of the root fuses with the surrounding alveolar bone preventing further eruption. This fusion of cementum to bone is called **ankylosis** [ANG ki lo sis].

### 2. TERMS RELATED TO TOOTH-TO-TOOTH MALOCCLUSION

When opposing teeth do not align themselves ideally into the ideal maximal intercuspation, the following variations can occur.



**FIGURE 9-7.** **Supraeruption** (extrusion) of the maxillary third molar, No. 1. Arrows point to **facets** (flattened areas) caused by heavy tooth contacts that occur when the posterior teeth come together and function.

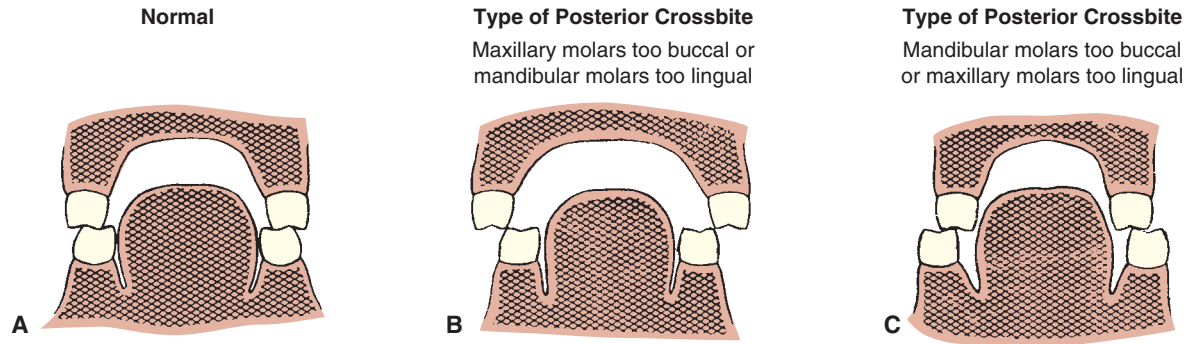


FIGURE 9-8.

Molar relationships in cross section. **A.** Views of the **normal occlusion** with the buccal surfaces of maxillary molars facial to mandibular molars. **B.** Maxillary molars exhibit **posterior crossbite** (with mandibular molars totally to the lingual of the maxillary molars). This condition is common in persons with class II malocclusion where the mandible is small relative to the maxillae. **C.** **Posterior crossbite (reverse articulation)** with the buccal cusps of maxillary molars and lingual cusps of mandibular molars occluding into opposing fossae. This condition is common in persons with class III malocclusion, where the mandible is large relative to the maxillae.

- When buccal cusps of maxillary posterior teeth line up directly over mandibular buccal cusps, the relationship is called an **end-to-end** occlusion. An end-to-end occlusal relationship is seen between first premolars in the shadows on the right side of the photograph in Figure 9-6.
- **Posterior crossbite (reverse articulation)** occurs when mandibular posterior teeth are positioned too far buccally so that the *lingual* cusps of mandibular teeth (and not the buccal cusps) are positioned in the central fossae of the maxillary teeth as seen between molars in Figure 9-8C and on the left side of the photograph in Figure 9-6. Mandibular posterior teeth are also in crossbite if *both* cusps are positioned to the lingual of the opposing maxillary teeth. This is the case in Figure 9-8B where the mandibular molars are so lingual (or maxillary molars are so buccal) that they are in crossbite.
- When mandibular anterior teeth are facial to maxillary anterior teeth, this is called an **anterior crossbite (reverse articulation)** as seen in Figure 9-9. Compare this to the ideal anterior relationship where mandibular incisors are lingual to maxillary incisors.
- When viewed from the facial, maxillary incisors normally *vertically* overlap the incisal thirds of mandibular incisors (recall Fig. 9-2). This amount of vertical overlap is considered a **normal overbite**. An anterior overbite is considered to be a **severe overbite** when maxillary incisors overlap mandibular incisors down to the level of the cervical lines of the mandibular incisors hiding them from view (Fig. 9-10A). In some persons, mandibular incisors in severe overbite may actually impinge upon the tissue of the roof of the mouth (hard palate) and result in an imprint in, or

damage to, that tissue. In people with a severe overbite, jaw joint problems can occur since the mandible cannot move freely forward without dropping down considerably before it can move forward.

- If the posterior teeth are in maximum intercuspation and maxillary incisal edges line up touching mandibular incisal edges with *no* vertical overlap, the result is an **edge-to-edge** relationship (Fig. 9-10B).
- An anterior **open bite** occurs when the posterior teeth occlude, but there is a space between opposing incisal edges (also called an open occlusal relationship) (Fig. 9-10C). In persons with this relationship, the posterior teeth occlude as the mandible moves forward but not the anterior teeth.
- The amount of horizontal overlap between these teeth is called the **overjet**. It is normal for the incisal edges of mandibular incisors to come close to occluding with the lingual surfaces of maxillary incisors when

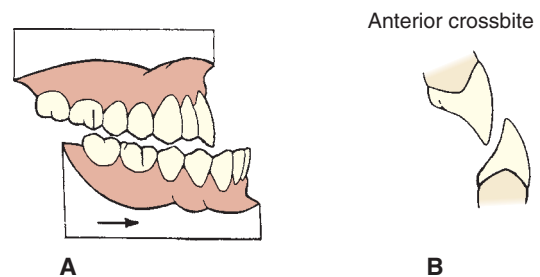
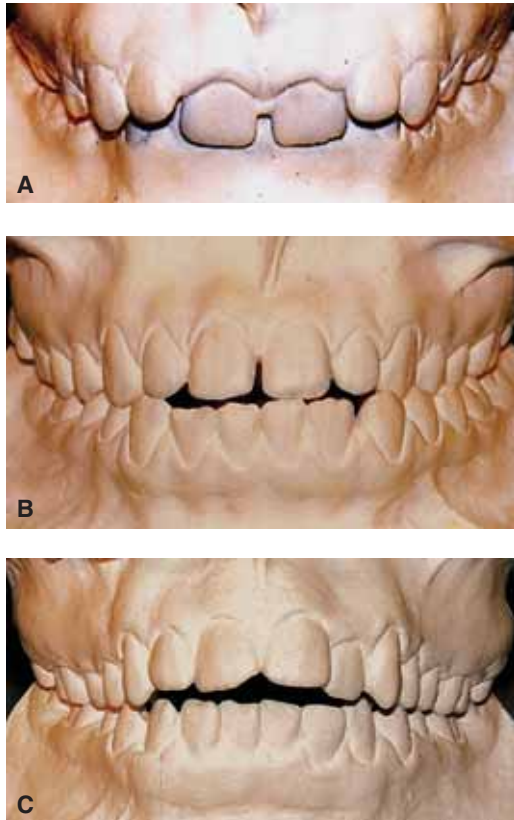


FIGURE 9-9.

**Anterior crossbite.** **A.** Dental arches showing the shift in alignment of jaws (Angle's class III occlusion) resulting in anterior teeth in crossbite (mandibular incisors are anterior to maxillary incisors). **B.** Close-up of the incisors in crossbite.



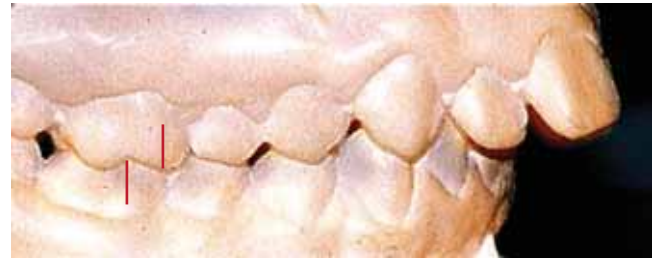

**FIGURE 9-10.** Three types of anterior tooth relationships.

**A. Severe overbite** with maxillary incisors completely overlapping (covering up) the mandibular incisors. Note that the maxillary incisors are tipped inward relative to the lateral incisors, which are flared normally outward. This is a common relationship in patients with **Angle's class II, division 2 occlusion**. **B. Edge-to-edge** bite where the incisal edges of the maxillary incisors line up directly over the incisal edges of mandibular incisors. This anterior relationship is common in persons with class III occlusion. **C. Anterior open bite** where the incisal edges of the maxillary incisors neither overlap vertically nor touch the incisal edges of mandibular incisors.

a person closes the posterior teeth together. A **severe overjet** is seen in *Figure 9-11* where the maxillary incisors are considerably anterior to the mandibular incisors. This overlap may contribute to **crepitation**, a crackly or grating sound within the jaw joint during function.<sup>A</sup>

Poorly aligned teeth that occlude before other teeth in the mouth are said to have **premature contacts** (or to be in **heavy occlusion**). These teeth are exposed to heavier forces than other teeth, especially in persons who exhibit **bruxism** [BRUCKS iz em], that is, who involuntarily grind their teeth, especially at night. These premature contacts could also be called **deflective occlusal contacts** if, upon closing in a posterior position, the



**FIGURE 9-11.** Severe overjet relationship of incisors. Notice the overjet and flare of the maxillary incisors, which is common in persons with **division 1 anterior relationship of class II occlusion**. Class II occlusion is confirmed since the mesiobuccal groove of the mandibular first molar is distal to the mesiobuccal cusp of the maxillary first molar.

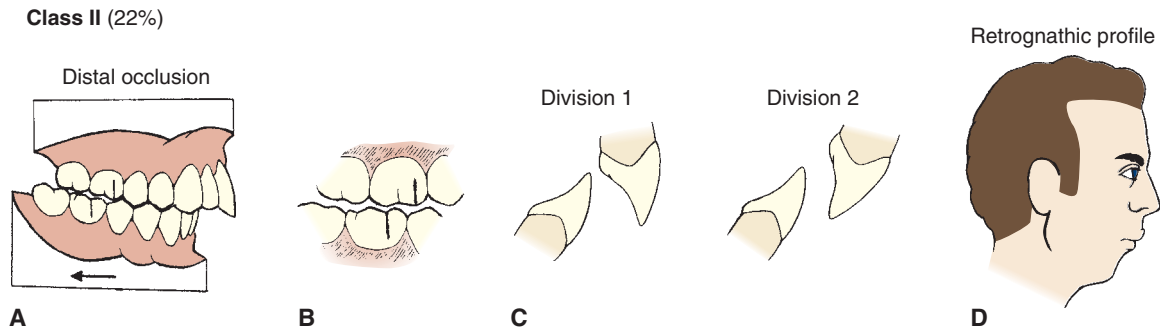
teeth do not close directly into best or tightest fit but instead hit the prematurity, which deflects the mandible (changes direction of the mandible) before it can reach its tightest fit. This closure is different than the way the relaxed chewing muscles and anatomy of the jaw joint would guide the jaws together if there were no teeth. This could eventually contribute to the wearing away of enamel forming a **facet** [FAS it] or flat spot, clearly evident on the occlusal surfaces of the mandibular premolars and first molar in *Figure 9-7*. Under certain circumstances, this imbalance can cause muscle pain.

### C. CLASS II MALOCCLUSION

A **class II relationship** (or **disto-occlusion**) is a skeletal type of malocclusion where the mandibular teeth are in a **distal** (or **posterior**) relationship with their normal maxillary opponents (*Fig. 9-12A*). A person with class II occlusion may have a mandible that is too small, maxillae that are too large, or both. The result is a mandible that appears behind (retruded from) where it should normally be located. That is, the mandible is in **disto-occlusion**, and the person has a **receded chin**. This profile (with a **retruded mandible**) is convex and is called **retrognathic** [ret rog NATH ik] (*Fig. 9-12D*).

In a person with class II occlusion, the mesiobuccal groove of the mandibular first molar is **distal** to the mesiobuccal cusp of the maxillary first molar by a distance at least the width of a premolar (*Fig. 9-12A* and *B*). That is, the mandible is distal to where it is located in a person with class I occlusion. If the alignment differs by less distance than the width of a premolar, it is called a **tendency toward class II occlusion**. There are two subdivisions of this type of skeletal malocclusion based on the inclination and overlap of the maxillary incisors. They are known as **division 1** and **division 2** (as seen in *Fig. 9-12C*).



**FIGURE 9-12.**

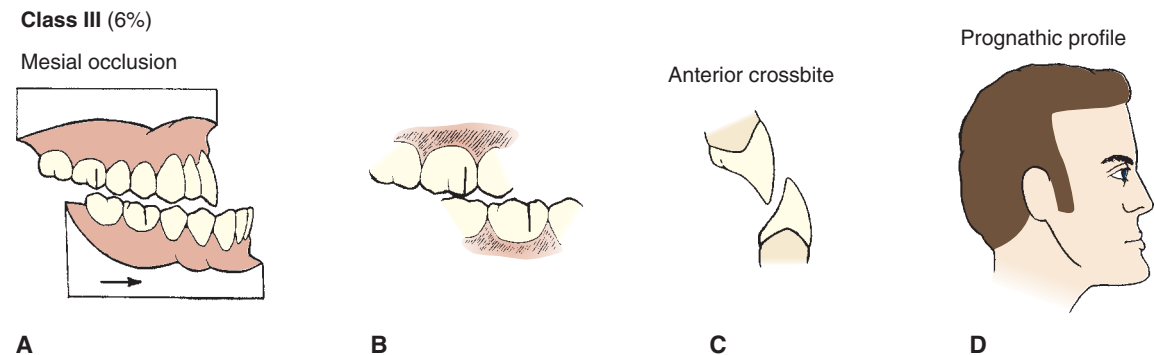
**Angle's class II occlusal relationship.** **A.** Lateral view of tooth models with the teeth aligned in class II occlusion. **B.** The first molar relationship showing the mesiobuccal groove of the mandibular first molar *distal* to the mesiobuccal cusp of the maxillary first molar. **C.** Two **divisions** of anterior relationship of incisors: **Division 1** is where maxillary and mandibular incisors flare labially. **Division 2** is where the maxillary incisors (especially central incisors) are flared (tipped) to the lingual. **D.** The **retrognathic profile** associated with a person having class II tooth relationships.

- Class II, **division 1** is an incisor relationship where maxillary incisors labial inclination is similar to incisors found in normal class I occlusion (seen in Fig. 9-11). People with this relationship often exhibit unique oral traits including a severe horizontal overjet of maxillary incisors labial to mandibular incisors, and supraeruption of mandibular incisors.<sup>B</sup>
- Class II, **division 2** is an incisor relationship where the maxillary central incisors are retruded with a severe *lingual* inclination, whereas the lateral incisors are labially inclined. This is evident in Figure 9-10A where maxillary central incisors tilt quite a bit to the lingual, especially relative to the adjacent labially flared lateral incisors. These people are likely to have other unique morphology including very little horizontal overjet but a severe vertical overbite.<sup>C</sup>

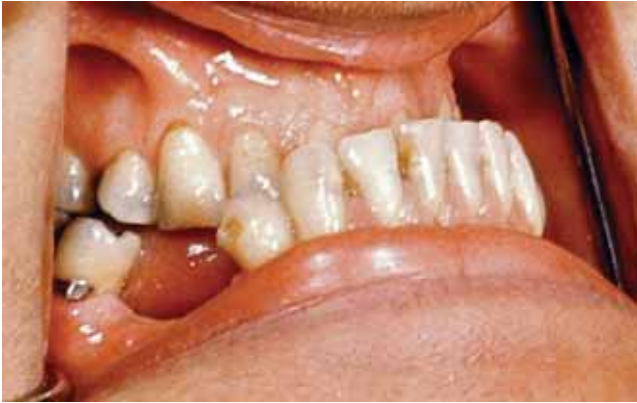### D. CLASS III MALOCCLUSION

Persons with a **class III** relationship or **mesio-occlusion** have a skeletal type of malocclusion where the mandibular dental arch is *anterior* to the maxillary dental arch. Persons with this relationship have a relatively large mandible compared to their maxillae, so their facial profile is concave with a very prominent chin. This profile (with a *protruded* mandible) is called **prognathic** [prog NA thik] (Fig. 9-13A, B, and D).

For persons with a class III molar relationship, the mesiobuccal groove of the mandibular first molar is *mesial* to the mesiobuccal cusp of the maxillary first molar by at least the width of a premolar (Fig. 9-13A and B). That is, the mandible is mesial to where it is located in a person with class I occlusion. If the difference in alignment is less distance than the width of a premolar, it is called a *tendency toward* class III

**FIGURE 9-13.**

**Angle's class III occlusal relationship.** **A.** Lateral view of tooth models with the teeth aligned in class III occlusion. **B.** The first molar relationship showing the mesiobuccal groove of the mandibular first molar *mesial* to the mesiobuccal cusp of the maxillary first molar. **C.** Anterior relationship of incisors: anterior crossbite. **D.** The **prognathic profile** associated with a person having class III tooth relationships.



**FIGURE 9-14.** Severe anterior crossbite in a person with class III occlusion.

## SECTION II

## MOVEMENTS WITHIN THE TEMPOROMANDIBULAR JOINT

The human TMJ is unique to mammals in that movement of this joint includes a combination of both *hinge* and *gliding* movement.<sup>F</sup> This unique, complex type of joint may be called ginglymoarthrodial [JIN gli mo ar THRO de al], where *ginglymus* refers to a joint that allows the mandible to rotate like a **hinge** against the base of the skull, whereas *arthrodia* refers to the capability of the entire mandible to bodily move or glide a bit forward or from side to side (called **translational movement**). In order to understand how this complex joint works, you first need to understand how the jaw joint is put together.

### A. ANATOMY OF THE TEMPOROMANDIBULAR JOINT

This introduction to the anatomy of the jaw joint is brief. A more complete discussion of this joint relative to the other structures of the skull (other bones plus muscles, ligaments, nerves, and blood vessels) can be found in Chapter 14.

A **joint**, or articulation, is a connection between two separate parts of the skeleton. The **temporomandibular joint** or TMJ (or craniomandibular articulation<sup>2</sup>) is the articulation between the *mandible* and the two bones on the base of the skull called the *temporal* bones. This joint is the only visible, free-moving articulation in the head. All other bones of the skull are connected by sutures and are immovable.<sup>3</sup> The TMJ is a bilateral articulation, that is, the right and left sides work as a unit. There are three parts to *each half* of the TMJ: the process of the mandible called the **mandibular condyle** [KON dile], the shallow concavity on

occlusion. People with class III occlusion often exhibit unique traits including anterior teeth that are in an edge-to-edge or in a crossbite relationship where mandibular teeth are facial to maxillary teeth. An edge-to-edge anterior relationship is seen in Figure 9-10B, and an anterior crossbite is seen in Figures 9-9B and 9-14.<sup>D</sup>

It is possible that the classification of occlusion for a person may be described as one class on the right side and a different class on the left side. Class I malocclusions are most common, and class III malocclusions are least common.<sup>E</sup>

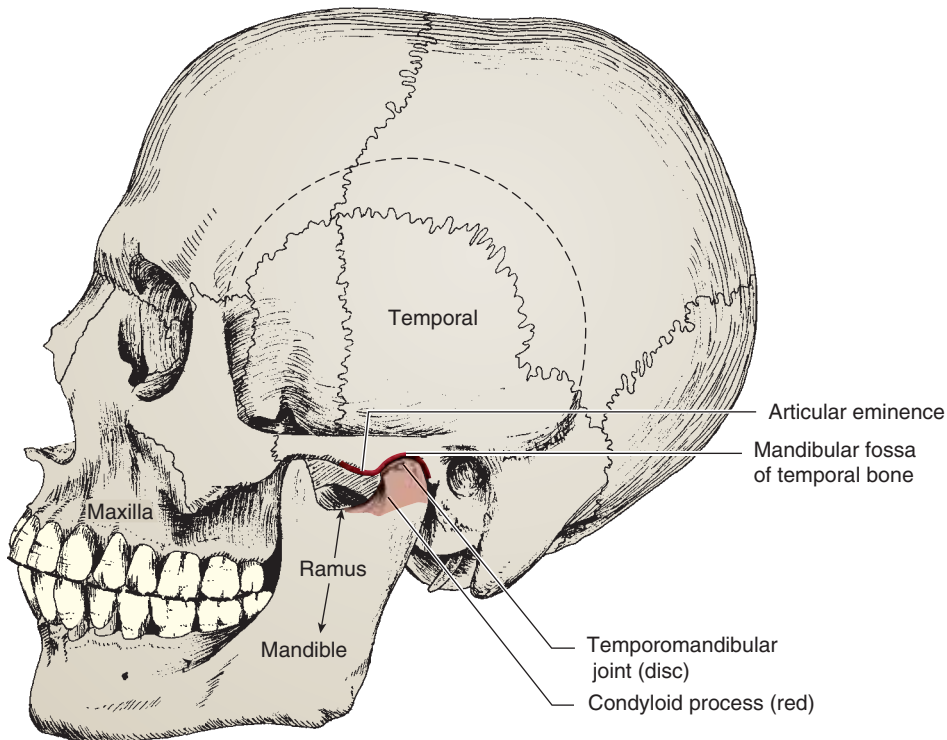
the base of the skull in the temporal bone called the **articular (glenoid) fossa** with its adjacent **articular eminence (ridge)**, and the **articular disc** interposed between these two bony parts (Fig. 9-15). These three parts are enclosed by a **fibrous connective tissue capsule**.<sup>3-5</sup>

#### 1. MANDIBULAR CONDYLE

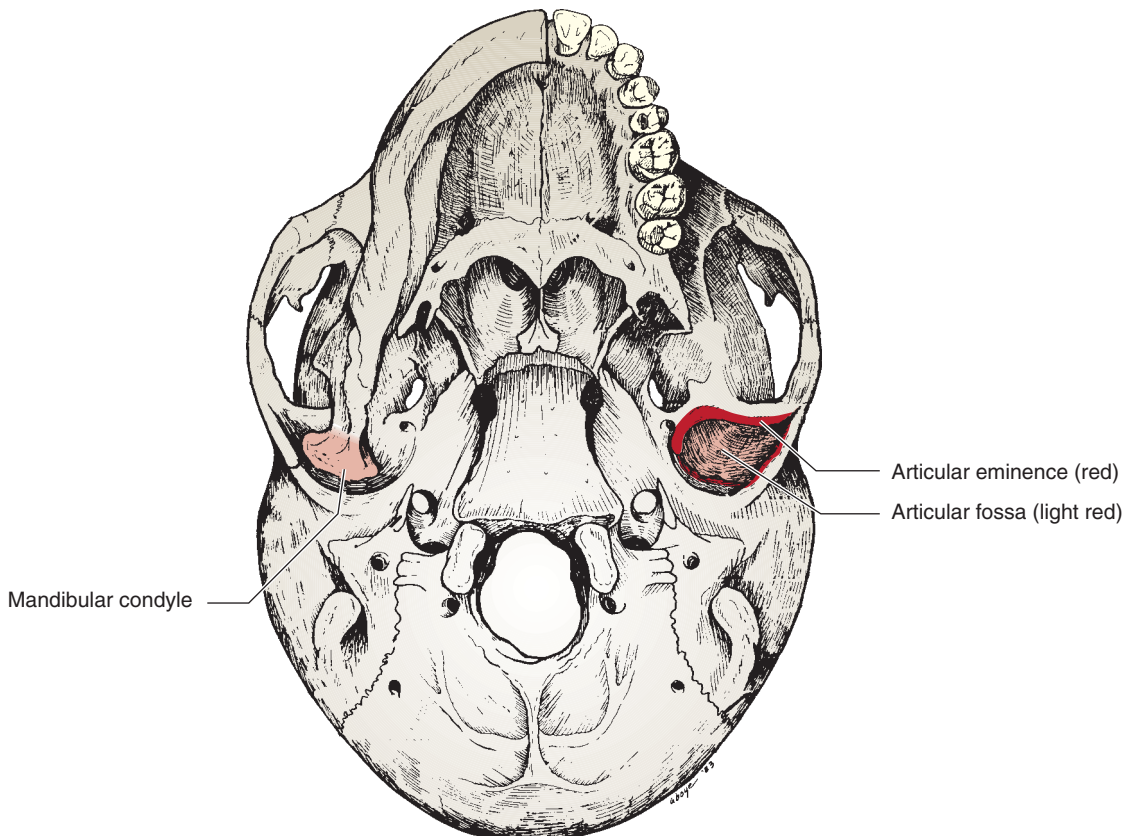
The horizontal portion of the mandible that contains the teeth is called the **body** of the mandible. There are two broad vertical parts on each side of the body called **rami** [RAY my] (singular is **ramus**). The **mandibular condyles** are the most superior processes of the rami and are rounded from front to back and from side to side (Fig. 9-15). The rounded end (**head**) of each condyle fits into a concave fossa on the base of the skull called an **articular fossa** (seen on the skull in Fig. 9-16).

#### 2. ARTICULAR FOSSA AND ARTICULAR EMINENCE

Study the right side of Figure 9-16 where half of the mandible has been removed, exposing the maxillary teeth and the articular fossa and eminence. A transverse bony ridge called the **articular eminence** forms the anterior border of the **articular fossa** (Fig. 9-15). The fossa is considered to be a *nonfunctioning* portion of the joint because, when the teeth are in tight occlusion, there is no forceful contact between the head of the condyle and the concave part of the articular fossa. In the photograph of a sectioned TMJ viewed under magnification in Figure 9-17, the head of a condyle is in the position it would occupy when the teeth come

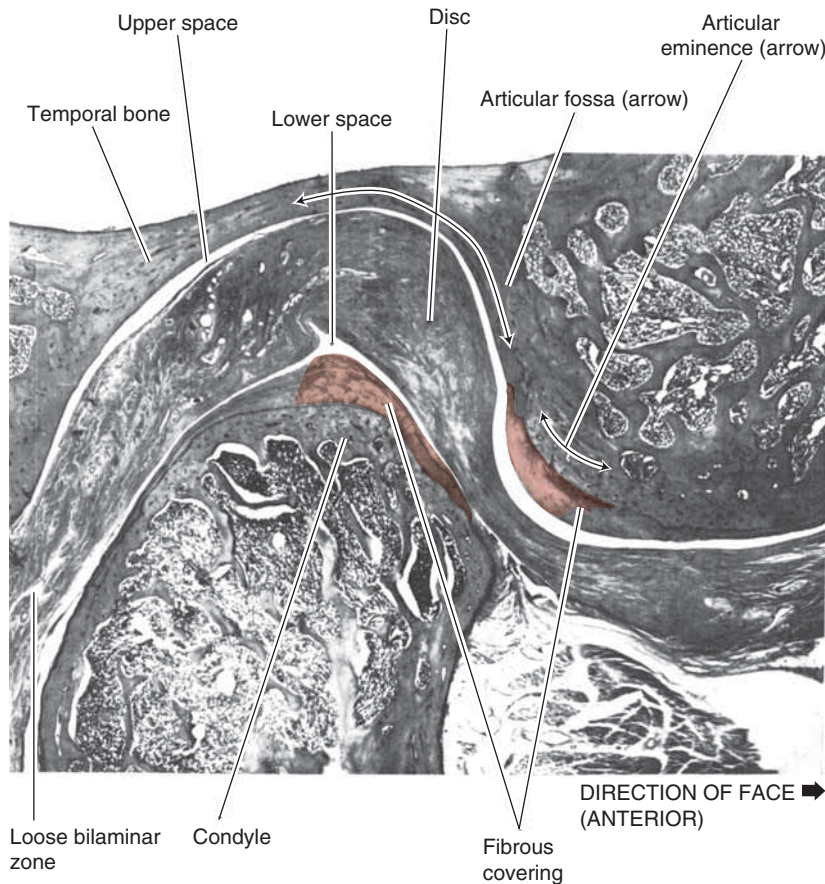


**FIGURE 9-15.** Human skull, left side. This lateral view shows the articulation of the bones of the **TMJ**, namely, the *temporal* bones and the *mandible*. The **head of the condyle** of the mandible is shaded light red, and the red line on the inferior border of a process of the temporal bone clearly outlines the concave **articular fossa** and the convex **articular eminence** just anterior to it. For the mandible to move forward, the condyles move the mandible down under the articular eminence, so the mandible is depressed and the mouth opens.



**FIGURE 9-16.** Human skull: inferior surface with half of the mandible removed on the right side of the drawing. Parts of the mandible and temporal bone that make up the TMJ are highlighted in red. On the *left* side, the **condylar process** of the mandible is shaded red, and on the *right* side with the mandible removed, the **articular fossa** of the temporal bone is shaded light red and the **articular eminence** just anterior to the fossa is red.





**FIGURE 9-17.** TMJ, lateral aspect, close-up photo under the microscope. The anterior of the skull (the face) is toward the right of the picture. The *arrows* indicate the contours of the concave articular fossa and convex articular eminence of the temporal bone. The white area across the top of this photograph is the space of the brain case. Notice the thicker **fibrous covering** (highlighted in red) and underlying compact bone on the functional part of the *posterior inferior articular eminence* and *superior anterior part of the mandibular condyle*. (Courtesy of Professor Rudy Melfi.)

together as tightly and as comfortably as possible. The *functional region* of each condyle and eminence is padded with a thick layer of tough fibrous tissue, an area that has no blood vessels or nerves.<sup>6</sup> This fibrous tissue is particularly thick on the surfaces where function occurs: between the *superior and anterior surfaces* of the condyle and the *posterior surface of the articular eminence*. This contact is only indirect, however, since an articular disc is normally interposed between the two functioning bony elements.

### 3. ARTICULAR DISC

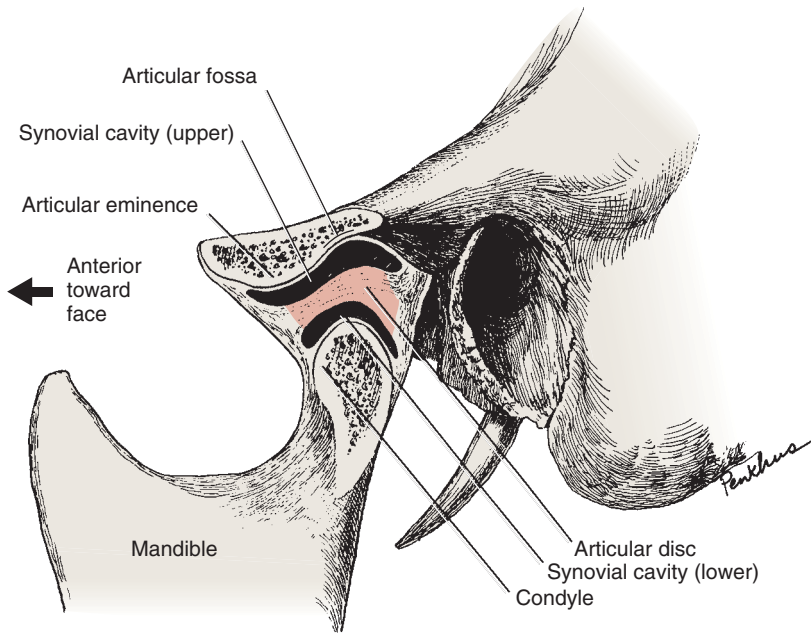
Examine a skull with the posterior teeth fitting together (in tight occlusion) and study how the mandibular condyle fits loosely into the articular fossa. There should be a visible space between the mandibular condyle and the articular fossa that in life was occupied by the **articular disc**. The disc is not present in a prepared dry skull because the disc is not bone. The disc (*Fig. 9-18*) is a tough pad of dense fibrous connective tissue that acts as a shock absorber between the mandibular condyle, and the articular fossa and articular eminence. It stabilizes the condyle by filling the space between the different contours of the condyle, and the articular fossa

and articular eminence.<sup>7</sup> The disc also acts as a cushion between the bones at the point of contact (like a shock absorber).

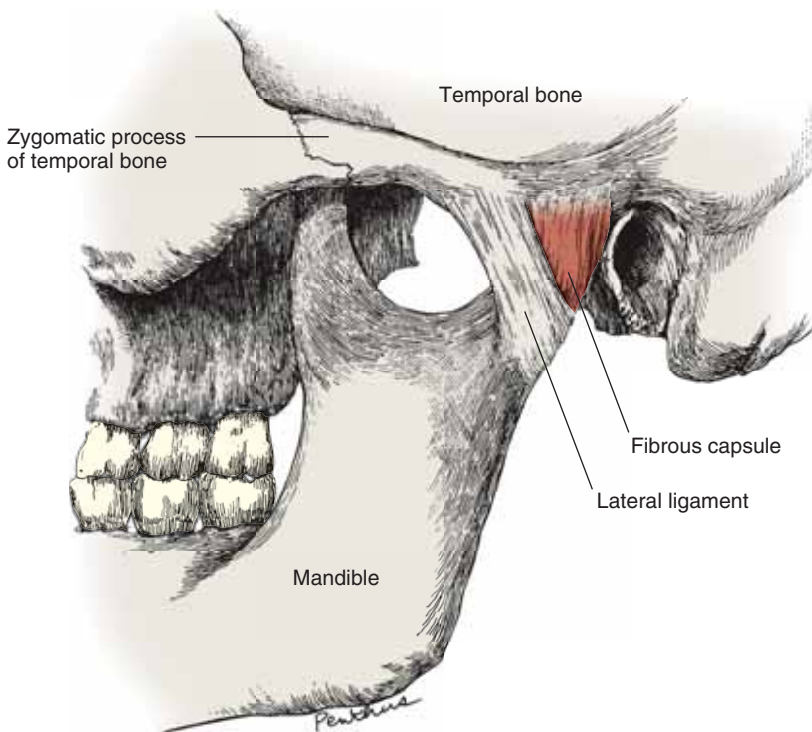
The articular disc divides the space between the head of the condyle and the articular fossa into **upper and lower joint spaces** (upper and lower synovial cavities seen in *Fig. 9-18*), which permit complex functional movements of the mandible.<sup>7</sup> When the mandible moves during function, the right and left discs normally move at the same time because the muscles that pull the jaw forward are attached to the mandibular condyles as well as to the discs. **Proprioceptive** [PRO pri o SEP tiv] **fibers** in the disc help regulate movements of the condyle by unconsciously determining the position of the mandible.

### 4. FIBROUS CAPSULE

A fibrous tube of tissue called the **fibrous capsule** encloses the joint and limits its movement, best seen in *Figure 9-19*. The internal surface of the fibrous capsule is lined with a synovial membrane that secretes very slippery **synovial fluid** that lubricates and nourishes the fibrous covering of the articulating surfaces and center of the disc that lack a blood supply.



**FIGURE 9-18.** TMJ, sagittal section. The anterior surface of the skull (face) is to the left. The sectioned temporal bone (with **articular fossa** and **articular eminence**) forms the *superior* part of the joint, and the sectioned **head of the condyle** forms the *inferior* part. The articular disc in between is shaded red. The upper and lower synovial cavities surround the disc and secrete synovial fluid. (Reproduced by permission from Clemente CD, ed. Gray's anatomy of the human body. 30th ed. Philadelphia: Lea & Febiger, 1985:340.)



**FIGURE 9-19.** Fibrous capsule of the TMJ, lateral aspect (in red), encloses the joint. (Reproduced by permission from Clemente CD, ed. Gray's anatomy of the human body. 30th ed. Philadelphia, PA: Lea & Febiger, 1985:339.)

## B. MOVEMENTS WITHIN THE LOWER JOINT SPACE

Movement between the heads of the condyles of the mandible and the inferior surface of the discs occurs within the lower joint spaces. In the lower joint space, only a **hinge-type** or rotary motion occurs around a hinge axis line. That is, the body of the mandible

rotates around an imaginary horizontal axis line that connects both condyles. This purely rotational (hinge-type) movement of the two condyles around a horizontal axis can be compared to a playground swing with two supporting chains (similar to the supporting rami) that rotates front to back around a supporting pole (the swing's horizontal bar, or the axis line that passes

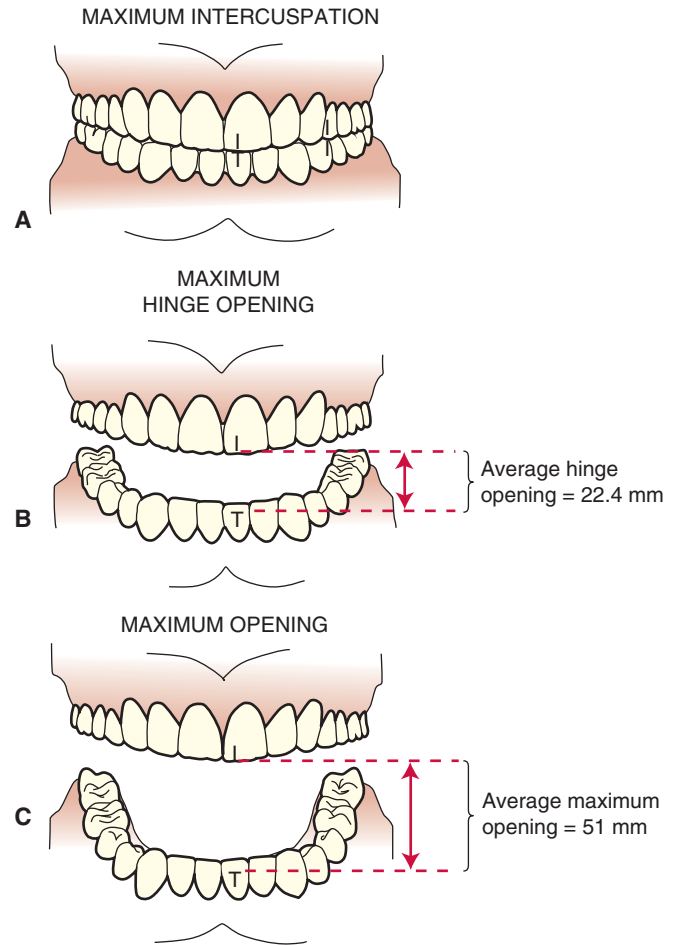


through the right and left mandibular condyles). The seat of the swing, like the body of the mandible, moves quite a bit, whereas the highest chain links (like the heads of the condyles) move little since they are at the axis of rotation. This purely rotational movement is possible only when opening the mandible up to about half way.<sup>6</sup> Further, the rotation of the mandible around this hinge axis is possible only when the mandible is *not being pulled forward*.

### C. MOVEMENTS WITHIN THE UPPER JOINT SPACE

Movement between the superior surfaces of the discs and the articular fossa (and eminence) occurs within the upper joint spaces. When you open and close the mouth beyond about half way (i.e., beyond the limit of the purely hinge-like movement), the mandibular *condyles and discs together* translate or glide forward (when opening) and backward (when closing). **Translation** is the bodily movement of the entire mandible (and discs) downward and forward onto the articular eminences. During translation, the horizontal axis between the condyles actually moves forward as the condyles and discs slide from the articular fossae over the adjacent eminences. Think of this translatory movement as taking the entire playground swing set with its horizontal bar (rotational axis) in the previous example and moving it forward, which moves the swing (condyles and body of the mandible) bodily forward. If the swing is still swinging, a hinge movement is now combined with translation, similar to most movements within the jaw.

When the condyles and discs do not move forward simultaneously, the result may be crepitation. **Crepitation** (crepitus) is the crackling or snapping sound or noise emitted from the TMJ because of a disharmonious movement of the mandibular condyles against the articular discs, sometimes erroneously thought to be caused by the rubbing together of the dry synovial surfaces of joints. When the crackling noise is heard, the articular disc may be snapping in or out of position or it may become locked in the wrong position.<sup>1,8-12,H</sup> Crepitation is not a rare occurrence and does not normally require treatment unless it is accompanied by pain, limited jaw opening, or **trismus** [TRIZ mus] (i.e., a spasm of chewing muscles associated with difficulty opening or locking of the jaw).<sup>10,13</sup> The noise may disappear with time, or it may persist for many years being no more than a noisy annoyance. With practice, if a person who has crepitus on one or both sides can learn to open the jaw like a hinge without protruding it forward, the condyles will be able to rotate beneath the discs and the noise will stop.



**FIGURE 9-20.** Range of opening for hinge and translation movements. **A.** Maximal intercuspal position. **B.** Maximum opening for **hinge** movement. **C.** Maximum normal **total opening**. Note: Movement from position **B** to **C** would include both hinge and translatory movement.

Both translatory and rotational opening movement occur when a person continues opening movement beyond about halfway, beginning when the jaw exceeds the maximum hinge opening limit, and continuing until the jaw is opened all of the way (Fig. 9-20).

### LEARNING EXERCISE

Place your fingers in front of your ears and open and close your jaw to palpate the lateral heads of the mandibular condyles. When you open widely (as in yawning), you will now be rotating *and* translating your mandible. You may feel a bump, or hear a click or popping sound, or hear a grating noise (called crepitation) as the condyles move (translate) forward and slide down onto the

**Learning Exercise, cont.**

articular eminences. These sounds could be a sign of dysfunction within the joint such as a disc that does not follow the movements of the condyle. How far are you able to open in the incisor region before you feel the condyles begin to slide forward (translation in the upper part of the joints)?

**D. TOTAL JOINT MOVEMENT**

Normal day-to-day **functional mandibular movement** required for eating, swallowing, yawning, and talking involves hinge-like rotation *simultaneously with* some translation of the mandible that occurs in both the upper and lower spaces of the TMJ. The combined hinge and translatory motion follows a curved path primarily dictated by the movement of the condyle against the posterior and inferior surface of the articular eminence because no conscious effort is being made to open in a retruded manner.<sup>14,15</sup>

Poor occlusal relationships of any type can contribute to a variety of joint problems.<sup>1,9–11,16,17,1</sup>

**E. DISLOCATION OF THE MANDIBLE**

When widely opening the mandible, the disc and head of the condyle may move forward so far that they slip

out of the articular fossa and move forward beyond the articular eminence. Thus, the mandible will be partially dislocated (**luxation** or **condylar subluxation**). This dislocation occurs in the upper joint compartment where translation occurs. The mandibular condyle can also come off of the disc, causing the jaw to lock open. If the closing muscles suddenly contract, the mandible could become painfully *locked open*. A person's jaw-opening muscles are not nearly as powerful as the closing muscles, and therefore, we may not be able to unlock a mandibular dislocation in our own mouth without help. (Perhaps you have seen an alligator trainer hold the alligator's jaws closed with only one hand since their opening muscles are so weak.)

A subluxed position may be released when another person depresses the mandible with heavy force *downward and backward* to slip the mandibular condyles and discs under the articular eminences and back into the articular fossae. In order to avoid having the person bite down on the fingers of the rescuer as the muscles are released from their state of contraction, the rescuer's thumbs should be placed *not* on the mandibular teeth but bilaterally on the bony shelf (buccal shelf) of the mandible just lateral to the molars. The disc is loosely attached to the condyle and normally travels with it. There could be a lot of pain until the contracted muscles relax after the mandible is depressed and repositioned by the thumbs of the rescuer.

**SECTION III****TERMS USED TO DESCRIBE JAW RELATIONSHIPS BETWEEN THE MANDIBLE AND THE MAXILLAE**

**Jaw relation** (or the maxillomandibular relationship) refers to the position of the mandible relative to the maxillae and can be described as a tooth-to-tooth relationship between maxillary and mandibular teeth, or as a bone-to-bone relationship between the maxillae and mandible. Several terms describing different tooth and jaw relations are discussed in this section.

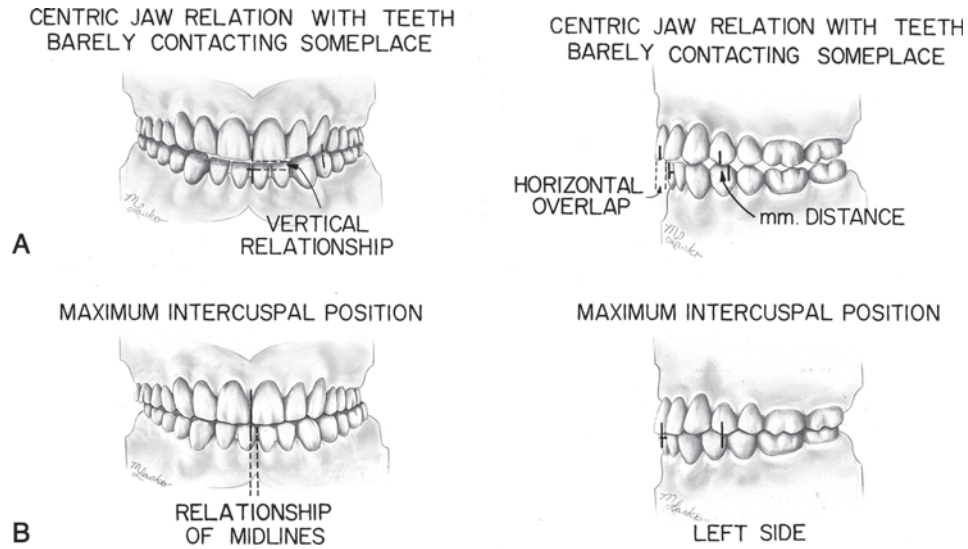
**A. MAXIMAL INTERCUSPAL POSITION**

**Maximum intercuspal position (MIP)** is a tooth-to-tooth relationship that is not dependent on where the jaw muscles or joint anatomy would like to position the mandible. It is the tightest or best fit between maxillary and mandibular posterior teeth and can be demonstrated on handheld casts of the upper and lower arches without looking into the mouth (*Figs. 9-21B and 9-22B*). This can also be called **maximal intercuspation**.

**B. CENTRIC RELATION**

**Centric relation (CR)** or **centric jaw relation** is an important reproducible and repeatable relationship of the mandible to the maxillae because it is the relationship people return to each time they chew and swallow, and it is the relationship that dentists use when they mount diagnostic casts of the mouth prior to major restorative procedures. This jaw relationship is not affected by the presence (or absence) of teeth, so it does not change due to tooth malocclusion. It includes the *range of positions* of the mandible during a hinge-like opening and closing *without moving bodily forward* and without teeth touching, or up until the first two teeth *initially* just touch but do not yet begin to close more tightly into MIP.<sup>18–20,J</sup>

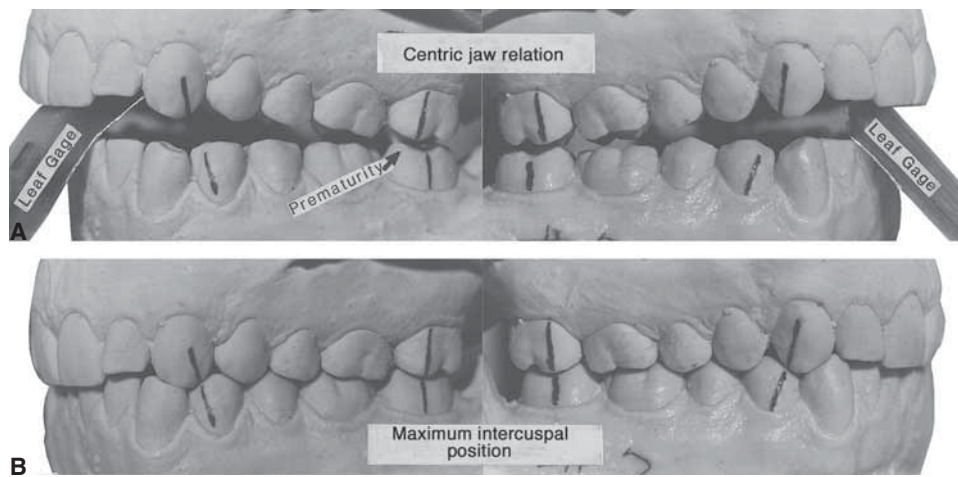
It is a relatively rare but ideal occurrence when CR coincides with the MIP. This occurs when the mandible



**FIGURE 9-21.** Maximum intercuspal position (MIP) compared to centric jaw relation. **A.** Mandible has closed in the **centric jaw relation** until the *first tooth contact* between any upper and lower teeth (indicating a **prematurity or deflective contact**). **B.** The mandible has continued to close from the first tooth contact into **MIP**, and as a result of the prematurities, the mandible has *deviated* (deflected) forward (as seen in the shift of the relationship of the vertical lines placed on the maxillary and mandibular first premolars) and laterally to the left (as seen in the shift of the alignment of the midlines of the maxillary and mandibular dentition).

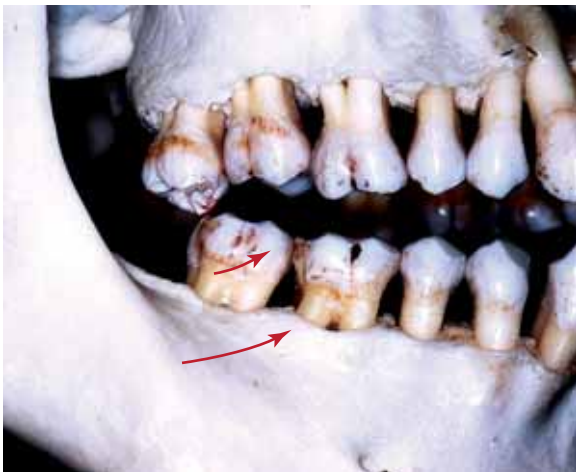closes in its CR position and there is *simultaneous* even contact of teeth in maximal intercuspation when the teeth first touch.<sup>8,19–22</sup> This type of ideal occlusal relationship results in a harmony between the guidance afforded by jaw muscles, the position of condyles against the discs and fossae, and the maximum fitting together of the teeth. This condition does not occur in

most people unless they have just had a well-executed occlusal reshaping (equilibration) where small amounts of interfering occlusal enamel were removed by the dentist to equalize occlusal stress,<sup>22</sup> have a well-made removable denture, or have had a complete dental arch rehabilitation replacing or reorienting all occlusal surfaces (described later in this chapter).



**FIGURE 9-22.** MIP compared to centric jaw relation on a patient with severe deflective tooth contacts. **A.** Patient’s casts (left side and right side) mounted in **centric jaw relation**. An articulator mounting of these casts in centric jaw relation using a leaf gauge revealed the severe deflective left second molar contact that was impossible to correct by an equilibration. This person’s mandible deflected forward 2 mm and to the right 1 mm as the teeth closed into MIP. **B.** Same patient’s casts (left side and right side) mounted in **MIP**.

When centric jaw relation does not coincide with the MIP, a **prematurity** or **deflective occlusal contact** exists. Most people have deflective malocclusion to some degree. Premature or deflective occlusal contacts refer to the teeth that are the *first* to contact as the mandible closes into its most retruded position in CR. Deflective occlusal contacts guide or direct the mandible away from where healthy muscles and joint anatomy would comfortably guide the mandible if there were no teeth. **Mandibular deviation** refers to the direction and movement of the mandible from the first slight premature tooth contact with the jaw in CR until the teeth reach their MIP. The direction of the deviation of the mandible is usually forward (about 1 to 2 mm) and upward, with or without simultaneous lateral movement.<sup>18,20,21,24,25</sup> This is illustrated in Figure 9-21 where premature contacts deflect the mandible forward and to the left as the teeth move from CR into MIP (from A to B), and in Figure 9-22, where the mandible is deflected forward 2 mm (from A to B). In Figure 9-22, compare the short vertical pencil lines on two pairs of opposing maxillary and mandibular teeth that line up when the teeth are in their MIP but reveal how distally the mandible is positioned when in centric jaw relation. A prematurity is most obvious on the skull in Figure 9-23 where the supraerupted maxillary third molar occludes before any other teeth when the mandible closes in its CR. This deflective occlusal contact forces the mandible to move considerably forward and superiorly in order to reach MIP.



**FIGURE 9-23.** Centric prematurity: initial contact of a supraerupted maxillary third molar. When the mandible is positioned as it closes in centric relation, the first tooth to contact in this dentition is the third molar. The mandible must then shift forward and upward (*arrows*) in order for all teeth to come together in the MIP.

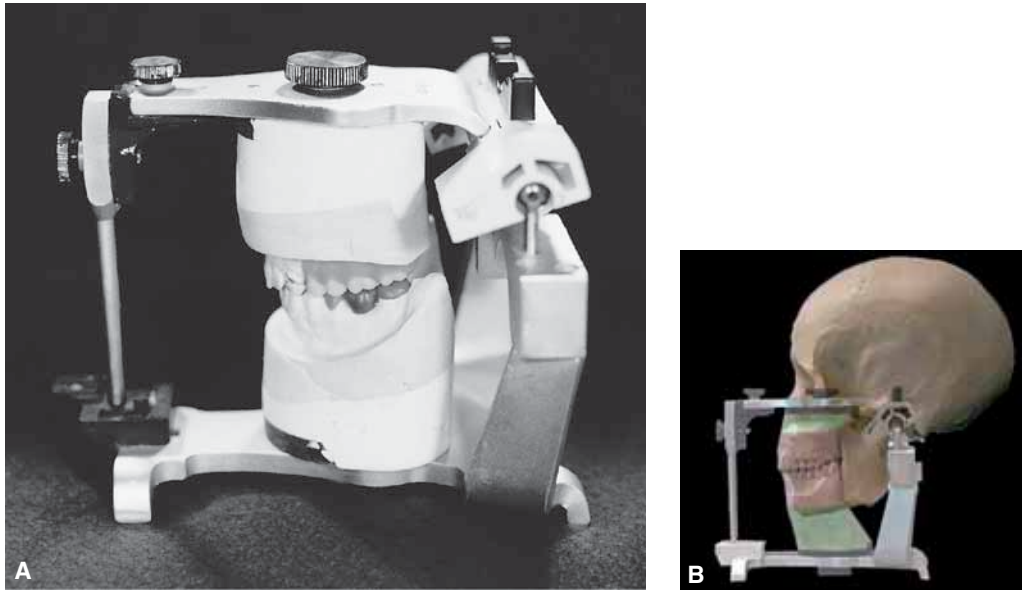
Edentulous people (with no teeth) who wear complete dentures or false teeth are provided with CR that coincides with MIP because they can learn to pull the mandible back and close into a *stable and repeatable position* of CR during jaw closure. This enables the tight occlusion of denture teeth to coincide with the repeatable centric jaw position, so the dentures will remain tightly secured against the mucosa and not rock loose when functioning.

An **articulator** is a mechanical device that holds casts of the two arches, permitting a close duplication of the patient's opening and closing centric jaw relations (Fig. 9-24). Notice the fit of the ball of the lower (mandibular) part fitting into a concavity on the upper (maxillary) part. This design simulates the heads of the condyles fitting into their articular fossae. It is easier to study tooth relationships with the patient's dental arches (dental stone casts) on the articulator in your hands, rather than with your hands in the patient's mouth. What better way is there to determine whether or not the maxillary and mandibular lingual cusps fit together tightly or properly in the maximal intercuspal relationship?

### LEARNING EXERCISE

Open your mouth so that your teeth are *slightly* apart, and close very slowly in a hinge motion *without sliding the jaw forward* until the first teeth initially touch gently. The relationship of your jaws prior to your first gentle tooth contacts is your centric jaw relation. The relation of this pure hinge opening is a most important one to record when making extensive dental restorations for a patient. If your mandible is deflected (hits and slides) forward as you continue to close your teeth together into their MIP where they fit together most tightly, you are experiencing deflective or premature occlusal contacts, and you are among the majority of people whose CR does not coincide with the MIP. The mandible will almost always slide forward from CR into MIP, either straight forward or to one side. More than likely, your own deflective tooth contacts will not be as severe as that shown in Figure 9-22. Can you determine in which direction your premature tooth contacts deflect your mandible? Compare the location of your first (premature) tooth contact in CR with those in Table 9-1. Less than 1% of this group had MIP coincide with CR, yet most were asymptomatic.





**FIGURE 9-24.** Casts mounted on an articulator. **A.** This articulator (Denar, Anaheim, CA) can be used to mount casts of the patient's dentition in order to reproduce the position and movements of mandibular teeth relative to maxillary teeth. This mounting was used to design the tooth anatomy and occlusion for a fixed dental prosthesis (bridge) from tooth 18 to 20 (replacing tooth 19) and a removable partial dental prosthesis replacing teeth 12 through 15. (Mounting courtesy of Dr. Lisa Knobloch, Ohio State University.) **B.** Skull superimposed over an articulator to show how tooth models mounted on an articulator can reproduce the movements of the teeth relative to the TMJ. (Photo compiled by Dr. Julie Holloway, Ohio State University.)

### C. PHYSIOLOGIC REST POSITION

Occlusal vertical dimension refers to the distance between a selected point on the mandible and a selected point on the maxillae. This dimension can be measured with the jaws positioned in CR or in MIP.

The physiologic rest position (or vertical dimension of rest position) is the position of the mandible when all of its supporting muscles are in their resting posture.<sup>26</sup> Physiologic rest position is further defined as the mandibular position when the person's head is

**Table 9-1** DEFLECTIVE CENTRIC RELATION TOOTH CONTACT DATA FROM 811 DENTAL HYGIENISTS

LOCATION OF FIRST CENTRIC RELATION TOOTH CONTACT	NUMBER OF HYGIENISTS	PERCENT
Premolars one side	232	28.6
Premolars both sides	90	11.1
Molars one side	328	40.5
Molars both sides	113	13.9
Molar one side; premolar one side	38	4.7
Canine	4	0.5
MIP = centric jaw relation (no prematurity)	6*	0.7
TYPE AND PLACE OF DEFLECTIVE CONTACT	PERCENT	
Premolars only	39.7	
Molars only	54.4	
Unilateral prematurity	69.2	
Bilateral prematurity: same tooth	25.8	
Bilateral prematurity; premolar-molar	4.7	

\*Three of the six recently had an equilibration by their dentists.  
Research conducted by Dr. Woelfel at the Ohio State University, 1974–1986.



upright, the muscles of mandibular movement are in equilibrium, and the condyles are in an unstrained position. Unless we are nervous, eating, talking, yawning, or using our muscles to perform other less natural functions (such as playing a clarinet), the mandible is in this comfortable resting position most of the time (over 23 hours each day). When a person with an erect posture is totally relaxed and makes no conscious effort to open or close the mouth so that the mandible is in its physiologic rest position, there is a space between the occlusal surfaces of the maxillary and mandibular teeth called the **interocclusal rest space** (or freeway space). This space is normally 2 to 4 mm between the maxillary and mandibular teeth. Of course, when the teeth are missing (in an edentulous person), there would be a much larger distance between the residual toothless ridges when the mandible is resting.<sup>27</sup>

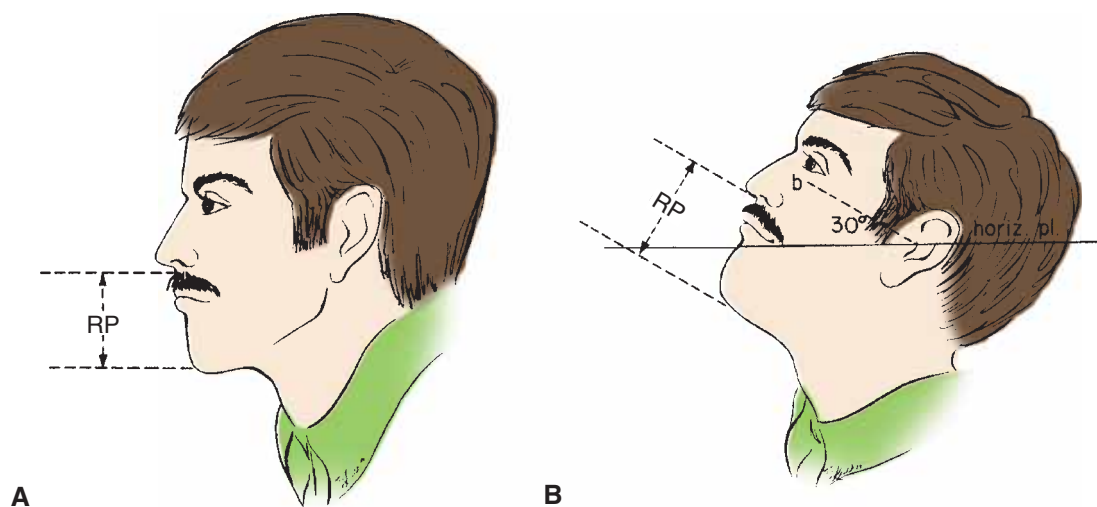
A simple change in posture, such as looking up at the sky or stretching the neck back in the reclined dental chair, will change the resting position of the jaw, pulling the mandible back and separating the teeth farther than when in a comfortable upright position (Fig. 9-25). This change is due to the pull on the mandible by stretching skin and underlying tissue (fascia). Therefore, when a dentist places a restoration (filling) for a patient who is reclined in the dental chair, a final assessment and possible adjustment of the occlusion on this new restoration should take place with the patient in a *relaxed upright position*.

## D. JAW RELATIONSHIPS DURING HORIZONTAL MOVEMENTS OF THE MANDIBLE

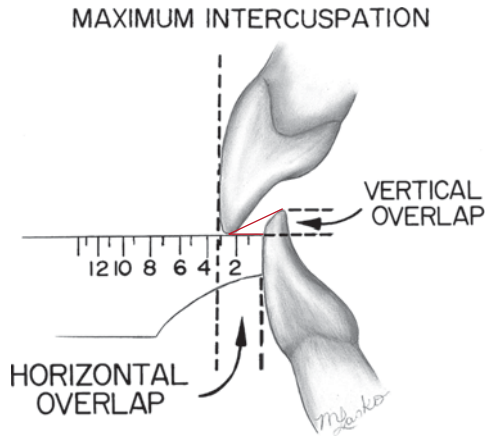
Relationships between the mandible and the maxillae can be defined and documented as the mandible moves horizontally out of its centric relationship into other positions. **Eccentric jaw relationships** are any deviation of the mandible from the CR position. These relationships occur when the lower jaw moves anteriorly (protrusion), laterally (mandibular lateral translation or excursion), or a combination of both.

### 1. PROTRUSIVE JAW RELATION AND OCCLUSION

**Protrusive movement** occurs when the mandible moves anteriorly (as when incising food between the anterior teeth). Both mandibular condyles and discs move forward together in their articular fossa, functioning against and beneath the articular eminences whose sloping morphology guides the mandible *downward* as it moves forward. As protrusion occurs, the movement of the mandible is also influenced by the amount of overlap of the anterior teeth. When teeth are positioned in MIP, upper incisors and canines overlap lower incisors and canines (Fig. 9-26). As stated earlier in this chapter, this overlap can be described in terms of a *horizontal* overlap where maxillary incisal edges are labial to the mandibular incisal edges and a *vertical* overlap



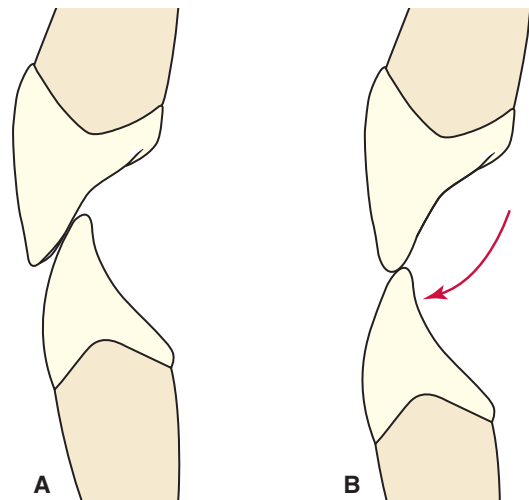
**FIGURE 9-25.** Physiologic rest position: effects of posture. **A.** This man assumes a normal posture with his mandible in physiologic rest position (RP). Posterior teeth, though not visible, are not occluding. **B.** Now the man is looking up and his mandible is again in physiologic RP with his posterior teeth separated but more so than in A because of the stretch of fascia, skin, and muscles. The resting position of the mandible varies with factors such as body posture, fatigue, and stress.



**FIGURE 9-26.** Incisor and canine relationship and guidance.

Lateral view of maxillary and mandibular incisors shows the normal vertical and horizontal overlap of incisors when the posterior teeth are in maximum intercuspation. The incisal guidance angle is the angle formed between the occlusal plane (horizontal numbered line on illustration) and a line connecting the upper and lower incisal edges. It is only 37° in this illustration, which is less steep than in many dentitions. A canine guidance (rise) angle of 60° or more is necessary to provide canine-protected articulation (or canine guidance).

where maxillary incisal edges overlap (and facially hide from view) part of the mandibular incisor crowns. (See Table 9-2 for the average amount of overlap and range of variations on 1114 dental and dental hygiene students.) When a person with normal horizontal and vertical overlap of the incisors moves the mandible forward, the incisal edges of the mandibular anterior teeth glide against the lingual surfaces of the maxillary anterior teeth, also guiding the mandible *downward* when protruding (Fig. 9-27). This is known as **incisal guidance**, which is a type of **anterior guidance**, or **anterior protected articulation**. It is influenced by the angle at which the lower incisors and mandible must move



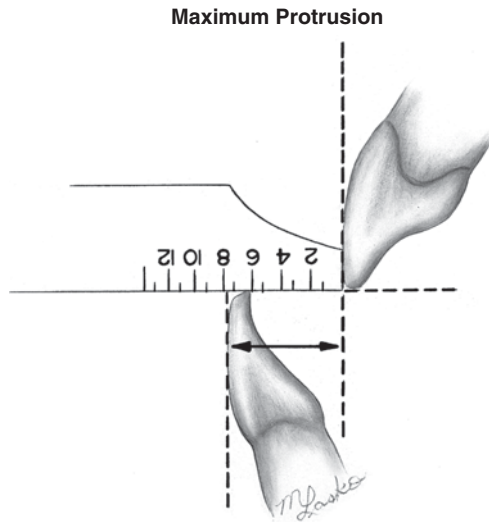
**FIGURE 9-27.** Movement of incisors during protrusive movement. Notice how the normal overlap (in A) causes the incisors to direct the mandible downward as it moves forward (the red arrow in B), a movement that normally separates posterior teeth. This is called **anterior guidance** or **anterior protected articulation**.

downward and forward from the MIP to reach the edge-to-edge incisor relationship. Anterior guidance is a *desirable* relationship since, when the mandible protrudes or moves to either side a small distance as in chewing, the incisor overlap causes the mandible to move downward resulting in the separation (**disocclusion**) of the posterior teeth.<sup>23,28,K</sup> In other words, the posterior teeth only occlude in CR but not during protrusion. When the mandible is fully **protruded**, the incisal edges of the mandibular incisors move in front of the maxillary anterior teeth (Fig. 9-28).<sup>L</sup> When the mandible moves posteriorly toward its maximum intercuspal position, jaw movement is known as **retrusion** (retraction).

**Table 9-2** INCISOR AND CANINE OVERLAP OF 1114 STUDENTS

		INCISOR OVERLAP		CANINE HORIZONTAL OVERLAP		CANINE VERTICAL OVERLAP	
		Horizontal (mm)	Vertical (mm)	Right (mm)	Left (mm)	Right (mm)	Left (mm)
DENTAL HYGIENE STUDENTS (796)	Average	2.78	3.27	2.01	2.02	3.23	3.19
	Low	-2.5	-1.0	-1.0	-1.0	-1.0	-1.0
	High	9.0	13.0	6.2	6.2	11.0	9.0
DENTAL STUDENTS (318)	Average	2.88	3.60	4.05	4.25	—	—
	Low	-6.5	-2.0	0.0	0.0	—	—
	High	10.0	8.0	8.5	9.0	—	—

Research conducted by Dr. Woelfel at the Ohio State University, 1974–1986.



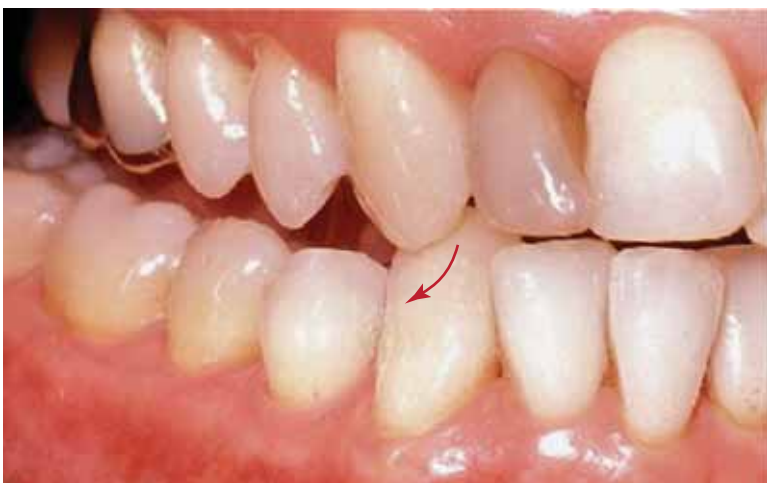**FIGURE 9-28.** Maximum protrusive jaw relationship. This is the relationship of mandibular to maxillary central incisors when the mandible is maximally protruded. The mandible has protruded 11 mm because the mandibular central incisor was 3 mm lingual to the maxillary incisor in centric occlusion.

## 2. LATERAL MANDIBULAR RELATION AND OCCLUSION

During mandibular lateral translation, the mandible moves to the right or left side and slightly downward as when chewing food. When the mandible moves to one side, both condyles do not move equally toward that side. Rather, when the mandible moves to the right side, the right condyle rotates but remains relatively stationary, while the left condyle and disc move forward, downward, and medially within the articular fossa. During maximum jaw movement, the mandible can move almost twice as far from side to side as it can directly forward.<sup>M</sup>

When the mandible moves laterally, the **working side** is the side toward which the mandible moves during lateral excursion (seen in Fig. 9-29), and it is also the side where chewing (or work) occurs. The opposite side is called the **nonworking side**. These terms are *dependent upon which way the mandible is moved*. For example, when the mandible moves to the right, the right side is the working side and the left is the nonworking, whereas when the mandible moves to the left, the left side is the working side and the right is the nonworking side. The working side is the side where the “work” of chewing occurs. As a person with an ideal occlusal relationship moves the mandible laterally, the ridges of mandibular teeth on the *working side* move over the opposing maxillary ridges until maxillary buccal cusps line up over mandibular buccal cusps, and maxillary lingual cusps line up over mandibular lingual cusps (seen in Fig. 9-29). The condyle on the working side does not move much; it rotates on its vertical axis and moves laterally only about 1 to 2 mm (called laterotrusion or Bennett’s movement). When the *working side* cusps are lined up end to end, the maxillary *lingual* cusps of the *nonworking side* are aligned over the mandibular *buccal* cusps.

**Canine-protected articulation** is the *desirable* occlusal relationship in which the vertical overlap of the maxillary and mandibular canines produces a disocclusion (separation) of all of the posterior teeth when the mandible moves to either side. **Disocclusion** refers to the separation of opposing posterior teeth during eccentric movements of the mandible.<sup>23,28</sup> That is, when the person moves the mandible to the right (working) side, there are *no* posterior tooth contacts evident on the *working side* (Fig. 9-29) and, although you cannot see this in the figure, there are *no nonworking* posterior tooth contacts due to the steep canine guidance on the right (working) side. **Nonworking side**



**FIGURE 9-29.** Canine-protected articulation.

When the mandible moves to the patient’s right side (in the direction of the red arrow), the overlap of canines results in the separation (disocclusion) of his posterior teeth on the right side. This is the patient’s **working side** since the mandibular buccal cusps are lining up directly under the maxillary buccal cusps (as during chewing or working).

**interferences** refer to the tooth contacts on the non-working side, which are considered undesirable.<sup>N</sup> If the nonworking side interferences are heavy and frequent, they may actually be destructive to the supportive structures of the involved teeth and can possibly cause TMJ pain on the opposite side because of the pivoting of the mandible and the stretching of opposite side ligaments and muscles. Many dentists consider canine-protected occlusion to be a desirable or healthy relationship to have. One study of 500 persons indicated that there was a lesser tendency toward bruxism (grinding the teeth together) with canine-protected occlusion.<sup>29</sup> Another study found posterior tooth mobility to be higher in dentitions with canine protection than those with group function.<sup>30</sup> When canine-protected articulation is not present, it may be achieved through orthodontic treatment or by adding length or lingual thickness to the maxillary canines (by placing restorations).

**Group function** (or unilateral balanced occlusion) is an occlusal relationship in which multiple teeth on a working side contact evenly as the jaw is moved toward that side.<sup>O</sup>

The occlusion between an upper and lower complete denture false teeth is different from natural teeth.<sup>P</sup>

### LEARNING EXERCISE

Place a finger just in front of your ears or in your ear openings while you move the mandible to the right side. Do you feel more movement of the condyle on the right side or on the left side? How do you account for this difference? Repeat while moving the jaw to the left side. (See Ref. 31 for interesting information on this subject.)

## SECTION IV

### FUNCTIONAL MOVEMENTS WHEN EATING: CHEWING AND SWALLOWING

**Functional movements** are the normal movements of the mandible during speech, chewing, yawning, and swallowing. **Functional occlusion** refers to the tooth contacts that occur only during chewing and swallowing. You may think that your teeth need to touch when speaking, but go through the alphabet to see if teeth need to touch for any sound. You will find that, for most persons, teeth do not actually touch, although they must come close during sounds like “sss.” since if the incisors are moved very far apart, the result is more of an “sh” or whistling sound.

Eating involves the intake of food by placing it in the mouth, **incising** (bringing incisors together) to bite off a manageable size piece of food, **chewing** (also called **mastication** [mas ti KA shun]), and **swallowing** (also called **deglutition** [deg loo TISH un]). The following descriptions of incising, chewing, and swallowing apply to persons with ideal class I occlusion eating a piece of chicken.

#### A. INCISING

**Incising** is the articulation of the anterior teeth performed to cut food into chewable pieces. Eating begins as the mandible drops downward to open the mouth, and the mandible is protruded as food is placed between the opposing anterior teeth. The mandible then closes in this protrusive position until the incisal edges of

the anterior teeth meet the food. The mandible is then moved up and posteriorly with the mandibular incisors against lingual surfaces of the maxillary incisors, thus cutting off a small portion of the food.

#### B. MASTICATION (CHEWING)

Next, the tongue transfers food to the posterior teeth; it is held in position on the teeth of the working side by the cheek muscles and the action of the tongue. The teeth are brought together, engaging the food with the mandible in a slightly lateral position toward the working side. The upper buccal cusps are directly over the lower buccal cusps with the mandible in this lateral position. The closing motion slows as the mandible is forcibly closed<sup>32</sup> while the canine overlap and inclines of posterior tooth cusps guide the mandible into maximal intercuspation of the posterior teeth for chewing. Tooth cusp slopes and triangular ridges act as cutting blades, whereas major and supplemental grooves serve as escape pathways (spillways or sluiceways) for crushed food to squeeze out through the buccal and lingual embrasures and over the tooth curvatures toward the cheek and onto the tongue. There, it can be tasted, mixed with saliva, placed back over the teeth, and chewed some more. This process significantly reduces lateral forces applied to the teeth that could be damaging to the teeth and their supporting bone. After the



posterior teeth contact in MIP, there is a slight pause<sup>Q</sup> before the mandible opens and moves laterally to commence the next chewing cycle. We usually chew like this on one side for several cycles and then switch the food over to the opposite side where a similar chewing cycle occurs. This process is called **mastication**.

### LEARNING EXERCISE

Look in a mirror and move your jaw as far as possible in all directions (wide open, and from right to left) to discover exactly how wide and long your total range of motion is. Then chew some sugarless gum and notice that you use perhaps only half of this overall range of motion. Observe the pattern of movement of your mandible from the facial view during chewing to see if you move your mandible in a tear drop or circle shape similar to the pattern of chewing. Your side or sagittal view could also be viewed using a second mirror placed at 45°.

## C. SWALLOWING (DEGLUTITION)

Swallowing begins as a voluntary muscular act (when we decide to) but is completed involuntarily by reflex action. The mechanics are as follows:

- The anterior part of the mouth is sealed (lips closed).
- The teeth are closed into their MIP.
- The soft tissue in the back of the roof of the mouth (soft palate) is raised, so food cannot enter the nasal passageway.
- The bone above the voice box (**hyoid bone**) is raised as we close off the trachea (windpipe). This prevents food from passing into the lungs.
- The posterior part of the tongue is engaged in a piston-like thrust causing the small mass of chewed

food (bolus) to be pushed into the throat (oral **pharynx** [FAR inks]).

- The act of swallowing, also known as **deglutition**, takes place.
- Once the bolus is in the pharynx, the superior portion of the posterior wall presses forward to seal the pharynx, and then the esophageal phase of swallowing commences. This is accomplished by involuntary **peristalsis** (waves of contraction), which moves the food bolus through the entire length of the digestive tract.
- Then the mandible usually drops open, assuming its physiologic resting posture where relaxed muscles permit a slight space between upper and lower teeth. Several swallows are necessary to empty the mouth of a given food mass. However, even without food or drink, we swallow saliva a number of times every hour without thinking about it.

### LEARNING EXERCISE

Bite off a piece of firm food and analyze your jaw movements by looking in a mirror as you prepare the food for swallowing. This process is called mastication followed by deglutition (swallowing). Observe and feel the hyoid bone above the voice box move as you swallow. During swallowing, feel the bulge of the muscles located inferior to the mandible (near the midline) but superior to the hyoid bone. Also notice how difficult it is to swallow with your lips and teeth apart. Dental professionals must remember this fact as they keep patients' mouths open for extended periods of time without providing an opportunity for them to close their teeth together and swallow!

## SECTION V

### PARAFUNCTIONAL MOVEMENTS AND HEAVY TOOTH CONTACTS: SIGNS AND SYMPTOMS

**Functional tooth contacts** occur during the normal day-to-day processes of mastication and deglutition. Some forces between teeth are actually necessary for maintaining a healthy periodontium. **Parafunctional contacts**, on the other hand, are those tooth contacts that occur outside of these normal functions, like when teeth contact a hard object, or soft tissue, or other teeth. For example,

tooth-to-hard object contacts occur when smoking a pipe if the smoker chews on the pipe stem, or when playing a reed instrument such as a clarinet, or when chewing on a pencil. Tooth-to-soft tissue contacts occur during cheek biting or lip biting that can be confirmed during an oral examination as raw or thickened mucosa of the cheek or lip. Parafunctional tooth-to-tooth contacts

occur when **clenching** (squeezing the teeth together without jaw movement), **bruxing** (grinding the teeth back and forth during movements other than chewing), or playing a violin (where tooth contacts occur when supporting the instrument with the chin). Bruxing can be particularly damaging to teeth and to the TMJ.

Tooth contacts during parafunctional movements may be nothing more than an annoyance, but if these contacts involve *considerable force and frequency* beyond which the tooth and muscles are able to withstand, they can be potentially damaging to teeth, to tooth supportive structures, and to the TMJ. When a person develops a bruxing habit, these heavy and potentially damaging tooth contacts may be exercised almost constantly under stressful situations. In a healthy person without occlusal problems, functional tooth contacts including eating three meals will total only 7 to 8 minutes over a 24-hour period. Parafunctional tooth contacts, in contrast, may occur several hours per day or night. Also, biting strength in bruxers or clencherers can be as much as six times higher than in the nonbruxers, so it takes little imagination to understand why parafunctional habits like bruxing can be an undesirable and damaging habit.<sup>14,5</sup> Bruxing can be confirmed by the noise it produces that can be heard by others and can result in sore chewing muscles. Bruxing may be worse if a person has malocclusions; anxiety or stress; suppressed anger; or is hyperactive; uses caffeine, tobacco, or drugs like cocaine and amphetamines. (See general reference for the Mayo Clinic.)

Teeth in heavy occlusion often exhibit flattened tooth contours seen as tooth **facets**, or chipped enamel and exposed dentin. These teeth may become sensitive when chewing forcefully or when tapped on with a dental instrument, a condition known as **sensitivity to percussion**. Heavy occlusion can also lead to tooth mobility and loose teeth, possibly seen as fremitus. **Fremitus** [FREM i tus] is the palpable or visible vibration or movement of a tooth when subjected to heavy occlusal forces. Fremitus is not necessarily an unhealthy condition but may be an indication of a premature CR tooth contact or of interferences during sideways (lateral) movements of the mandible.

On a radiograph, heavy occlusion on a tooth may contribute to a widened periodontal ligament or angular bone loss or loss of bone in the furcation (which could result in a loose tooth), thickened lining of the tooth socket (lamina dura), and **root resorption** (i.e., the shortening of a root). In the presence of factors contributing to periodontal disease, heavy occlusion can worsen the disease process. Open proximal contacts associated with malocclusions can contribute to food impaction, gingivitis, and periodontitis if not kept clean.

Parafunctional contacts like bruxing can also negatively impact on the ability to open and close the mouth due to tired muscles, or **trismus** (a disturbance of the trigeminal nerve resulting in spasms of the chewing muscles and limited jaw opening). **Myofascial** [my o FASH i el] **trigger points** may result from overuse of the jaw muscles.<sup>9,16</sup> “Myofascial” refers to muscle and *fascia*, which is the thin connective tissue covering that connects muscles. Symptoms include tenderness and pain of the muscles of the face and head, and even the neck and back. Other symptoms associated with heavy occlusion include migraine-type headaches, sinus pain, and jaw joint pain. The pain can sometimes be severe.<sup>1,9,16,17,27,33,34</sup>

*Joint pain* can result from heavy forces on premature or undesirable contacts,<sup>27</sup> but joint pain can also be due to disease, such as arthritis, or injury. **Temporomandibular disorders** (TMDs) caused by abnormal functioning of the TMJ can result from loss of vertical dimension from tooth wear or tooth loss, loss of posterior tooth support, or other malocclusions. Symptoms of TMD include headaches, ringing of the ears (**tinnitus** [ti NI tis]), ear pain, and impaired hearing. Symptoms can be made worse when the force or frequency of clenching and grinding increases, as might occur in persons under psychological stress, or in persons with poor posture (e.g. those who frequently rest one side of their jaw on their hand).

Some tooth contacts are less desirable than others because they are less capable of withstanding heavy forces and more likely to result in an increase of muscle or tooth pain. For example, signs and symptoms from heavy occlusion are more likely when *only* two posterior teeth occlude during heavy or repeated contacts. Canines, on the other hand, are more capable of withstanding heavy occlusal forces, which is why canine-protected occlusion is desirable since posterior teeth separate during protrusive and lateral jaw movements. Also, tooth contacts on the nonworking side are not tolerated well, and heavy forces that are *not* along the vertical axis of the tooth are more likely to be destructive.

Fortunately, we have a natural mechanism that helps to protect teeth from heavy tooth contacts. Our fifth cranial nerve (trigeminal nerve) provides nerve branches to the periodontal ligaments of each tooth (especially canines), and these nerve fibers send messages to the brain from sensory end organs called **proprioceptors** [PRO pree o SEP ters]. Therefore, tooth contacts direct movements of the muscles that move the mandible in order for us to avoid heavy traumatic or deflective contacts.<sup>R</sup> By virtue of this complex protective mechanism, traumatic or deflective tooth contacts are most often avoided during normal functioning (chewing, talking, and swallowing).<sup>8,18–20,22</sup>

**SECTION VI****TREATMENT METHODS RELATED TO MALOCCLUSION**

There are many treatment methods for patients symptomatic due to heavy bruxing, myofascial pain, and TMDs.<sup>29,30,33–35</sup> It is appropriate to begin with therapies that are **reversible** (do not result in permanent changes to the teeth or supportive structures) or **diagnostic** (i.e., therapies used to confirm that the symptoms are caused by malocclusion) before irreversibly moving, restoring, or reshaping teeth or jaw bones.

**A. PATIENT EDUCATION AND BEHAVIOR THERAPY**

It is important to **educate** a person on self-treatments that help alleviate muscle pain or tooth pain related to undesirable or premature occlusion. To begin with, they need to know that their pain may be due to their tooth grinding. Just knowing that clenching and bruxing may cause their pain can help the patient to stop bruxing, at least during the day when they notice it. They need to know that keeping their teeth apart and resting the muscles for a while may help. It is better to eat foods that are easy to chew (like pasta and soups), to avoid foods that require considerable force to chew (like candy-coated peanuts or taco chips), and to avoid foods that increase the frequency of tooth contacts (like chewing gum). Also, limit alcohol, tobacco, and caffeine, all of which may worsen the problem. They should be made aware that bad posture might contribute to muscle pain in the neck and jaws. **Biofeedback** (from monitors charting muscle activity) may also be helpful to provide patients with printouts that confirm when they are tightening their muscles so that they can learn how to avoid these actions.

**B. STRESS MANAGEMENT AND MUSCLE RELAXATION**

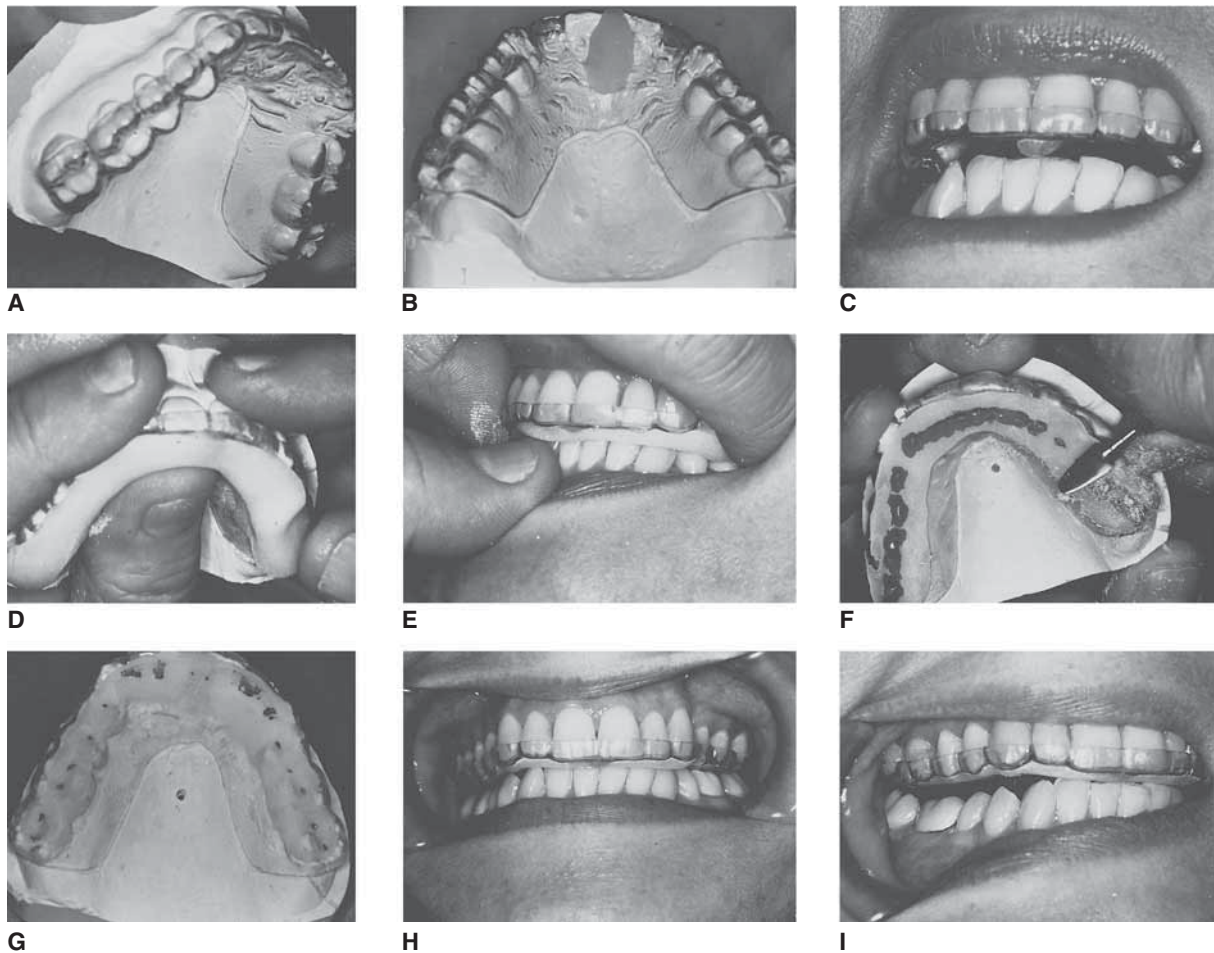
Since persons under psychological stress are more likely to clench and brux more frequently or with more force, therapies that can **reduce stress** may help. Self-therapies include yoga, meditation, deep breathing, and visualization of a peaceful scene. Referral for **psychological counseling** may also be necessary. The dentist may prescribe **pain medications** initially to reduce the pain, **tranquilizers** to help the patient relax, or **muscle relaxants** to help reduce muscle tension, but side effects like drowsiness or dry mouth may be undesirable. Botulinum toxin (Botox) has been shown to be helpful for some persons with severe bruxism who have not responded to other therapies.<sup>36</sup> New research has actually shown that taking some antidepressant medications (like serotonin specific reuptake inhibitors) may have the side effect of bruxing.<sup>37</sup> Therapies that help relieve muscle pain

elsewhere in the body could also be used to reduce pain in the muscles of mastication, and these include applying ice for several minutes followed by moist heat to relax muscles. Jaw muscle exercise may also be helpful once the muscle pain has been eliminated.

**C. CHANGING JAW RELATIONSHIPS WITH AN OCCLUSAL DEVICE**

To successfully correct a patient's unfortunate parafunctional bruxing habit is not an easy task and takes time, skill, and patience at best. A basic principle of treating occlusal dysfunction is to get the teeth to come together evenly (without premature or undesirable contacts) while the mandible is in its most comfortable position. When a patient suffers from pain due to malocclusion, the use of an occlusal device like a bite plane should be considered, and extensive dental work (multiple restorations, bridges, equilibration, orthodontics, etc.) should be postponed until the patient has remained comfortable for several weeks, and upon return visits requires little or no adjustment of the device.

An **occlusal device** (sometimes called a **bite guard** or **night guard**) is a removable artificial occlusal surface that can be used to stabilize occlusion, treat the pain from TMDs, or prevent tooth wear. A detailed description of the method for constructing a maxillary occlusal device is presented in *Figure 9-30*. This type of occlusal device is constructed of a thin, horseshoe-shaped layer of transparent plastic that fits over the upper teeth to provide a smooth surface for the mandibular teeth to contact without a deflective prematurity. A properly constructed occlusal device reduces deflection of the mandible by preventing the input to proprioceptive sensors around the teeth that are in heavy occlusion, thereby providing a noninvasive, reversible therapy.<sup>1,8,18–20,22,38</sup> Its use permits the mandible to close into a centric jaw relation, which is the *most comfortable and stable* position. Patients are advised to wear the occlusal device 24 hours each day except when eating, and the device should be periodically evaluated and adjusted as needed. After a few days, the patient may experience tremendous relief from severe facial muscle pain, headaches, or even some backaches that are related to an imbalance of the TMJ and tooth occlusion. For example, the patient in *Figure 9-22* exhibited trismus and limited jaw opening over a 4-year period. He was only able to open 35 mm at the incisors, but after he wore a maxillary occlusal device for 18 months, his mandible stabilized into a comfortable CR position, and he was able to open at the incisors 55 mm.



**FIGURE 9-30.** Stages of construction and adjustment of a maxillary occlusal device (previously called a night guard). **A.** A thin plastic sheet (1.5 to 2.0 mm thick) has been heated and vacuum-molded (sucked down) onto a clean, dry, accurate cast of the maxillary teeth. The center palatal portion and excess on the sides and posteriorly have been removed, leaving only a 3-mm overlap on the facial surfaces of the teeth. The occlusal surfaces are roughened with a carbide bur so that additional acrylic resin will adhere securely. **B.** A triangular-shaped anterior ramp of cold-curing acrylic resin has been added lingually between the central incisors to maintain vertical dimension and to guide the mandible posteriorly (like a leaf gauge or sliding guide). **C.** Contact with the anterior ramp shows an excessive increase of the vertical dimension, so this is adjusted leaving only a point of contact with the mandibular incisors, so they will contact at an incline of about 45° upward and posteriorly. **D.** The softened dough roll of orthodontic cold-curing clear acrylic resin is adapted over the roughened occlusal and incisal portion of the template with the anterior portion slightly longer and thinner than the posterior part. **E.** The template with the molded softened acrylic resin dough is placed in the mouth and the patient closes gently two or three times in the *terminal hinge position* and just far enough upward so that the mandibular incisors are stopped and the mandible is guided posteriorly by the previously adjusted narrow anterior hard resin ramp. The resin dough is permitted to harden. **F.** With the acrylic resin hardened, return the occlusal device or bite plane to the cast, mark the cusp indentations with a bright red felt marker, and then grind off all excess acrylic except the imprints of only the tips of the cusps resulting in a flat plane. **G.** Relieve the anterior portion of all tooth imprints and slope it sharply upward toward the lingual to provide a ramp for disocclusion during lateral jaw movement. The posterior imprints are correct for *initial placement* of the device. While on the cast, the roughened acrylic resin is lightly buffed with a rag wheel and polishing compound. **H.** Place the maxillary occlusal device with the patient initially closing in centric relation. The mandibular posterior teeth contact uniformly (without deflections) on a flat smooth plane. The mandibular anterior teeth are just barely out of contact until the jaw moves forward or to either side. **I.** The patient slides the mandible to the right, and all teeth on the right side disocclude as the lower left canine slides up the lingual ramp. (Courtesy of Dr. Richard W. Huffman, Professor Emeritus, Ohio State University.)



## D. CHANGING TEETH SHAPES TO TREAT SYMPTOMS OF MALOCCLUSION

**Occlusal equilibration** is the process by which a dentist modifies the occlusal or incisal form of the teeth by using revolving burs or stones in a dental handpiece to remove very small amounts of enamel at the sites of the tooth prematurities.<sup>22</sup> An occlusal equilibration should never be attempted without first having the patient wear a maxillary occlusal device for 1 to 6 weeks, which ensures natural and comfortable repositioning of the mandible and its TMJ. After equilibration, the teeth should be in harmony with physiologically relaxed joints. The occlusal equilibration should be reevaluated at appropriate intervals to confirm the need for follow-up treatment.

Another technique that can be used to perfect the contours and occlusion of teeth that are not too badly out of alignment is to reconstruct the occluding surfaces of all or most teeth by constructing large, stress-bearing restorations such as crowns or fixed partial dentures (bridges). This technique is called a **full-mouth rehabilitation** where most teeth are restored with crowns that change and perfect the occlusion. An example of the stages of a full mouth rehabilitation performed during the 2000s is presented in *Figure 9-31*. This patient presented to the dentist with a history of severe gastric (acid) reflux, which contributed to erosion of lingual enamel and much dentin on the lingual surfaces of the anterior teeth. He complained of tooth pain (due to exposed dentinal tubules), muscle pain, and TMJ pain. He exhibited a deviation between CR and MIP of about 2 mm. After preliminary diagnostic procedures were completed, the decision was made to restore all

posterior teeth with crowns to correct the deviation, and place all-ceramic crowns or lingual indirect composite veneers to improve contours and cover exposed dentin on all anterior teeth. *Figure 9-31* shows the teeth before, during, and after the full mouth rehabilitation. After therapy, the patient reported no symptoms, and esthetics was improved.

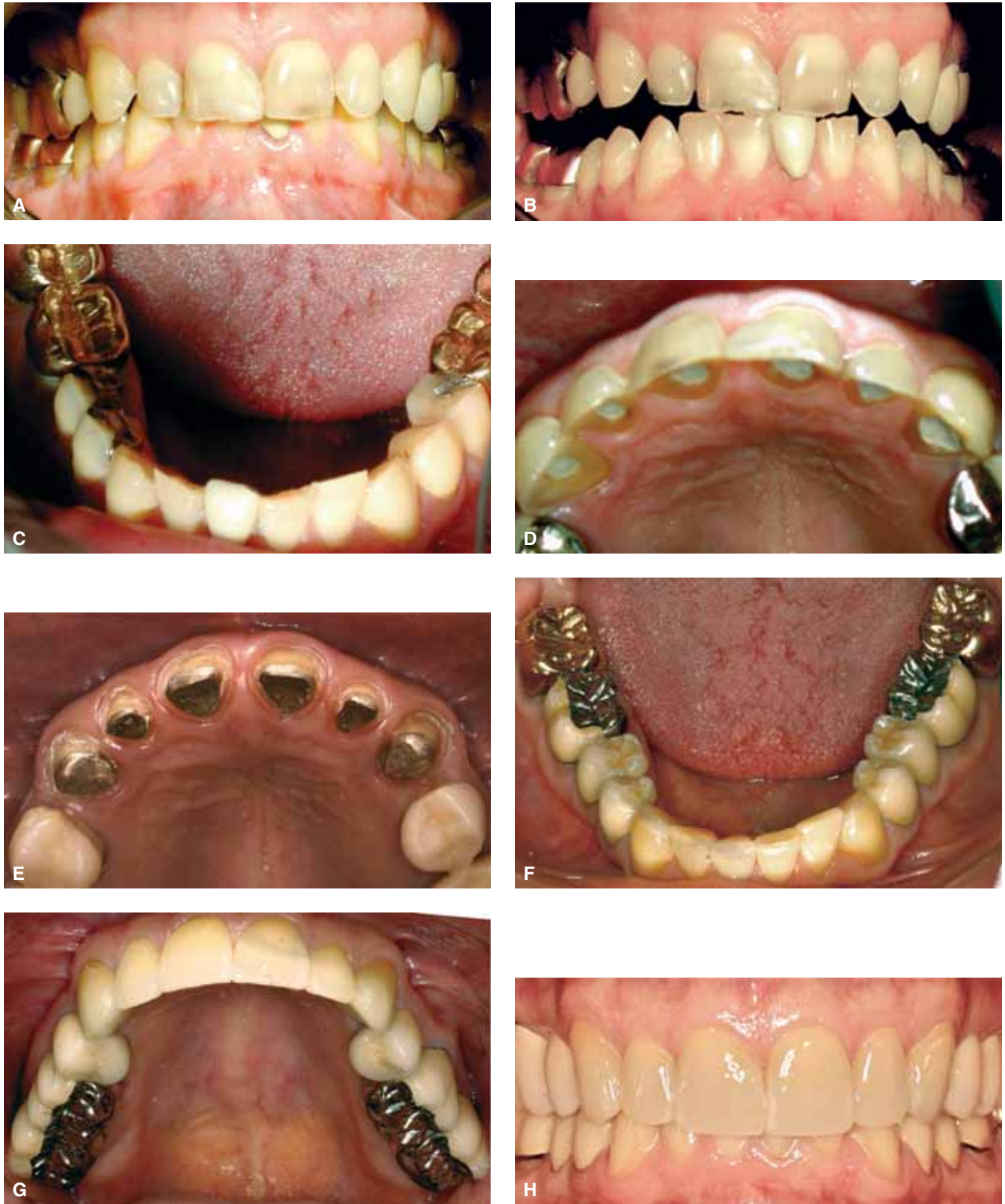
## E. CHANGING TOOTH LOCATION TO TREAT MALOCCLUSION

When teeth are so poorly aligned that the amount of tooth structure to be removed during an equilibration or a full mouth rehabilitation would result in exposure of sensitive dentin or even exposure of pulpal tissue, the dentist needs to consider other treatment options. **Orthodontic treatment** can be used to bodily move the teeth into an improved alignment. *Figure 9-22* shows the results of a severe unilateral molar prematurity in the centric relation position. This patient underwent over 2 years of orthodontic therapy to correct the enormous discrepancy between centric jaw relation and MIP. Other alternatives would have been surgery (intrusion of molars) or possibly root canal therapy on the molars followed by eight cast crowns (reducing molar cusp height). Ordinarily, a centric relation prematurity is not as severe as this and often can be corrected when necessary with minimal occlusal equilibrations or minor orthodontic tooth movement.

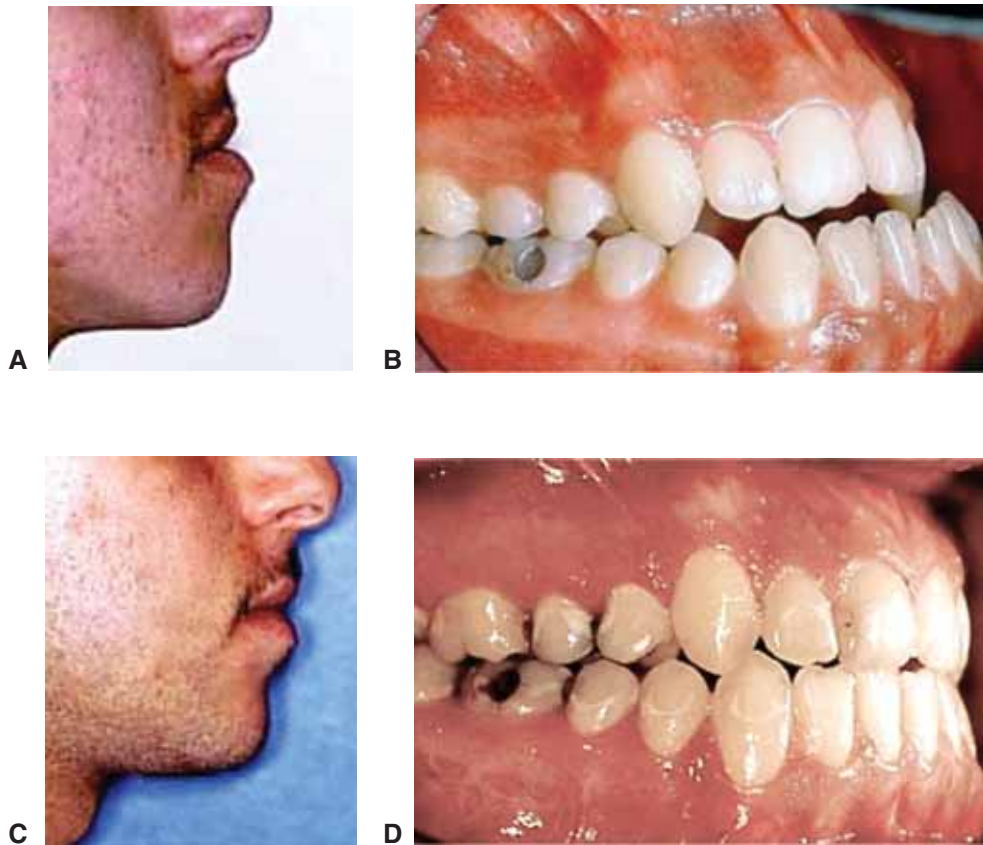
Treatment of class II and class III malocclusions using orthodontics (including braces) usually requires much longer correction time and often involves surgical intervention compared to treatment of class I malocclusions. This is due to the greater disparity from an ideal

**FIGURE 9-31.**

**Stages of a full mouth rehabilitation.** **A.** Pretreatment: facial surfaces of teeth in maximum intercuspal position. Notice the anterior deep overbite. **B.** Pretreatment: facial surfaces of teeth with the mandible protruded so the incisors are now in an edge-to-edge position. Notice the translucency of the maxillary central incisors, indicating very thin enamel due to severe lingual erosion. Also notice the gingival irritation related to a bulbous existing crown on the mandibular left central incisor (No. 24). **C.** Pretreatment: incisal/occlusal view of the mandibular teeth. Notice the thinness of the mandibular anterior teeth due to severe lingual erosion. **D.** During treatment: incisal view of maxillary anterior teeth revealing the temporary (interim) restorations on the lingual surface of each of these teeth. These restorations cover the openings that were required to access and remove the pulp from each tooth (endodontic therapy). **E.** During treatment: all maxillary anterior teeth (that had been treated with endodontic therapy) were prepared for crowns and, due to the reduction of remaining tooth structure, had custom cast post and cores placed within each anterior tooth. The posts were cemented into spaces prepared by the dentist into the root along the pulp canals, and the core (the metal that shows) provides additional support and retention for the crowns that would be placed over them. **F.** Posttreatment photograph of the mandibular teeth showing complete cast metal crowns on both second molars (Numbers 18 and 31), metal ceramic crowns on both first molars (Numbers 19 and 30), and metal ceramic crowns (metal is not visible) on all premolars (Numbers 20, 21, 28, and 29), as well as replacing an overcontoured crown on the mandibular left central incisor (No. 24). All other mandibular anterior teeth were veneered lingually with indirect composite veneers (Numbers 22, 23, 25, 26, and 27). **G.** Posttreatment of the maxillary teeth showing metal ceramic restorations (porcelain fused to metal crowns) on first and second molars (Numbers 2, 3, 14, and 15), metal ceramic crowns (metal is not visible) on the two remaining premolars (Numbers 4 and 13), and all-ceramic crowns on the anterior teeth (Numbers 6, 7, 8, 9, 10, and 11). **H.** Posttreatment: facial view of all teeth in intercuspal position (which now is the same as centric relation) showing improved esthetics. (Provided by Julie Holloway, D.D.S., M.S., The Ohio State University.)



**FIGURE 9-31.** (Continued). Legend is on previous page.



**FIGURE 9-32.** Comparison of jaw alignment before and after orthognathic surgery. **A.** Pretreatment patient prognathic profile. **B.** Pretreatment class III molar alignment with anterior cross bite. **C.** Posttreatment orthognathic profile. **D.** Posttreatment class I (almost) molar alignment. (Slide courtesy of Dr. Guillermo E. Chacon, D.D.S., The Ohio State University.)

relationship of the corresponding teeth in the maxillae and mandible. When the jaws are so poorly aligned or so different in size that it is impossible to perfect tooth contour using only restorations or orthodontics, **surgical techniques** can be used to reshape and realign jaw bones, usually followed by orthodontic treatment to perfect tooth alignment. **Orthognathic surgery** [or thog NATH ik] is the surgical reshaping of the jawbones and

may be used in conjunction with orthodontics to correct severe class II and class III skeletal malocclusions. This technique dramatically and quickly improves appearance; provides better tooth relationships; and eventually, better function as well. The change in profile and occlusion from this surgery can clearly be seen in *Figure 9-32*.

## SECTION VII ADVANCED TOPICS IN OCCLUSION

### A. ENVELOPE OF MOTION

A helpful method for analyzing a patient's mandibular movement is to obtain an outline of their jaw movement called an **envelope of motion**. This is done by attaching a marking device (stylus) to the mandibular teeth that can trace on paper the movements of the mandible as viewed from the front (a frontal view) or from the side (a sagittal view). *Figure 9-33* shows examples of these

two tracings, both reproducing the outer border movements during maximal movement of the mandible. When facing a person, the *frontal* envelope is the outline formed (traced) by a marker located between the mandibular central incisors while the mandible moves *maximally in all directions*. Beginning with teeth in their most intercuspal position (MIP), the mandible (with teeth lightly touching) moves the maximum distance



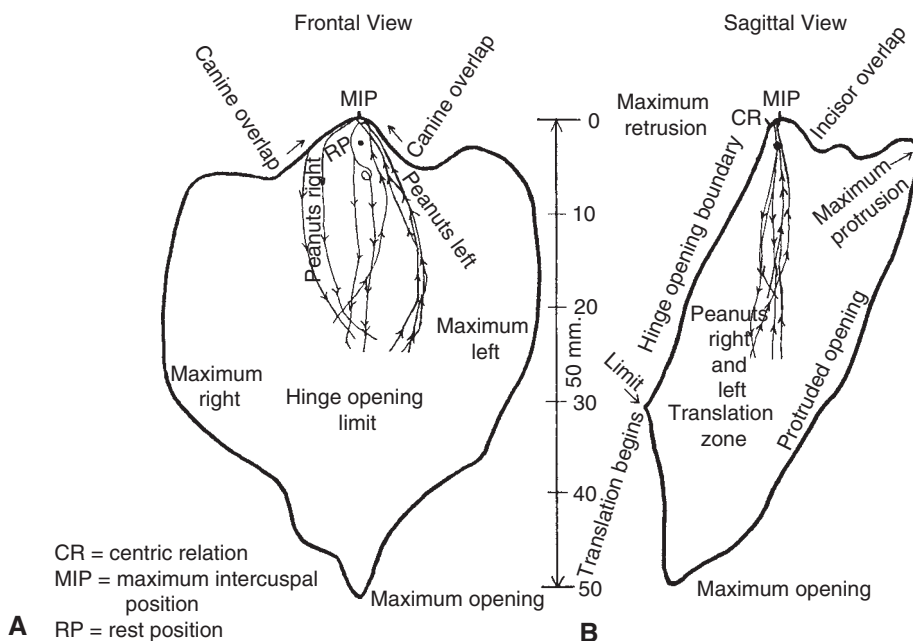
to the right, then, in its most right position, depresses to its most open position, and from there closes in its most left position until teeth lightly touch, and finally returns (with teeth lightly touching) to the MIP.

Now, analyze an actual tracing of a *frontal* envelope in Figure 9-33A in order to appreciate what it reveals. Begin in the MIP at the top and follow clockwise. The mandible with the teeth in light contact first slides laterally to the patient's left (our right) as far as possible. The outline reveals the amount of canine overlap resulting in the mandible initially moving down as it moves to the side until the canines are end to end, and then moves upward as the canines move laterally beyond their end-to-end alignment. Next, the jaw opens downward in its most left lateral position until open about 30 mm, then begins veering toward the center to a maximum opening of 51 mm. From this point, the jaw moves to the patient's right (our left) as far as possible as it begins to close. Finally, from the closed maximum right side position, the teeth slide into MIP as the jaw slowly moves back and upward (due to the canine overlap) into the starting point (MIP).

The *sagittal* envelope can be visualized, when viewing a person from the side, as an outline formed (traced) by a dot located between the mandibular central incisors while the mandible begins in the centric relation (CR) position, just before the teeth move forward into the MIP. Next, with teeth lightly together, the mandible moves into its most anterior (protruded) position, then to its most open position, and from there the mandible closes in its most posterior position into CR until teeth

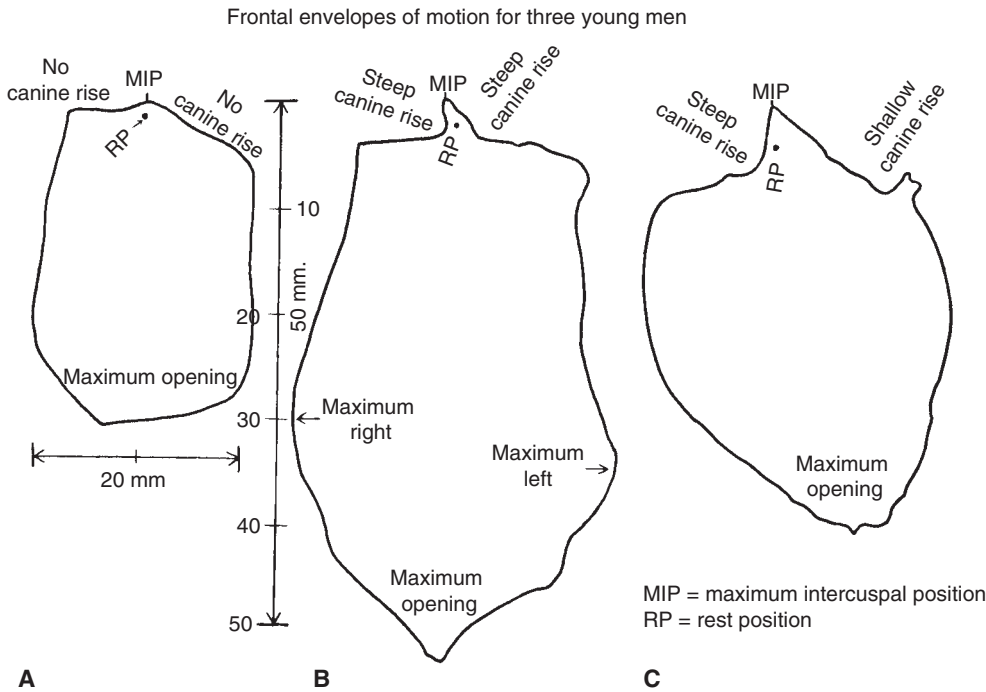
lightly touch. Finally, the mandible returns (with teeth lightly touching) to the MIP. To analyze the tracing of a sagittal envelope of motion in Figure 9-33B, begin at the centric relation or CR. Due to a slight deflective (premature) contact, the mandible is directed forward and slightly upward into the MIP. With the teeth held together lightly as the mandible continues to protrude maximally, the initial downward movement of the mandible is due to incisal overlap (normal overbite) where the lingual surfaces of maxillary incisors guide the mandible downward as it goes forward, followed by an upward and forward movement as mandibular incisors move beyond the edge-to-edge position into the most protruded position. With the mandible protruded, it moves down to the maximum opening of 51 mm. From this point, the jaw closes while firmly retruded, which develops the curved *translation* portion of closure, followed by the straighter *hinge*-opening boundary (with rotary motion only), and finally back to the starting point (MIP). We can tell from this envelope of motion that upon opening, this person can rotate his retruded mandible open 30 mm at the incisors with a hinge movement before it begins to translate forward.

Now, study Figure 9-34 to compare the uppermost portions of the frontal envelopes of motion of three subjects in order to visualize differences in the superior portion related to the amount of canine guidance (overlap). Subject A has the smallest and narrowest range of movement for his mandible (32 mm vertically, 21 mm sideways). No lowering of the mandible on either side of the MIP indicates that he did not have



**FIGURE 9-33.** Frontal and sagittal maximum envelopes of motion with chewing strokes. **A. Frontal view:** Four chewing strokes are shown within the large envelope of motion as the patient chewed on 3 gm portions of peanuts, first on the left side and then on the right side (arrows denote direction of chewing strokes). **B. Sagittal view** of same patient during chewing.





**FIGURE 9-34. Envelopes of motion** that reveal variations in movement and canine guidance (canine-protected articulation): The frontal envelopes of motion of three men, demonstrating the wide range of variability between the movement capabilities and their canine guidance.

canine protection (i.e., there are no deeply overlapping canines) to lower the mandible and disocclude the posterior teeth. Subject B can open his mandible 53 mm and move it laterally 31 mm. He has a canine-protected occlusion as indicated by the steep portion where the mandible drops on either side of the MIP. Subject C has a medium-sized envelope of motion with canine protection on his right side (left side of envelope C) and group function occlusion with shallow canine rise on his left. This patient preferred to chew mostly on his left side where his envelope is lopsided.

To appreciate the amount of mandibular movement during **chewing** relative to the entire envelope of motion, once again analyze Figure 9-33A. Focus on the smaller pattern of lines with arrows (enclosed within the larger frontal envelope of motion) of that person chewing peanuts on the right and left sides. The lines traced during the opening stroke (denoted by opening arrows pointing downward) are somewhat straight, whereas the closing stroke lines are considerably convex (or bulge) as the mandible moves toward the working side to obtain working side tooth contacts. The chewing cycles occupy only 25 mm of the maximum 51 mm opening range for this man. The chewing strokes on peanuts in a lateral direction utilize only 12 mm of the total side-to-side range of mandibular movement.

On the *sagittal* view (Fig. 9-33B), note that the chewing stroke begins at the MIP and that the opening stroke is more posterior than the closing stroke. The opening stroke is only 7 mm anterior to the hinge-opening

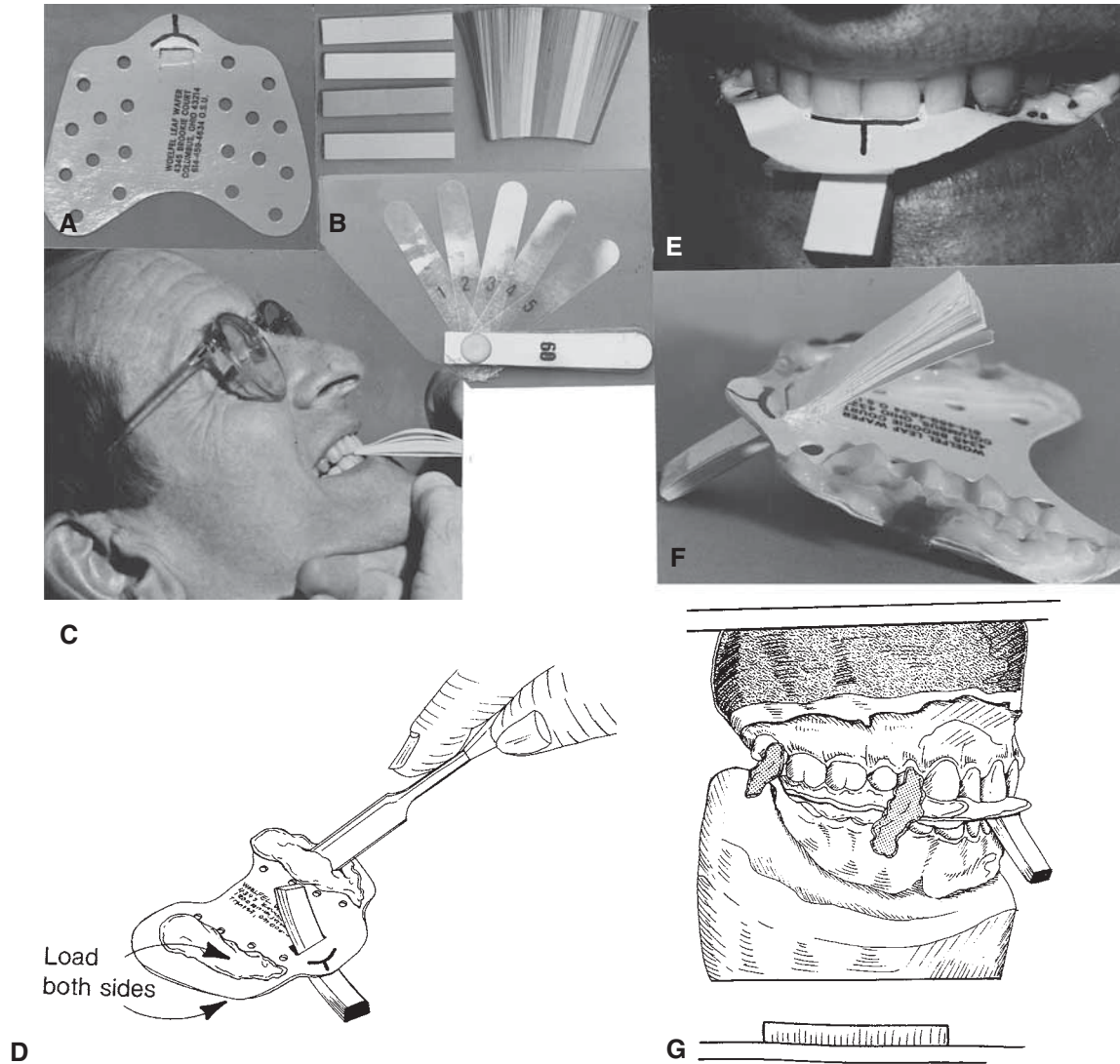
boundary, whereas the closing stroke is 10 mm anterior to that boundary. However, as the jaws are closed to crush the food bolus, the mandible is slightly more retruded than the MIP. Crushing of the food bolus (a rounded mass of food) occurs at this MIP.

## B. ACCURATE RECORDING OF THE CENTRIC RELATION JAW POSITION

The process of obtaining an accurate centric relation jaw registration or occlusal record is seen in Figure 9-35. First, a leaf wafer<sup>19,25,39</sup> is selected and deformed in the mouth as the patient bites into it. Then an anterior deprogrammer<sup>18,22,25,39-43</sup> is inserted at an upward angle between the incisors as the patient arcs the mandible open and then closes (hinge type or rotational opening) until the incisors engage the leaf gauge of sufficient thickness so all other teeth separate slightly (Fig. 9-35C). **Anterior deprogramming**<sup>18,22,25,39-47</sup> is the process of getting the TMJ into a relaxed or comfortable neuromuscular position (centric relation) by interrupting or negating the proprioceptors surrounding the teeth in the periodontal ligaments. These proprioceptors would otherwise automatically or subconsciously direct the mandible into the habitual or acquired intercuspal position. Anterior deprogramming is usually accomplished in 10 to 15 minutes by interposing something between the anterior teeth<sup>20,39,41,42,45,46</sup> (such as a leaf gauge, Lucia jig, or sliding guide) while the

patient retrudes the mandible and squeezes slightly on the centered anterior fulcrum (see Fig. 9-35C). In this manner, the mandible is “tripodized” (stabilized by two condyles and the leaf gauge) by the patient’s nerves and muscles, and the patient is momentarily unable to aim the jaw into the acquired or habitual occlusion because no signals can be sent to the brain from the proprioceptors in the separated teeth.<sup>38</sup> Otherwise, the

teeth could cause the mandible to deflect forward from the centric relation position. The posterior teeth must remain separated several minutes for deprogramming to occur.<sup>20,43</sup> Once it has occurred, the patient will feel as if the posterior teeth occlude (contact) improperly or in a strange way (with deflective contacts). In some instances, the deprogramming will not occur until the patient has worn an occlusal device for several weeks



**FIGURE 9-35.** Procedure for making a centric relation jaw registration. This jaw relation registration (interocclusal record) is used for mounting casts in centric jaw relation on an articulator for analysis and possible tooth alteration or orthodontic movement. **A.** A Woelfel leaf wafer used to carry a leaf gauge (in **B**) of predetermined thickness and the registration medium into the mouth. **B.** Paper leaf gauges above (color coded for thickness) and below, a numbered plastic leaf gauge. **C.** Patient, with head tipped back, is arcing his mandible in the hinge position and closing on the leaf gauge of minimal but sufficient thickness to separate all teeth to negate any learned habitual closure. **D.** The recording material, polyether rubber, was applied to tooth indentations on the wafer. **E.** The patient closes firmly onto the leaf gauge as the recording material sets. **F.** The centric relation registration with leaf gauge. **G.** The leaf wafer registration is used to orient the lower to upper cast for assembly on an articulator. A brittle, strong sticky wax (shaded areas on drawing) is used to maintain the relationship of the maxillary and mandibular casts until the mounting plaster attaches the casts to the articulator sets.

and has maintained a stable and comfortable mandibular position for at least 1 week.<sup>43</sup>

Next, the leaf gauge is inserted in the wafer, and an impression material is thinly spread over tooth indentations in the leaf wafer (Fig. 9-35D). Then the entire assembly is carried to the mouth (Fig. 9-35E), and the patient closes firmly, as previously, onto the leaf gauge until the recording medium sets. The imprints of the upper and lower teeth in this **centric relation registration** (Fig. 9-35F) are used to relate casts of each arch mounted on the articulator (Fig. 9-35G). This diagnostic mounting procedure should always be accomplished prior to attempting any type of tooth equilibration in the mouth.<sup>18,19,22</sup> These dental stone casts, mounted in their relaxed centric relation position, can be used to determine the extent of tooth reshaping required in order to decide the best treatment. The dental stone teeth with interfering or premature contacts can be reshaped (reduced) in order to predict the amount of tooth reduction that will be required during the equilibration. If the amount of tooth structure that must be removed during the equilibration would likely expose dentin or pulp, then orthodontics or surgical procedures must be considered.

Another device used for anterior deprogramming of the mandible and for recording centric jaw relation is the *sliding guiding inclined gauge or sliding guide*<sup>40-44</sup> (Fig. 9-36). It comes in three maximum thicknesses, and the thickness used is dependent on the severity of the malocclusion (Fig. 9-36A). The thickness gradually increases from tip to handle, and the curvature of the sliding guide is critical, so that it can be placed in the mouth between overlapping incisors at a relatively steep angle relative to the plane of occlusal without injuring the tissue of the roof of the mouth (Fig. 9-36B). The exact thickness between the incisors is read on the millimeter scale (Fig. 9-36C). Minimal incisal separation is the goal for deprogramming and jaw position registration, just so long as no posterior teeth touch, thus avoiding proprioceptive impulses. This is particularly important for the centric jaw relation registration to

minimize errors between the articulator and the patient. The sliding guide is made of a non-brittle autoclavable plastic and works well with a custom bite deformed Woelfel leaf wafer for centric relation jaw registrations (Fig. 9-36D and E).<sup>40-43</sup>

### C. LONG CENTRIC ARTICULATION

**Long centric articulation** or the intercuspal contact area is actually a range of mandibular movement where a person can smoothly (without interferences) move the mandible from centric relation directly forward in a horizontal plane to the position of maximum intercuspal contact. There is no upward or lateral component. This range of movement is often the goal during an equilibration to provide the patient with a long centric relationship by relieving all deflective or premature tooth contacts that had previously caused the mandible to deviate either sideways or upward from centric relation to the MIP. The patient with a long centric articulation will have a small anteroposterior range (0.5 to 2.0 mm) of uniform posterior tooth contact occurring at the same vertical dimension of occlusion.

#### LEARNING EXERCISE TO EVALUATE YOUR OWN JAW MOBILITY OR MANDIBULAR MOVEMENT CAPABILITY

It should be an educational and interesting experience for you to complete this simple exercise in order to increase your awareness of your own jaw movements. It will take about 20 minutes to do this exercise.

Obtain a clean, plastic millimeter ruler cut off even with the zero mark. Make the following measurements as described while observing your tooth relationship in a mirror.

**FIGURE 9-36.** Obtaining centric relation jaw registrations. **A.** Three sliding guiding inclined gauges. The millimeter scales denote the amount of incisal separation between overlapping incisors (left sliding guide 16 mm, center one 9 mm, right one 4 mm). **B.** A 4-mm sliding guide is held between the incisors at a steep angle to the occlusal plane separating them by 2.5 mm, just enough to keep all of the posterior teeth from touching. **C.** A 9-mm sliding guide is placed in the mouth so that the incisors are separated by 6.5 mm during the muscular deprogramming period. **D.** A centric relation jaw registration made with a 4-mm sliding guide inserted into a previously constructed custom “bite deformed Woelfel leaf wafer.” The minimal amount of incisal separation (2.5 mm) was determined prior to the centric relation registration that was used to mount diagnostic casts of the patient on an articulator in centric jaw relation. **E.** The curvature of the sliding guide and its proper angle above the occlusal plane are seen. **F.** Maxillary side of the registration showing the tooth indentations and the 3.5-mm incisal separation. **G.** Inferior view with mandibular tooth imprints in the registration media and pertinent patient information written with a Sharpie fine point marker.



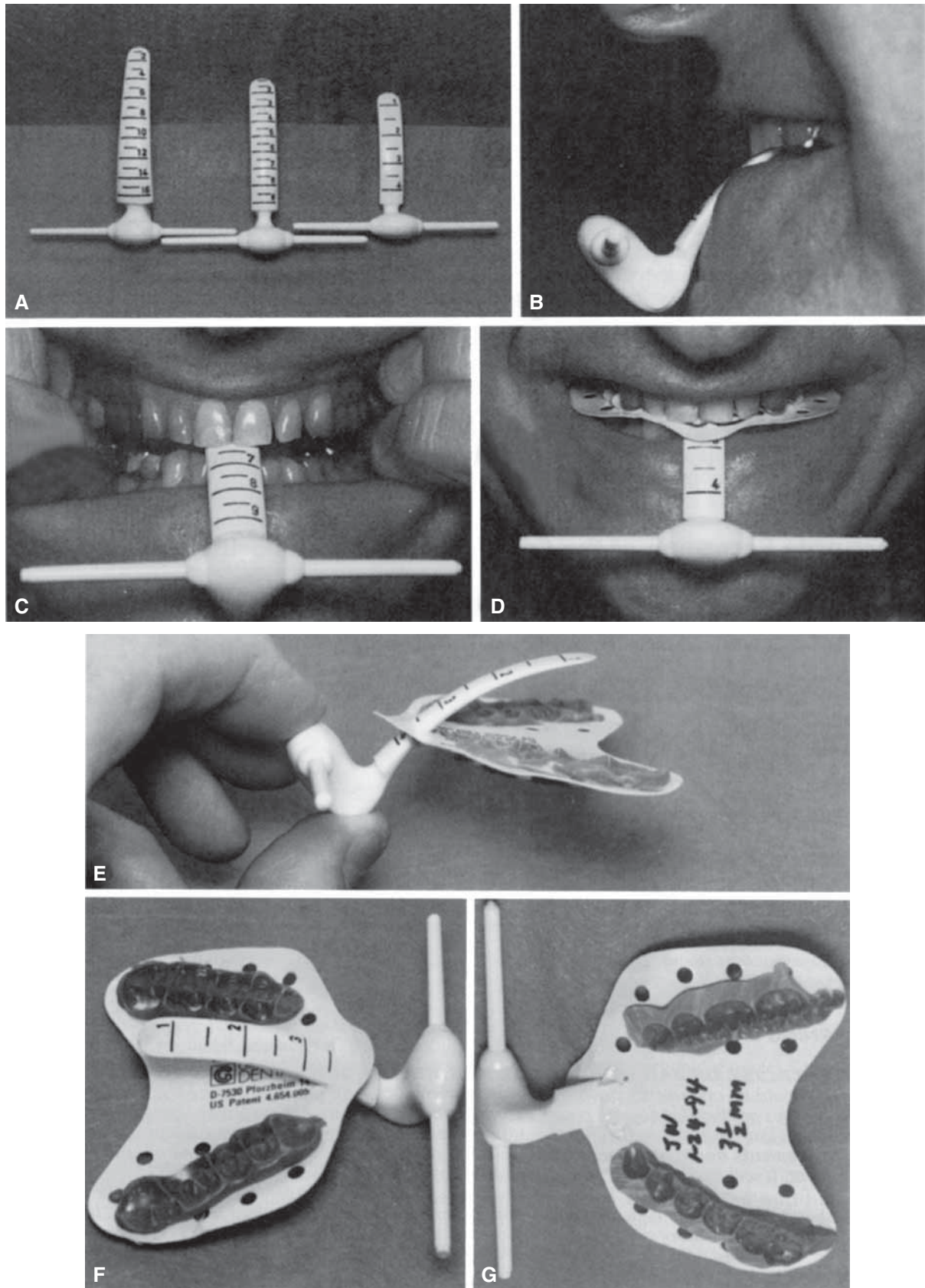
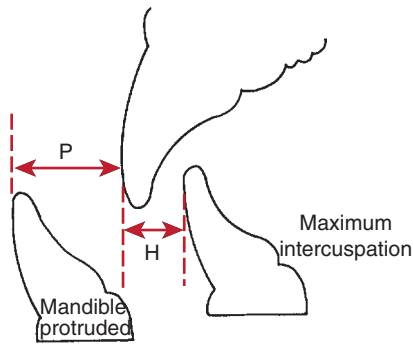


FIGURE 9-36. (Continued). Legend is on previous page.





**FIGURE 9-37.** H is the horizontal overlap of central incisors with the teeth in maximum intercuspation, and P is the horizontal overlap with the mandible protruded as far as possible.

### Learning Exercise, cont.

#### 1. Horizontal overlap (H) of incisors and canines

Using a mirror, measure the horizontal overlap (H in Fig. 9-37) in the following three locations while holding your teeth together in MIP (or on handheld tooth models with teeth tightly closed).

- 1a. \_\_\_ mm = horizontal overlap between the labial surfaces of central incisors at the midline
- 1b. \_\_\_ mm = horizontal overlap between labial surfaces of left canines
- 1c. \_\_\_ mm = horizontal overlap between labial surfaces of right canines

#### 2. Protrusive overlap (P) = \_\_\_ mm

Measure the protrusive overlap (P in Fig. 9-37) with your lower jaw moved forward as far as

### Learning Exercise, cont.

possible (like a bulldog), between the labial surface of the maxillary central incisors and the labial surface of the mandibular incisors.

#### 3. Horizontal overlap of canines during lateral excursions (right and left sides)

Measure the horizontal distance between the facial surfaces of the upper and lower canines during maximum movements in lateral excursions, first with the lower jaw moved to the left as far as possible as seen in Figure 9-38A. This is just like the measurement P in Figure 9-37, only between the facial surfaces of the maxillary and mandibular left canines.

- 3a. \_\_\_ mm = left horizontal overlap of canines

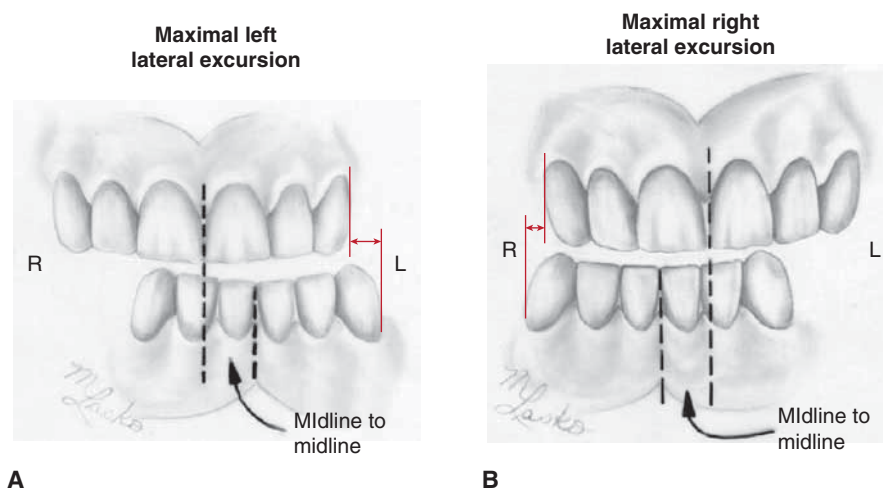
Next, measure the horizontal distance between the facial surfaces of the upper and lower canines during a maximum lateral movement of the jaw to the right side as far as possible, as seen in Figure 9-38B.

- 3b. \_\_\_ mm = right horizontal overlap of canines

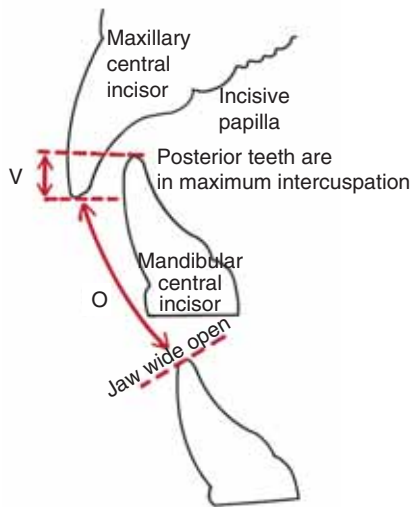
#### 4. Vertical overlap of central incisors (V) = \_\_\_ mm

Measure the vertical overlap (V in Fig. 9-39) at the midline between the incisal edges of your central incisors while holding your back teeth tightly closed or on your tooth models in MIP.

#### 5. Opening movements (hinge opening and total opening)



**FIGURE 9-38.** Lateral jaw movements of the mandible moved as far as possible to the left (A) and to the right (B).



**FIGURE 9-39.** V is the vertical overlap of central incisors in maximum intercuspation, and O denotes the maximum opening distance between incisors.

#### Learning Exercise, cont.

The **hinge opening** is the distance between incisal edges at the maximum hinge-only opening. Practice opening your jaw slowly as far as possible with a hinge movement in centric relation. Hinge opening is usually only half or less than half of the maximal opening (**first portion of O** in Fig. 9-39, and represented in Fig. 9-20B as the limit of the hinge opening). If you open properly, there should not be any crepitation because the articular discs and condyles are fixed posteriorly.

5a. \_\_\_ mm = hinge opening

Now open as widely as you can and measure the **maximum opening** (O in Fig. 9-39) between the incisal edges (usually you can fit four fingers between your incisors). If you noticed a noise near one or both ears when you opened widely, it is probably caused by a disharmony between the movement of the jaw and the movement of the disc that fits between the jaw condyle and the skull on either side. It is usually not a serious problem, and many people experience crepitation for a while during their lifetime.

5b. \_\_\_ mm = maximum opening (O in Fig. 9-39)

#### Learning Exercise, cont.

#### 6. Calculate maximum movements

- 6a. Add measurements 4 plus 5b to obtain **total incisor opening** = \_\_\_ mm
- 6b. Add 4 and 5a to obtain **maximum hinge opening at incisors** = \_\_\_ mm
- 6c. Add measurements 1b and 3a to obtain **maximum left lateral movement** = \_\_\_ mm
- 6d. Add measurements 1c and 3b to obtain **maximum right lateral movement** = \_\_\_ mm
- 6e. Add measurements 1a and 2 to obtain **maximum protrusion** = \_\_\_ mm
- 6f. Add totals 6c and 6d to obtain **total lateral movement** (from right to left) = \_\_\_ mm

Are you surprised that you can move your mandible farther from side to side than you can move it directly forward? Usually your jaw can move about twice as far sideways (laterally) as it can protrude or move directly forward. Compare the results of your own jaw movement capability with that of 796 dental hygienists and 318 dental students in *Table 9-3*.

#### LEARNING EXERCISE

Sketch, by memory, the teeth on the right side of the mouth in ideal class I relationship. (Third molars do not need to be included.)

To appreciate the alignment of maxillary and mandibular teeth in ideal class I occlusion, use the following directions to sketch all teeth on the right side of the mouth several times until you can repeat the sketch by memory. Perfection of anatomic form is not as critical as developing the correct proportions and shape of each tooth (incisal edges vs. one, two, or three facial cusps), and correct alignment between arches.

1. Use a model of maxillary and mandibular teeth, or a typodont, with teeth in ideal alignment as a guide. First, hold the teeth together in maximal intercuspation but then separate them only enough so that from the facial view, you can see all maxillary and mandibular facial cusp tips and incisal edges.


Table 9-3 CAPABILITY OF MANDIBULAR MOVEMENT OF 1114 STUDENTS

		MAXIMUM JAW OPENING (mm)	RIGHT MAXIMUM LATERAL JAW MOVEMENT (mm)	LEFT MAXIMUM LATERAL JAW MOVEMENT (mm)	MAXIMUM JAW PROTRUSION (mm)	ENTIRE LATERAL JAW MOVEMENT (mm)
DENTAL HYGIENE STUDENTS (796)	Average	51.01	7.68	7.71	8.44	15.39
	Low	27.0	2.5	2.0	3.0	7.0
	High	68.5	14.0	15.2	16.0	28.4
DENTAL STUDENTS (318)	Average	50.99	9.12	9.32	7.95	18.44
	Low	35.5	2.0	3.0	2.5	6.0
	High	71.0	14.0	15.4	13.5	32.0
	Total average (1114 students)	50.29	8.09	8.17	8.30	16.26

Research conducted by Dr. Woelfel at the Ohio State University, 1974–1986.

### Learning Exercise, cont.

- To make your job easier, do not attempt to reproduce the anterior-posterior curve of Spee. On your paper, place two horizontal, slightly separated, parallel lines that can be used to align the chewing edges of all teeth. Also, place vertical lines to denote the midline of both arches (Fig. A).

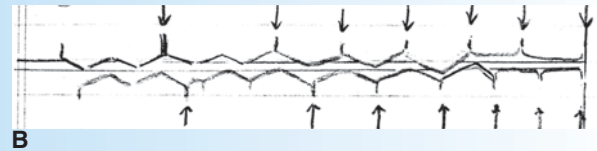


A

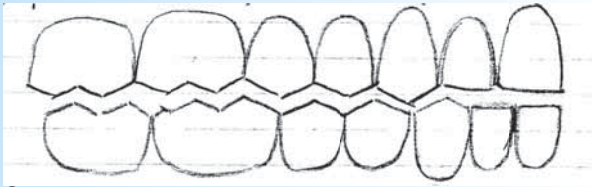
- Sketch (*very lightly*) the right maxillary and mandibular central incisors. View the anterior teeth from the facial view with the midlines lined up. The mesial surfaces of each tooth should touch the midline, the incisal edge should touch the parallel horizontal lines, and the maxillary central should be wider than the mandibular incisor.
- Next, sketch (*very lightly*) the relative shape and width of each incisal edge or cusp in the maxillary arch using the top horizontal line as a guide for placing the incisal and occlusal surfaces. Note that the models or typodonts must be rotated when viewing more posterior teeth so that each tooth is viewed directly from the facial. Recall that the maxillary lateral incisor is narrower than the central, but the canine and two premolar cusps are about equal in width (except the canine is often slightly longer [beyond the horizontal line]). The

### Learning Exercise, cont.

first and second molars each have two facial cusps of approximately the same width, neither of which is as wide as the premolars or canine (Fig. B).



- Now sketch (*lightly*) the incisal edge or cusp of each tooth in the mandibular arch. Try to correctly align mandibular cusps relative to maxillary cusps. For example, the cusp tip of the mandibular canine is aligned with the embrasure between the maxillary lateral incisor and the canine, the cusp tip of the mandibular first premolar is aligned with the embrasure between the maxillary canine and first premolar, and so forth. Recall that the mandibular first molar most often has three buccal cusps; keep the distal cusp quite small in order to maintain the proper alignment between arches. Begin to form the occlusal/incisal embrasure spaces by rounding the mesial and distal “corners” of each tooth (more so for posterior teeth).
- Sketch (*very lightly*) the proximal and cervical contours of each tooth. Remember to form the rounded incisal/occlusal embrasures that contour to form proximal contacts with the adjacent tooth, and then taper narrower toward the convex cervical line (which, in health, parallels the free gingival margin) (see Fig. C).

**Learning Exercise, cont.****C**

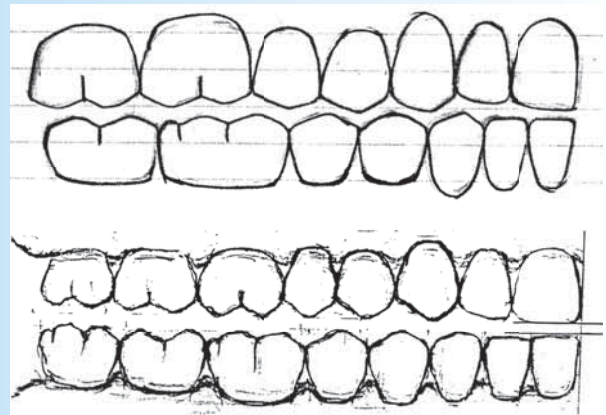
7. Evaluate the overall shape and proportion of each tooth to see if changes are required. If you sketched lightly up to this point, it should be easy to erase and make corrections. **Self-evaluate your light sketches using the following criteria:**

- **Crown shapes** are recognizable as facial views of each type of tooth.
- **Proportions** for each tooth are reproduced (i.e., approximate width vs. height).
- **Relative sizes** of teeth are correct.
- **Proximal contacts** are in the incisal or middle thirds but never in the cervical half of the tooth.
- **Embrasure spaces** are reproduced.
- **Cervical line contours** approximate the junction of gingiva and tooth.
- **Correct class I occlusion** is reproduced. (That is, mesiobuccal cusp tip of the maxillary first

**Learning Exercise, cont.**

molar aligns with the mesiobuccal groove of the mandibular first molar, and the cusp tip of the maxillary canine aligns with the embrasure between the mandibular canine and first premolar.)

8. Then, finally, neatly perfect the contours with a darker line in order to produce the final, distinct shapes for each tooth. Two drawings sketched from memory by two dental students during a final dental anatomy examination are presented in *Figure D*.

**D**

## Review Questions

Answer the following questions with the one best answer based on this sketch of teeth in class I occlusion.

1. In the maximum intercuspal position (MIP), which two teeth occlude with the maxillary first premolar?
  - a. Mandibular canine and first premolar
  - b. Mandibular first premolar and second premolar
  - c. Mandibular second premolar and first molar
2. In MIP, which two teeth occlude with the mandibular second molar?
  - a. Maxillary first premolar and second premolar
  - b. Maxillary second premolar and first molar
  - c. Maxillary first molar and second molar
3. Which two teeth would occlude with the incisal edge of the right mandibular lateral incisor during protrusion of the mandible?
  - a. Maxillary right central incisor and left central incisor
  - b. Maxillary right central incisor and right lateral incisor
  - c. Maxillary right lateral incisor and canine
  - d. Maxillary right canine and first premolar
4. In MIP, with what landmark would the lingual cusp of the maxillary second premolar occlude?
  - a. The mesial marginal ridge of the mandibular second premolar
  - b. The mesial fossa of the mandibular second premolar
  - c. The distal marginal ridge of the mandibular second premolar
  - d. The mesial fossa of the mandibular first molar



5. If this person did not have class I occlusion but had class II occlusion (where the mandible was positioned one full tooth distal to its class I position), which tooth or teeth would contact the maxillary second premolar?
  - a. Mandibular canine and first premolar
  - b. Mandibular first premolar and second premolar
  - c. Mandibular second premolar only
  - d. Mandibular second premolar and first molar
  - e. Mandibular first molar only
6. If this person did not have class I occlusion but had class III occlusion (where the mandible was positioned one full tooth mesial to its class I position), which tooth or teeth would contact the maxillary second premolar?
  - a. Mandibular canine and first premolar
  - b. Mandibular first premolar and second premolar
  - c. Mandibular second premolar only
  - d. Mandibular second premolar and first molar
  - e. Mandibular first molar only

**ANSWERS:** 1—b; 2—c; 3—b; 4—c (recall that the lingual cusps of the maxillary premolars are slightly mesial to the crown midline); 5—b; 6—e

## Critical Thinking

1. It has been determined that Randy Matthews, a 35-year-old stock broker since 2008, has a third molar, tooth No. 1, that occludes before any other teeth in the mouth. Using two columns, one for **signs** (that can be seen) and one for **symptoms** (that are felt), list as many signs and symptoms that *might be* associated with this tooth, especially if Mr. Matthews is a bruxer.

## REFERENCES

1. Ramjford SP, Ash MM Jr. Occlusion. Philadelphia, PA: W.B. Saunders, 1966:142–159.
2. Sicher H, DuBrul EL. Oral anatomy. 7th ed. St. Louis, MO: C. V. Mosby, 1975:174–209.
3. Edwards LF, Gaughran GRL. Concise anatomy. 3rd ed. New York, NY: McGraw-Hill, 1971.
4. Clemente CD, ed. Gray's anatomy of the human body. 30th ed. Philadelphia, PA: Lea & Febiger, 1985.
5. Woelfel JB, Hickey JC, Rinear L. Electromyographic evidence supporting the mandibular hinge axis theory. J Prosthet Dent 1957;7:361–367.
6. Melfi RC. Permar's oral embryology and microscopic anatomy. 8th ed. Philadelphia, PA: Lea & Febiger, 1988:247–257.
7. Ricketts RM. Abnormal function of the temporomandibular joint. Am J Orthod 1955;41:425, 435–441.
8. Williamson EH. Occlusion: understanding or misunderstanding. Angle Orthod 1976;46:86–93.
9. American Dental Association. Temporomandibular disorders. JADA Guide to Dental Health Special Issue 1988; 45–46.
10. Seligman DA, Pullinger AG, Solberg WD. The prevalence of dental attrition and its association with factors of age, gender, occlusion, and TMJ symptomatology. J Dent Res 1988;67:1323–1333.
11. Turell J, Ruiz GH. Normal and abnormal findings in temporomandibular joints in autopsy specimens. J Craniomandibular Disord Facial Oral Pain 1987;1: 257–275.
12. Renner RP. An introduction to dental anatomy and esthetics. Chicago: Quintessence Publishing, 1985:162.
13. Lindblom G. On the anatomy and function of the temporomandibular joint. Acta Odontol Scand 1960;17(Suppl 28):1–287.
14. Gibbs CH, Mahan PE, Mauderli A, et al. Limits of human bite strength. J Prosthet Dent 1986;56:226–240.
15. Guernsey LH. Biting force measurement. Dent Clin North Am 1966;10:286–289.
16. Locker D, Grushka M. The impact of dental and facial pain. J Dent Res 1987;66:1414–1417.
17. Gross A, Gale EN. A prevalence study of the clinical signs associated with mandibular dysfunction. JADA 1983;107:932–936.
18. Williamson EH, Steinke RM, Morse PK, et al. Centric relation: a comparison of muscle determined position and operator guidance. Am J Orthod 1980;77:133–145.
19. Woelfel JB. New device for accurately recording centric relation. J Prosthet Dent 1986;56:716–727.
20. Carroll WJ, Woelfel JB, Huffman RW. Simple application of anterior jig or leaf gauge in routine clinical practice. J Prosthet Dent 1988;59:611–617.
21. Posselt U. The physiology of occlusion and rehabilitation. Philadelphia, PA: F.A. Davis, 1962.
22. Huffman RW. A cusp-fossa equilibration technique using a numbered leaf gauge. J Gnathol 1987;6:23–36.

23. Brose MO, Tanquist RA. The influence of anterior coupling on mandibular movement. *J Prosthet Dent* 1987;57:345–353.
24. Rosner D, Goldberg G. Condylar retruded contact position correlation in dentulous patients. Part I: three-dimensional analysis of condylar registrations. *J Prosthet Dent* 1986;56:230–237.
25. Fenlon MR, Woelfel JB. Condylar position recorded using leaf gauges and specific closure forces. *Intern J Prost* 1993;6(4):402–408.
26. Williamson EH, Woelfel JB, Williams BH. A longitudinal study of rest position and centric occlusion. *Angle Orthod* 1975;45:130–136.
27. Winter CM, Woelfel JB, Igarashi T. Five-year changes in the edentulous mandible as determined on oblique cephalometric radiographs. *J Dent Res* 1974;53(6):1455–1467.
28. Kohno S, Nakano M. The measurement and development of anterior guidance. *J Prosthet Dent* 1987;57:620–630.
29. Barghi N. Clinical evaluation of occlusion. *Tex Dent J* 1978;96(Mar):12–14.
30. O’Leary J, Shanley D, Drake R. Tooth mobility in cuspid-protected and group function occlusions. *J Prosthet Dent* 1972;27(Jan):21–25.
31. Sicher H, DuBrul EL. *Oral anatomy*. 7th ed. St. Louis, MO: C.V. Mosby, 1975:174–209.
32. Woelfel J, Hickey JC, Allison ML. Effect of posterior tooth form on jaw and denture movement. *J Prosthet Dent* 1962;12:922–939.
33. Green CS. A critique of nonconventional treatment concepts and procedures for TMJ disorders. *Comp Cont Educ* 1984;5:848–851.
34. Pierce CJ, Gale EN. A comparison of different treatments for nocturnal bruxism. *J Dent Res* 1988;67:597–601.
35. Young JL. Successful restorative dentistry for the internal derangement patient. *Mo Dent J* 1987;67:21–26.
36. Tan EK, Jankovik J. Treating severe bruxism with botulinum toxin. *J Am Dent Assoc* 2000;131(2):211–216
37. Gerber PE, Lynd LD. Selective serotonin reuptake inhibitor induced movement disorders. *Ann Pharmacother* 1998;32:692–698.
38. Crum RJ, Loiselle RJ. Oral perception and proprioception. A review of the literature and its significance to prosthodontics. *J Prosthet Dent* 1972;28:215–230.
39. Paltaleao JF, Silva-Netto CR, Nunes LJ, et al. Determination of the centric relation. A comparison between the wax prepared method and the Leaf Gauge-Leaf Wafer System. *RGO* 1992;40(5):356–360.
40. Woelfel JB. New device for deprogramming and recording centric jaw relation: the sliding guiding inclined gauge. *Advanced Prosthodontics Worldwide, Proceedings of the World Congress on Prosthodontics, Hiroshima, Japan, September 21–23, 1991:218–219.*
41. Woelfel JB. A new device for mandibular deprogramming and recording centric relation: the sliding guiding inclined gauge. *Protesi occlusionone ATM a cura di Giorgio Vogel FDI* 1991. Milan, Italy: Monduzzi Editore III, 1991: 35–40.
42. Woelfel JB. Sliding and guiding the mandible into the retruded arc without pushing. *Compend Contin Educ Dent* 1991(Sept);12(9):614–624.
43. Woelfel JB. An easy practical method for centric registration. *Jpn J Gnathol* 1994;15(3):125–131.
44. Tsolka P, Woelfel JB, Man WK, et al. A laboratory assessment of recording reliability and analysis of the K6 diagnostic system. *J Craniomandib Disord Facial Oral Pain* 1992;6:273–280.
45. Donegan SJ, Carr AB, Christensen LV, et al. An electromyographic study of aspects of “deprogramming” of human jaw muscles. *J Oral Rehabil* 1990;17:509–518.
46. Carr AB, Donegan SJ, Christensen LV, et al. An electrognathographic study of aspects of “deprogramming” human jaw muscles. *J Oral Rehabil* 1991;18:143–148.
47. Christensen LV, Carr AB, Donegan SJ, Ziebert GJ. Observation on the motor control of brief teeth clenching in man. *J Oral Rehabil* 1991;18(1):15–29.
48. Kruger L, Michel F. A single neuron analysis of buccal cavity representation in the sensory trigeminal complex of the cat. *Arch Oral Biol* 1962;7:491–503.
49. Kawamura Y, Nishiyama T. Projection of dental afferent impulses to the trigeminal nuclei of the cat. *Jpn J Physiol* 1966;16:584–597.
50. Jerge CR. Comments on the innervation of the teeth. *Dent Clin North Am* 1965(3);117–127.

#### GENERAL REFERENCES

- The glossary of prosthodontic terms. *J Prosthet Dent* 2005;94(1):10–88.  
 MayoClinic.com; <http://mayoclinic.com/invoke.cfm?id=DS00337>



## Original Research Data

Interesting research findings and facts related to topics found within this chapter were referenced using superscript letter throughout the chapter like this (data<sup>A</sup>), and are described here.

- A. Some evidence indicates that people with severe overjet exhibit more crackling or grating noise in their joint (called crepitus or crepitation) because of the frequent necessity to protrude the jaw considerably forward in order to properly enunciate and to incise.
- B. People with a class II, division 1 malocclusion often have a long face, a narrow maxillary arch with high palate, diminished muscle tone in the upper lip, and an overactive lower lip.<sup>12</sup>
- C. People with class II, division 2 malocclusion often exhibit unique oral traits including a short, wide face, square arch, severe anteroposterior curve (of Spee), anterior crowding, and well-developed chin musculature.<sup>12</sup>
- D. In addition to a massive mandible, people with class III occlusion have a long narrow face, a tapered upper arch with a high vaulted palate, increased activity of their upper lip, and decreased activity of their lower lip. Crepitus is not common with class III malocclusion since little, if any, protrusion is required to clearly enunciate or to incise.
- E. From eight unrelated surveys of the prevalence of malocclusion treated by orthodontists on 21,328 children, ages 6 to 18, in the United States between 1951 and 1971, Dr. Woelfel averaged the results and derived the following information:
- 71.7% had malocclusion (range: 31 to 95%)
  - 28.3% had acceptable occlusion
- F. Even in the highest order of apes (chimpanzee), the mandible can only drop open in a simple hinge movement.
- G. The maximum separation of the incisors for a pure hinge opening (maximum hinge opening in Fig. 9-20) averages only 22.4 mm or 44% of maximum opening on 352 subjects (*Table 9-4*).
- H. The frequency of crepitation among 1099 dental hygiene and dental students was presented in *Table 9-5*. Over one third of these students had some crepitus while opening widely; it was slightly more prevalent on the right side than on the left side and was more common in women than in men.
- I. An exhaustive study on the TMJ by Turell includes color pictures of many human TMJs—some healthy, some with displaced discs, and others diseased with osteoarthritis.<sup>11</sup> This project involved dissection and analysis of joints from 100 cadavers (dead for <12 hours). Joint conditions were found to be directly related to existing occlusal relationships. Older people with their teeth and natural occlusion had normal joints. Internal joint changes were determined to be more common in the elderly only because of occlusal interferences, loss of teeth, heavy attrition, and uncorrected malposition of teeth. It was concluded that many of the alterations seen in osteoarthritic TMJs had been caused by abnormal, heavy forces within the

Table 9-4

### TERMINAL HINGE (ROTARY) OPENING CAPABILITY OF 352 DENTAL HYGIENE STUDENTS\*

TYPE OF JAW OPENING	AVERAGE	RANGE	CONDYLAR ROTATION (AVERAGE IN DEGREES)	RANGE OF CONDYLAR ROTATION (IN DEGREES)
Maximum opening at incisors	51.0 ± 6.3 mm	27.0–68.5 mm	NA**	NA**
Hinge opening at incisors	22.4 ± 5.7 mm	9.5–40.5 mm	12.7	4.4–24.2
Percentage of maximum incisor opening	44.0%	18.9–50.6%	—	—

\*\*Unknown because translation has taken place in upper compartment.

\*Results obtained by Dr. Woelfel (1980–1986).

**Table 9-5 PREVALENCE OF CREPITUS DURING MAXIMUM OPENING\***

	NONE (%)	BOTH SIDES (%)	RIGHT SIDE (%)	LEFT SIDE (%)	ONE SIDE (R OR L) (%)
594 dental hygiene students	52.0	13.3	18.2	16.8	35.0
505 dental students	72.0	4.2	15.9	7.9	23.8
Percentage of all 1099 students	61.2	9.1	17.1	12.7	29.8

\*Determinations by Dr. Woelfel, 1970–1986. More than 20% of these professional students had or were undergoing orthodontic treatment.

joints from poor occlusion.<sup>11</sup> Try to find a copy of reference<sup>13</sup> in your library. It has a glossary, a review of significant research on the TMJ, and 488 references, and contains original research on the joints of 318 oral rehabilitation patients compared to those of 61 other patients. It is a fascinating treatise.

- J. Posselt found the distance between centric relation and MIP to average  $1.25 \pm 1$  mm with a range of 0.25 to 2.55 mm.<sup>21</sup>
- K. The average incisal guidance angle for 1114 dental hygiene and dental students is  $50^\circ$  as shown in Table 9-6. Many of these people did not have ideal class I occlusion.
- L. The average maximum forward protrusion for 1114 young men and women was 8.3 mm with a range from 2.5 to 16.0 mm (Table 9-3). These extremes included a very tight TMJ compartment that exhibited the smallest protrusion, and a very large jaw with loose ligament attachments that exhibited 16 mm protrusion.
- M. The maximum average movement to either the right or left side was about 8.1 mm. Therefore, the entire lateral movement from right to left averaged 16.2 mm compared to an average forward protrusion of only 8.3 mm (Table 9-3).
- N. The nonworking side mandibular condyle moves medially, downward, and forward perhaps 5 to 12 mm. As seen in Table 9-7, of 342 dental hygiene students examined, 26.8% had nonworking side interferences in at least one side.
- O. **Group function** is much different from disocclusion because multiple posterior teeth contact along with the canines on the working side.<sup>1,8</sup> As seen in Table 9-6, the average canine guidance angle was a little steeper (at  $56^\circ$  and  $57^\circ$ ) than the anterior guidance (at  $50^\circ$ ). To have a canine-protected articulation where the overlap of the canine teeth disengages the posterior teeth during excursive movements of the mandible, it is usually necessary to have a canine angle of over  $60^\circ$ . Dr. Woelfel found canine-protected articulation with posterior disocclusion in 60.2% of the natural dentitions of dental hygiene students (Table 9-7).
- P. **Complete Denture occlusion:** The desirable type of relationship in a patient who has no teeth and must wear a set of complete dentures is bilateral balanced occlusion. This occurs when all of the posterior teeth contact on the working side and one or more teeth on the balancing side contact simultaneously. With complete dentures, the bilateral balancing contacts help to prevent the dentures from tipping and coming loose. It is considered undesirable for a patient with natural teeth, however, to have any tooth contact on the nonworking side.
- Q. There is a pause of about 0.16 second (*silent period*) between chewing into MIP and commencing the net chewing stroke. The duration of each chewing cycle varies from 0.7 to 1.2 seconds in most people.<sup>32</sup>

**Table 9-6 INCISAL AND CANINE GUIDANCE ANGLES OF 1114 STUDENTS**

	INCISAL ANGLE (CENTRAL INCISORS)	CANINE RISE ANGLE RIGHT SIDE	LEFT SIDE
Average	$50^\circ$	$56^\circ$	$57^\circ$
Low	$-26^\circ$	$0^\circ$	$0^\circ$
High	$86^\circ$	$84.2^\circ$	$83^\circ$



**Table 9-7** ECCENTRIC OCCLUSAL CONTACTS OF 342 HYGIENE STUDENTS

	CONDITION	IN RIGHT QUADRANT	IN LEFT QUADRANT	TOTAL	PERCENT
WORKING SIDE TOOTH RELATIONSHIPS	Canine-protected articulation	207	205	412	60.2
	Group function	135	137	272	39.8
NONWORKING SIDE TOOTH RELATIONSHIPS	No contact	250	251	501	73.2
	Interference	92	91	183	26.8
	CONDITION	STUDENTS	PERCENT		
	Bilateral canine-protected articulation without nonworking side interference*	129	37.7		
	Bilateral canine-protected articulation with nonworking side interference	29	8.5		
	Bilateral croup function without nonworking side interference	58	17.0		
	Bilateral group function articulation with nonworking side interference	34	9.9		
	Different relationships on each side	92	26.9		

\*Considered to be the best type of relationship.

Survey conducted by Dr. Woelfel and his carefully trained staff. He personally reexamined suspicious recordings for their validity (1980–1986).

More than 30% of these 342 dental hygiene students had undergone orthodontic treatment.

- R. Several animal studies using cats have found that canines are more richly represented by neuron units (mechanoreceptors in the periodontal ligament) than any other teeth.<sup>38,48,49</sup> Another study reported that the periodontal ligament proprioceptors were directionally sensitive to forces of a just few grams.<sup>50</sup> Such evidence lends credence to the canine protection theory.<sup>8,23,28</sup>
- S. Natural dentition chewing forces are well below maximum bite force on average foods, ranging from

0.5 to 33 pounds, seldom exceeding 100 pounds.<sup>15</sup> The human jaw muscles are very powerful, however. The largest maximum bite strength ever recorded was that of a 37-year-old man who maintained a force of 975 pounds for 2 seconds.<sup>14</sup> The average maximum biting force for 20 subjects was 192 pounds (range: 55 to 280 pounds).

## Treating Decayed, Broken, and Missing Teeth

- I. Overview of carious lesions
- II. Operative dentistry, restorative dentistry, and prosthodontics: definitions
- III. Dental materials used to restore teeth
- IV. Principles of cavity preparation
  - A. Establish an outline form
  - B. Provide retention form
  - C. Remove caries and treat the pulp
  - D. Finish the preparation walls
  - E. Clean the preparation
  - F. Final evaluation of the preparation
- V. Restoring each class of caries
  - A. Class I caries
  - B. Class II caries
  - C. Class III caries
  - D. Class IV caries
  - E. Class V caries
  - F. Class VI type of dental caries
- VI. Restoring large tooth defects and tooth replacement

### OBJECTIVES

This chapter is designed to prepare the learner to perform the following:

- Describe the process of caries formation and the importance of prevention.
- List types of restorations involved in operative dentistry, restorative dentistry, and prosthodontics.
- Classify dental caries according to pit and fissure versus smooth surface, and describe (and sketch) the pattern of spread of each within enamel and once it reaches dentin.
- List and describe characteristics of commonly used restorative materials.
- List and describe the principles of cavity preparation.
- Define and identify root caries.
- Describe and identify each G.V. Black class of dental caries clinically and radiographically.
- Describe the indications for restoring a tooth for each class of caries.
- For each class of caries, describe the unique application of the principles of cavity preparation dependent upon the material used.
- For each class of caries, define terms used to describe cavity walls, cavosurfaces, line angles, and point angles.
- Describe and identify the types of restorations used to restore large tooth defects.
- Describe and identify the restorations used to replace lost teeth.

### SECTION I

### OVERVIEW OF CARIOUS LESIONS

**T**ooth destruction can occur from dental decay (caries), attrition (from tooth-to-tooth wear), abrasion (from improper tooth brushing with abrasive toothpaste), erosion (from acids), fracture, and the breakdown of old restorations. **Dental caries** [CARE eez] (always plural, never a carie), known more commonly as tooth decay, is the most common cause of tooth destruction. Caries (which literally means “rotten”) results from the **demineralization** of mineralized tooth structures, that is, the loss of minerals from enamel, dentin, and cementum. This demineralization process begins when specific *bacteria* firmly adhere to teeth in a layer called **dental plaque** (or **biofilm**) and are exposed to certain *carbohydrates* in the diet over

an extended period of time. These carbohydrates react with the bacteria to form *acids* (such as lactic acid) that act upon hard tooth structure, resulting in the loss of minerals. As minerals are lost, the affected tooth structure becomes “softer,” and as the process continues, a hole or cavity can form. *Streptococcus mutans* and *lactobacilli* are two types of **bacteria** known to contribute to the caries process. **Sugar-containing food**, such as candy, honey, pastries, and especially nondiet, sugar-containing soft drinks, contribute to acid formation that can destroy mineralized tooth structure.<sup>1</sup>

Demineralization can be reduced if plaque is removed frequently through good oral hygiene measures, or if sweets in the diet are limited. The process can actually

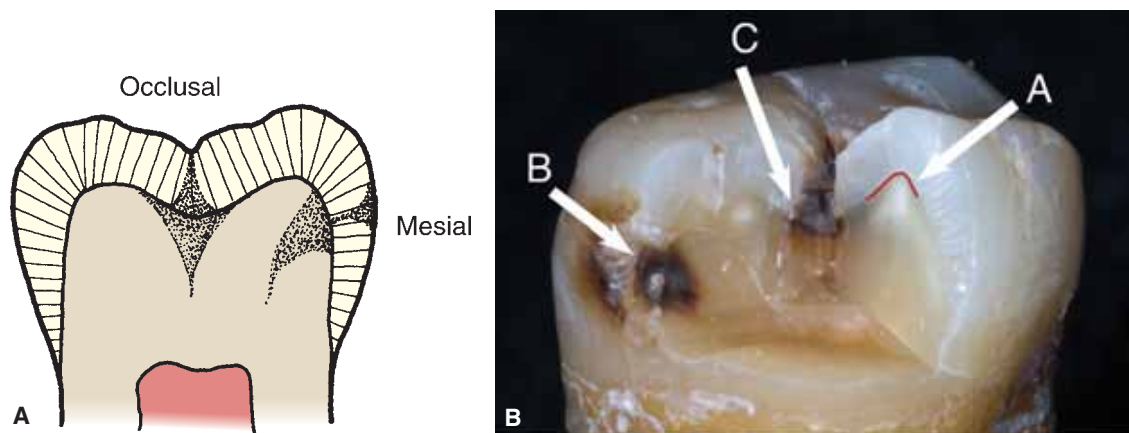
be reversed if minerals, especially calcium in healthy saliva, and fluoride, are available for uptake (**remineralization**) into the softer demineralized tooth. The *tug-of-war* between demineralization and remineralization is constant and is the basis for prevention methods that are applied and taught by dental professionals.

Patient education and preventive treatment are important aspects of dental patient care. Prevention and treatment should be based on personalized risk-based assessment of each patient's caries history, which includes their history of fluoride use, their salivary flow rate, and the frequency of sugar uptake (especially snacks).<sup>2,3</sup> **Fluoride** [FLOOR ide] applied to teeth in appropriate concentrations has been shown to reduce dental caries incidence because it increases the tooth's resistance to breakdown by caries-forming acids. Therefore, caries prevention includes daily use of fluoride-containing paste and fluoride-containing mouthwashes (either prescription or over the counter), as well as office-applied fluorides. Further, since saliva is normally rich in minerals like calcium, healthy **saliva flow** improves remineralization. When saliva flow is reduced (from damage to the salivary glands due to radiation therapy, or as a side effect of certain medications), teeth are more susceptible to tooth decay. Artificial saliva or sugarless chewing gum (which stimulates saliva flow) can be used to alleviate this problem.

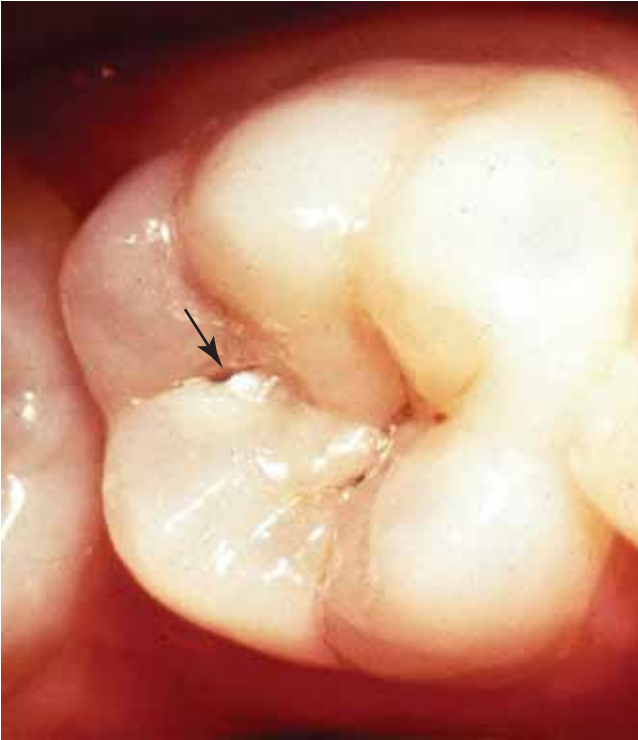Finally, patients must be **educated** to reduce the amount and frequency of carbohydrates in the diet and

to remove harmful bacteria off of the teeth. Since more acids form when teeth are exposed *frequently* to snacks, *frequent snacking must be curtailed*. Frequent intake of carbonated, nondiet soft drinks can be especially damaging since these drinks not only contain sugar but are also mildly acidic due to the carbonation. Since bacteria in plaque can, over time, begin to form enough acid to begin destroying teeth, it is important to remove all plaque frequently and thoroughly.

In a 1979 to 1980 survey representing 45.3 million U.S. school children between the ages of 5 and 17 years, the estimated prevalence of breakdown in permanent dentition was 4.77 decayed, missing, or filled surfaces per child.<sup>4</sup> Comparing data from two studies conducted for the Centers for Disease Control and Prevention, the number of carious permanent teeth (both treated and untreated) in children from 6 to 18 years old decreased by 57% from 1971–1974 through 1988–1994 (decreasing from 4.44 to 1.9 carious teeth).<sup>5</sup> These studies also showed a 40% decline in the number of primary teeth with caries in two to ten year olds (from 2.29 to 1.38). These and other reports have shown a worldwide decrease in the incidence of coronal caries, especially in children and adolescents, ranging from 10 to 60% depending on the article cited. However, the number of adults older than 65 is expected to double by 2025, and people are keeping their teeth longer (53% of persons older than 65 still have at least 20 natural teeth).<sup>6</sup> Further, the prevalence of root caries



**FIGURE 10-1.** Pattern and location of pit and fissure and smooth surface caries. **A.** Drawing of a cross section of a mandibular molar showing the usual pattern of spreading decay. The occlusal lesion (class I, pit and fissure) is small externally, widening toward the depth of the fissure as it approaches the dentinoenamel junction (DEJ). Once within dentin, the caries spreads out laterally, as well as progresses toward the pulp. The mesial lesion (class II, smooth surface) is broad externally, narrowing toward the DEJ. Once within dentin, this lesion spreads out laterally (like the class I) as well as progressing toward the pulp. **B.** Spread pattern of caries in enamel and dentin. The red line labeled “A” follows the DEJ of one cusp. The arrow labeled “B” points to caries that began on the smooth proximal surface of the tooth enamel (class II caries) showing that when it reaches dentin, it spreads out along the DEJ. The arrow labeled “C” points to pit and fissure (class I) caries, which began in the occlusal pit (almost hidden from view clinically) showing that once it reaches dentin, it also spreads out at the DEJ.



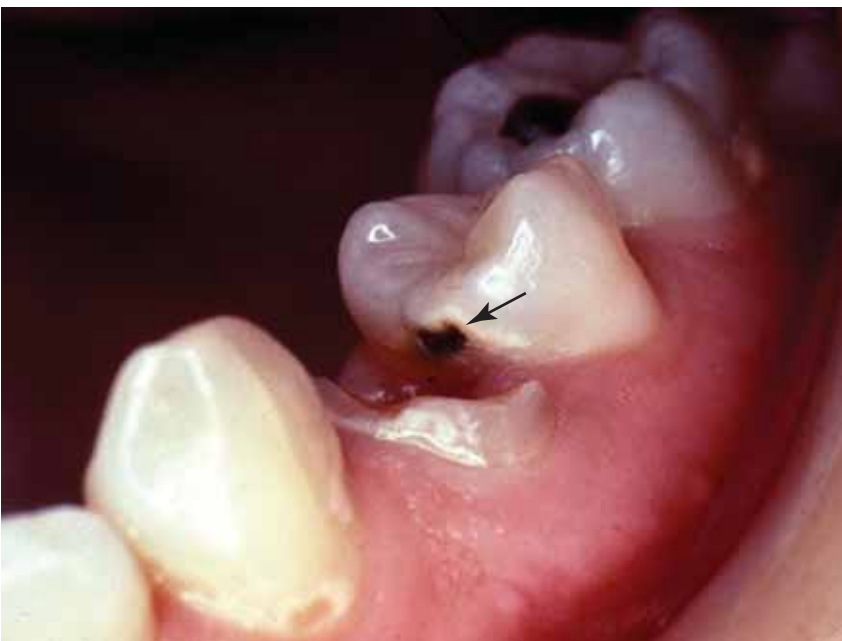**FIGURE 10-2.** Pit and fissure caries (at arrow) visible as stained grooves and adjacent demineralization seen as a chalky whiteness surrounding the stained pit.

in the elderly is increasing, with one study reporting 75% of elderly women with clinically detectable root caries.<sup>7,8</sup> Therefore, the restoration of damaged teeth (from caries and other reasons) will continue to be a

part of the practice of general dentistry for some time to come. Additionally, with improvements in the properties of contemporary esthetic restorative materials, the decline in caries rate is being offset by the increased number of patients who ask for dental procedures that improve esthetics.

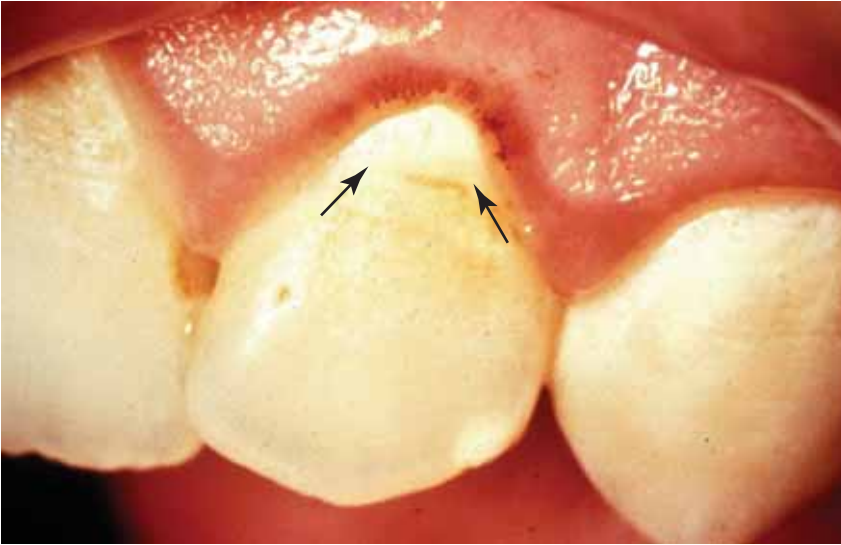
There are two broad classifications of tooth decay based on the anatomy of the tooth surface involved: pit and fissure, and smooth surface. Caries prone **pit and fissures** form when enamel lobes fuse incompletely during tooth development. These pits and fissures are often nearly impossible to keep clean. Note the deep occlusal fissures on the occlusal surfaces of a molar in *Fig. 10-1*. Remember that pits and fissures are located most often on the occlusal surfaces of posterior teeth (molars and premolars), as well as on the lingual surface of maxillary molars, on the buccal surface of mandibular molars, and in the lingual fossae of maxillary incisors, especially lateral incisors. A small pit and fissure lesion may be almost undetectable externally (*Fig. 10-2*), but as it progresses deeper, the decay widens within the fissure as it approaches the dentinoenamel junction (DEJ). Then, when it reaches the DEJ, it spreads faster because dentin is less mineralized than enamel, especially near the DEJ (seen on the occlusal surfaces of molars in *Fig. 10-1A* and *B*).

In contrast to pit and fissure caries, **smooth surface carious lesions** occur on the smooth surfaces of the anatomic crown of a tooth in locations that are not readily accessible to the natural cleansing action of the lips, cheeks, and tongue. These areas include the



**FIGURE 10-3.** Smooth surface caries on the mesial surface of a mandibular second premolar (arrow) is clearly visible because the adjacent first premolar was broken off at the cervical line. Notice the location of the lesion (just cervical to where the proximal contact had been) and the color: a darkly stained hole surrounded by discoloration and chalkiness. This lesion would have been difficult to detect clinically when the adjacent first premolar was intact. Bitewing radiographs are most useful for confirming these lesions.





**FIGURE 10-4.** Smooth surface demineralization appearing as chalky white area (at arrows) seen in the cervical third of a maxillary lateral incisor is evidence of the first stages of dental caries. If this demineralization continued and did not reverse itself (through excellent oral hygiene, diet, and use of topical fluoride), this area could develop a cavitation (hole) that would need to be restored. Also notice the inflammation of the adjacent gingiva (gingivitis), which is also caused by bacterial plaque.

inaccessible proximal surfaces of teeth just cervical to the proximal contact (Fig. 10-3) and on the facial and lingual crown surfaces in the gingival one third, cervical to the crest of curvature of the crown as seen in Figure 10-4. The pattern of spread within enamel for smooth surface caries differs from that of pit and fissure caries since it begins near the enamel surface as a relatively broad area of destruction but narrows as it progresses more deeply toward the DEJ due to the convergence of enamel rods. Once it reaches dentin, however, it spreads out wider at the DEJ, just like pit and fissure caries (seen on the smooth surfaces on the molars in Fig. 10-1A and B).

**Root surface caries** is another type of smooth surface caries that begins when cementum (which is much less mineralized than enamel or dentin) is exposed to caries-forming plaque. Cementum is exposed frequently in persons with periodontal disease, or in older persons who have had gingival recession. The potential for root caries is increased greatly in persons with decreased saliva flow. Root caries is a softening, destructive process that *may not* require a restoration if there is only minimal involvement.<sup>9</sup> Treatment in these cases can include polishing the root, applying fluoride (topical or fluoride-containing varnishes), and keeping the roots clean through excellent oral hygiene.

## SECTION II

### OPERATIVE DENTISTRY, RESTORATIVE DENTISTRY, AND PROSTHODONTICS: DEFINITIONS

There are several terms that define treatment methods used to restore carious, broken, or missing teeth. These terms can be used to define courses within a dental curriculum and are used in the literature to categorize types of dental treatments. The first term, **operative dentistry**, includes the art and science of the diagnosis, treatment, and prognosis of defects in teeth that require restorations that *do not cover* the entire tooth crown. Most of this chapter is devoted to the concepts and cavity preparation terminology applied to conservative restorations placed when treating small carious lesions that are confined to enamel or have progressed only slightly deeper than the DEJ.

When tooth destruction increases in size, larger restorations that cover (and protect) all or most of the

occlusal surface may be a more appropriate restoration of choice. These larger restorations often surround and cover all or part of the exposed tooth and include crowns (also known by many as “caps”) or onlays. The goal of the dentist when placing both large and small tooth restorations is to reproduce proper tooth form, function, and esthetics while maintaining a harmonious relationship with the adjacent hard and soft tissues, all of which enhances the general health and welfare of the patient.<sup>10</sup>

**Restorative dentistry** is a term used to describe the phase of clinical dentistry that involves the restoration of lost tooth structure of individual teeth and/or replacement of lost or missing teeth with the ultimate goal of reestablishing a healthy, functioning, and comfortable dentition. **Prosthodontics** [pros tha

DON tiks], on the other hand, is defined as a phase of dentistry that includes the treatment of patients with missing or deficient teeth. (A **prosthesis** [pros THEE sis] is defined as an artificial replacement of a missing part of the human body.) **Fixed prosthodontics** is the branch of prosthodontics concerned with the replacement and/or restoration of teeth with parts that *cannot* be readily removed from the mouth. An example is a dental bridge (more appropriately called a fixed dental prosthesis) where artificial teeth are cemented onto

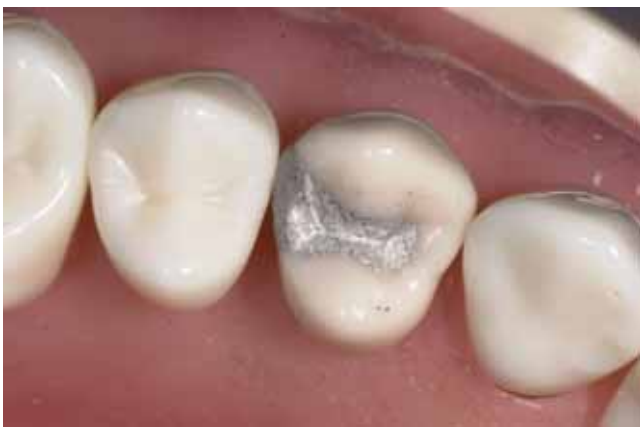adjacent teeth in the mouth. **Removable prosthodontics** involves the replacement of teeth with devices that *can be* readily removed. Examples include a complete denture (also called a complete removable dental prosthesis but known to the public as false teeth or a denture) or a removable partial denture prosthesis (called a partial denture), both of which can and should be removed often for easy cleaning and to maintain tissue health. These prostheses will be described in the last section of this chapter.

### SECTION III

### DENTAL MATERIALS USED TO RESTORE TEETH

The success of decay prevention techniques taught in dental offices and presented in the media is an important factor for reducing the number and size of restorations being placed in the adult population. Susceptible smooth surfaces can be protected by the application of fluoride and fluoride varnish, which strengthens the enamel and can even reverse early bacterial damage in lesions on smooth surfaces. Also, susceptible pits and fissures can be treated with sealants before the caries process has begun. These efforts reduce the number of invasive (surgical or cutting) procedures.

When it is deemed necessary to use surgical techniques to restore small carious defects, conservative tooth preparations are most often filled with dental amalgam, composite resin, and glass ionomer or resin ionomer. The materials of choice for restoring larger defects that require protection of thin remaining tooth structure include cast gold or semiprecious or nonprecious metals, and porcelain.



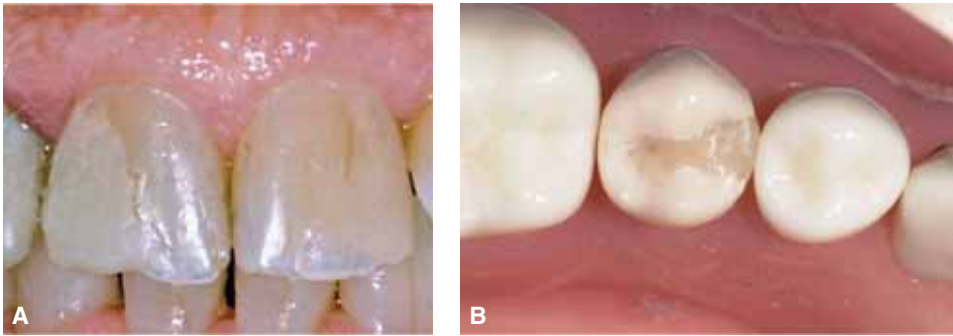
**FIGURE 10-5.** Amalgam restoration on a maxillary first premolar. It can be abbreviated No. 5 DO-A.

#### A. AMALGAM

**Dental amalgam** has been a widely used restorative material owing to its ease of placement and relatively low cost. It is silver in color and is condensed (packed) into a preparation in successive small increments that, within several hours, becomes a hard mass that can withstand chewing forces. Therefore, amalgam is often used for restorations on the chewing (or occlusal) surfaces of posterior teeth and to restore posterior proximal contacts, but when esthetics is not a factor (Fig. 10-5).

#### B. ESTHETIC RESTORATIVE MATERIALS

Esthetic restorative materials such as composite resin, glass ionomer, and resin ionomer are being increasingly used due to patients' demands for esthetic restorations. **Composite resin** is a tooth-colored restorative material that is applied into a preparation in a dough-like consistency. It hardens quickly when exposed to a light source. Due to initial concerns about the strength and abrasion resistance of composite resins,<sup>11,12</sup> it was historically used primarily for restoring the proximal surfaces of anterior teeth and the facial surfaces of teeth on which esthetics was a chief concern (Fig. 10-6A). Newer generations of esthetic restorative materials perform better in posterior areas, so composite is replacing amalgam as the restoration of choice for small class I and II lesions (Fig. 10-6B). One longitudinal study rated composite restorations after 10 years (using a U.S. Public Health system of evaluation) to be over 90% satisfactory for color stability, surface smoothness, anatomic form, lack of recurrent caries, and pulp response.<sup>13</sup> Only marginal adaptation was scored below 90%, with a score of 81%. With recent physical property improvements,<sup>14</sup> a new generation of dentin bonding agents that can



**FIGURE 10-6.** Composite resin restorations. **A.** A composite resin restoration on a maxillary central incisor, which can be abbreviated No. 8 DIFLC. **B.** A composite resin restoration on a mandibular second premolar, which can be abbreviated No. 20 MOC.

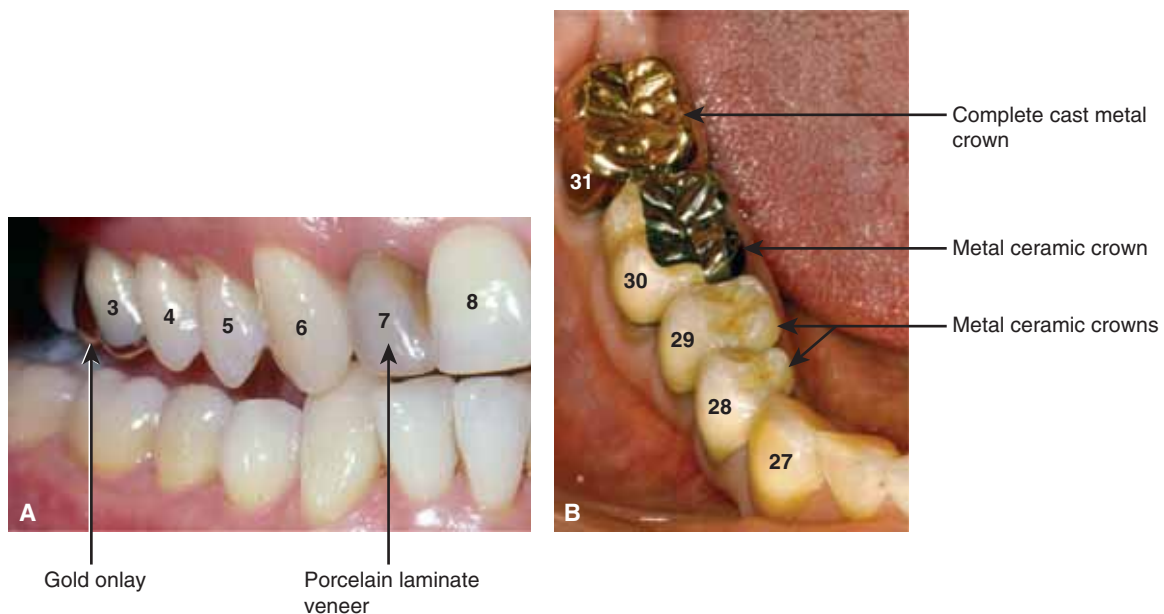
etch enamel and dentin simultaneously,<sup>15</sup> and a new generation of packable composite-based resins, these esthetic restoration materials are being used more frequently.

When esthetics is a factor, tooth-colored composite resin restorations can also be constructed outside the mouth and then cemented in place. Also, when there are large cavities, an adhesive (bonded) indirect composite restoration that has adequate wear resistance can be used to strengthen the remaining tooth.<sup>10</sup>

Glass ionomer and related materials such as resin-modified glass ionomer are recommended for the treatment of caries on the root surface or over erosion lesions.<sup>16</sup> These materials bond chemically to dentin, are reasonably esthetic, and contain fluoride, which protects the tooth against future caries.

### C. CAST METAL RESTORATIONS

When the tooth structure is weak and needs to be protected from occlusal forces, a cast restoration is often the treatment of choice. Cast gold or semiprecious metals can be used for constructing onlays (restorations, which cover cusp tips) or complete cast crowns (which cover the entire tooth crown). A gold onlay is seen on tooth No. 3 in *Figure 10-7A*, and a **complete cast metal crown** is seen on tooth No. 31 in *Figure 10-7B*. These cast restorations are constructed on a precise dental stone reproduction of the individual prepared tooth called a **die** (seen later in Fig. 10-21). Since they are constructed outside of the mouth, cast metal restorations can be contoured more perfectly than an amalgam restoration that must be contoured in the mouth. Further, since cast metal



**FIGURE 10-7.** Cast metal and ceramic (porcelain) restorations. **A.** Tooth No. 3 has a cast **gold onlay** that covers the entire occlusal surface. It can be abbreviated No. 3 MOD On. Tooth No. 7 has a **porcelain laminate veneer**. The veneer has reasonable contours but the shade is too dark. **B.** Tooth No. 31 has a **complete cast metal (gold) crown**. Tooth No. 30 has a **metal ceramic restoration** (porcelain fused to metal crown). Both mandibular premolars (No. 28 and No. 29) also have **metal ceramic crowns** (the metal is not visible). (Photos courtesy of Dr. Julie Holloway.)

is stronger than amalgam, it can be used to restore the entire occlusal, stress-bearing surface of a tooth using a thinner layer than amalgam, and therefore requiring less occlusal tooth reduction to make room for the restoration. Finally, cast metal restorations have better marginal stability over time. However, since considerably more time is required to restore a tooth with a cast restoration (including the laboratory procedures outside of the mouth) than for composite resin or amalgam restorations that are placed the same day the tooth is prepared, cast restorations are more expensive for the patient.

#### D. PORCELAIN: INLAYS, ONLAYS, AND VENEERS

Indirect (i.e., constructed outside of the mouth and cemented) porcelain (ceramic) restorations are esthetic

alternatives to cast metal inlays and onlays due to advanced processing methods and bonding techniques that have improved fit.<sup>17,18</sup> Advances are also occurring in the generation of these restorations using a computer.<sup>19</sup> **Porcelain veneers** are conservative restorations that require minimal or no tooth reduction in order to veneer the labial surface of an anterior tooth in order to improve esthetics (seen on tooth No. 7 in Fig. 10-7A). Fees for a veneer are generally less than for a crown with a porcelain veneer. Porcelain can also be used to construct **all ceramic restorations** (crowns) (seen later in Fig. 10-45) or **metal ceramic restorations** or crowns where porcelain is fused to underlying metal in order to provide an esthetic result (teeth numbers 28, 29, and 30 in Fig. 10-7B).

## SECTION IV

## PRINCIPLES OF CAVITY PREPARATION

Basic principles of cavity preparation were developed by Dr. G.V. Black in the early 1900s and are uniquely applied to each class of caries and type of restorative material. Today, the application of his principles has been modified due to the introduction of new dental restorative materials that were not available in his day. A dentist still needs to consider each principle when preparing a tooth for a conservative operative restoration.

### A. ESTABLISH AN OUTLINE FORM

The **outline form** of a preparation is the external shape of the preparation where prepared tooth meets unprepared tooth. It is developed by removing the least amount of tooth structure possible, yet adhering to the following principles:

#### 1. EXTEND THE PREPARATION TO SOUND ENAMEL

The dentist enlarges the preparation outline so that it extends to enamel that has no signs of active decay. Also, when the dentist ends the preparation on enamel margins, the enamel must be able to withstand the forces required when placing the restoration, and the forces applied during tooth function. In many cases, this involves extending the preparation to enamel that is supported by, or resting on, sound dentin that is not undermined by the spread of caries within the dentin. Since enamel is brittle, if it is not sufficiently supported by sound dentin and/or bonding techniques,

the unsupported, brittle enamel rods may fracture, leaving a gap between the tooth and the restorative material.

#### 2. EXTEND THE PREPARATION FOR PREVENTION

The dentist evaluates the need to enlarge the preparation within enamel beyond the specific area of decay in order to include adjacent tooth structure felt to be prone to the development of future decay. For example, when treating a carious pit and fissure lesion, it may be advisable to include adjacent deep pits and fissures thought to be caries prone, even though they have not yet become carious. Similarly, when developing the cavity preparation for smooth surface carious lesions, the outline of the preparation may be extended to include adjacent smooth surface areas likely to become carious.

The dentist must determine whether or not to extend the outline based on a risk assessment of that patient. Over the past 35 years, there has been a tremendous increase in the use of fluoride (in community water, toothpaste, rinses, and topical applications applied periodically in the dental office), as well as improved efforts by dental professionals to educate the population in prevention techniques. Therefore, the need for preventive extension on smooth surface lesions must be weighed against the possibility that excellent hygiene and fluoride could stop or even reverse the decay process, especially if the decay has not progressed too far.



The degree of extension should be based on factors such as the age of the patient (younger enamel is more susceptible to caries than mature enamel), the person's rate of caries activity, personal oral hygiene, and dietary habits. For example, extension for prevention for a tooth preparation on a younger patient with multiple areas of active decay, poor oral hygiene, and frequent intake of high-sugar snacks and sugar-containing carbonated beverages *who is unwilling or unable to change* is more appropriate than it would be in an older patient with a lower caries rate, better eating habits, and good or improving oral hygiene.

### 3. PROVIDE ADEQUATE ACCESS


A restoration outline must be large enough for the dentist to ensure that all carious tooth structure has been removed and that instruments required to insert the filling material will fit. A small, narrow initial cut through the enamel might not permit the dentist to confirm the removal of all caries that may have spread laterally at the DEJ. Further, even when the removal of all caries can be verified visually or by probing, the initial preparation might be too small to place the restoration without voids.

### 4. PROVIDE RESISTANCE FORM


The dentist must design a preparation to ensure room for an adequate thickness of *restorative material* for strength, and sufficient remaining solid *tooth structure* to withstand or *resist* occlusal forces. This is known as **resistance form**. If the preparation depth is inadequate for the material of choice to withstand occlusal forces, the restoration could break. If the remaining tooth structure is too thin or undermined, it could fracture.

## B. PROVIDE RETENTION FORM

**Retention form** is the design of a preparation that prevents the restoration from falling out. The methods for providing retention differ depending on the restorative material and on the location of the carious lesion. *Retention for amalgam restorations* is provided by internal retentive features, such as retentive grooves, and by the convergence of some preparation walls. *Retention for composite resin restorations* is provided by **acid etching** the enamel to produce microscopic irregularities (minute undercuts) on the surface. Then, a first layer of **flowable resin** (bonding agent) can flow into the irregularities forming retentive **resin tags** that, when hardened, *mechanically* lock into the microscopic retentive features of the etched enamel (Fig. 10-8). Layers of the stronger composite resin can subsequently be



A



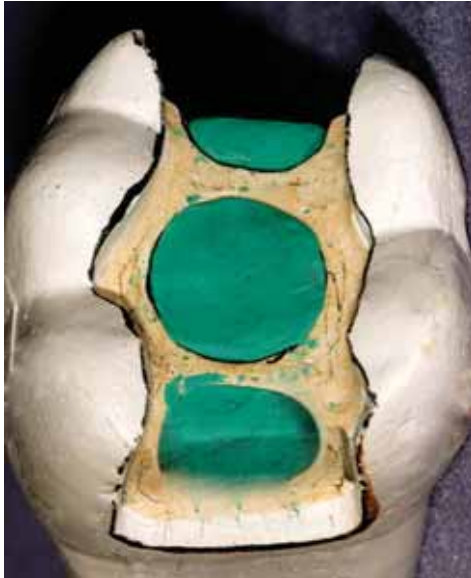
B

**FIGURE 10-8.** The effect of etching enamel. **A.** Magnified view of a nonetched enamel surface (3260 times bigger). **B.** Magnified view of an etched enamel surface (3600 times bigger) after application of 50% phosphoric acid. This etched surface allows the resin bonding agent of the composite systems to flow into the irregular microscopic undercuts, thus affording mechanical retention for the material. (Courtesy of Dr. Ruth Paulson, Ohio State University.)

*chemically* bonded to the initial flowable resin layer to complete the restoration. When using newer adhesive agents, additional retention is gained by chemical bonds formed between tooth and resin.

## C. REMOVE CARIES AND TREAT THE PULP

All principles of the cavity preparation described up to this point assume that caries has spread just beyond the DEJ into dentin. The dentist usually prepares the outline form and retention for a cavity preparation to a depth just beyond the DEJ with a high-speed dental handpiece using carbide or diamond burs that cut quickly, minimizing the potentially damaging heat by



**FIGURE 10-9.** Model of an amalgam preparation illustrating three areas of the axial and pulpal walls that had caries deeper than ideal that were filled with a **cement base** (shown in green) before the amalgam would be placed.

use of an effective water coolant spray. When removing carious lesions that have progressed deeper into dentin, the dentist uses slowly rotating round burs in slow-speed handpieces, or hand instruments. The slow-speed handpiece, or hand instruments, permit the dentist to differentiate between the softer carious dentin and the harder healthy or noncarious dentin.

## SECTION V

## RESTORING EACH CLASS OF CARIES

In 1908, Dr. G.V. Black developed a comprehensive method for classifying carious lesions that has been useful when describing specific principles of cavity preparation.<sup>20</sup> The original classifications were G.V. Black classes I, II, III, IV, and V. All pit and fissure type lesions are class I, whereas class II, III, IV, and V caries are all smooth surface-type lesions. The five classifications of decay devised and published by Dr. G.V. Black in 1908 are still appropriate to consider, although the principles of cavity preparation are now applied uniquely for each class of decay, and for each new restorative material. Successful cavity preparations for restorative materials such as dental amalgam, composite, resin, or cast metal are designed to allow placement and maintenance of each restorative material and, at the same time, to ensure the preservation of remaining tooth structure.

When caries extends close to the pulp, it may be advisable to protect the vital tissues of the tooth (odontoblasts, blood vessels, and nerves within the pulp) with **dental liners** and **cement bases** prior to placing the final restoration (Fig. 10-9). Various dental materials have been developed for this purpose. When used in the appropriate combination and in the correct order, they can prevent bacterial penetration, provide thermal insulation, sedate the pulp, or stimulate the production of secondary dentin.

### D. FINISH THE PREPARATION WALLS

This step involves using a handpiece with appropriate burs or hand instruments (chisel type) designed to smoothly plane the walls while removing unsound enamel (i.e., enamel that is crazed or cracked, or not supported by sound dentin).

### E. CLEAN THE PREPARATION

Prior to the restoration of any cavity preparation, the operator must remove tooth debris, hemorrhage, saliva, and any excess cement base. In this way, the restorative material will contact only sound, clean tooth structure.

### F. FINAL EVALUATION OF THE PREPARATION

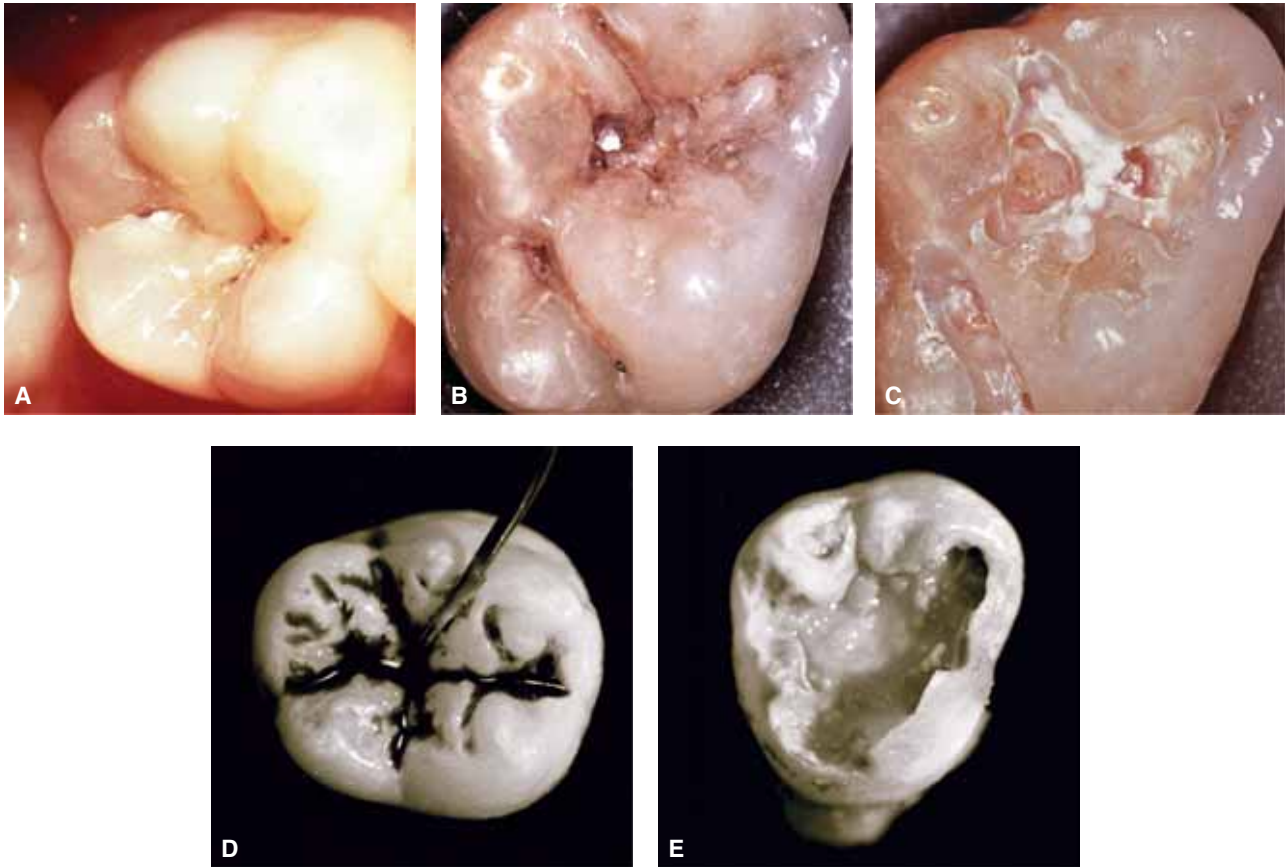
Finally, it is critical to evaluate the finished preparation to ensure that all of the principles of cavity preparation have been addressed.

The discussion of tooth restoration in this section assumes that the tooth to be prepared for a restoration is periodontally sound (i.e., has healthy periodontium with adequate bony support) and that the maintenance of the tooth is an integral part of the overall treatment for that patient.

### A. CLASS I CARIES

#### 1. CLASS I CARIES: DEFINED

**Class I lesions** form in enamel pits and fissures and may form wherever deep inaccessible pits and fissures occur (Fig. 10-10). In a 1979 to 1980 survey of U.S. schoolchildren aged 5 to 17 years, 54% of all carious lesions were found on the occlusal surfaces.<sup>4</sup> In 2000, studies of teeth at risk showed that the occlusal surfaces of the first molars are at greatest risk for initial caries,



**FIGURE 10-10. Class I caries.** **A.** Class I caries visible as stained grooves and adjacent demineralization seen as a chalky whiteness surrounding the stained pit. **B.** This maxillary molar has a small hole in the central pit (and in the lingual groove) that indicates class I decay. **C.** The dentist removed the decay in the maxillary molar seen in “B,” and since the decay spread out considerably at the DEJ, the outline has gotten quite wide. **D.** Typical stained occlusal grooves that need to be evaluated for decay by cleaning debris and using air and good light. **E.** This class I decay is so large that it might be best to restore this tooth with a crown.

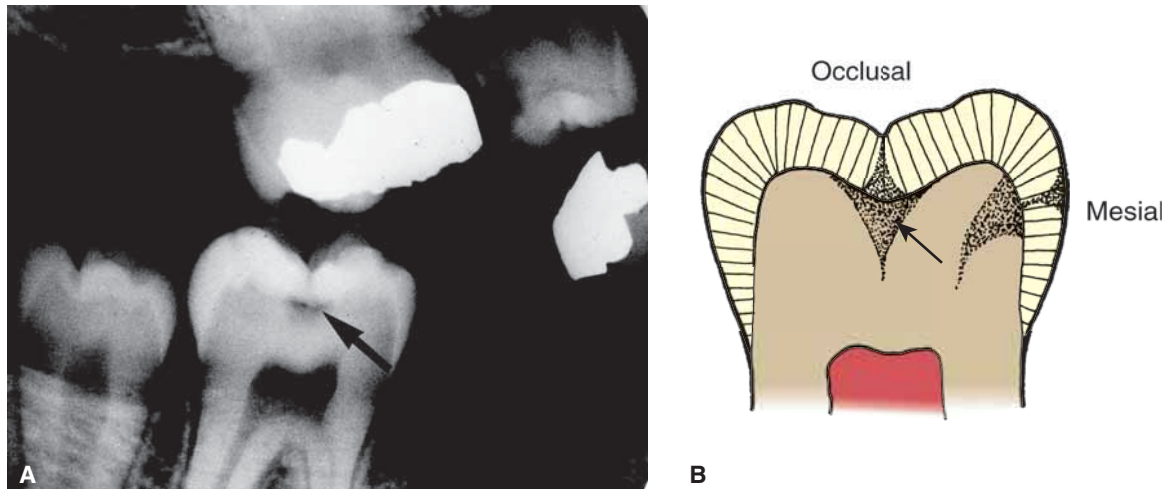
followed by the occlusal surfaces of lower, and then upper second molars.<sup>21</sup>

Detecting class I lesions clinically requires *visual* inspection and *tactile* evaluation. Careful visual analysis of a clean, dry, well-lighted occlusal surface will reveal this type of caries as a fissure or pit surrounded by enamel that is *chalky* or more *opaque* (less translucent) than the adjacent enamel (Fig. 10-10A). Some dentists prefer to confirm caries within these suspicious defects by probing with a very sharp explorer. When the dentist presses the explorer into the defect with moderate to firm pressure, and, upon removal, senses a resistance (known as *tug-back*), this helps to confirm the presence of softness and therefore caries within the defect or fissure wall. However, the firm use of the explorer for the detection of occlusal caries should be used with caution. One study suggests that the confirmation of decay based on tug-back may not always be accurate (there might not be decay, just a deep groove), and excessive

force could actually damage fragile enamel rods on the tooth.<sup>22</sup> Even in the absence of obvious tug-back, loss of translucency of enamel around a pit or fissure may be considered to be reliable evidence of attack. It is especially important to avoid undue pressure with the explorer point in larger, frank lesions (as seen in Fig. 10-10B and E) because probing in these areas may cause pain or additional enamel rod destruction.

A class I lesion is usually not detectable on a radiograph until it has spread considerably into dentin because the lesion is superimposed between the thick buccal and lingual surfaces of enamel, which show up whiter (radiopaque), thereby masking the darker color of caries. By the time the cavity is visible on the radiograph (Fig. 10-11), the size of the preparation required to remove all of the decay would be considerably deeper (toward the pulp) than if the decay had been detected during a good clinical examination when the lesion was smaller. Thus, early class I decay can be best diagnosed





**FIGURE 10-11.** **A. Radiograph of a class I lesion** (arrow) on tooth No. 31. By the time the lesion appeared this deep on the radiograph, the caries had destroyed dentin to such a depth that a thermal-insulating base of some type of dental cement will possibly be needed to protect the pulp from thermal conductivity through the metal filling. This pit and fissure caries should have been detected earlier with a good clinical examination. (There is also a large distal class II lesion on tooth No. 4, which appears to be rotated [top right]). **B. Spread pattern of class I decay:** The occlusal lesion at the arrow (class I, pit and fissure) is small externally, widening toward the depth of the fissure as it approaches the DEJ. Once within dentin, the caries spreads out laterally, as well as progressing toward the pulp.

during a thorough, systematic clinical examination of clean, dry teeth using good lighting and a sharp explorer point.

Recall that the shape of class I lesion in cross section in enamel is somewhat triangular in shape with the apex of the triangle barely visible on the enamel surface, and its wide base located along the DEJ. Once into dentin, the spread at the DEJ also forms a triangle with its base along the DEJ and its apex toward the pulp following the dentinal tubules (as seen in Fig. 10-11B). That is, the shape of the spread of class I caries through enamel and into dentin is like two triangles with their bases touching at the DEJ.

## 2. CLASS I CARIES: WHEN TO RESTORE

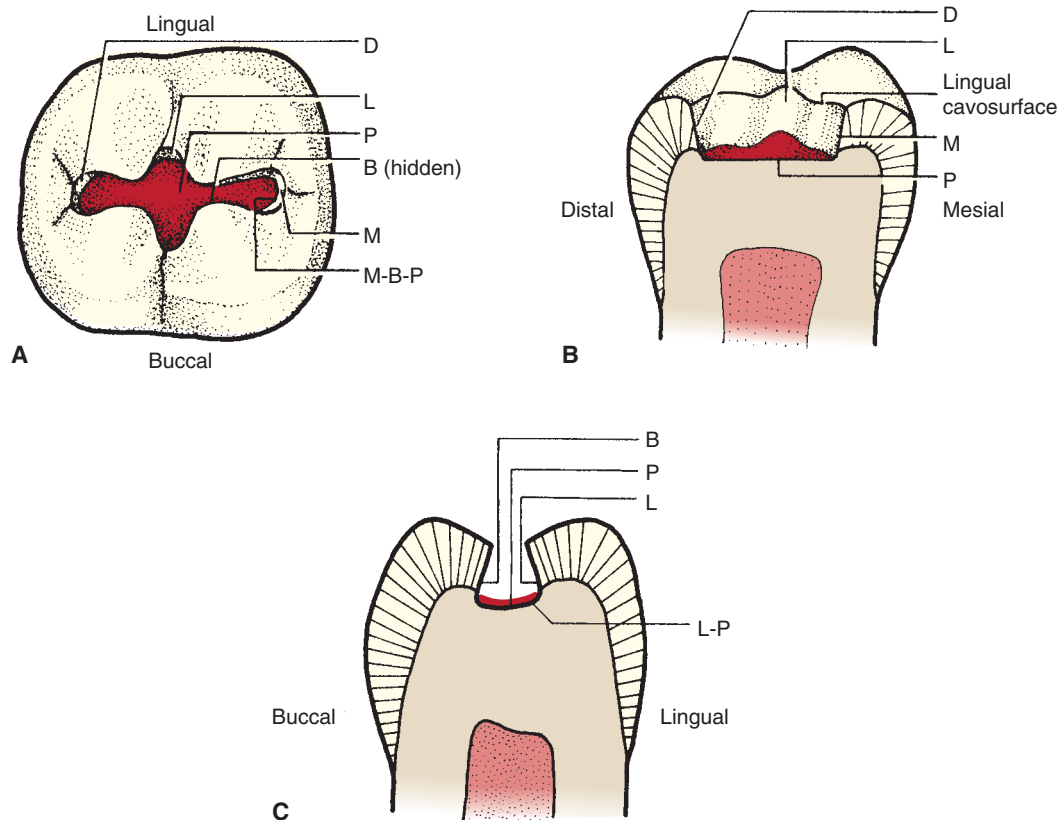
Some class I lesions are difficult to differentiate from noncarious, deep enamel defects. If tug-back occurs with a sharp explorer in a deep pit or fissure *and* the surrounding enamel is chalky or less translucent, a restoration is indicated. However, if tug-back is slight but there is no accompanying evidence, the dentist might consider periodically reevaluating the area during recall appointments, especially if the patient is older and has a low caries rate, since tug-back can occur when probing in deep fissures even when caries is not present. Generally, multiple signs should be present to make a clinical diagnosis of caries and then consider the need for a restoration. Finally, it is important to know that if **dental sealants** are applied shortly after

tooth eruption, pit and fissure decay on adult teeth can be prevented. For permanent first molars, this would be age 6, and for second molars, age 12. Certainly, by the time class I caries is obvious on the radiograph, it would be quite large, evident clinically, and should be restored.

## 3. CLASS I: CAVITY WALL TERMINOLOGY

The traditional occlusal preparation for amalgam can be compared to a room (with no ceiling) that has four vertical walls and a horizontal floor (sometimes called a fifth wall). The four vertical walls are named after the closest tooth surfaces, namely, *buccal*, *mesial*, *lingual*, and *distal*; the horizontal floor is called the **pulpal floor** (or wall) because it is over the pulp (abbreviated as B, M, L, D, and P in Fig. 10-12A). A **line angle** in the preparation is the line formed when two walls join. There are eight internal line angles in a conservative class I preparation (if the preparation is confined to the occlusal surface and is not extended into a buccal or lingual groove). These are named by combining the terms for the two walls that join to make up each line angle, changing the suffix of the first word from “al” to “o.” The junction of the pulpal floor and distal wall is the **distopulpal line angle**. All possible line angles in a class I occlusal preparation include four horizontal ones (distopulpal, mesiopulpal, buccopulpal, and linguopulpal), and four vertical ones (mesiobuccal, distobuccal, mesiolingual, and distolingual).





**FIGURE 10-12.** Three drawings of a conservative class I cavity preparation for amalgam on tooth No. 31. **A.** Occlusal surface showing extension for prevention into the major grooves. **B.** Mesiodistal cross section of the same tooth showing the ideal depth of the pulpal floor (red), just into dentin (about 0.5 mm). The lingual cavosurface is also identified where the lingual wall of the preparation joins the unprepared surface of the tooth. **C.** Buccolingual cross section of the same tooth showing the convergence of the vertical buccal and lingual walls toward the occlusal for retention and resistance form. Key for nomenclature: B, buccal wall; L, lingual wall; M, mesial wall; D, distal wall; P, pulpal wall or floor (red). Example of a line angle: L-P is the linguopulpal line angle. Example of a point angle: M-B-P is the mesiobuccopulpal point angle in A.

The term that describes the junction of any wall of the preparation with the unprepared tooth structure is called the **cavosurface**. The cavosurface, therefore, is the outline that encircles the preparation (or restoration).

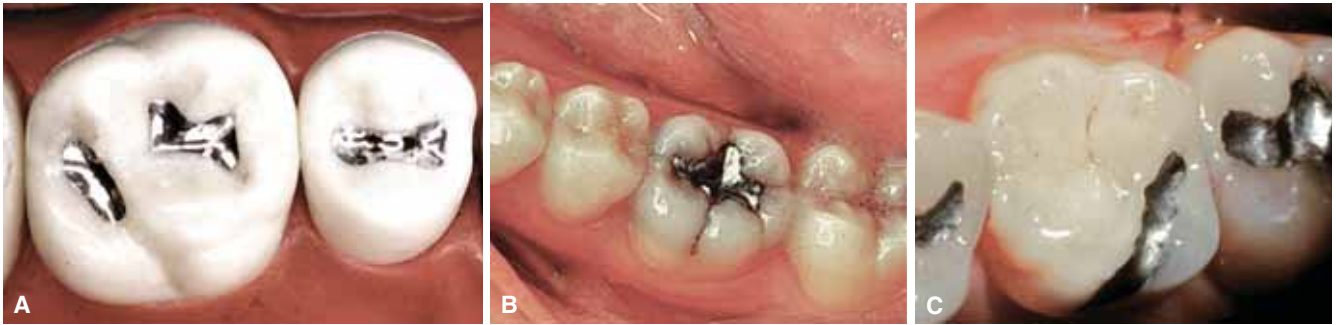Finally, there are four **point angles** in a class I preparation, each formed by the junction of three walls (as in the corner of a room where two walls meet the floor). Point angles are named after the three walls that form them: mesiobuccopulpal (abbreviated M-B-P in Fig. 10-12A), mesiolinguopulpal, distolinguopulpal, and distobuccopulpal. Since the junction of walls in a preparation is often rounded, line angles and point angles may be small, general areas rather than distinct, sharp angles or points.

A specific class I restoration is properly identified by naming the surfaces involved and material used. For example, an amalgam on tooth No. 14 involving the occlusal surface with a lingual extension would be abbreviated OL-A, No. 14 (Fig. 10-13C). The letter O

represents the occlusal portion of the preparation, the L represents the lingual extension, and the letter A represents the restorative material, amalgam. Test yourself by referring to the teeth in *Figures 10-13* and *10-23* where the legends give the correct abbreviations for several types of amalgam restorations. If composite had been used, the representation would have been OL-C, No. 14. A lower right third molar with an occlusal amalgam and buccal extension would be an OB-A, No. 32. A buccal or lingual pit restored with composite would be a B-C or L-C, followed or preceded by the tooth number.

#### 4. CLASS I CARIES: APPLYING PRINCIPLES OF CAVITY PREPARATION

Pit and fissure sealants can be used as a preventive measure to prevent class I caries in deep caries-prone pits and fissures, especially for the young patient. A **sealant** is a “flowable” resin that is applied over




**FIGURE 10-13.** Amalgam restorations for conservative class I caries. **A.** An occlusal amalgam on a maxillary first premolar (abbreviated No. 4 OA) and two occlusal amalgams on a maxillary first molar that are separated by the oblique ridge since the transverse groove of the oblique ridge is rarely carious (abbreviated No. 3 OA, OA). **B.** An occlusal amalgam on a mandibular first molar (abbreviated No. 19 OA). If this restoration needed to be replaced, the buccal groove would have to be evaluated carefully to see if it should be included in the new restoration. **C.** Class I caries was restored on a maxillary first molar with a preparation that included the distal pit and the lingual groove. It is abbreviated No. 14, OLA.

noncarious but caries-prone, unprepared pits and fissures on recently erupted teeth. These sealants have been shown to be an effective means of preventing caries in pits and fissures.<sup>23–25</sup> An initial sealant application for all permanent molars and premolars requires only 15 to 20 minutes per child.<sup>26</sup> If there is a slight bit of decay in a groove, the dentist may make a very small preparation, possibly confined to enamel. This very small preparation can be restored with a small amount of composite resin followed by a sealant to protect other deep grooves. This restoration is called a **conservative resin restoration** (previously called a **preventive resin restoration** or **PRR**). A sealant and conservative resin preparation are shown in *Figure 10-14*. Conservative preparations can also be formed using an air-abrasion system where abrasive particles are blown forcefully toward the tooth to actually remove tooth structure. This technique permits removal of only a

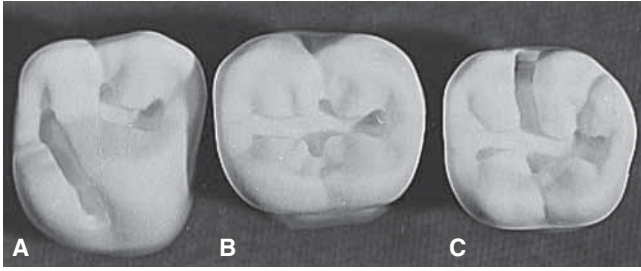
minimum amount of tooth structure, but the principles of cavity preparation for this new technology (such as providing retention, obtaining access to the decay, and extending to sound enamel, etc.) must still be considered. Retention is obtained by flowing an initial layer of bonding agent, similar to a sealant, into the irregularities of the microscopically roughened enamel.<sup>27</sup>

Amalgam is frequently chosen for larger stress-bearing class I restorations on occlusal surfaces (*Fig. 10-13*). For small class I pits or fissures on posterior teeth where esthetics are important, composite resins may be used, possibly in conjunction with sealants to protect, rather than cut into, adjacent susceptible pits and fissures.

Certain of G.V. Black's principles of cavity preparation are uniquely applied when restoring the class I cavity with amalgam as described here. Differences in preparation requirements will be noted for resin materials.



**FIGURE 10-14.** Conservative treatment for class I decay. **A.** A typical groove pattern for a mandibular second molar. **B.** A sealant placed over the grooves of a mandibular second molar would normally be almost invisible, so this sealant was outlined. **C.** A preparation for a conservative resin restoration.



**FIGURE 10-15.** Class I amalgam preparations showing various degrees of extension for prevention. **A.** Tooth No. 3 with an occlusal and an occlusal-lingual preparation (OA, OLA). The preparations are separate since in this case, there was no need to cross the oblique ridge. **B.** An occlusal amalgam preparation of tooth No. 31 (OA). **C.** An occlusobuccal amalgam preparation on tooth No. 30 (OBA).

### a. Extension for Prevention (Class I)

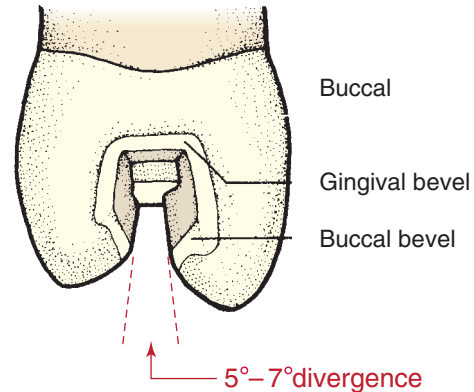
Extension for prevention, to include those pits and fissures adjoining the defects with active decay, should be considered when the patient is young, has a high caries rate, and/or exhibits poor oral hygiene, but sealants may also be used to protect adjacent pits and fissures. Examples of several amalgam preparations that include all major grooves can be seen in *Figure 10-15*.

### b. Resistance Form (Class I)

When amalgam is used on a stress-bearing surface, a minimum depth (of 1.5 to 2 mm) is recommended due to the brittleness of amalgam in thinner layers. However, if cast metal is used, less reduction (of only 1 mm) will provide room for a sufficient bulk of gold to withstand occlusal forces and preserve more tooth structure. Ideally, amalgam meets the unprepared tooth surface at right angles to provide resistance to marginal breakage, whereas the preparation margins for small cast restorations end with a **bevel** at the cavosurface (*Fig. 10-16*). Bevels are angular enamel reductions placed at the cavosurface of cast metal preparations in order for the margins (or outer edges) of the casting to be thin enough so that the dentist can perfect the adaptation and minimize the cavosurface gap between tooth and metal. The goal is to minimize the gap between the casting and tooth since this gap is filled with a dental cement, which is neither as strong nor as durable as the metal.

### c. Retention (Class I)

For amalgam, retention is provided in an occlusal preparation by a slight convergence of the buccal and lingual preparation walls toward the occlusal surface. The buccal and lingual cavity walls each form almost



**FIGURE 10-16.** Class II MOD cast metal inlay preparation showing retentive form (similar to porcelain inlay) provided by opposing walls diverging very slightly (only 5 to 7°) so that the inlay fits snugly like a stopper in a wine decanter bottle. Also, note that this cast metal inlay preparation design includes **bevels** that permit thin metal to be burnished or adapted more closely to the enamel.

a right angle with the uncut tooth at the cavosurface that permits a good bulk of amalgam to abut against a strong enamel surface (*Fig. 10-12C*).

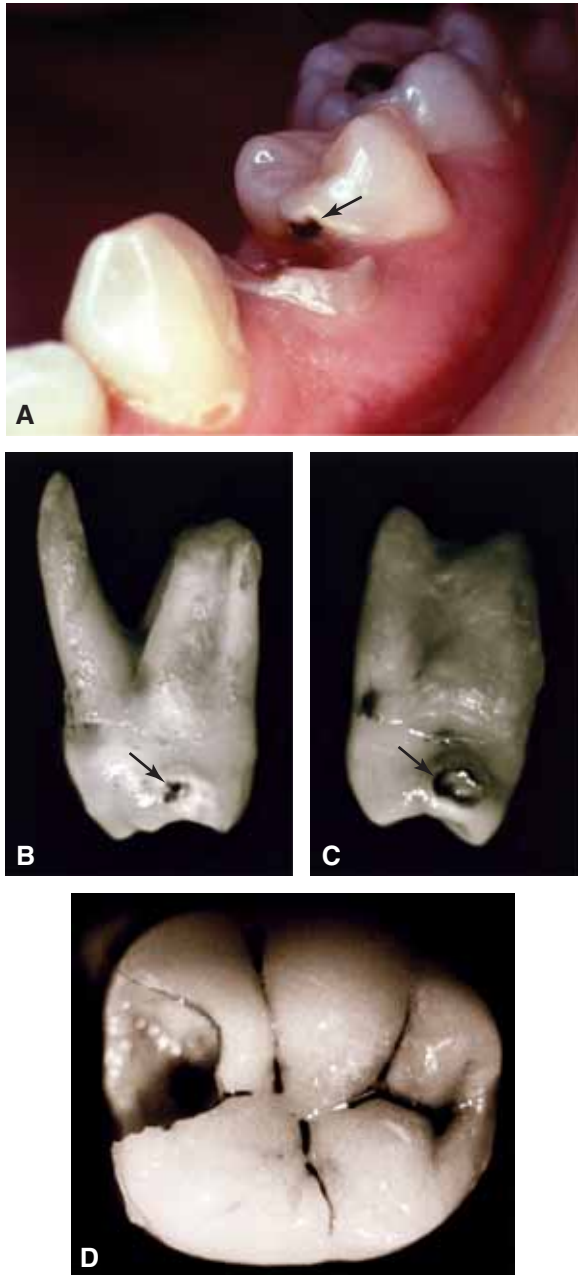
For composite preparations, retention is also provided by **acid etching** the enamel to produce microscopic irregularities on the surface that can be filled with a first layer of flowable bonding agent.

For inlays or onlays (cast gold or porcelain), retention is provided by preparing the opposing internal walls of the preparation with a *slight* (5 to 7°) divergence toward the occlusal surface (as seen within the class II gold inlay preparation in *Fig. 10-16*), thus allowing the solid casting to be seated snugly within the tooth, somewhat like a glass stopper fitting into the opening of a decanter. The dental cement (or sealant for porcelain) placed between the inlay and the tooth provides retention by sealing the margins and by setting to hardness at the interface between the slight irregularities of the enamel walls of the preparation and those of the inlay/onlay. Some types of dental cement chemically bond to the calcium of the tooth and can be mechanically attached to the etched surface of metal castings.

## B. CLASS II CARIES

### 1. CLASS II CARIES: DEFINED

Class II lesions form on the smooth *proximal* surface of *posterior* teeth just cervical to the proximal contact (*Fig. 10-17A* and *B*). It forms due to inadequate plaque removal in the hard to reach interproximal surfaces. Judicious use of dental floss to remove bacterial plaque

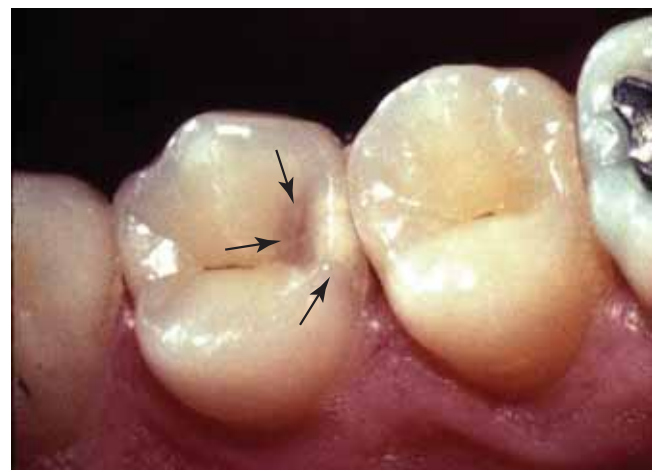

**FIGURE 10-17. Class II lesions.** **A.** Class II caries on the mesial surface of a mandibular second premolar (*arrow*) is clearly visible because the adjacent first premolar was broken off at the cervical line. Notice the location of the lesion (just cervical to where the proximal contact had been) and the color: a darkly stained hole surrounded by discoloration and chalkiness. This lesion would have been difficult to detect clinically when the first premolar was intact. Bitewing radiographs are most useful for confirming small class II lesions. **B.** An incipient (beginning) lesion without cavitation (*arrow*) on the mesial surface of tooth No. 14, probably visible only on a radiograph if an adjacent tooth was present. **C.** A larger class II lesion with cavitation (*arrow*) on the mesial surface of tooth No. 15, with color changes to the enamel that would be evident beyond the proximal contact area in the mouth. **D.** A very large class II lesion on the mesial surface of tooth No. 30, which resulted in the collapse of the entire mesial marginal ridge of enamel.

between posterior teeth is one method for preventing (or reversing) class II caries.

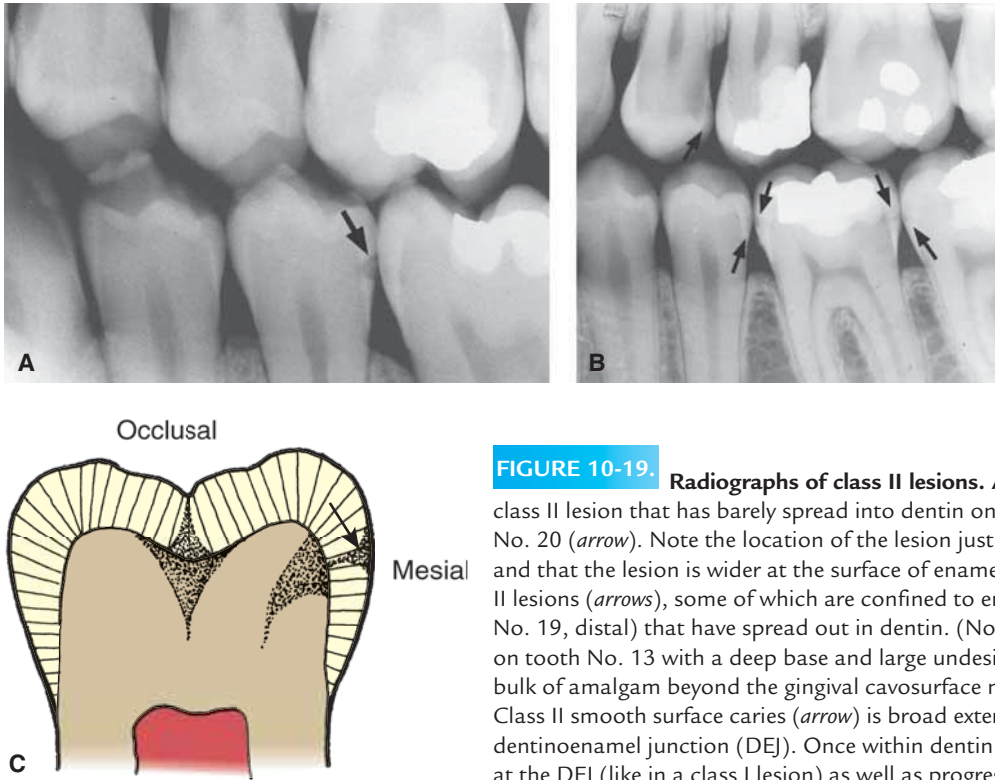
Clinical detection of a small class II lesion in the mouth without the aid of radiographs is often difficult due to the inability to visualize or probe the areas where it forms. A loss of translucency of the enamel seen when examining the overlying marginal ridge may be the first clinical evidence of class II caries (*Fig. 10-18*). As a carious lesion increases in size, it may appear as a dark, cavitated area (hole) that can be detected by using a thin probe (explorer) into the interproximal space. A very large class II lesion may actually undermine the marginal ridge, causing the entire ridge of enamel to break off during mastication (*Fig. 10-17D*).

Radiographic detection of an incipient (beginning, small) class II lesion is most predictably accomplished using **bitewing radiographs** because a class II lesion is normally visible on the radiograph before it can be detected clinically. A class II lesion is seen as a narrow triangular shadow within the enamel just cervical to the proximal contact (*Fig. 10-19A*). Unlike the spread pattern of class I caries, the wide base of the triangle is located at the enamel surface, and it tapers to its apex toward the DEJ. When the lesion gets large enough to reach dentin, the spread pattern is the same as for class I caries. It is triangular with its base spread out along the DEJ, and its apex follows the dentinal tubules toward the pulp (seen in two large lesions in *Fig. 10-19B* and on the proximal surface of the cross section diagram in *Fig. 10-19C*).



**FIGURE 10-18. Class II caries is suspected** when the area of the marginal ridge over the proximal contact of this posterior tooth shows a change in translucency appearing like a brown or gray shadow (*arrows*) beneath the surface of the enamel. Inspection of the tooth surrounding the proximal contact and evaluation of bitewing radiographs would be useful to confirm this area of decay.





**FIGURE 10-19.** Radiographs of class II lesions. **A.** Radiographic evidence of a class II lesion that has barely spread into dentin on the distal surface of tooth No. 20 (*arrow*). Note the location of the lesion just cervical to the proximal contacts, and that the lesion is wider at the surface of enamel than at the DEJ. **B.** Several class II lesions (*arrows*), some of which are confined to enamel and two (No. 12 and No. 19, distal) that have spread out in dentin. (Note the existing class II amalgam on tooth No. 13 with a deep base and large undesirable overhang, that is, excess bulk of amalgam beyond the gingival cavosurface margin.) **C.** The spread pattern of Class II smooth surface caries (*arrow*) is broad externally, narrowing toward the dentinoenamel junction (DEJ). Once within dentin, this lesion spreads out laterally at the DEJ (like in a class I lesion) as well as progressing toward the pulp.

## 2. CLASS II CARIES: WHEN TO RESTORE

Class II lesions that are clinically obvious, when cavitated (with a break or hole in the surface), should be restored (Fig. 10-17D). The *radiographic* indication for restoring a small lesion is when the lesion has penetrated to the DEJ and begins to spread out into dentin (teeth numbers 12 and 19 in Fig. 10-19B). If the lesion is small enough to be confined to enamel on the radiograph, the dentist must consider the patient's previous history of carious activity, oral hygiene, and age in order to decide whether to restore now or to reevaluate at subsequent recall intervals. The use of fluoride and fluoride varnishes has improved the potential to arrest early lesions. However, a young patient with a small carious lesion only two thirds of the way through enamel, but with many deeper lesions and poor oral hygiene that is not improving, should probably have the tooth restored, especially since a lesion *extends deeper in the actual tooth than it appears on the radiograph*.<sup>9</sup>

## 3. CLASS II: CAVITY WALL TERMINOLOGY

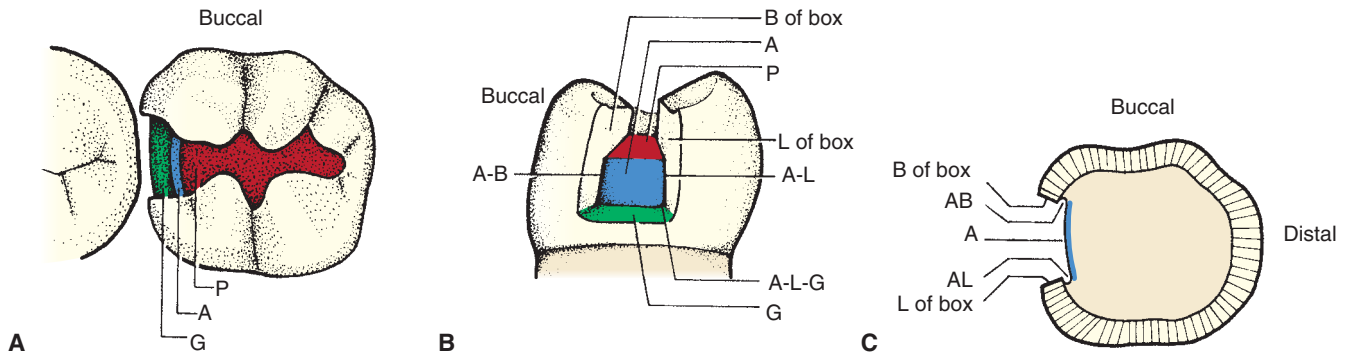
To reach and remove class II lesions (which form just cervical to the proximal contact), the dentist most often needs to prepare a **proximal box** that extends cervically through the marginal ridge. The proximal box is extended to a level that is more gingival than the pulpal floor of a class I preparation and has *vertical* buccal,

lingual, and axial walls (the **axial wall** is along the long axis of the tooth) and a **horizontal gingival wall** (or floor) (all labeled with abbreviations in Fig. 10-20).

Further, class II lesions can involve just one or both proximal surfaces of a posterior tooth (i.e., have one or two proximal boxes). Since obtaining access into the proximal lesion normally requires breaking through the occlusal marginal ridge, these restorations involve a minimum of two (occlusal and mesial, or occlusal and distal) or three (mesial, occlusal, and distal) surfaces.

The line angles that are present in a mesial or distal proximal box are axiopulpal, axiokingival, buccokingival, linguokingival, axiobuccal, and axiolingual. In a mesio-occlusodistal preparation, you can differentiate each line angle in a proximal box by stating whether it is located in the mesial or distal box. For example, there are two axiopulpal line angles in the mesio-occlusodistal amalgam preparation: One is the axiopulpal line angle of the mesial box and the other is the axiopulpal line angle of the distal box. The point angles in each box include axiolinguokingival (A-L-G in Fig. 10-20B), axiobuccokingival, axiobuccopulpal, and axiolinguopulpal.

Class II preparations for amalgam involving only two surfaces, such as mesio-occlusal or disto-occlusal, are traditionally abbreviated as MO-A or DO-A (not OM-A or OD-A). A mesio-occlusodistal amalgam preparation is abbreviated as MOD-A (not DOM-A). A class II

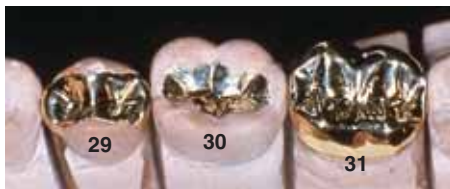

**FIGURE 10-20.** Conservative class II preparation for amalgam on tooth No. 30. **A.** Occlusal view showing the proximal box extending just through the proximal contact buccally and lingually. **B.** The mesial view showing the slight convergence toward the occlusal of the buccal and lingual walls of the box, and axiobuccal (A-B) and axiolingual (A-L) line angles where retentive grooves are placed. An example of a point angle: A-L-G for axiolinguogingival is seen. **C.** A cross section of this prepared tooth in the middle third of the crown showing the placement of the retentive grooves entirely within dentin at the axiobuccal and axiolingual line angles. Key for nomenclature: Walls, B, buccal; P, pulpal (red); L, lingual; A, axial (blue); G, gingival (green). Example of line angles: A-B, axiobuccal; A-L, axiolingual (location of retentive grooves).

preparation for composite material involving only two surfaces would be abbreviated similarly, with the abbreviation of “C” such as MO-C or DO-C. For inlays (I) or onlays (O), the abbreviation would be MO-I and DO-I, MOD-I and MO-O, and DO-O and MOD-O, respectively.

#### 4. CLASS II CARIES: APPLIED PRINCIPLES OF CAVITY PREPARATION

The preparation for a class II carious lesion can be restored with amalgam, direct composite, inlays, or onlays (cast metal or tooth colored). Improvements in composite restorative materials and techniques have resulted in the increased use of this tooth-colored material for class II restorations, especially when esthetics is an important factor. The larger the preparation (and therefore the thinner the remaining tooth structure), the more appropriate the onlay restoration might be to cover the cusp tips, protect the remaining thin tooth, and provide adequate resistance form (seen in gold on tooth No. 31 in Fig. 10-21).



**FIGURE 10-21.** Three gold cast restorations were constructed on stone dies. There is an inlay on tooth No. 29 (MOD In), an occlusal inlay on No. 30 (O In), and an onlay on tooth No. 31 (MOD On).

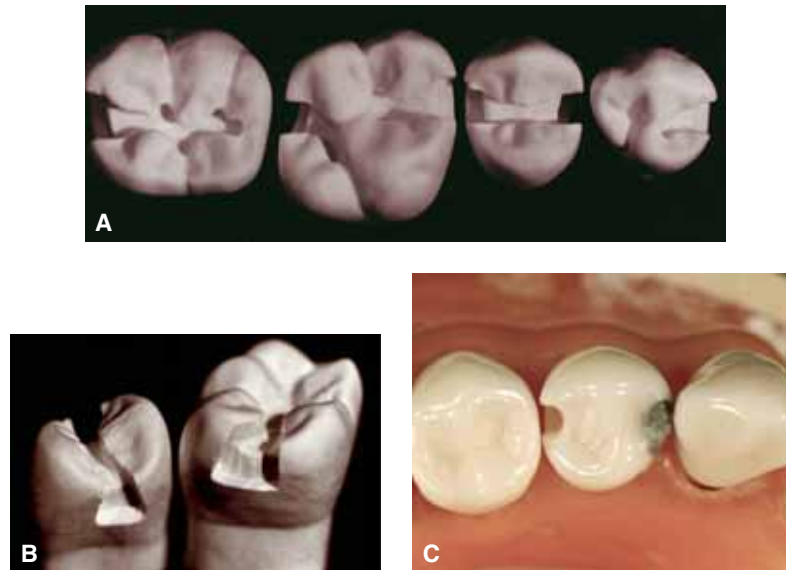
#### a. Extension for Prevention (Class II)

The class II preparation often extends over some of the occlusal surface to include adjacent defective or carious occlusal pits and fissures as in a class I preparation. The proximal box might be compared to a stair step descending farther gingivally than the occlusal portion (Fig. 10-22A and B). When proximal decay is present but there are no carious fissures on the occlusal surface, the dentist may prepare a *slot preparation*. This conservative preparation is just the proximal box of the traditional class II amalgam preparation with no extension across the occlusal surface into the occlusal grooves (Fig. 10-22C). Notice that in Figure 10-22A, the maxillary molar preparation does not extend over the oblique ridge since there is seldom a susceptible groove in this area. Also, the DO-A preparation on the mandibular first premolar does not cross the transverse ridge (which seldom has a deep groove), nor does it include the mesial pit if it is not deeply fissured or carious.

The class I portion follows the principles for restoring a class I lesion already discussed, but the proximal extension (box) adds new features. For example, the buccal and lingual walls of the proximal box of class II preparations are prepared beyond the proximal contact areas just into the buccal and lingual embrasures (Fig. 10-23). In this way, the margins of the restoration can be better evaluated by the dentist and kept clean by the patient.

#### b. Retention Form (Class II)

The buccal and lingual walls of the occlusal portion and the proximal boxes for *amalgam* are prepared so that they *converge* slightly toward the occlusal to prevent

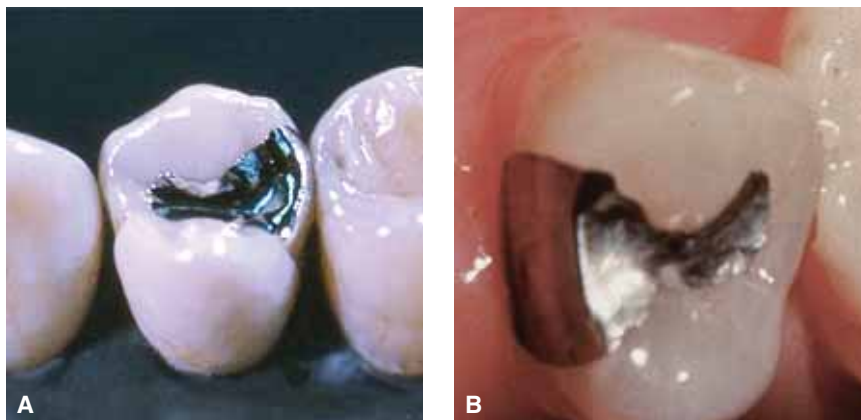


**FIGURE 10-22. Models of conservative class II amalgam preparations.** **A.** Occlusal views: Left: MO-A (mesio-occlusal amalgam) preparation on tooth No. 30. Left-center: MO-A, DO-A (mesio-occlusal and disto-occlusal amalgam) preparation on tooth No. 3 with the oblique ridge intact. Right-center: MOD-A (mesio-occlusodistal amalgam) preparation on tooth No. 5. Right: DO-A (disto-occlusal amalgam) preparation on tooth No. 28 with the transverse ridge intact. **B.** Proximal views of class II amalgam preparations. **Left:** MOD-A preparation on tooth No. 4. **Right:** MO-A preparation on tooth No. 30. Note the convergence of the buccal and lingual walls toward the occlusal for retention and resistance form. When the decay process has progressed deeper and wider, the prepared walls by necessity will be farther apart than these. **C.** Conservative **slot preparation** involving the distal and occlusal surfaces of typodont tooth No. 28; note the amalgam restoration (MO-A) in a similar slot preparation on the mesial and occlusal surfaces. This conservative preparation may be preferred to reach interproximal caries when there is proximal caries without any occlusal involvement.

the restoration from dislodging occlusally (seen clearly in Fig. 10-22B). Retentive grooves may be prepared buccally and lingually in a proximal box as extensions of the internal vertical wall of the box that is aligned along the long axis of the tooth, and is therefore called the axial wall. These retentive grooves are designed to prevent the amalgam restoration from dislodging in a proximal direction. They are located at the axiobuccal (A-B) and axiolingual (A-L) line angles seen best in Figure 10-20C. Resin restorations are generally prepared in a similar fashion to amalgam. However, with

additional retention gained from the enamel etching and bonding, there is less need for internal retention grooves.

For cast metal or porcelain *inlays or onlays*, opposing buccal and lingual walls must *diverge* slightly toward the occlusal (seen on a die for a cast metal onlay in Fig. 10-24), and the two axial walls in a mesio-occlusodistal inlay preparation must converge slightly toward the occlusal. This is necessary so that an accurate restoration can be refined outside of the mouth and then be seated within the tooth preparation in the mouth.



**FIGURE 10-23. Class II amalgam restorations.** **A.** A polished class II amalgam on a maxillary first premolar (No. 12 DOA). **B.** This class II amalgam restoration on a tooth with no adjacent tooth shows how the dentist had to extend this preparation toward the gingiva in order to reach the area where caries had been located: gingival to the proximal contact.

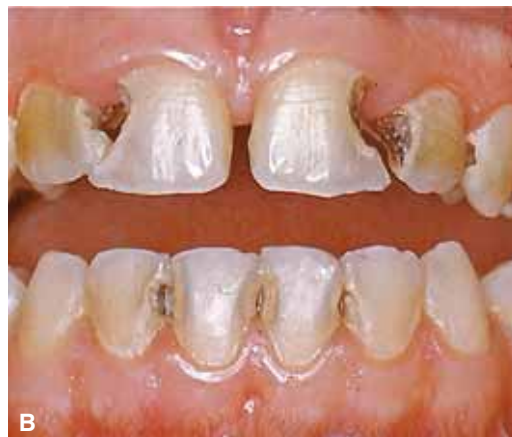
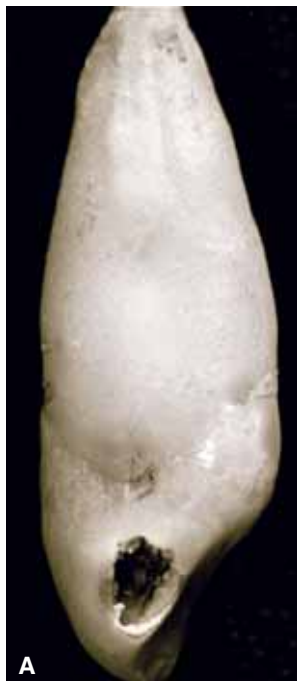
**FIGURE 10-24.** A die of a tooth prepared for a cast metal onlay that covers the mesial, occlusal, and distal surfaces (MOD On). The line on the die marks the cavosurface margin that ends with a continuous bevel. The buccal and lingual walls diverge toward the occlusal so that the restoration can be removed from the die and then placed in the prepared tooth in the mouth.

## C. CLASS III CARIES

### 1. CLASS III CARIES: DEFINED

Class III lesions are smooth surface lesions located on the *proximal* surfaces of *anterior* teeth, just cervical to the proximal contact, but not involving the incisal angle (or corner) of the tooth (Fig. 10-25).



**FIGURE 10-25.** Class III lesions. **A.** A class III lesion on the mesial of tooth No. 6 with an area of obvious cavitation (or hole) in the enamel surface. **B.** Most of these anterior teeth have large class III lesions. The decay on the distal surfaces of the maxillary central incisors may be class IV decay since the decay is close to the incisal angles.

An incipient (small or beginning) class III lesion can often be detected clinically by carefully examining the enamel facially or lingually for changes in translucency just cervical to the proximal contact (Fig. 10-26). The underlying lesion causes overlying enamel to appear slightly darker or more opaque than surrounding, sound enamel. These changes are most evident when a source of light (such as fiber optics) is placed lingually against the proximal enamel of the tooth, revealing the change in translucency facially (Fig. 10-27). This method of clinical detection is called **transillumination**.

Radiographs of the anterior teeth can also be used to confirm a class III lesion (Fig. 10-28). The location, just cervical to the proximal contact, and pattern of spread are both typical of smooth surface lesions that were described for a class II lesion.

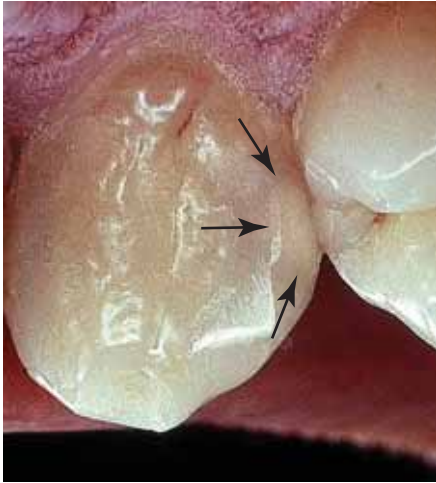
### 2. CLASS III CARIES: WHEN TO RESTORE

The indications for restoring a class III lesion are the same as for a class II lesion: That is, if the surface is cavitated or decay has reached the dentin as seen on the radiograph or through transillumination, a restoration is indicated.

### 3. CLASS III: CAVITY WALL TERMINOLOGY

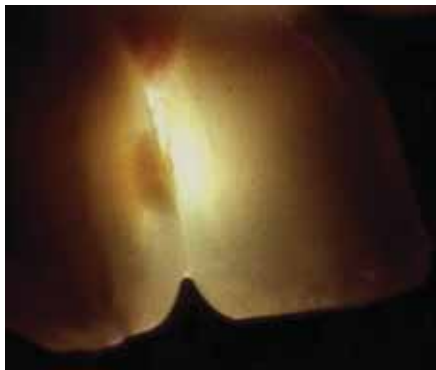Since the class III resin restoration obtains retention in most cases from the bonding of resin to etched enamel and to dentin, the final shape of a resin class III preparation may be somewhat amorphous, removing only



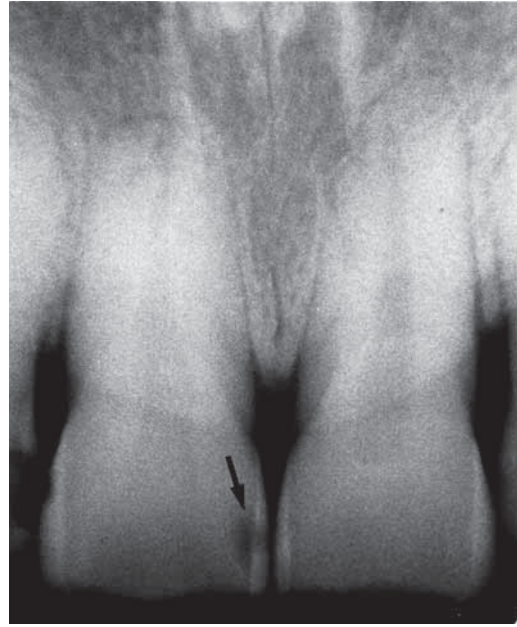

**FIGURE 10-26.** Tooth No. 6 lingual view. Class III caries is suspected when the area of the marginal ridge lingual to the proximal contact of this anterior tooth shows a change in translucency (*arrows*) appearing like a brown or gray shadow beneath the surface of the enamel. Inspection of the tooth surrounding the proximal contact and transillumination or radiographs would be useful to confirm this area of decay.

carious tooth structure while conserving as much healthy tooth structure as possible. Sometimes, however, a more defined, traditional preparation may be desirable. The traditional preparation for the *lingual approach* for a class III composite is represented in *Figure 10-29A*. This lingual approach preparation can be compared to the slot preparation of a class II preparation, which is also cut through the marginal ridge. However, due to the more horizontal alignment of the box of a class III preparation, the names assigned to the walls differ. Here, the four walls are called gingival, facial,



**FIGURE 10-27.** Transillumination. A light source is directed through the proximal surfaces of these anterior teeth to reveal a change in translucency just cervical to the proximal contact area, indicating the presence of class III caries.

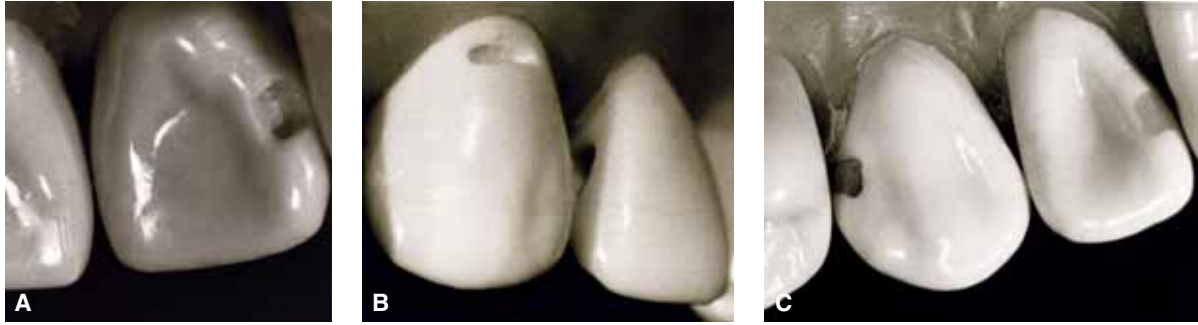

**FIGURE 10-28.** Radiograph of a class III lesion (*arrow*) on the mesial of tooth No. 8. Note the location of this decay just cervical to the proximal contact and the characteristic spread or widening of the decay at the DEJ.

incisal, and axial (as abbreviated in *Fig. 10-30A* and *B*). There are only five internal line angles: gingivofacial, incisofacial, gingivoaxial, facioaxial, and incisoaxial. There are only two internal point angles: gingivofacioaxial and incisofacioaxial.

The traditional preparation for a composite with a *facial approach* may be more triangular in shape (with its base near the gingiva). It has three walls and a floor (*Fig. 10-29B*). The three walls are the facial, lingual, and gingival walls, and the fourth wall (or floor) is the axial. Subsequently, this preparation has six internal line angles: facioaxial, linguoaxial, gingivoaxial, faciolingual, linguogingival, and gingivofacial. There are only three internal point angles: faciolinguoaxial (abbreviated F-L-A in *Fig. 10-30C*), linguogingivoaxial, and faciogingivoaxial.

Class III composite restorations may be abbreviated by identifying the proximal surface, as well as the surface through which access was gained and the material used. For example, the class III composite on the mesial surface of tooth No. 10 (in *Fig. 10-29C*) with access to the decay through the lingual enamel would be identified as M-C, No. 10, lingual approach, or more precisely, ML-C, No. 10. An old class III restored with amalgam approached from the lingual on the distal of tooth No. 11 would be identified as DA, No. 11, lingual approach, or DLA, No. 11 (*Fig. 10-29C*). A composite



**FIGURE 10-29.** Class III cavity preparations. **A.** A composite resin preparation with *lingual* approach on tooth No. 8 DLC. Note the axioincisal retentive feature. (The axioingival retentive feature is less visible here.) **B.** A class III composite resin preparation with *labial* approach can be seen in the facial embrasure (No. 7 DFC preparation). (This tooth was prepared by Gregory Blackstone, second-year dental student.) (There is also a class V preparation on the facial of the canine, No. 6.) **C.** Two teeth with class III restorations: tooth No. 10 was restored with a mesial composite restoration with a lingual approach (ML-C, No. 10), and tooth No. 11 was restored with a distal amalgam with a lingual approach (DLA, No. 11).

with a facial approach on the mesial of tooth No. 24 would be identified as MF-C, No. 24. Note that instead of using “L” to denote the labial (or facial) surface, “F” is used to denote the facial surface in order to avoid confusion with “L,” which is used to denote the lingual surface.

#### 4. CLASS III CARIES: APPLIED PRINCIPLES OF CAVITY PREPARATION

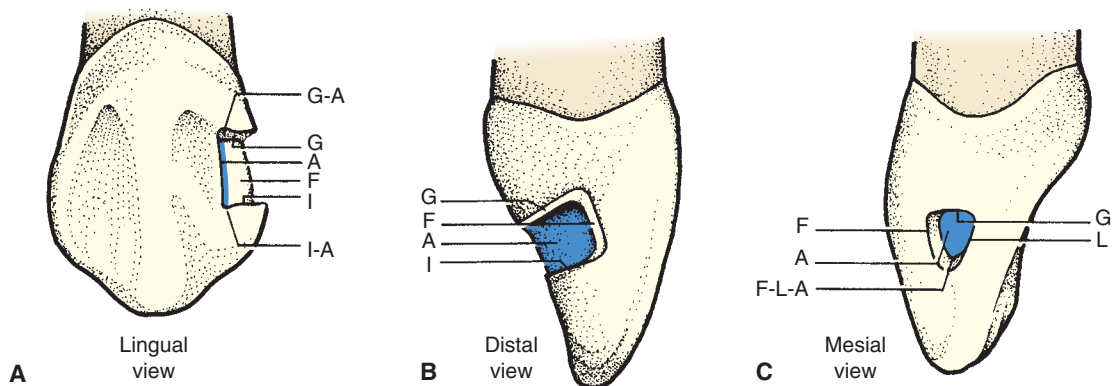
Since the class III lesion occurs in a non-stress-bearing area that is most often of esthetic concern to the patient, a tooth-colored composite resin is most often the restoration of choice.

##### a. Extension for Prevention: Class III

Extension for prevention is minimal in the class III composite preparation since the dentist wants to preserve as much enamel as possible for esthetic reasons. The approach for removing the decay, whenever possible, is from the lingual of the tooth, so the facial plate of enamel is preserved for maximum esthetic effect (Fig. 10-29A), but when the decay has already destroyed the facial enamel, a facial approach can be used (Fig. 10-29B).

##### b. Retention: Class III

When restoring teeth with larger carious lesions, retention form may be obtained by simply removing



**FIGURE 10-30.** Class III preparations. **A.** The lingual view of the class III amalgam preparation, lingual approach, on the distal of tooth No. 6. Retentive grooves are evident at the cavosurface of the gingivoaxial and incisoaxial line angles. **B.** The distal view of a class III composite preparation, *lingual* approach. Note the slight convergence of the incisal and gingival wall toward the lingual for retention. This preparation also has a retentive groove (in the shadow between G and A) at the gingivoaxial line angle, but it does not extend to the cavosurface. **C.** The mesial view of a class III composite preparation, *labial* approach. Note the triangular shape. Retentive features are found internally at the axioingival line angle and the faciolinguoaxial point angle. Key for nomenclature: for lingual approach (A and B): G, gingival; A, axial (blue); F, facial; I, incisal. Examples of the angles are the retentive features G-A and I-A for the gingivoaxial and incisoaxial line angles, respectively. Key for the facial approach (C): F, facial; A, axial (blue); G, gingival; L, lingual.

the decay that has spread out at the DEJ, resulting in a preparation that is wider internally than externally. Historically, retentive pits or grooves have been used as extensions of the axial wall in order to improve retention for either a composite or amalgam class III preparation (seen in Fig. 10-30A). However, the more conservative method of affording retention and reducing leakage at the cavosurface margin of a composite restoration is by bonding the composite resin to an acid-etched, beveled enamel surface. The preparation shape therefore can be more conservative, without the need for internal retentive grooves or pits.

## D. CLASS IV CARIES

### 1. CLASS IV CARIES: DEFINED

A class IV lesion involves the proximal surface of an anterior tooth (as does a class III lesion), but, in addition, it involves the *incisal angle* (or corner) of the tooth (Fig. 10-31). The class IV lesion is frequently the result of a class III lesion that became so large that the undermined tooth angle broke off. A similar-shaped defect occurs when the tooth corner fractures off due to a blow to the mouth. The loss of an incisal angle is plainly visible upon clinical examination. Radiographs are not needed to detect the class IV lesion but may be useful to determine the depth of the lesion relative to its proximity to the pulp chamber (Fig. 10-32).

### 2. CLASS IV CARIES: WHEN TO RESTORE

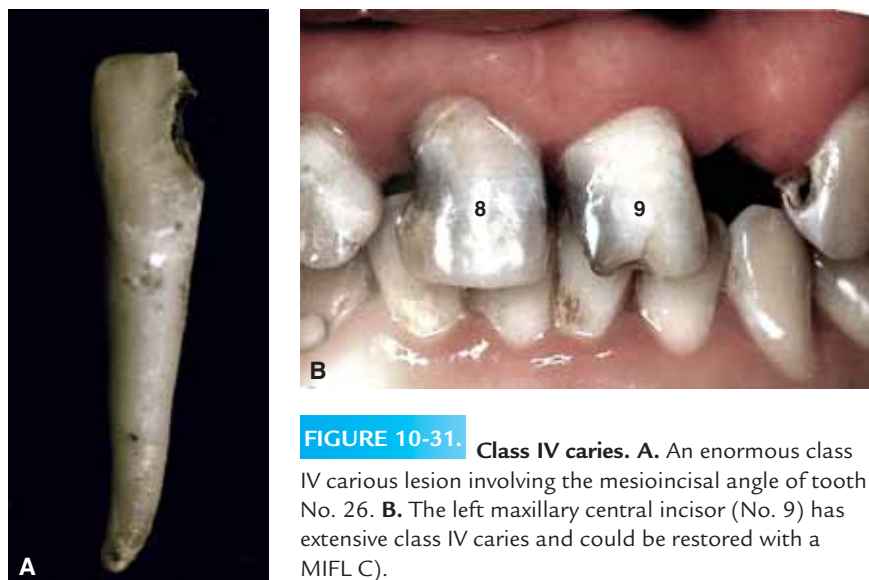
The class IV restoration is indicated when active caries is detected. Many class IV restorations are indicated,

however, not because of caries but because the incisal angle of the tooth has fractured off in an accident. In these instances, the extent of the fracture, the proximity of the exposed tooth structure to the pulp chamber, hypersensitivity to temperature changes, and the patient's concern for esthetics are important factors when deciding whether or not to restore the tooth. If the fracture is not into the dentin and the patient is not concerned about the appearance of the tooth, smoothing the rough edges of the tooth may suffice. If, however, dentin is involved or if there is evidence of decay, a restoration is indicated to prevent discomfort from the exposed dentin and to stop the spread of decay.

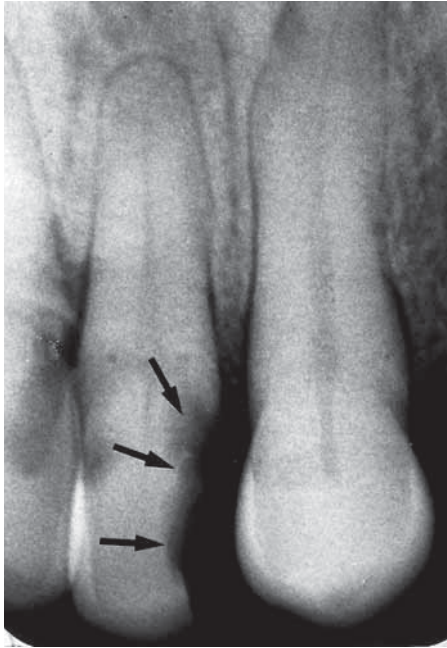
### 3. CLASS IV CARIES: CAVITY WALL TERMINOLOGY

Depending on the degree of involvement, this preparation may have only one flat wall (as in a fracture; similar to the shape seen in Fig. 10-33) or may be made up of two main surfaces: a gingival surface and a more axial surface. These two portions may join at an angle called the axiokingival line angle. There are no point angles.

A composite restoration that restores one incisal angle actually restores parts of four surfaces, so it may be abbreviated as either an MIFL-C or DIFL-C (Fig. 10-34) to denote the involvement of all surfaces of either the mesioincisal or the distoincisal angle of the tooth. If both proximal surfaces were involved, the restoration would be designated as MIDFL-C. As usual, the tooth number can be added before the abbreviation, for example, No. 9 MIDFL-C.



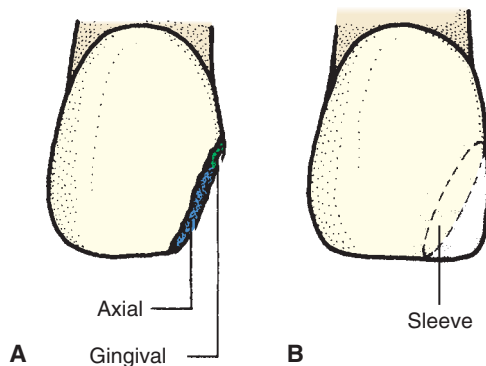
**FIGURE 10-31.** Class IV caries. **A.** An enormous class IV carious lesion involving the mesioincisal angle of tooth No. 26. **B.** The left maxillary central incisor (No. 9) has extensive class IV caries and could be restored with a MIFL C).



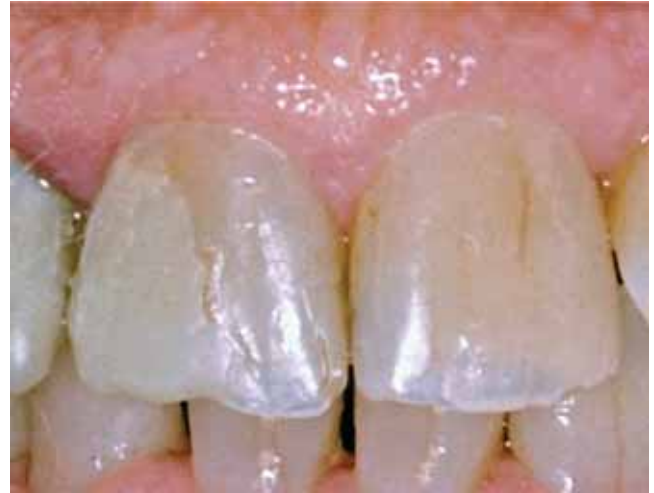**FIGURE 10-32.** Radiograph of a class IV lesion (arrows) involving the distoincisal angle of tooth No. 10.

#### 4. CLASS IV CARIES: APPLIED PRINCIPLES OF CAVITY PREPARATION

If a class IV preparation is conservative, a composite resin, particularly one that utilizes an acid-etching technique, is the restoration of choice. An alternative treatment is a veneer of porcelain bonded to the facial surface of the tooth, replacing the fractured incisal area (seen previously in Fig. 10-7A). If the preparation is



**FIGURE 10-33.** Class IV carious lesion on tooth No. 8 and the resultant restoration. **A.** View of the lesion showing the gingival and axial portions of the defect. **B.** After smoothing the preparation and acid etching the enamel, the restored tooth with a sleeve (thin layer of bonded resin) that overlaps the etched enamel surface, thus establishing maximum retention and enhancing (blending) the color match.



**FIGURE 10-34.** This class IV composite resin restoration on a maxillary central incisor can be abbreviated No. 8 DIFLC.

extensive or if the whole incisal edge of the tooth and both proximal surfaces are involved, but there is sufficient remaining tooth structure, it may be better to restore the tooth with a full crown that has a tooth-colored facial surface, or an all ceramic restoration (crown), for the best esthetics and longevity.

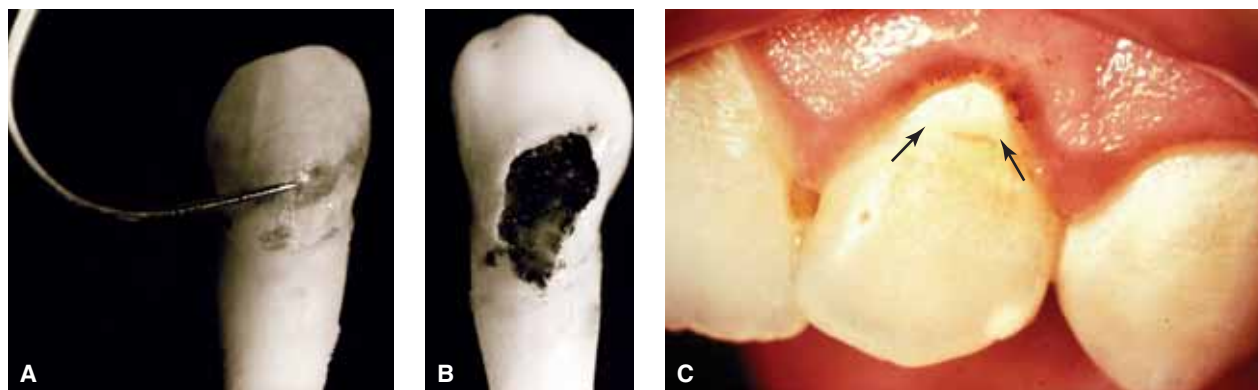
Caries removal and smoothing extremely rough or unsupported enamel may be all that is needed to prepare the tooth for a class IV composite. The occlusion, as always, must be analyzed to be sure that there is room for the restoration when the patient chews and incises, especially in a protrusive direction. Retention is most commonly achieved by acid-etch techniques that permit resin tags to bond the composite to the tooth. A thin overlapping sleeve of excess composite material can cover beveled enamel that has been acid etched to maximize retention (Fig. 10-33B) and to improve esthetics by blending the color differential between composite and enamel.

### E. CLASS V CARIES

#### 1. CLASS V CARIES: DEFINED

The class V lesion is located in the cervical one third of the facial or lingual surface of any anterior or posterior tooth crown (Fig. 10-35). It is a smooth surface lesion that results from poor oral hygiene in the area of the tooth just cervical to the buccal or lingual crest of curvature, adjacent to the gingiva, where the natural cleansing action of the lips, tongue, and cheeks is ineffective. This area of the tooth is susceptible to plaque accumulation and resultant caries. Over the lifetime of a tooth, the gingiva and supporting bone may recede





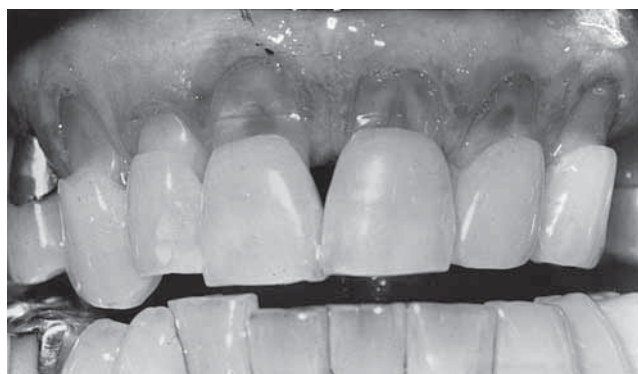
**FIGURE 10-35. Class V lesions.** **A.** Incipient (beginning) facial lesion that is seen as chalky and discolored and is flaking away. **B.** An obvious cavitated class V facial lesion that has destroyed much of the enamel on the buccal surface of the crown and adjacent cementum and dentin of the root. **C.** Class V demineralization: a chalky white area (*arrows*) seen in the cervical third of a maxillary lateral incisor with incisal wear is evidence of the first stages of dental caries. If this demineralization continued and did not reverse itself (through excellent oral hygiene, diet, and use of topical fluoride), this area could develop a cavitation (hole) that would need to be restored. Also, notice the inflammation of the adjacent gingiva (gingivitis), which is also caused by bacterial plaque.

apically, exposing greater amounts of the root surface. With decreased salivary flow and/or poor oral hygiene, the incidence and severity of caries increase in this area (Fig. 10-35B).

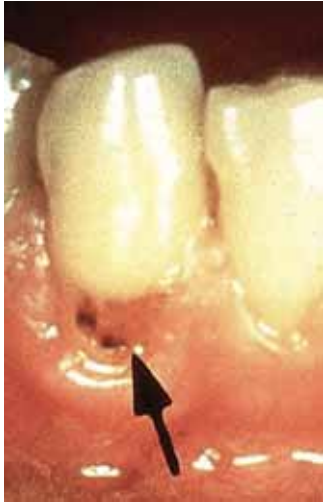As a class V lesion begins to form, it appears as a chalky white or stained surface (Fig. 10-35C). In these beginning (incipient) lesions, care should be taken with the explorer not to break through an area of beginning demineralization that has not yet cavitated since excellent oral hygiene and fluoride have been shown to reverse the caries process. These lesions may be hidden slightly apical to the level of inflamed gingiva so that the use of the tactile sense obtained through the explorer is critical for detection of cavitation<sup>9</sup> and for distinction between these lesions (which are cavitated) and a calcified buildup of calculus (which is felt as a bump attached to the surface of the tooth).

Other areas of cavitation (or depressions) located in the cervical of the crown and the adjacent root surface include defects formed from *erosion* by acids, or from *abrasion* (most commonly caused by abrasive toothpastes and improper tooth brushing [as seen in Fig. 10-36]), and a process known as *abfraction* (the loss of hard tooth structure, which appears similar to abrasion but is caused by flexure or bending of the tooth caused by heavy occlusal forces). Caries may develop at the depth of these defects. Also, as the root becomes exposed to the oral environment due to gingival recession, the cementum, which is much less mineralized than enamel, is more susceptible to caries compared to enamel. The result is root caries, a condition that is occurring more frequently in our aging population (Fig. 10-37).

As with a radiograph of a class I lesion, the class V lesion is superimposed over buccal or lingual surfaces of enamel that show up whiter (radiopaque), thereby masking the darker (radiolucent) caries (Fig. 10-38). By the time a class V lesion is evident on radiographs, it has progressed far beyond the incipient stage and will require a much larger restoration than would have been required if it were clinically diagnosed at its earliest stages. Therefore, the examiner should not depend on radiographs for detection of these lesions. However, when discovering a cervically located radiolucency on a radiograph, the dentist should carefully evaluate the tooth to clinically prove or disprove the presence



**FIGURE 10-36.** Maxillary anterior teeth showing **cervical abrasion**, possibly due to poor tooth brushing technique and abrasive pastes. These areas are prone to caries and often become sensitive. Each tooth should be evaluated carefully to determine if application of a desensitizing solution or a restoration is indicated.

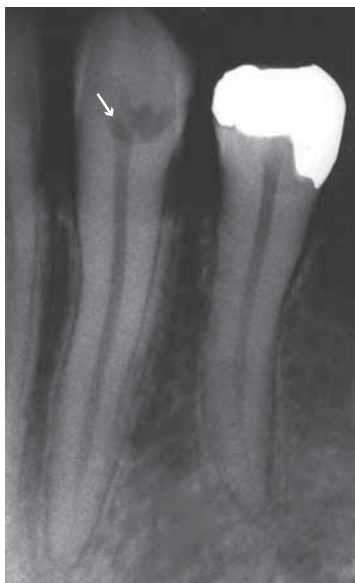

**FIGURE 10-37.** Root caries (arrow) on an area of exposed cementum after gingival recession.

of class V caries. Darker (radiolucent) areas of cervical abrasion, as well as older types of radiolucent restorative materials, can appear like class V or root surface caries on radiographs.

## 2. CLASS V CARIES: WHEN TO RESTORE

Not all areas at the cervical of the tooth that are white or darkly stained require a class V restoration (as in Fig. 10-35C) since these areas of beginning (incipient)



**FIGURE 10-38.** Radiograph of a class V lesion (arrow) on tooth No. 22. It is impossible to tell from the radiograph whether it is on the buccal or lingual surface or whether it is decay or a radiolucent (dark looking on the radiograph) composite restoration.

decay could respond to fluoride and improved oral hygiene and actually remineralize so that no restoration is required. Also, these defects could be areas of arrested (old, inactive) decay, or noncarious cavitated defects due to abrasion, erosion, or abfraction. Class V lesions require restorations when tooth structure is soft or cavitated (as seen in Fig. 10-35B). Restorations should also be considered to protect noncarious defects (like abrasion defects) that occur in this part of the tooth if the tooth is sensitive and does not respond to desensitizing agents, if the lesion is very deep and cannot be kept clean, or if it appears that it will continue to advance due to poor oral hygiene or parafunctional habits.

## 3. CLASS V CARIES: CAVITY TERMINOLOGY

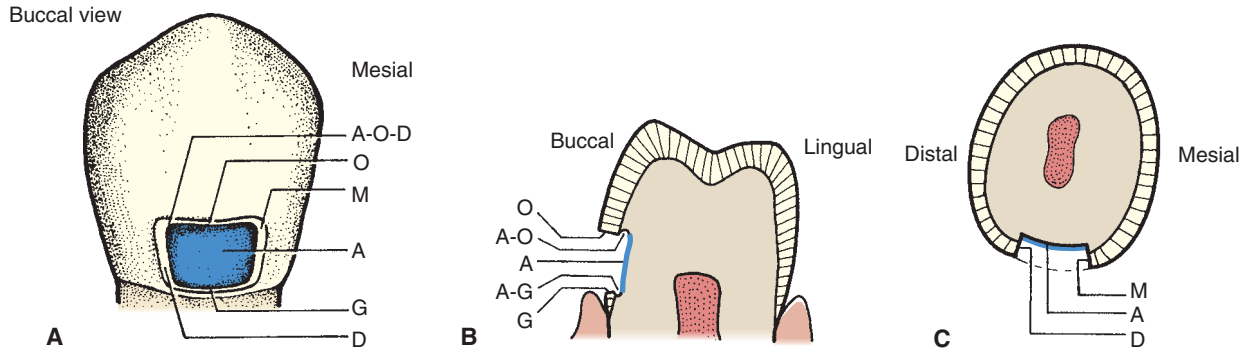
The class V preparation is somewhat box shaped and consists of five walls: distal, occlusal, mesial, gingival, and axial. These preparations have eight line angles: axiomesial, axiokingival, axiodistal, axio-occlusal, mesio-axial, disto-axial, mesio-occlusal, and disto-occlusal. The axio-occlusal and axiokingival line angles are prepared with retentive grooves labeled as A-O and A-G in Figure 10-39B. There are four point angles: axio-occlusodistal (A-O-D in Fig. 10-39A), axio-occlusomesial, axiodisto-axial, and axiomesio-axial.

The restoration is identified by surface and material. For example, a buccal amalgam on tooth No. 19 is B-A, No. 19, a facial composite on tooth No. 7 is F-C, No. 7, and a glass ionomer on the facial surface of tooth No. 11 would be F-GI, No. 11. Typically, the term facial (F) is applied to anterior teeth, whereas buccal (B) is applied to posterior teeth.

## 4. CLASS V CARIES: APPLIED PRINCIPLES OF CAVITY PREPARATION

Since a class V lesion occurs in non-stress-bearing areas, when esthetics is a factor, a composite may be used, even though it may be less resistant to abrasion than amalgam (Fig. 10-40B). In gingival abrasion lesions and areas of root caries, the dentist may restore the tooth with a glass ionomer or resin-modified glass ionomer because they both bond to dentin and contain fluoride. Amalgam may be used when the esthetics are not of prime concern (Fig. 10-40A). In rare cases, primarily at the patient's request, a cast metal inlay (or porcelain inlay) could be used to replace lost tooth contour.

The preparation for a class V composite restoration is usually kept as conservative as possible (Fig. 10-40B), with a convex axial wall that is just into dentin (Fig. 10-39C) and little or no extension for prevention. Prevention of future caries occurs through patient education in oral hygiene techniques and from periodic

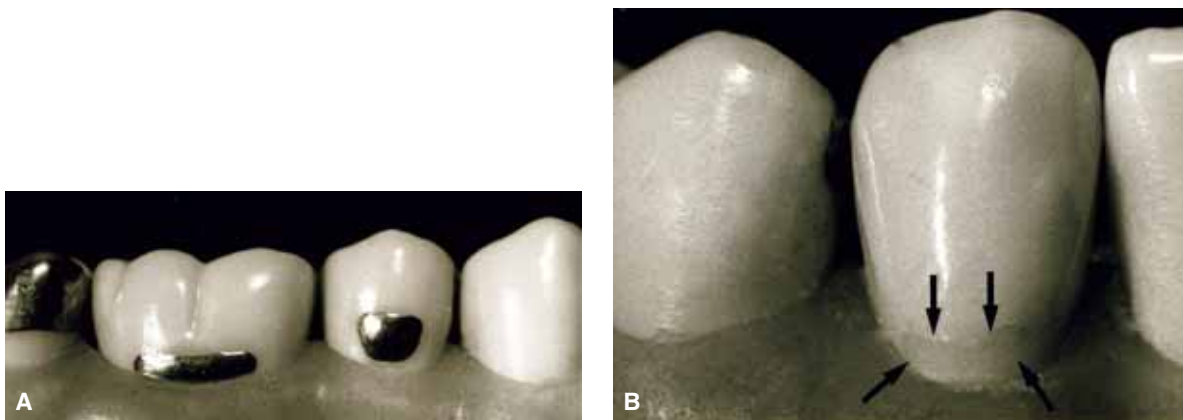


**FIGURE 10-39.** Conservative class V preparation for amalgam on tooth No. 29. **A.** Buccal view showing the trapezoidal outline form. Example of a point angle is the A-O-D or axio-occluso-distal point angle. **B.** Buccolingual cross section of the same tooth revealing axio-occlusal (AO) and axio-gingival (AG) line angles and retentive grooves. **C.** Cross section of B showing the axial wall (A) just minimally into dentin (0.5 mm) forming a convex axial wall. Key for nomenclature: O, occlusal; M, mesial; A, axial (blue); D, distal; G, gingival.

application of topical fluoride. The retention of amalgam restorations is obtained by preparing retentive grooves that are extensions of the axial wall in an occlusal and gingival direction (A-O and A-G in Fig. 10-39B). When using composite, similar retentive grooves could be used, but more often, retention is dependent on beveled enamel surfaces that have been acid etched. A glass ionomer restoration in an area of deep cervical abrasion (V-shaped or notched) may require no preparation, only a treatment with a dentin conditioner or primer that aids in the chemical bond between dentin and a glass ionomer restoration.

### F. CLASS VI TYPE OF DENTAL CARIES

A class VI type of dental caries or restoration is not one of Black's original classifications. In Baum's text, it is defined as the cavity or defect found on the tips of cusps or along the incisal edges of incisors.<sup>9</sup> In Sturdevant's text, class VI caries includes lesions on the cusp tips of posterior teeth.<sup>10</sup> The resultant preparation for a class VI lesion conservatively follows Black's principles of cavity preparation, and the restoration of choice depends on size and location of the lesion and the need for strength and esthetics.



**FIGURE 10-40.** Class V restorations. **A.** Two buccal amalgams on teeth No. 29 and 30 (abbreviated BA). The extent of these amalgams is usually dictated by the extent of the caries. **B.** Class V buccal composite (arrows) on tooth No. 27 (abbreviated BC). If the shade of the material is excellent, these restorations are difficult to detect, and their surface grittiness felt by a dental instrument might be confused for incipient calculus formation. (Restorations by Gregory Blackstone, second-year dental student.)

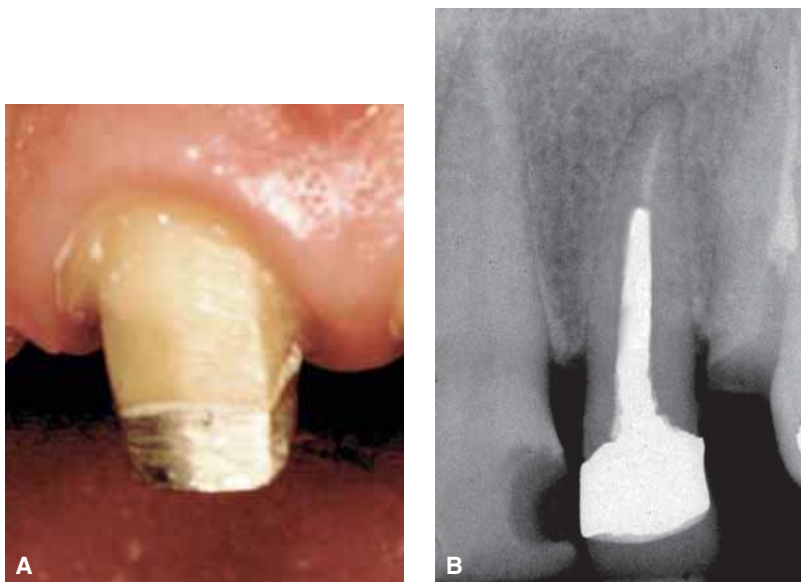
## SECTION VI

## RESTORING LARGE TOOTH DEFECTS AND TOOTH REPLACEMENT

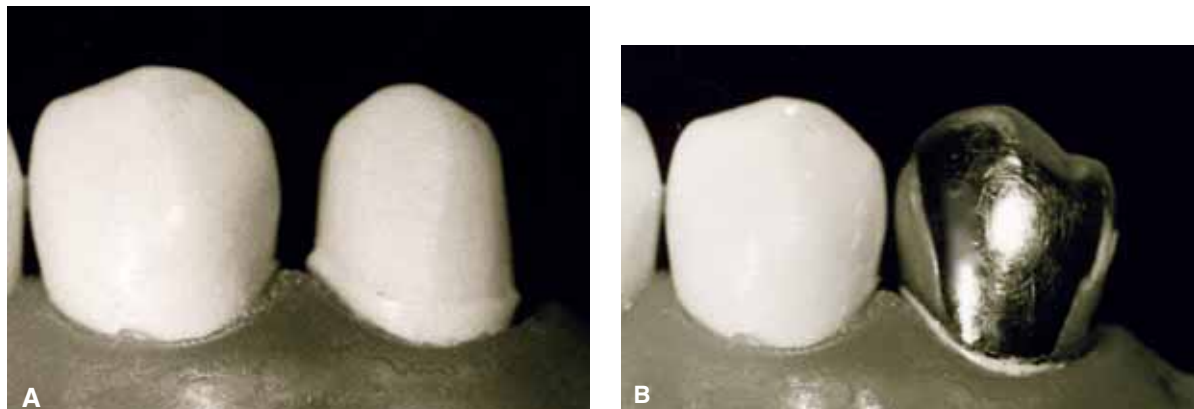
When a tooth is too badly broken down to be restored with a conservative restoration and only a thin shell of enamel remains, it may be necessary to remove decay and replace some or all of the lost tooth structure with amalgam or composite to develop a “core” of tooth and filling around which a complete crown can be constructed. The *core* restoration that replaces tooth structure prior to preparing a tooth for a crown may be called a restoration under crown (RUC) or amalgam under crown (AUC). When the remaining tooth crown is almost completely gone, a cast metal core (resembling a tooth prepared to receive a crown) must be designed with a metal *post*, which fits snugly into one of the previously endodontically treated and prepared root

canals. The post is necessary to provide retention. This restoration is called a **cast post and core** (Fig. 10-41).

On posterior teeth, a crown will sometimes be constructed entirely of cast metal and is called a **complete cast metal crown** (Fig. 10-42). To prepare a tooth for a complete crown, the previously restored anatomic tooth crown (or prepared core) is externally reduced with diamond burs to make room for the required thickness of the cast metal crown. The preparation usually extends gingivally beyond the core filling material, so that the crown margins end on sound tooth structure. Full cast metal crown preparations end at the gingival cavosurface with a rounded shape called a chamfer (Figs. 10-42A and 10-43A).

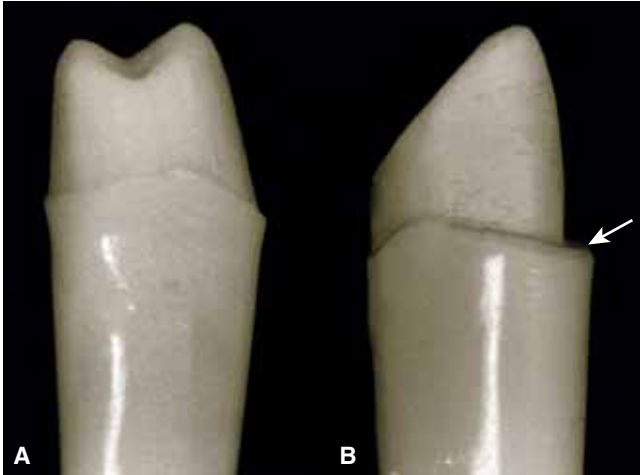


**FIGURE 10-41.** Cast post and core. **A.** The visible portion of a post and core is the **core** that can be seen forming the missing part of the crown preparation. **B.** The **post** can be seen on this radiograph extending well down within the root to provide retention for the crown that will be placed over the post and core.

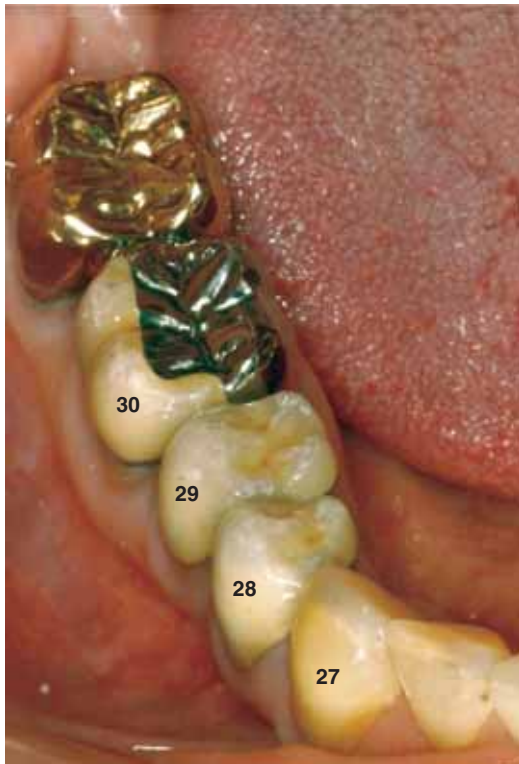


**FIGURE 10-42.** Complete cast metal crown. **A.** Crown preparation on tooth No. 20 for a full cast metal crown. The reduction at the gingival cavosurface is called a chamfer. **B.** The **complete cast metal crown** cemented in place.





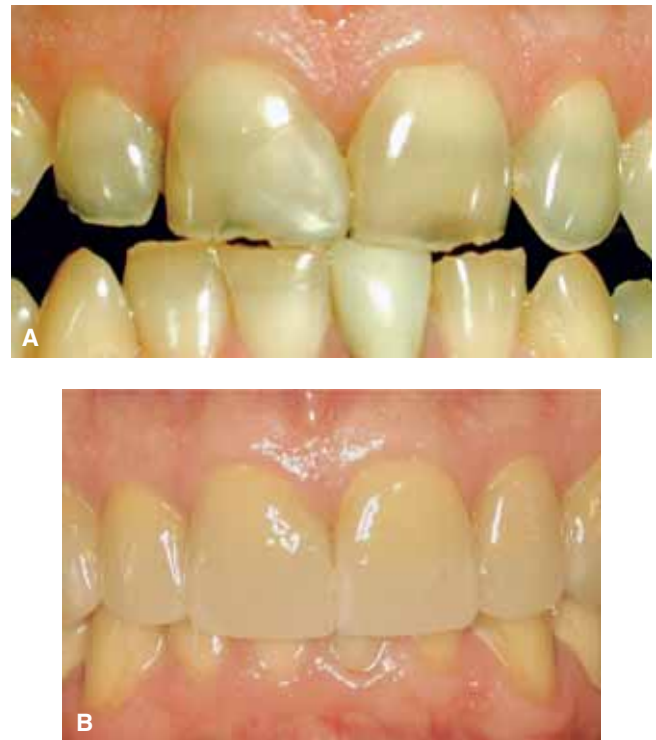**FIGURE 10-43.** Proximal views: Crown preparations with their facial surface toward the right. **A.** Full cast metal crown (no porcelain veneer) preparation on a mandibular premolar. **B.** Preparation on a maxillary canine that will have a facial fused porcelain veneer over metal to provide esthetics. Greater facial tooth reduction was necessary (arrow).



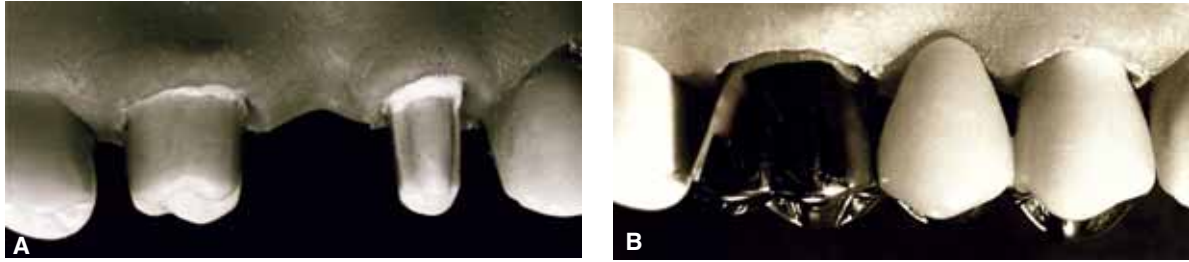
**FIGURE 10-44.** Types of crowns. Tooth No. 31 is restored with a **complete cast metal crown**; No. 30 is restored with a **metal ceramic restoration** (porcelain fused to metal crown), and Numbers 28 and 29 both have **metal ceramic crowns** (metal is not visible). (Photographs courtesy of Dr. Julie Holloway.)

When esthetics is a factor, especially on anterior teeth and maxillary premolars, further reduction of tooth structure is necessary on the facial surface to make room not only for the thin cast metal but also for an additional thickness of tooth-colored porcelain veneer, which can be fused onto the facial surface of the metal. This restoration is called a **metal ceramic restoration** (also called a porcelain fused to metal crown) and is seen on tooth No. 30 in *Figure 10-44*. Crowns gain retention from the nearly parallel walls that slightly converge toward the occlusal, accurate fit, and the cement. Another esthetic solution for a full coverage restoration is an **all ceramic restoration** (previously called a porcelain jacket crown). Teeth are prepared with a wide chamfer completely around the tooth. There is no internal metal support under the porcelain, permitting increased translucency that more closely resembles a natural tooth (seen on the maxillary incisor teeth in *Fig. 10-45*).

Even when little or no caries or breakdown is evident, a crown may be recommended if the tooth is cracked, or when needed to support an adjacent false tooth (pontic) that replaces a missing tooth. The crowned teeth and the replaced tooth or teeth together are called a **fixed dental prosthesis** (also called a fixed partial denture [FPD] or a bridge by many people)



**FIGURE 10-45.** **A.** Thin, badly damaged maxillary incisors. **B.** Same incisors after placing **all ceramic restorations** (porcelain full jacket crowns). (Photographs courtesy of Dr. Julie Holloway.)



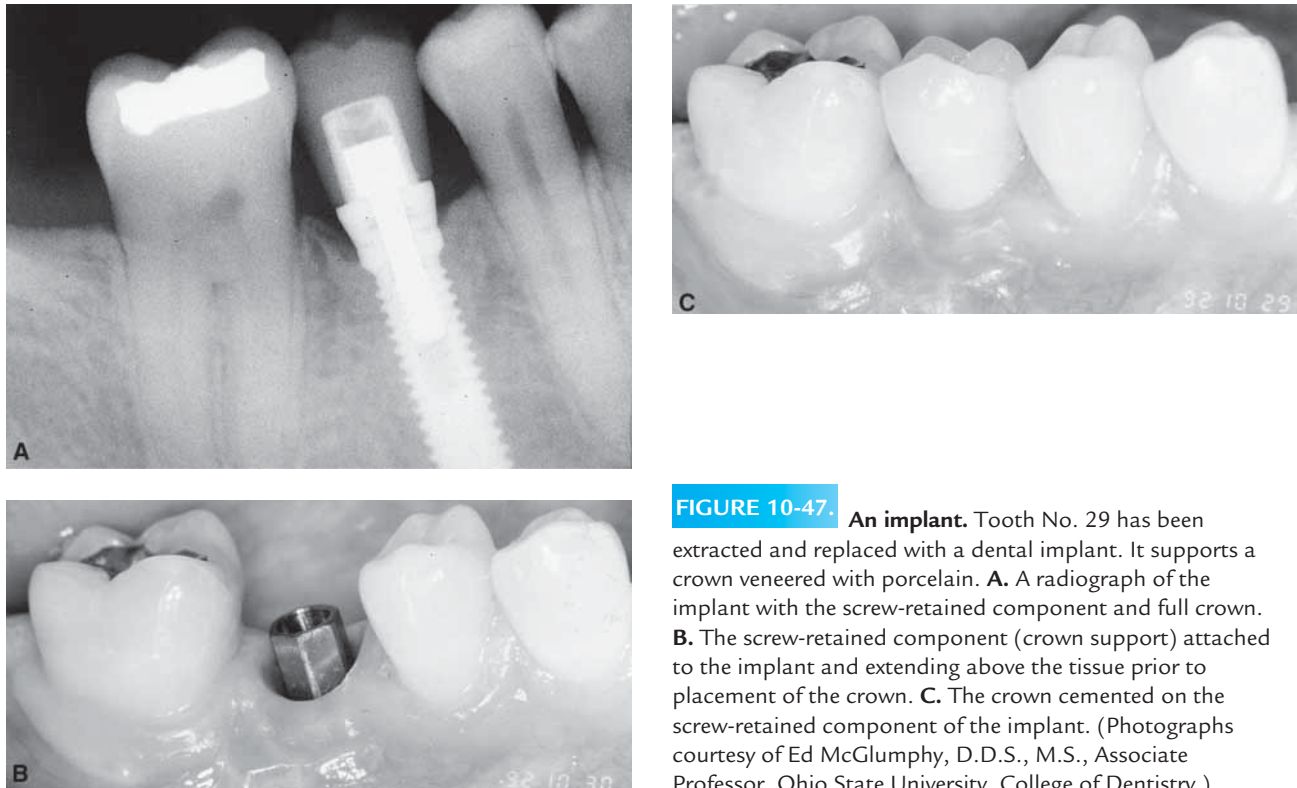
**FIGURE 10-46.** Fixed dental prosthesis also called a “bridge” by many persons. **A.** Buccal view of full crown preparation on tooth No. 3 (on left) and a crown veneer preparation on tooth No. 5 for the attachment of a bridge to replace tooth No. 4. **B.** The completed three-tooth fixed dental prosthesis (fixed partial denture or bridge) for replacing tooth No. 4. The premolar **retainer** (abutment tooth crown) and **pontic** (replacement tooth) in the photograph are restored with porcelain fused to metal. The molar retainer is covered with a complete cast metal crown.

(Fig. 10-46). The false tooth is called a **pontic**, and the teeth that are attached to and support the pontic are called the **abutment teeth**, which are covered by their crowns called **retainers**. A fixed dental prosthesis replacing tooth No. 4 with an abutment metal ceramic crown on tooth No. 5 and a complete cast metal crown on tooth No. 3 is shown in Figure 10-46B. The metal pontic replacing No. 4 is veneered with porcelain.

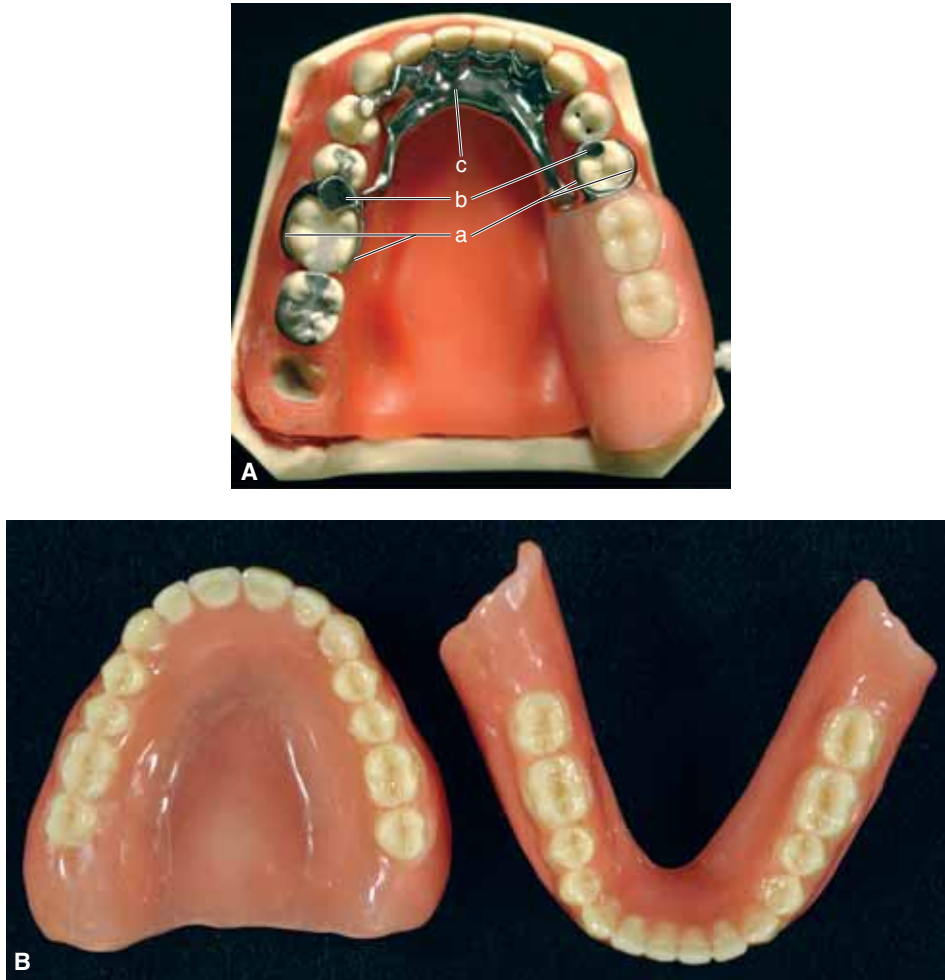
In the 1980s and 1990s, techniques for replacing lost teeth with **dental implants** (titanium alloy roots surgically embedded into the bone) were perfected and are now widely used (Fig. 10-47). A dental implant

involves embedding an artificial root (titanium alloy) into the bone. Three to six months after surgical placement, the embedded implant can be used to provide retention for a crown or a screw-retained fixed dental prosthesis, or to provide support for a removable partial denture. Ten-year success rates of 91% for dental implants in the mandible have been reported.<sup>28</sup>

Groups of lost teeth can also be replaced with multiple implants, a fixed dental prosthesis, or a **removable dental prosthesis** (also called a **removable partial denture**). One type of removable dental prosthesis is made of an acrylic saddle that adapts to the edentulous area,



**FIGURE 10-47.** An implant. Tooth No. 29 has been extracted and replaced with a dental implant. It supports a crown veneered with porcelain. **A.** A radiograph of the implant with the screw-retained component and full crown. **B.** The screw-retained component (crown support) attached to the implant and extending above the tissue prior to placement of the crown. **C.** The crown cemented on the screw-retained component of the implant. (Photographs courtesy of Ed McGlumphy, D.D.S., M.S., Associate Professor, Ohio State University, College of Dentistry.)



**FIGURE 10-48.** **A. Removable partial dental prosthesis** (also known as a removable partial denture) on a typodont replacing teeth numbers 30 and 31, and attached to abutment teeth numbers 19 and 29 using clasps (a) and rests (b) that retain and position the prosthesis in the mouth. The major connector (c) of the metal framework that connects the left and right sides of the prosthesis has a lingual plate that adapts to the lingual surfaces of all of the mandibular anterior teeth, providing additional stability. **B. Complete removable dental prosthesis** (also known as a complete denture). The upper denture on the left is designed to cover the palate, while the lower denture on the right is designed to maintain room for the tongue.

and the acrylic saddle contains the artificial replacement tooth crowns, and a framework (usually metal) that provides stability and retention (*Fig. 10-48A*). The part of the framework that connects the left and right sides of the prosthesis is called a **major connector**. The framework also contains **clasps**, which surround abutment teeth and adapt to these teeth just cervical to the height of contour facially or lingually to provide retention. It also has **rests** that are designed to adapt into small depressions (rest seats) that the dentist has prepared in the enamel of the marginal ridges and adjacent tooth structure in order to keep the partial denture from seating too firmly against the mucosa. When all teeth have been lost, a **complete removable dental prosthesis** (also called a **complete denture** or false teeth) can be constructed (*Fig. 10-48B*).

### LEARNING EXERCISE

Without looking at the key to each photograph of restorations in this chapter, identify the material used, the surfaces involved, and the abbreviation that could be used to denote the restoration. Do the same with extracted teeth that have existing restorations. Looking in your mouth using a mirror or in a friend's mouth, identify the classification of the existing restorations (according to Dr. G.V. Black). Note that some restorations are extended over more of the tooth than others. Could this be because the dentist extended the preparations, or was it due to the spread of caries? Do you suspect any areas of decay? (If so, check with a dentist.)

## Review Questions

Answer each of the following test items by selecting the correct answer, or answers, for each item.

- What is the class of decay found in the buccal pit of tooth No. 19?
  - Class I
  - Class II
  - Class III
  - Class IV
  - Class V
- Which material is more likely to be used for a conservative class III restoration (mesial and facial surfaces) on tooth No. 8?
  - Amalgam
  - Cast metal crown
  - Composite resin
  - Cast porcelain inlay
  - Cast metal onlay
- Caries in the lingual fossa of tooth No. 7 is an example of which class of caries?
  - Class I
  - Class II
  - Class III
  - Class IV
  - Class V
- Throughout the end of the 20th century, has occurrence of dental caries in children increased, decreased, or stayed about the same?
  - Increased
  - Decreased
  - Stayed about the same
- Which class(es) of caries occur(s) in posterior teeth but not in anterior teeth?
  - Class I
  - Class II
  - Class III
  - Class IV
  - Class V
- Which class(es) of caries occur(s) in anterior teeth but not in posterior teeth?
  - Class I
  - Class II
  - Class III
  - Class IV
  - Class V
- A point angle is the junction of how many cavity preparation walls?
  - One
  - Two
  - Three
  - Four
  - Five
- Which of the following are point angles in a conservative class I preparation (if it has not extended onto the buccal or lingual surfaces to include buccal or lingual grooves)?
  - Gingivobuccoaxial
  - Occlusobuccoaxial
  - Mesiobuccopulpal
  - Distolinguopulpal
  - Buccolinguopulpal
- Which of the following are line angles within a DO-A preparation?
  - Axiobuccal
  - Axiopulpal
  - Distopulpal
  - Distoaxial
  - Mesiopulpal

ANSWERS: 1—a; 2—c; 3—a; 4—b; 5—b; 6—c; 7—c; 8—c; 9—a, b, e

## Critical Thinking

- List as many types of restorations (and materials involved) as possible that could be used to restore small, and then large, defects on a **maxillary incisor**. First, start with as many combinations of surfaces and materials that might be used to restore the smallest areas of decay for each G.V. Black class of decay. Use words to describe the surfaces and materials, and then the abbreviations. Second, list the largest types of restorations appropriate to restore or replace these teeth. Add abbreviations where applicable.



## REFERENCES

1. DiOrio LP. Clinical preventive dentistry. East Norwalk, CT: Appleton-Century-Crofts, 1983.
2. Newbrun E. Problems in caries diagnosis. *Int Dent J* 1993;43:133–142.
3. Powell LV. Caries risk assessment: relevance to the practitioner. *JADA* 1998;129:349–353.
4. National Caries Program. The prevalence of caries in U.S. children, 1979–1980. NIH Publication No. 82-2245, December 1981.
5. Brown JL, Wall TP, Lazar V. Trends in total caries experience: permanent and primary teeth. *JADA* 2000;131:223–231.
6. American Dietetic Association. Position of the American Dietetic Association: oral health and nutrition. Available at [www.eatright.org/aoral.html](http://www.eatright.org/aoral.html)
7. Hicks MJ, Flaitz CM. Epidemiology of dental caries in the pediatric and adolescent population: a review of past and current trends. *J Clin Pediatr Dent* 1993;18:43–49.
8. Heinrich R, Heinrich J, Kunzel W. Prevalence of root caries in women. *Z Stomatol* 1989;86:241–247.
9. Baum L, Phillips RW, Lund MR. Textbook of operative dentistry. Philadelphia, PA: Saunders, 1995.
10. Robertson T. Sturdevant's art and science of operative dentistry. 4th ed. St. Louis, MO: C.V. Mosby, 2002.
11. Leinfelder KF. Posterior composite resins. *JADA* 1988;11(Special Issue):21E–26E.
12. Roulet JF. The problems associated with substituting composite resins for amalgam: a status report on posterior composites. *J Dent* 1988;16:101–113.
13. Ishikawa A. 10-year clinical evaluation of a posterior composite resin [Abstract 2178]. *J Dent Res* 1996;75:290.
14. Leinfelder KF. Posterior composite resins: the materials and their clinical performance. *JADA* 1995;126(May): 663–676.
15. Kugel G, Ferrari M. The science of bonding: from first to sixth generation. *JADA* 2000;131:20S–25S.
16. Shaw K. Root caries in the older patient. *Dent Clin North Am* 1997;41(4):763–793.
17. Nathanson D, Riis D. Advances and current research on ceramic restorative materials. *Curr Opin Cosmetic Dent* 1993;34–40.
18. Leinfelder KF. Porcelain esthetics for the 21st century. *JADA* 2000;131:47S–51S.
19. Leinfelder KF. Advances in bioresorbable materials. *JADA* 2000;131:35–41.
20. Black GV. A work on operative dentistry. Vol. 1. Chicago: Medico-Dental Publishing Company, 1908;203–234.
21. Hannigan A, O'Mullane DM, Barry D. Caries susceptibility classification of tooth surfaces by survival time. *Caries Res* 2000;34:103–108.
22. Radike AW. Criteria for diagnosis of dental caries. In: Proceedings of the Conference on the Clinical Testing of Cariostatic Agents. Chicago: American Dental Association, 1972.
23. Simonsen RJ. The clinical effectiveness of a colored sealant at 36 months. *J Dent Res* 1980;59:406.
24. Simonson RJ. Preventive resin restorations: three-year results. *JADA* 1980;100:535.
25. Craig RG, O'Brien WJ, Powers JM. Dental materials properties and manipulation. 3rd ed. St. Louis, MO: C.V. Mosby; 1983:33–44.
26. Harris NO, Cristen G. Primary preventive dentistry. Reston, VA: Reston Publishing, 1982.
27. Guirguis R, Lee J, Conry J. Microleakage evaluation of restorations prepared with air abrasion. *Pediatr Dent* 1999;21,6:311–315.
28. Rosenstiel S, Land M, Fujimoto J. Contemporary fixed prosthodontics. 3rd ed. St. Louis, MO: Mosby, Inc., 2001.

**ACKNOWLEDGMENTS**

This chapter was originally contributed by Connie Sylvester, R.D.H., B.A., M.S., former faculty of the Ohio State University and the University of Texas Schools of Dental Hygiene. Special thanks to Drs C.C. Dollens, Rudy Melfi, and Donald Bowers for their gracious assistance in obtaining several of the photographs and radiographs used in this chapter. Also, special thanks to the first-year dental hygiene students at Ohio State University, who brought in numerous anomalies and casts depicting such unusual teeth.

- I. Anodontia: absence of teeth
  - A. Total anodontia
  - B. Partial anodontia
- II. Extra or supernumerary teeth
  - A. Maxillary incisor area
  - B. Third molar area
  - C. Mandibular premolar area
- III. Abnormal tooth morphology
  - A. Abnormal crown morphology
  - B. Abnormal root morphology
  - C. Anomalies in tooth position
  - D. Additional tooth developmental malformations (and discoloration)
  - E. Changes in tooth shape due to injury after tooth eruption
  - F. Unusual dentitions

**OBJECTIVES**

This chapter is designed to help the learner perform the following:

- Identify variations from the normal (anomalies) for the number of teeth in an arch.
- Identify anomalies in crown morphology and, when applicable, identify the anomaly by name and give a possible cause (etiology).
- Identify anomalies in root morphology and, when applicable, identify the anomaly by name and give a possible cause (etiology).
- Identify anomalies in the alignment of teeth within an arch.



An anomaly [ah NOM ah lee] is a deviation from normal, usually related to embryonic development that may result in the absence, excess, or deformity of body parts.<sup>1</sup> Dental anomalies are abnormalities of teeth that range from such “common” occurrences as malformed permanent maxillary lateral incisors that are peg shaped, to such rare occurrences as complete anodontia (no teeth at all). Dental anomalies are most often caused by hereditary factors (gene related) or by developmental or metabolic disturbances. While more anomalies occur in the permanent than primary dentition and in the maxilla than the mandible, it is important to remember that their occurrence is rare. For example, only 1 to 2% of the population have some form of anodontia (one or more missing teeth), while another 1 to 2% have supernumerary (extra) teeth.<sup>2-4</sup> When specific deformities or abnormal formations of teeth occur with greater frequency, it is difficult to say whether the deviation is a “true” anomaly or simply a variation in tooth morphology.

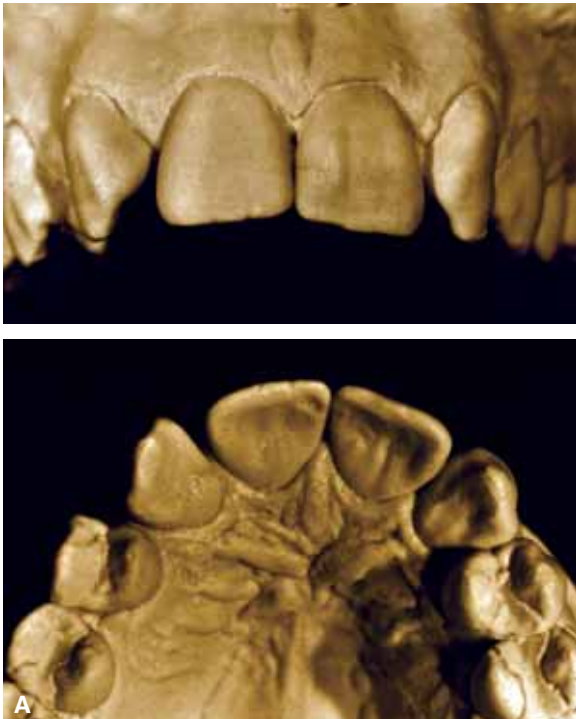
Familiarity with dental anomalies is essential to the clinical practice of dentistry and dental hygiene. Recognition and correct identification of anomalies are important when communicating with other dental team members, especially in the case of referral to or from another dental office. Additionally, a dental professional’s communication with the patient (or, in the case of a child, the parent) should reflect knowledge of abnormal oral conditions. Your assurance that the fused anterior teeth of their 4-year-old child occur with 0.5% frequency but rarely affect the number of teeth in the permanent dentition, will go a long way to promote the patient’s confidence in you and the office. Likewise, the informed patient who understands why the accessory cusp on the buccal of his maxillary or mandibular molar is more prone to decay than normal will likely be more receptive to home care instructions that are specific to his mouth and his needs. Finally, understanding the etiology (cause) of a specific anomaly is important in determining the

course of treatment, if any. Additional information related to the etiology of the following anomalies is found in the study of both oral histology/embryology and oral pathology.

## SECTION I ANODONTIA: ABSENCE OF TEETH

### A. TOTAL ANODONTIA

True anodontia [an o DON she ah] (or **total anodontia**) is the total congenital absence of a set of teeth. Total anodontia is characterized by the absence of the entire primary and secondary dentitions and is extremely rare. It is most often associated with a generalized congeni-



**FIGURE 11-1.** **Partial anodontia.** Mouths with congenitally missing maxillary lateral incisors. **A.** Notice that maxillary canines have moved into the spaces normally reserved for the missing lateral incisors. **B.** Maxillary lateral incisors are missing.

Note that within this chapter, the frequency of anomalies is included in brackets [like this]. These details do not need to be committed to memory but are useful references when considering how common each anomaly is.

tal deformation (a sex-linked genetic trait) involving the abnormal development of the ectoderm or outer embryonic cell layer. Faulty ectodermal development further affects such structures as hair, nails, sebaceous and sweat glands, and salivary glands.

### B. PARTIAL ANODONTIA

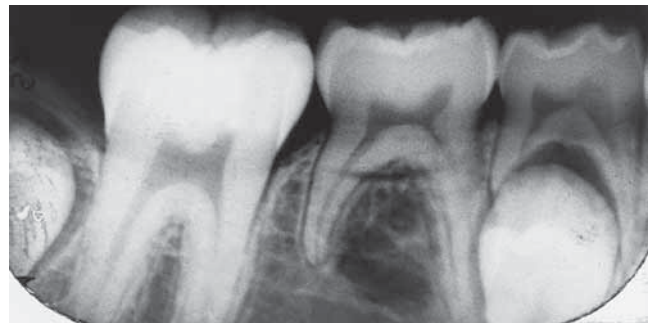
**Partial anodontia**, also referred to as congenitally missing teeth, involves one or more missing teeth from a dentition. Though not proven to be a hereditary trait, the tendency for missing the same teeth does run in families. Radiographs are required to assure that missing teeth are, in fact, missing and not just unerupted.

#### 1. MOST COMMONLY MISSING PERMANENT TEETH

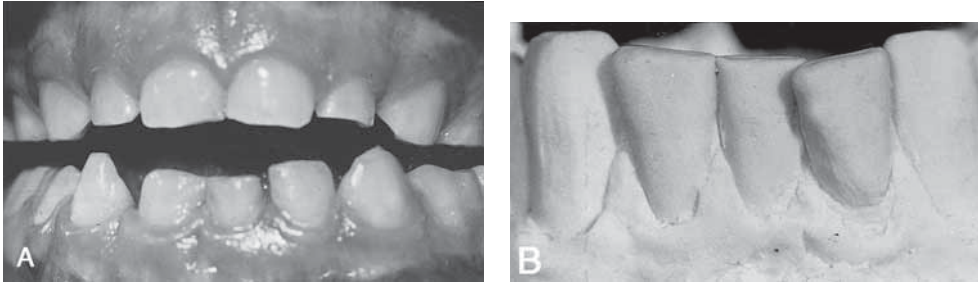
The most commonly missing permanent teeth are third molars, with the maxillary third molars absent from the dentition more often than the mandibular thirds.

#### 2. SECOND MOST COMMONLY MISSING TEETH

The permanent maxillary lateral incisors are the next most commonly missing teeth (*Fig. 11-1*). (Approximately



**FIGURE 11-2.** **Partial anodontia.** A radiograph revealing a missing mandibular second premolar. A routine radiographic examination of a 10-year-old female revealed that both mandibular right and left second premolars were missing. The first premolar is erupting between the roots of the primary first molar. The primary second molar is functional and its roots will probably not resorb resulting in a retained primary tooth. (Notice the fully erupted permanent first molar and the unerupted second molar partially visible at the extreme left.)



**FIGURE 11-3.** Partial anodontia. **A.** Congenitally missing primary mandibular central incisor. **B.** Congenitally missing permanent mandibular central incisor.

1 to 2% of the population are missing one or both of these maxillary incisors.<sup>4,5</sup>

### 3. THIRD MOST COMMONLY MISSING TEETH

The mandibular second premolars are the third most frequently missing permanent teeth (seen on a radiograph in *Fig. 11-2*) (with 1% of the popula-

tion missing one or both<sup>4</sup>). Some studies indicate the order of most commonly missing teeth to be third molars, maxillary and mandibular premolars, and then maxillary lateral incisors.<sup>6</sup> The most stable teeth in the permanent dentition, the canines, are the least likely to be absent from the dentition.<sup>6</sup>

Other congenitally missing permanent and primary teeth are evident in *Figure 11-3*.

## SECTION II

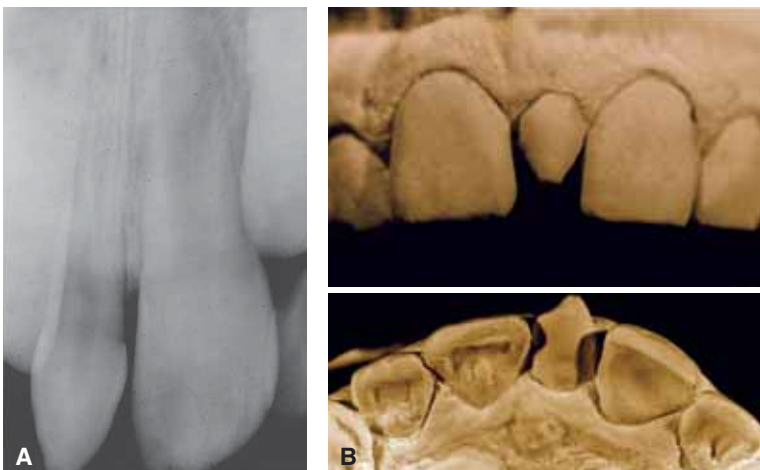
## EXTRA OR SUPERNUMERARY TEETH

Supernumerary teeth are teeth that form in excess of the normal dental formulas for each quadrant (primary quadrant: I-2, C-1, M-2; permanent quadrant: I-2, C-1, P-2, M-3). They occur in 0.3 to 3.8% of the population.<sup>7</sup> They are found in both permanent and primary dentitions, with 90% of all occurrences in the maxilla.<sup>8</sup> Specifically, the most frequent supernumerary specimens are found in one of two locations: maxillary incisor area or maxillary third molar region. One report states that supernumerary teeth occur eight times more often in the maxillary than mandibular regions and twice as frequently in men than in women.<sup>9</sup> (Another study of 50 patients from 16 months to 17 years of age found 20% of the supernumerary teeth

to be inverted.<sup>10</sup> Fourteen percent of these patients had multiple supernumerary teeth, and 80% of the extra teeth were in a lingual position relative to the dental arch.) Supernumerary teeth can vary considerably in size and shape.

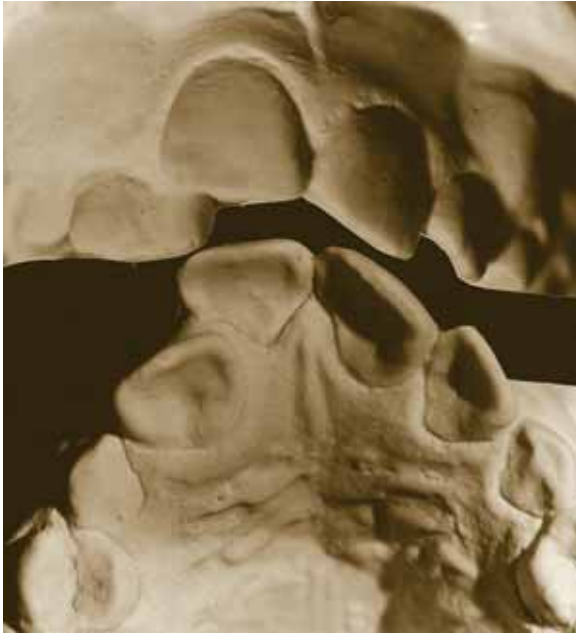### A. MAXILLARY INCISOR AREA

The most common location of supernumerary teeth in the permanent dentition is located at the maxillary midline (called a mesiodens). A **mesiodens** is a small supernumerary tooth that forms between central incisors. It has a cone-shaped crown and short root (*Fig. 11-4*). It may be visible in the oral cavity or remain



**FIGURE 11-4.** Supernumerary mesiodens. **A.** Radiograph showing a mesiodens next to the fully erupted permanent maxillary central incisor. **B.** Fully erupted mesiodens (facial and incisal views) that has a peg shape.



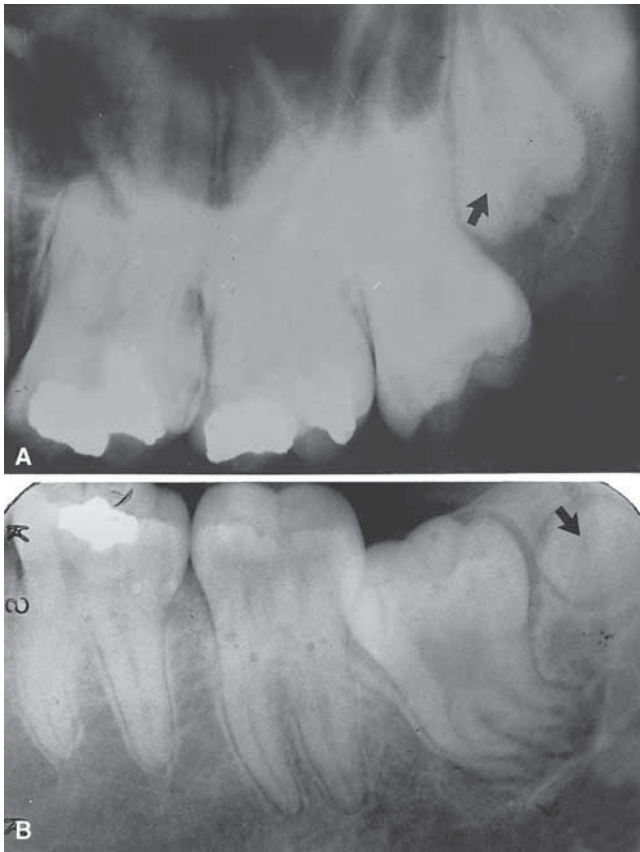


**FIGURE 11-5.** **Supernumerary tooth.** Maxillary dentition with three incisors shaped like central incisors (and only one shaped like a lateral incisor).

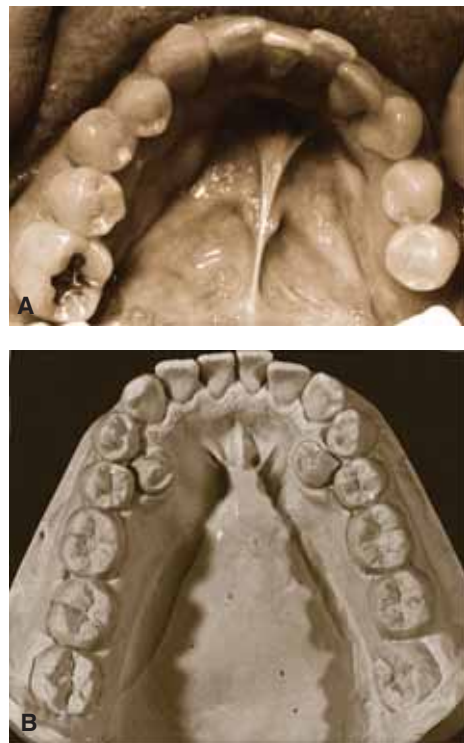unerupted. If unerupted, a diastema (space) may be present.<sup>11</sup> (One study of 375 children with mesiodens reports that they are often in an inverted position and rarely erupt into the oral cavity.<sup>9</sup> The prevalence of mesiodens in the permanent dentition in the Caucasian populations is 0.15 to 1.9%.<sup>12</sup>) Less frequently, supernumerary teeth may be positioned between central and lateral incisors or between lateral incisors and canines. An unusual occurrence of a person with what appears to be three maxillary central incisors is seen in *Figure 11-5*. The occurrence of supernumerary teeth in the primary dentition is low (approximately 0.5%).<sup>12</sup>

### B. THIRD MOLAR AREA

The presence of supernumerary teeth distal to the third molars is more common in the maxillary arch but does occur in the mandible. These supernumerary teeth are often called **distomolars**, **paramolars**, or **fourth molars**. These extra teeth rarely erupt into the oral cavity and, thus, are usually discovered through radiographs (*Fig. 11-6*).



**FIGURE 11-6.** **Paramolars, distomolars, or fourth (supernumerary) molars.** **A.** Radiograph showing a maxillary (fourth) distomolar. **B.** Mandibular (fourth) distomolar just distal to the permanent third molar.

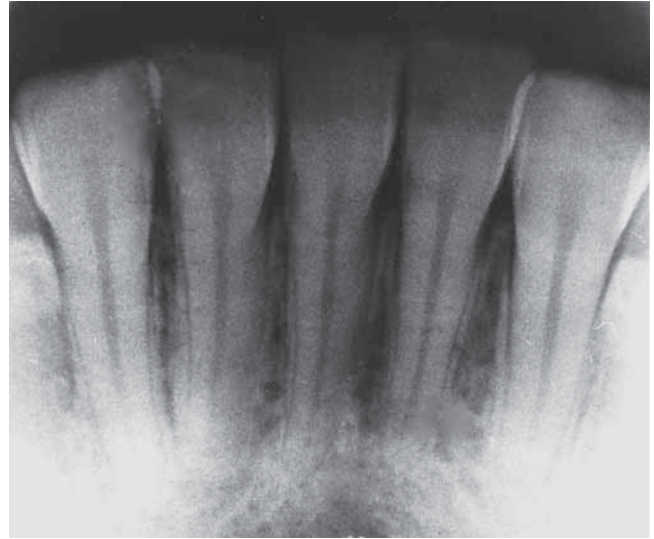


**FIGURE 11-7.** **Supernumerary teeth in mandibular premolar region.** **A.** View of extra mandibular first premolar (on the left side of the mouth) fully erupted but crowded. (Courtesy of Dr. L. Claman.) **B.** Extra mandibular first premolars on each side of the mandibular arch are positioned lingually.

### C. MANDIBULAR PREMOLAR AREA

The most common location for supernumerary teeth in the mandible is between the first and second premolar regions (Fig. 11-7). Supernumerary teeth appearing in this area generally resemble normal premolars in size and shape.<sup>13</sup>

Extra teeth may also form in other locations in the mouth. For example, a most unusual instance of three mandibular central incisors is seen in the radiograph in Figure 11-8.



**FIGURE 11-8.** Supernumerary mandibular central incisor.

Radiograph of the mandibular incisor region depicting three central incisors and two lateral incisors with no fused roots, and with normal pulp cavities.

## SECTION III

## ABNORMAL TOOTH MORPHOLOGY

### A. ABNORMAL CROWN MORPHOLOGY

Crown malformations may be seen clinically upon visual inspection of the oral cavity.

#### 1. THIRD MOLAR MALFORMATIONS

Maxillary third molars have the most variable crown shape of all permanent teeth followed by mandibular thirds. These anomalies can range in shape from a small peg-shaped crown to a multicusped, malformed version of either the first or second molar.

#### 2. PEG-SHAPED LATERAL INCISORS

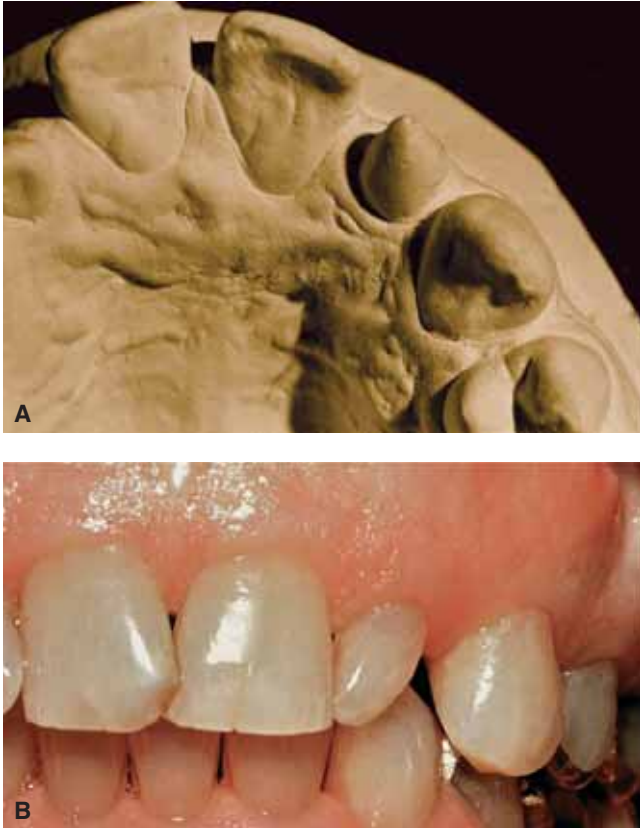
The most common anomaly in tooth shape in the anterior region of the secondary dentition is the **peg-shaped** (or cone-shaped) **lateral incisor** (Fig. 11-9) (which occur in 1 to 2% of the population).<sup>4</sup> The tooth is somewhat conical in shape and broadest cervically and tapers toward the incisal to a blunt point. Several studies of identical twins seem to indicate that missing and peg-shaped lateral incisor teeth may be varied expressions of the same genetic trait.<sup>14,15</sup> A most unusual occurrence is that of peg-shaped maxillary *central* incisors (Fig. 11-10). Recall that peg-shaped teeth develop from one lobe instead of the four lobes, which are normal for anterior teeth.

#### 3. GEMINATION OR TWINNING

**Gemination** or **twinning** results from the splitting (or twinning) of a single forming tooth. Since the tooth division is incomplete, the twinned crown appears doubled in width compared to a single tooth and possibly notched (Fig. 11-11). The single root is not split and has a *common pulp canal*. If the doubled tooth is counted as two teeth, the dental arch containing the geminated tooth will have an extra tooth beyond the normal number of teeth. It occurs more frequently in the primary dentition than in the permanent dentition and most commonly in the region of the maxillary incisors and canines.<sup>3</sup> (Gemination occurs in <1% of the population.) Note in Figure 11-12 that the wide, notched crowns of the anterior maxillary teeth of this Native American resemble teeth that have geminated.

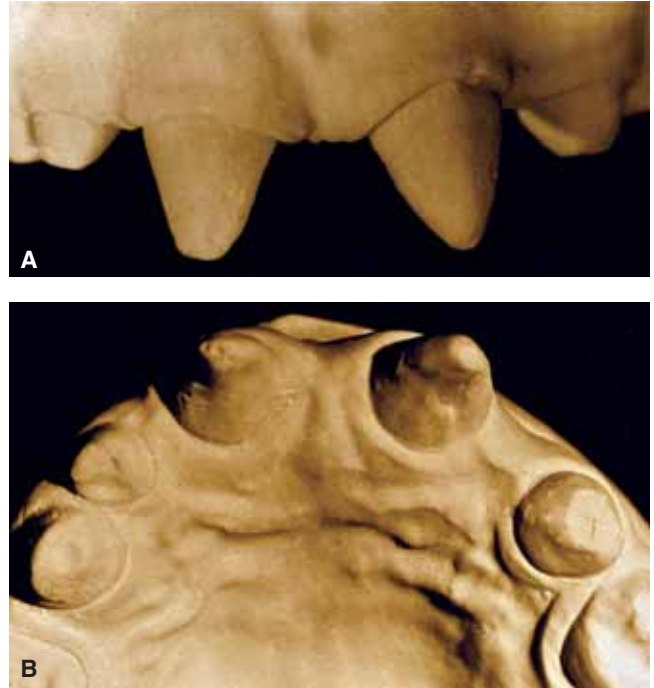
#### 4. FUSION

**Fusion** is the union of two adjacent tooth germs, always *involving the dentin*. Upon clinical examination, this condition appears similar to gemination since the fused teeth have one crown that appears doubled in width. However, unlike gemination, radiographs usually reveal two separate but fused roots (seen in Fig. 11-13

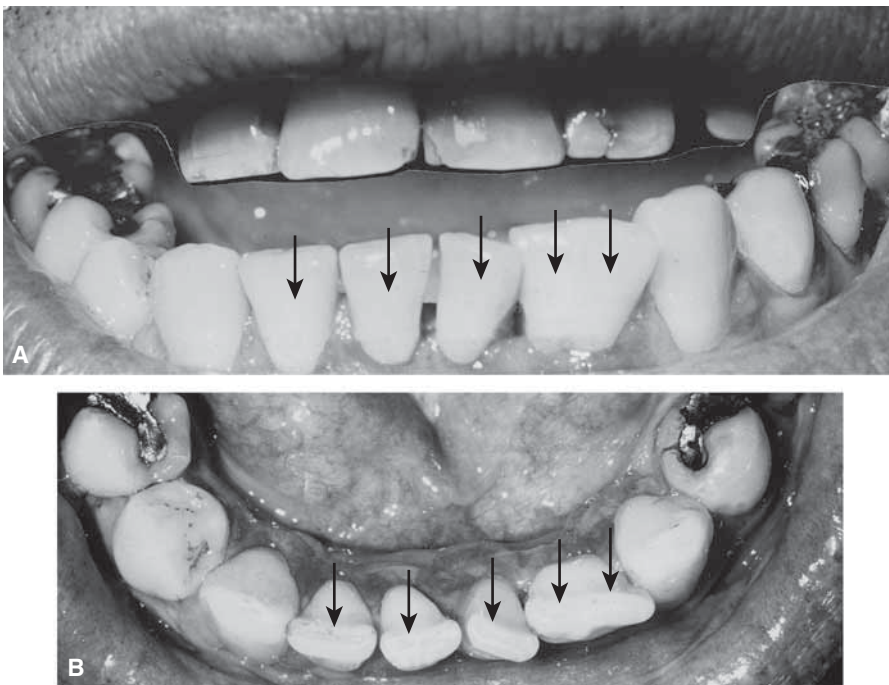


**FIGURE 11-9.** Peg-shaped maxillary lateral incisors.

**A.** Incisal view on a plaster model. **B.** A peg-shaped lateral incisor seen in the mouth.

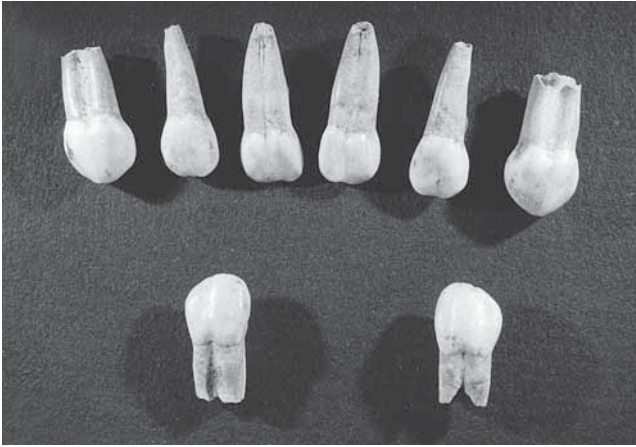


**FIGURE 11-10.** Peg-shaped maxillary central incisors, a very rare occurrence. **A.** Facial view. **B.** Incisal view showing both canines, one lateral incisor and the two peg-shaped central incisors.



**FIGURE 11-11.** Gemination. It appears that the left lateral incisor germ split or divided into two since, if that tooth is counted as two, there are five incisors (five arrows), one more than expected. The geminated tooth will generally have a single root and common pulp canal. The facial view is seen in **A**, and the incisal view of the same mouth is shown in **B**.

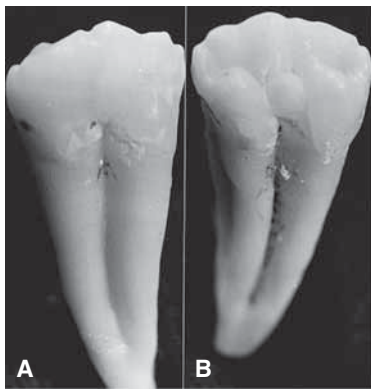




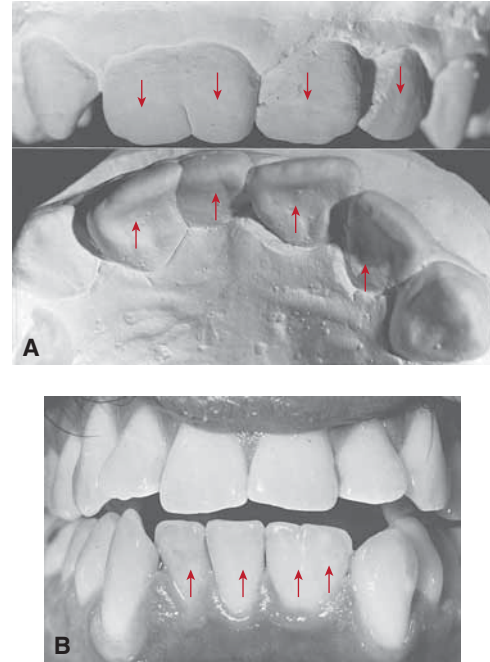
**FIGURE 11-12.** Deep labial grooves on all four maxillary central incisors and four canines (maxillary and mandibular) of a Native American. Notice the similarity in morphology of these wide, grooved incisor crowns with the crowns of geminated teeth.

with separate pulp chambers). Another way to differentiate fusion from gemination is to count the teeth in the arch. If the fused teeth are counted as two, the total number of teeth will reflect the normal number of teeth in that arch (Fig. 11-14). Like geminated teeth, fused teeth occur more commonly in the anterior portion of the mouth (but in <1% of the population) and more often in the primary dentition than in the permanent dentition. The mandibular incisor area is affected more often than the maxilla.<sup>2,3</sup>

It is thought that fusion is caused by pressure or force during development of adjacent roots. Many of the reports of fusion involve a supernumerary tooth joining with an adjacent tooth, such as the fusion of a



**FIGURE 11-13.** Fusion. Two teeth appearing similar to mandibular first premolars are fused together. Buccal aspect (A) and lingual aspect (B). Some separation between the roots is visible. There are two pulp canals.



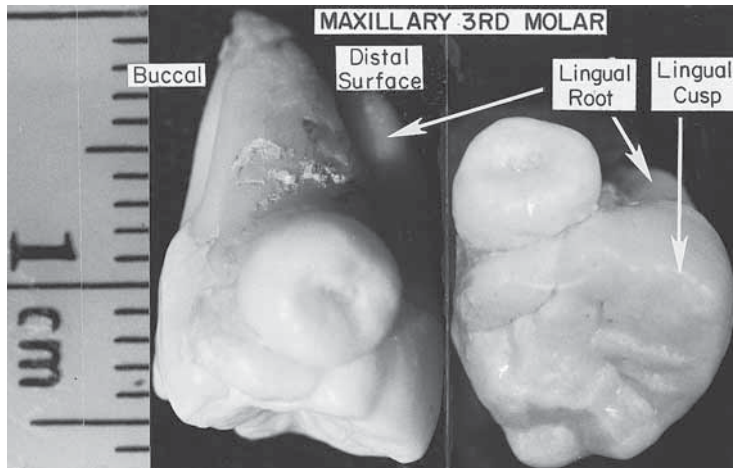
**FIGURE 11-14.** Fusion. **A.** If the tooth that is twice as wide as it should be is counted as two, the number of incisors is four (four arrows)—the expected number. Therefore, we suspect that the maxillary right lateral and central incisor have fused. Another possibility is the fusion of the central incisor and a supernumerary mesiodens, and the lateral incisor is congenitally absent. **B.** Four teeth (four arrows) appear like three crowns due to the fusion of a mandibular central and lateral incisor.

mandibular third and fourth molar seen in Figure 11-15, or the fusion of a maxillary lateral incisor and anterior supernumerary tooth.<sup>16-18</sup>

## 5. HUTCHINSON'S INCISORS AND MULBERRY MOLARS

When an infected mother passes syphilis on to her unborn baby, the child's teeth in both dentitions may develop with unusual shapes. Maxillary and mandibular incisors may be screwdriver shaped, broad cervically, and narrowing incisally, with a notched incisal edge. These teeth are referred to as **Hutchinson's incisors**. Note in Figure 11-16A that the crowns of Hutchinson's incisors resemble somewhat the notched crowns of fused incisors seen in Figure 11-14. Also, first molars in these dentitions may have occlusal anatomy made up of multiple tiny tubercles with poorly developed indistinguishable cusps. Because of the berry-like shape on the occlusal surfaces, these molars are called **mulberry molars** (Fig. 11-16B). Other manifestations of congenital syphilis may include scarring of the skin around the mouth, bone pain, and swelling of the joints.





**FIGURE 11-15.** Fusion. Unusual maxillary third molar with a supernumerary paramolar fused to its distal surface.

## 6. ACCESSORY CUSPS, TUBERCLES, OR RIDGES

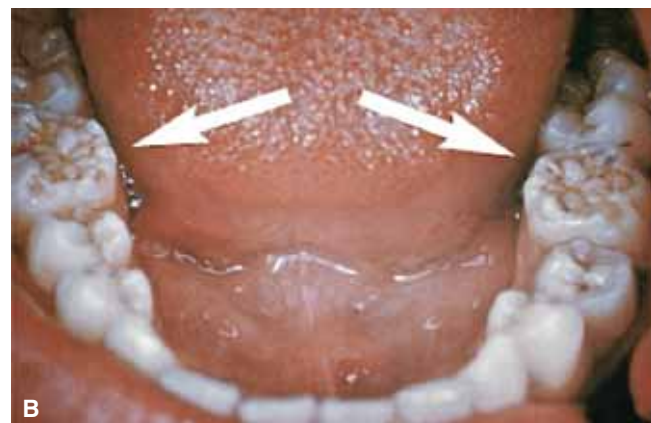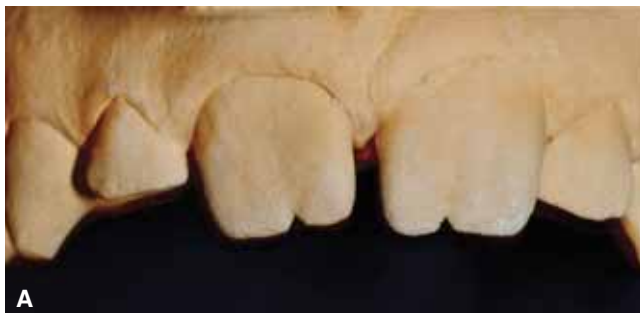Accessory enamel projections may result from developmental localized hyperplasia (increase in volume of tissue caused by growth of new cells), or crowded conditions prior to eruption may result in fusion of a supernumerary tooth, which may appear similar to an extra cusp (Fig. 11-17). A third lingual cusp may develop on mandibular molars on the lingual surface and is called a **tuberculum** [too BER ku lum] **intermedium** (Fig. 11-18). If this extra cusp were located on the distal marginal ridge, it would be called a **tuberculum sextum**.

A **talon cusp** (like a “claw of an animal”) is small projection on the lingual surface of maxillary or mandibular anterior permanent teeth (Fig. 11-19A). Frequently, the cusp has a pulp horn so that on a radiograph it may be mistaken for a supernumerary tooth superimposed over an anterior tooth, or a dens in dente (described later in this chapter). Removal of this cusp is often

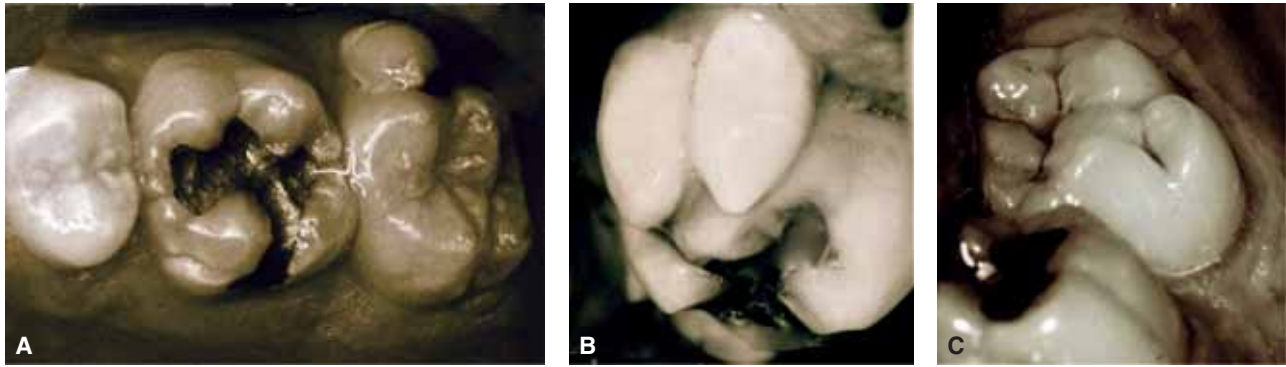
necessary because of its interference in jaw closure in the maximum intercuspal position. Since the pulp horn is present, endodontic treatment is usually required when this cusp is removed.<sup>2,19</sup> The malformed marginal ridge that extends over much of the lingual surface on the anterior tooth in Figure 11-19B resembles a talon cusp.

Mandibular second premolars vary in the number of lingual cusps, ranging from one to three. Occlusal morphology can vary greatly in terms of groove and fossa patterns established by the number of lingual cusps.<sup>20</sup> Recall that mandibular second premolars have three cusps (one buccal and two lingual) most of the time.

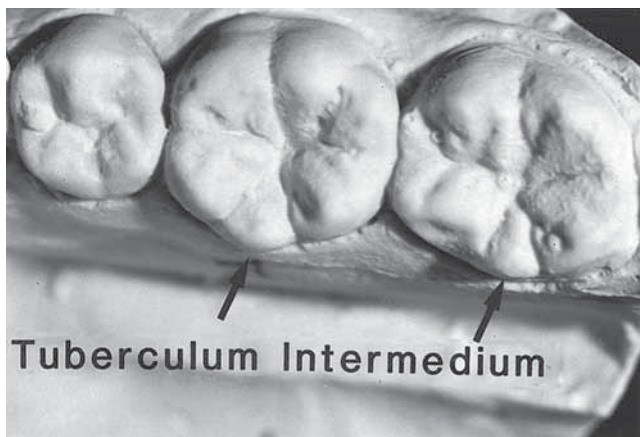
Teeth may also exhibit extra small enamel projections called **tubercles** (Fig. 11-20), or extra accessory cusps. Finally, an unusual prominent ridge is seen on the facial surface of a maxillary central incisor in Figure 11-21.



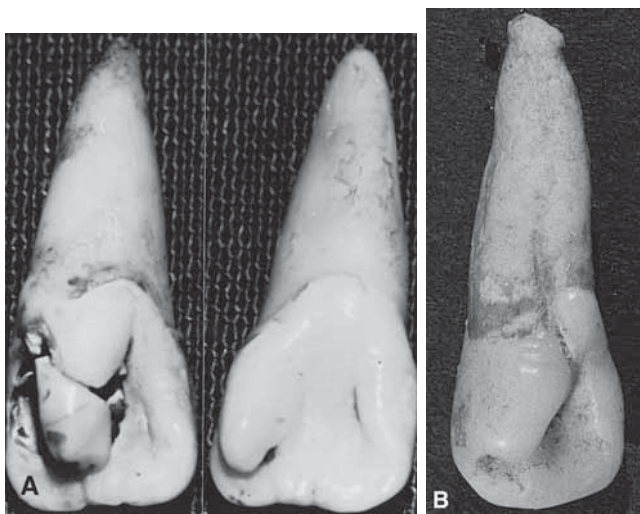
**FIGURE 11-16.** Effects of congenital syphilis on the teeth. **A.** Hutchinson's incisors are notched on these maxillary central incisors of a 9-year-old female. (Model courtesy of Dmitri J. Harampopoulos, D.D.S.) **B.** Mulberry molars (arrows) resemble the shape of a mulberry with many tubercles.



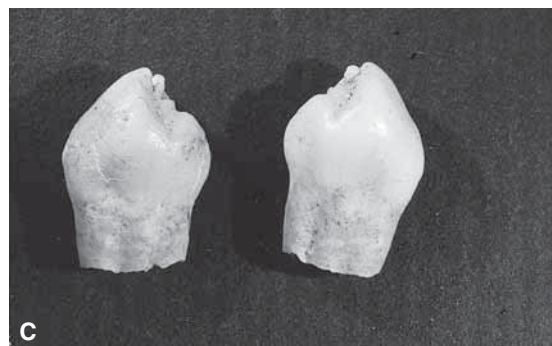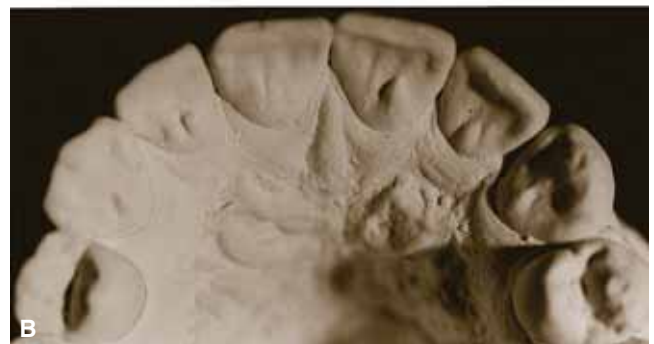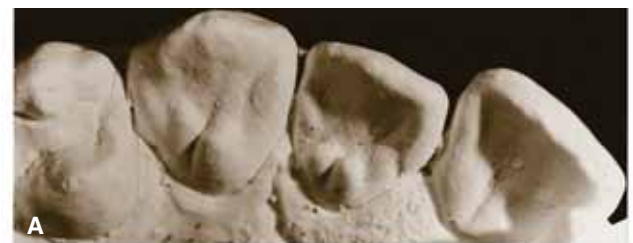**FIGURE 11-17. Extra cusps.** **A.** Extra buccal cusp (or a fused paramolar) seen on a maxillary second molar. **B.** Two extra cusps (or two fused paramolars) on the buccal surface of a maxillary molar. **C.** Extra buccal cusp on a mandibular molar.



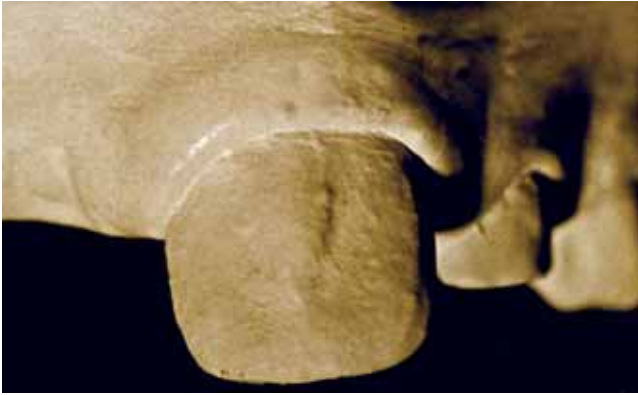**FIGURE 11-18. Tuberculum intermedium** (arrows). Mandibular first and second molars with extra, midlingual cusps called tuberculum intermedium.



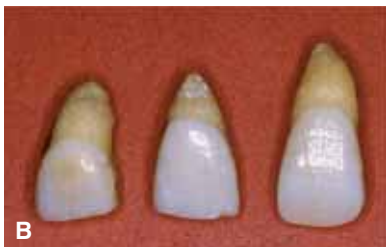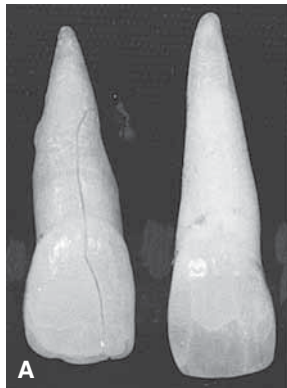**FIGURE 11-19. Talon cusps.** **A.** Lingual view of two maxillary central incisors with talon cusps. **B.** Lingual view of a maxillary left lateral incisor shows an enamel prominence in the lingual fossa that appears similar to a talon cusp. The lingual defects in all three of these teeth could affect the occlusion.




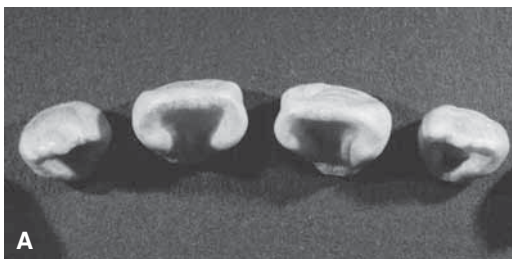
**FIGURE 11-20. Tubercles.** **A.** Elevations or tubercles (or cusplets) on the cingula of a canine and lateral incisor. **B.** Pronounced tubercles on the cingula of maxillary anterior teeth, most noticeable (due to lighting) on the patient's left central and lateral incisor and canine. **C.** Proximal views of both mandibular first premolars from a young Native American showing tubercles emanating from the triangular ridges of the buccal cusps.



**FIGURE 11-21.** Unusually prominent labial ridge on a secondary maxillary central incisor.



**FIGURE 11-22.** Variation in tooth size from macrodontia (very large) to microdontia (very small). **A.** Macrodontia of two very long incisors (one 34 mm long). **B.** Microdontia of three very short central incisors with dwarfed roots.



**FIGURE 11-23.** **A.** Shovel-shaped permanent incisors from a young Native American dentition (incisal view). Note the prominent marginal ridges on the lingual surface. **B.** The range of prominent labial ridges on double-shovel-shaped incisors varies from labial ridges (barely discernible) on the left to more prominent labial ridges on the right.

## 7. VARIATIONS IN TOOTH SIZE

**Microdontia** (very small, but normally shaped teeth) and **macrodontia** (very large, but normally shaped teeth) may occur as a single tooth, several teeth, or all teeth in a dentition.<sup>21</sup> Macrodontia most frequently involves incisors and canines, whereas microdontia affects maxillary lateral incisors and third molars.<sup>11,22,23</sup> Some examples of variation in size of teeth are shown in *Figure 11-22A* and *B*. One report described a maxillary canine 39 mm long and a maxillary first molar 31 mm long (compared to average lengths of 26.3 and 20.1 mm, respectively), both removed from a pituitary giant.<sup>21</sup>

## 8. SHOVEL-SHAPED MAXILLARY INCISORS

Possibly not a true anomaly, **shovel-shaped incisors** are a frequently occurring trait that reflect biologic differences between races.<sup>4</sup> The lingual anatomy includes a pronounced cingulum and marginal ridges that resemble the shape of a “shovel” (*Fig. 11-23A*). These teeth occur most frequently in Asian, Mongoloid, Arctic, and Native American populations. Double shoveling refers to the pronounced lingual marginal ridges, as well as prominent ridges on the mesial and distal portions of the labial surface as seen in *Figure 11-23B*.

## B. ABNORMAL ROOT MORPHOLOGY

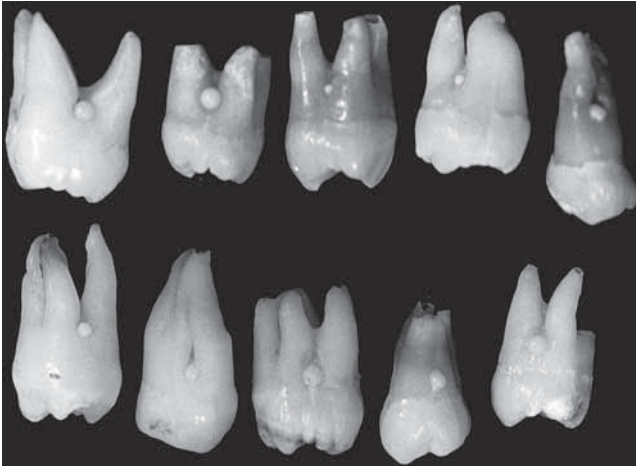
Root malformations are normally only obvious on radiographs, although close examination of extracted teeth reveals much variation.

### 1. ENAMEL PEARLS

**Enamel pearls** are small, round nodules of enamel with a tiny core of dentin. Since they are covered with enamel, they prevent the normal connective tissue attachment, may be felt with a probe and, consequently, may lead to periodontal problems in this region.

They are found most frequently on the distal of third molars and near the buccal root furcation of molars<sup>24</sup>





**FIGURE 11-24.** Enamel pearls on maxillary molar roots, many located near the furcation.

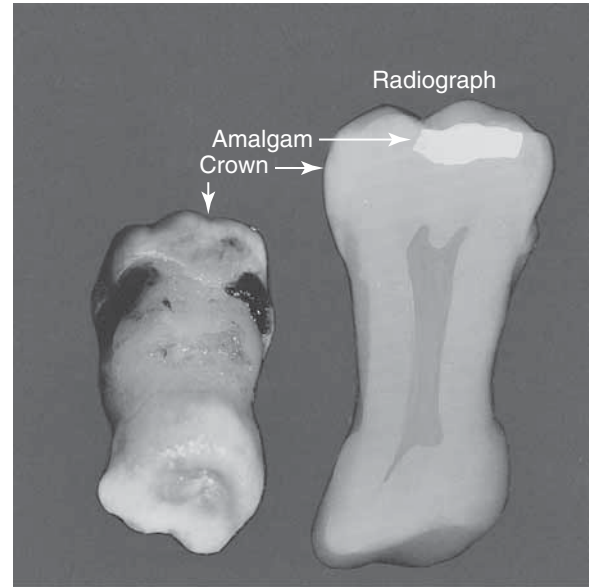
(Fig. 11-24). On a radiograph, enamel pearls appear as small round radiopacities (i.e., areas appearing light or white on the exposed film).

## 2. TAURODONTIA

In **taurodontia**, or so-called bull or prism teeth, the pulp chamber is very long, without a constriction near the cemento-enamel junction (Fig. 11-25). This occurs only in permanent teeth (with a frequency of <1 in 1000 among American Indians and some Arctic populations).<sup>25</sup> Taurodontia is caused by a disorganization of the calcified tissues and possibly occurs in dentitions subjected to heavy use.

## 3. DILACERATION

**Dilaceration** [die lass er A shun] is a severe bend or angular distortion of a tooth root (Fig. 11-26).<sup>26</sup> This unusual occurrence may be the result of a traumatic injury or of insufficient space for development, as is often the case with third molars (Fig. 11-27). Dilaceration is often observed in teeth with accessory roots. Historically, flexion is another term that has

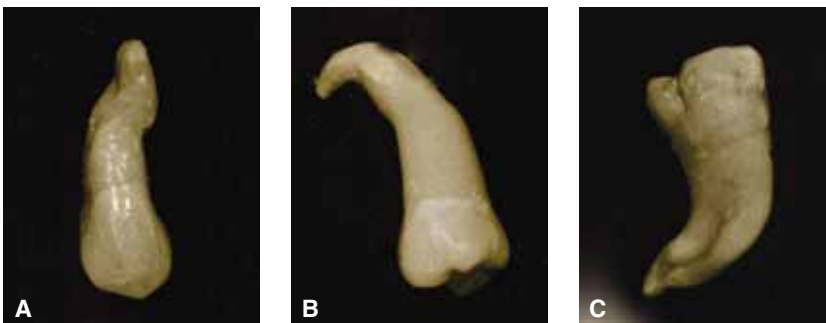

**FIGURE 11-25.** Taurodontia. Photograph of extracted tooth on left; radiograph on right. (Courtesy of Professor Rudy Melfi, D.D.S.)

been used to describe a sharp curvature or bend of a tooth root.

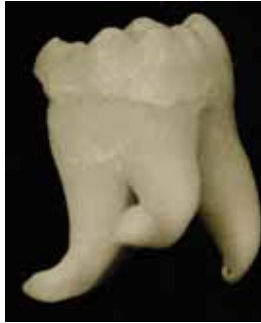## 4. DENS IN DENTE

**Dens in dente** (literally “tooth within a tooth”) is a developmental anomaly resulting from the invagination of the enamel organ within the crown of a tooth (seen in Fig. 11-28A). Clinically, it appears most often as a deep crevice near the cingulum region of incisors. Although most commonly found in maxillary lateral incisors, this condition has also been noted in maxillary central incisors and in mandibular incisors. On a radiograph, dens in dente appears as a mass of elongated enamel within the dentin of a normal-sized tooth (Fig. 11-28B). Usually, it appears in the coronal third of the tooth but may extend the entire root length. Often peg-shaped lateral incisors, with failure of mesial and distal lobes to develop, are found to have dens in dente



**FIGURE 11-26.** Dilaceration. A, B, and C. Three teeth with dilaceration of the root.



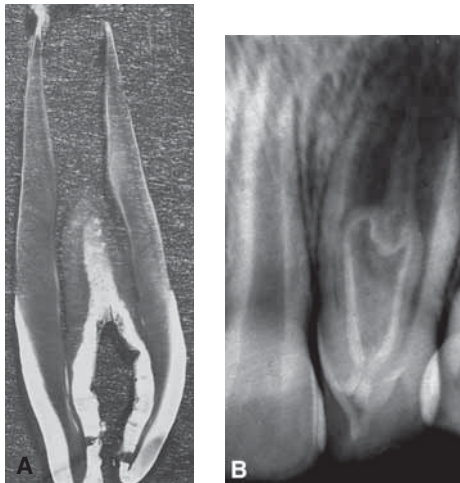


**FIGURE 11-27.** Dilaceration (severe) of the roots of a mandibular molar.

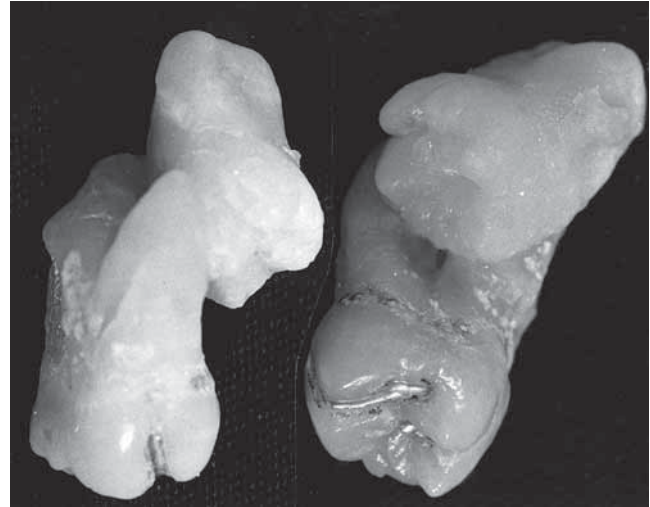
upon radiographic examination. (Their occurrence is from 1 to 5% of the population.<sup>2</sup>)

## 5. CONCRESCENCE

**Concrescence** [kon KRES ens] involves the superficial fusion or growing together of only the cementum of two adjacent tooth roots (*Fig. 11-29*). Unlike fusion, these teeth usually become joined after eruption into the oral cavity due to the close proximity of the roots and excessive cementum deposition.<sup>6</sup> This anomaly occurs most frequently in the maxillary molar region.



**FIGURE 11-28.** **Dens in dente** (“tooth within a tooth”) is caused by an invagination of the epithelium of the enamel organ before the formation of hard tissue. **A.** A faciolingual, very thin cross section of a maxillary lateral incisor with a dens in dente (tooth within a tooth). The defect within the tooth that connects with the lingual pit is seen here and may be an area where dental decay can occur. **B.** Radiograph of a dens in dente on a maxillary right central incisor. (Courtesy of Professor Rudy Melfi, D.D.S.)



**FIGURE 11-29.** **Concrescence** is the junction or joining of cementum between adjacent teeth. Here, the cementum of a maxillary first molar is joined to the cementum of an adjacent second molar. **Left:** Lingual view. **Right:** Disto-occlusal aspect with the buccal toward the right.

## 6. DWARFED ROOTS

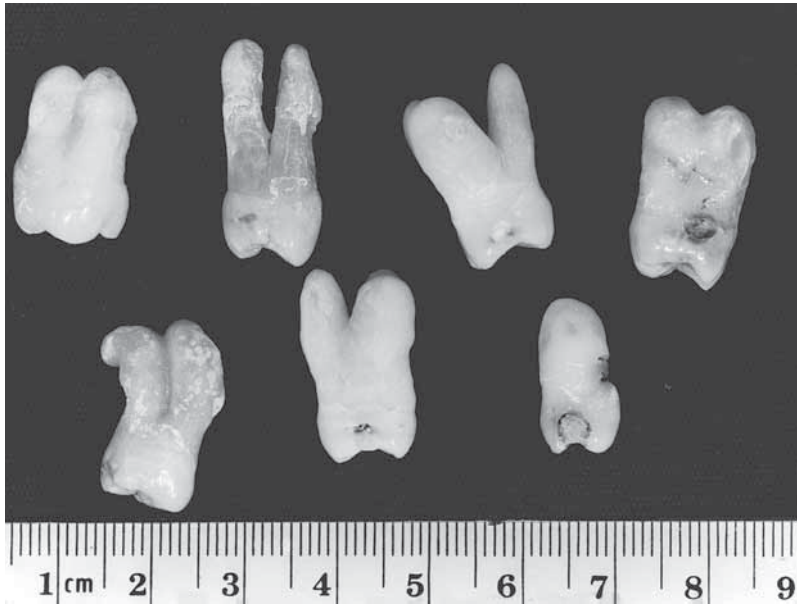Maxillary teeth often exhibit normal-sized crowns with abnormally dwarfed (short) roots (seen in *Fig. 11-22B*). The incisal edges of maxillary teeth with dwarfed roots are often displaced lingually (as also occurs on mandibular incisors). This condition is often hereditary; however, isolated or generalized dwarfing of roots may also result from orthodontic movement of the teeth (with braces) when the movement has occurred too rapidly.

## 7. HYPERCEMENTOSIS

**Hypercementosis** is the excessive formation of cementum around the root of a tooth after the tooth has erupted (*Fig. 11-30*). It may be caused by trauma, metabolic dysfunction, or periapical inflammation. Excess cementum may actually form a thin layer that connects adjacent roots, similar to the thin tissue that connects the “toes” on the webbed foot of a duck.

## 8. EXTRA (ACCESSORY) ROOTS

Usually occurring in teeth whose roots form after birth, accessory roots are probably caused by trauma, metabolic dysfunction, or pressure. Third molars are the multirooted teeth most likely to exhibit accessory roots (*Fig. 11-31A*).<sup>2</sup> Other molars may also develop extra roots, as seen on a mandibular molars in *Figure 11-31B* and *C*. The single-rooted teeth most likely to have an

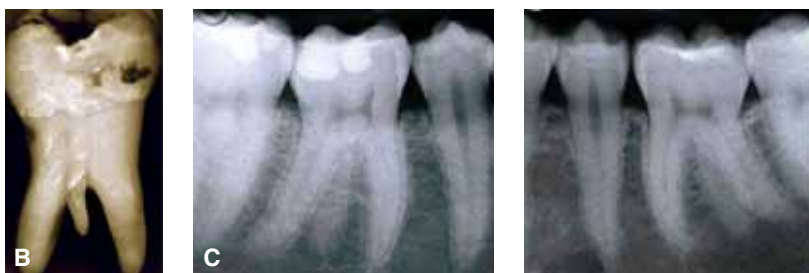
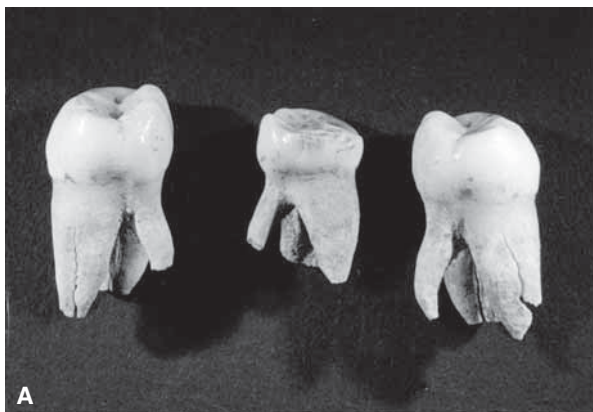
**FIGURE 11-30.** Hypercementosis or excess cementum thickness is evident on a variety of teeth.

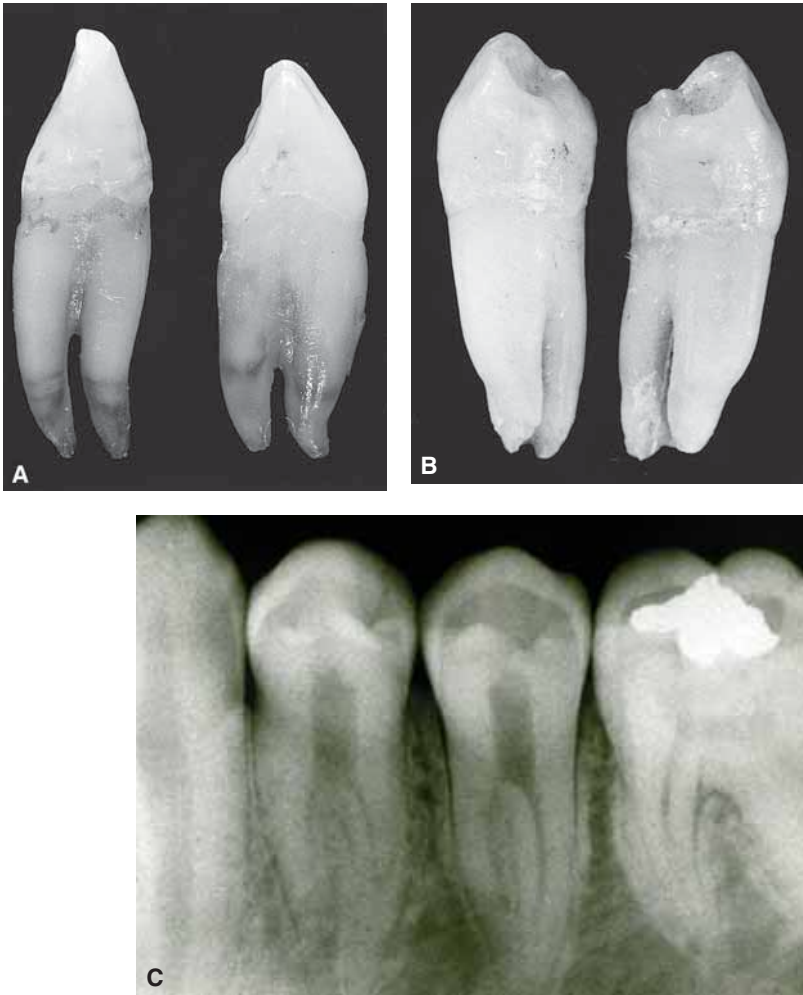
extra root are the mandibular canines and premolars. Two roots (one facial and one lingual) are found rarely enough on mandibular canines to be interesting but frequently enough not to be amazing (*Fig. 11-32A*). Mandibular first premolars may also exhibit a bifurcated root, one buccal, and one lingual (*Fig. 11-32B*), a condition less common for these teeth than for mandibular canines. A rare occurrence of two roots on mandibular

premolars (one mesial and one distal) is evident in the radiographs in *Figure 11-32C*. (A Japanese study of 500 mandibular first premolars found that this type of bifurcation occurred in 1.6% of Japanese teeth. These researchers also found one very rare specimen with three roots, two buccal and one lingual.<sup>27</sup>)

A very unusual maxillary first premolar with three roots (two buccal and one lingual) similar to the



**FIGURE 11-31.** Extra roots. **A.** Three examples of distolingual extra (accessory) roots in a young Native American: two permanent contralateral first mandibular molars and a primary second molar. **B.** Secondary mandibular left second molar with extra root-like appendage in the furcation area. **C.** Two radiographs showing a right and left mandibular first molar, each with three (instead of two) roots.



**FIGURE 11-32. Unusual bifurcated roots.** **A.** Two mandibular canines with a bifurcated root (one facial and one lingual). **B.** Two mandibular right first premolars with bifurcated roots, a condition that is less common on this tooth than on mandibular canines. **C.** Radiograph showing both first and second mandibular premolars with mesial and distal roots. This mesiodistal split is quite rare. A more common occurrence is for mandibular first premolars to have their root divided buccolingually (as in **B**).

roots of a maxillary molar is seen in *Figure 11-33*. The somewhat rare occurrence of a primary maxillary canines with their root divided mesiodistally is shown in *Figure 11-34*.<sup>21,28–33</sup> There have also been a number of reports of bifurcated roots on primary maxillary canines: five discovered from routine radiographic examination and the sixth on a routine dental recall examination.<sup>28–33</sup>

## C. ANOMALIES IN TOOTH POSITION

### 1. UNERUPTED (IMPACTED) TEETH

Unerupted teeth are embedded teeth that fail to erupt into the oral cavity because of a lack of eruptive force. **Impacted teeth**, on the other hand, fail to erupt due to mechanical obstruction, often related to the evolutionary decreasing size of modern man's jaw. The most common teeth to be impacted are maxillary and mandibular third molars (*Fig. 11-35*) and maxillary canines.<sup>2,4,34</sup> (At least 10% of the population have impacted teeth.)

### 2. MISPLACED TEETH (TRANSPOSITION)

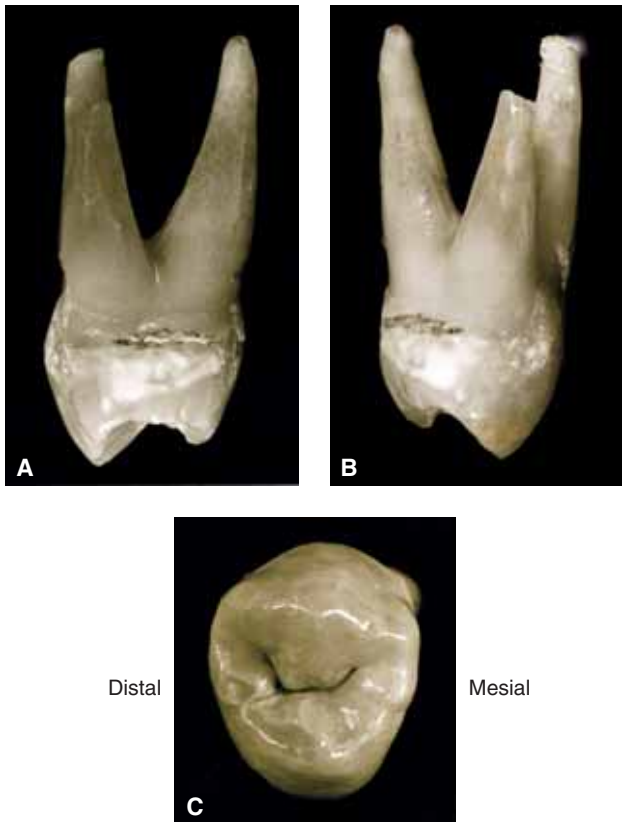
Occasionally, the cells that form a tooth (tooth buds) seem to get out of place, causing teeth to emerge in unusual locations. The most common tooth involved is the maxillary canine seen in *Figure 11-36* (20 of 25 cases reported),<sup>35</sup> followed by the mandibular canine (*Fig. 11-37*). Maxillary canines can even be transposed to the central incisor region.<sup>36,37</sup>

### 3. TOOTH ROTATION

Rotation is a rare anomaly, most common for the maxillary second premolar (*Fig. 11-38*), sometimes the maxillary incisor, first premolar, or mandibular second premolar.<sup>38</sup> A tooth may be rotated on its axis by as much as 180°.

### 4. ANKYLOSIS

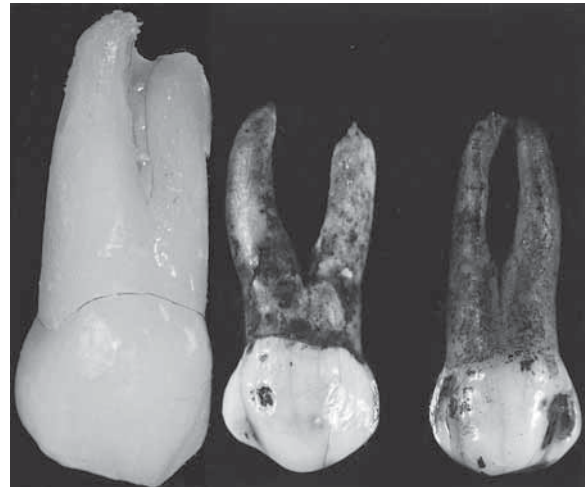**Ankylosis** [ang ki LO sis] may be initiated by an infection or trauma to the periodontal ligament, resulting in the loss of its periodontal ligament space so the tooth root is truly fused to the alveolar process or bone. These teeth



**FIGURE 11-33. Unusual trifurcation on a maxillary premolar.**

Three views of a maxillary right first premolar with a normal-looking crown but with three roots: two buccal and one lingual root (mesiobuccal, distobuccal, and lingual). These roots somewhat resemble those found on maxillary molars. **A** is the mesial view, **B** is the distal view, and **C** is the occlusal view.

erupt into the oral cavity but after ankylosis, fail to reach occlusion with the opposing arch and appear shorter than adjacent teeth in its arch. Many times, ankylosis of a primary tooth occurs when the permanent successor is missing. Primary mandibular second molars most often

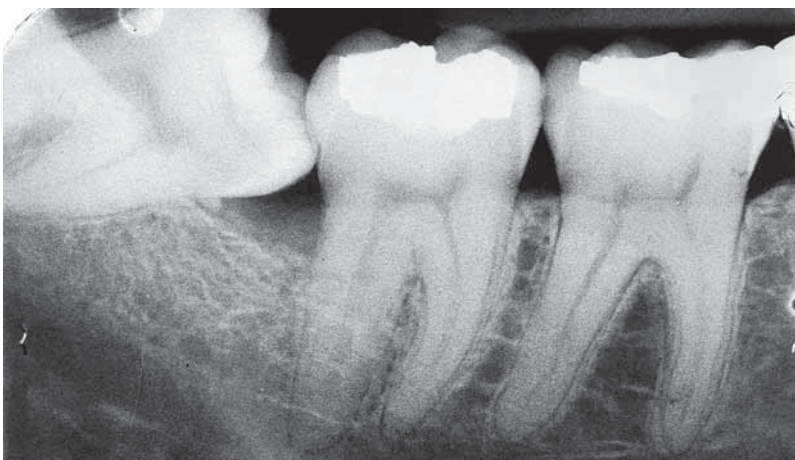

**FIGURE 11-34. Unusual bifurcation** seen on buccal views of primary maxillary canines.<sup>41</sup> The left tooth was extracted from a 9-year-old African American child (mesial surface is to the right). The middle and right teeth came from a 5-year-old Native American child in Woods County, Ohio, believed to be 2580 years old. Mesial sides face each other. (Courtesy of Dr. Ruth B. Paulson.)

fail to continue erupting as the jaw grows. Consequently, the ankylosed tooth will be 2 to 4 mm short of occluding with an opposing tooth.

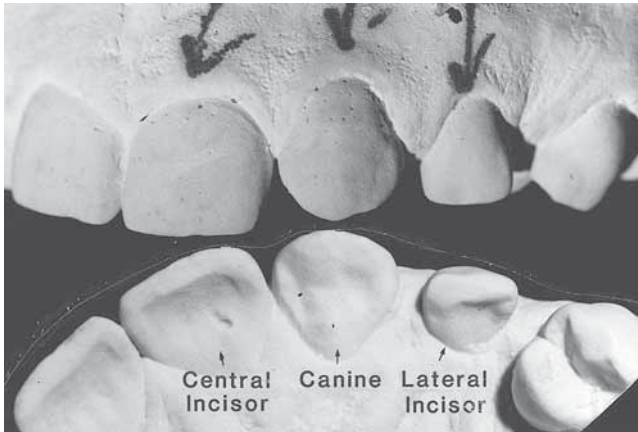
#### **D. ADDITIONAL TOOTH DEVELOPMENTAL MALFORMATIONS (AND DISCOLORATIONS)**

Other tooth malformations may be related to heredity or injury during formation and therefore may affect many teeth rather than just one or two specific teeth. These conditions are not anomalies, but dental professionals should be able to distinguish them from other anomalies.



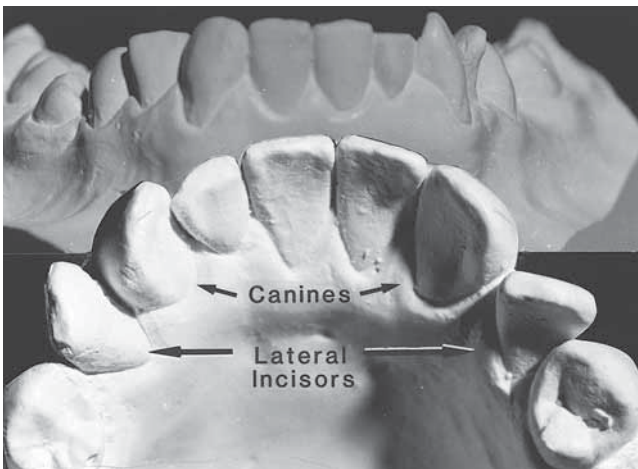
**FIGURE 11-35. Impacted mandibular third molar.** Because of its horizontal position, it is mechanically locked beneath the distal bulge on the second molar.



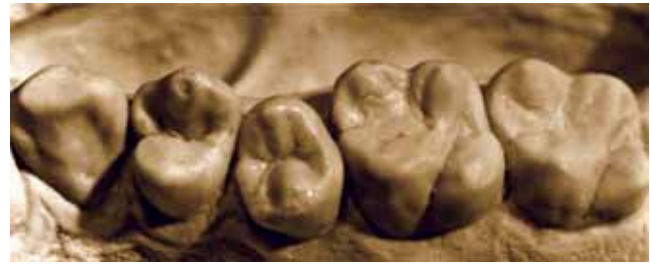

**FIGURE 11-36.** Switched positions for the permanent left maxillary lateral incisor and canine.

There are several terms you need to be familiar with in order to understand this section. First, the suffix “-plasia” refers to formation or development. **Dysplasia** is a generic term that indicates abnormal development. Dysplasia can result from too little mineral content being incorporated (**hypomineralization**) or too little calcium (**hypocalcification**) incorporated into enamel or dentin. **Hypoplasia** is a form of dysplasia that refers to an incomplete formation of a tissue. Dysplasia of the enamel or dentin can result from a number of factors during tooth formation, such as taking in *too much* fluoride, administration of tetracycline antibiotic, congenital syphilis, or injury to the tooth.



**FIGURE 11-37.** Unusual order of teeth. Bilaterally misplaced mandibular canines and lateral incisors, a rare occurrence. Also note the small, retained left primary lateral incisor.



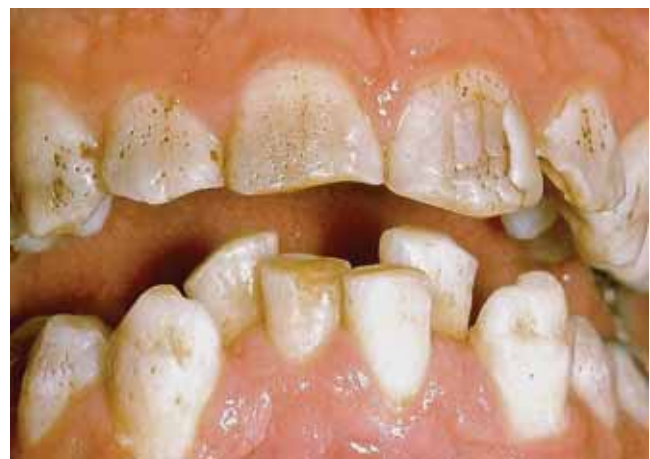**FIGURE 11-38.** Rotation of a secondary maxillary second premolar with its buccal surface rotated 180° so that it is now facing the lingual.

## 1. ENAMEL DYSPLASIA

**Enamel dysplasia** is a term used to describe a disturbance in the enamel-forming cells (ameloblasts) *during early enamel formation*. Enamel dysplasia may be hereditary (as with amelogenesis imperfecta) or could result from systemic causes during early tooth formation (such as exposure to a high fever, nutritional deficiencies, or an *excess amount* of fluoride) or local disturbances (such as trauma or periapical infection). Generally, variations in color (from white to yellow and brown) or variations in morphology (such as pitting or roughened enamel) can result. Several examples of enamel disturbances are presented here.

### a. Amelogenesis Imperfecta

**Amelogenesis imperfecta** [ah mel o JEN e sis im per FEC ta] is a hereditary disorder that affects the enamel formation of both dentitions (Fig. 11-39). (“Amelo-” refers to the ameloblasts or enamel-forming cells, and “genesis”



**FIGURE 11-39.** Amelogenesis imperfecta is a hereditary disorder affecting enamel formation. (Courtesy of Carl Allen, D.D.S., M.S.D.)

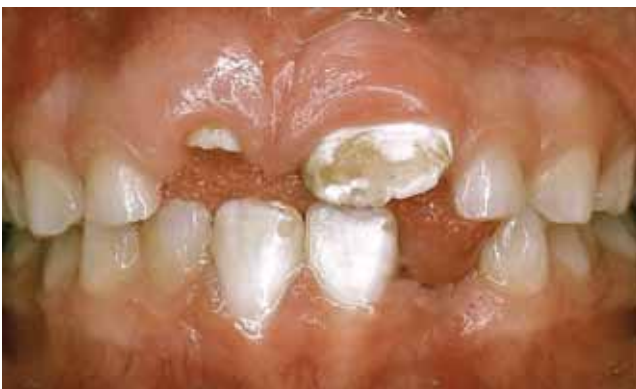refers to the beginning formation of these cells. The word “imperfecta” means imperfect.) The partial or complete lack of enamel results in rough yellow to brownish crowns that are susceptible to decay. This condition is rare (with an incidence in the United States of 1 in 15,000<sup>2</sup>).

### b. Fluorosis

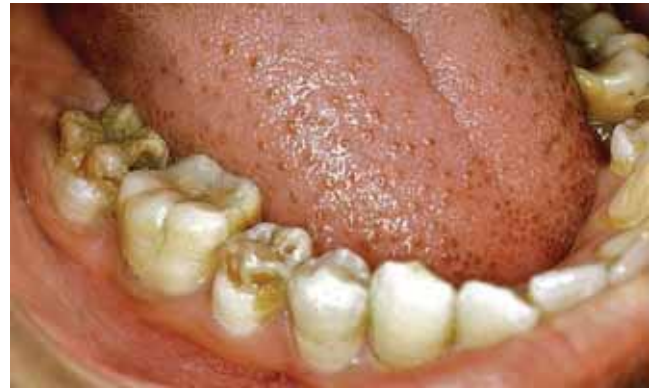**Fluorosis** is a condition caused during enamel formation by the ingestion of a high concentration of fluoride compounds in drinking water that *greatly exceeds* the concentration recommended for controlling decay. The amount of fluoride compounds in some naturally occurring mineral water that causes this condition is many times greater than the one part per million that is added to drinking water to effectively reduce the prevalence of decay. If during enamel formation, teeth that are forming their crowns are exposed to excessively high concentrations of ingested fluoride, the tooth can exhibit a color change from white to yellow/brown spots called **mottled enamel**, and if severe, the tooth enamel can undergo a morphologic change resulting in the formation of pits within the enamel (**pitted enamel**) (seen on erupting secondary central incisors in Fig 11-40). Clinically, all permanent teeth may be involved depending on the length of time that the person was ingesting high levels of fluoride. These teeth are most often resistant to decay.

### c. Enamel Damage Due to High Fever

Pitted enamel on permanent teeth may result from a very high fever during early childhood due to diseases such as measles.<sup>4</sup> Usually, the tooth crowns that are developing at the time of the fever are affected. For example, the damage to the crowns of the permanent



**FIGURE 11-40.** **Fluorosis.** This condition is most evident on the maxillary and mandibular central incisors. It is seen as white coloration or mottling of color, and some pitting (on partially erupted tooth No. 9). (Courtesy of Carl Allen, D.D.S., M.S.D.)

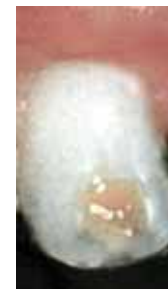

**FIGURE 11-41.** **Enamel dysplasia (hypoplasia).** This tooth damage resulted from the disruption of enamel formation on the mandibular second premolar and second molar at about 2 years of age when these crowns were forming. (Courtesy of Carl Allen, D.D.S., M.S.D.)

second molars as well as the permanent second premolars of the person in *Figure 11-41* resulted from a high fever at about age 2 years and 3 months when the enamel was forming on both the mandibular second premolar and second molar.

### d. Focal Hypoplasia (or Hypomaturation)

**Focal hypoplasia** is an incomplete development of enamel seen as a *localized* discolored spot or deformed area on a tooth. During enamel formation, this condition may result from trauma, a local infection of an adjacent abscessed primary tooth, or some other interference in enamel matrix maturation, most likely to occur in succedaneous teeth (called a **Turner’s tooth**) seen in *Figure 11-42*. Unlike decalcification (early decay), which can usually be seen in the cervical thirds of teeth or on occlusal surfaces of posterior teeth, this



**FIGURE 11-42.** **Enamel hypoplasia (focal hypomaturation)** caused by a disturbance during the formative stage of the enamel matrix. A defect on the labial surface of the maxillary central incisor (a so-called **Turner’s tooth**) could be caused by an infection (abscess) on the primary central incisor that preceded it.

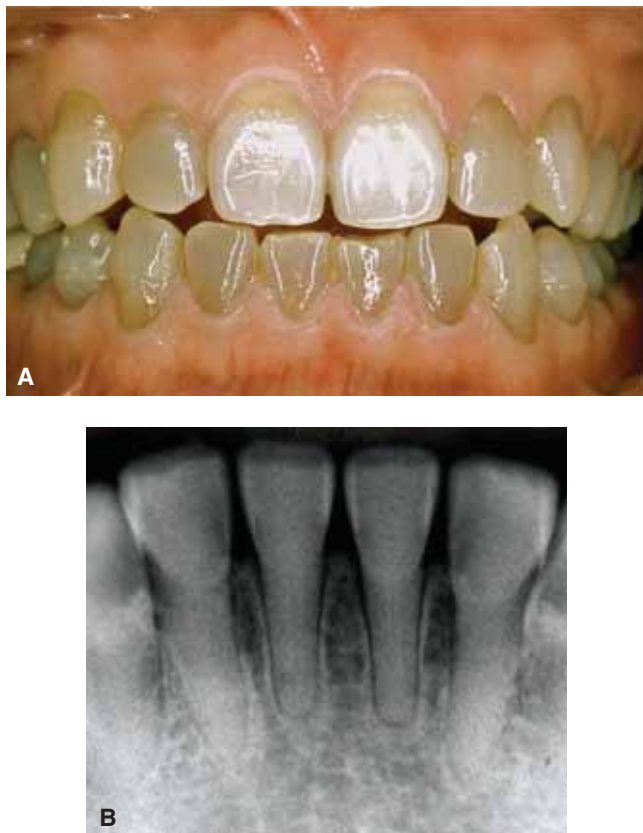
form of hypomaturation generally appears in the middle third of the smooth crown surfaces (facial and lingual surfaces). The underlying enamel may be soft making the area susceptible to decay.

## 2. DENTIN DYSPLASIA

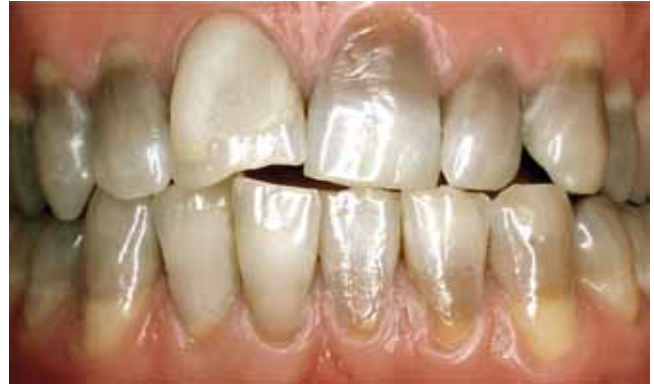Dysplasias of dentin occur twice as often as those in enamel (1 in 8000).<sup>39</sup> Abnormal development of the dentin includes conditions with hereditary and systemic causes as follows.

### a. Dentinogenesis Imperfecta

**Dentinogenesis** [den ti no JEN e sis] **imperfecta** is a hereditary disorder that affects the dentin formation of both dentitions. Clinically, all teeth have an unesthetic light blue-gray to yellow, somewhat opalescent appearance (Fig. 11-43A), hence the term hereditary opalescent dentin. On a radiograph, there may be a partial



**FIGURE 11-43.** **Dentinogenesis imperfecta** (opalescent dentin) is a hereditary disorder that affects the dentin and external appearance of all teeth. This condition occurs only once in every 8000 people. **A.** The teeth take on a gray or yellow opalescent appearance. **B.** Radiographs reveal the total or partial lack of pulp chambers and canals. (Courtesy of Carl Allen, D.D.S., M.S.D.)



**FIGURE 11-44.** **Tetracycline staining** in this permanent dentition resulted from the administration of tetracycline antibiotic during the time that crowns formed. Teeth have the appearance of yellow to gray-brown horizontal bands across the crowns. (The staining on tooth No. 8 has been covered with a tooth-colored restorative material such as composite resin.) (Courtesy of Carl Allen, D.D.S., M.S.D.)

or total absence of pulp chambers and root canals since the pulp chambers and root canals may calcify (Fig. 11-43B). These teeth may be weak because of a lack of support in the dentin, so they may be susceptible to severe attrition.

### b. Tetracycline Stain

When the antibiotic **tetracycline** is taken by a pregnant woman, an infant, or a child during the time of tooth formation and calcification, it can affect developing dentin. The result is a change in tooth color depending on the dose of the drug, to a yellow or gray-brown (Fig. 11-44). The resultant staining may be generalized in the primary dentition but may also affect some permanent teeth, depending on the age at which tetracycline was administered. Since only the teeth that are calcifying during the tetracycline therapy are stained, it is possible to confirm this condition by noting the age when tetracycline was given and comparing this to the teeth that were calcifying at that age. Some persons have erroneously blamed the staining from tetracycline antibiotic therapy during tooth formation on fluoridated community drinking water, which is beneficial for both teeth and general health.

## E. CHANGES IN TOOTH SHAPE DUE TO INJURY AFTER TOOTH ERUPTION

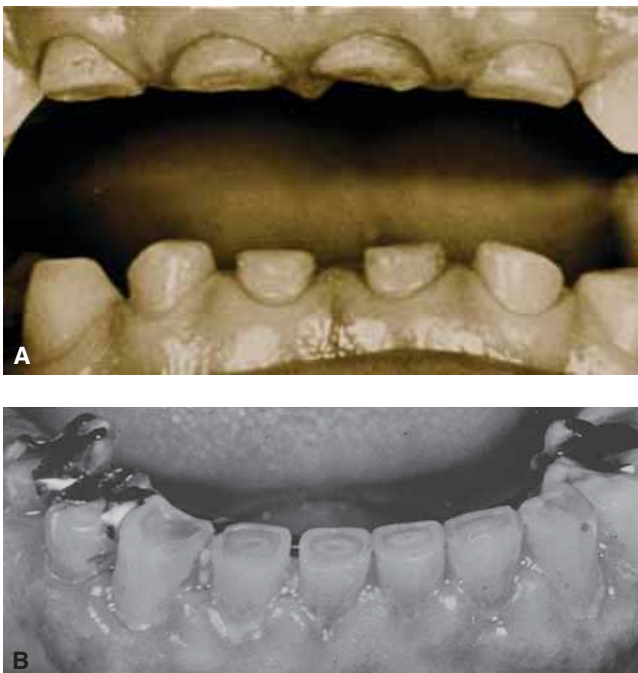
Reactions to injury are not really anomalies but are unique changes in tooth morphology associated with a specific cause. It is important to recognize these conditions so that their etiology (causes) can be identified



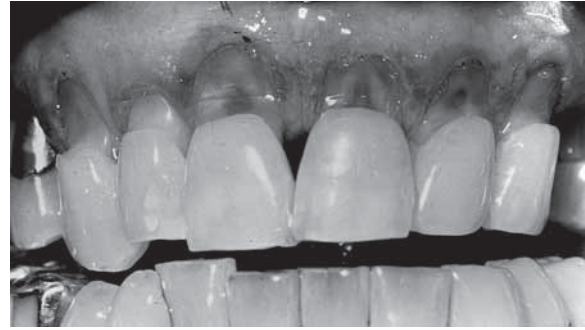
and modified, when possible, to avoid the causative factor(s) that could worsen the condition.

## 1. ATTRITION

**Attrition** is the wearing away of enamel (and eventually dentin) due to the movement of mandibular teeth against maxillary teeth during normal function and is made worse by excessive grinding together of teeth known as **bruxism**. Two examples of severe attrition are shown in *Figure 11-45*. Stress greatly increases bruxism. Attrition should be distinguished from other forms of tooth damage such as abrasion and erosion since the cause of each condition, and therefore the therapy to prevent further damage, is quite different. Recall from the discussion on bruxism in Chapter 9 (Occlusion) that normal tooth-to-tooth contacts per day in a healthy person without occlusal problems may be as little as 7 to 8 min/d during mastication of food with a force that is normally less than 33 pounds. Imagine, on the other hand, the potential damage to teeth (as well as muscles and the TMJ) if a bruxer bites together for 5 hours per night at pressures exceeding 190 pounds!



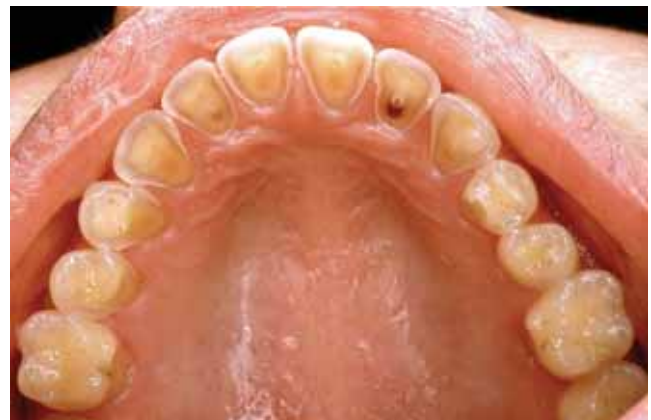**FIGURE 11-45.** **Attrition** results from prolonged bruxism or grinding of the teeth. **A.** The anterior teeth have been worn down almost to the gingival sulcus. **B.** The permanent mandibular incisors are worn down to a level where the pulp chamber had been at one time many years previously. (Note the darker circular and oval areas of exposed secondary or reparative dentin visible on the incisal ridges.)



**FIGURE 11-46.** **Abrasion** (sometimes called toothbrush abrasion) is due in part to incorrect horizontal tooth brushing over areas of cementum that are exposed due to the recession of the gingiva. Flexing of the teeth during heavy occlusal forces and subsequent enamel loss (called **abfraction**) may contribute to and appear similar to abrasion.

## 2. ABRASION

The wearing away of tooth structure by mechanical means is called **abrasion**. A common example of abrasion (sometimes called toothbrush abrasion) results in the loss of enamel near the cemento-enamel junction of the facial surfaces of crowns, especially on premolars and canines, due to improper tooth brushing techniques (*Fig. 11-46*). It can be caused by using a hard bristle toothbrush, a horizontal brushing stroke, and/or a gritty dentifrice. Another contributing factor to the



**FIGURE 11-47.** **Erosion.** Severe erosion is evident on the lingual surfaces of these maxillary teeth, especially the anterior teeth. This pattern of tooth destruction is typically associated with someone with severe acid reflux, or repeated regurgitation in bulimic persons. Note the exposure of one pulp chamber on tooth No. 10. (Courtesy of Carl Allen, D.D.S., M.S.D.) Erosion of facial enamel may be caused by holding pieces of acidic fruit like lemons next to the teeth and sucking on them for an extended period of time, a habit practiced by some persons in Southeast Asia.



loss of tooth structure near the cemento-enamel junction is known as **abfraction** [ab FRAC shun], which is the bending (flexure) of the tooth caused by heavy occlusal forces. This condition is thought to result in loss of tooth structure due to separation of enamel rods near the CEJ.

Occlusal abrasion results from chewing or biting hard foods or objects, or from chewing tobacco and results in flattened cusps on all posterior teeth and worn incisal edges (appearing similar to attrition). An unusual type of abrasion, caused by the use for many years of a toothpick between the maxillary central incisors, has been reported by Melfi.<sup>40</sup> The same type of proximal abrasion has been reported from the use of a straight pin for the same purpose over many years.

### 3. EROSION

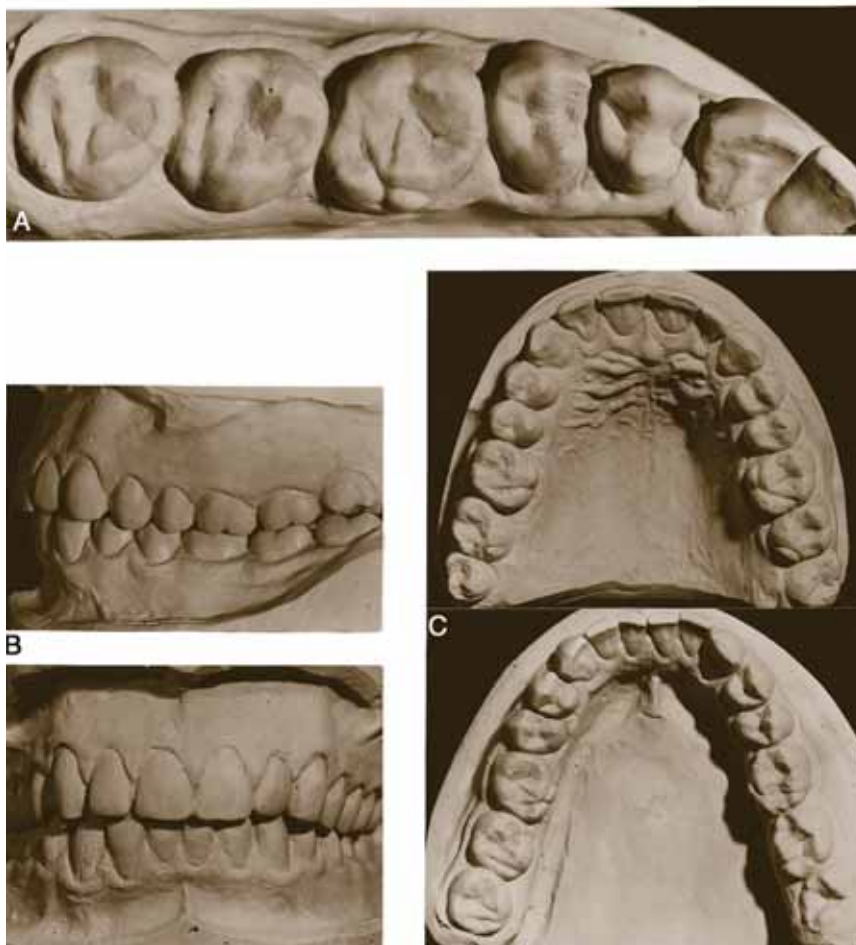
**Erosion** is the loss of tooth structure from chemical (not mechanical) means and affects smooth and occlusal surfaces. Erosion can be the result of excessive intake

or use of citric acid (like in lemons), carbonated beverages, or the result of regurgitated stomach acids (seen in bulimic individuals who habitually induce vomiting, as in the “binge and purge” syndrome).<sup>2</sup> Erosion can also occur from an unknown cause (idiopathic). Severe erosion of the lingual enamel of all maxillary anterior teeth is evident in *Figure 11-47*. Careful inspection of the tooth damage evident in the figure reveals that at least one pulp horn has been exposed on the maxillary left lateral incisor.

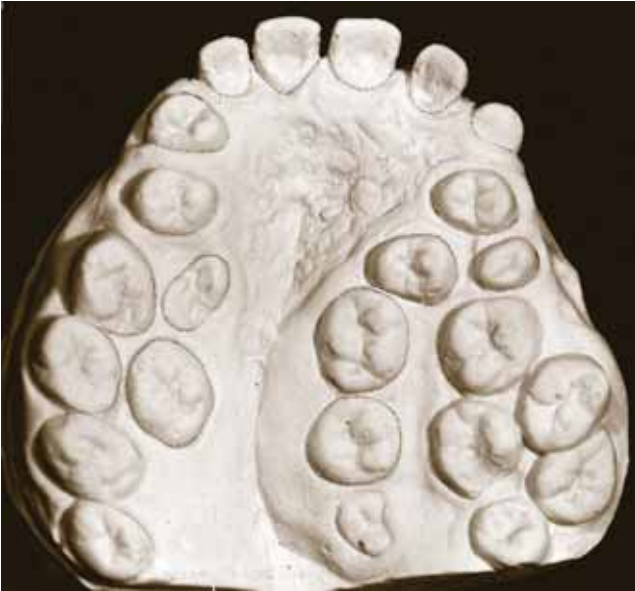### F. UNUSUAL DENTITIONS

Careful examination of the casts of the dentition of a 23-year-old man reveals that the mandibular left first molar closely resembles a maxillary first molar, complete with what appears to be an oblique ridge and a cusp of Carabelli (*Fig. 11-48*). On closer examination, the first and second mandibular premolars and first, second, and third mandibular molars on both sides also appear remarkably similar morphologically to maxillary

#### A MOST UNUSUAL MANDIBULAR DENTITION



**FIGURE 11-48.** A most unusual mandibular dentition. **A.** A close-up of the mandibular dentition of a 23-year-old man who has premolars and molars with crown morphology more similar to maxillary premolars and molars, particularly on the left side. **B.** The teeth as they fit together well into the maximum intercuspal position. **C.** Both dentitions are seen from the occlusal aspect, maxillary in the top photo and mandibular in the bottom photo. Lower premolar crowns do not resemble mandibular premolars in any fashion but are more similar to maxillary premolars. However, the six mandibular anterior teeth appear truly mandibular. The mandibular right first molar has three buccal cusps but otherwise seems to be a mixture of both maxillary and mandibular first molars: oblong mesiodistally like a lower, but with a much larger mesio-lingual cusp and a Carabelli-like cusp similar to upper first molars. The mandibular left three molars seem to have only morphologic characteristics of maxillary molars. This man’s maxillary dentition seems entirely normal. It is most interesting to note that the lower left posterior teeth (particularly the premolars) have the morphology of maxillary right-side teeth. Likewise, the lower right teeth appear similar to those found in an upper left quadrant.



**FIGURE 11-49.** Very unusual permanent maxillary dentition with 24 teeth, including 13 molars. This cast was furnished courtesy of J. Andrew Stevenson (D.T.L.) and Dr. Robert Stevenson, Columbus, OH.

posterior teeth The mandibular six anterior teeth unquestionably belonged to the mandibular dentition. The occlusion of the young man's teeth was remarkably good considering the fact that maxillary posterior teeth were occluding against practically identical maxillary teeth on both sides!

Another most unusual dentition of a foreign exchange student from Africa is seen in *Figure 11-49*. This maxillary dentition has a total of 24 erupted or partially erupted teeth. There appear to be 4 incisors, 1 canine, 6 premolars, and 13 molars (5 of which somewhat resemble mandibular molars).

## Review Questions

Circle the correct answer(s).

- What condition may result when a forming succedaneous tooth is located next to an abscess on an adjacent primary tooth?
  - Turner tooth
  - Fluorosis
  - Tetracycline staining
  - Dentinogenesis imperfecta
  - Amelogenesis imperfecta
- An adult has only three maxillary incisor crowns, but one of the crowns is doubled in width and notched. What do you suspect?
  - Fusion
  - Twinning
  - Gemination
  - Concrescence
  - Cementosis
- Which condition may be caused by habitually sucking on lemons (which are quite acidic)?
  - Attrition
  - Erosion
  - Abrasion
  - Amelogenesis imperfecta
  - Hypoplasia
- Which three of the following locations are *most likely* to have supernumerary teeth form?
  - Mandibular premolar area
  - Maxillary premolar area
  - Maxillary incisor area
  - Mandibular incisor area
  - Third molar area
- Which one of the following teeth that are normally single rooted are most likely to have a bifurcated root?
  - Maxillary central incisors
  - Maxillary lateral incisors
  - Mandibular canines
  - Mandibular first premolars
  - Mandibular second premolars
- Which two of the following are most likely to exhibit unusually formed crown morphology?
  - Maxillary central incisors
  - Maxillary lateral incisors
  - Mandibular canines
  - Maxillary third molars
  - Maxillary first molars

ANSWERS: 1—a, 2—a, 3—b, 4—a, c, e; 5—c; 6—b, d

## Critical Thinking

List and describe as many anomalies you can that you are likely to see in the maxillary incisor area of the mouth.

### REFERENCES

- Dorland WA, Dorland's pocket medical dictionary. Philadelphia, PA: W.B. Saunders, 1965.
- Smith RM, Turner JE, Robbins ML. Atlas of oral pathology. St. Louis, MO: C.V. Mosby, 1981.
- Croll TP, Rains JR, Chen E. Fusion and gemination in one dental arch: report of case. *ASDC J Dent Child* 1981; 48:297.
- Rowe AHR, Johns RB, eds. A companion to dental studies: dental anatomy and embryology. Vol. 1, Book 2. Boston, MA: Blackwell Scientific Publications, 1981.
- McDonald TP. An American Board of Orthodontics case report. *Am J Orthod* 1981;80:437-442.
- Fuller JL, Denehy GE. Concise dental anatomy and morphology. Chicago, IL: Year Book Publishers, Inc., 1984:264-265.
- McKibben DR, Brearley LJ. Radiographic determination of the prevalence of selected dental anomalies in children. *J Dent Child* 1971;28:390-398.
- Jones AW. Supernumerary mandibular premolars. Report of a case in a patient of mongoloid origins. *Br J Oral Surg* 1981;19:305-306.
- Rothberg J, Kopel M. Early versus late removal of mesiodens: a clinical study of 375 children. *Compend Contin Educ Pract* 1984;5:115-120.
- Nazif MM, Ruffalo RC, Zullo T. Impacted supernumerary teeth: a survey of fifty cases. *JADA* 1983;106:201-204.
- Robinson HB, Miller AS. Colby, Kerr and Robinson's color atlas of oral pathology. Philadelphia, PA: J.B. Lippincott, 1983:38.
- Primosch RE. Anterior supernumerary teeth—assessment and surgical intervention in children. *Pediatr Dent* 1981;3:204-215.
- Ranta R, Ylipaavalniemi P. Developmental course of supernumerary premolars in childhood: report of two cases. *ASDC J Dent Child* 1981;48:385-388.
- Rubin MM, Nevins A, Berg M, et al. A comparison of identical twins in relation to three dental anomalies. Multiple supernumerary teeth, juvenile periodontosis, and zero caries incidence. *Oral Surg* 1981;52:391-394.
- Zvolanek JW. Maxillary lateral incisor anomalies in identical twins. *Dent Radiogr Photogr* 1981;54:17-18.
- Hemmig SB. Third and fourth molar fusion. *Oral Surg* 1979;48:572.
- Good DL, Berson RB. A supernumerary tooth fused to a maxillary permanent central incisor. *Pediatr Dent* 1980;2:294-296.
- Powell RE. Fusion of maxillary lateral incisor and supernumerary tooth. *Oral Surg* 1981;51(3):331.
- Myers CL. Treatment of a talon-cusp incisor: report of case. *ASDC J Dent Child* 1980;47:119-121.
- Speiser AM, Bikofsky VM. Premolars with double occlusal surfaces. *JADA* 1981;103:600-601.
- Goldman HM. Anomalies of teeth (part 1). *Compend Contin Educ Pract* 1981;2:358-367.
- Hayward JR. Cuspid gigantism. *Oral Surg* 1980;49: 500-501.
- Ruprecht A, Singer DL. Macrodontia of the mandibular left first premolar. *Oral Surg* 1979;48:573.
- Melfi RC, Alley KE. Permar's oral embryology and microscopic anatomy: a textbook for students in dental hygiene. Philadelphia, PA: Lippincott Williams & Wilkins, 2000.
- Hamner JE, Witkop CJ, Metro PS. Taurodontism. *Oral Surg* 1964;18:409-418.
- Pindborg JJ. Pathology of the dental hard tissues. Philadelphia, PA: W.B. Saunders, 1970:15-73.
- Takeda Y. A rare occurrence of a three-rooted mandibular premolar. *Ann Dent* 1988;44:43-44.
- Paulson RB, Gottlieb LJ, Sciulli PW, et al. Double-rooted maxillary primary canines. *ASDC J Dent Child* 1985;52: 195-198.
- Bimstein E, Bystrom E. Birooted bilateral maxillary primary canines. *ASDC J Dent Child* 1982;49:217-28.
- Kelly JR. Birooted primary canines. *Oral Surg* 1978;46:872.
- Brown CK. Bilateral bifurcation of the maxillary deciduous cuspids. *Oral Surg* 1975;40:817.
- Kroll SO. Double rooted maxillary primary canines. *Oral Surg* 1980;49:379.
- Bryant RH Jr, Bowers DF. Four birooted primary canines: report of a case. *ASDC J Dent Child* 1982;49:441-442.
- Becker A, Smith P, Behar R. The incidence of anomalous maxillary lateral incisors in relation to palatally-displaced cuspids. *Angle Orthod* 1981;51:24-29.
- Schachter H. A treated case of transposed upper canine. *Dent Rec* 1951;71:105-108.
- Jackson M, Leeds, LD. Upper canine in position of upper central. *Br Dent J* 1951;90:243.
- Curran JD, Baker CG. Roentgeno-oddities. *Oral Surg* 1973;41:906-907.
- DeJong TE. Rotatio dentis. *Gegenbaurs Morphologisches Jahrbuch* 1965;108:67-70.
- Schulze C. Developmental abnormalities of the teeth and jaws. In: Gorlin RJ, Goldman HM, eds. Thoma's oral pathology. 6th ed. St. Louis, MO: C.V. Mosby, 1970:138-140.
- Dr. Rudy Melfi, Columbus, Ohio, personal communication.
- Paulson RB, Gottlieb LJ, Sciulli PW, et al. Double rooted maxillary primary canines. *ASDC J Dent Child* 1985; 52:195-198.

**ACKNOWLEDGMENTS**

This chapter was contributed by Daniel E. Jolly, D.D.S., D.A.B.S.C.D., former Professor of Clinical Dentistry and Director of the General Practice Residency program at Ohio State University College of Dentistry and University Medical Center, and currently in private practice. He is a diplomate of the American Board of Special Care Dentistry, Chief Forensic Odontologist for the Franklin County Coroner's Office in Columbus, Ohio, Core team member of the Ohio Dental Association's Forensic and Mass Disaster Team, member of the American Society of Forensic Odontology, and associate member of the American Academy of Forensic Sciences.

Most illustrations shown in this chapter are from cases with which the author was directly involved as part of his duties with the Franklin County Coroner's Office and other agencies in Ohio. The final three figures are from Dr. Theodore Berg, the author of this chapter in previous editions, and are used with permission.

- I. Forensic dentistry defined
- II. Dentistry and human identification
- III. Civil litigation (including human abuse and neglect)
- IV. Bite marks
- V. Mass disasters
  - A. Preparation and training
  - B. Initial response
  - C. Morgue and forensic dental identification operations
  - D. Forensic anthropology
  - E. Mass disaster case studies
- VI. Importance of forensic dentistry to practicing dentists

**OBJECTIVES**

This chapter is designed to prepare the reader to perform the following:

- Cite examples of the importance of dentistry in human identification and crime investigation.

- Recognize the role of the dentist in identifying and reporting cases of abuse.

**SECTION I****FORENSIC DENTISTRY DEFINED**

**F**orensic dentistry, or forensic odontology, is the area of dentistry that encompasses concepts and practices related to the oral and maxillofacial structures in the context of the legal or judicial system. Forensic odontology is a part of the much larger field of forensic sciences, which includes all the areas of practice and activity used in a judicial setting. The forensic sciences are accepted by the legal system, as well as by the scientific community as the means of separating truth and untruth.

Forensic dentistry as a science is represented in the United States by numerous forensic dentistry teams on local levels, including the Odontology Section of the American Academy of Forensic Sciences (AAFS), the American Board of Forensic Odontology, and the American Society of Forensic Odontology. Each year more dentists become involved as law enforcement becomes increasingly aware of dentistry's potential and reliable contribution.

This chapter provides an overview and introduction to forensic dentistry, while illustrating its elemental dependence on dental anatomy. This textbook is cited in the American Society of Forensic Odontology Manual as the prime dental anatomy reference on this subject.

The forensic sciences include many areas of specialization and special interest. The AAFS is the largest forensic professional organization in the world with over 5600 members worldwide (<http://www.aafs.org>). The AAFS recognizes 10 areas of forensic endeavors as noted below:

1. **Forensic anthropology** is the study of skeletal evidence in a manner similar to the field of archeology. The forensic anthropologist examines evidence such as bones, teeth, hair, clothing, artifacts, and other aspects of the scene of a legal matter such as the crime of murder. This person



addresses considerations such as time of death, age, sex, race, ethnicity, culture, body size and weight, and cause and manner of death.

2. **Forensic pathology and biology** is the field that uses autopsy techniques and the analysis of tissues in the investigation of a crime or suspicious death such as homicide, suicide, and accidental death, or if the subject is unidentified. This duty is legally the responsibility of a coroner or medical examiner with specialized training in pathology and forensic sciences. A forensic pathologist attempts to determine matters such as the cause and manner of death (for example, a gunshot wound to the chest resulting in laceration of the left ventricle, which resulted in cardiac arrest as a result of a homicide).
3. **Criminalistics** is the forensic science that analyzes fingerprints, ballistics, tool marks (knife, saw, hammer, etc.), and other physical evidence from the investigated scene to reconstruct the crime (or other event) and to confirm or eliminate the connection between suspects and victims.
4. **Toxicology** uses chemistry, photography, and biology to identify harmful substances in the victim such as medications, poisons, and illegal drugs.
5. **Forensic psychiatry and behavioral sciences** examine and provide legal opinions regarding such matters as sanity, human motivation, and personality profiles that are relevant to the investigation of an event such as a crime.
6. **Forensic engineering** investigates events such as airplane and other vehicular accidents, as well as structural collapse as part of the legal process.
7. **Questioned documents** is a field where technicians study and provide legal testimony about printing, handwriting, typewriting, ink, paper, and other features of documents.
8. **General forensics** involves other specialists who are qualified to analyze specific evidence such as designers, photographers, and technical experts. They might report, for example, in a case of product liability associated with death or injury.
9. **Forensic jurisprudence** involves criminal and civil lawyers using the earlier described specialists, reports, and testimony to pursue their case in our system of justice.
10. **Forensic odontology** is divided into five major areas: (a) human dental identification, (b) mass disaster human dental identification, (c) bite mark analysis, (d) human abuse, and (e) legal issues such as the standard of care considerations in personal injury cases.

## SECTION II

## DENTISTRY AND HUMAN IDENTIFICATION

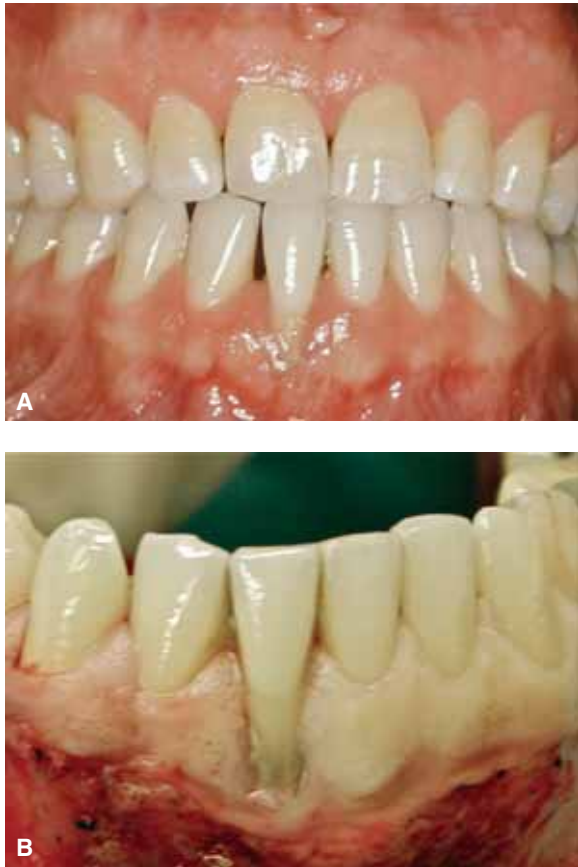Teeth are the most durable parts of the body, and dentitions are as individual as fingerprints. Therefore, individual tooth morphology as well as the restorations that exist in teeth are useful for human identification. Situations involving decomposition and skeletal remains may yield no recognizable facial features or fingerprints. Postmortem (after death) teeth, jaws, prostheses, and appliances can yield a positive identification, given the existence and accuracy of antemortem (before death) records. Even DNA, a popular and valuable identification tool, relies on accurate and complete antemortem (before death) records. Therefore, accurate, comprehensive, and current radiographs and dental charting are critical to the successful confirmation or elimination of an individual as a victim.

Even with the lack of antemortem records, evaluation of the dentition is a worthwhile aid for investigators to provide information regarding the age, sex, and estimated socioeconomic (sometimes called race or cultural heritage) grouping. This information is derived from tooth and dental arch morphology and anatomy, restorative materials, attrition patterns, periodontal

status, eruption patterns, skeletal features, and serology (the study of body fluids like blood).

Forensic dental techniques most commonly include collection and preservation of dental and jaw remains, dental radiographs, photographs, impressions and casts, antemortem and postmortem charting, and the comparison of these records. Points of comparison (specific features) include (a) the number, class, and type of teeth; (b) tooth rotation, spacing, and malposition; (c) anomalies and general morphology (*Fig. 12-1*); (d) restorations (*Fig. 12-2*) and prostheses or appliances (*Fig. 12-3*); (e) caries and other pathology (in some situations); (f) endodontic treatment; (g) implants and surgical repairs; (h) bony trabecular patterns; and (i) occlusion, erosion, and attrition.

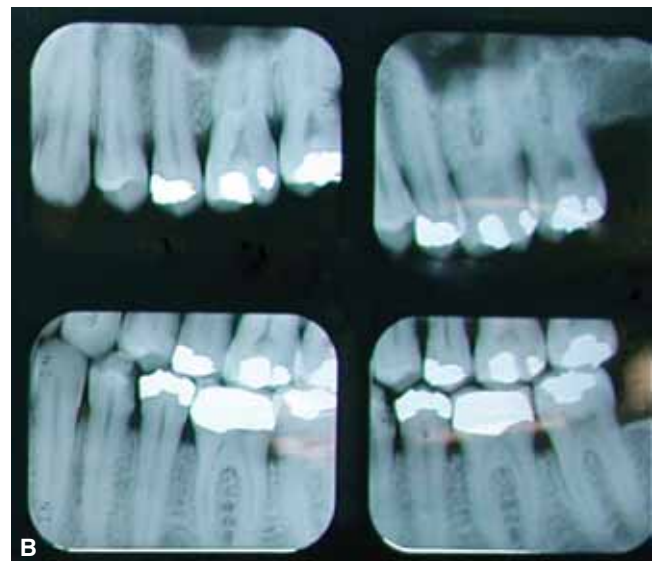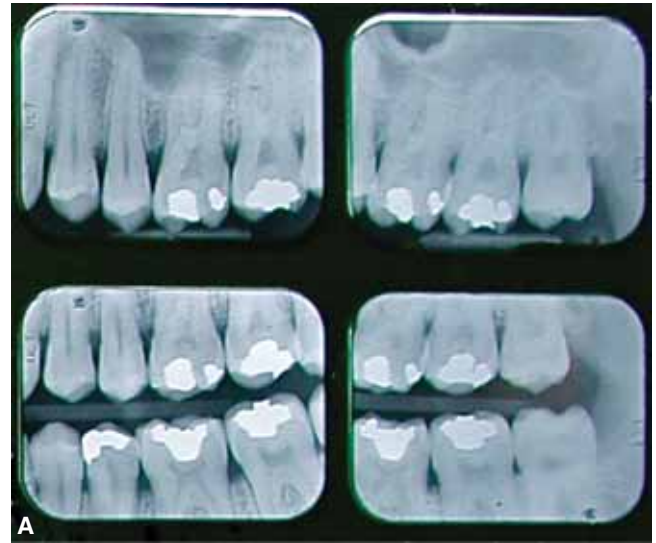
DNA can be recovered from periodontal and pulpal tissues, as well as the hard tissues, of the teeth. Although DNA analysis has become an important tool in the forensic science armamentaria, its limitations include high costs and lengthy processing times. And like all methods, the use of DNA requires antemortem information. A DNA collection kit is shown



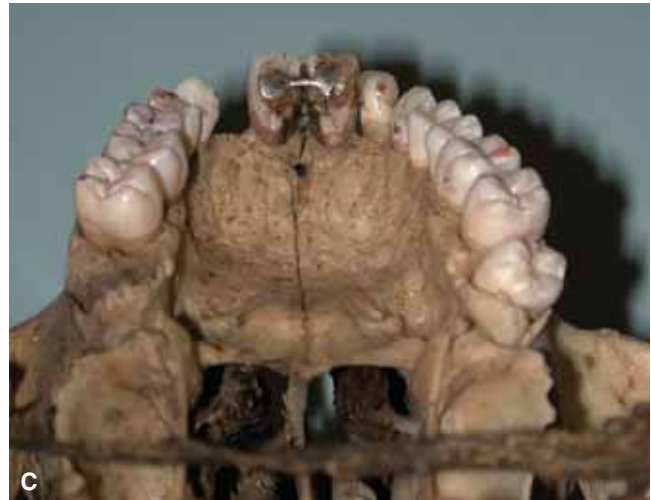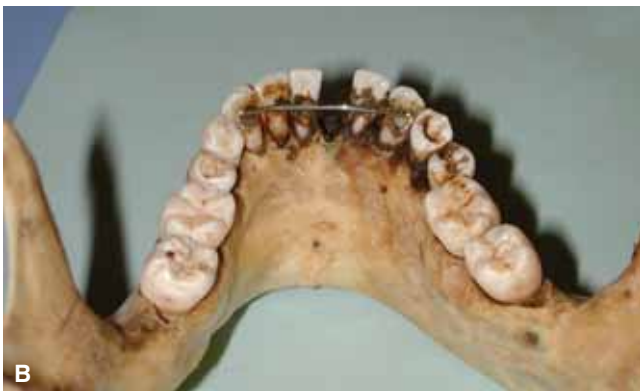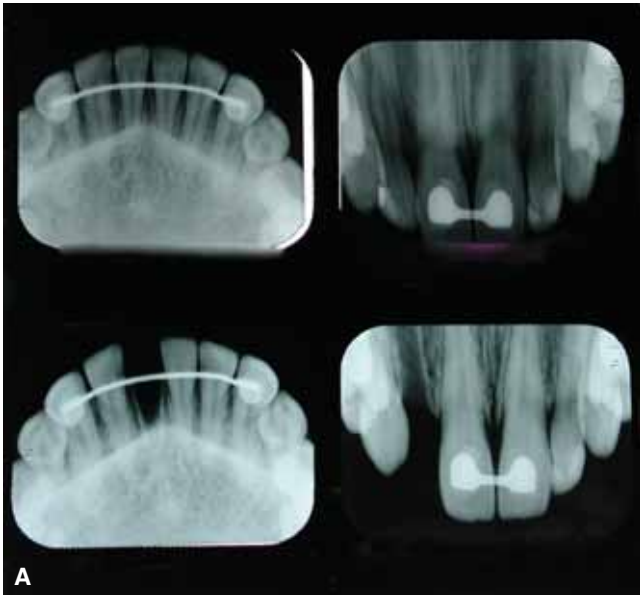**FIGURE 12-1.** Comparison of antemortem and postmortem photographs looking for similarities in general morphology. **A.** Antemortem dental photograph showing gingival clefting. **B.** Postmortem photograph showing similar clefting found in the victim at autopsy. Similar dental arch form is observed as is the overall morphology of the dental coronal structure.

in Figure 12-4. Forensic dentistry techniques retain a valuable place in the scope of forensic sciences because of the accuracy, low cost, generally available antemortem records, and speed with which a conclusion can be reached.

The forensic dentist must carefully organize all evidence so that it is analyzed in a systematic manner using consistent and standardized methods that are easily understood by other professionals and defensible in a legal action. A well-organized and thorough approach results in accurate comparisons and minimizes the chance of error. The examiner should record each feature of the postmortem teeth, jaws, and radiographs on a standardized dental chart (Fig. 12-5B). The same is done for antemortem records, radiographs, casts, and pictures on a separate, but identical, chart (Fig. 12-5A). Antemortem records vary widely



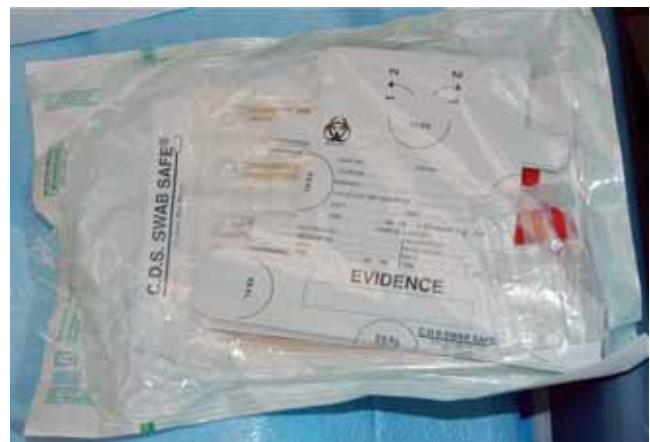**FIGURE 12-2.** Comparison of antemortem and postmortem radiographs looking for similarities of restorations and general morphology. **A.** Antemortem radiographs of the same victim shown in Figure 12-1 demonstrate multiple dental restorations, unique root and sinus morphology, pulp chamber shape, interdental bone height, and trabecular patterns. **B.** Postmortem radiographs show consistency in some restorations when compared to the antemortem radiographs, but note that several teeth have had restorations placed after the antemortem radiographs were obtained. For example, an MOA was placed on tooth No. 13, a crown was placed on tooth No. 19, an MOA on tooth No. 20 was replaced with an MODA, and third molars numbers 16 and 17 were extracted. Also noted are identical matching restorations that had not been replaced, as well as the unique root and sinus morphology, pulp chamber shape interdental bone height, and trabecular patterns. This was sufficient to prove positive identification of this individual.



**FIGURE 12-3.** Comparison of antemortem radiographs with postmortem findings (photographs). **A.** These radiographs show antemortem (top) and postmortem (bottom) radiographs of a homicide victim with orthodontic appliances in place, which are identical to actual postmortem findings (seen in B and C) and served to confirm the identity. Note also the restoration of tooth No. 10, a peg lateral that matches as well. **B.** This postmortem photograph shows the orthodontic retainer in the mandibular arch as evident in the antemortem radiographs. **C.** This postmortem photograph shows the orthodontic retainer in the maxillary arch as evident in the antemortem radiographs.

in quality and completeness. Some dentists mount radiographs as viewed from the front of the patient (with the film bump facing toward the viewer), which is the standard in forensic dentistry, while others still prefer mounting them as viewed from the lingual (film bump facing away from the viewer). Charting tooth identification in dental offices (the antemortem record) is not always done using the Universal system. (See Chapter 1 for other tooth identification systems such as Palmer and the FDI or International systems.)

A real test of the value of dental identification is found in the case of John Wayne Gacy of Chicago, convicted of 33 counts of murder. Only five of the human remains found still had soft tissue, making the identification process a challenge. However, 20 of the 33 known victims were identified through their dental records.



**FIGURE 12-4.** This is a DNA collection kit as used by the FBI to obtain swabbings of bite marks or other human tissues for comparison to antemortem records.



### Antemortem Dental Record

ID#: 05-1111

Last: Doe First: John MI: E

Date: 3/15/05 Sex: M Race: C Age/DOB: 8/8/1951

Height: \_\_\_\_\_ Weight: \_\_\_\_\_ Eye: \_\_\_\_\_ Hair: \_\_\_\_\_ Blood Type: \_\_\_\_\_

Team Member: Daniel E. Jolly, DDS

Confirmed by: William Baldwin, DDS

Type, Date, and Number of X-Rays \_\_\_\_\_

Panorex and 2 bitewings 11/10/04

Codes	
Primary Codes	Secondary Codes
M - Mesial	A - Annotation
O - Occlusal	B - Deciduous
D - Distal	C - Crown
F - Facial	E - Resin
L - Lingual	G - Gold
I - Incisal	H - Porcelain
U - Unerupted	N - Non-precious
V - Virgin	P - Pontic
X - Missing	R - Root Canal
J - Missing Cr	S - Silver Amalgam
/ - NoData	T - Denture Tooth
	Z - Temporary

A: \_\_\_\_\_  
 B: \_\_\_\_\_  
 C: \_\_\_\_\_

ID As: \_\_\_\_\_

				Description	Code
1	18				OS
2	17				OS
3	16				MODFS
4	15	A	55		V
5	14	B	54	ORTHO EXT	X
6	13	C	53		V
7	12	D	52		V
8	11	E	51		V
9	21	F	61		V
10	22	G	62		V
11	23	H	63		V
12	24	I	64	ORTHO EXT	X
13	25	J	65		V
14	26				OFS
15	27				OFS
16	28				OS
17	38				OS
18	37				OS
19	36				MOS
20	35	K	75		V
21	34	L	74	ORTHO EXT	X
22	33	M	73		V
23	32	N	72		V
24	31	O	71		V
25	41	P	81		V
26	42	Q	82		V
27	43	R	83		V
28	44	S	84	ORTHO EXT	X
29	45	T	85		OS
30	46				OS
31	47				OS
32	48			? OFS	OS

Comments: \_\_\_\_\_  
 \_\_\_\_\_ Aircraft crash victim \_\_\_\_\_  
 \_\_\_\_\_  
 \_\_\_\_\_

Copyright © 2001 James McGivney, DMD

**FIGURE 12-5.** A. An antemortem dental chart using the WinID format and coding.



### Postmortem Dental Record

ID#: 05-1111

Date: 3/15/05 Sex: M Race: C Estimated Age: 53

Height: \_\_\_\_\_ Weight: \_\_\_\_\_ Eye: \_\_\_\_\_ Hair: \_\_\_\_\_ Blood Type: \_\_\_\_\_

Code	Description				
OS				18	<b>1</b>
OS				17	<b>2</b>
MODFS				16	<b>3</b>
V		55	A	15	<b>4</b>
X		54	B	14	<b>5</b>
V		53	C	13	<b>6</b>
V		52	D	12	<b>7</b>
V		51	E	11	<b>8</b>
V		61	F	21	<b>9</b>
V		62	G	22	<b>10</b>
V		63	H	23	<b>11</b>
X		64	I	24	<b>12</b>
V		65	J	25	<b>13</b>
OFLS				26	<b>14</b>
OFS				27	<b>15</b>
OS				28	<b>16</b>
OS				38	<b>17</b>
OFS				37	<b>18</b>
MOFS				36	<b>19</b>
V		75	K	35	<b>20</b>
X		74	L	34	<b>21</b>
DE		73	M	33	<b>22</b>
V		72	N	32	<b>23</b>
V		71	O	31	<b>24</b>
V		81	P	41	<b>25</b>
V		82	Q	42	<b>26</b>
V		83	R	43	<b>27</b>
X		84	S	44	<b>28</b>
OS		85	T	45	<b>29</b>
OFS				46	<b>30</b>
OFS				47	<b>31</b>
OFS				48	<b>32</b>

Team member: Daniel E. Jolly, DDS

Confirmed by: William Baldwin, DDS

Type and Number of X-Rays \_\_\_\_\_

\_\_\_\_\_ Full mouth radiographs with bitewings \_\_\_\_\_

WinID Codes	
Primary Codes	Secondary Codes
M - Mesial	A - Annotation
O - Occlusal	B - Deciduous
D - Distal	C - Crown
F - Facial	E - Resin
L - Lingual	G - Gold
I - Incisal	H - Porcelain
U - Unerupted	N - Non-precious
V - Virgin	P - Pontic
X - Missing	R - Root Canal
J - Missing Cr	S - Silver Amalgam
/ - NoData	T - Denture Tooth
	Z - Temporary

A: \_\_\_\_\_

B: \_\_\_\_\_

C: \_\_\_\_\_

Body ID As: \_\_\_\_\_

Comments: \_\_\_\_\_

\_\_\_\_\_

\_\_\_\_\_

\_\_\_\_\_

Copyright © 2001 James McGivney, DMD

B

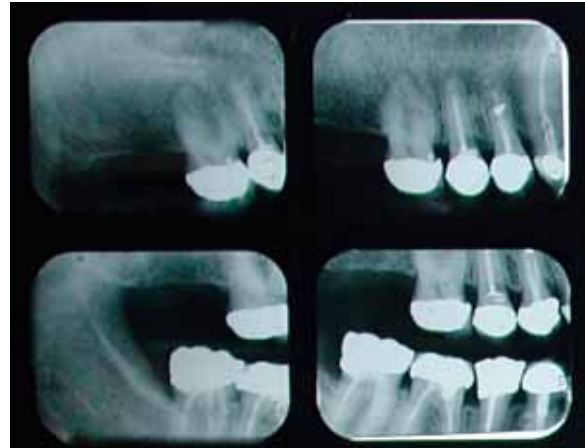**FIGURE 12-5.** (Continued), **B.** A postmortem dental chart using the WinID format and coding. Notice how the two forms can be placed side by side for easy comparison.

## SECTION III

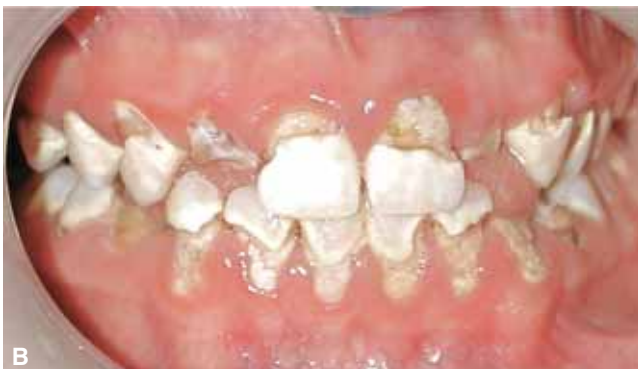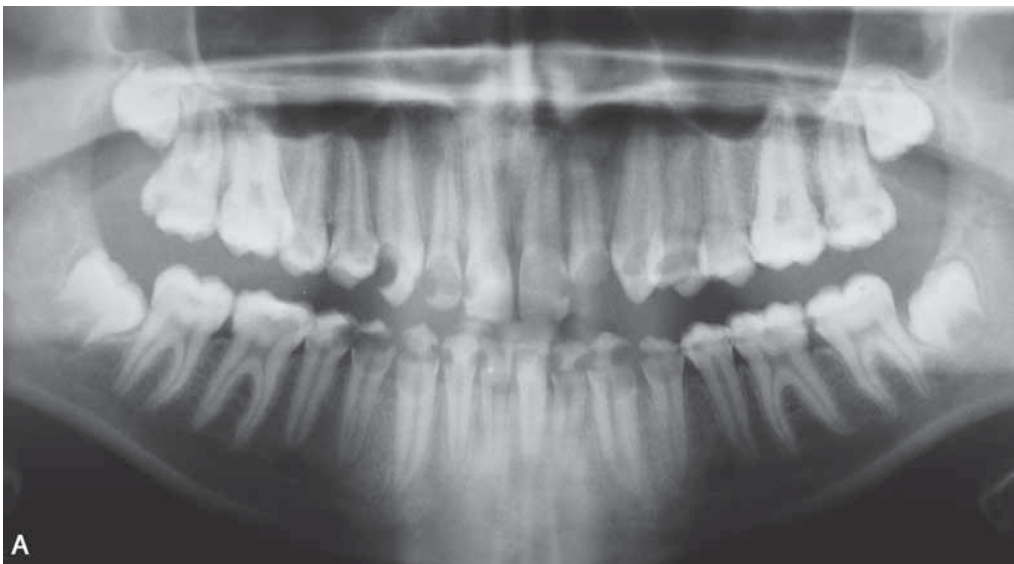
## CIVIL LITIGATION (INCLUDING HUMAN ABUSE AND NEGLECT)

Civil litigation (violations of the standard of care or malpractice) and human abuse and/or neglect are two distinct areas of endeavor for the forensic dentist. Due to the focus of this text (the relevance of dental anatomy), only brief comments will be made about these topics.

In civil litigation cases, a person might claim that improper dental care was rendered (malpractice) as illustrated in the radiographs in *Figure 12-6*; damage was sustained at the hands of another person (criminal assault and battery); damage was sustained due to food contaminated with a foreign body (glass, shell, etc.) (product or corporate liability); or a dentist failed to provide specific treatment that had been billed to the patient and/or third-party payer (fraud). Investigators of these situations often require examinations, comparisons, and testimony by expert witnesses including the forensic dentist. This may involve examining a person and studying records and radiographs from prior



**FIGURE 12-6.** These bitewing radiographs were used in a **standard-of-care** case. One can see marginal discrepancies between tooth contours and restoration contours (especially on the mesial crown margin on tooth No. 3) and poor endodontic procedures that are the basis for the malpractice claim.



**FIGURE 12-7.** **A.** This is a Panorex (panoramic) radiograph of a 14-year-old girl showing rampant caries that progressed over many years resulting in a treatment recommendation to extract all teeth. This evidence of **parental neglect** was reason for the dentist to contact legal authorities for suspected child abuse/neglect. **B.** This is a photograph of this same 14-year-old girl showing rampant dental caries.

dentists. All of the techniques and careful comparisons described previously are useful.

Dentists and other health caregivers have a responsibility to report suspected **abuse and neglect** of their patients by others. This includes recognition and differentiation of the signs, symptoms, and body areas involved in accidents compared to the injuries that are sustained by a child, a spouse (male or female), or an elderly or disabled individual. One abuse scenario is described here. A young adult male brought his girlfriend into the dental office for emergency treatment of several broken front teeth and lacerated lips. The woman was silent while the man related an accident as the cause of the injuries. The man insisted on being present during the treatment and was evasive about answering questions. As required by all state laws, the

situation was reported immediately to the appropriate law enforcement agency. The dentist's suspicions had been aroused sufficiently regarding the incongruity of the story and the injuries sustained. Toward the end of treatment, the police arrived, and the man was arrested. Radiographs, the dental record, and the dentist's testimony were critical since the victim was fearful of future revenge from her abuser. Injuries the dentist might observe include fractured bones and teeth, bruises, lacerations, and bite marks.

Neglecting dental pathology is also a reportable and potentially criminal offense. As often seen by this author, children may not be taken to a dentist for treatment of dental caries. This can result in pain and infection and, in some cases, may result in the loss of all teeth at an early age (Fig. 12-7).

## SECTION IV

## BITE MARKS

**Bite marks** are in the category described as pattern injuries. Pattern injuries can result from teeth, belt buckles, and other blunt objects such as a hammer or pipe. Homicides and assault and battery cases have been solved by bite mark identification, analysis, and comparison. Many bites are severe and leave telltale marks long after an assault. One of several techniques of comparison and analysis is shown here, comparing bite mark tracings to the tooth imprint pattern tracings of the suspect or defendant. Dental casts and photographs from the suspect or suspects are made after obtaining a court-ordered search warrant (Fig. 12-8A and B).

In all cases of bite mark analysis, the forensic dentist must have a thorough knowledge and understanding of tooth morphology, occlusion, dental arch characteristics, and the physiology of jaw function. Teeth that are malpositioned, not in occlusion, fractured, or restored may not leave the same mark on a victim as teeth that are in ideal alignment. This deviation from normal (or differences from one suspect to another) could benefit the forensic dentist in analysis and identification.

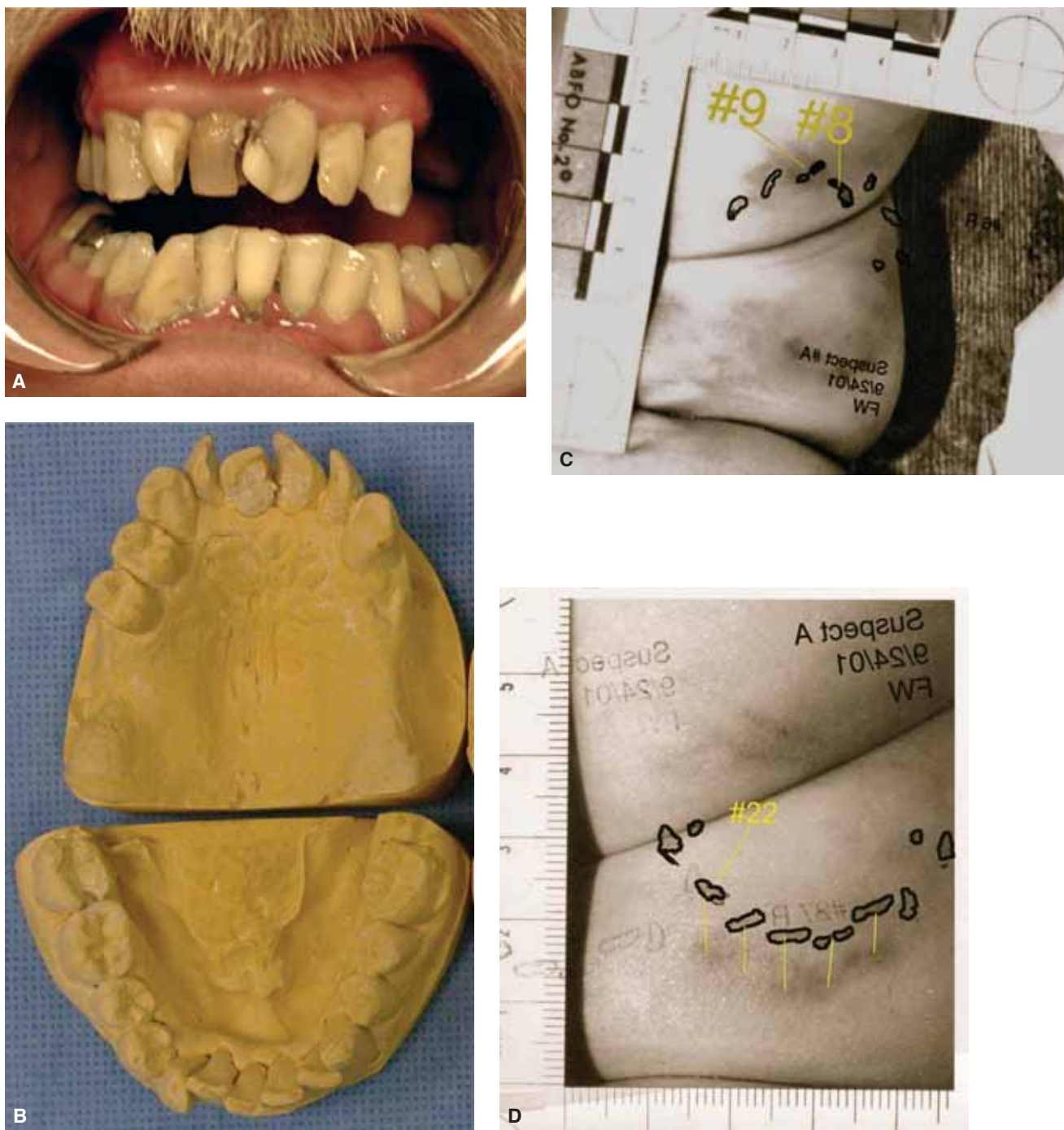
Although these techniques can be useful in solving some child abuse cases, assaults, and homicide, bite marks cannot generally be used to a level of absolute certainty in suspect identification. A potential suspect is either "ruled out or eliminated" as the perpetrator of the crime or "included" as a suspect (see Fig. 12-8C and D). Additional evidence is usually required to obtain a firm conviction. However, in this author's experience, suspects often admit their guilt prior to trial when faced with a forensic dentist who would testify in court regarding the bite mark.

Photography can be used to assist bite mark identification. Color and black-and-white film photography is still the standard, but digital photography has become fairly well accepted. The use of infrared photography can be used to identify subcutaneous evidence of damage from a bite mark that is not visible on the surface of the skin. Ultraviolet photography can serve to depict a bite mark in an area with extraneous other marks such as tattoos and skin damage.

The forensic dentist must first establish the mark as a human bite mark, and then identify, if possible, the teeth involved in the mark. Aberrations include teeth that are missing, extruded (supererupted), hypoperupted or ankylosed, rotated (torsion), tilted, chipped, and anomalous. The chapter in this text on anomalies should be reason enough to remain open-minded and diligent when considering bite marks! The dental forensic examiner must also consider the possibility of animal bites, victim self-bites, and marks from foreign objects that might be mistaken for a bite mark. Separate analysis of those markings may be useful to law enforcement agencies by connecting the victim's injuries to a tool or instrument owned by a suspect.

A bite mark may also provide DNA evidence of the perpetrator of the crime. Techniques are available to obtain this information. Today, when DNA can be collected, amplified, and analyzed with the standard accepted modern methods (e.g., polymerase chain reaction [PCR]) of mitochondrial or nuclear DNA, it is possible to quantify the numerical probability of the association between the biter and the bite mark injury.



**FIGURE 12-8.**

**Bite mark evidence.** **A.** A photograph of the dentition of the perpetrator of child abuse of a 2-year-old girl resulting in her death. **B.** Models of the suspect show a distinct dental pattern that matches well to the injuries depicted in **C.** **C.** This photograph shows the bite marks on the victim depicting the relationship of the maxillary teeth as shown in **A** and **B.** **D.** This photograph shows the bite marks of the mandibular teeth.

Law enforcement agencies are becoming increasingly aware of potential identifications from the dental profession. In a landmark bite mark case in California, *State v. Marx, Dr. G. Vale*, a forensic dentist, recognized bite marks on the autopsy photograph of a nose.

After alerting investigators, the body was exhumed and studied with the resultant identification and conviction of the murderer based on the victim's nose bite mark and the suspect's dentition! An appeal was made to the Supreme Court on the grounds that the dental



techniques were unique, untested, and not scientific. The appeal was denied, making this the first U.S. bite mark case to withstand the appellate process. Thus, the reliability of this method of identification was legally verified. (*People [of California] versus Marx*, 54 Cal. App. 3rd 100, 126 Cal. Repr. 350, Dec. 29, 1975.) Since the outcome of the decision in this landmark case, it has been cited many times in most state, federal, and military courts.

The notorious mass murderer Ted Bundy (executed January 1989) was positively identified as the perpetrator by his bite marks found on the buttocks of one of his young female victims.

An important development in forensic sciences was the report of the National Academy of Sciences in 2009 titled *Strengthening Forensic Science in the United States, A Path Forward*. This is an exhaustive report on all the forensic sciences and focused on the improvement of the entire field. This report is most applicable

to forensic dentistry in the area of bite marks. The Academy agreed that (1) the uniqueness of the human dentition has not been scientifically established, (2) the ability of the teeth to transfer a truly unique pattern to skin has not been scientifically established, (3) the analysis of the distortion of bite mark patterns has not been demonstrated, (4) the effect of distortion on different comparison techniques is not fully understood and has not been quantified, and (5) a standard for the type, quality, and number of individual characteristics required to make a bite mark valid for evidentiary value has not been scientifically established.

As a result of this report, the field of forensic dentistry is now working toward establishing increased scientific validity for human bite marks so that the evidentiary value is adequate for jurisprudence purposes. However, in the mean time, bite marks continue to remain a serious and important tool in criminal investigations.

## SECTION V

## MASS DISASTERS

Mass disasters are relatively common occurrences in our world. Most of us vividly recall the mass disaster that occurred on September 11, 2001 at the World Trade Center in New York City as well as at the Pentagon and in Pennsylvania. However, there are many natural disasters that cause mass fatalities. These include the August and September 2005 hurricanes (Katrina, Rita, and Wilma) affecting the Gulf Coast of the United States, the December 2004 tsunami in Indonesia and the Indian Ocean, and other hurricanes, earthquakes, floods, and tornados. Man-made mass disasters include the various forms of terrorist acts, armed conflicts, building collapses, large freeway motor vehicle accidents, industrial accidents, airplane crashes, and train wrecks. Mass disasters cannot be predicted with any accuracy, but they will certainly continue to happen in our immediate future and beyond.

The role of the forensic dentist in mass disasters is primarily to identify human remains. Knowledge of dental anatomy is crucial to this role. Human fatalities in mass disasters can number from a relative handful of individuals to thousands or hundreds of thousands. Management of small disasters can be relatively easily managed while larger disasters are more complex. The management of any size disaster will necessarily include considerations for harmful chemicals or other biologic agents (such as in bioterrorism). The dentist must be able to coordinate and function well in these situations from the initial occurrence of the disaster. This requires that the forensic dentist and the dental team are well

trained, led by experienced individuals, and completely integrated into the operation.

### A. PREPARATION AND TRAINING

A forensic dental team must be trained at the individual level and as a team. The Armed Forces Institute of Pathology (AFIP) course is the premier international training course held annually in Bethesda, Maryland (<http://www.afip.org>). The Southwest Symposium is offered biannually in June at the University of Texas Health Sciences Center at San Antonio (<http://www.uthscsa.edu>). Additionally, the American Society of Forensic Odontology (<http://www.asfo.org>) offers annual training and scientific programs and information on other courses nationally and internationally. All forensic dentists and teams who were initially called to New York City for the World Trade Center attack on November 9, 2001 were required to be AFIP trained and/or board certified by the American Board of Forensic Odontology.

### B. INITIAL RESPONSE

In the event of a mass disaster, local law enforcement agencies and emergency medical teams respond first. Legal authority and jurisdiction are by the legal entity such as city or county in which the disaster occurs. Rescue of injured individuals is the first priority for emergency medical services (EMS) personnel. Site security is the first priority for the law enforcement agency.

The initial response may include the mobilization of federal and statewide assistance. Responding agencies may include the National Transportation and Safety Board (NTSB), the Federal Emergency Management Agency (FEMA), the Disaster Mortuary Operational Response Team (DMORT), the Federal Bureau of Investigation (FBI), the National Disaster Medical System (NDMS), the Department of Homeland Security, and related state agencies.

It is critical for a dentist to be available at the disaster site to identify human remains and dental components of human remains that may not be recognizable by a non-dental-trained person. There should be a dentist onsite during the entire operation of search and recovery. Obviously, the knowledge of dental anatomy is critical to this aspect. A general recommendation is to have a forensic dentist accompany each body recovery team to ascertain that all relevant dental information necessary for identification is retained in a useful and trackable manner. All body parts are initially flagged on site and in situ, then photographed in place prior to removal. Extreme burn cases may require stabilization of the dentition with a spray lacquer such as polyurethane or even hair spray. This will stabilize the fragile dental evidence from damage during transport.

All body parts are given separate identification numbers, which will often mean that several parts of a single individual's dentition may possess different and unique identifiers that will ultimately be connected to a single identified body. In New York City after the World Trade Center disaster, as many as 200 individually identified and numbered body parts were later associated with a single victim. A single tooth found separated from a portion of a jaw or body would have a different number than the jaw part from which it is later associated. An appropriate tracking method is used to locate within the site grid and diagram the original location of each body and part. Aspects of this process can be used later in the forensic determination of cause and method of progression of the disaster event.

### C. MORGUE AND FORENSIC DENTAL IDENTIFICATION OPERATIONS

The dental section of the morgue operation is divided into three major components: antemortem examination, postmortem examination, and a comparison of each. Each of the three major sections has two forensic dentists. There is a minimum of one experienced forensic dentist in each of the teams. A team leader generally functions in a supervisory capacity as a shift commander. There are usually additional secretarial support personnel for overall coordination. *Figure 12-9*

depicts the dental radiographs and actual dissected jaws with dentition used to identify an actual aircraft incident victim for which a dental identification was required.

A critical component for dental identification procedures is the computer-based **WinID program** developed by Dr. James McGivney. An example of the document used for gathering information for this program is seen in *Figure 12-9D*. It is a database program that utilizes specific codes of antemortem and postmortem dental findings and identifies records that have a possible identification match. The forensic dental team then examines hardcopy records for final verification. This program can be downloaded at no cost from <http://www.winid.com>.

The personnel in charge of **antemortem records** obtain antemortem dental records from dentists of likely victims. These records must include copies of all dental chart information and notations, as well as original dental radiographs that are identified by name, date, and position (left, right, etc.). The antemortem team verifies and inputs this information into the WinID program to create a digital database.

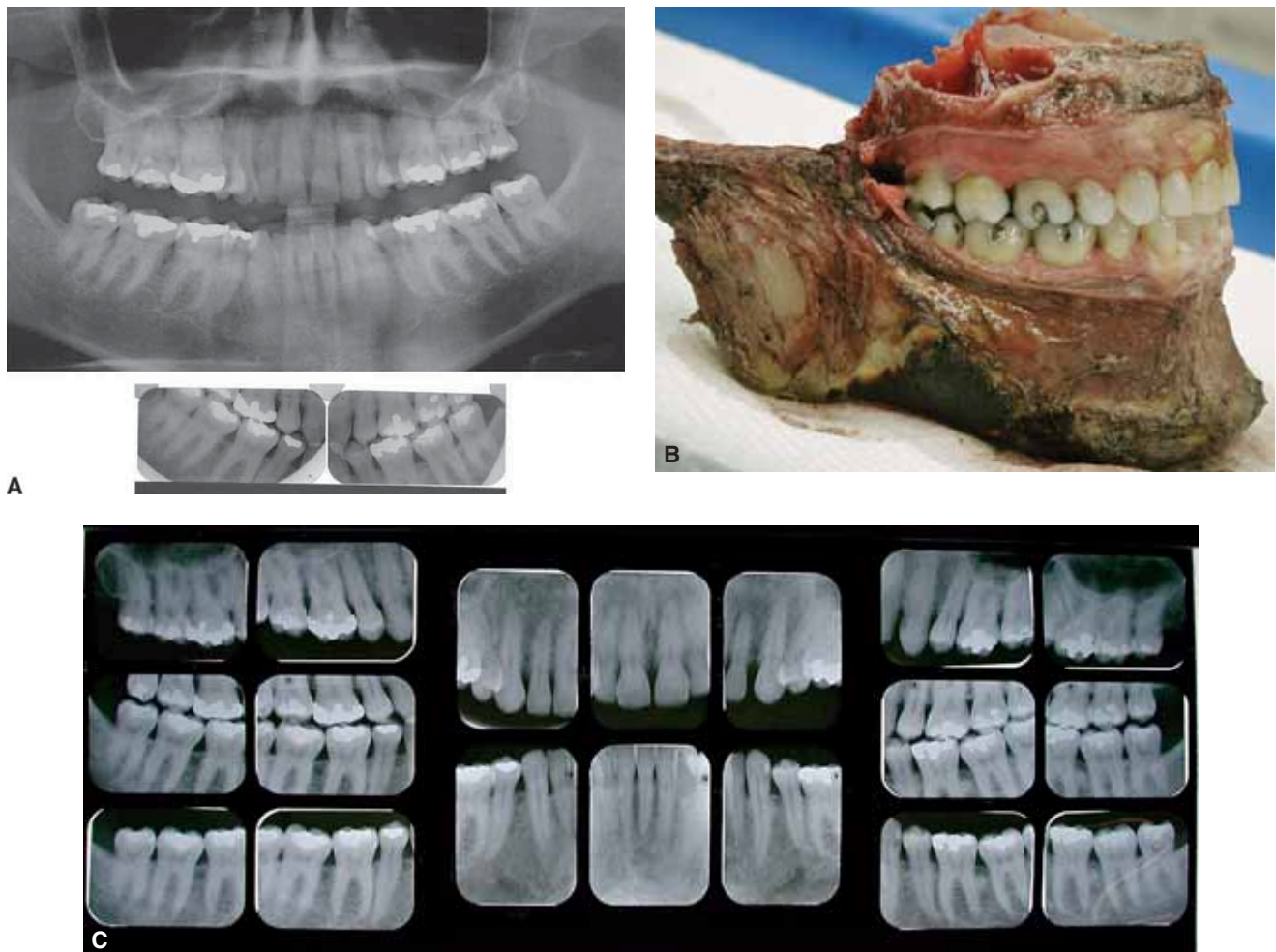
The dental radiographs alone are not adequate to complete antemortem charting. One must also consider the time span between antemortem information and the presumed time of death. Additional dentists may have provided dental care, and therefore, additional antemortem records may exist. The dental chart must be reviewed in detail to determine what additional restorations or other treatments (such as extractions) were provided subsequent to the date of the radiographs. For example, even though there is no antemortem radiographic evidence of a new mesio-occlusal amalgam, the postmortem charting can still be considered consistent with the antemortem radiographs if the radiographs were obtained prior to the placement of this more recent restoration, and if all other findings match. A paper record is filed in the antemortem file area. (See *Fig. 12-2* for a comparison of antemortem and postmortem radiographs to illustrate the changes that can occur between the antemortem and postmortem radiographs.)

Dental records could be provided in a language other than English, so translation may be necessary. When reviewing the antemortem chart, it is important, as noted earlier, to convert any numbering systems used by the dentist of record (Palmer, FDI, etc.) to the Universal numbering system common in the United States (numbered 1 to 32 for permanent teeth and A to T for primary teeth). One should also be attentive to esthetic treatments (composites, veneers, etc.) that could be missed on postmortem examination of remains that are covered with debris or damaged by

fire and trauma. Finally, in reviewing dental records, the quality of the handwriting and/or completeness of the record may pose significant barriers to determining accurate antemortem information.

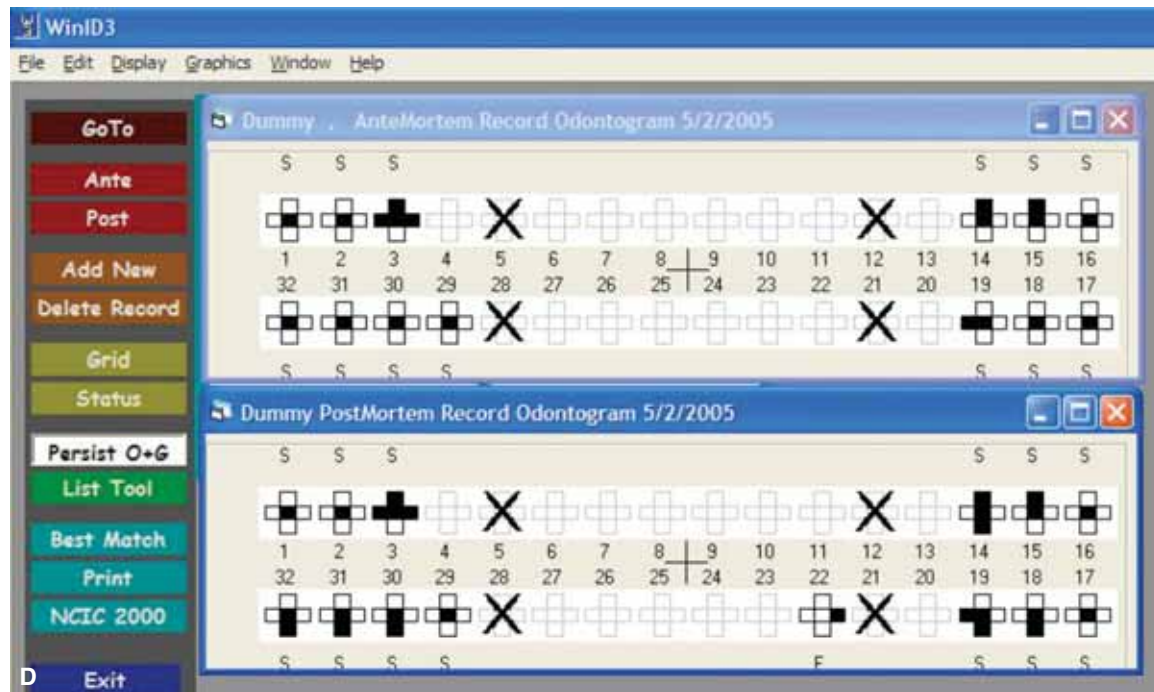
A team of two forensic dentists performs a thorough **postmortem examination** and then verifies each other to reduce the chance of errors. In severe burn cases, resection of the jaws may be required to accurately observe and take radiographs of the dental conditions (Fig. 12-9B). The victim's condition is recorded photographically, radiographically, and in written notes

as received in the morgue area. The process of postmortem dental examination, both clinical and radiographic, must consider numerous factors. On clinical examination, the forensic personnel must prepare the specimens by careful cleaning of debris, with care taken not to destroy fragile tooth fragments or the relation of teeth and tooth fragments to the rest of the dental arch. This is most critical in the burned victim. As noted earlier, the preservation of fragile dentition can be aided with spray lacquer or hair spray. Failure to do so can cause enamel to separate from the dentin, restoration



**FIGURE 12-9.** **A.** Antemortem films from the victim of an aircraft crash and severe burning. Original films must always be provided to the forensic dentist so that appropriate anatomic orientation can be made. Bitewings are the most helpful images for use in comparison of restoration morphology and pulpal conditions such as recession, pulp stones, etc. The antemortem charting of this individual's dentition can be seen in Figure 12-5A. **B.** For this victim, the jaws had to be resected to permit appropriate detailed clinical and radiographic examination. When properly dissected and cleaned, all tooth surfaces can be directly visualized, examined, photographed, and radiographed. (The forensic dentist must have appropriate permission from the medical examiner or coroner to remove body parts such as the jaws. Only when the victim is not viewable in a funeral home open casket setting, can this procedure be permitted.) **C.** The **postmortem dental radiographs** are shown here and can be easily compared to the antemortem records found in A. Close attention must be paid to tooth and root morphology, sinuses, trabecular patterns, bone levels, and restorations.

(Continued)



**FIGURE 12-9.** (Continued), **D. Antemortem and postmortem information** is transferred from the paper charts shown in Figure 12-5A and B to the WinID database. The database can then be used to search all unidentified victims for possible matches to antemortem records. The computer will provide a report as shown here in graphic fashion. The forensic dentist is still required to visually compare the dental radiographs and other examination information to ascertain identity, which was “positive” in this case.

loss, and/or destruction of porcelain restorations. The use of disclosing solution or transillumination can aid in the identification of composite restorations or other esthetic restorations.

The postmortem examination must also take into account the following: (a) identification of existing and missing teeth; (b) developmental and eruption stage; (c) estimated dental age; (d) occlusion and alignment of teeth; (e) structure of tooth crown (basic dental anatomy, anthropologic features, restorations, wear patterns, appliances, etc.); (f) root structure (such as apical development, dilacerations, root numbers, and endodontic therapy); (g) pulpal anatomy (pulp stones, recession of pulp chamber); (h) pathologic changes; (i) retained primary and supernumerary teeth, impactions, and retained root tips; (j) anatomy of sinuses; (k) bony architecture and trabeculation as seen on a radiograph; (l) bony pathology (exostoses, cysts, tumors, periodontal condition, periapical pathology, fractures, and foreign objects); (m) bone plates, screws, and wires, etc.; and (n) evidence of systemic diseases and conditions as well as congenital abnormalities.

At this time, the postmortem record can be completed according to the appropriate coding as shown on the forms. Coding used in the WinID program is slightly

different from that used in the average dental practice. Failure to use the appropriate codes will prevent the comparison feature of WinID from functioning properly. As a result, a match may not be found and a victim may not be properly identified.

The final step is **comparison** of the antemortem and postmortem records. In cases of individual identifications or the review of a few charts, this may be done manually. However, in large disasters, the use of a comparison program such as WinID is critical. In the management of a disaster on the scale of the World Trade Center disaster in 2001 involving the analysis of several thousand antemortem records and over 1000 postmortem dental examination records, WinID and computerized assistance are mandatory.

In the comparison process, there are three outcomes possible. Ideally, a positive identification is obtained. The other possible outcomes are either “consistent with” or “not a match or unidentified.” If any of the following conditions exist in the antemortem record but not in the postmortem record, there is an immediate **non-match**: missing teeth, restored tooth surfaces, unusual root morphology, or chronic pathology. However, it is possible for teeth to be removed, restored, or even orthodontically moved between the date of antemortem



information and time of death (recall Fig. 12-2A compared to B). These postmortem findings would not rule out a match between a person and an unknown victim. Pathology present in antemortem information could have been treated, or pathology present in the postmortem condition may not have existed in antemortem information. All of these situations must be readily and reliably explained.

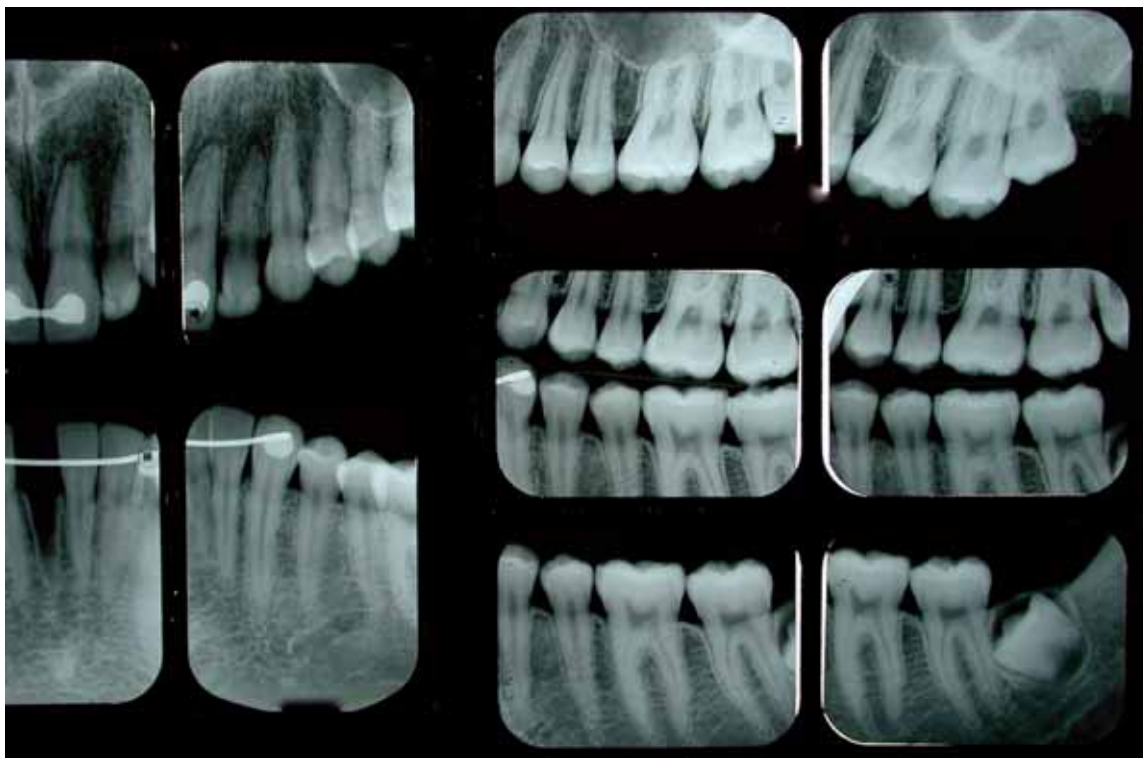
Final “sign-off” of the comparison is legally the responsibility of a licensed dentist with appropriate forensic odontology credentials.

#### D. FORENSIC ANTHROPOLOGY

Another component of forensic identification may involve determining the age, race (cultural heritage), and sex of the victim. Age can be estimated in some cases by the evaluation of the teeth, especially during the time of primary or mixed dentition as described in detail in Chapter 6. Growth and development of the dentition are complete by about 18 years of age. Once all primary teeth are exfoliated and third molars

are fully developed, whether impacted or erupted, the ability to gauge age by dental development is no longer reliable. Wear patterns and pulp chamber changes such as pulp stones and pulpal recession are not accurate. This author has worked with forensic cases where dental wear and pulpal recession appeared to indicate a person of 35 to 50 years of age when in reality the victim was in the early 20s. In another homicide case, a known 21-year-old female presented with an impacted tooth No. 16, which suggested a developmental age of 15 years, and an impacted tooth No. 17, which suggested a developmental age of at least 18 (Fig. 12-10).

Other anthropologic aspects of the dentition can provide indicators of racial or cultural backgrounds. Shovel-shaped incisors may indicate a person of Asian or Mongolian background. Other indicators of this ancestry include prominent zygomatic processes, moderate prognathism, rotation of the incisors, buccal pitting, an elliptical dental arch form, a straight mandibular border, and a wide and vertical ascending ramus. The presence of a cusp of Carabelli is most often an indicator of Caucasian ancestry. Other traits of Caucasian



**FIGURE 12-10.** Dental aging can be variable as shown in this same homicide victim case depicted in Figure 12-3. The development of the root of tooth No. 17 appears to be of a person around 15 years of age as shown in dental growth and development charts elsewhere in this textbook. However, tooth No. 16 appears to be of an individual at least 18 years of age. The actual victim’s age was 20 years. Although dental growth, eruption patterns, tooth apex development, and closure patterns are well documented, the reality of human variations can still be problematic in accurately assessing an individual’s age.

ancestry include a parabolic dental arch form, bilobate (two-lobed), and/or prominent chin, slanted and pinched vertical ramus, canine fossae, retreating zygomatic bones, and lack of prognathic mandible. The African American population may show vertical zygomatic bones, a noticeably prognathic mandible, molar crenelations (scalloped or notched), hyperbolic dental arch form, blunt and vertical chin, and a pinched and slanting ascending ramus. However, one must be cautious when making an ancestral determination due to the increasing number of mixed racial and ethnic backgrounds that can blur these findings.

Anthropologic determinants also include overall skull characteristics for ethnic, as well as sexual determination. The cranial sutures will ossify and obliterate as a person ages and can be used for age determination.

### E. MASS DISASTER CASE STUDIES

Several disasters highlight the value of a forensic dental team in the accurate identification of bodies. On the July 17, 1996, off East Moriches, New York, TWA flight 800 (a Boeing 747 aircraft) bound for Paris, France, exploded with 230 passengers aboard. Within the first 12 hours, a team of 30 dentists began the painstaking work of identifying the recovered bodies, which were devoid of clothing. Two and a half weeks later, 208 of the 210 recovered bodies and body parts had been positively identified. Ninety-five bodies were identified by dental records alone and another 60 by dental records along with medical records (radiographs, magnetic resonance images, etc.), medical anomalies, and fingerprints.

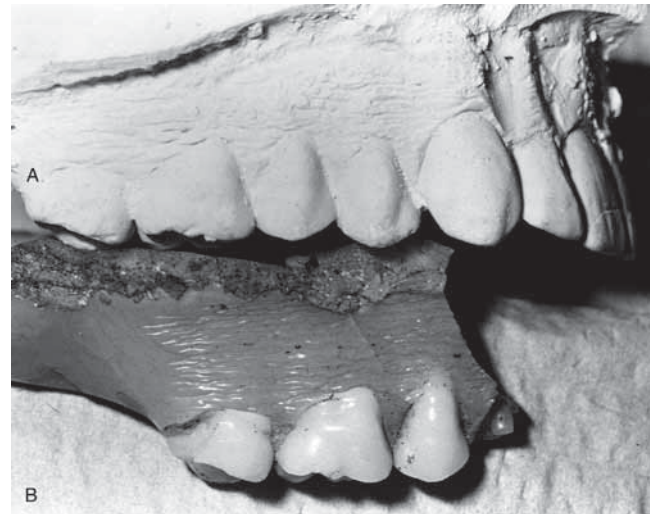For the first time ever, all relatives were screened for DNA samples to compare with the more than 400 recovered body parts, enabling the return of each to the families for an appropriate resting place. Nuclear DNA samples were extracted from both bone and dental pulps (which was all that remained after the first week). Mitochondrial DNA was also extracted from ground tooth structure, but it is only effective in matching maternal family connections. One victim was identified by examining DNA on toothbrushes in his home (Columbus Dispatch, Columbus, Ohio, April 1, 1997) since, during tooth brushing, microscopic bits of tissue from the gums and mucosa are scrubbed off and collect on the brush bristles. In all, seven people were identified by DNA alone because no other method was available.

One month later, Norwegian researchers were able to identify 139 of 141 people who died in a plane crash in Spitsbergen, Norway, in August 1996 (*Journal of Nature Genetics*, April 1997). They proved that 257 recovered body parts belonged to 141 people. They

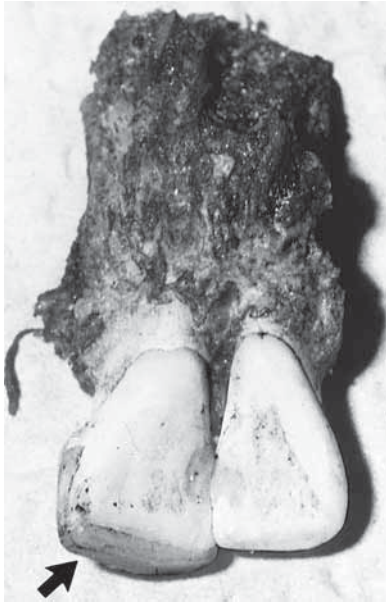collected DNA samples from close relatives. When relatives were not available, investigators collected DNA from hairbrushes, dirty laundry, and toothbrushes in the victims' homes.

On September 11, 2001, both towers of the World Trade Center in New York City were destroyed by terrorist hijacked aircraft, and 2726 people were killed in the disaster, more than those who died at the attack of Pearl Harbor by the Japanese Navy in 1941. The dental identification team consisted of over 200 dental personnel working for more than 1 year to identify bodies and body parts by dental records. Approximately 50% of all known victims (<1500) were identified, about half of those by dental records and half by DNA means. On November 12, 2001, American Airlines flight 587 crashed in Queens on Long Island due to mechanical failures and air turbulence. All 265 victims were processed for dental identification through the same facility serving the victims of the World Trade Center disaster. The identification process was completed in approximately 1 month and attention returned to World Trade Center victims by the Dental Identification Unit of the Office of the Chief Medical Examiner of New York City.

On December 26, 2004, the tsunami struck many communities around the Indian Ocean, causing an estimated death toll in excess of 212,000 people. The challenges for dental identification in this situation included



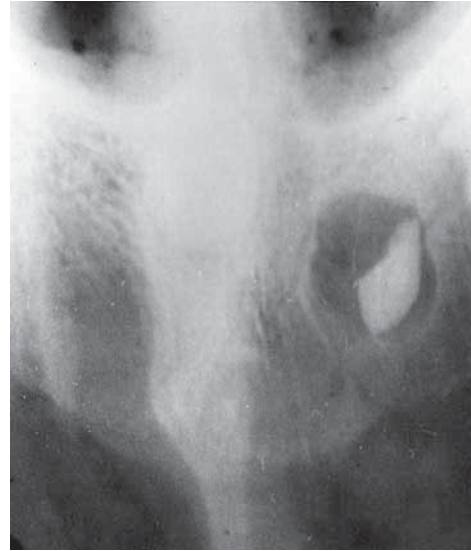**FIGURE 12-11.** The dental stone cast of an upper denture (A) was obtained in evidence collection for investigation of an airliner crash. A denture fragment (B) recovered from the crash site, with teeth numbers 2, 3, and 4 present, matches the antemortem cast. The impact broke off a distal piece of tooth No. 2. Unique horizontal grooves in the buccal resin of the denture precisely match those seen in the antemortem cast. (This photograph was provided by Dr. Theodore Berg.)



**FIGURE 12-12.** Although one or two teeth might seem scant evidence for identification, they should be thoroughly examined and radiographed. The labial laminate bonded veneer (*arrow*) made this specimen especially unique since this was in the early period of such technique. Also useful can be crown, root, and pulp shape; tooth positions; other restorations; pin and base buildups; endodontic therapy; posts; and bone trabecular patterns. (This photograph was provided by Dr. Theodore Berg.)

the loss of dental records from destroyed dental offices, and the socioeconomic and cultural situation that precluded many people from visiting a dentist and having antemortem information available for comparison.

On August 29, 2005, Hurricane Katrina, which had slightly weakened from a Category 5 to Category 4 storm, struck the New Orleans, Louisiana area of the Gulf Coast of the United States. At least 1386 people lost their lives. The primary challenge for the



**FIGURE 12-13.** Even an edentulous jaw might provide a big clue to identification with some unique feature such as the dentigerous cyst shown in the maxillary canine region. Each case challenges the investigator to carefully consider all possibilities and to make no premature assumptions. (This photograph was provided by Dr. Theodore Berg.)

dental identification teams was obtaining antemortem records. Many dental offices had been destroyed in the hurricane, and records were either lost entirely or too damaged by water to be usable. Only a minority of victims has been identified by any of the available techniques.

*Figures 12-11 through 12-13* provide three additional examples of dental evidence that was useful for identifying the victim of a mass disaster. *Figure 12-11* shows a denture, *Figure 12-12* shows a two-tooth jaw fragment with a unique restoration, and *Figure 12-13* shows a radiograph of a uniquely impacted tooth.

## SECTION VI

### IMPORTANCE OF FORENSIC DENTISTRY TO PRACTICING DENTISTS

Forensic dentistry is a large area of special interest. This short chapter could only provide a brief overview of the importance of dental anatomy as a foundation for the effective practice of the specialty. All dental professionals must maintain accurate and comprehensive dental records for legal, standard-of-care, and forensic purposes. This includes written records, radiographs, and models that accurately describe or reproduce the oral anatomic and anthropologic forms in detail. The weakest

link in the dental identification process (subsequent to locating the antemortem dentist of record) is the quality of the dental written and radiographic record. These records are the first step in the practice of forensic dentistry by every dental professional.

Even if the average dentist does not intend to be involved in forensic dentistry, the probability is that eventually he or she will be contacted regarding questions about quality of care or observed injuries (such as



suspected child or spousal abuse), or from law enforcement agencies requesting help. A valuable contribution can be made by understanding the role of dentistry in forensic science, by recognizing dental evidence or a bite mark, and by helping to properly preserve crucial evidence for later analysis.

The dental professional must understand how dental anatomy knowledge is valuable in forensic procedures. Other chapters of this text describe in more detail some of these anatomic features. The presence of a cusp of Carabelli on a maxillary first molar will identify a person as Caucasian heritage. Shovel-shaped incisors will identify a person of Mongoloid or Asian origin. Tooth root apex development is an age indicator. Cusp contours of lower premolars assist in the orientation of bites in a bite mark case when one understands cusp anatomy of lower versus upper premolars. Root dilacerations, pulp stones, pulpal recession in the elderly or bruxing patient, maxillary sinus morphology, and virtually all aspects of dental anatomy are useful in the forensic identification of an individual or for assessing standard-of-care issues. In some cases, as in the World Trade Center disaster, the ability to identify a single tooth as a maxillary versus mandibular premolar was the key to the ability to search the database of antemortem records and confirm identification.

You will find dental anatomy the foundation or basis for any forensic dentistry investigation. The references offered within this chapter were selected to give the novice a practical and representative introduction to the field and techniques of forensic dentistry.

## GENERAL REFERENCES

- Seven concise articles with an overview introduction on bite marks, crime investigation, child abuse, photographic computers, and mass disasters are presented in the May 1996 *Journal of the California Dental Association*.
- American Board of Forensic Odontology. Guidelines for bite mark analysis. *JADA* 1986;112(3):383–386. Available at: <http://www.abfo.org>;
- American Society of Forensic Odontology's information source via the Internet: <http://www.asfo.org>
- Bowers CM. *Forensic dental evidence*. Boston, MA: Elsevier Academic Press, 2004
- Bowers CM, Bell GL, eds. *Manual of forensic odontology*. 3rd rev. ed. Saratoga Springs, NY: American Society of Forensic Odontology, 1997. This manual can be obtained from the American Society of Forensic Odontology at <http://www.asfo.org>
- Clark DH, ed. *Practical forensic odontology*. Boston, MA: Wright (Butterworth-Heinman Ltd), 1992.
- Cottone JA, Standish SM. *Outline of forensic dentistry*. Chicago, IL: Year Book Medical Publishers, Inc., 1982.
- deVilliers CJ, Phillips VM. Person identification by means of a single unique dental feature. *J Forensic Odontostomatol* 1998;16(1):17–19.
- Dorion RB. *Bitemark evidence*. New York: Marcel Dekker, 2005.
- Gill GW, Rhine S. Symposium ed: skeletal attribution of race—methods for forensic anthropology. Manual available from Maxwell Museum of Anthropology at the University of New Mexico, Albuquerque, NM, 1990.
- Guidelines for bite mark analysis by the American Board of Forensic Odontology. *JADA* 1986.
- Harvey W. *Dental identification and forensic odontology*. London: Henry Kimpton Publishing, 1976.
- Krogman W. *The human skeleton in forensic medicine*. Springfield, IL: Charles C. Thomas Publishers, 1973.
- Lampe H, Roetzcher K. Age determination from adult human teeth. *Med Law* 1994;13(7–8):623–628.
- Luntz L, Luntz P. *Handbook for dental identification*. Philadelphia, PA: J.B. Lippincott, 1973.
- Melia E, Carr M. Forensic odontology and the role of the dental hygienist. *Access* 2005;19(3):15–23.
- Nuckles DB, Herschaft EE, Whatmough LN. Forensic odontology in solving crimes: dental techniques and bite mark evidence. *Gen Dent* 1994;42(3):210–214.
- Rothwell BR. Bitemarks in forensic dentistry: a review of legal, scientific issues. *JADA* 1995;126(2):223–232.
- Sopher M. *Forensic dentistry*. Springfield, IL: Charles C. Thomas, 1976.
- Standish SM, Stimson PG. Symposium on forensic dentistry: legal obligations and methods of identification for the practitioner. *Dent Clin North Am* 1977;21(1):145–158.
- Strengthening Forensic Science in the United States: A Path Forward. Committee on Identifying the needs of the Forensic Sciences Community; Committee on Applied and Theoretical Statistics, National Research Council, 2009 (ISBN: 0-309-13131-6, 24 pages).
- Stimson PG, Mertz CA. *Forensic dentistry*. Vol 21(1). Boca Raton, FL: CRC Press, 1997.
- Wood JD, Gould G. Mass fatality incidents: are California dentists ready to respond. *J Calif Dent Assoc* 2004;32(8):681–688.
- Wright FD. Integrating new technologies in bitemark analysis. *Am Soc Forensic Odontol News* 1999;Winter.
- Wright FW. *Forensic dentistry: an introduction*. Columbus: Ohio Dental Association 2005. Available from the Ohio Dental Association, 1305 Dublin Road, Columbus, Ohio 43215.



# Guidelines for Drawing, Sketching, and Carving Teeth

- I. Drawing teeth
  - A. Materials needed
  - B. How to accurately reproduce a tooth outline
  - C. Example: accurately reproduce the shape of a *mandibular canine* (copying an actual tooth or tooth model)
- II. Sketch teeth recognizably from memory
- III. Carving teeth
  - A. Materials needed
  - B. How to carve a tooth
  - C. Example: how to carve a maxillary central incisor from a block of wax
  - D. Advice

## OBJECTIVES

This chapter is designed to prepare the learner to perform the following:

- Carefully draw a tooth to reproduce its contours precisely from various views.
- From memory, sketch (quickly) teeth from various views so that the sketch is recognizable as the tooth is being sketched.
- Reproduce the contours of a tooth in wax.

## SECTION I

## DRAWING TEETH

### A. MATERIALS NEEDED

- Graph paper ruled eight squares to the inch
- Drawing pencil, sharpened to a fine point
- Eraser
- Ruler with millimeter scale
- Boley gauge
- Teeth or tooth model
- Chart with dimensions of tooth to be drawn (such as Table 1-7)

### B. HOW TO ACCURATELY REPRODUCE A TOOTH OUTLINE

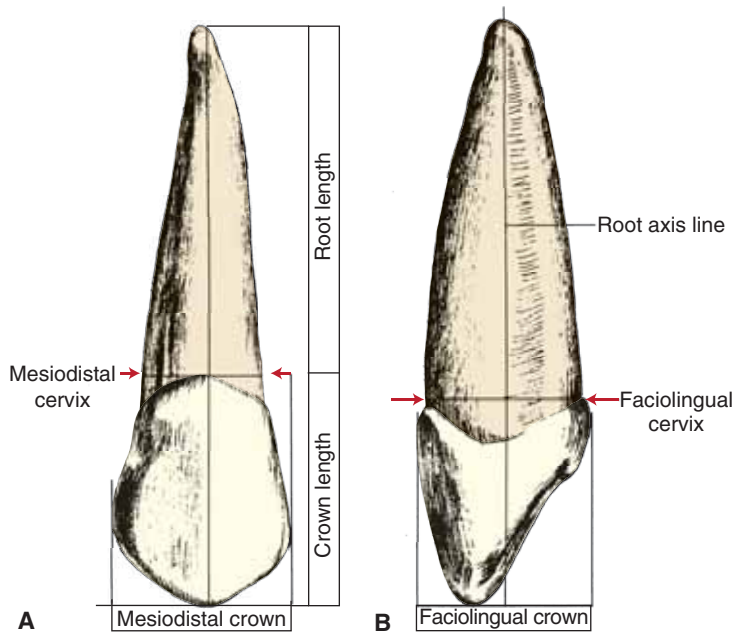
To accurately reproduce the outline of any object, not only must you look at the object, but you must also study and visualize it. Rarely is there a person, however lacking in artistic skill, who cannot make a reasonably good drawing of a human tooth. Those who are not skilled in accurate drawing (extensive art training does not necessarily result in accuracy of outline) may find a solution in using graph paper ruled eight squares to the inch. The tooth specimen is measured in millimeters with a Boley gauge, and the measurements are transferred to the graph paper, allowing one square to equal 1 mm.

Drawings may be made to scale of each type of tooth: maxillary and mandibular incisors, canines, premolars, and molars. All drawings should depict maxillary teeth with crowns down and mandibular teeth with crowns up, the same orientation they have in the mouth.

Using an undamaged extracted tooth or a tooth model for a specimen, make the following six measurements with the Boley gauge (Fig. 13-1A and B):

- Crown length
- Root length
- Mesiodistal crown width
- Faciolingual crown width
- Mesiodistal cervix
- Faciolingual cervix

Using a consistent method of measurement avoids confusion. On anterior teeth, measure the crown length on the facial side from the cervical line to the incisal edge. On premolars, measure the crown length on the facial side from the cervical line to the tip of the buccal cusp. On molars, which have more than one buccal cusp, crown length is always to the mesiobuccal cusp tip. Make the other cusps their proper length relative to the measured cusp, that is, either longer or shorter.



**FIGURE 13-1.** A. Facial side of a maxillary right canine tooth model showing how measurements of a tooth may be made to assist in drawing and carving. B. Mesial side of the same maxillary canine showing how tooth measurements can be made and how the incisal portion is positioned relative to the root axis line.

With more than one root, the overall tooth length is measured from the mesial or mesiobuccal root apex to the mesiobuccal cusp (refer to Table 1-7).

Plan how you want to place your drawings on the graph paper. One convenient arrangement is facial aspect, upper left corner; lingual aspect, upper right; mesial aspect, lower left; distal aspect, lower right; and incisal aspect, center (Figs. 13-2 and 13-3). These views will be centered nicely if you allow a four-square border on all sides of the paper, as shown in the same illustrations.

### C. EXAMPLE: ACCURATELY REPRODUCE THE SHAPE OF A MANDIBULAR CANINE (COPYING AN ACTUAL TOOTH OR TOOTH MODEL)

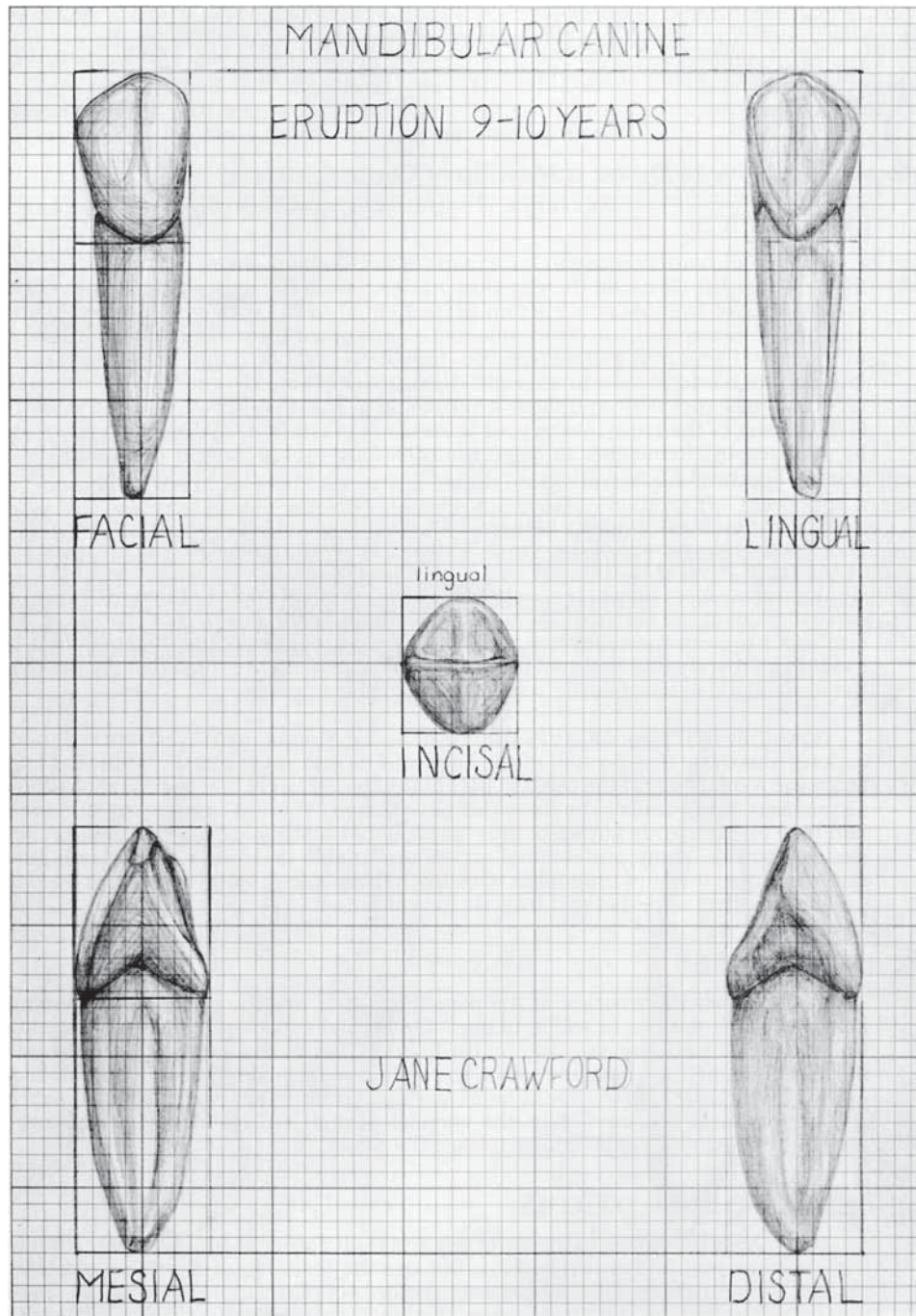
#### 1. FACIAL VIEWS

Use the measurements you have made of the tooth specimen you intend to draw. Begin with the outlines for the facial view of the tooth in the upper left corner of the page, and count down from the upper four-square border the number of squares and fraction thereof equal to the *crown length* in millimeters and draw a horizontal line. From this line, count down the number of squares equal to the *root length* in millimeters and draw a second horizontal line. From the inside of the left four-square border, count to the right the number of squares equal to the *mesiodistal crown* measurement and draw a

vertical line. You will draw the facial aspect of the tooth inside the box. Make your lines very light at first so that corrections can be made easily. Remember to begin from the four-square margin (top and side), as seen in Figure 13-2.

Before you start to draw the crown from the facial view, make a light mark at the locations of the mesial and distal contact areas of the crown. (A pencil or straight edge held vertically against the side of the tooth parallel to the root axis line will help you determine where to put these light marks.) Then, mark the location of the apex of the root. Also, mark the mesiodistal width of the cervix of the tooth on the horizontal line that separates the crown from the root. When you fit the crown into the box, if you remember to keep the root vertical, the mid-root axis will not always be an equal distance from the mesial and distal sides because the crowns of some teeth are tilted distally. Mark off the mesiodistal cervical measurement very lightly.

Now draw in the curvature of the crown at the contact areas (you marked the location) and draw in a portion of the cervical line and the incisal cusp ridges. Draw the root apex and the cervical part of the root. Correct any errors in location or shape, and then connect the lines you have drawn. You have a drawing of a tooth. You may be pleasantly surprised how natural and morphologically correct this first sketch appears. Many professional artists are unable to depict natural teeth accurately because they are unfamiliar with tooth morphology, and they do not have the proportions that were dictated by your measurements.



**FIGURE 13-2.**

A precise drawing on graph paper of a model of a mandibular right canine by a first-year dental hygiene student.

## 2. LINGUAL VIEWS

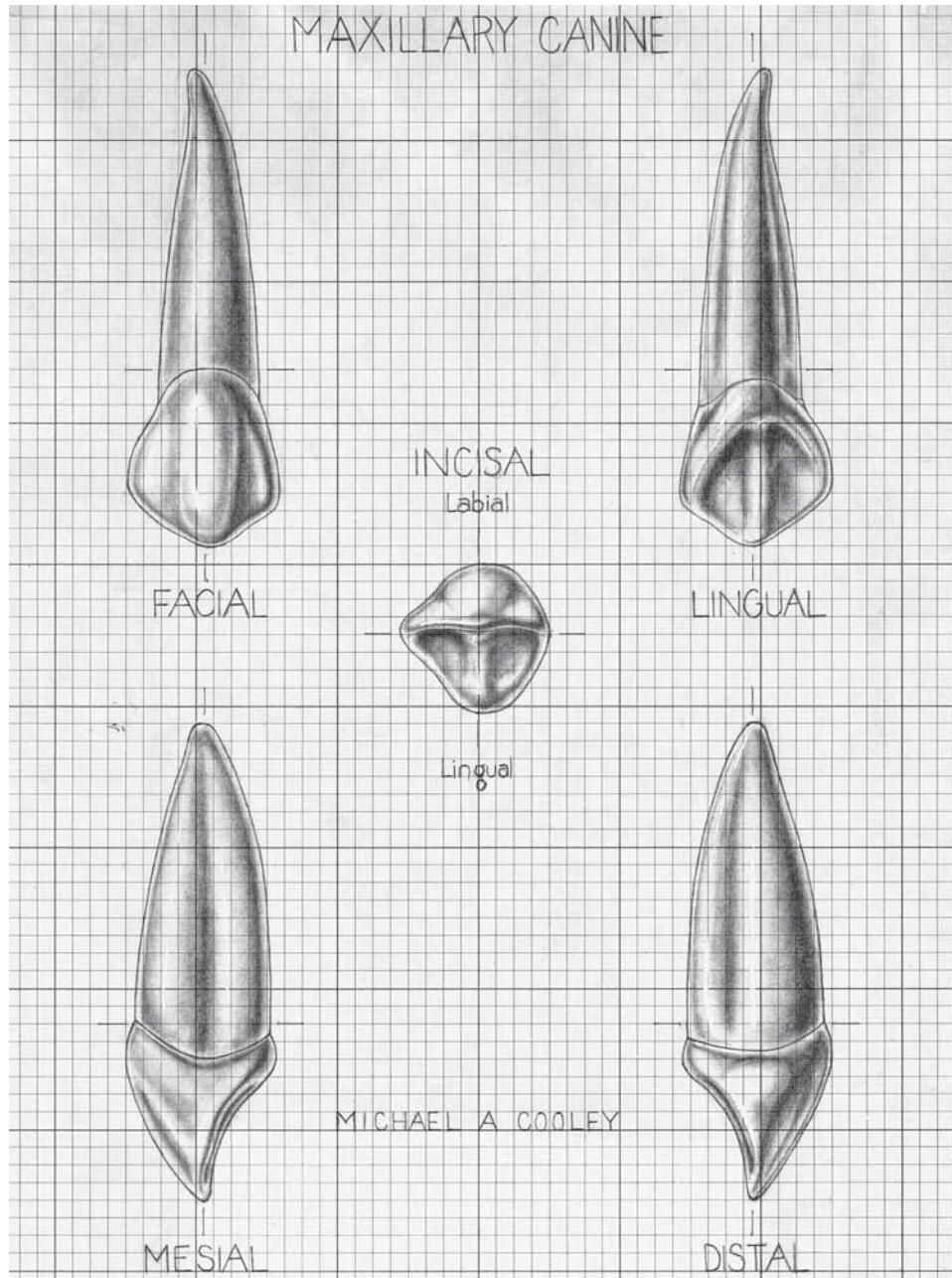
In the upper right corner of the page (Fig. 13-2), use the same set of measurements to make the box in which to draw the lingual aspect of the tooth. Remember that almost all teeth taper toward the narrower lingual surface, but the overall outline from the lingual is the same width as from the facial view. The cingulum is narrower

than the cervical portion on the labial sketch, and it should be drawn centered or a little toward the distal.

## 3. MESIAL AND DISTAL VIEWS

Draw these two boxes in the lower left and right corner of the page (Fig. 13-2) using the same root and crown lengths. However, use the *faciolingual crown*





**FIGURE 13-3.** Professional drawing (by medical artist) of a model of a maxillary canine based on dimensions given in Table 1-7.

measurement instead of the mesiodistal measurement. Before you start to draw the tooth, lightly mark the locations of the incisal edge, the labial crest of curvature (i.e., where the curve or greatest convexity of the labial surface will touch the line of the box), and the crest of curvature on the cingulum (Fig. 13-1B) and the root tip. Mark the faciolingual width of the cervix. Then draw the tooth. Remember to leave the four-square border at each side and below these views.

#### 4. INCISAL VIEW

Near the center of the page, draw a box with the distance between the upper and lower horizontal lines the exact number of squares for the *faciolingual* measurement of the crown in millimeters. The distance between right and left vertical lines of this box should equal the number of the squares of the *mesiodistal* crown measurement in millimeters. Hold the tooth facial side down and in such a position that you are looking exactly in



line with the root axis line. Be sure that the tooth crown is not tilted up or down. On the sides of the box, mark the places where you are going to locate the mesial and distal contact points of the crown. The incisal edge of the tooth will normally have a slight lingual twist of the distoincisor corner (not evident in Fig. 13-2) and will lie either in the center of the box faciolingually or slightly lingual to the center (in the same position it is shown on your drawings of the mesial and distal aspects).

The cingulum is normally centered on, or slightly distal to, the root axis line.

Do you find any straight lines (ruler-straight, that is) on any tooth other than those lines that have been produced by attrition? This would be most unusual.

Using the same approach, you will be able to draw other types of teeth. Labeling the grooves, the fossae, and the ridges on the occlusal surfaces of the posterior teeth will help to fix the morphology in your mind.

**SECTION II SKETCH TEETH RECOGNIZABLY FROM MEMORY**

The extremely precise and accurate drawings described in Section I of this chapter have the value of developing skills to accurately visualize and reproduce the subtle outlines and exact grooves of a specific tooth from various views. However, this time-consuming method of copying teeth may have limited value in helping the student to quickly sketch a tooth from memory for a specified view as might be expected during a conversation with an instructor or a patient. Therefore, this section includes guidelines that can be useful for dental and dental hygiene students when learning how to quickly sketch a specific tooth and view from memory.

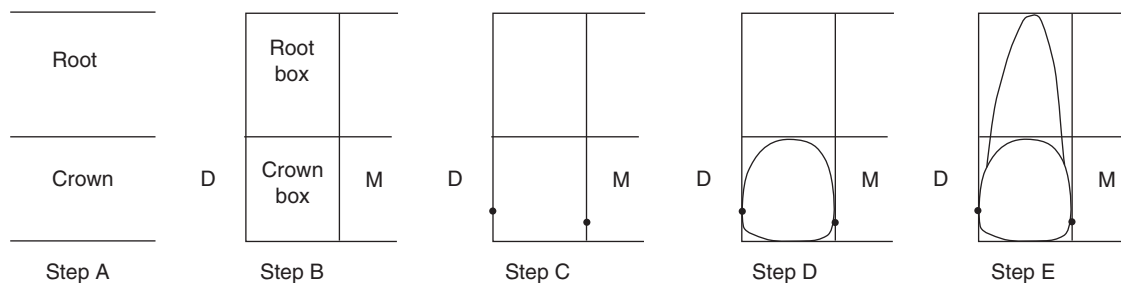
In order to sketch a facial view of a recognizable tooth from memory, the drawer must have knowledge of the following characteristics related to the tooth being drawn: (a) approximate crown-to-root ratio (i.e., how much longer is the root compared to the crown), (b) approximate crown proportions (i.e., which is wider: the crown width or its length), (c) location of the crown heights of contour (crests of curvature), (d) crown shape (taper, incisal edge shape or number and relative size of cusps, and cementoenamel junction [CEJ] shape), and (e) root shape (taper and number of roots) when drawing the entire tooth. If one considers each of these tooth characteristics in the appropriate order, sketching a tooth becomes a relatively easy task and is an excellent exercise to apply all of the

knowledge of dental morphology that was presented in Section I of this text: Comparative Tooth Anatomy.

As an example, consider a sketch of a *right maxillary central incisor* from the facial view. Follow along with *Figure 13-4* as you read about each step.

**Step A:** Consider the root-to-crown ratio. It is not expected that a student will remember the exact ratio of this tooth (1.16 to 1) but rather he or she should recall that all roots are normally longer than the crown. On maxillary central incisors, the root is only slightly longer than the crown. Based on this fact, three parallel horizontal lines can be drawn to denote the distance of the crown length from incisal edge to the cervical line relative to the root length from cervical line to root apex (only slightly longer). Position the smaller crown length on top for the mandibular teeth and on the bottom for maxillary teeth. For this maxillary central incisor, the crown length is on the bottom.

**Step B:** Consider the proportions of the crown, that is, the crown height (incisocervically) compared to its width (mesiodistally). Again, you do not need to memorize that the average crown width for this tooth is 8.6 mm and its average length is 11.2 mm, but you should recall that the maxillary central incisor crown is slightly longer than it is wide. Using this



**FIGURE 13-4.** Five steps involved in sketching the facial view of a tooth (in this case, a right maxillary central incisor).

knowledge, two parallel vertical lines can be placed perpendicular to the horizontal lines to establish the proportion for the tooth crown. Extending these vertical lines along the entire tooth length results in the formation of two boxes: a crown box that will surround the crown and a root box that will enclose the root. At this time, label the mesial (M) and distal (D) surfaces of the crown box that is dependent on whether you are viewing a right or left incisor. For this right incisor, the mesial surface is on the right side of the box, and the distal is on the left side, as if you were facing the patient.

**Step C:** Consider the heights of contour (crests of curvature) on the mesial and distal surfaces. Since these two points are the widest parts of the tooth crown where the mesial and distal surfaces bulge out the most, they are therefore the points where the crown outline touches the crown box established in the previous step. When the teeth are in ideal alignment, they are the location of the proximal contacts. On all incisors, the proximal heights of contour (contacts) occur in the incisal one third (EXCEPT on the distal of a maxillary lateral incisor, which is in the middle third) and are located more incisally on the mesial surface than on the distal surface (EXCEPT on the symmetrical mandibular central incisor). With this knowledge, a dot can be placed on the mesial and distal crown box outline at the appropriate levels. It is not until this step is complete that you actually begin sketching the tooth crown shape (outline).

**Step D:** Begin sketching the crown outline. Use as many of the criteria presented in the Appendix as you can recall in order to sketch a recognizable tooth. For example, on a maxillary central incisor, we know that the areas immediately surrounding all contact areas are convex; mesial and distal crown walls taper slightly toward the root; and the incisal edge is almost flat or slightly convex and is a little shorter toward the distal. We also know that the cervical line from the facial view is broad and curves toward the apex. Based on this knowledge, begin sketching the crown outline by placing subtle convexities that touch the crown box at the heights of contact points (dots). These convexities blend apically to become the mesial and distal crown walls, and these walls converge (just slightly) toward the cervical line. The proximal convexities also curve incisally to blend with the relatively straight incisal edge that touches the incisal line of the crown box in the mesial half and tapers shorter (farther from the box outline) toward the distal. Finally, the cervical line appears as a continuation of the mesial and distal walls and curves toward the apex, just touching the cervical line of the

crown box. If a sketch of the crown were all that you are reproducing, you would be finished. If, however, you wish to add the root, proceed to the final step.

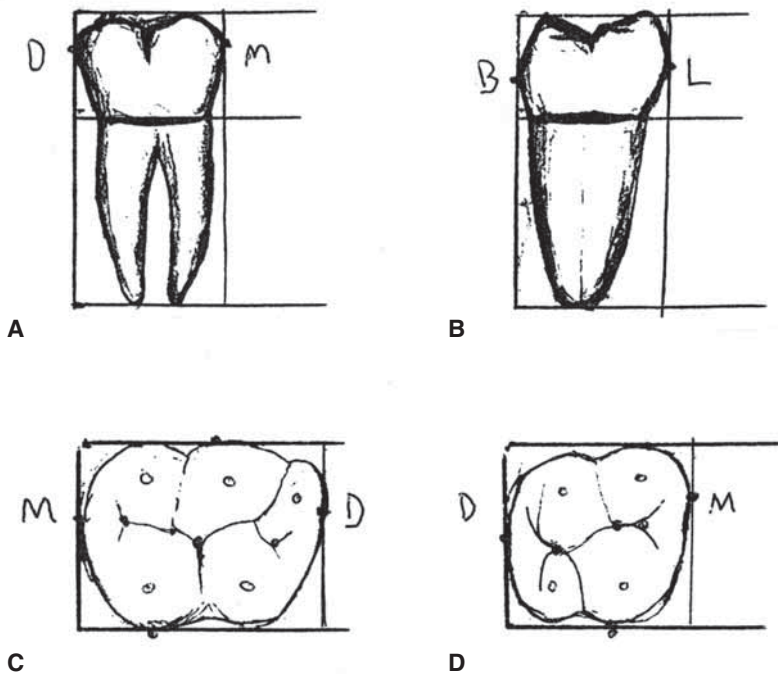
**Step E:** Sketch the root. We know that the apex of the root is near the center of the tooth root axis (a vertical line in the center of the root at the cervix). We also know that roots are broadest in the cervical third (but not very much narrower than the width of the crown), may be nearly parallel in the cervical third, and taper toward the rounded apex. Based on this knowledge, you can finish the sketch. Be aware that part of the root outline where it joins the CEJ is actually visible within the crown box, and the rounded apex just touches the apical line of the root box.

When sketching other teeth from the facial views, use steps A through C as described earlier for developing the “boxes” and crests of curvature, and refer to the Appendix pages for tooth traits when sketching the actual tooth outlines. With practice, teeth can be sketched without the boxes in less than a minute while still maintaining the approximate proportions and heights of contour. See the student sketch of a recognizable mandibular second molar from the buccal view in *Figure 13-5A*.

The steps used to sketch the *lingual* view of all teeth are the same as for the facial view EXCEPT the outline is a mirror image of the facial view. Also, on this surface of anterior teeth, there is normally evidence of a narrower crown cingulum, marginal ridges, a lingual fossa, and a cervical line that often includes a partial view of the proximal CEJ due to the taper of teeth toward the lingual (as seen in Fig. 13-2, lingual view). On maxillary molars, the lingual root is now in the foreground.

When sketching the *proximal* view of teeth, the first two steps are similar to steps A and B above except that the crown outline box is developed for this view by using the faciolingual and inciso- or occluso-cervical crown proportions. The facial crest of curvature is similar for all teeth: in the cervical third. Lingually, the crest of curvature is in the cervical third on the cingulum for anterior teeth but in the middle third for most posterior teeth. Develop a crown and root shape according to guidelines in the Appendix. See the student sketch of a mandibular second molar from the mesial view in *Figure 13-5B*.

Posterior teeth from the *occlusal* view are viewed looking directly down along the axis of the root. Crown-to-root ratios do not apply from this view. The crown outline box is developed for this view by using the mesiodistal and faciolingual crown proportions. On mandibular premolars, the crown proportions are slightly longer buccolingually than mesiodistally, but close to square. Maxillary premolars from the occlusal



**FIGURE 13-5.** Four sketches of teeth by first-quarter dental and dental hygiene students: although not perfectly drawn, each sketch is recognizable as the tooth being drawn. **A.** Right mandibular second molar, facial (buccal) view. **B.** Right mandibular first molar, mesial view. **C.** A right mandibular first molar, occlusal view. **D.** A right maxillary first molar, occlusal view. Sketches A and B would look nicer if the lines were not so wide and dark.

view are similar to mandibular premolars except crown proportions are less square, more rectangular: proportionally wider buccolingually than mesiodistally. Mandibular molars from the occlusal view are wider mesiodistally than buccolingually, whereas maxillary molars are slightly wider buccolingually than mesiodistally. The crests of curvature on molars and premolars on the mesial and distal surfaces are located in the center or slightly to the buccal of the buccolingual midline. The buccal and lingual crests of curvature for molars are located mesial to the middle, except on the buccal of the mandibular first molar where it is close to the middle. After the outline “box” is sketched and crests of curvature have been noted, sketch the crown outlines using descriptions from the Appendix pages.

An additional challenge on these views involves reproducing the location of the cusp tips, grooves, and pits (as must be accomplished by dental personnel every time a restoration is placed on an occlusal surface, finished and polished, or constructed or carved in wax in the laboratory).

Cusp tips can be identified by placing small dots (or small circles) on the sketches at these locations. It may be helpful to remember these basic guidelines regarding pits and grooves. Most premolars have a mesial and distal pit connected by a groove running mesiodistally between buccal and lingual cusps. Most molars (and three-cusped mandibular second premolars) have three pits (mesial, central, and distal) that are also connected by a groove passing mesiodistally between buccal and lingual cusps. Molars also have one or two buccal grooves that separate the two or three buccal cusps, respectively. On mandibular molars, the lingual groove comes off near the central pit, but on maxillary molars, a lingual (distolingual) groove comes off of the distal pit and parallels the oblique ridge. Developmental triangular or fossa grooves or supplemental grooves may angle off from the mesial and distal pits of most posterior teeth, directed toward the “corners” of the tooth. See the student sketches of the occlusal views of two recognizable molars in Figure 13-5C and D.

## SECTION III CARVING TEETH


### A. MATERIALS NEEDED

- Blocks of carving wax (34 × 17 × 17 mm for molars or 32 × 12 × 12 mm for other teeth)
- Boley gauge (Vernier caliper)
- Millimeter ruler
- Office knife and sharpening stone
- Roach carver, No. 7 wax spatula, and PKT-1 (for melting and adding wax)
- No. 3, No. 5-6, 6C, and PKT-4 carvers
- Sharpened drawing pencil
- Large or small tooth model and its measurements

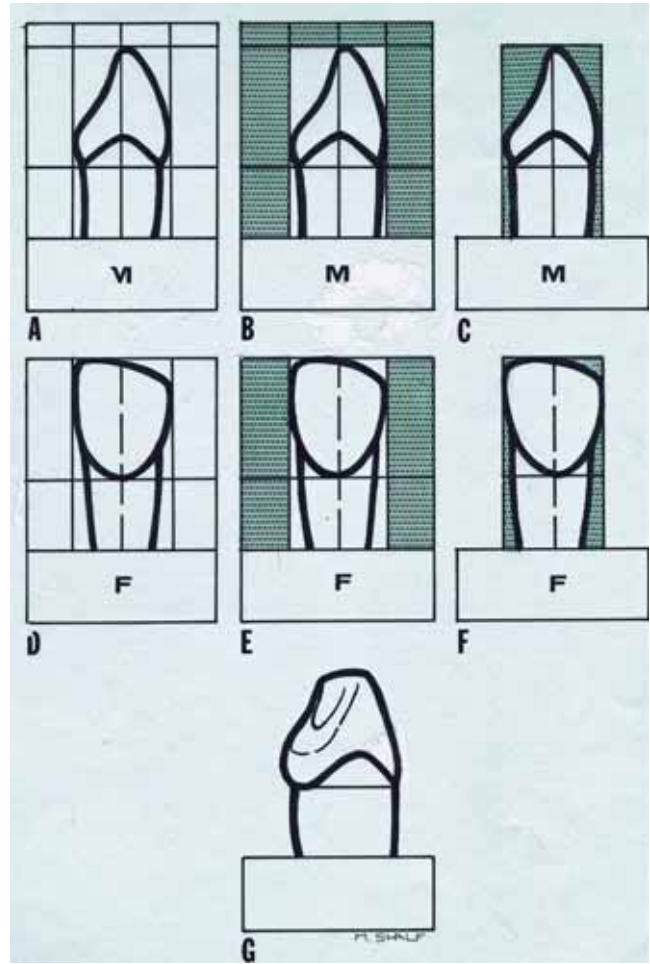
## B. HOW TO CARVE A TOOTH

Carving a tooth helps you to see the tooth in three dimensions and also to develop considerable manual skill and dexterity. Examples of carvings by dental hygiene students are shown in Figure 13-6. While eventually you may be able to carve a tooth from a block of wax without preliminary measurement, the beginner can only do well by approaching the carving systematically in the same way you approached the drawings: first, by drawing a box on the wax block; second, by sketching an outline of the tooth in the box; and third, by carving around the sketch or outline, one view or aspect at a time (sequence is shown in Fig. 13-7).

When approaching the task of carving a tooth, consider Michelangelo who conceived of his task of producing a marble statue by “liberating the figure from the marble that imprisons it.” And remember that he, too, sometimes made mistakes and had to discard a half-finished statue. The same can happen to your tooth carving. To minimize this, as you cut away wax, repeatedly examine your carving from all sides; turn it around and around and compare it with your specimen from each view. Where it is too bulbous, the fault is easily correctable by further reductions. Where too much wax has been removed, you have one of three choices: add molten wax to the deficient region, make the entire carving proportionally smaller, or start with a new block of wax.



**FIGURE 13-6.** Maxillary central incisor wax carvings by first-year dental hygiene students as seen from the mesial (M), lingual (L), incisal (I), facial (F), and mesial-facial (M, F) aspects: The crown and half of the root were carved to specific dimensions that were proportional to the tooth model they viewed during the carving. These excellent carvings were each done in less than 3 hours as a required skill test.



**FIGURE 13-7.** The sequential method described in this chapter for **carving a tooth from a block of wax**. The final product should look like those shown in Figure 13-6. The large letter M denotes the mesial aspect of the carving. Likewise, F indicates the facial side of the block.

## C. EXAMPLE: HOW TO CARVE A MAXILLARY CENTRAL INCISOR FROM A BLOCK OF WAX

Use the measurements you used for drawing. (Again, use the measurement of the buccal cusp on premolars for the crown length, and of the mesiobuccal cusp and mesiobuccal or mesial root on molars for the root length.) This consistency of method prevents confusion. Allowance is made for the greater length of some lingual cusps, which are longer than the measured buccal cusp. Refer to Figure 13-7 as you follow the following guidelines:

- Step 1: Shave the sides of the block flat and make all angles right angles.
- Step 2: Measure 2 mm from one end of the block and **draw** a line at this level, encircling the block (on all four sides). (This end of the block will be the incisal



or occlusal end of the tooth and the 2 mm allowance here is to provide for the extra length of the lingual cups on molars that are longer than the mesiobuccal cusp that established crown length. Although it is convenient to allow the 2 mm on all carvings, it is essential only for molars.)

**Step 3:** From the 2-mm line, measure the crown length and **draw** a second line around the block at this level. This line is the location of the cervical line on the facial, mesial, distal, and lingual sides of the tooth (Fig. 13-7A).

**Step 4:** From this cervical line, measure one half of the length of the root and **draw** a third line around the block. (The end of the block beyond this line will be referred to now as the base.)

**Step 5:** On the base of the block, **carve**, on appropriate sides, F (facial), L (lingual), M (mesial), and D (distal). Be sure to put M and D in the proper relation to F and L so that you will carve a right or a left tooth, whichever you intend.

**Step 6:** Using a very sharp pencil, **draw** a shallow line lengthwise on the block in the center of the mesial surface. Do the same on the distal surface and be sure that these lines are exactly opposite.

**Step 7:** Add 0.5 mm to the faciolingual measurement of the crown. Divide this number by 2. Using this measurement, **draw** a line this distance on either side of the center line on the mesial and distal sides of the block (Fig. 13-7A). These two outer lines should be parallel to the center line and extend from the top of the block to the base. These two lines form a box whose dimension faciolingually is equal to the crown dimension plus 0.5 mm. The extra 0.5 mm is an allowance for safety in carving. Do not make trouble for yourself by allowing more than this extra 0.5 mm.

**Step 8:** On the *mesial* side of the block marked M, **draw**, within the box, an outline of the mesial side of the tooth as you drew it on the graph paper. Be careful to place the incisal edge and the labial and lingual crests of curvature accurately. Your carving will probably be no better than this drawing.

**Step 9:** **Draw** a similar outline on the *distal* side of the block. Be sure that on both sides, the drawings are oriented so that the facial surface of the tooth is toward the side of the block you have marked F (facial). (It is easy to make a mistake here.) These drawings of the crown may appear slightly fat due to the extra 0.5 mm width allowance confining the crown size faciolingually.

**Step 10:** **Carve** away the shaded portions of wax in Figure 13-7B from the facial, lingual, and incisal sides of the block so that it is now shaped like

Figure 13-7C. At this time, do not carve around the outline of the tooth, but rather carve up to the straight vertical lines that form the box in which the tooth picture is drawn.

**Step 11:** Check the distance between the two opposite carved surfaces carefully with your Boley gauge. Be sure they are perfectly flat and smooth. Be sure the thickness of the column of wax between these parallel surfaces exactly equals the given faciolingual crown dimension plus 0.5 mm.

**Step 12:** Now **carve** away the shaded regions seen in Figure 13-7C around and down to the facial and lingual outlines of the tooth. Follow the drawing carefully, making the tooth shape the same all the way through the block. Keep the carving surface smooth; if it becomes chopped up, it will be impossible to smooth it without losing both the shape and the size of the carving.

**Step 13:** With a sharp pencil, very lightly **draw** center lines on the curved facial and lingual sides of the carving as in Figure 13-7D. Be sure they are exactly opposite.

**Step 14:** Add 0.5 mm to the mesiodistal crown measurement and **draw** two lines one half this distance on either side of the center line. This makes a box on the curved surface as wide as the greatest mesiodistal crown measurement plus 0.5 mm (Fig. 13-7D).


**Step 15:** **Redraw** a horizontal line the exact crown length distance from the incisal edge on the facial and lingual sides (since the original line was carved away). Then **draw** the *facial* outline of the crown and half of the root on the curved facial side of the block (Fig. 13-7D).

**Step 16:** On the *lingual* surface of the block, **draw** an outline the same shape as the one on the facial surface except, of course, that it is a mirror image; the distal side of the tooth must be toward the same side of the block in each case. Check the crown length on the lingual surface too, so the crown will not be too long.

**Step 17:** **Carve** away all the wax outside the drawing box, removing all the shaded portions as shown in Figure 13-7E. On some first molars, their spreading roots may extend beyond the box lines, and these roots should be carved accordingly. Check your measurements again.

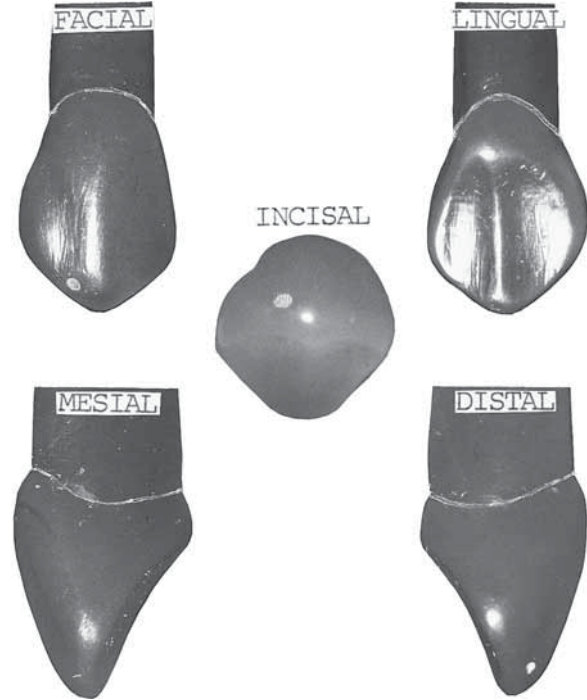
**Step 18:** Shape the tooth by carefully **carving** the mesial and distal contours by removing the shaded portions of Figure 13-7F so that it resembles your tooth specimen outline from the facial and lingual sides.

**Step 19:** Now it is time to round off the corners, narrow the lingual surface, shape the cingulum (it is distal to the center line, and the mesial marginal ridge is

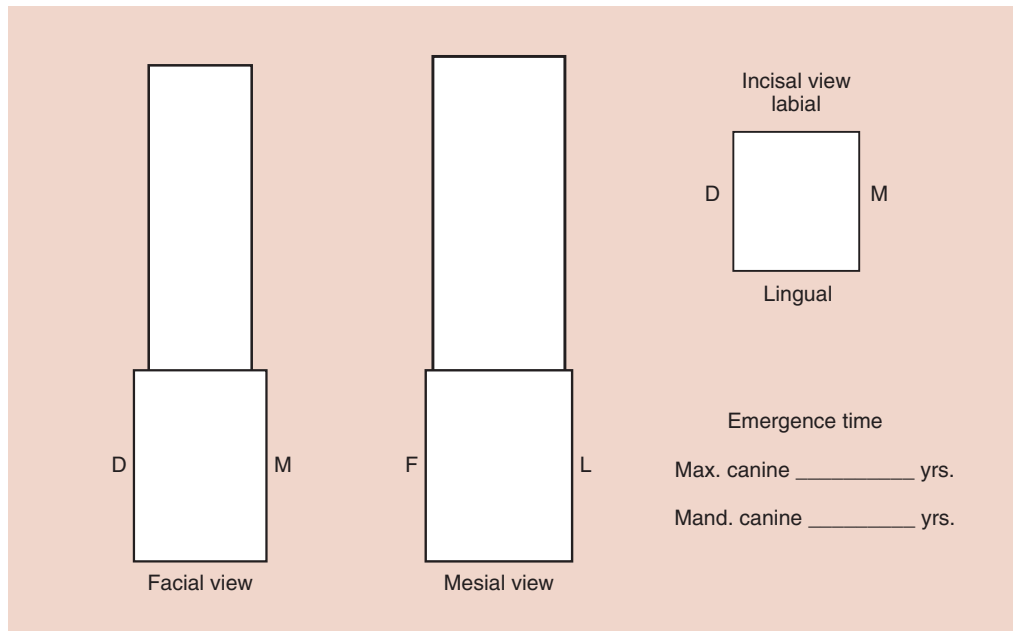


**FIGURE 13-8.** Maxillary canine wax carvings viewed from the distal (D), lingual (L), incisal (I), and facial (F) aspects. First-year dental hygiene students carved these during a skill test (2 hours, 50 minutes time limit).

longer than the distal), and carve out the lingual fossa. Be sure to look at all aspects of the tooth as you are finishing the carving. Include, of course, the incisal view (seen in Fig. 13-6), or the occlusal view. Four nice carvings of maxillary canines, made by dental hygiene students at The Ohio State University, are shown in *Figure 13-8*. Five aspects of another very fine carving by a dental student are seen in *Figure 13-9*.



**FIGURE 13-9.** Maxillary right canine carving done by senior dental student Keith Schmidt: observe the nearly perfect contours from all aspects and that the root is not becoming narrower as it joins the crown (a very common carving error in attempting to refine the cervical line).



**FIGURE 13-10.** Outlines within which you may draw three views of a maxillary canine: the boxes are proportional to the natural tooth average measurements in Table 3-2. The widest portions of the crown (mesial and distal contacts) should touch the sides of the wider lower box. Only the widest part of the root should touch the sides of the narrower box above with the root apex touching the top of this box. On the incisal view, be sure to position the incisal ridge just labial to the faciolingual middle of this box. Drawing these three views will be helpful to you when you outline similar contours on a block of wax for carving a maxillary canine.

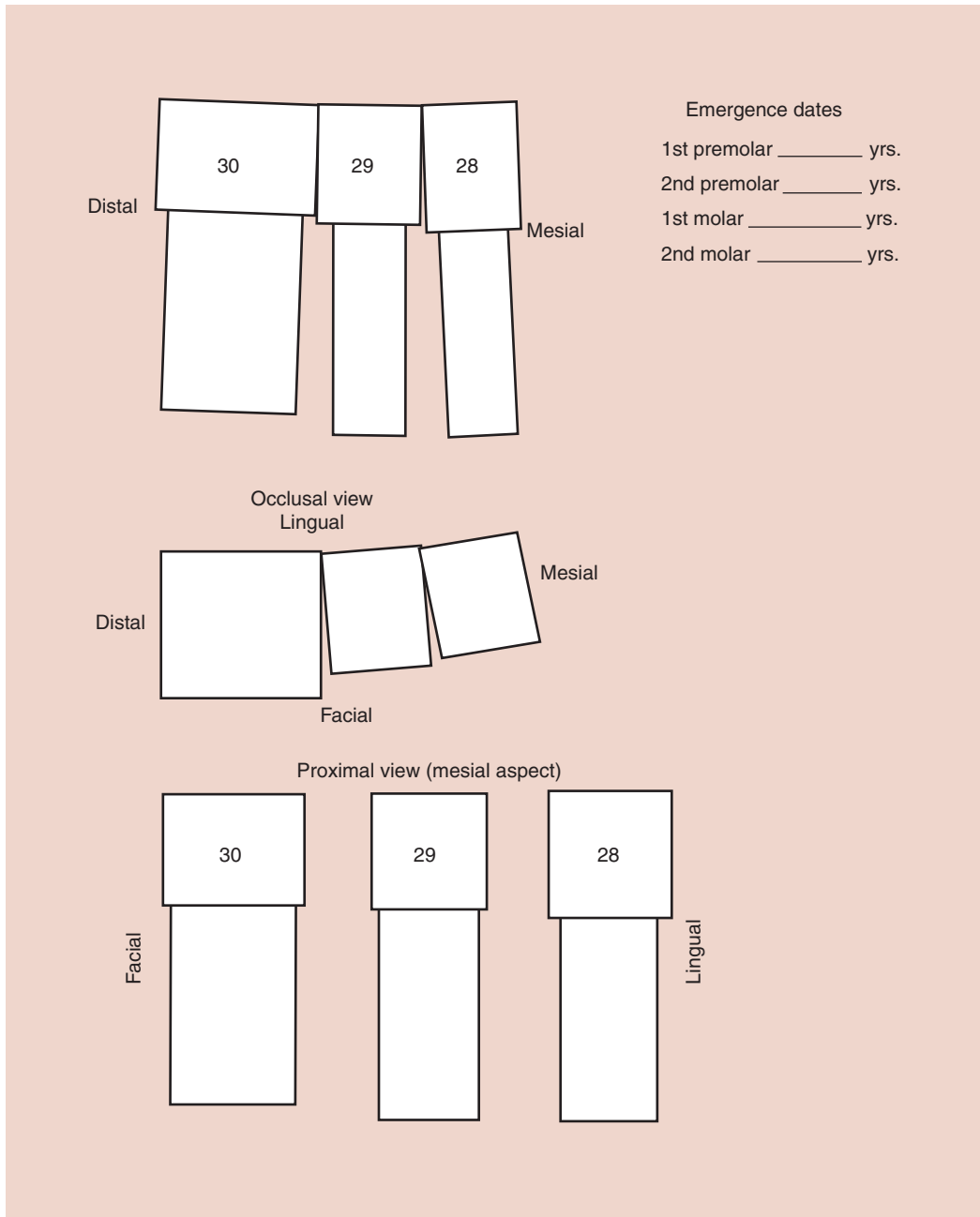
Step 20: Carve your initials on the bottom of the base of the block. Be an honest critic of your work, constantly looking for regions where the carving could be improved.

You can work toward becoming proficient in drawing teeth by sketching outlines (lightly at first) in the blank boxes that are proportionally the correct size for the view and tooth listed in *Figures 13-10 to 13-11*. You should have a tooth model or extracted tooth specimen

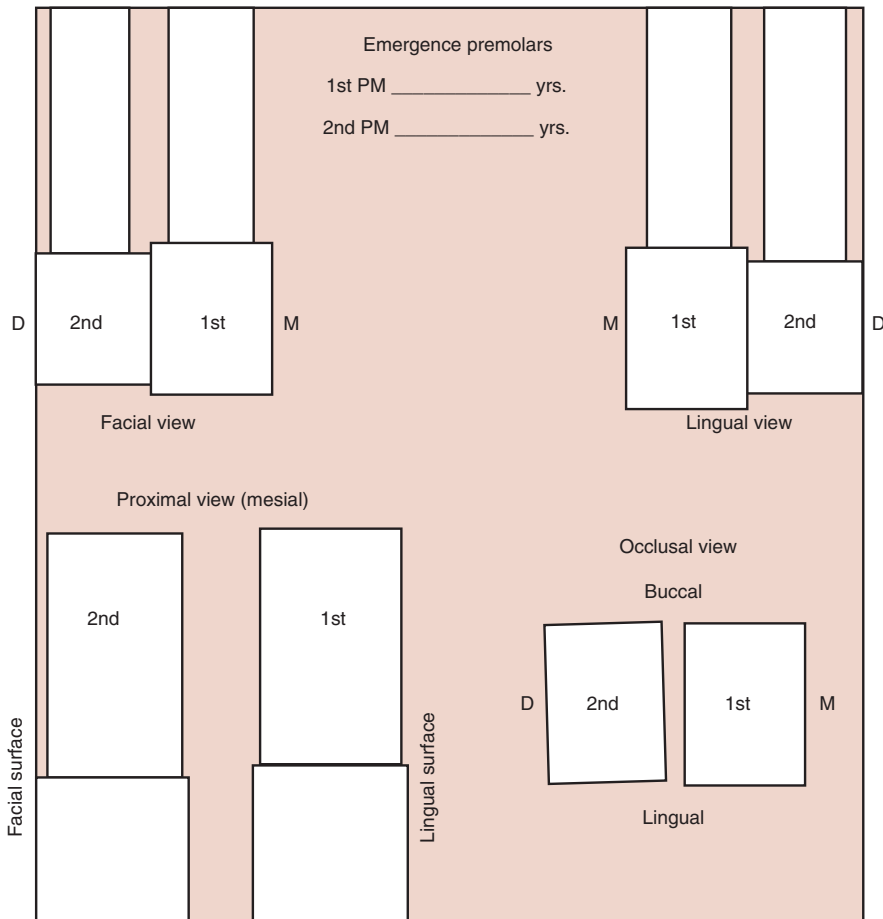
to view as you make these sketches. An example of how to sketch teeth into the blank boxes of *Figure 13-12* is shown in *Figure 13-13*.

#### D. ADVICE

Practice makes perfect, or at least you will see pronounced improvement in your later carvings. Therefore, do not discard your first ones, but keep them for future comparisons. The most difficult task is to begin for

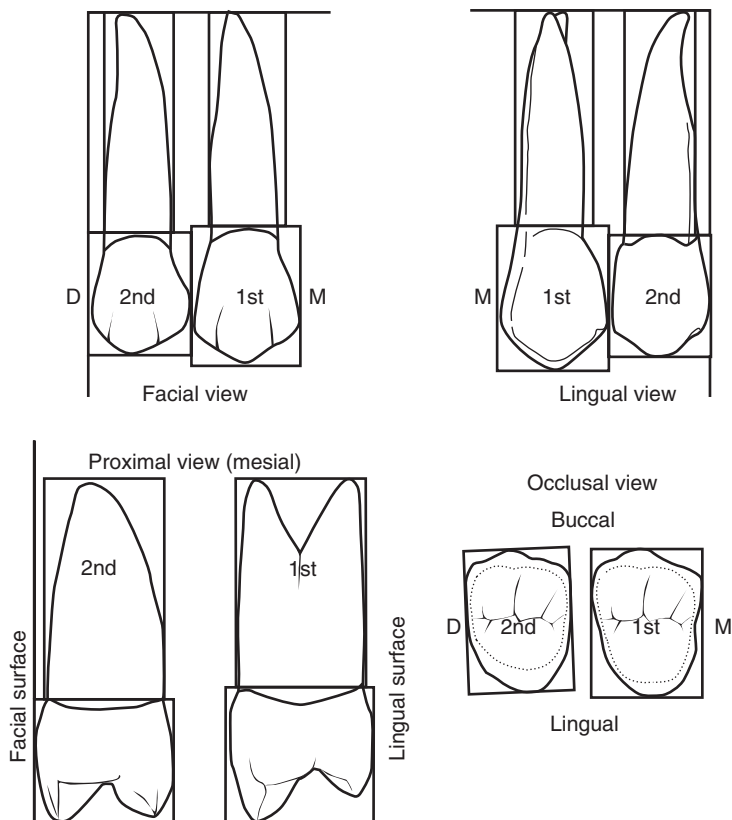


**FIGURE 13-11.** Proportionally outlined boxes for drawing the lower right first and second premolars and first molar in their usual relationship to one another: select three nice tooth specimens or tooth models and go to work.



**FIGURE 13-12.** Outlined proportional boxes for drawing several views of the maxillary first and second premolars in their usual relationship to each other: Use the same guidelines given in the legend for Figure 13-10. A dental hygiene student's drawing of these two teeth within the outlined boxes is seen in Figure 13-13.

Maxillary premolars



**FIGURE 13-13.** These drawings within the outlined boxes are examples to help you with your drawings in the blank boxes in Figure 13-12. Study these and perhaps you can make even better drawings. For example, in the lingual view, the maxillary first premolar's lingual cusp is too long. It is the correct length in the drawing of the mesial aspect.




the very first time. We have found from many years of experience, however, that the inexperienced people who follow these or similar directions and proceed step by step often end up with some of the best carvings in the class. Do not be afraid to begin. When you become skillful at carving teeth, it may surprise you that it is possible to carve the contours of a tooth from memory, possibly aided only by several important dimensions. Average measurements from 4572 extracted teeth are given in Table 1-7. Should you draw or carve a tooth to these average dimensions, it might surprise you how normal it looks. You may find the General References helpful in perfecting your carving techniques.

#### GENERAL REFERENCES

- Ash MM Jr. Wheeler's atlas of tooth form. Philadelphia, PA: W.B. Saunders, 1984.
- Beaudreau DE. Tooth form and contour. *J Am Soc Prev Dent* 1973;3:36-37.
- Burch JG. Coronal tooth contours: didactic, clinical and laboratory. 3rd ed. Worthington, OH: James G. Burch, 1980.
- Grundler H. The study of tooth shapes: a systematic procedure. Berlin: Buch-und Zeitschriften-Verlag "Die Quintessenz," 1976.
- Linek HA. Tooth carving manual. Pasadena, CA: Wood and Jones, Printers, 1948.

PART



# ANATOMIC STRUCTURES OF THE ORAL CAVITY



# Structures that Form the Foundation for Tooth Function

Topics covered within the seven sections of this chapter include the following:

- I. Bones of the human skull (with emphasis on the sphenoid, temporal, maxillae, and mandible bones)
  - A. Bones that cover the superior portion of the brain case
  - B. Bones that form the floor of the brain case
  - C. Large bones of the face and temporomandibular joint (TMJ)
  - D. Small bones of the face
  - E. Hyoid bone
- II. The temporomandibular joint (TMJ)
  - A. Anatomy of the temporomandibular joint
  - B. Ligaments that support the joint and limit joint movement
  - C. Development of the temporomandibular joint
  - D. Advanced topics: Dimensions related to the TMJ
- III. Muscles of the mouth
  - A. Muscles involved in mastication (chewing)
  - B. Other muscles affecting mandibular movement
- C. Other factors affecting tooth position or movement
- D. Summary of muscles that move and control the mandible
- IV. Nerves of the oral cavity (with emphasis on cranial nerves (CN) V, VII, IX, and XII)
  - A. Trigeminal nerve (fifth CN)
  - B. Facial nerve (seventh CN)
  - C. Glossopharyngeal nerve (ninth CN)
  - D. Hypoglossal nerve (12th CN)
  - E. Summary of nerve supply to the tongue, salivary glands, facial skin, and facial muscles
- V. Vessels associated with the oral cavity (arteries, veins, and lymph vessels)
  - A. Arteries
  - B. Veins
  - C. Lymph vessels
- VI. Structures visible on a panoramic radiograph

**T**his chapter introduces the reader to the structures that form the foundation for the functions of the oral cavity. Emphasis is placed on structures that relate to the functioning of the jaws and teeth. The chapter begins with the gross anatomy of the *bones* of the skull including the identification of important foramen where nerves and blood vessels pass from the brain to the oral

structures of the mouth, the location for attachments of the muscles and tendons that support and move the mandible, and the anatomy of the temporomandibular joint (TMJ). Next, the attachments and functions of the major chewing muscles are described, followed by a description of the passageway and function of the nerves, blood supply, and lymph vessels that supply the face and mouth.

## SECTION I

### BONES OF THE HUMAN SKULL (WITH EMPHASIS ON THE SPHENOID, TEMPORAL, MAXILLAE, AND MANDIBLE BONES)

#### OBJECTIVES OF THIS SECTION

This section is designed to prepare the learner to perform the following:

- Describe and identify each bone seen on an intact human skull.
- Describe and identify each bony structure highlighted in bold in this chapter. (Emphasis is placed on structures of the mandible, maxillae, temporal, and sphenoid bones.)
- Describe and identify *the location* of the attachment of chewing muscles and ligaments that are attached to the mandible.
- Describe and identify *the foramen* of the nerves and arteries that supply the teeth and oral cavity.



There are 206 distinct bones in our skeleton, 28 of which are in the skull if we count the malleus, stapes, and incus bones of each ear. To obtain a clear understanding of the bones of the skull and their relationship to one another and to the teeth, it is best to have a skull or skull model at hand to examine while reading this chapter. If you touch and trace each bone with your fingers as you read, you are not apt to forget its characteristics. Also, as you study this section, you should relate the location of each *bony* structure on the skull to its location on your own head, that is, where it is located under the skin of the face or under the mucosa of the mouth. This is important in order to fully appreciate where muscles attach and how they can move the lower jaw (mandible) in all directions, and to figure out where to apply local anesthetic along the path of the nerves to the teeth and oral cavity, as described in more detail in Chapter 15.

When reading the description of each bone, there are many descriptive terms that are used to describe the bumps, depressions, holes and relative location of important landmarks. Many terms have similar definitions, so they are defined here in groups to facilitate learning. Since anatomy terms are often similar to common familiar words, the new terms are compared to familiar words whenever possible.

#### BUMPS—TERMS USED TO DESCRIBE CONVEXITIES ON BONES AND/OR TEETH

- Crest:** a projecting ridge along a bone
- Eminence:** a prominence or elevation of bone
- Process:** a projection or outgrowth from a bone
- Protuberance** [pro TU ber ahns]: a prominence or swelling (of bone)
- Ridge:** linear, narrow, elevated portion of bone or tooth
- Tubercle** [TOO ber k'l]: a small rounded projection on a bone or tooth

#### DEPRESSIONS—TERMS USED TO DESCRIBE CONCAVITIES IN BONES AND/OR TEETH

- Alveolus** [al VEE o lus] (plural: alveoli [al VEE o lie]): small hollow space or socket where the tooth root fits within the jaw bones
- Cavity:** a hollow place within the body of bone (or within a tooth)
- Fissure** [FISH er]: a cleft or groove (crack) between parts
- Fossa** [FOS ah] (plural: fossae [FOS ee]): a small hollow or depressed area
- Fovea** [FO ve ah]: small pit or depression
- Groove:** linear depression or furrow
- Sinus:** hollow, air-filled cavity or space within skull bones, or a channel for venous blood

#### OPENINGS—TERMS USED TO DESCRIBE HOLES IN BONES AND/OR TEETH

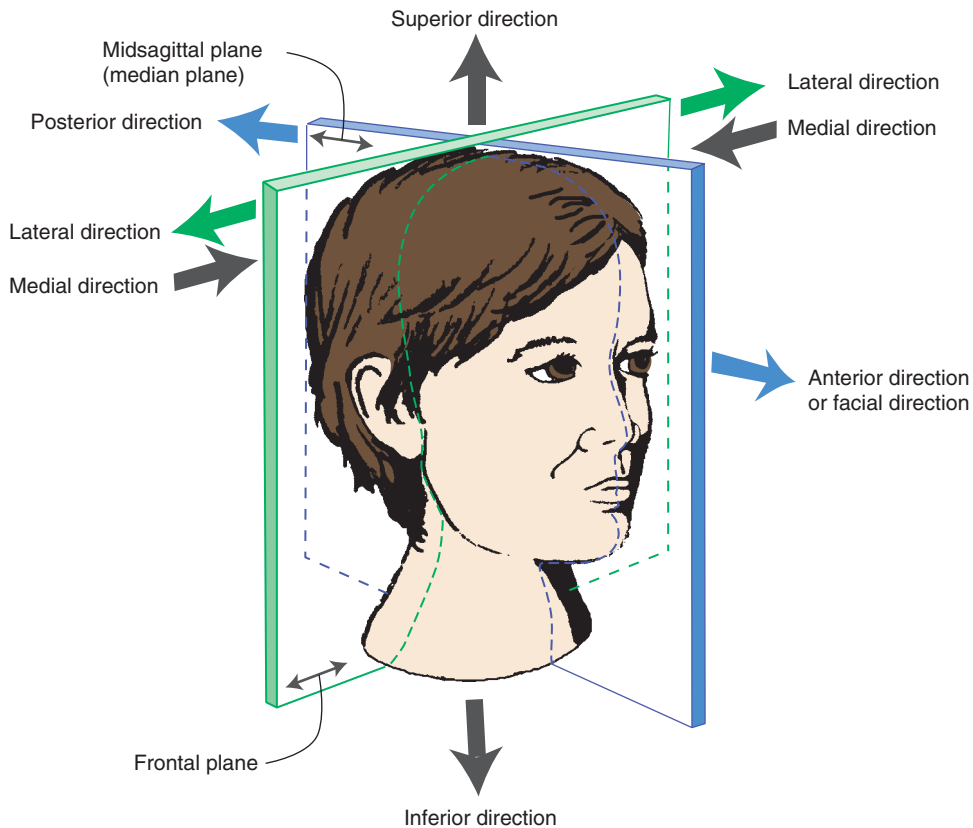
- Aperture:** an opening; compare a *camera lens aperture*
- Foramen** [fo RAY men] (plural: foramina [fo RAM i nah]): a small hole through bone or tooth for passage of nerves and vessels
- Foramen ovale** [o VAL ee]: a specific oval or egg-shaped foramen
- Foramen rotundum:** a specific round foramen; recall the *Capitol's rotundum or dome* is round when viewed from above
- Meatus** [me A tus]: a natural passage or opening in the body

#### TERMS USED TO DESCRIBE RELATIVE LOCATION—*Figure 14-1* will be helpful in understanding terms with an asterisk (\*).

- Anterior\*:** toward the front of the body
- Buccal** [BUCK al]: related to or near the cheek; the buccal nerve innervates the cheek; the buccinator muscle is within the cheek; the buccal surface of a tooth is the side toward the cheek
- Cervix:** of the neck or neck-like; compare a *cervical vertebrae* in the neck
- External:** toward the outside of the body; seen from the outside
- Facial\*:** toward the face; seen when viewing the face side
- Inferior\* or the prefix infra:** located below or beneath; lower than
- Lateral\*:** pertaining to, or situated at, the side
- Medial\*:** the surface toward, or closest to, the midline (median) plane of the body; do not confuse medial with mesial
- Median plane\*:** a longitudinal plane that divides the body into relatively equal right and left halves
- Midsagittal plane\* [mid SAJ i t'l]:** same as median plane
- Posterior\*:** toward the rear of the mouth or body
- Retro (prefix):** back or behind
- Sub (prefix):** under or beneath; compare to *infra*
- Superficial:** closer to the surface
- Superior\* or the prefix supra:** located above or over; higher or upper

#### GENERAL TERMS RELATED TO BONES

- Acoustic** [ah KOOS tik]: referring to sounds or hearing; near the ear
- Cervical** [SER vi kal]: related to the neck; like *cervical vertebrae*
- Condyle** [KON dile]: an articular prominence of a bone resembling a knuckle



**FIGURE 14-1.** Planes of the head and directions used to identify relative location of structures or surfaces of the head.

**Coronoid:** where the *king's coronation crown* fits or the shape of a crown (compare coronation); for example, the coronoid process of the mandible is shaped like the point of a coronation crown; or a coronoid suture is where the crown fits

**Dura:** hard, not soft

**Glenoid** [GLE noyd]: socket-like

**Glosso:** a prefix referring to the tongue

**Labial** [LAY bee al]: related to the lips; toward the lips

**Lacrima** [LAK ri mal] (also spelled lachrymal): referring to the tears (compare *lacrimosa*)

**Lamina:** a thin layer (compare *laminated wood*)

**Lingula** [LING gyoo la]: tongue-shaped structure (compare to the word “lingual”)

**Malar** [MAY lar]: referring to the cheek or cheek bone (not to be confused with molar)

**Meatus** [mee A tus]: a pathway or opening

**Palpebral** [PAL pe bral]: referring to the eyelid

**Piriform** [PEER i form]: pear shaped

**Septum:** a partition (compare separate)

**Suture** [SOO chur] line: the line of union of adjoining bones of the skull

**Symphysis** [SIM fi sis]: fibrocartilaginous joint or connection where opposed bony surfaces are joined (a suture line may not be evident)

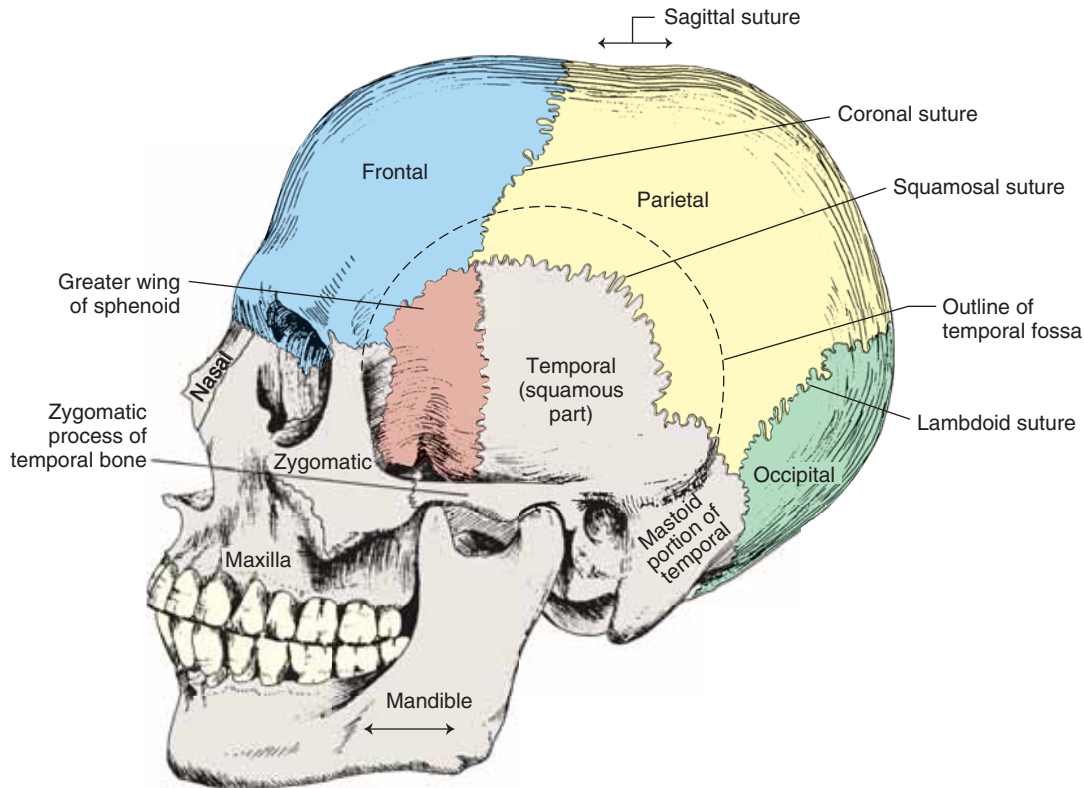
**Trochlea** [TROK lee ah]: pulley shaped

The skull bones can be divided into two broad categories: the bones of the **neurocranium** [NOOR o CRAY ne um] surrounding the brain, and the facial bones that make up the face and mouth and are involved in respiration and eating. The **neurocranium** is the portion of the skull that supports, encloses, and protects the brain. The eight bones of the neurocranium are four single bones (sphenoid, occipital, ethmoid, and frontal) and two paired bones (one on each side): temporal and parietal.

### A. BONES THAT COVER THE SUPERIOR PORTION OF THE BRAIN CASE

Study *Figure 14-2* while reading about the frontal and temporal bones. The **frontal bone** is a single, large midline bone that forms the “forehead” and eyebrow region. Two **parietal bones** are large, paired bones that protect the brain superiorly, laterally, and posteriorly. A small portion of these bones make up a part of the **temporal fossa** region (outlined in *Fig. 14-2*), which serves as part of the attachment for the superior end of one of the major muscles of chewing called the *temporalis muscle*.

**Suture lines** are lines of fibrous connective tissue that join two bones of the skull immovably together as seen in *Figure 14-2*. The **coronal suture** is located



**FIGURE 14-2.** Human skull, left side: The following large bones of the neurocranium: the single **frontal bone** (*blue*) forms the anterior superior portion, the **parietal bones** (*yellow*) form the lateral and superior surfaces, and the **occipital bone** (*light green*) forms the posterior inferior portion and the greater wing of the sphenoid bone (*light red*). Note the outline of the shallow **temporal fossa**, which includes portions of temporal, parietal, sphenoid, and frontal bones.

between the frontal and two parietal bones. (Hint: This location is where a crown might fit during the coronation of a royal person.) The **sagittal suture** (best seen on the superior surface of the skull) joins the right and left parietal bones along the midline of the skull along the midsagittal plane of the skull.

## B. BONES THAT FORM THE FLOOR OF THE BRAIN CASE

The occipital bone, sphenoid bone, ethmoid bone, and two temporal bones support the base of the brain. They all have holes (foramen) for the passage of nerves to the face and mouth. However, the temporal bones play a most important part in the functioning of the jaw, so they will be discussed separately when discussing the TMJ.

### 1. OCCIPITAL BONE

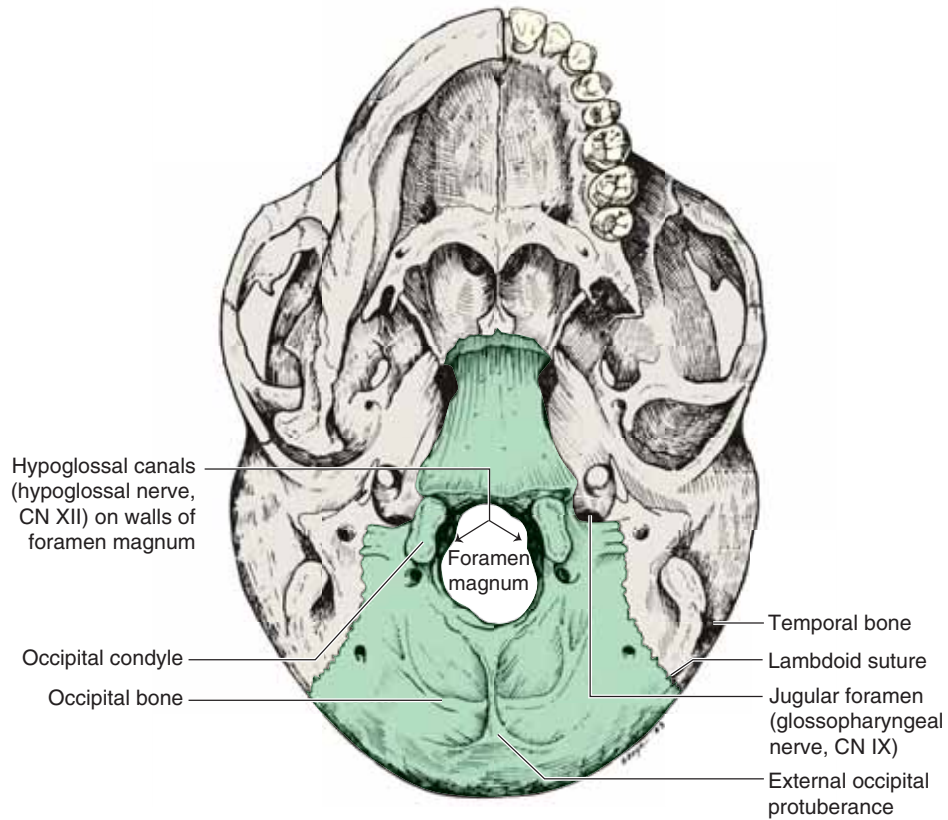
The **occipital bone** provides the articulating surface between the skull and vertebral column at the **occipital condyles** [ahk SIP eh tal KON diles] (seen on the inferior surface in *Fig. 14-3*). The large **foramen magnum** serves as the passageway for the spinal cord that

connects the peripheral nervous system with the brain. The **hypoglossal canals** are located on the right and left lateral walls of the foramen magnum. These canals are the passageways of the **hypoglossal nerves** (CN XII). Lateral to the foramen magnum (between the occipital and temporal bones) are the large **jugular** [JUG you lar] **foramen** (*Fig. 14-3*), the passageway of blood draining from the brain to the internal **jugular vein**, and the passageway of the **glossopharyngeal nerve** (CN IX).

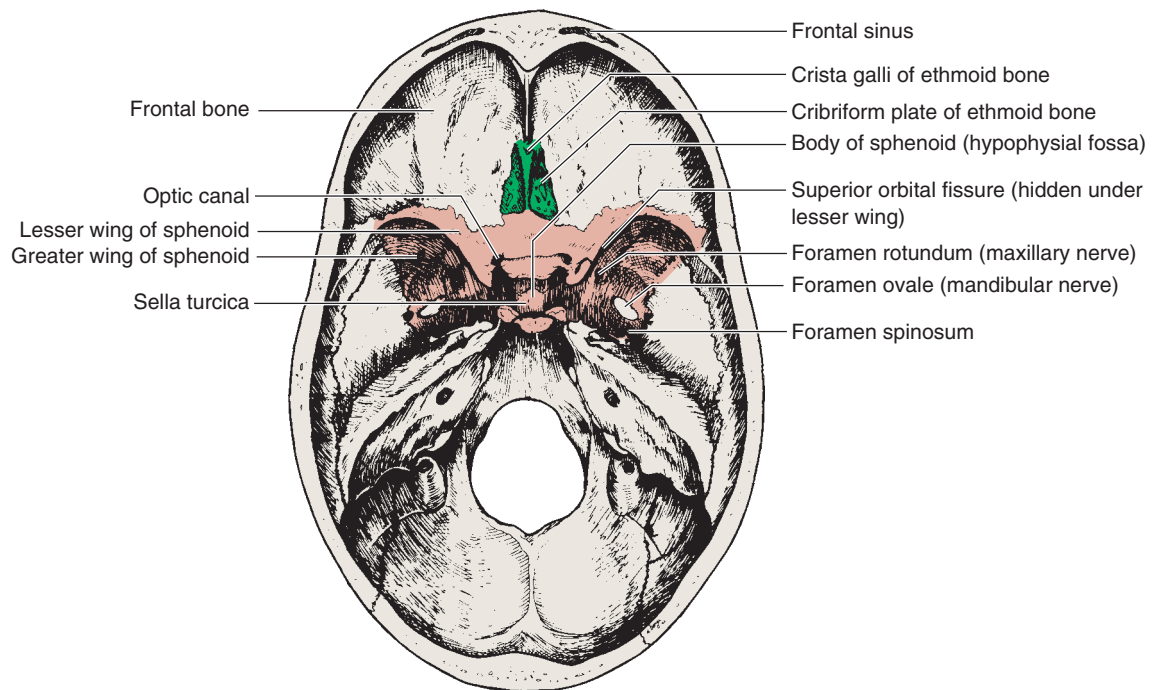
The **lambdoid** [LAM doid] **suture** joins the occipital bone with the parietal bones (*Fig. 14-2*). Its shape from the posterior view resembles an upside-down “V” and can be compared to the shape of the Greek letter lambda ( $\lambda$ ).

### 2. ETHMOID BONE

The **ethmoid bone** is a single, hollow, sinus-filled bone that is located on the midline inferior to the anterior part of the brain. The superior aspect of this bone is visible within the brain case as the sieve-like **cribriform** [KRIB ri form] **plate** (*Fig. 14-4*) surrounding the triangular projection called the **crista galli** [KRIS ta GAL li, meaning rooster comb]. The cribriform plate is full



**FIGURE 14-3.** Human skull: inferior surface with half of the mandible removed on the right side of the drawing. The **occipital bone** is highlighted *light green*. Note the location of the hypoglossal canals (in the lateral walls of the foramen magnum) and the jugular foramen just adjacent to the occipital bone.



**FIGURE 14-4.** Human skull: bones lining the inside of the neurocranium, superior view. The **sphenoid bone** is shaded *light red* in this figure. Also, notice the portion of the midline **ethmoid bone** (*green*) that is visible in the anterior braincase.

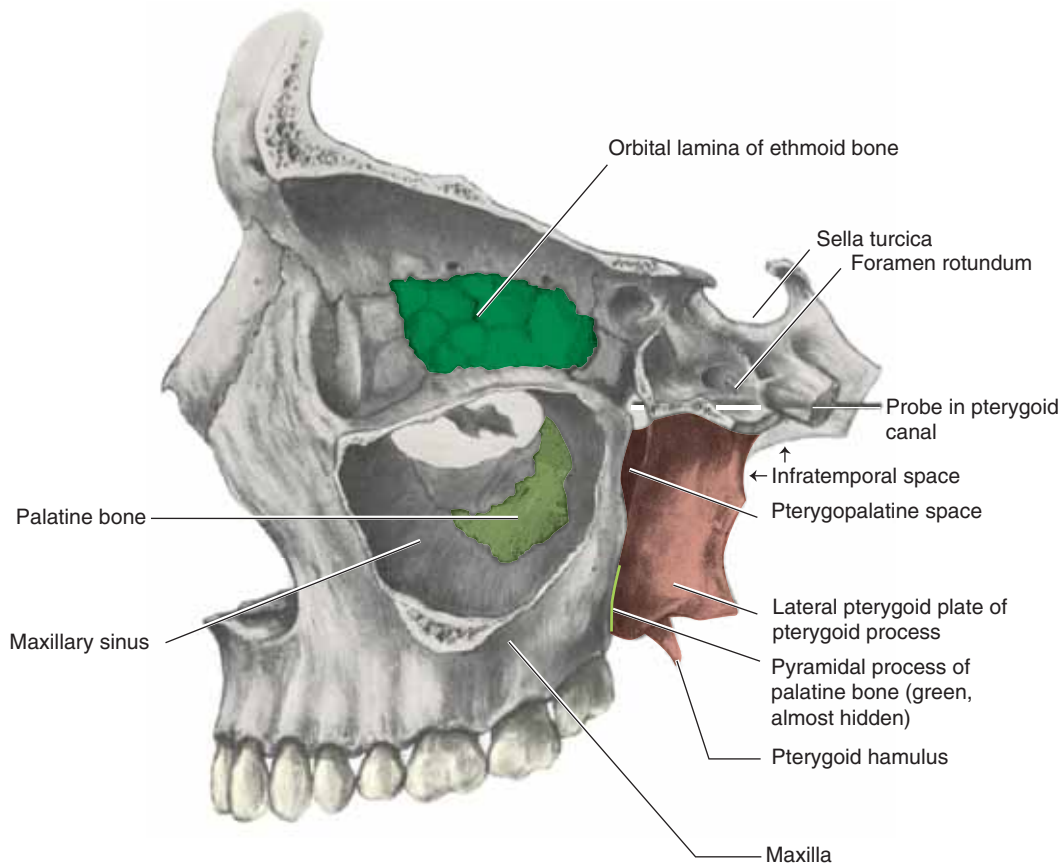


of holes providing the passage from the brain into the nasal cavity for the fibers of CN I, the *olfactory nerve* (the nerve for smell).

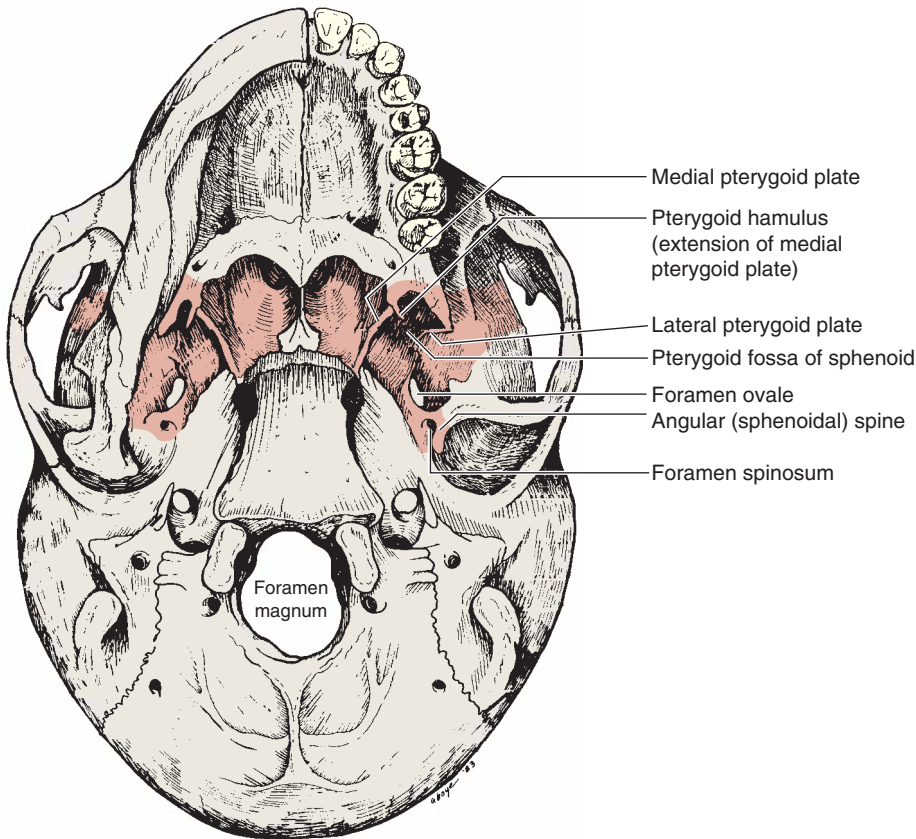
Inferior to the cribriform plate, the hollow ethmoid bone balloons out to form part of the medial aspect of each eye orbit (the orbital lamina of the ethmoid bone is visible in Fig. 14-5 and later in Fig. 14-7). It also has scrolled processes extending into the nasal cavity similar in appearance to the inferior nasal concha described later in this section. Finally, a vertical midline plate of the ethmoid bone extends downward into the nasal cavity (along with the separate single *vomer bone*) to form the **nasal septum** (seen later in Fig. 14-7), which separates the right and left nasal cavities. The scrolled portions and midline plate of the ethmoid bone are visible through the piriform opening (anterior opening of the nasal passageways).

### 3. SPHENOID BONE

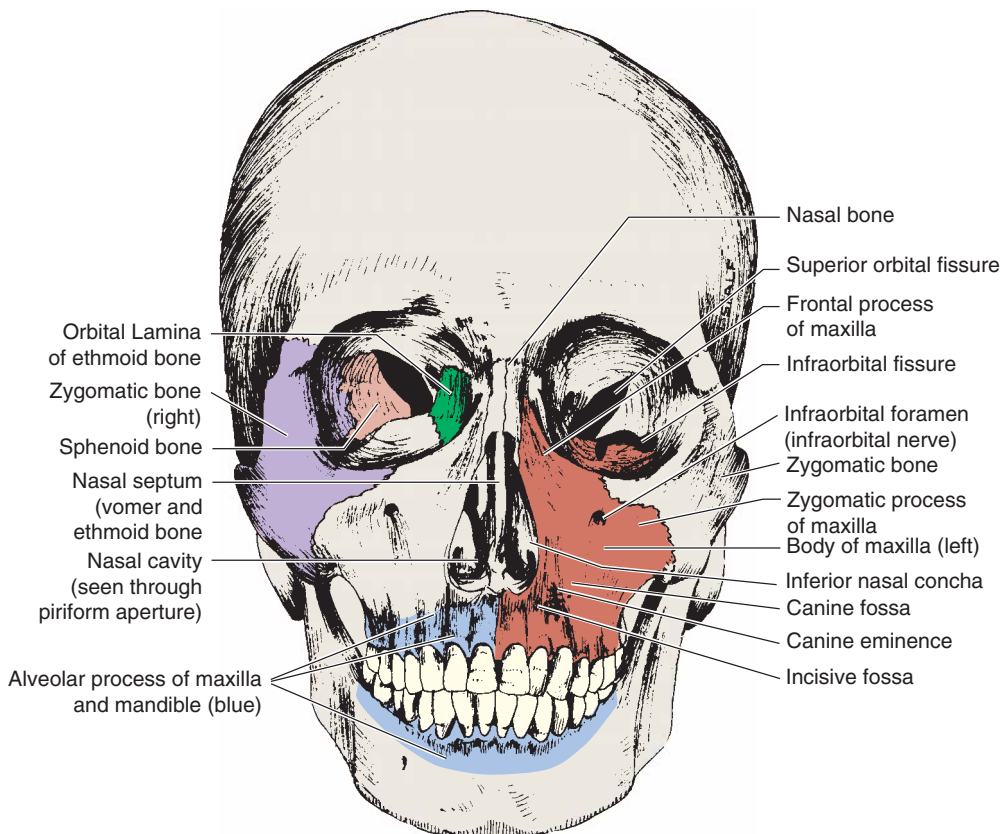
The **sphenoid** [SFE noid] **bone** is a single, irregularly shaped, midline bone that cradles the base of the brain (and forms the posterior part of the orbit or eye socket as seen later in Fig. 14-7). The complex shape of the sphenoid bone can only be appreciated by looking at it from several different views (seen from above in Fig. 14-4, from below in Fig. 14-6, and seen later in the lateral surface of the orbit in Fig. 14-7). The sphenoid bone is important to dental professionals because it has processes that serve as part of the attachment for three of the four pairs of major chewing muscles. The sphenoid bone also has foramina (holes) that are the passageway for branches of the important fifth CN (trigeminal nerve) that supply all teeth and surrounding structures.



**FIGURE 14-5.** Part of human skull, lateral view, with the lateral wall of the left maxilla removed, exposing the large **maxillary sinus**: Note the lateral surface of the **lateral pterygoid plate** of the sphenoid bone (shaded *light red*) just behind the maxilla. The **pterygoid hamulus** of the medial pterygoid plate is also visible and is just posterior (and slightly medial) to the third molars. Also, note the part of the midline **ethmoid bone** (*green*) that balloons out between the right and left eye orbits to form part of their medial walls, and the part of the palatine bone (*light green*) that extends superiorly from the palate to form part of the maxillary sinus (and part of the pterygopalatine space). (Reproduced from Clemente CD, ed. *Gray's anatomy of the human body*. 30th ed. Philadelphia, PA: Lea & Febiger, 1985:166, with permission.)



**FIGURE 14-6.** Human skull: inferior surface with half of the mandible removed on the right side of the drawing to permit easier viewing of the **sphenoid bone**, which is shaded *light red*. Notice the relative location of the medial and lateral **pterygoid plates and fossae** just posterior to the bones of the hard palate.



**FIGURE 14-7.** Human skull, frontal aspect: The left maxilla is shaded *red* (on the right side of the drawing), and the right **zygomatic bone** is shaded *purple* (on the left side of the drawing). Also, the facial surface of the arch-shaped **alveolar process of the left maxilla** (process that surrounds the tooth roots) and the **alveolar process of the entire mandible** are shaded *blue*. Also forming part of the right eye orbit, the orbital lamina of the **ethmoid bone** is shaded *green* on the medial surface, and part of the **sphenoid bone** is shaded *light red* in the right eye orbit (left side of drawing).

The midline *body* of the sphenoid bone has a depression on the superior surface called the **hypophysial fossa** or **sella turcica** [SELL a TER si ka] (meaning Turkish chair or saddle) that cradles the pituitary gland (Fig. 14-4). This gland secretes hormones which regulate many body functions. There are two pairs of processes or wings (greater and lesser wings) that project off of the body laterally and superiorly. The **greater wings** are visible internally in Figure 14-4 but are best viewed externally in Figure 14-2. If you put your thumb on the external surface of the greater wing, you can place your forefinger opposite to your thumb on the inner surface to confirm the location of the greater wing on the inner surface of the braincase. These wings extend superiorly from the body, posterior to the upper jawbones (maxillae), and medial to the lower jawbone and cheekbones. The external surface of the greater wing (along with part of the temporal, frontal, and parietal bones) forms part of each **temporal fossa** (outlined in Fig. 14-2) where a muscle of mastication, the *temporalis* muscle, attaches to the neurocranium. The **lesser wings** are located superior to a fissure in the posterior surface of the eye socket (seen internally in Fig. 14-4 and externally on the posterior surface of the eye sockets seen in Fig. 14-7). The fissure between the greater wing and the lesser wing is called the **superior orbital fissure**, which is the passageway of the *ophthalmic nerve* (one part of the trigeminal nerve). Look at this fissure on the inside of the braincase, and then look at the front of the skull to see this fissure on the posterior superior surface of the eye socket.

The sphenoid bone also has two important processes that project *inferiorly* from the base of the skull adjacent to the posterior surface of the upper jawbones (maxillae). These are called **pterygoid** [TER i goid] **processes** and are best seen in the lateral view of Figure 14-5. (Hint: To remember the name of this process, note that each has a scalloped border somewhat resembling the wings of a pterodactyl flying dinosaur.) When each pterygoid process is viewed from below (or posteriorly), you can see that it is made up of two thin plates of bone (a **lateral pterygoid plate** or lamina, and a **medial pterygoid plate** or lamina) that surround a concavity about the size of your little finger called the **pterygoid fossa** (Fig. 14-6). This fossa is where one end of another major muscle of mastication, the *medial pterygoid muscle*, attaches. The lateral surface of the lateral pterygoid plate (visible in Fig. 14-5) is where one end of yet another muscle of mastication (the *lateral pterygoid muscle*) attaches. The medial plate has a hook-like projection just posterior and medial to the third molars and behind the palate, called the **pterygoid hamulus** (Figs. 14-5 and 14-6). The space just lateral to and

posterior to the lateral plate and inferior to the temporal bone is called the **infratemporal space** (Fig. 14-5), and it is filled with muscles, ligaments, vessels, and nerves, which will be described later. Note that all of the terms presented here that contain “ptery” relate to the pterygoid process of the sphenoid bone, and the closest you can come to touching this process on your own head is by placing a clean finger in the mouth and sliding it posterior, superior, and medial to the maxillary third molars. Confirm this by looking at a skull.

Two pairs of foramina in the sphenoid bone are important to dental professionals: the foramen rotundum and the foramen ovale. The oval, more posterior **foramen ovale** is the passage of the important *mandibular nerve* (part of the trigeminal nerve) that passes from the brain to the mandibular teeth and jaw, and the chewing muscles. The foramen ovale is best seen internally in Figure 14-4 and externally in Figure 14-6. On a skull, if you carefully pass a pipe cleaner through this foramen, you will see that it drops inferiorly through the **infratemporal space** (beneath part of the temporal bone) toward the lower jaw (mandible). The foramen ovale can be easily identified by its proximity to the much smaller **foramen spinosum** [spy NO sum] that is located just posterior to it. Just posterior to the foramen spinosum on the inferior surface is a thorn-shaped bony prominence called the **sphenoidal** [SFE noid al] **spine** (or **angular spine**) (Fig. 14-6). This spine is the superior attachment of the *sphenomandibular ligament*, which extends inferiorly from the spine toward the medial surface of the lower jaw (mandible).

The **foramen rotundum** [ro TUN dum] is visible only internally in Figure 14-4 and is round, anterior, and just slightly medial to the foramen ovale. It is the opening for the passage of another important branch of the trigeminal nerve called the *maxillary nerve* (another part of the trigeminal nerve) that supplies all maxillary teeth. If you are able to carefully pass a pipe cleaner from the brain case through this foramen, it will be somewhat hidden in a space between the pterygoid process and upper jawbone (maxilla). This space between the pterygoid process and the posterior wall of the maxilla (which is covered in part by vertical projections of the palatine bones) is known as the **pterygopalatine** [TER i go PAL eh tine] **space** labeled in Figure 14-5. The maxillary nerve that exits the skull through the foramen rotundum proceeds through this pterygopalatine space as it gives off branches to the upper jaw (maxillae) and teeth.

At this time, look inside the brain case to review the location for the openings of the three branches of the trigeminal nerve on each half of the skull (Fig. 14-4). The trigeminal nerve begins within the braincase as

one cranial nerve but splits to exit the neurocranium in three nerve branches through three openings. The most anterior opening is the superior orbital fissure for the ophthalmic branch. Posterior to it is the foramen rotundum for the maxillary branch, and the more posterior (and slightly lateral) foramen ovale is for the mandibular branch. (Recall that the much smaller foramen spinosum is just posterior to the foramen ovale.)

### C. LARGE BONES OF THE FACE AND TEMPOROMANDIBULAR JOINT (TMJ)

The form of 14 facial bones gives us our appearance. They function in both respiration and digestion. The facial bones are located inferior to the forehead and make up most of the anterior part of the skull. Five large bones of the face are the mandible, two maxillae, and two zygomatic (cheek) bones. The smaller bones of the face are the vomer, two palatine, two nasal, two lacrimal bones, and two inferior nasal conchae [KONG kee] (also called turbinates). The mandible and maxillae are most important when considering the foundation for teeth and tooth function, so they will be discussed in most detail. Although the temporal bones are not considered facial bones, they are being discussed here due to their importance in our understanding of the TMJ.

#### 1. MAXILLAE

One maxilla is shaded red in Figure 14-7. Each **maxilla** [mak SILL a] (right or left) consists of one large, hollow, central mass called the *body*, and four projecting *processes* or extensions of bone. The plural of maxilla is maxillae [mack SILL ee]. The two maxillae contain all of the maxillary teeth.

##### a. Body of the Maxilla (Structures Seen in Fig. 14-7)

The body of the maxilla is shaped like a four-sided, hollow pyramid with the base oriented vertically next to the nasal cavity and the apex or peak extending laterally into part of the cheekbone (or zygomatic bone). The superior portion of the maxilla forms the floor of the orbit of the eye where an **infraorbital fissure** is located. This fissure disappears anteriorly to become the **infraorbital canal** (hidden within the bone in Fig. 14-7). Important branches of the fifth CN and vessels enter this fissure and canal and give off branches within the canal, which supply some of the maxillary teeth and surrounding tissue. The *infraorbital nerves and vessels* exit the infraorbital canal on to the face through the **infraorbital foramen**. This foramen is on the anterior surface of the body of the maxilla, inferior to the

eye orbit and superior to the canine fossa, which is a shallow depression superior and lateral to the canine.

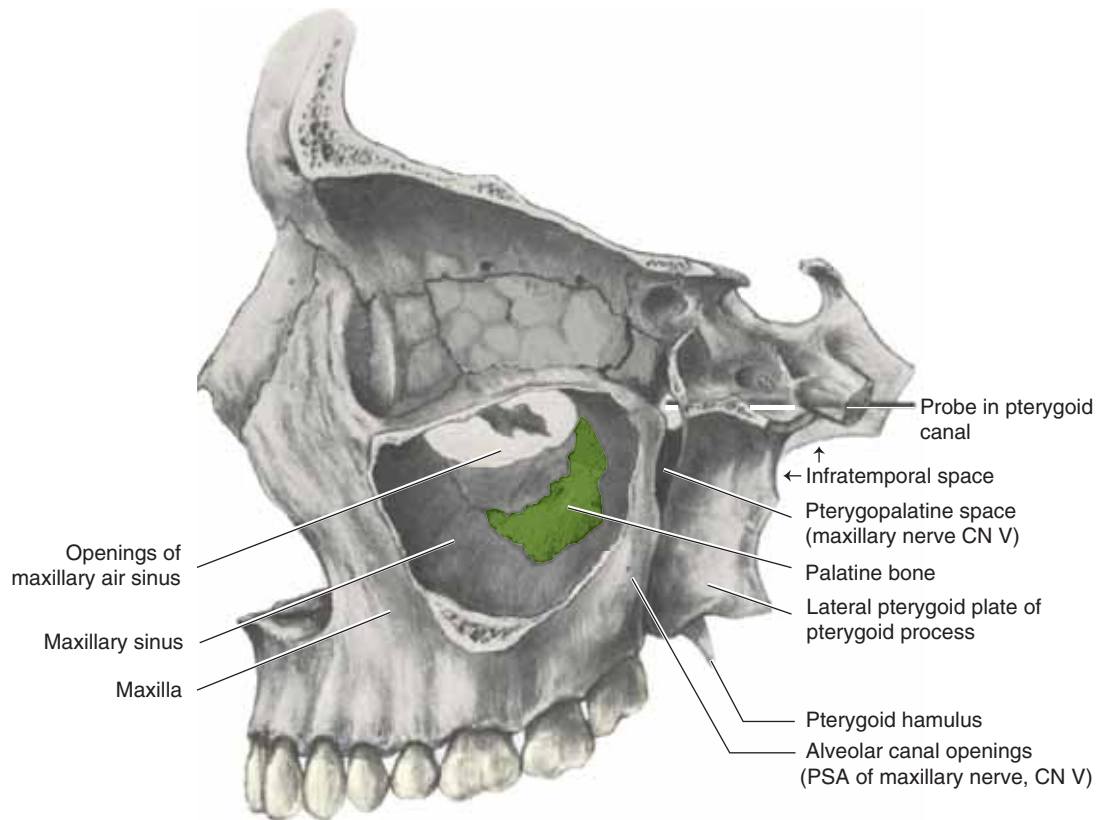
##### b. Maxillary Sinus or Antrum

Sinuses are hollow spaces within bones and are found within the sphenoid, frontal, and ethmoid bones, as well as within each maxilla. The **maxillary sinus**, located within the body of each maxilla, functions to (a) lighten the skull, (b) give resonance to the voice, (c) warm the air we breathe, and (d) moisten the nasal cavity. (The average size of each maxillary sinus in an adult is about 25 mm from side to side, 30 mm from front to back, and 30 mm high, with an average capacity of 15 mL (range: 9.5 to 20 mL)<sup>1</sup> or about 1 tablespoon.)

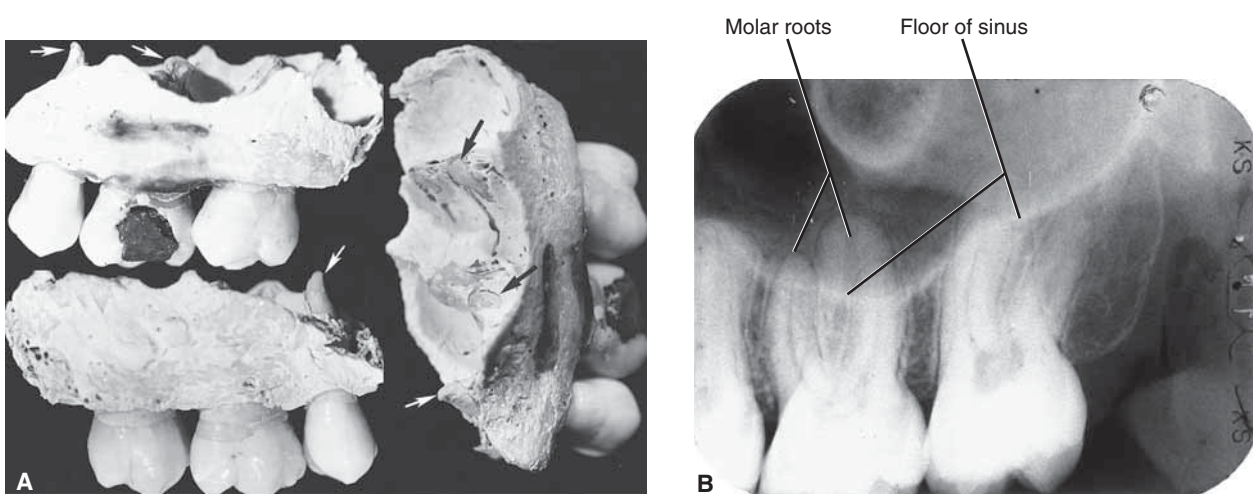
Refer to *Figure 14-8* while reading about the maxillary sinus. This large, four-sided, pyramid-shaped cavity is located within the body of each maxilla. It is important to dental health professionals because of the close relationship it has to the teeth. The sinus cavity floor extends inferiorly onto the superior portion of the maxillary alveolar process where projections of the apices of the molar roots, and sometimes premolar roots, may be found. This intimate relationship between the teeth and maxillary sinus space can be appreciated in *Figure 14-9A* and *B*. Only very thin bone lies between the floor of the sinus and the apices of the roots of the maxillary molars. In rare cases, no bone separates the root apices from the sinus, but there is always soft tissue between the root and the space of the cavity, made up of the periodontal ligament on the tooth root and the mucous membrane lining the sinus cavity. Sometimes when a dentist extracts a molar and the root breaks off, he or she is unjustly accused of pushing the root into the sinus. It may have been located in the maxillary sinus prior to the extraction. The other three walls of the pyramid-shaped sinus are toward the orbit of the eye, toward the face, and posteriorly and laterally, next to the infratemporal space.

The nerves to the maxillary molars (*posterior superior alveolar [PSA] nerves*) enter the maxilla and sinus lining through very small foramina called the **alveolar** [al VEE o lar] **canals** located posterior and superior to the maxillary third molars (Fig. 14-8). These nerves pass just beneath the membrane lining of the sinus or through bony canals within the walls of the sinus. An infection in either the sinus *or* these teeth can spread to the other. Pain caused by a maxillary sinus infection can be mistaken for pain originating in any one or all of the molars or premolars on that side. Unfortunately, healthy teeth are sometimes extracted in a futile attempt to alleviate pain that was caused by a chronic maxillary sinus infection.





**FIGURE 14-8.** Part of human skull, lateral view, with the lateral wall of the left maxilla removed, exposing the large **maxillary sinus**: Note that the floor of this sinus is in proximity to the maxillary posterior teeth but does not extend forward as far as the maxillary anterior teeth. The **opening** of this sinus (into the nasal chamber) is located superiorly on the medial wall of the sinus. A portion of the **palatine bone** on the posterior wall of the sinus (shaded *light green*) is the vertical process of the palatine bone located adjacent to the pterygopalatine space. (Reproduced from Clemente CD, ed. *Gray's anatomy of the human body*. 30th ed. Philadelphia, PA: Lea & Febiger, 1985:166, with permission.)



**FIGURE 14-9.** **A.** Three views of part of the left **alveolar process** of the maxilla surrounding the roots of the maxillary first and second molar and second premolar. Note the root tips (apices) shown by *arrows* extending out of the maxilla into what would have been the floor of the **maxillary sinus** space in an intact skull. **B.** Radiograph of the maxillary molar region showing the roots of the first molar several millimeters deep into the maxillary sinus (dark area surrounded by white border). Parts of the roots of the second molar are also within the sinus cavity. The root tip of the second premolar root is in the sinus as well. This is a common relationship.

The opening from each maxillary sinus to the nasal cavity is located on its anterosuperior wall (Fig. 14-8). The maxillary sinus is lined with specialized cells (ciliated columnar epithelium) similar to those found in the respiratory tract. The lining secretes mucous that moves spirally and upward (against gravity) across the membrane toward the opening of the sinus, which is located on the anterosuperior wall (Fig. 14-8), where secretions can drain into the nasal cavity. If humans walked on all fours with the head forward like many animals, this opening for drainage would be on the floor of the sinus, not near the roof, and humans would have fewer sinus problems. Persons with a congested maxillary sinus may get pain relief by placing their head with the face downward for several minutes to permit more rapid drainage of the maxillary sinuses.

### c. Bony Processes of Each Maxilla

There are four processes extending out from the body of the maxillae. The first three described below are best viewed in Figure 14-7.

#### (1) Frontal (or Nasofrontal) Process

The **frontal** (or **nasofrontal**) process derives its name from the fact that its medial edge joins with the nasal bone, extending superiorly to also articulate with the frontal bone. The medial surface forms part of the lateral wall of the nasal cavity and half of the opening of the nasal cavity (called the **piriform aperture** because of its pear shape).

#### (2) Zygomatic Process

The bulky **zygomatic process** forms part of the anterior or facial surface of each maxilla. It extends laterally to join with the maxillary process of the zygomatic bone.

#### (3) Alveolar Process

The horseshoe-shaped **alveolar** [al VEE o lar] processes of the right and left maxillae (also found on the mandible, described later) extend from the body of the maxillae to surround the roots of all maxillary teeth. The extension of these process from the body of each maxilla is best appreciated by viewing the maxillary from below since when viewed laterally, the alveolar process appears to be continuous with the body of the maxilla (seen shaded on the right maxilla and the entire lower jaw or mandible in Fig. 14-7 and identified in cross section in Fig. 14-10). Within each alveolar process, the roots of each tooth are embedded in an individual **alveoli** (or tooth sockets) that are visible in the mouth after a recent tooth extraction. The shape of each alveolus or thin bony socket naturally corresponds closely with the shape of the roots of the tooth it surrounds. **Alveolar eminences** are raised ridges of bone

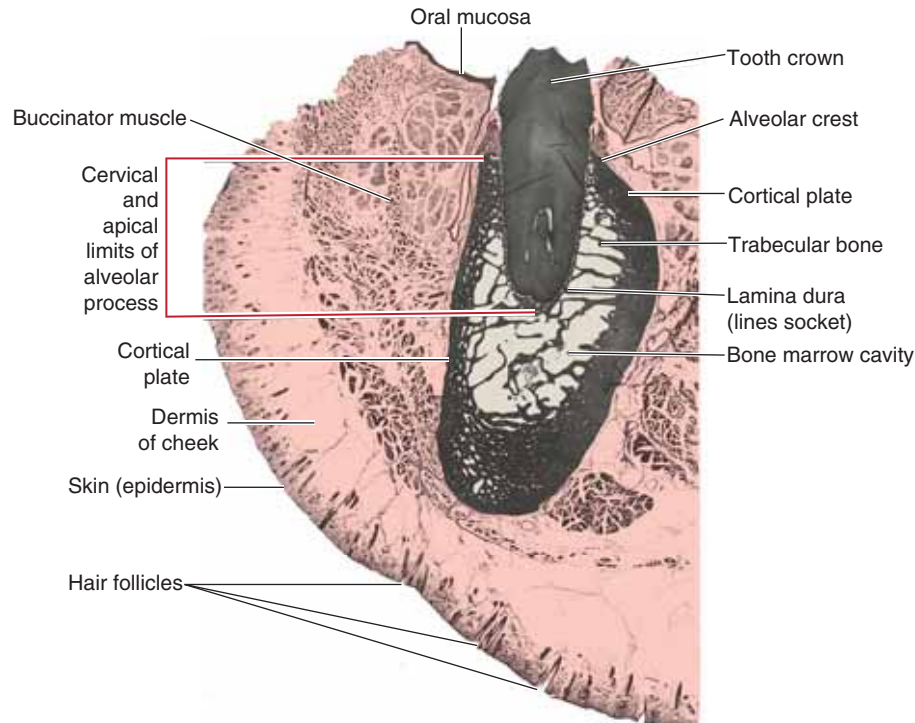
externally overlying prominent tooth root convexities. The alveolar eminence over the canine tooth on each side is called the **canine eminence** (Fig. 14-7). Medial to the canine eminence is a shallow fossa over the root of the maxillary lateral incisor called the **incisive** [in SI siv] **fossa**. Lateral and superior to the canine eminence is a fossa over the roots of maxillary premolars named the **canine fossa**.

The alveolar process is made up of several bony layers (seen in cross section of the mandible in Fig. 14-10). The mandibular bone is made up of the thickened inner (lingual) and outer (facial) dense **cortical plate** with less dense **trabecular** [trah BEK u lar] **bone** sandwiched in between. Trabecular bone is composed of many plate-like bone partitions that separate the irregularly shaped marrow spaces located within this bone. Synonyms for trabecular bone include cancellous or spongy bone. Small nerve branches and vessels actually pass through this spongy bone to enter all teeth through their apical foramen. A thin, compact bony layer lines the wall of each tooth socket (or alveolus) and shows up on radiographs as a white line called the **lamina dura**. Other terms used to describe this bony layer include alveolar bony socket, alveolar bone, true alveolar bone, alveolar bone proper, and cribriform plate of the alveolar process. The only space between the outer layer of tooth root (which is covered with cementum) and this alveolar bone is occupied by a periodontal ligament that suspends each tooth within its alveolus by attaching the circumference of each tooth root to the surrounding alveolar bony socket. The **periodontal ligament** is very thin [less than a third of a millimeter].

#### (4) Palatine Process of the Maxilla

The right and left **palatine** [Pal a tine] processes (Fig. 14-11) join to form the anterior three quarters of the bony roof of the mouth called the **hard palate**. The palatine bones, discussed later in this chapter, form the posterior one quarter of the hard palate. The palatine process of each maxilla is a thin, bony shelf that projects horizontally to join the process from the opposite side. The entire hard palate separates the nasal passageways from the oral cavity. That is, the hard palate forms the roof the mouth and the floor of the nasal passageways. The shape and relative location of these processes can be best appreciated by viewing them posteriorly between the two pterygoid processes of the sphenoid bone.

The anteroposterior line of fusion between the right and left palatine processes of the maxillae (and the horizontal plates of the palatine bones) is the **intermaxillary** (or **midpalatine**) **suture**. It is located on the midline running posteriorly from the incisive foramen (Fig. 14-11). The **incisive foramen** is a centrally located



**FIGURE 14-10.** A buccolingual cross section (about 30  $\mu\text{m}$  thick) of a human mandible and a molar: To the left of the mandible is the soft facial tissue of the cheek. Note the extent of the **alveolar process** (denoted by a red bracket)—the part of the mandible that surrounds the teeth roots. The thick **cortical plate** surrounds the entire facial (**left**) and medial (**right, inner**) surfaces of the mandible, while the very thin **lamina dura** layer of bone lines the socket that surrounds the tooth root. A very thin **periodontal ligament** extends between the lamina dura that lines the socket, and outer layer of tooth root. It supports the tooth within its socket. Note that much of this mandible has the texture of a sponge with many hollow spaces (bone marrow cavities), allowing nerves and blood vessels, after entering the bone through foramen, to pass through this **trabecular (spongy) bone** on their way to each tooth and adjacent bony structures. (Tooth enamel was destroyed by the decalcification of the specimen with nitric acid preparatory to embedding and sectioning.) For further information on the histology of these structures, refer to references.<sup>10,23,34-38</sup>

opening at the most anterior part of this suture, just posterior to the central incisors. It transmits branches of the *nasopalatine nerve* and artery that supply adjacent palatal mucosa. Just posterior to the maxillary alveolar process of the most posterior maxillary molar is a bulge of bone called the **maxillary tuberosity**. A notch that separates the maxillary tuberosity of each maxilla from the adjacent pterygoid process of the sphenoid bone is called the **hamular notch**. Recall that the **pterygoid hamulus**, the hook-like projection of the medial plate of the pterygoid process, is located just posterior to the hamular notch. In your mouth, the pterygoid hamulus might be felt with your tongue (or clean fingers) under the mucosa of the soft palate posterior to the hard palate and slightly medial to the maxillary tuberosity.

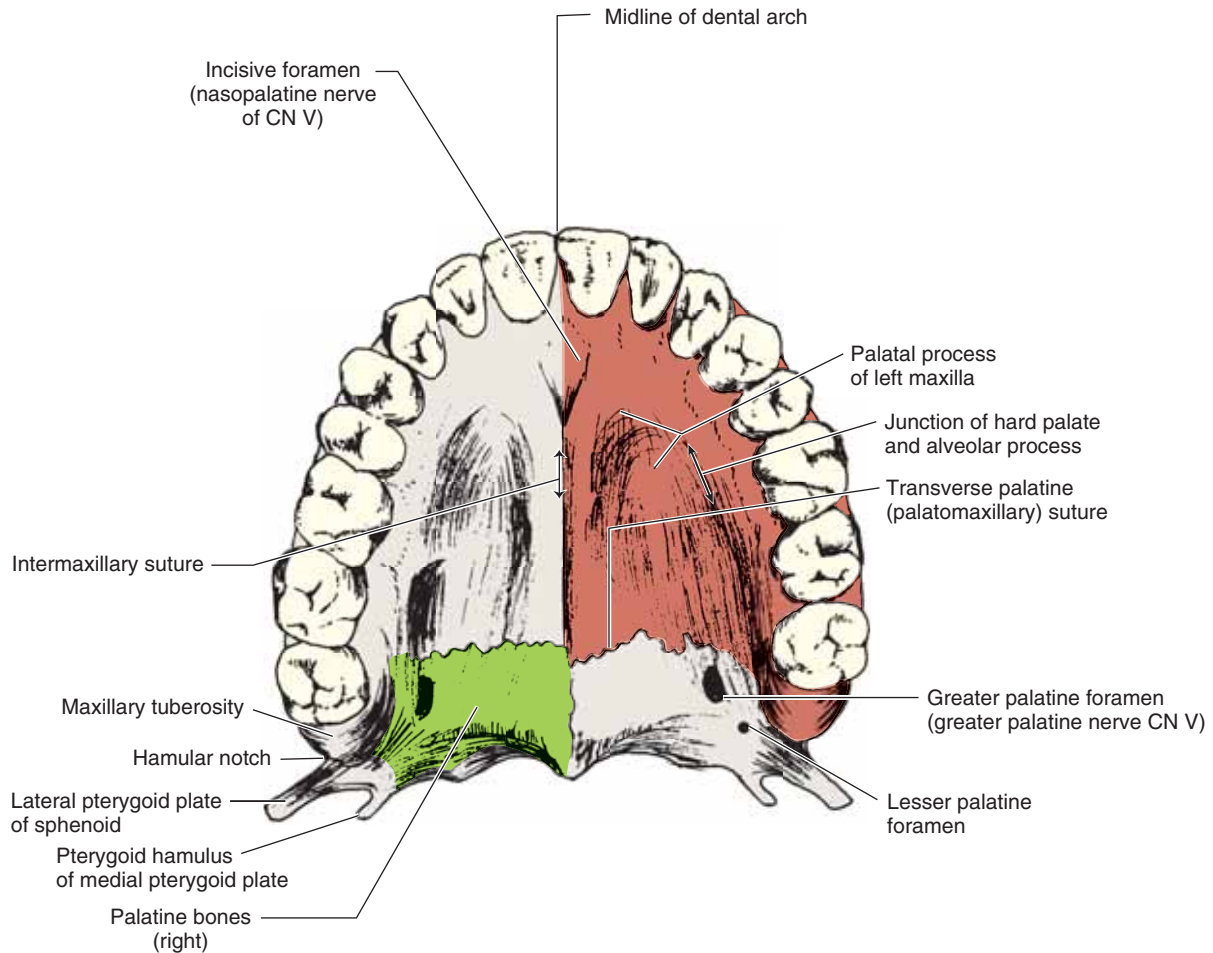
An embryonic **premaxilla** cannot normally be distinguished in the adult skull. It is the anterior part of the maxillary bone, which contains the incisors. When visible, a suture line separates the premaxilla from the palatine processes of the two maxillae.

## 2. PALATINE BONES

Refer to Figure 14-11 while reading about the **palatine bone**. The *horizontal* processes of the paired palatine bones form the posterior one fourth of the **hard palate**. The entire hard palate is made up of these palatine bones, along with the right and left palatine processes of the maxillae. A **palatamaxillary** [PAL ah toe MACK si lar ee] (**transverse palatine**) suture, at right angles to the intermaxillary suture, is the junction between the palatine processes of the maxillae and the horizontal processes of the palatine bones. The shape of the palate and the shape of the maxillary arch vary in length, breadth, and height. The hard palate blends smoothly with the palatal portion of the maxillary alveolar process. Part or all of the palatine processes are absent in a person who was born with a cleft palate.

The **greater palatine** [PAL ah tine] foramen (Fig. 14-11) are located posteriorly on each side near the angle where the right and left palatine bones meet





**FIGURE 14-11.** Inferior view of the hard palate with maxillary teeth: The palatal process of the left maxilla is shaded red (on the right side of the drawing), and the horizontal process of the right palatine bone is shaded light green on the left side of the drawing. Note the important foramen where nerves and vessels can pass through to supply the palatal tissue: the greater palatine foramen in the palatine bones, and the incisive foramen anteriorly between the palatine processes of the two maxillae. Also, notice the location of the junction of the hard palate and alveolar process.

the alveolar processes of the hard palate. They transmit the descending palatine vessels and *greater (anterior) palatine nerves* to the palate. The **lesser palatine foramina** are located on the palatine bone just behind and lateral to the greater palatine foramen. They transmit the middle and posterior palatine nerves.

The palatine bones also have *vertical processes* that are practically hidden from view on the intact skull. These vertical processes form part of the posterior wall of the maxillary sinus in Figure 14-8. These vertical processes of the palatine bones are separated from the pterygoid process of the sphenoid bone by a space called the **pterygopalatine** [TER i go PAL ah tine] **space**, mentioned earlier when discussing the maxillae. Recall that this space is an important passageway of the *maxillary nerve* branches of CN V that exited from the cranium via the foramen rotundum on their way to the maxillary teeth and surrounding structures.

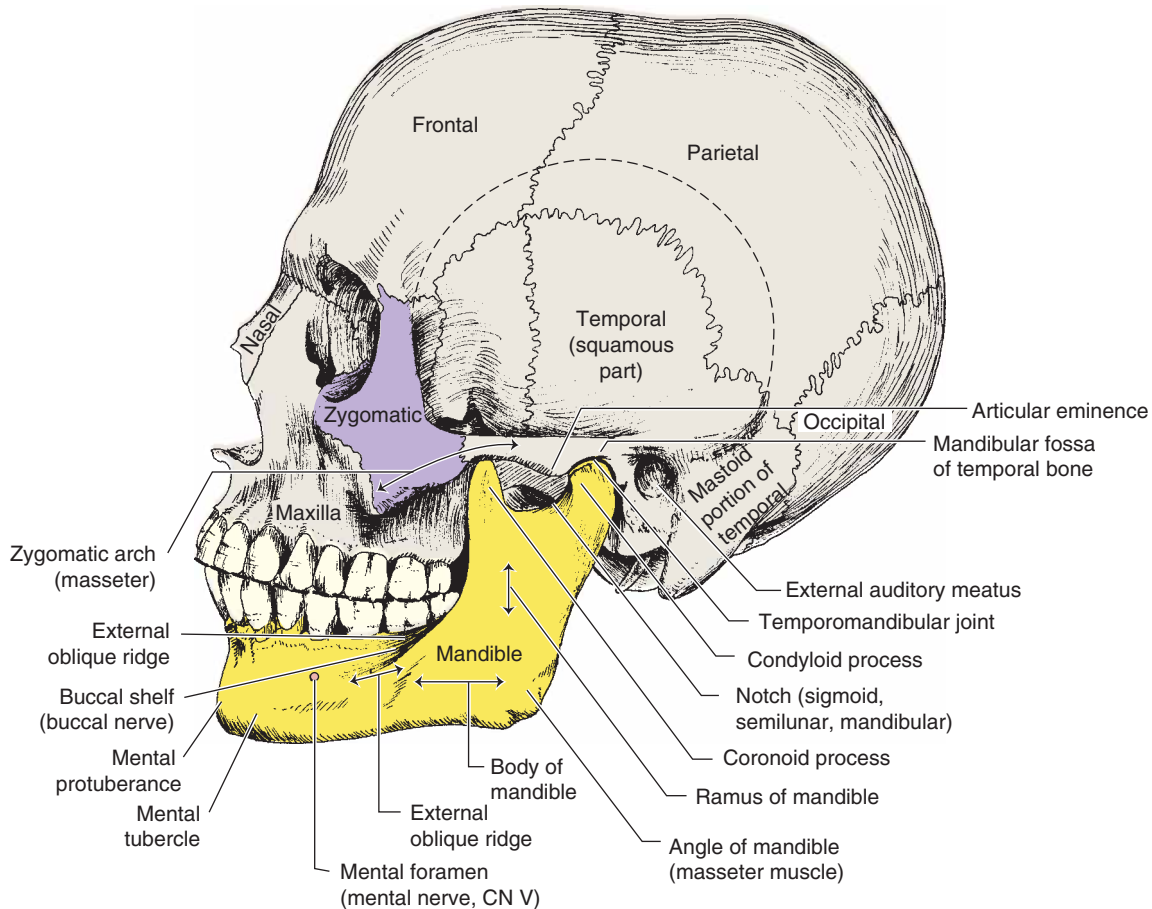
### 3. ZYGOMATIC BONES

The **zygomatic bones** (also called **malar bones**) form the prominence of each cheek (one on each side of the face, shaded green in Fig. 14-12). The temporal process of the zygomatic bone forms an arch along with the adjoining zygomatic process of the temporal bone. This **zygomatic arch** is where another muscle of mastication (the *masseter muscle*) attaches to the skull.

### 4. MANDIBLE: FORMING THE INFERIOR PORTION OF THE TEMPOROMANDIBULAR JOINT

The single horseshoe-shaped **mandible** [MAN de b'l], seen anteriorly in Figure 14-13, is the largest and strongest bone of the face. Generally speaking, it is bilaterally symmetrical, and it contains all of the mandibular teeth. It is attached by ligaments and muscles to the relatively





**FIGURE 14-12.** Human skull, left side: The lateral view of the **mandible** is shaded *yellow*, and the left zygomatic bone (of the cheek) is shaded *purple*. In this view, the vertical **ramus** and its two processes (condylar and coronoid processes) are evident. Also, the zygoma bone, the zygomatic process of the temporal bone, and the zygomatic process of the maxilla form the **zygomatic arch**.

immovable bones of the temporal bone that form part of the neurocranium. Therefore, the mandible is the only bone of the skull that can move. The other bones of the skull move only when the whole head is moved, and then they move in unison. The TMJs between the mandible and the temporal bones are movable articulations, the only visible movable articulations in the head.

The mandible has three parts: one horizontal, horse-shoe-shaped body and two vertical **rami** [RAY mee] (singular, ramus [RAY mus]) (see Fig. 14-13). The landmarks of the mandible will be discussed according to their location: first those seen on the external surface of the body, then those on each ramus, and then those seen on the internal surface.

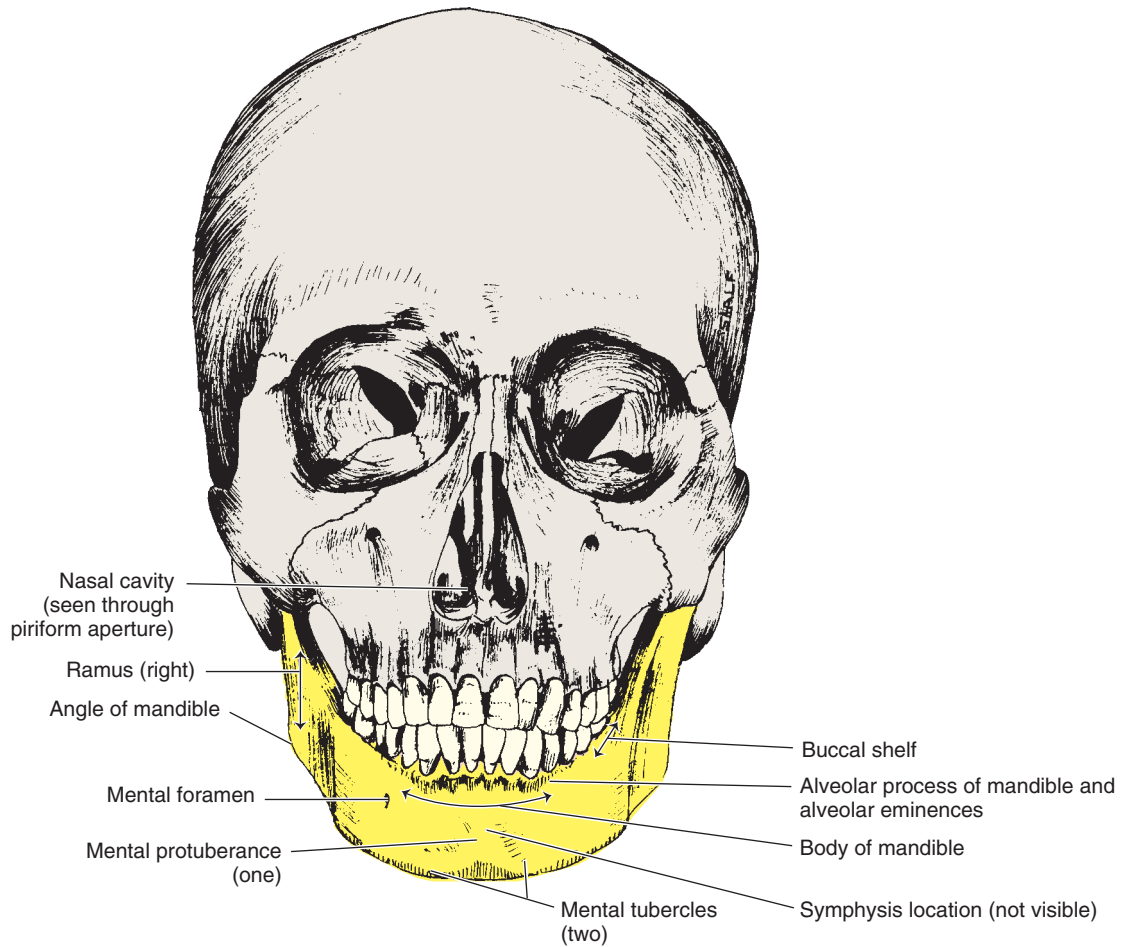
#### a. Body of the Mandible: External Surface

As with the maxillae, an **alveolar** [al VEE o lar] process surrounds the tooth roots (shaded in Fig. 14-7), and **alveolar eminences** are visible as vertical elevations

over tooth roots on the facial surface. The prominent elevations overlying the roots of the canines are called the **canine eminences**.

The bulky, curved, horizontal body and the flattened vertical ramus join at the angle of the mandible on either side. The **angle** of the mandible is where the inferior border of the body joins the posterior border of the ramus (Fig. 14-12). The roughened portion of the lateral surface near the angle of the mandible is where the inferior end of the powerful *masseter muscle* attaches. The posterior border of the ramus is the location of the attachment of one end of the *stylomandibular ligament* (whose other end attaches to the styloid process of the temporal bone).

The **symphysis** [SIM fi sis] is the line of fusion of the right and left sides at the midline where the two halves of the mandible fused (joined together) during the first year after birth. It is therefore usually not visible. Near the symphysis, two mental tubercles and one mental protuberance make up the human



**FIGURE 14-13.** Human skull, frontal aspect: The **mandible** is shaded *yellow*. The bulky **body** of the mandible is the horizontal portion including the alveolar process that surrounds the mandibular teeth, and the two vertical processes extending to the base of the neurocranium (to the temporal bones) are called the **rami** (single is **ramus**).

chin (Fig. 14-13). No other mammal has a chin. Two **mental tubercles** lie on either side of the midline near the inferior border of the mandible. The **mental protuberance** is centered on the midline between the two mental tubercles but is about 10 mm superior. The protuberance and the tubercles are more prominent on men than on women.

An **external oblique** [ob LEEK] **ridge** (Fig. 14-12) extends from the anterior border of the ramus toward the canine region. The nearly horizontal ledge of bone in the molar region between the external oblique ridge and alveolar process is named the **buccal shelf**. The **buccal** (or **buccinator**) **nerve** is located in the cheek just superior to this shelf.

The **mental foramen** is located near the root end (apex) of the second premolar (Fig. 14-12). The nerve within the mandible (**inferior alveolar nerve**) gives off a branch (**mental branch** of the inferior alveolar nerve) that exits through this mental foramen to supply skin

on that side of the chin. The mental nerve exits the mandible in an outward, upward, and posterior direction before it spreads anteriorly. Place a flexible probe carefully into this canal of the mandible to confirm the direction of this canal. The mental foramen is located at practically the same level on most humans: 13 to 15 mm superior to the inferior border of the mandible. (In a study of 40 skulls,<sup>2</sup> the mental foramen was found most often to be directly under the second premolar (42.5% of the time) or between the apices of the first and second premolars (40%). Infrequently, it was located distal to the apex of the second premolar (17.5%) and was never found under the apex of the first premolar.) On dental radiographs (x-rays), this foramen appears as a small dark circle next to the premolar root and must be distinguished from a periapical abscess (infection destroying bone near the root apex), which may appear very similar to the normal mental foramen.

### b. Ramus of the Mandible: Lateral Surfaces

Refer to Figure 14-12 while reading about this surface. There are two processes on the superior end of each ramus. The **coronoid** [KOR o noyd] **process** is the more pointed, anterior process on the upper border. The second more rounded and posterior process of the ramus is the **condyloid** [KON di loyd] **process** (also called the **mandibular condyle**). This process is composed of a bulky condyle head and a narrow neck that attaches the head to the ramus. The **sigmoid notch** (also called the **mandibular or semilunar notch**) is located between the coronoid process and the condyloid process. One part of an important muscle of mastication, the *lateral pterygoid*, attaches to the front of the neck of the condyloid process in a depression called the **pterygoid fovea** (Fig. 14-14). The head of the mandibular condyle fits into and functions beneath the articular (glenoid) fossa of the temporal bone (which is discussed in more detail later in this chapter).

### c. Internal or Medial Surface of Mandible

Refer to Figure 14-14 while reading about this surface of the mandible. The **mandibular foramen** is a prominent opening located on the medial surface of the ramus inferior to the sigmoid notch near the middle of the ramus anterioposteriorly. It is the entrance into the mandibular canal where the *inferior alveolar* vessels and nerves pass from the infratemporal space into the mandible. The **mandibular lingula** [LING gu lah] is a tongue-shaped projection of bone just anterior and slightly superior to the mandibular foramen. This is where the inferior end of the *sphenomandibular ligament* attaches to the mandible. The superior end attaches to the angular (sphenoidal) spine on the sphenoid bone. The **mylohyoid groove** is a small groove running

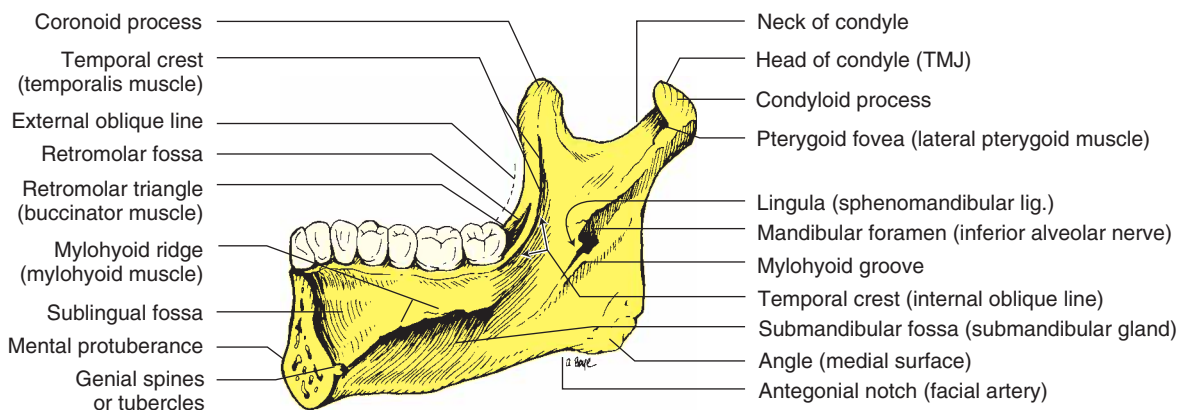
inferior and anterior from the mandibular foramen. The mylohyoid nerve rests in this groove.

The **temporal crest** is a ridge of bone extending from the tip of the coronoid process onto the medial surface of the ramus and terminating near the third molar. The tendon from the fibers of the wide, flat, fan-shaped *temporalis muscle* attaches here. The inferior one fourth of the temporal crest is called the **internal oblique line**. It is most important as a radiographic, rather than an anatomic, landmark. It appears on radiographs as a short, curved line somewhat inferior to the image of the external oblique line.

The **retromolar fossa** is a roughened shallow fossa distal to the last molar and bounded medially by the lowest portion of the temporal crest and laterally by the external oblique ridge. The **retromolar triangle** is in the lowest most anterior, and only horizontal, portion of the retromolar fossa. The most posterior fibers of the *buccinator muscle* (a pouch-shaped cheek muscle) attach within this retromolar triangle on a slight ridge of bone called the **buccinator crest**.

**Genial** [JEE ne al] and **mental spines** or **tubercles** are located on either side of the midline on the internal surface of the mandible. Two large muscles (the *genioglossus* and the *geniohyoid*) attach to these spines and the elevated, roughened bone near them.

The **mylohyoid ridge** extends downward and forward from the molar region to the genial tubercles. It is not synonymous with the internal oblique line as incorrectly stated in some radiographic textbooks. The *mylohyoid muscle*, which forms part of the floor of the mouth, attaches from the mylohyoid ridge on the right medial side of the mandible to the ridge on the left medial side (somewhat like a hammock). The mylohyoid ridge separates two fossae, one above and one below. A very broad, shallow **sublingual** [sub LING



**FIGURE 14-14.** Mandible, medial surface: Notice the important **mandibular foramen**, as well as ridges, fossa, and processes.

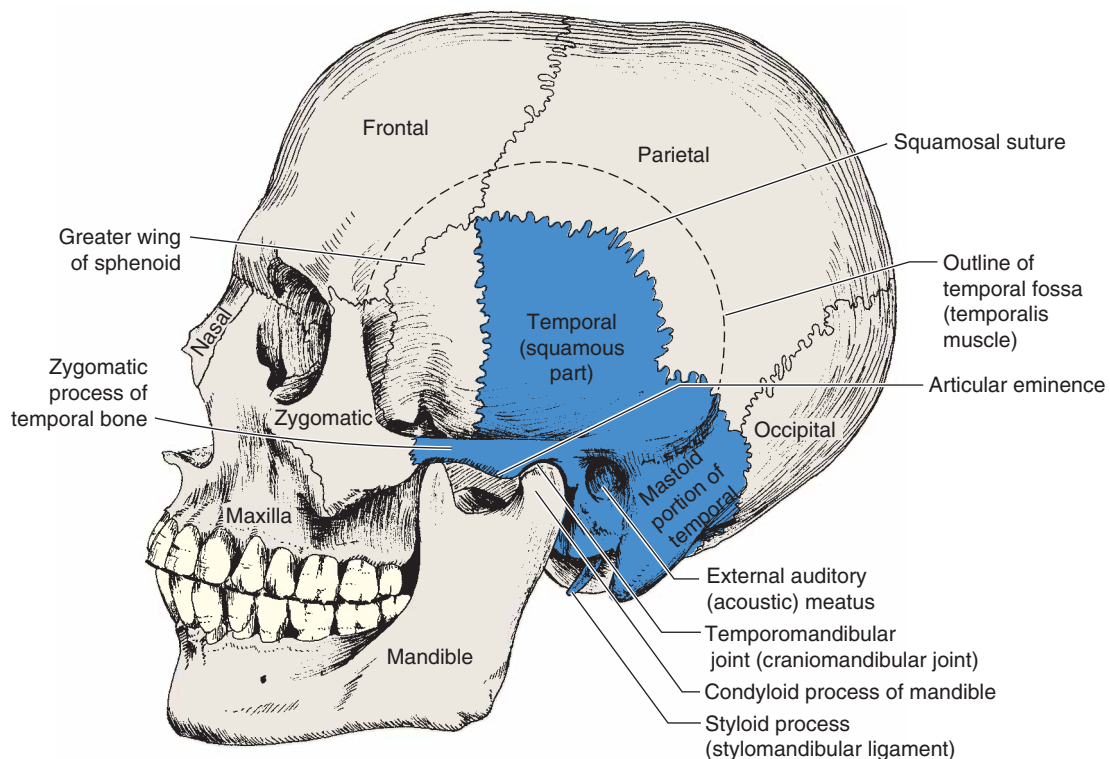
gwal] fossa is found just superior to the mylohyoid ridge and lateral to the genial tubercles on each side. The *sublingual salivary gland* rests in this fossa. A shallow **submandibular fossa** is found just inferior to the mylohyoid ridge in the premolar and molar regions. This is where the large *submandibular salivary gland* rests. On the inferior border of the mandible, a shallow notch (called the antegonial notch) is located anterior to the angle of the mandible and is where the facial arteries and veins pass from the neck to the face. You should be able to feel a pulse at this location of your own lower jaw.

## 5. TEMPORAL BONES: FORMING THE SUPERIOR PART OF THE TEMPOROMANDIBULAR JOINT

The **temporal bones** are a pair of complex bones that form part of the sides and base of the neurocranium (brain case) (best seen laterally in Fig. 14-15 where one is shaded blue). Laterally, the **temporal fossa** (outlined in Fig. 14-15) is a large, very shallow depression in the temple region of the face formed primarily by the lateral part of the temporal bone (also called the squamous

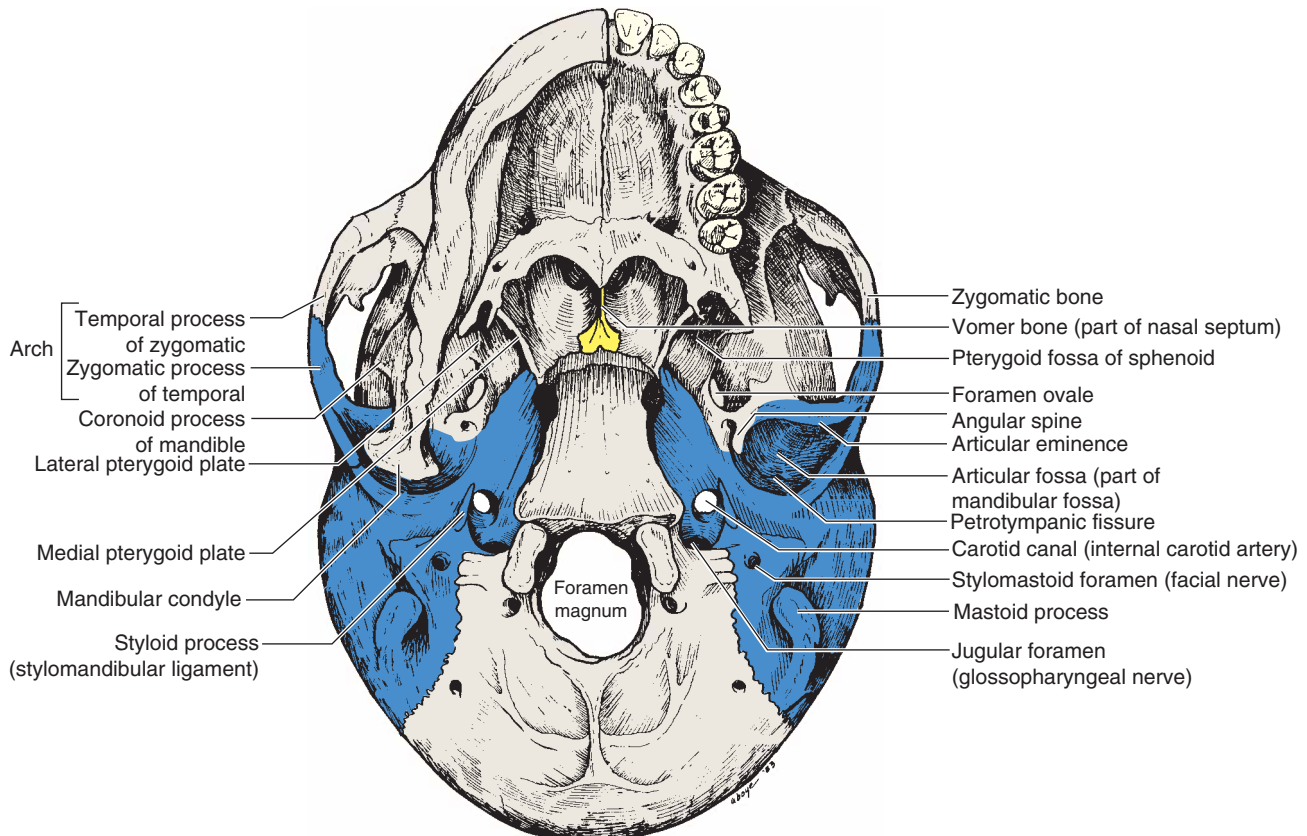
part because it is shaped like a large fish scale), and also by the greater wing of the sphenoid bone and parts of the parietal and frontal bones that were discussed earlier. The temporal fossa is where the superior end of the major muscle of mastication (the *temporalis muscle*) attaches. **Squamosal** [skwa MO sal] sutures join the temporal bones to the parietal bones.

The paired temporal bones are especially important to dental professionals since each has a **mandibular fossa** (one is labeled on the right side of Fig. 14-16) located on the inferior aspect of the temporal bones. It is within these fossae that the condyloid processes of the mandible articulate with the temporal bones on the base of the neurocranium. This jaw joint (actually a joint on each side) is called the **temporomandibular joint** (commonly abbreviated TMJ) where the temporal bone and mandible articulate. Each mandibular fossa can be divided into two parts by the **petrotympanic fissure** (Fig. 14-16). The anterior two thirds of each mandibular fossa (that portion anterior to the petrotympanic fissure) is the important **articular fossa** (or **glenoid fossa**). Each articular fossa has a ridge of bone forming its anterior border, which is called the **articular eminence**.



**FIGURE 14-15.** Human skull, left side: The lateral surface of the left **temporal bone** is shaded *blue*. Note its squamous part, as well as its processes: mastoid, styloid, and zygomatic.

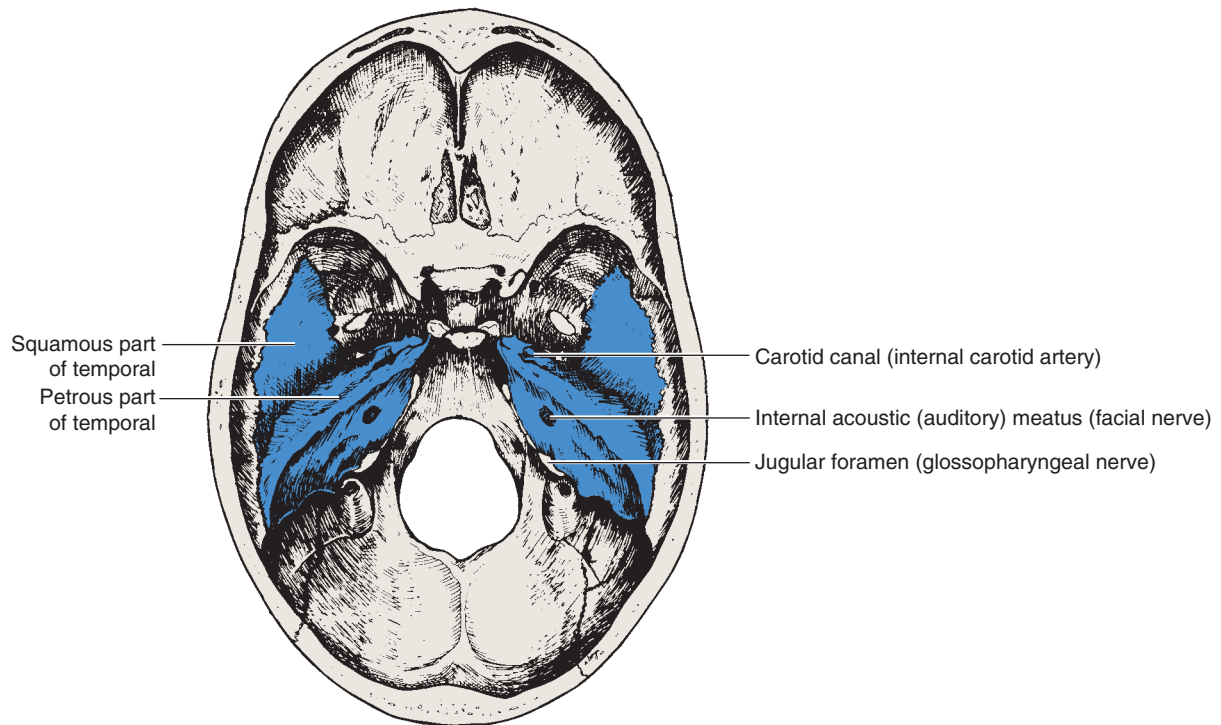




**FIGURE 14-16.** Human skull: inferior surface, with half of the mandible removed on the right side of the drawing. The right and left temporal bones are shaded blue. Note the zygomatic process forming part of the zygomatic arch and the mandibular and articular fossa and articular eminence. The small portion of the midline vomer bone (shaded yellow) is seen separating the right and left halves of the nasal passageways.

Each temporal bone has several processes. The zygomatic [zy go MAT ik] process (Fig. 14-15) is the finger of bone extending anterior and lateral to the mandibular fossa of the TMJ. It joins with the temporal process of the zygomatic bone (and the zygomatic process of the maxillae) to form an arch called the zygomatic arch. This arch shape of bones, seen from beneath in Figure 14-16, is the attachment of one end of the large muscle of mastication (*masseter muscle*). The prominent mastoid process or portion (Fig. 14-15), seen inferiorly and posteriorly to the mandibular fossa, is the attachment for one end of a major neck muscle, the *sternocleidomastoid muscle*. You can feel the bump of the mastoid process behind your ear lobe. Also on the inferior surface of the temporal bones but more medial is the styloid process (Fig. 14-15), shaped like a small skinny pencil (or stylus). It is the attachment for one end of a ligament (*stylomandibular ligament*) that extends to the mandible.

Several paired foramina are of importance on this bone. Laterally, the large external acoustic (or auditory) meatus [a KOO stik me A tus] is the entrance into the ear canal (Fig. 14-15). Note the proximity of the TMJ to the ear canal opening. The facial nerve (CN VII) exits the brain case by entering the petrous portion of the temporal bone through the internal acoustic meatus (Fig. 14-17) and exits the temporal bone into the infratemporal space through the stylomastoid foramen (Fig. 14-16), which is located between the styloid and mastoid processes. This petrous portion of the temporal bone contains the auditory canal with the minute bones of hearing known as the malleus, incus, and stapes. The carotid canal is the passageway of the internal carotid artery into the brain case, and the jugular foramen (between the temporal and occipital bones) is where the glossopharyngeal nerve (CN IX) passes out of the brain case (seen externally in Fig. 14-16 and internally in Fig. 14-17).



**FIGURE 14-17.** Part of human skull: bones lining the inside of the neurocranium with the **temporal bones** in blue. The thick **petrous portion** of these bones contains the very small bones of the inner ear (incus, stapes, and malleus). Important nerves and vessels pass through the foramen labeled on this diagram. (Reproduced from Clemente CD, ed. Gray's anatomy of the human body. 30th ed. Philadelphia, PA: Lea & Febiger, 1985:166, with permission.)

#### D. SMALL BONES OF THE FACE

The **vomer bone** is a midline bone that, along with the vertical projection of the ethmoid bone, forms the **nasal septum**. The vomer is visible posteriorly between the two halves of the nasal passageways in Figure 14-16, and the nasal septum is visible anteriorly in Figure 14-18. The nasal septum separates the right and left halves of the nasal cavity. A deviated septum may limit breathing and require surgery.

The two **nasal bones** form the bony bridge of the nose (Fig. 14-18).

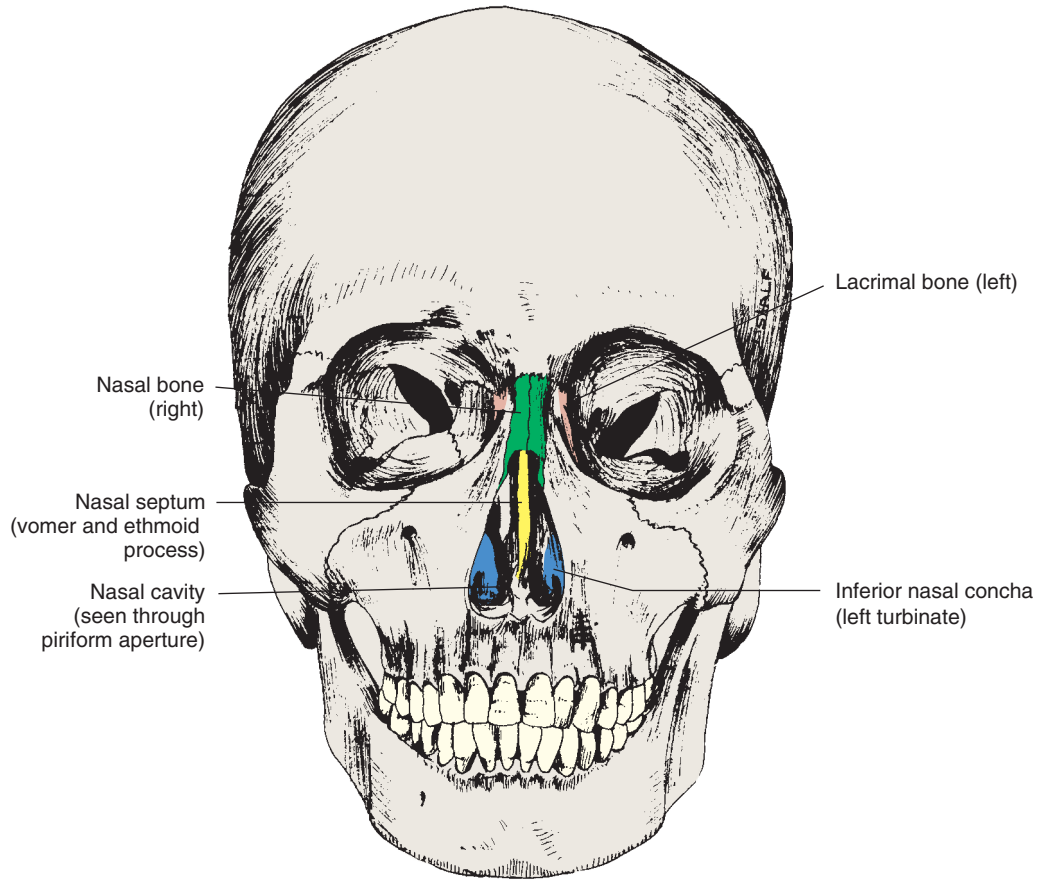
The **lacrimal** [LAK ri mal] bones (also spelled lachrymal) are small rectangular bones at the medial corner of each orbit that contain a depression for tear glands (Fig. 14-18).

The **inferior nasal conchae** [CONG kee] or singular concha [KONG kah] (or **turbinates**) are scrolled bones (like the cross section scroll shape of a conch shell) in the nasal cavity forming part of the maxillary sinus wall. These are best seen through the opening to the nasal

cavity (piriform aperture) (Fig. 14-18). Along with other scrolled processes of the ethmoid bone described earlier, they increase the area of mucous membrane inside the nasal cavity to warm and moisten air that we breathe.

#### E. HYOID BONE

The **hyoid** [HI oid] bone (see later in Fig. 14-35) is not really a bone of the skull but is located in the neck above the laryngeal prominence of the thyroid cartilage (known to many as the Adam's apple or voice box). The hyoid bone is not connected to the bones of the skull except via soft tissue. A group of muscles that extend from the hyoid bone superiorly to attach to the mandible are called **suprahyoid muscles** (such as the geniohyoid muscles that also attach to the genial tubercles), and another group that extend inferiorly from the hyoid bone to attach to the sternum (breastbone) or clavicle (collar bone) are called **infrahyoid muscles**.



**FIGURE 14-18. Human skull, frontal aspect:** Several small bones of the face and nose are shaded: the **nasal bones** forming the bridge of the nose are shaded *green*, the **lacrimal bones** on the medial surfaces of the eye socket are shaded *light red*, the **inferior nasal conchae** or turbinate bones on the lateral sides of the nasal passageway are shaded *blue*, and the midline **nasal septum** is shaded *yellow*. The septum is made up of two bones: the **vomer bone** and the midline plate of the **ethmoid bone**.

## Review Questions

Select the one best answer.

- Which of the following bones does not form part of the temporal fossa?
  - Parietal
  - Frontal
  - Sphenoid
  - Temporal
  - Occipital
- The mental foramen is located where?
  - On the external surface of the mandible
  - On the internal surface of the mandible
  - On the palatal surface of the maxilla
  - On the external surface of the maxillae
  - On the sphenoid bone
- What space does the maxillary nerve pass through immediately after exiting the foramen rotundum?
  - Nasopalatine canal
  - Mandibular canal
  - Maxillary sinus
  - Infraorbital canal
  - Pterygopalatine space
- What bony process of the maxilla surrounds tooth roots?
  - Nasofrontal process
  - Frontal process
  - Alveolar process
  - Zygomatic process
  - Palatine process

5. Which structure is not located on the sphenoid bone?
- Foramen ovale
  - Foramen rotundum
  - Greater wing
  - Pterygoid process
  - Articular fossa
6. Which teeth are most likely to have the roots in proximity with the maxillary sinus?
- Maxillary molars and premolars
  - Maxillary canines
  - Maxillary incisors
  - Mandibular posterior teeth
7. The suture line joining the two parietal bones is called the
- Squamosal suture.
  - Coronoid suture.
  - Sagittal suture.
  - Intermaxillary suture.
  - Lambdoid suture.

ANSWERS: 1—e, 2—a, 3—e, 4—c, 5—e, 6—a, 7—c

## LEARNING EXERCISES

Each of the following bony landmarks can be seen or felt underneath the soft tissue on the face or in the mouth and could be used to describe the location of abnormalities during a clinical examination. First, describe the location; then, identify each of the following landmarks on your own face and on an actual skull (or figures within this text). Use the referenced figures to confirm that you have correctly located each landmark. Use clean fingers when palpating structures within the mouth.

- Canine eminence of the mandible and maxillae—Figure 14-7
- Mental protuberance—Figure 14-13
- Maxillary tuberosity—Figure 14-11
- External auditory meatus—Figure 14-12

Each of the following landmarks is the attachment of a major muscle or ligament of importance to the dental professional. First, describe the location; then, identify each of the following landmarks on an actual skull (or figures within this text). Use the referenced figures to confirm that you have correctly described the location of the attachment on the skull. When possible, also feel or point to the landmark's location on your own head, or within your mouth (using clean fingers).

- Angle of the mandible, lateral surface (lower end of *masseter muscle*)—Figure 14-12
- Zygomatic arch (upper end of *masseter muscle*)—Figure 14-12

## Learning Exercise, cont.

- Angle of the mandible, medial surface (lower end of *medial pterygoid muscle*)—Figure 14-14
- Medial surface of the lateral pterygoid plate and adjacent pterygoid fossa of the sphenoid bone (upper end of *medial pterygoid muscle*)—Figure 14-6
- Temporal fossa (upper end of *temporalis muscle*)—Figure 14-15
- Coronoid process and temporal crest of mandible (lower end of *temporalis muscle*)—Figure 14-14
- Lateral surface of the lateral pterygoid plate of the sphenoid bone (anterior end of *lateral pterygoid muscle*)—Figure 14-5
- Pterygoid fovea: anterior neck of mandibular condyle (posterior end of *lateral pterygoid muscle*)—Figure 14-14
- Angular spine of the sphenoid (upper end of *sphenomandibular ligament*)—Figure 14-6
- Lingula of the mandible (lower end of *sphenomandibular ligament*)—Figure 14-14
- Styloid process of the temporal bone (upper end of *stylomandibular ligament*)—Figure 14-15
- Mastoid process of the temporal bone (upper end of *sternocleidomastoid muscle*)—Figure 14-15
- Mylohyoid ridge of the mandible (*mylohyoid muscle*)—Figure 14-14
- Genial spines of the mandible (upper end of some *suprahyoid muscles*)—Figure 14-14



**Learning Exercise, cont.**

Each of the following foramen or spaces is the passageway for nerves and blood vessels of importance to the dental professional. First, describe the location; then, identify each of the following foramina or spaces on an actual skull (or figures within this text). Use the referenced figures to confirm that you have correctly located the foramen, canal, or space on the skull. Then try to place your finger as close as possible to that opening, realizing that sometimes you cannot get very close with your finger but might get closer with the needle of a hypodermic syringe.

- Foramina rotundum in the sphenoid bone (for the *maxillary division of trigeminal nerve*)—Figure 14-4

**Learning Exercise, cont.**

- Pterygopalatine space (for the *maxillary division of trigeminal nerve*)—Figure 14-5
- Foramina ovale in the sphenoid bone (for the *mandibular division of trigeminal nerve*)—Figures 14-4 and 14-6
- Mandibular foramina in the mandible (for the *inferior alveolar nerve*) Figure 14-14
- Mental foramina in the mandible (for the *mental nerve*)—Figure 14-12
- Greater palatine foramina in the palatine bones (for the *greater palatine nerve*)—Figure 14-11
- Incisive foramen between the maxillary bones (for the *nasopalatine nerve*)—Figure 14-11
- Infraorbital foramina in the maxillae (for the *infraorbital nerve*)—Figure 14-7

**SECTION II****THE TEMPOROMANDIBULAR JOINT (TMJ)****OBJECTIVES**

The objectives for this section are to prepare the reader to perform the following:

- Describe and locate (on a skull) the articulating parts of the TMJ.
- Describe the location and functions of the articular disc.
- Palpate the lateral and posterior surfaces of the condyle of the mandible during movement of the jaws.
- On a skull, describe and locate the attachments of the ligaments of the TMJ.

An introduction to the TMJ was presented in Chapter 9 on Occlusion, but this chapter goes into more detail regarding the anatomy of this joint. A joint, or articulation, is a connection between two separate bones of the skeleton. The TMJ is the articulation between the two condyles of the mandible and the two temporal bones. For that reason, some authors state that we have two TMJs. This articulation may also correctly be termed the craniomandibular articulation since it is the articulation between the movable mandible and the stationary cranium or skull.<sup>3</sup> It is a bilateral articulation since the right and left sides work as a unit. It is the only visible free-moving articulation in the head; all others are sutures and are immovable.<sup>4</sup>

The coordinated movements of the right and left joints are complex and usually controlled by reflexes. Within some limit or range, the great adaptability of the joints permits the freedom of movement of the mandible required during speech and mastication (chewing). One can learn, however, to move the mandible voluntarily into specific, well-defined positions or pathways.<sup>5-9</sup> Both the maxillae and mandible support teeth whose shape and position greatly influence man-

dibular movements.<sup>3</sup> Proper functioning of the TMJs has a profound effect on the occlusal contacts of teeth, which involve nearly all phases of dentistry.

**A. ANATOMY OF THE TEMPOROMANDIBULAR JOINT**

There are three articulating parts to each TMJ: the mandibular condyle, the articular fossa of the temporal bone (with its adjacent eminence), and the articular disc interposed between the bony parts (Figs. 14-19 and 14-20). These parts are enclosed by a fibrous connective tissue capsule.<sup>1,4,7</sup>

**1. MANDIBULAR CONDYLE**

Each **mandibular condyle** [KON dile] is about the size and shape of a large date pit with the greater dimension mediolaterally than anterioposteriorly, evident when comparing the width of the condyle mediolaterally in Figure 14-20 to the narrower width anterioposteriorly seen from the side in Figure 14-19. From the posterior (or anterior) aspect, it is wide mediolaterally with

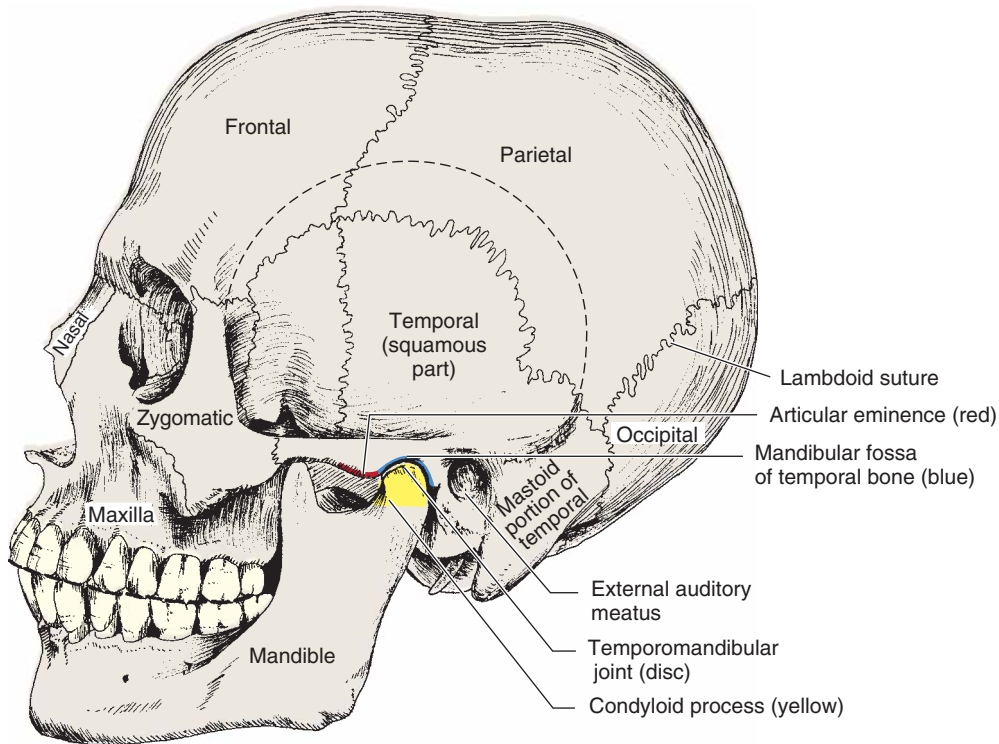


FIGURE 14-19.

**Human skull, left side:** This lateral view shows the articulation of the bones of the **temporomandibular joint**, namely, the temporal bones and the mandible. The head of the condyle of the mandible is shaded *yellow*, and the *blue* line on the inferior border of the zygomatic process of the temporal bone outlines the concave **mandibular** (with its **articular**), fossa. A *red* line just anterior to it outlines the convex **articular eminence**. For the mandibular to move forward, the condyles guide the mandible down onto the articular eminence, so the mandible is depressed and the mouth opens.

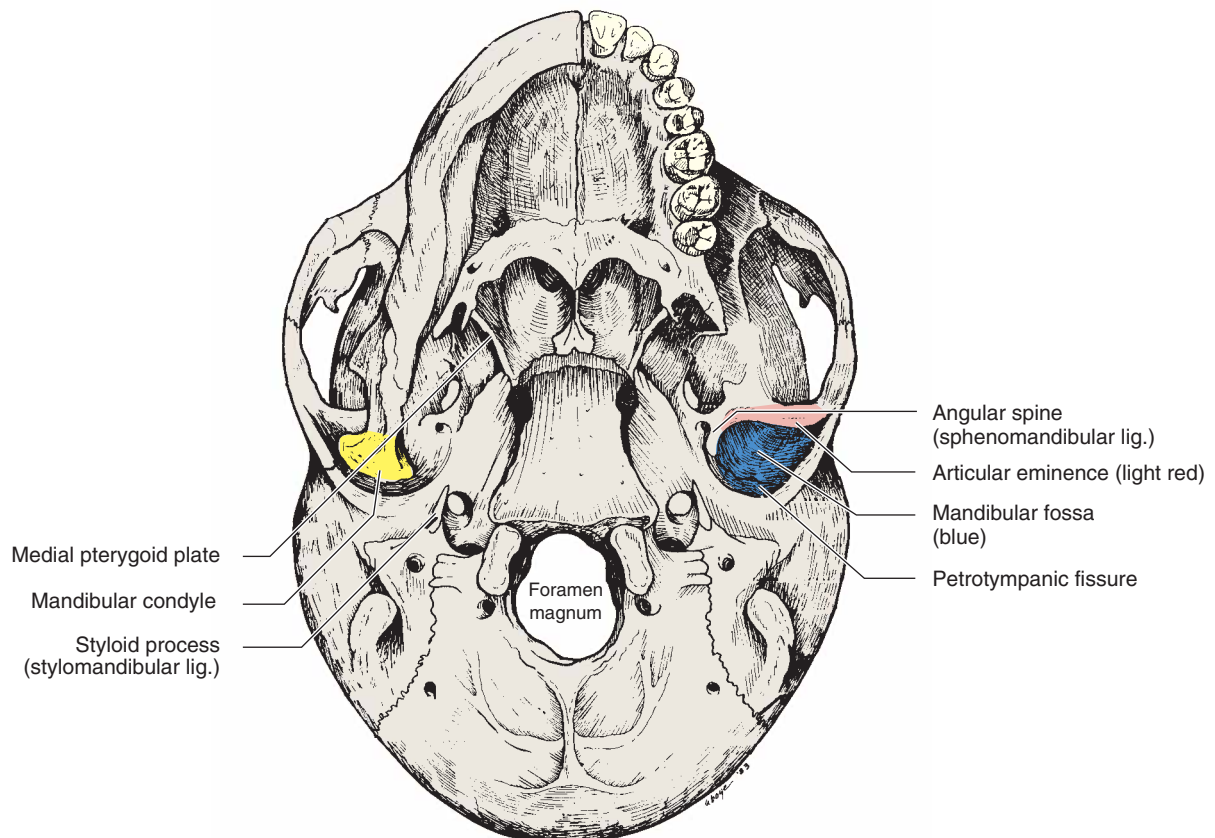


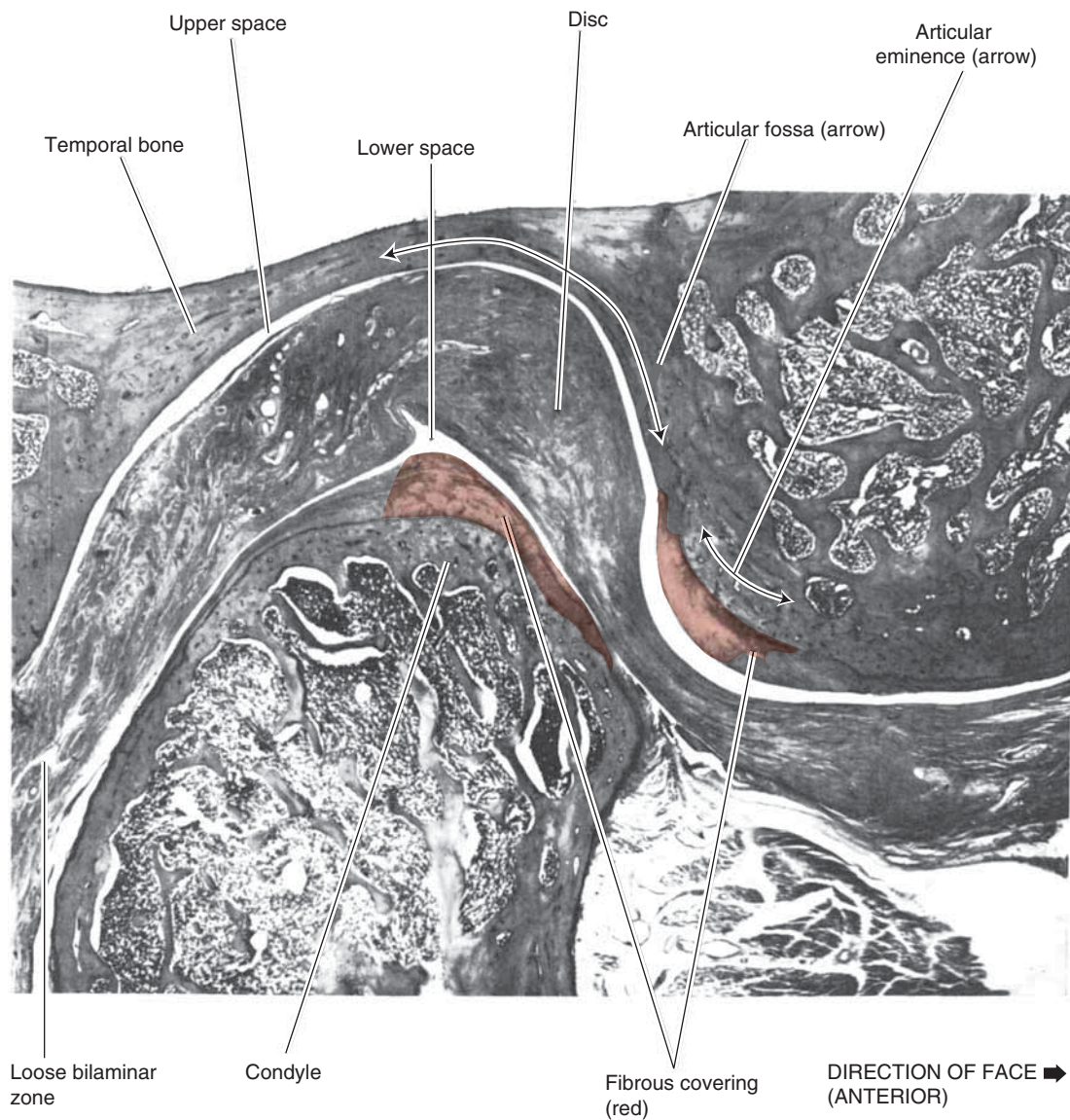
FIGURE 14-20.

**Human skull:** inferior surface with half of the mandible removed on the right side of the drawing. On the left side of the drawing, the **condylar process** of the mandible is shaded *yellow*, and on the right side with the mandible removed, the **mandibular** (and **articular**) fossa of the temporal bone is shaded *blue*, and the more anterior **articular eminence** is shaded *light red*.

a narrow neck. The superior surface of the mandibular condyle is strongly convex anteroposteriorly and mildly convex mediolaterally.

Carefully examine the photomicrograph of a human TMJ seen in *Figure 14-21*. The condyle is in the position it would occupy when the teeth fit together as tightly as possible (maximum intercuspal position). The *functioning regions* are covered with fibrous connective tissue. The fibrous layers of the condyle are avascular (devoid of blood vessels and nerves).<sup>10</sup>

This fibrous, avascular type of connective tissue is adapted to resist pressure. It is particularly thick on the superior and anterior surfaces of the condyle (seen as the red-shaded structure in Fig. 14-21) over the region where most function occurs when the condyle is forward from its resting position, as when we bring our incisors together. (Notice in Fig. 14-21 that this same type of fibrous covering also lines the posterior articulating surfaces of the articular eminence and adjacent fossa, as well as the center portion of the disc.)



**FIGURE 14-21.** **Temporomandibular joint**, photomicrograph of the lateral aspect: The anterior of the skull (the face) is toward the right of the picture. The white area across the top is the space of the brain case. Notice the thicker **fibrous covering** (shaded *red*) and underlying compact bone on the **functional part** of the posterior inferior articular eminence and superior anterior part of the mandibular condyle. Also, notice the *arrows* indicating the contours of the concave articular fossa, and convex articular eminence, of the temporal bone. (Courtesy of Professor Rudy Melfi.)



## 2. ARTICULAR FOSSA (NONFUNCTIONING PORTION) AND ARTICULAR EMINENCE (FUNCTIONING PORTION)

Study the right side of Figure 14-20 where half of the mandible has been removed, exposing the maxillary teeth and articular fossa and eminence of the temporal bone. The **articular (glenoid) fossa** is the portion of the **mandibular fossa** that is anterior to the **petrotympanic fissure**. It is considered to be a nonfunctioning portion of the joint because, when the teeth are in tight occlusion, there is no tight contact from the head of the condyle through the disc to the concave part of the articular fossa.

The **articular eminence** or transverse bony ridge is located just anterior and inferior to the articular fossa (Fig. 14-19). As stated previously, its posterior inferior surface is padded or lined with a thickened layer of fibrous connective tissue, more than the rest of the articular fossa (Fig. 14-21), indicating that this is the functional portion of the joint that take the force when we are chewing food with the mandible in a slightly protruded and/or lateral position. This is where the anterior superior portion of the mandibular condyle rubs against it, but only indirectly since the articular disc is normally interposed between the two functioning bony elements.

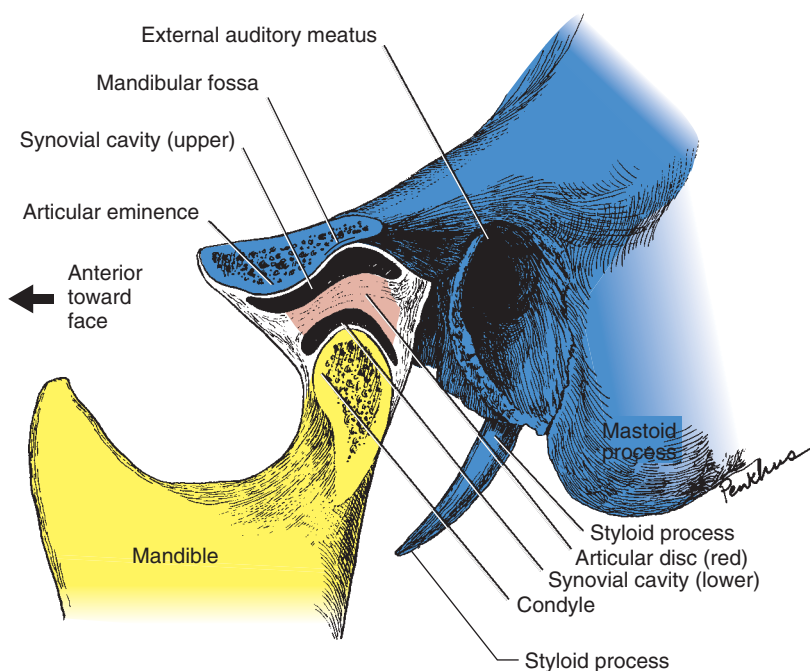
## 3. ARTICULAR DISC

Examine a skull with the posterior teeth fitting together (in tight occlusion) and study how the mandibular

condyle fits loosely into the articular fossa. The disc is not present in a prepared dry skull because the disc is not bone. There should be a visible space between the mandibular condyle and the articular fossa that, in life, was occupied by the disc.

The **articular disc** (Figs. 14-21 and 14-22) is a tough oval pad of dense fibrous connective tissue acting as a shock absorber between the mandibular condyle and the articular fossa and articular eminence. The disc surfaces are very smooth. Each disc is thinner in the center than around the edges. This shape provides one natural wedge anterior to the condyle head and a second wedge posterior to the condyle. Rarely, it may become perforated. The center of the disc has no blood supply<sup>10</sup>; however, it is richly supplied elsewhere. The *upper surface* of the disc is concave anteriorly to conform to the convex articular eminence, and it is convex posteriorly, conforming to the concave shape of the articular fossa that it loosely rests against. The *lower surface* of the disc is concave anterior to posterior, thus adapting to the upper surface of the convex mandibular condyle.

The articular disc has many functions.<sup>11,12</sup> It divides the space between the head of the condyle and the articulating fossa into upper and lower spaces (synovial cavities seen in Fig. 14-22), which permits complex functional movements of the mandible.<sup>12</sup> The anterior and posterior portions of the disc contain specialized nerve fibers called **proprioceptive [PRO pri o SEP tiv] fibers**, which help to unconsciously determine the position of the mandible, and therefore help regulate movements of the condyle. It stabilizes the condyle by



**FIGURE 14-22.** Temporomandibular joint, sagittal section: The anterior surface of the skull (face) is to the left. The sectioned (*blue*) temporal bone (with mandibular fossa and articular eminence) forms the superior part of the joint, and the sectioned head of the mandibular condyle (*yellow*) forms the inferior part. The **articular disc** is shaded *light red*. The **upper and lower synovial spaces** surround the disc. (Reproduced from Clemente CD, ed. Gray's anatomy of the human body. 30th ed. Philadelphia, PA: Lea & Febiger, 1985:340, with permission.)



**Table 14-1 PREVALENCE OF CREPITUS DURING MAXIMUM OPENING\***

	NONE (%)	BOTH SIDES (%)	RIGHT SIDE (%)	LEFT SIDE (%)	ONE SIDE (R OR L) (%)
594 Dental hygiene students	52.0	13.3	18.2	16.8	35.0
505 Dental students	72.0	4.2	15.9	7.9	23.8
Percentage of all 1099 students	61.2	9.1	17.1	12.7	29.8

\*Determinations by Dr. Woelfel, 1970–1986. More than 20% of these professional students had or were undergoing orthodontic treatment.

filling the space between incongruous articulating surfaces of the convex condyle and concave-convex articular fossa and articular eminence.<sup>12</sup> The disc cushions the articulating bones of the joint at the areas of contact (like a shock absorber). The cushioning and lubrication reduce physical wear and strain on joint surfaces.

As the mandible moves forward, the discs move forward with the mandible due, in part, to the thickened borders of each disc, which conforms to the shape of the condyles, and because the muscles that pull the mandible forward (*lateral pterygoids*) are attached to the neck of each condyles (in the pterygoid fovea) as well as to the discs. When the thicker peripheral portions of the discs become flattened or the center of the disc thickens, the disc fails to move synchronously with the condyle, resulting in a popping or grating noise (*crepitus*), which is quite an annoying yet a fairly common occurrence. The frequency of this occurrence is presented in *Table 14-1*. With an elastic posterior attachment, the

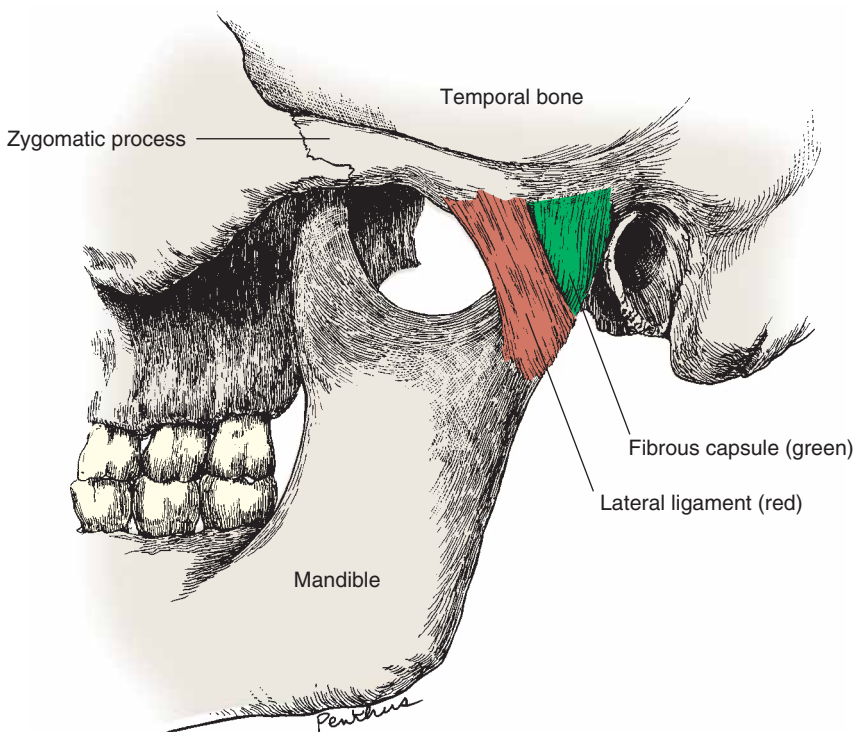
disc can move with the head of the condyle during function.

## B. LIGAMENTS THAT SUPPORT THE JOINT AND LIMIT JOINT MOVEMENT

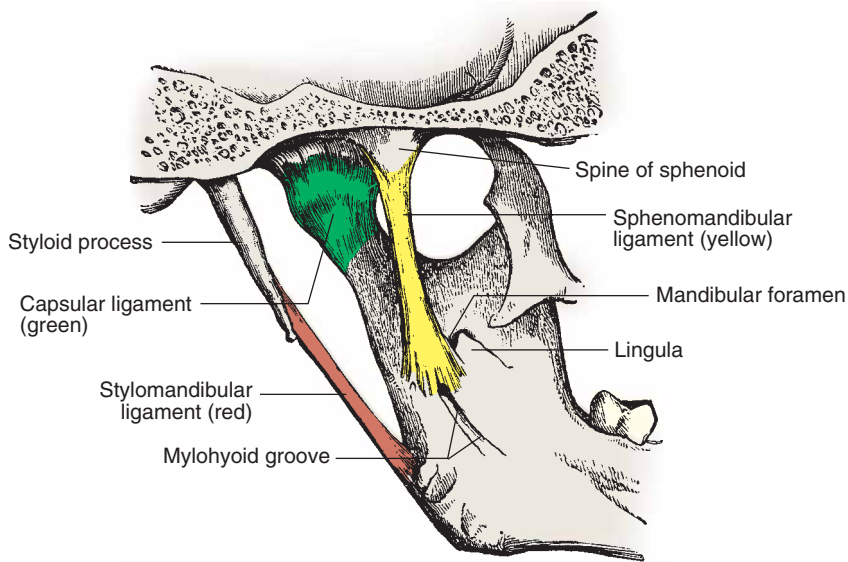
Ligaments are slightly elastic bands of tissue. They do not move the joint; muscles move the joint. They do support and confine the movement of the mandible to protect muscles from being stretched beyond their capabilities.

### 1. FIBROUS CAPSULE (CAPSULAR LIGAMENT)

The **fibrous** (or **articular**) **capsule** is a fibrous tube of tissue that encloses the joint, best seen laterally in *Figure 14-23* and medially in *Figure 14-24*. It is fairly thin, except laterally, where the thicker **lateral**



**FIGURE 14-23.** Fibrous capsule surrounding the TMJ is shaded *green*, and the thickened outer **lateral ligament** is shaded *red*. (Reproduced from Clemente CD, ed. *Gray's anatomy of the human body*. 30th ed. Philadelphia, PA: Lea & Febiger, 1985:339, with permission.)



**FIGURE 14-24.** Ligaments of the temporomandibular joint limit mandibular movement:

The **fibrous capsule** (capsular ligament) shaded *green* surrounds the joint, the **stylomandibular ligament** (*red*) connects the styloid process of the temporal bone to the posterior surface of the mandible near the angle, and the **sphenomandibular** (or spino-mandibular) ligament (*yellow*) connects the spine of the sphenoid bone with the medial surface of the mandible near the lingula (tongue-like process) adjacent to the mandibular foramen. (Reproduced from Clemente CD, ed. *Gray's anatomy of the human body*. 30th ed. Philadelphia, PA: Lea & Febiger, 1985:339, with permission.)

(formerly temporomandibular) ligament is located.<sup>13</sup> The upper border of the capsule is attached to the temporal bone around the circumference of the articular fossa and the articular eminence. The lower border is attached around the neck of the condyloid process, thus enclosing the condyle and completing the tube.

The internal surface of the fibrous capsule is lined with a **synovial membrane** that surrounds the bones and their articulating surfaces. This thin membrane secretes a fluid, **synovial fluid**, which lubricates the joint. This fluid is three times more slippery than ice. The synovial fluid both lubricates and nourishes the fibrous covering of the articulating surfaces and center of the disc that lack a blood supply. In a normal joint space, there is only a small amount of fluid (one or two drops).

The articular disc is not attached to the skull, but anteriorly it is attached to the fibrous capsule. Posteriorly, the disc and the capsule are connected by a thick pad of loose elastic vascular connective tissue called the **bilaminar zone** (Fig. 14-21). Laterally and medially, each disc is tightly attached to the lateral and medial sides of the mandibular condyle but not to the capsule. Therefore, the disc can follow the movement of the condyle when the muscles (*lateral pterygoid muscles* attached to the neck of the condyle and the discs) move the mandible and discs forward. This design of attachments gives each disc freedom to move anteriorly but limits it from excessive forward movement that could result in its displacement anterior to the head of the condyle.<sup>14</sup> The anterior part of this fibrous capsule prevents excessive movement of the condyle of the mandible on wide openings as it becomes taut.

## 2. LATERAL LIGAMENT (FORMERLY TMJ LIGAMENT)

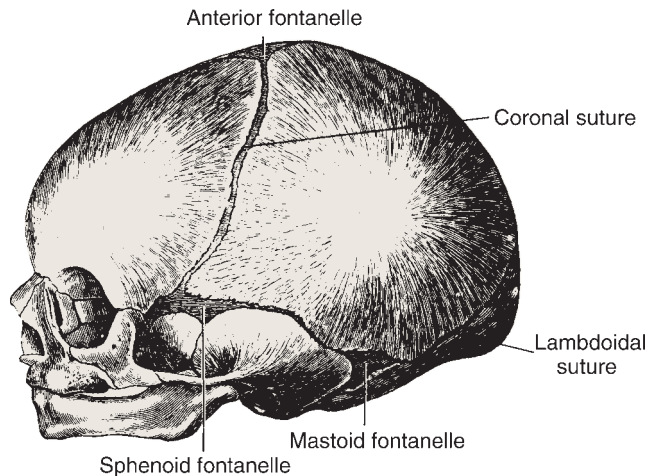
The outer layer of the fibrous capsule is a thicker layer of fibrous tissue that is reinforced by accessory ligaments, which strengthen it. The **lateral ligament** of this joint is the strong reinforcement of the anterior lateral wall of the capsule (Fig. 14-23). It attaches to the zygomatic arch and is directed obliquely down and posterior to the lateral and posterior neck of the condyle. This ligament keeps the condyle close to the fossa and helps to prevent lateral and posterior displacement of the mandible. It has no counterpart medially, and seemingly none is needed since the right and left temporomandibular articulations work together as a unit. The lateral ligament on the opposite side, by failing to stretch, prevents excess medial displacement on the side moving medially.

## 3. STYLOMANDIBULAR LIGAMENT

The **stylomandibular** [STY lo man DIB yoo lar] ligament is posterior to the joint but also gives support to the mandible (Fig. 14-24). It is relaxed when the mouth is closed but becomes tense on extreme protrusion of the mandible.<sup>13</sup> It is attached above to the styloid process of the temporal bone and below to the posterior border and angle of the mandible.

## 4. SPHENOMANDIBULAR LIGAMENT

The **sphenomandibular** [SFE no man DIB yoo lar] ligament is medial to the joint (Fig. 14-24). It gives some support to the mandible and may help limit maximum opening of the jaw. It is attached superiorly to the



**FIGURE 14-25.** Skull at birth shows fontanelles (membrane-covered openings between bones). Notice that the mandibular condyle is barely higher than the crest of the mandibular ridge.

angular (sphenoidal) spine of the sphenoid bone and fans out inferiorly to attach on the lingula of the mandible near the mandibular foramen.

### C. DEVELOPMENT OF THE TEMPOROMANDIBULAR JOINT

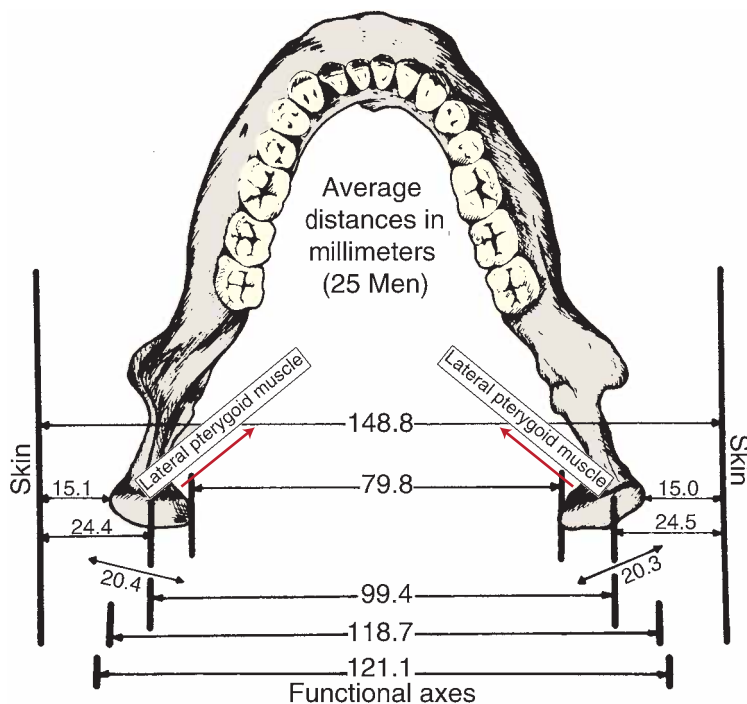
In infants, the articular fossa, the articular eminence, and the condyle are rather flat. This flatness allows for a wide range of sliding motions in the TMJ. Also, this

joint is at about the same level as the occlusal plane at birth with relatively no ramus height (Fig. 14-25). During growth, the articular fossa deepens, the articular eminence becomes prominent, the condyle becomes rounded, and the shape of the disc changes to conform to the change in shape of the fossa and condyle. There is also a lengthening of the ramus. The condyle contains cartilage beneath its surface, and the condyloid process and ramus lengthen until a person is 20 to 25 years old. As a result of growth in the condyle area, the body of the mandible is lowered from the skull, and the occlusal plane is located about 1 in. below the level of the condyles in an adult.

### D. ADVANCED TOPICS: DIMENSIONS RELATED TO THE TMJ

The average width of the condyle and its depth beneath the skin is illustrated in Figure 14-26. The condyle is a large solid structure, about 10 mm thick anteroposteriorly and 20.4 mm wide mediolaterally. Although the average depth of the outer surface of the condyle is 15 mm beneath the skin, it is readily palpated, and its movements are visible (seemingly just beneath the skin) when eating. Research by Drs. Woelfel and Igarashi on 25 men found the average depth of the outer surface of the mandibular condyle on each side to be 15.0 mm; the range was 10.3 to 21.4 mm beneath skin.

The size of the mandibular fossa averages about 23 mm mediolaterally and extends 15 mm posteriorly from the



**FIGURE 14-26.** Depth (beneath the skin) of the landmarks of the head of the mandibular condyle, and relative **direction of the lateral pterygoid muscle fibers** (red arrows) from the insertion on the neck of the condyle toward the origin (not seen, but on the lateral surface of the lateral plate of the sphenoid bone). (To obtain these measurements, metal markers were placed on the skin and some teeth on 25 men prior to taking submental vertex cephalometric radiographs for analysis, tracing, and measuring. The location of the center of rotational opening of the mandible [the hinge axis] was found to pass through or near the center of the heads of the condyles. The functional axes were determined from pantographic recordings. Resultant articular settings were found to be wider than the outer poles of the condyles. This means that lateral and protrusive excursions are controlled by ligaments and muscles, rather than by bone, as previously reported. This research was conducted by Drs. Woelfel and Igarashi and supported by the Ohio State University College of Dentistry and Nihon University School of Dentistry in Tokyo.)

eminence. The intracapsular surface area is two to three times greater than on the very mobile mandibular condyle. The anterior part of the capsule that surrounds the entire mandibular fossa and articular eminence attaches 10 mm in front of the crest of the articulating eminence.<sup>11</sup>

### LEARNING EXERCISE

Study a skull and see how the mandibular condyle fits into the mandibular fossa. When you examine the fit, notice the space between the mandibular condyles and the articular fossae when the posterior teeth are in tight occlusion. This space is where the disc would have been in life.

On yourself, palpate the TMJ and feel the movement of the mandibular condyle. First, put your index fingers immediately in front of either ear opening and open and close your mouth.

### Learning Exercise, cont.

Notice that when you open and close the mandible just a little, you feel little movement of the condyles, whereas when you open the mandible wide, you feel more movement. This happens because during minimal opening the condyles only rotate within the articular fossa, but when we open wide, the entire mandible moves bodily (translates) forward and downward as the condyles are pulled forward over the articular eminence. Next, move your jaw to the right and left sides. You are feeling the movement of the outer (lateral) surface of each mandibular condyle. Finally, place your little finger gently inside either ear opening, then open and close your mouth and pull your jaw back or posteriorly. You are feeling the upper and posterior portion of the mandibular condyle, especially when you close or retrude (pull back) your mandible.

## Review Questions

Select the one best answer.

- What two structures articulate with the disc in the TMJ?
  - The coronoid process of the mandible and the mandibular fossa of the temporal bone
  - The condyloid process of the mandible and the mandibular fossa of the temporal bone
  - The coronoid process of the mandible and the mandibular fossa of the sphenoid bone
  - The condyloid process of the mandible and the mandibular fossa of the sphenoid bone
  - The condyloid process of the mandible and the mandibular fossa of the maxillae
- The ligament that limits the amount of movement of the mandible and attaches from the inferior surface of the neurocranium to the lingula of the mandible is the
  - Lateral (TMJ) ligament.
  - Stylomandibular ligament.
  - Sphenomandibular ligament.
  - Sternocleidomastoid ligament.
- Where on the temporal bone does the mandible function?
  - In the anterior three quarters of the mandibular fossa called the articular fossa
  - In the posterior quarter of the mandibular fossa called the articular fossa
  - On the posterior inferior portion of the articular eminence
  - On the anterior inferior position of the articular eminence

ANSWERS: 1—b, 2—c, 3—c



## SECTION III

## MUSCLES OF THE MOUTH

## OBJECTIVES

The objectives for this section are to prepare the reader to perform the following:

- Identify the four pairs of major muscles of mastication.
- Describe and identify the origin and insertion of each of these muscles of mastication on a skull and be able to palpate each (if possible) on yourself or a partner.
- Describe and demonstrate the function of each of these muscles.
- List other factors that contribute to the position of teeth and movement of the mandible.
- Describe the location and list the functions of the groups of muscles that contribute to facial expression.

The following general terms relate to muscles and will be helpful to know as you read this section:

**Anguli** [AN gyoo lie]: triangular area or angle of a structure

**Depressor**: acts to depress or make lower

**Insertion of the muscles of mastication**: place of attachment of muscles to the bone that moves, such as muscle attachments on the movable mandible

**Labial** [LAY bee al]: related to, or toward, the lips; like the labial surface of a tooth

**Levator** [le VA tor]: acts to raise (compare *elevator*)

**Lingual** [LIN gwal]: related to the tongue; for example, the lingual nerve innervates the tongue; the lingual muscle is within the tongue; and the lingual surface of a tooth is the side toward the tongue

**Mental**: referring to the chin; the mental foramen is the hole in the mandible where the mental nerve passes out of the mandible to the chin; the mentalis muscle inserts into the chin<sup>1</sup>

**Orbicularis** [or BIK u lar is]: round; compare an *orbit*

**Origin (of a muscle of mastication)**: is the source, beginning or fixed proximal end attachment of a muscle as compared to its insertion, which is a muscle's more movable attachment or distal end<sup>1</sup>

**Oris**: referring to the edge of the mouth; compare *oral*

**Procerus** [pro SE rus]: long and slender

The muscles of the body contribute 40 to 50% of the total body weight.<sup>15</sup> Muscles produce the desired action by pulling or by shortening, never by pushing or by lengthening. Skeletal or voluntary muscles are made up of specialized cells that contract. Skeletal muscles are very active metabolically and therefore require a rich blood supply.<sup>15</sup> There are two other kinds of muscles, cardiac and smooth (involuntary) muscles, which we are unable to control or direct.

Individual muscle cells are small, elongated contractile fibers, each enclosed in a delicate envelope of loose connective tissue. Many individual parallel mus-

cle fibers make up a bundle, and various numbers of bundles comprise a muscle. The longest muscle fibers are 300 mm (11.4 in.) long. Each contractile bundle of cells can contract about 57% of its fully stretched length.<sup>16</sup> The all-or-none law states that any single muscle fiber always contracts to its fullest extent.<sup>11</sup> When a weak effort or contraction is required of the whole muscle, then only a few fibers contract (each to the fullest extent). Many fibers contracting produce greater power as needed. No single muscle acts alone to produce a movement or to maintain posture. Many muscles must work in perfect coordination to produce a steady, well-directed motion of a body part.

When a muscle becomes shorter as it moves a structure, the movement is called an isotonic contraction. When a muscle maintains its length as it contracts to stabilize a part, this movement is called isometric contraction. As you close your jaw until all teeth contact, the closing muscles work isotonicly because they become shorter as the mandible moves superiorly. If you maintain contact of all of your teeth but squeeze them together hard, these same muscles are contracting isometrically because they cannot shorten any more once your teeth are together.

A few or more individual muscles fibers of all of our voluntary muscles are continually or alternately contracting during consciousness. This minimal amount of contraction needed to maintain posture is called muscle tone or tonus, and the muscles involved are named “antigravity” muscles. As you read this, the muscles of mastication are probably in a state of minimal tonic contraction or balance with each other, with the neck muscles, and with gravity, enabling a comfortable, restful position for your mandible with the teeth apart. This normal resting jaw position varies slightly according to whether you are sitting, lying on your back, or standing up, and depending on how tense or stressed you are. When you fall asleep at your desk, antigravity muscles relax and, as you may have seen on others, the mouth drops open.

## A. MUSCLES INVOLVED IN MASTICATION (CHEWING)

Muscles of mastication or chewing move the mandible. They include four pairs of muscles (right and left): masseter, temporalis, medial pterygoid, and lateral pterygoid muscles. These muscles have the major control over the movements of the mandible. Each of these muscles has one end identified as its origin and the other end identified as its insertion. The **origin end** of each of the muscles of mastication is the source, beginning, or fixed proximal attachment located, in this case, on the bones of the neurocranium that are relatively immovable. The **insertion end** is the attachment on the movable bone that for each of these muscles is attached to, and moves, the mandible.

There are five different ways in which the mandible moves. We can **elevate** it (closing the mouth), **depress** it (opening the mouth), **retrude** (retracting or pulling back the mandible), **protrude** it (protracting or moving the mandible anteriorly), and move it into **lateral excursions** (moving the mandible sideways, as when chewing).

### 1. MASSETER MUSCLE

The **masseter** [ma SEE ter] muscle (Fig. 14-27) is the most superficial, bulky, and powerful of the muscles of mastication. It is four sided in shape. Its average volume is over twice that of the medial pterygoid

muscle (on 25 males is  $30.4 \pm 4.1 \text{ cm}^3$ , which is 2.6 times larger than the medial pterygoid muscle at  $11.5 \pm 2.1 \text{ cm}^3$ ).<sup>17</sup>

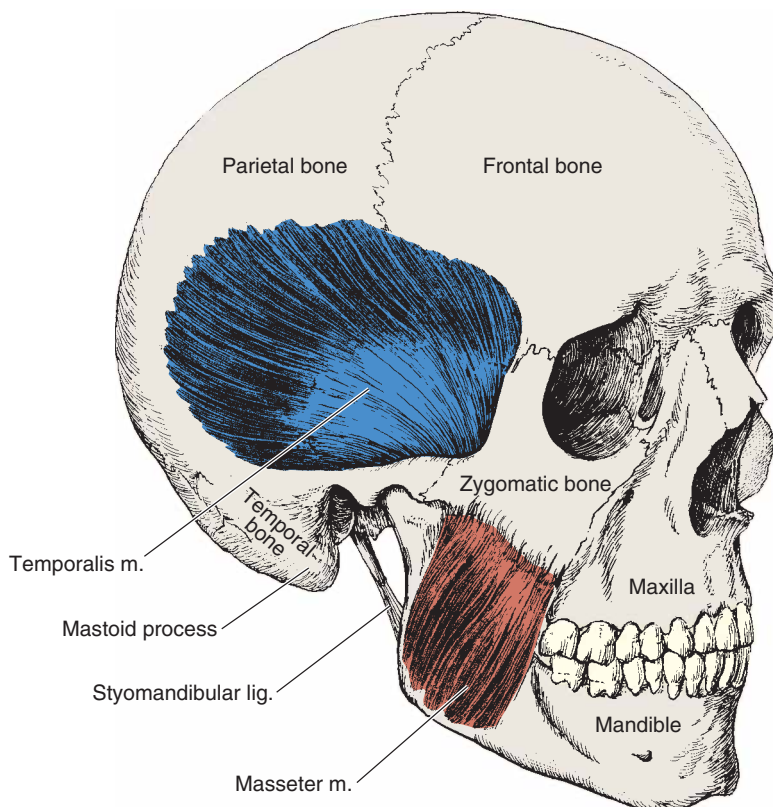
**Origin:** The masseter arises from the inferior and medial surfaces of the *zygomatic arch* that is made up of the zygomatic bone, the zygomatic process of the maxilla, and the temporal process of zygomatic bone (seen in Fig. 14-28). From here, it extends inferiorly and posteriorly toward its insertion.

**Insertion:** The masseter inserts on the inferior lateral surface of the ramus and *angle of the mandible* (Fig. 14-28).

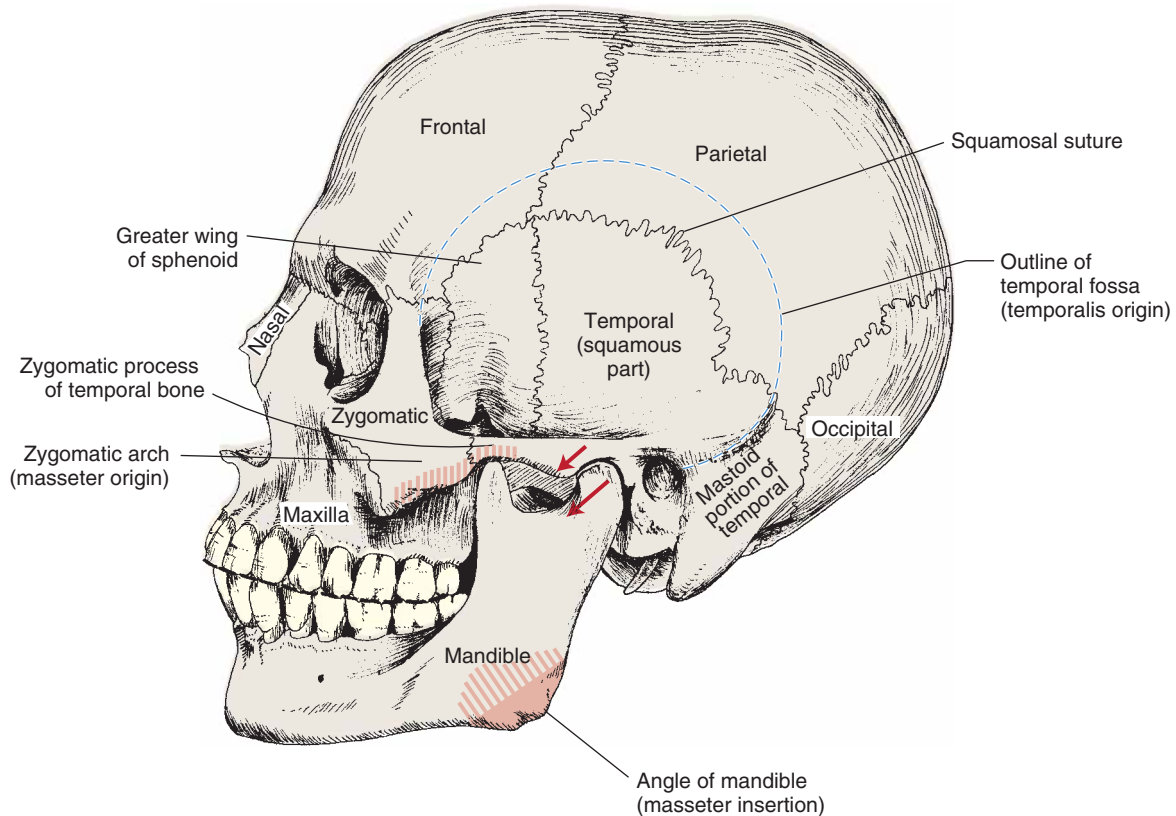
**Action:** It elevates the mandible (closes the mouth) and applies great power in crushing food.<sup>6,8,9</sup>

### LEARNING EXERCISE

As you clench your teeth several times, feel the contraction of the masseter by placing a finger on the outside of your cheek posterior to the third molar region. The muscle will produce a noticeable bulge beneath your finger each time. The part felt just inferior to the cheekbone (anterior to the ear lobe) is near the origin, and the bulge felt over the angle of the mandible is near the insertion.



**FIGURE 14-27.** Masseter muscle (shaded red) and fan-shaped temporalis muscle (shaded blue). (Reproduced from Clemente CD, ed. Gray's anatomy of the human body. 30th ed. Philadelphia, PA: Lea & Febiger, 1985:450, with permission.)



**FIGURE 14-28.** Human skull, left side, showing location of some **attachments of the temporalis (outlined in blue) and masseter muscles (shaded red)**. This lateral view shows the origin of the fan-shaped temporalis muscle (within the shallow temporal fossa outlined with a *blue dotted line*), and the origin of the masseter (light red area on the zygomatic arch) as well as the insertion of the masseter muscle light red area on the (lateral surface of the angle of the mandible). The *red arrows* indicate the slope of the posterior surface of the articular eminence and the subsequent downward (opening) movement of the mandible when it is pulled forward by both lateral pterygoid muscles.

## 2. TEMPORALIS MUSCLE

The **temporalis** [tem po RA lis] muscle is a fan-shaped, large but flat muscle with both vertical anterior (and middle) fibers and more horizontal posterior fibers. Vertical and horizontal fibers are shaded darker in *Figure 14-29*.

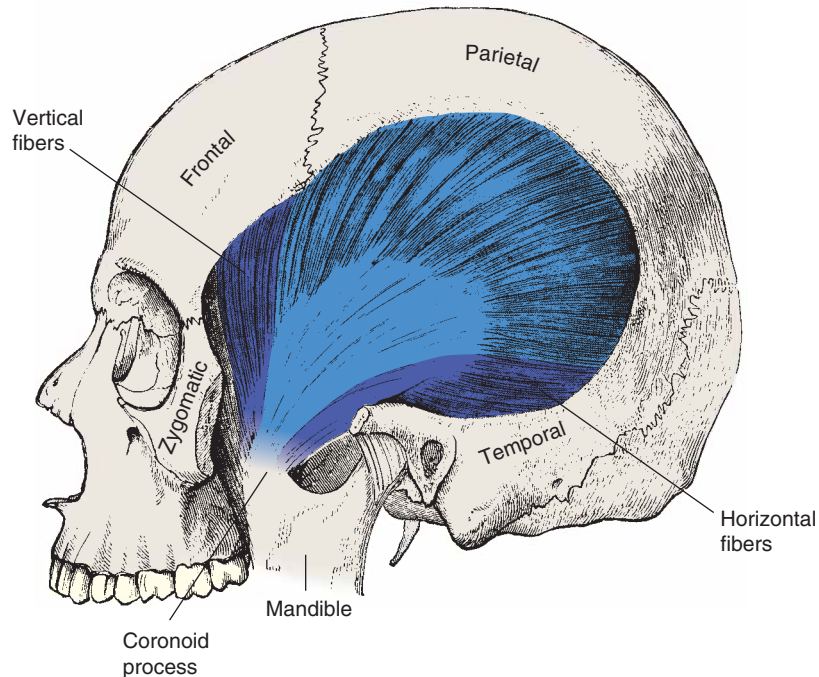
**Origin:** The temporalis arises from the entire *temporal fossa* (*Fig. 14-28*) (composed of the squamous part of temporal bone, the greater wing of the sphenoid bone, and the adjacent portions of the frontal and parietal bones). From here, its **anterior** (and middle) fibers are directed vertically downward while its **posterior fibers** are directed more horizontally, mostly anteriorly and somewhat inferiorly, passing medial to the zygomatic arch.

**Insertion:** The temporalis inserts on the coronoid process of the mandible, the medial surface of the *anterior border* of the ramus, and the *temporal crest* of the mandible (*Fig. 14-30*) via one common tendon.

**Action:** The *anterior* (and middle) *vertical* fibers contract to act to **elevate** the mandible (close the jaw) especially when great power is not required, and the *posterior horizontal* fibers **retrude** or pull the mandible posteriorly.<sup>6,8,9</sup> This muscle can position the mandible (slightly more anteriorly or more posteriorly) while also closing the teeth together.

### LEARNING EXERCISE

Feel contraction of the origin of the temporalis by placing several fingers above and in front of your ear to feel the vertical fibers contract as you firmly close your teeth together several times. Then feel the nearly horizontal fibers just above and behind your ears contract as you retrude or pull your mandible posteriorly. This may be more difficult to feel since the bulge is less evident.

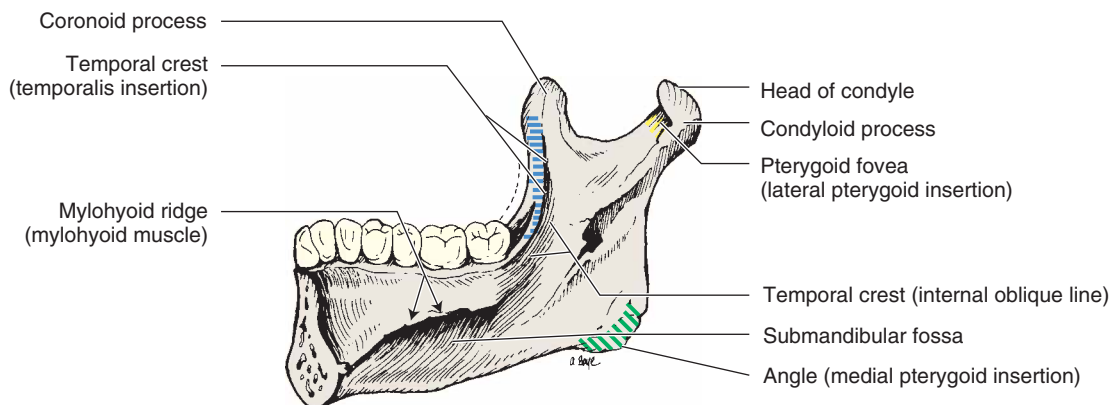


**FIGURE 14-29.** **Temporalis muscle:** some vertical (anterior) and horizontal (posterior) fibers are shaded *purple*. The zygomatic process of the temporal bone and temporal process of the zygomatic bone have been removed. When studying this drawing, you should understand why the contraction of the anterior, vertically oriented fibers of the temporal muscle acts to close the jaw, while contraction of the posteriorly positioned, horizontally oriented fibers acts to pull the jaw back or to retract (retrude) the mandible. (Reproduced from Clemente CD, ed. Gray's anatomy of the human body. 30th ed. Philadelphia, PA: Lea & Febiger, 1985:449, with permission.)

### 3. MEDIAL PTERYGOID MUSCLE

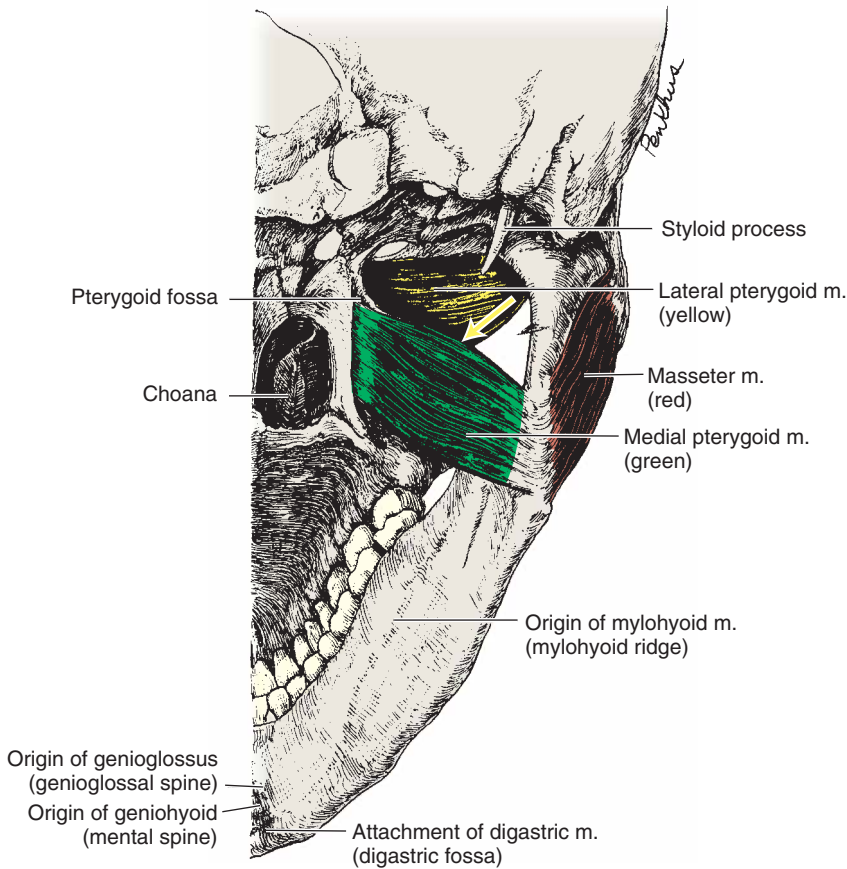
The **medial pterygoid** [TER i goid] muscle is located on the medial surface of the ramus (Figs. 14-31 and 14-32). Along with the masseter located on the lateral

surface, these two muscles serve as a sling with the medial pterygoid attached on the medial side and the masseter attached on the lateral side of the angle of the mandible. They have similar actions.

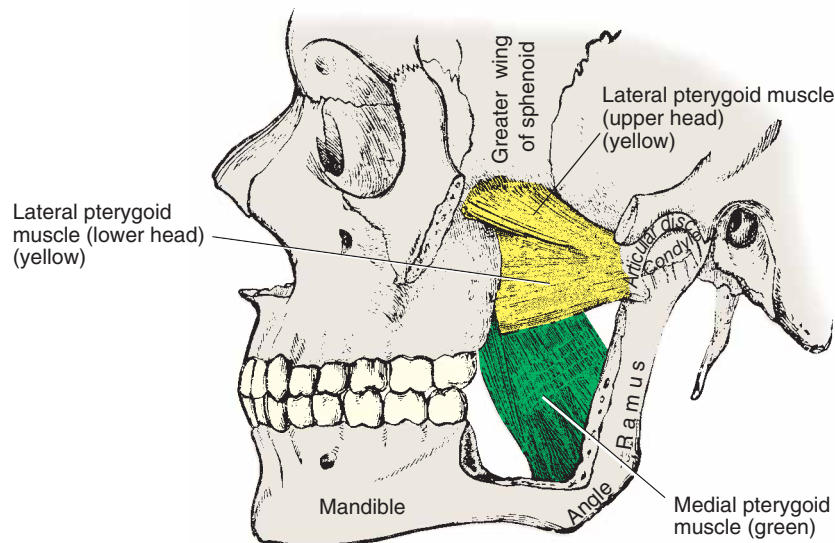


**FIGURE 14-30.** Mandible, medial surface, with the location of the **muscle insertions** of the temporalis, medial pterygoid, and lateral pterygoid muscles: The insertion of the **temporalis muscle** (*blue*) is located on the anterior medial ridge (temporal crest) of the mandibular ramus. The insertion of the **medial pterygoid muscle** (*green*) is on the internal surface of the angle of the mandible. The insertion of the **lateral pterygoid muscle** (*yellow*) is on the anterior surface of the neck of the condyle in the pterygoid fovea (as well as the articular disc, which is not shown).





**FIGURE 14-31.** The skull from the inferior view shows the medial pterygoid and masseter muscles, as well as the lateral pterygoid muscle. Note how the **medial pterygoid muscle** (shaded *green*) and **masseter muscles** (*red*) form a sling that supports the mandible. Also, from this view, it is clear that the **lateral pterygoid muscle** (*yellow*) has its origin (on the base of the cranium) more medial than its insertion (on the anterior portion of the neck of the condyle, and the articular disc). If this muscle contracts only on the right side as shown by the *arrow*, that condyle of the mandible moves toward its origin, thus bodily moving the mandible toward the left or opposite side. (Reproduced from Clemente CD, ed. Gray's anatomy of the human body. 30th ed. Philadelphia, PA: Lea & Febiger, 1985:452, with permission.)



**FIGURE 14-32.** A lateral view of two heads of the **lateral pterygoid muscle** (shaded *yellow*) and the **medial pterygoid muscle** (shaded *green*) with the zygomatic arch and the anterior part of the ramus removed. The **upper head of the lateral pterygoid muscle** has its *origin* on the infratemporal surface of the sphenoid bone, and the **lower head** has its origin on the lateral surface of the lateral pterygoid plate of the sphenoid bone (covered by the muscle in this drawing). The *insertion* of both heads of the lateral pterygoid muscle is on the fovea of the neck of the condyle of the mandible and on the articular disc. Notice the horizontal orientation of the lateral pterygoid fibers in direct contrast to the vertical direction of the medial pterygoid fibers. Simultaneous contraction of both lateral pterygoid muscles guides the condyles (and discs) forward, which causes the mandible to protrude and the mouth to open. Contraction of the medial pterygoid muscle in harmony with the masseter elevates the mandible (closes the mouth). (Reproduced from Clemente CD, ed. Gray's anatomy of the human body. 30th ed. Philadelphia, PA: Lea & Febiger, 1985:451, with permission.)

**Origin:** The medial pterygoid muscle arises mainly from the *medial surface of the lateral pterygoid plate* and the *pterygoid fossa* between the medial and lateral pterygoid plates (right side of the drawing in Fig. 14-33) of the sphenoid bone. (Also, there are fibers attached to the posterior surface of the maxillae and to the adjacent vertical processes of the palatine bones, and to the maxillary tuberosity.<sup>3</sup>) Similar to the masseter, the fibers pass from their origin inferiorly and posteriorly (but laterally) toward their insertion.

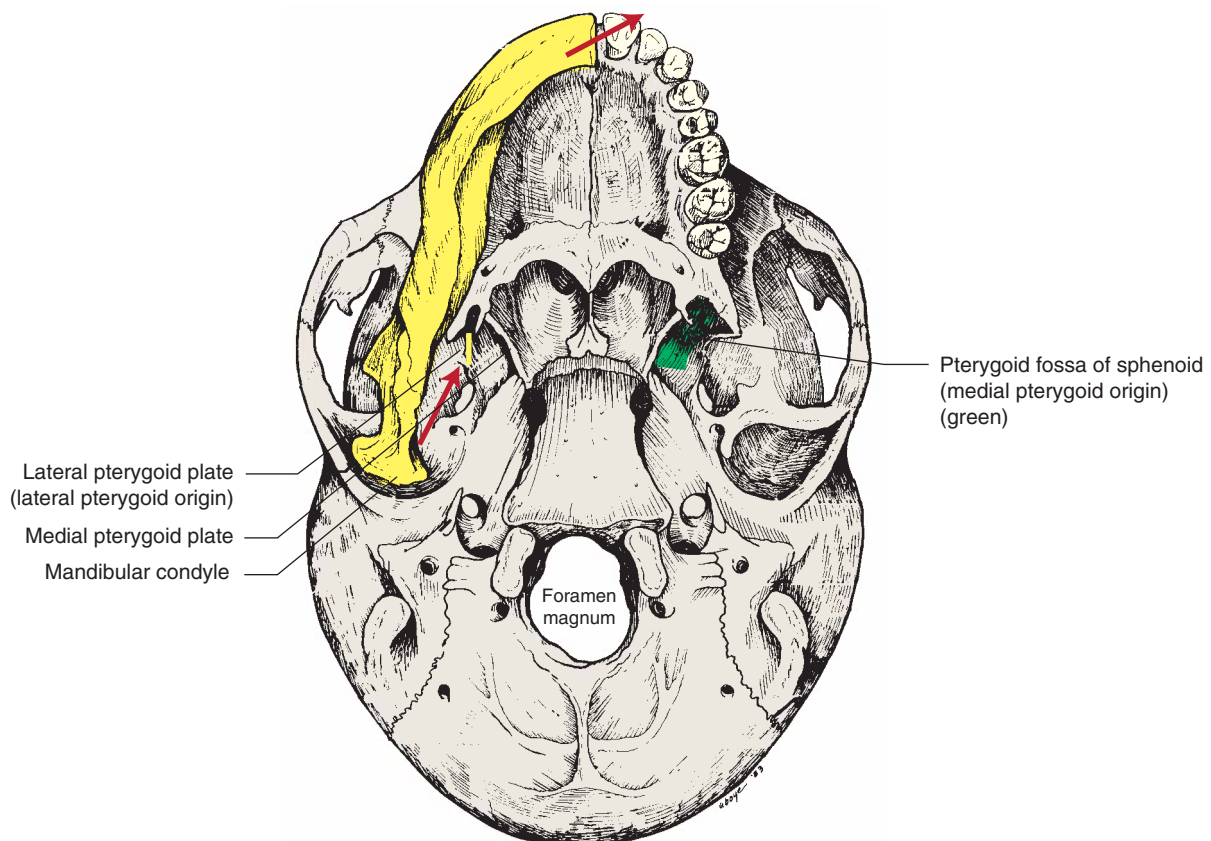
**Insertion:** The medial pterygoid muscle inserts on the *medial surface* of the mandible in a triangular region at the *angle* and on the adjacent portions of the ramus just above the angle (Fig. 14-30).

**Action:** It *elevates* the mandible (closes jaw) like the masseter and the anterior (and middle) fibers of the temporalis muscles. Although not as large or powerful,

it works together with the larger masseter muscle in helping to apply the power or great force upon closing the teeth together.

### LEARNING EXERCISE

Attempt to palpate the insertion of the medial pterygoid muscle in your mouth by bending the head forward to relax the skin on the neck, and placing the forefinger medial to the internal angle of the mandible while gently pressing your finger upward and outward. When the teeth are squeezed together, you should feel the bulge of this muscle.



**FIGURE 14-33.** Human skull, inferior surface, showing the location of the origin of the lateral pterygoid muscle (*yellow line*) and the origin of the medial pterygoid muscle in the pterygoid fossa (*green*): Only half of the mandible (shaded *yellow*) is shown, on the left side of the drawing. As you study this drawing, notice the *arrow* that connects the *insertion* of the lateral pterygoid muscle (on the **anterior neck of the condyle of the mandible**) with its *origin* (on the **lateral surface of the lateral pterygoid plate** denoted by a *yellow line*). When only one lateral pterygoid muscle contracts and pulls the insertion end toward its origin, the mandible moves medially, toward the opposite side, as shown by the *second arrow* near the anterior part of the mandible. The location of the *origin* of the **medial pterygoid muscle** is shaded *green* on the right side of the drawing in the pterygoid fossa.

#### 4. LATERAL PTERYGOID MUSCLE

The **lateral pterygoid muscle**, unlike the other three pairs of muscles where most fibers are oriented primarily vertically, has its fibers aligned mostly horizontally (Fig. 14-32). The lateral pterygoid muscle is a short, thick, somewhat conical muscle located deep in the infratemporal fossa (inferior to the temporal bone and posterior to the maxillae) and is the prime mover of the mandible except for closing the jaw.

**Origin:** The lateral pterygoid muscle arises from two heads, both located on the sphenoid bone. The smaller superior head is attached to the *infratemporal surface of the greater wing* of the sphenoid bone; the larger inferior head is attached to the adjacent *lateral surface of the lateral pterygoid plate* on the sphenoid bone (Figs. 14-32 and 14-34). Fibers pass posteriorly and laterally in a horizontal direction toward their insertion. When viewed from below, the direction of these fibers from their insertion on the anterior surfaces of the mandibular condyles is represented by the arrow in Figure 14-33.

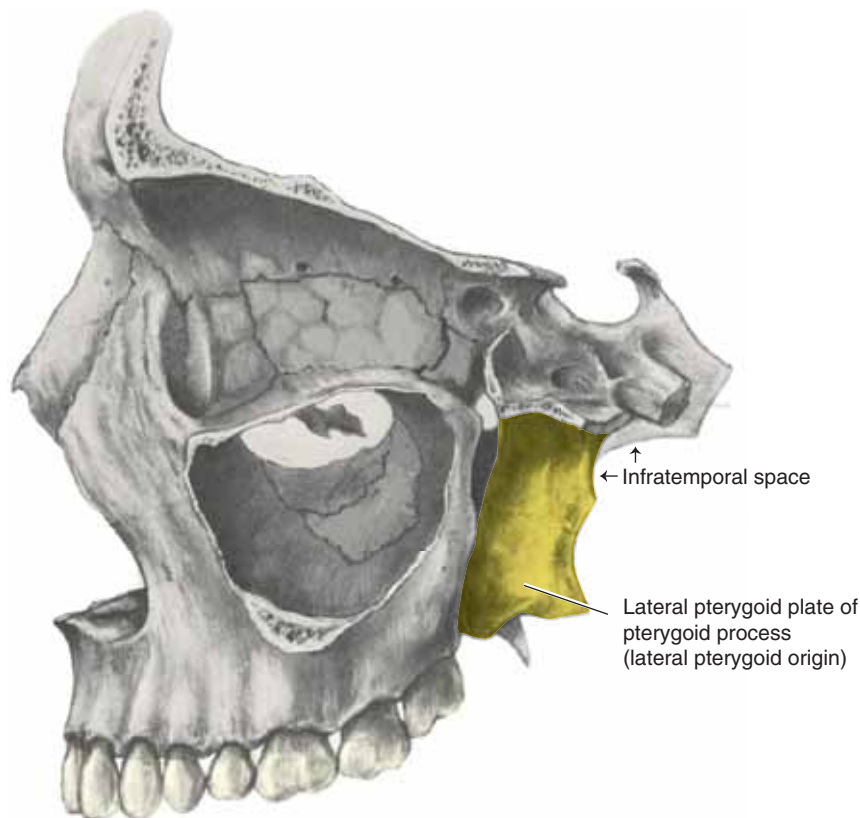
**Insertion:** The lateral pterygoid muscle inserts on the depression on the front of the neck of the condyloid process called the *pterygoid fovea* (Fig. 14-30) and into the anterior margin of the *articular disc*. Minor forward contractions of the upper head pulling the disc forward work in concert with the stretching of the elastic band of

tissues behind the disc (retrodiscal tissues) and permit the disc to accompany the mandible as it moves forward, preventing posterior displacement of the disc.<sup>14</sup>

**Actions:** When both lateral pterygoids contract simultaneously, the action is

- to **protrude** the mandible. No other muscle or groups of muscles are capable of doing this but can only assist in this action as stabilizers or by controlling the degree of jaw opening during the protrusion.<sup>5,6,8,9,18</sup>
- to **depress** the mandible. The lateral pterygoids do this by pulling the articular discs and the condyles forward and down onto the articular eminences, which moves the mandible inferiorly and helps rotate it, thereby opening the mouth (illustrated by arrows in Figure 14-28 that indicate the incline of the articular eminence and the same downward direction that condyles and the mandible take when pulled forward under the bump of the eminence). The lateral pterygoids are assisted somewhat in this task by groups of muscles in the neck attached from the mandible to the hyoid bone (called the suprahyoid muscles) and from the hyoid bone to the clavicle and sternum called the infrahyoid muscles.

When only one lateral pterygoid contracts, it pulls the condyle on that side toward the midline (medially)



**FIGURE 14-34.** Part of human skull, lateral view, has the lateral wall of the maxilla removed to expose the maxillary sinus. Posterior to the maxilla, note the location of the *origin* of the two heads of the **lateral pterygoid muscle**: the lateral surface of the **lateral pterygoid plate** (shaded yellow) just posterior to the maxilla and the roof of the **infratemporal space** on the base of the cranium. (Reproduced from Clemente CD, ed. Gray's anatomy of the human body. 30th ed. Philadelphia, PA: Lea & Febiger, 1985:166, with permission.)

and anteriorly, moving the body of the mandible and its teeth toward the opposite side (since the origin of the lateral pterygoid muscle is medial to its insertion as seen by the arrow in Figure 14-33). For example, contraction of the *right* lateral pterygoid muscle draws the right condyle medially (to the left) and forward, causing the mandible to move toward the left side (into **left lateral excursion**). Conversely, the contraction of the *left* lateral pterygoid muscle causes the mandible to move to the right side (**right lateral excursion**).<sup>8</sup> No other muscle is capable of moving the mandible sideways, although synergistic (in harmony with) unilateral contraction of the posterior fibers of the temporalis muscle occurs on the side toward which the jaw moves.<sup>8</sup>

### LEARNING EXERCISE

Viewing the inferior surface of a skull with a movable mandible, imagine elastic bands attached from the location of the origins to the insertions of the lateral pterygoid muscles, right and left sides. Since the origin on the base of the skull stays stationary, but the mandible at the insertion attachment can move, confirm that the mandible moves anterior and inferior if both elastic bands were contracted (shortened). Next, see what would happen if only one band was shortened (contracted). If only the right side is shortened, the right condyle moves medially (to the left), closer to its origin on the lateral pterygoid plate, so the body of the mandible and its teeth also move toward the left side. Practice this until you understand why the jaw moves the way it does when one lateral pterygoid muscle works. Next, attempt to palpate the origin of the lateral pterygoid muscle in your mouth. Slip a clean little finger into your mouth along the lateral surface of the maxillary alveolar process. Then gently move the finger posteriorly and medially, around to the posterior surface of the maxilla, and superiorly toward the lateral surface of the lateral pterygoid plate where the lateral pterygoid muscle attaches. Moving the mandible toward the side you are palpating will give your finger more room to reach the muscle. This palpation may be slightly uncomfortable.

### B. OTHER MUSCLES AFFECTING MANDIBULAR MOVEMENT

Other muscles affecting mandibular movement include the suprahyoid and infrahyoid group of muscles. The suprahyoid [SOO prah HI oid] muscle group extends superiorly from the hyoid bone to the mandible,

whereas the infrahyoid muscle group extends inferiorly from the hyoid bone to the clavicle (collarbone) and sternum (breastbone) and adjacent structures (Fig. 14-35). The inferior hyoid muscles must stabilize the hyoid bone and keep it from rising, so when the suprahyoid muscles contract, they can move the mandible and not just move the hyoid bone. These muscle groups act together with both lateral pterygoid muscles to help depress the mandible (open the mouth) and act with the posterior (horizontal) fibers of the temporalis muscles to retrude (pull back) the mandible.

The *suprahyoid muscles* include the **stylohyoid** [STY lo HI oid] muscles (which arise on the styloid process), **digastric** [di GAS trik] (the anterior belly of the digastric attaches in the digastric fossa near the genial spines or tubercles), **mylohyoid** (arising from the mylohyoid ridges on each half of the medial surface of the mandible and found in the tissue that forms the floor of the mouth), and **geniohyoid** [JEE ni o HI oid] (arising from the genial tubercles). The *infrahyoid muscles* include the **omohyoid**, **sternohyoid**, **sternothyroid**, and **thyrohyoid**.

Another neck muscle, the **sternocleidomastoid**, attaches from the mastoid process of the temporal bone to the sternum (breastbone) and clavicle (collarbone). The area around this muscle is palpated during a cancer-screening exam since the chain of cervical (neck) lymph nodes surrounds this muscle (Fig. 14-35).

### C. OTHER FACTORS AFFECTING TOOTH POSITION OR MOVEMENT

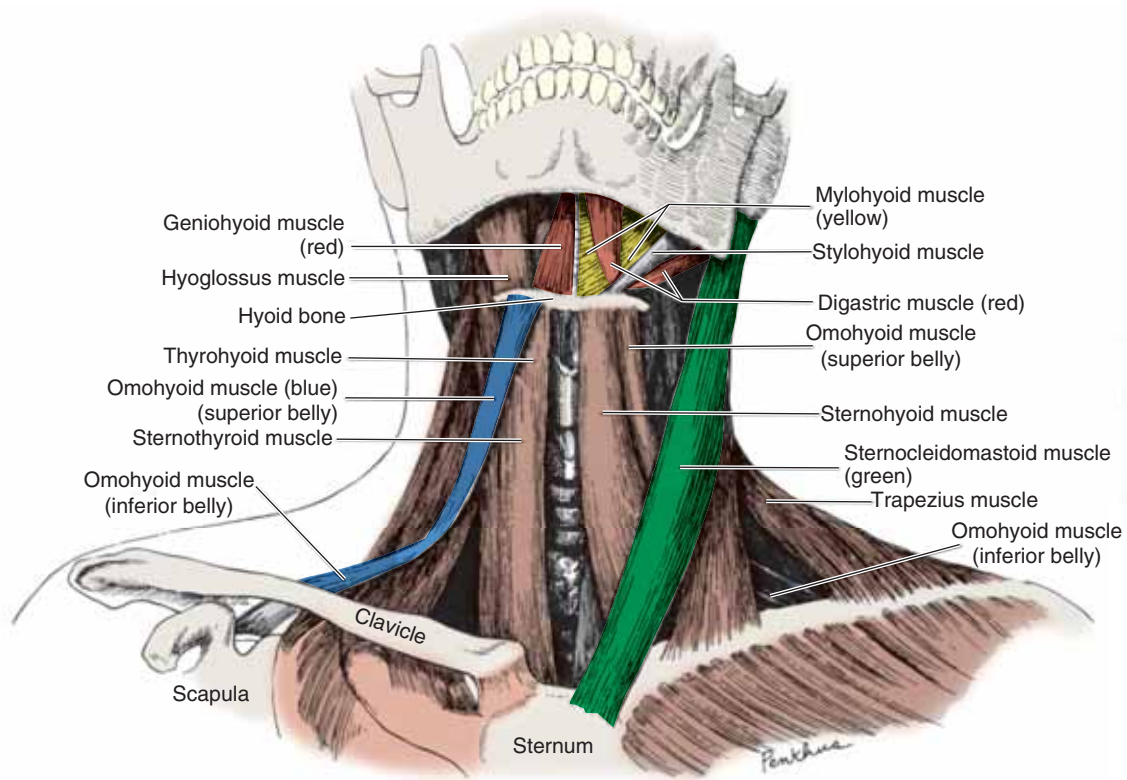
Other factors affecting relative tooth positions and movements include the ligaments, fascia, and, to a certain extent, the muscles of facial expression. The **ligaments**, including the capsular, temporomandibular, stylomandibular, and sphenomandibular ligaments (recall Figs. 14-23 and 14-24), provide some limits to protrusive, lateral, and opening movements of the mandible.

**Fascia** [FASH e ah] is also thought to limit movement of the mandible to some extent. Fascia is connective tissue that forms sheets or bands between anatomic structures. It attaches to bones and surrounds muscles, glands, vessels, nerves, and fat.

Some *muscles of facial expression* (especially in the lips and cheeks) and the tongue muscles are thought to influence development, position, and shape of the dental arches. The muscles of facial expression are shown in Figure 14-36 and include the following:

- **Orbicularis oris** [or BIK u LAR is O ris] is located within the lips around the opening of the mouth and acts to close or purse the lips (as around a straw or around a saliva ejector within the dental office).





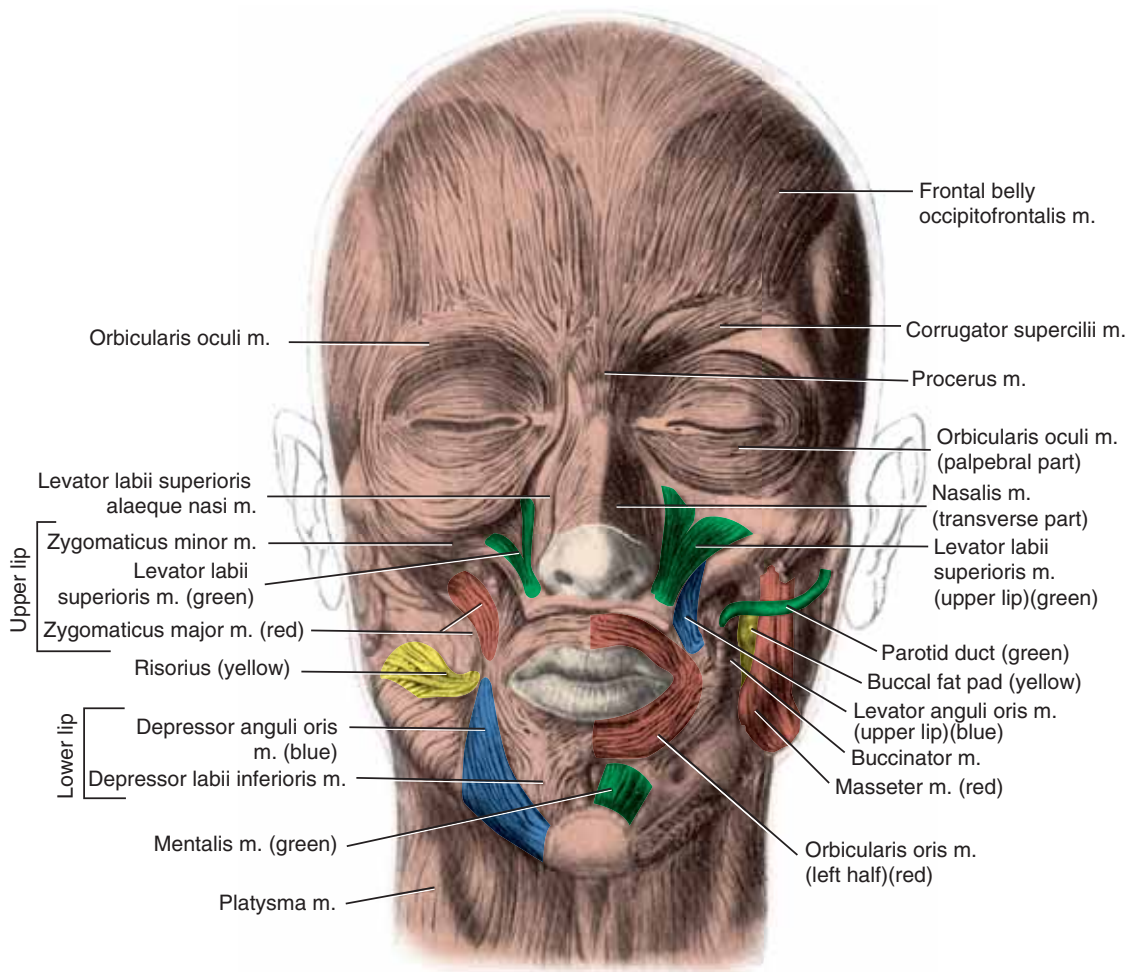
**FIGURE 14-35.** Muscles of the neck, anterior view, with the superficial, thin platysma muscle and some other muscles removed.

Note the **hyoid bone** with a group of muscles superior to the hyoid (called the **suprahyoid muscle group**) and another group of muscles inferior to the hyoid bone (called the **infrahyoid muscle group**). The suprahyoids generally attach the hyoid bone to the mandible and include the **digastric** muscles (one is shaded *red* over the mylohyoid muscle, which is shaded *yellow*) and the **geniohyoid** muscle (one is shaded *red*). The infrahyoids generally attach the hyoid bone to the clavicle (collarbone) and sternum (breast bone) and include the **omohyoid** muscle, shaded *blue*. When both muscle groups work together, they can help open and retrude the mandible. The **sternocleidomastoid** muscle is shaded *green*. (Reproduced from Clemente CD, ed. *Gray's anatomy of the human body*. 30th ed. Philadelphia: Lea & Febiger, 1985:451, with permission.)

- **Buccinator** [BUCK si na tor] attaches on the buccinator crest (posterior to the mandibular third molar) and adjacent soft tissue, forming a pouch in the cheeks. When contracting, it pulls the cheek inward to keep food on the chewing surfaces of teeth during chewing.
- **Upper oral group** includes the **zygomaticus** [ZI go MAT i kus] major and minor, **levator labii** [LAB e e] superioris, and **levator anguli oris**. All contribute to raising the upper lip and/or angle, as in smiling. The **risorius** [ri SO ri us] retracts (spreads) the angle of the mouth. (The **levator labii superioris alaeque [a LY kwe] nasi** dilates the nostrils, as in contempt.)
- **Lower oral group** (including the **depressor labii inferior** and **depressor anguli oris**) contracts to lower the lower lip or angle, as in a frown. The **mentalis** [men TA lis] is located in the chin and raises or protrudes the chin as in a pout.

Other muscles that influence facial expression include the following:

- Nose muscles include the **nasalis** [na SA lis], which flares the nostrils; the **depressor septi nasi** (not shown in figure), which pulls the nares down, thereby constricting the opening of the nose (nares); and the **procerus** [pro SE rus] superior from the bridge of the nose, which lowers the medial eyebrow and wrinkles the nose.
- Eye muscles include the **orbicularis oculi** [or BIK u lar is AHK u li], which surrounds the eye and acts to squint the eye, and the **corrugator supercilii** [COR u gay tor su per SIL e e], which draws the medial end of the eyebrow down, as in a frown.
- Ear muscles include the **posterior, superior, and anterior auricular** [aw RIK u lar] muscles (not shown), which act to move the ears and/or scalp. Can you wiggle your ears by contracting these muscles? Give it a try.



**FIGURE 14-36.** **The muscles of facial expression:** Note the shaded muscles superior to the upper lip, which help raise the lip or help us smile: the **zygomaticus major** (*red*) and **minor**, **levator labii superioris** (*green*), and **levator anguli oris** (*blue*); and the muscles inferior to the lower lip, which help lower the lip or frown: **depressor anguli oris** (*blue*) and the **depressor labii inferioris** (not shaded). The **risorius** (*yellow*) helps to widen the mouth, the **mentalis** (*green*) is in the chin, the **buccinator** (*yellow*) is in the cheek, and the **orbicularis oris** (*red*) surrounds the lips for puckering. The **platysma** is a thin layer of muscle covering deeper neck muscles. (Reproduced from Clemente CD, ed. *Gray's anatomy of the human body*. 30th ed. Philadelphia, PA: Lea & Febiger, 1985:444, with permission.)

- The broad **occipitofrontalis** [ahk SIP i toe fron TAL is] (or epicranial) **muscle** draws back the scalp, wrinkling the forehead and raising the eyebrows, as in surprise.
- The **platysma** [plah TIZ mah] muscle is a broad muscle that extends from the mouth to the anterior and lateral surfaces of the neck and contracts during a grimace.

The posterior and deep muscles of the neck, as well as the overlying fascia and skin, all have a slight postural influence on the physiologic resting position of the mandible. Other than this, the numerous facial muscles, including the buccinator, do not influence any movements of the mandible. However, a person's posture, state of mind, stress, health, and physical and

mental fatigue each have a decided effect on the resting posture of the mandible at any given time.<sup>19</sup>

#### D. SUMMARY OF MUSCLES THAT MOVE AND CONTROL THE MANDIBLE

There are five specifically different ways that we can voluntarily move our mandible. There are limitless combinations of these movements that occur throughout any 24 hours. In review, here are the muscles that contribute to each movement:

##### 1. ELEVATION OF THE MANDIBLE

Elevation (elevates the mandible and closes the mouth) results from the bilateral contraction of three pairs of

muscles. The **temporalis** muscles (vertical fibers) bring the mandible upward into position for crushing food. The temporalis muscles are primarily the positioning muscles as they elevate the mandible upward until it is in position to have the real force applied by the other two pairs of closing muscles. The **masseter** muscles and the **medial pterygoid muscles** act together to apply the power for forceful jaw closures, as in crushing food, such as biting through a carrot.

## 2. DEPRESSION OF THE MANDIBLE

Depression (depresses the mandible and opens the mouth) results primarily from the bilateral contraction of **both lateral pterygoid muscles**, assisted by **suprahyoid and infrahyoid muscles**, especially the anterior bellies of the digastric muscles, and the omohyoid (infrahyoid) muscles, which help fix or hold the hyoid bone.

## 3. RETRUSION

Retrusion (retracts the mandible) results from the bilateral contraction of the **posterior fibers of the temporalis** muscles assisted by the **suprahyoids**, especially the **digastric** muscles (anterior and posterior bellies seen in Fig. 14-35).

## 4. PROTRUSION

Protrusion (or protraction, protrudes the mandible) results from the simultaneous contraction of **both lateral pterygoid muscles**.

## 5. LATERAL EXCURSION

Lateral excursion (moves sideways) results from the contraction of **one lateral pterygoid** muscle. The mandible is moved bodily to the left by the contraction of the right lateral pterygoid muscle.<sup>8,20</sup>

## Review Questions

Select the one best answer.

- Which muscle has its origin in the pterygoid fossa?
  - Medial pterygoid muscle
  - Lateral pterygoid muscle
  - Masseter
  - Temporalis muscle
- The masseter muscle elevates the mandible. Which other muscles are involved in elevating the mandible?
  - Temporalis (anterior fibers) and lateral pterygoid muscles
  - Lateral pterygoid muscles and medial pterygoid muscles
  - Temporalis (posterior and anterior fibers) and medial pterygoid muscles
  - Medial pterygoid muscles and temporalis (anterior fibers)
  - Lateral pterygoid muscles and temporalis (posterior fibers)
- In which direction do the fibers of the lateral pterygoid muscles travel from their origin to their insertion?
  - Medial and posterior
  - Medial and anterior
  - Lateral and anterior
  - Lateral and posterior
- Which of the following muscles of facial expression does not contribute to moving the lips?
  - Orbicularis oris
  - Risorius
  - Levator labii superioris
  - Depressor labii inferioris
  - Orbicularis oculi
- Which of the following would you palpate anterior and 1 to 2 inches superior to the ear?
  - Masseter, the origin
  - Masseter, the insertion
  - Temporalis, posterior fibers
  - Temporalis, anterior fibers
  - Temporalis, the insertion
- Which muscle, when contracting, moves the mandible to the right?
  - The left medial pterygoid muscle
  - The right medial pterygoid muscle
  - The left temporalis muscle, horizontal fibers
  - The right lateral pterygoid muscle
  - The left lateral pterygoid muscle

ANSWERS: 1—a, 2—d, 3—d, 4—e, 5—d, 6—e

## SECTION IV NERVES OF THE ORAL CAVITY

### OBJECTIVES

The objectives for this section are to prepare the reader to perform the following:

- List the 12 cranial nerves (CNs) and briefly describe their function.
- Describe the important branches of the trigeminal nerve and trace the route of each important branch from the brain to the structures that they innervate in the oral cavity.
- Describe the pathway to the oral cavity of the facial nerve and identify the oral structure(s) it innervates.
- Describe the pathway to the oral cavity of the glossopharyngeal nerve and identify the oral structure(s) it innervates.
- Describe the pathway to the oral cavity of the hypoglossal nerve and identify the oral structure(s) it innervates.

There are three types of nerve fibers based on their function: afferent, efferent, and secretory. Afferent [AF er ent] (or sensory) fibers convey impulses (such as feeling, touch, pain, taste) from peripheral organs (like the skin or surface of the tongue) to the central nervous system. (Hint: Afferent: where “a” [as in approach] means sending impulses toward the brain, that is, from an organ receiving sensory input, so the brain can “feel” it; therefore, these impulses are sensory, related to the senses of feeling, touch, pain, taste, etc.)

Efferent [EF er ent] (or motor) nerve fibers convey impulses from the central nervous system to the peripheral organs, such as to muscle fibers to initiate contraction. They supply the four pairs of muscles

of mastication and other muscles in the region of the mouth. (Hint: Efferent: where “e” [as in exit] means sending an impulse from the brain, which could contract a muscle and move a bone in the intended direction [or could increase force on that bone without movement]; therefore, these impulses are motor.)

Secretory fibers are specialized efferent nerve fibers that, upon stimulation, can send messages to glands, such as the salivary and lacrimal (tear) glands to produce and secrete saliva or tears.

There are 12 cranial nerves (CNs) that all supply the area of the head. *Table 14-2* lists the 12 CNs (indicated by Roman numerals I to XII) that are responsible for the specific functions.<sup>1,21–26</sup>

**Table 14-2 THE TWELVE CRANIAL NERVES**

NERVE NO.	CRANIAL NERVE	FUNCTION
I	Olfactory [ol FAK toe ree]	Smell
II	Optic	Sight
III	Oculomotor [AHK u lo MO tor]	Orbital muscles for eye movement
IV	Trochlear [TROK le ar]	Orbital muscles for eye movement
V	<b>*Trigeminal [tri JEM i nal]</b>	<b>Motor: movement of the jaws and muscles of mastication</b> <b>Sensory: sensation of feeling for the face, teeth, and periodontal ligaments, and anterior two thirds of the tongue</b>
VI	Abducent [ab DOO sent]	Orbital muscles for eye movement
VII	<b>*Facial</b>	<b>Motor: to the muscles of facial expression</b> <b>Sensory: taste to anterior two-thirds of tongue</b> <b>Secretory: to submandibular and sublingual glands</b>
VIII	Auditory (or acoustic)	Sense of hearing, position, and balance
IX	<b>*Glossopharyngeal [GLOSS o feh rin Ji al]</b>	<b>Secretory: to parotid gland, pharyngeal movements</b> <b>Sensory: feeling to pharynx and posterior one third of tongue and taste to posterior one third of tongue</b>
X	Vagus [VAY gus]	Pharyngeal and laryngeal movements: digestive tract
XI	Spinal accessory	Neck movements: sternocleidomastoid and trapezius muscles
XII	<b>*Hypoglossal</b>	<b>Motor: tongue movement (muscles)</b>

**\*The asterisked nerves in bold** are most important when discussing the function of the oral cavity. A detailed discussion of these nerves will include the major branches to structures of the mouth, including teeth, periodontal ligaments and alveolar processes, gingiva (gums), the palate and floor of the mouth, and muscles of mastication, of facial expression, and of the tongue (both for muscular action and our sense of taste). Also, a mnemonic that may help you remember the cranial nerves (where the first letter of each word is the same as the first letter of each cranial nerve) is “On Old Olympus’ Towering Top, A Finn and German Viewed Some Hops.”



## A. TRIGEMINAL NERVE (FIFTH CN)

When discussing the function of the oral cavity, probably the most important nerve is the trigeminal. The **trigeminal nerve** or **fifth CN** is the largest of the CNs and is the major sensory nerve of the face and scalp. It originates in the large semilunar or trigeminal ganglion, a group of nerve cell bodies located on the superior surface of the petrous portion of the temporal bone in a small depression (the semilunar fossa) medial to the foramen ovale. The trigeminal nerve divides into **three major divisions** (or three nerve branches). (Hint: “tri” in trigeminal refers to the nerve’s three divisions.) **Division I** (the **ophthalmic** [ahf THAL mik] nerve) and **Division II** (the **maxillary** nerve) are only afferent (sensory). **Division III** (the **mandibular** nerve) is both afferent (sensory) and efferent (motor). Its efferent fibers supply the muscles of mastication. This is the only CN with sensory (touch and pain) innervation to the skin of the face, and the divisions or branches are distributed to the face as shown in *Figure 14-37*.

The maxillary and mandibular divisions of the trigeminal nerve also supply afferent or sensory neurons that provide the brain with information about the position of the teeth and jaws at all times. The interpretation of postural information by the brain (sense of position) is called **proprioception**. Proprioceptive nerve receptors are located in muscles and ligaments, including the periodontal ligaments, and in the lateral aspects of the TMJs. The periodontal ligament around each tooth is well supplied with proprioceptive neurons from the maxillary and mandibular divisions of

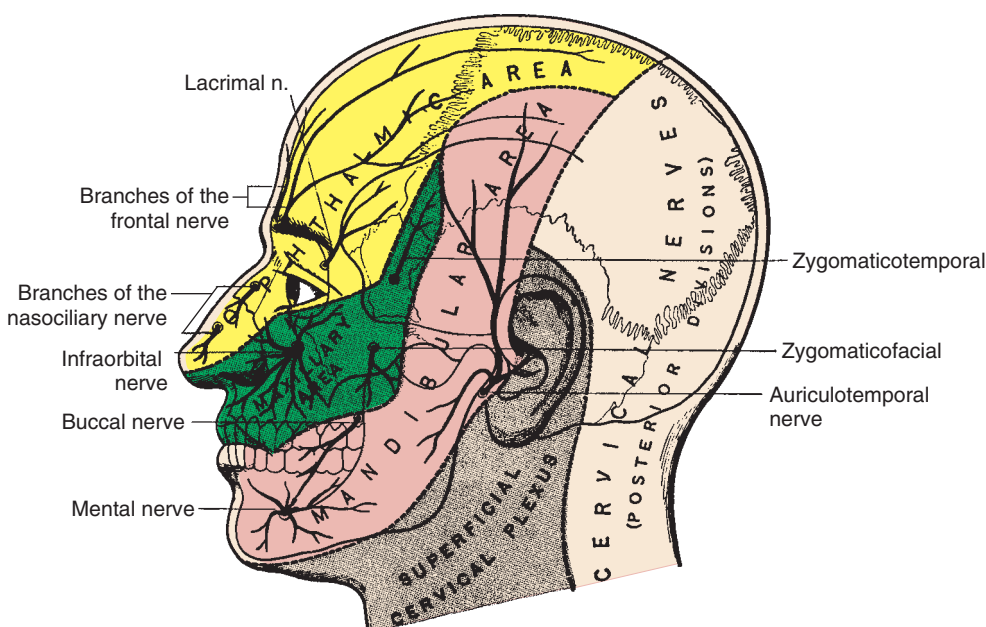
the trigeminal nerve. These branches send messages to the brain as to the relative position of the mandibular to maxillary teeth. This has a tremendous influence on relative jaw position, movement, and occlusion (the fitting together) of the teeth. Canines are reported to have the richest supply of proprioceptive nerve endings.

The TMJ also has proprioceptive neurons in the capsule and disc that are innervated by the auriculotemporal branch of the mandibular division of the trigeminal nerve. To a great extent, proprioceptive information, especially from the teeth, determines the subconscious but well-coordinated function of the two complex TMJs.<sup>24,25</sup> Otherwise, we could experience many unpleasant tooth interferences or frequent joint pain.

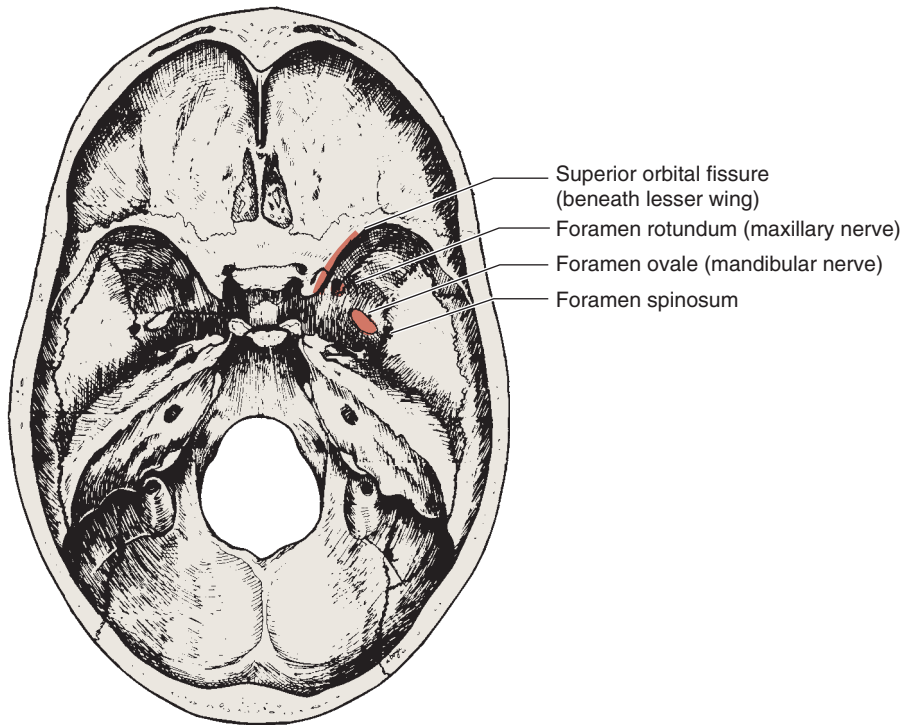
Each of the three divisions is divided into many branches. The branches of the maxillary nerve and the mandibular nerve are those that innervate the region of, and around, the oral cavity and will be discussed in the most depth in this section.

### 1. DIVISION I (OPHTHALMIC NERVE) OF THE TRIGEMINAL NERVE

The **ophthalmic** [of THAL mik] nerve exits from the skull by way of the superior orbital fissure on the superior surface of the orbit (*Fig. 14-38*). It has three main branches: the smallest lacrimal nerve, the largest frontal nerve, and the nasociliary nerve. The distribution of these sensory branches that supply the skin of the face is shown in *Figure 14-37*. The ophthalmic nerve and its branches supply general sensations (of touch, pain, pressure, and temperature) to the skin of the upper third of



**FIGURE 14-37.** General distribution to the skin of the three **sensory divisions** of the **trigeminal nerve**. Pain in these areas is felt by impulses sent through the **ophthalmic** (yellow), **maxillary** (green), and **mandibular** branches (red) or divisions of this nerve. These three branches are distributed to the face as indicated in this drawing. (Reproduced from Clemente CD, ed. *Gray’s anatomy of the human body*. 30th ed. Philadelphia, PA: Lea & Febiger, 1985:1164, with permission.)



**FIGURE 14-38.** Human skull: bones lining the inside of the neurocranium, superior view. Note the location of the three pairs of openings where the three branches of the **trigeminal nerve** leave the brain: the **superior orbital fissure** for the **ophthalmic branch**, the **foramen rotundum** for the **maxillary branch**, and the **foramen ovale** for the **mandibular branch**. The openings on the right side of the drawing are shaded *red*.

the face including the skin of the forehead and anterior scalp, and the skin around the eyeball, eyelid and nose, and part of the nasal mucosa and maxillary sinus. The ophthalmic nerve does not supply the oral cavity. (Hint: “Ophthalmic” is related to the eye; compare ophthalmologist, a physician who specializes in eyes.)

## 2. DIVISION II (MAXILLARY NERVE) OF THE TRIGEMINAL NERVE

The **maxillary nerve** provides general sensations (of touch, pain, pressure, and temperature) to the skin of the middle third of the face and the palate (Fig. 14-37), plus provides sensory branches to the pulp of all maxillary teeth. It exits the brain case of the skull through the **foramen rotundum** (Fig. 14-38). After passing through the foramen rotundum, the maxillary nerve passes into the **pterygopalatine space** and eventually splits into four branches: the pterygopalatine, posterior superior alveolar (PSA), infraorbital, and zygomatic nerves.

### a. First Branch of the Maxillary Nerve: Pterygopalatine Nerve

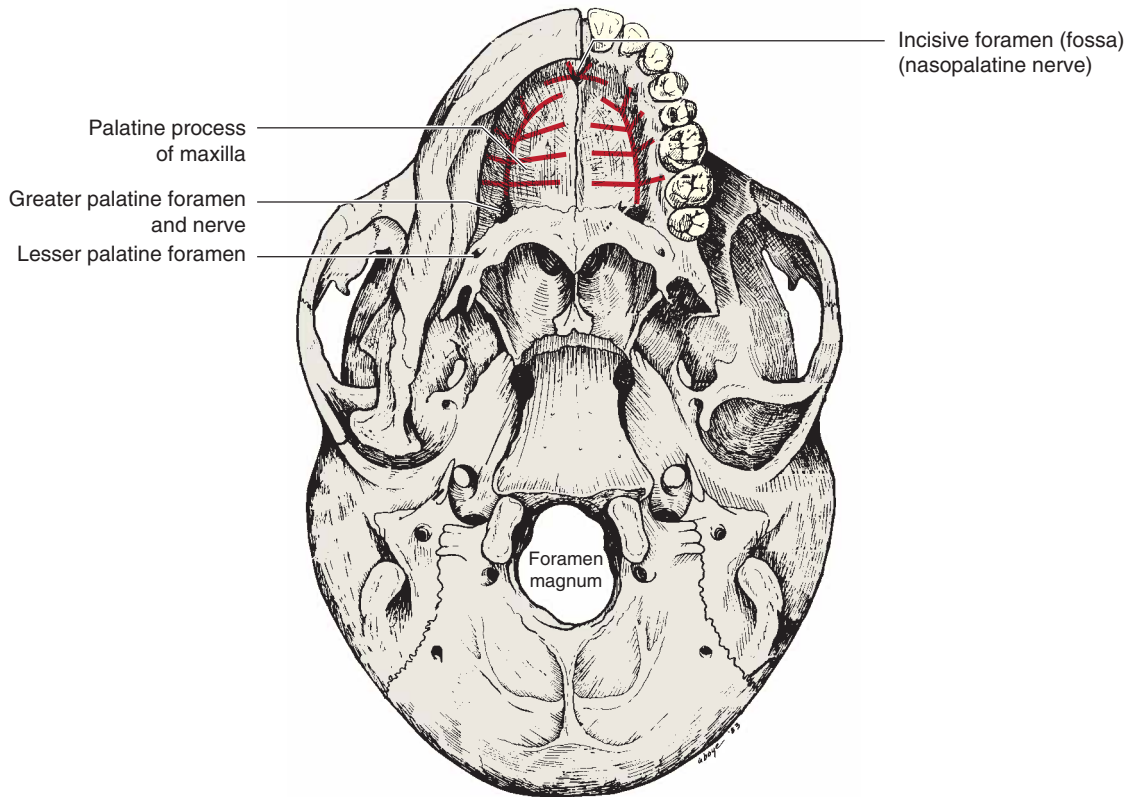
The first branch of the maxillary nerve, the **pterygopalatine nerve**, splits off closest to the foramen rotundum. A branch of this nerve, called the **descending palatine nerve**, passes through the **greater palatine foramen** to become the **greater palatine nerve**. The greater palatine nerve spreads anteriorly to supply the mucosa (soft tissue

covering) of the posterior portion of the hard palate and the palatal gingiva medial to the posterior teeth (molars and premolars) (some red lines in Fig. 14-39). Just posterior to the greater palatine foramen, the **middle** and **posterior** (lesser) **palatine nerves** enter the palate through the lesser palatine foramen to spread posteriorly to supply the tonsils and mucosa of the soft palate.

Another long branch of the pterygopalatine nerve, the **nasopalatine nerve**, runs along the roof of the nasal cavity, then diagonally downward and anteriorly along the nasal septum where it enters the bone of the palate to emerge onto the anterior palate through the **incisive foramen**. This branch innervates the soft tissue of the nasal septum and gingiva and palatal soft tissue lingual to the anterior teeth. The right and left nasopalatine nerves combined with the greater palatine nerves innervate the soft tissue of the entire hard palate (shown as all red lines in Fig. 14-39).

### b. Second Branch of the Maxillary Nerve: Posterior Superior Alveolar (PSA) Nerve

Just before the maxillary nerve branch enters the infraorbital fissure and canal on the floor of the orbit, it gives off its second branch, the PSA nerve. This branch enters the **alveolar canals** on the infratemporal portion of the maxilla (Fig. 14-40). Once within the trabecular (spongy) bone of the maxilla and the maxillary sinus, its **dental branches** enter small openings in the tooth roots to supply the maxillary molars (except for one root,



**FIGURE 14-39.** Human skull: inferior surface including the palate, showing the foramina for branches of the trigeminal nerve that innervates the mucosa of the palate: the **greater palatine foramen** (for the *greater palatine nerve*) and the incisive foramen (for the *nasopalatine nerve*). The more posterior *red lines* indicate the diagrammatic distribution of the branches of the greater palatine nerves as they spread out along the junction of the alveolar processes with the palatine processes of the maxillae to the tissues (mucosa) of the palate located between the posterior teeth. The more anterior *red lines* indicate the *nasopalatine nerve* branches spreading out to the mucosa between the anterior teeth.

the mesiobuccal root of the maxillary first molars). It also innervates the supporting alveolar bone, periodontal ligaments, and facial gingiva next to the maxillary molars, the mucosa of part of the maxillary sinus, and cheek mucosa next to maxillary molars.

### c. Third Branch of the Maxillary Nerve: Infraorbital Nerve

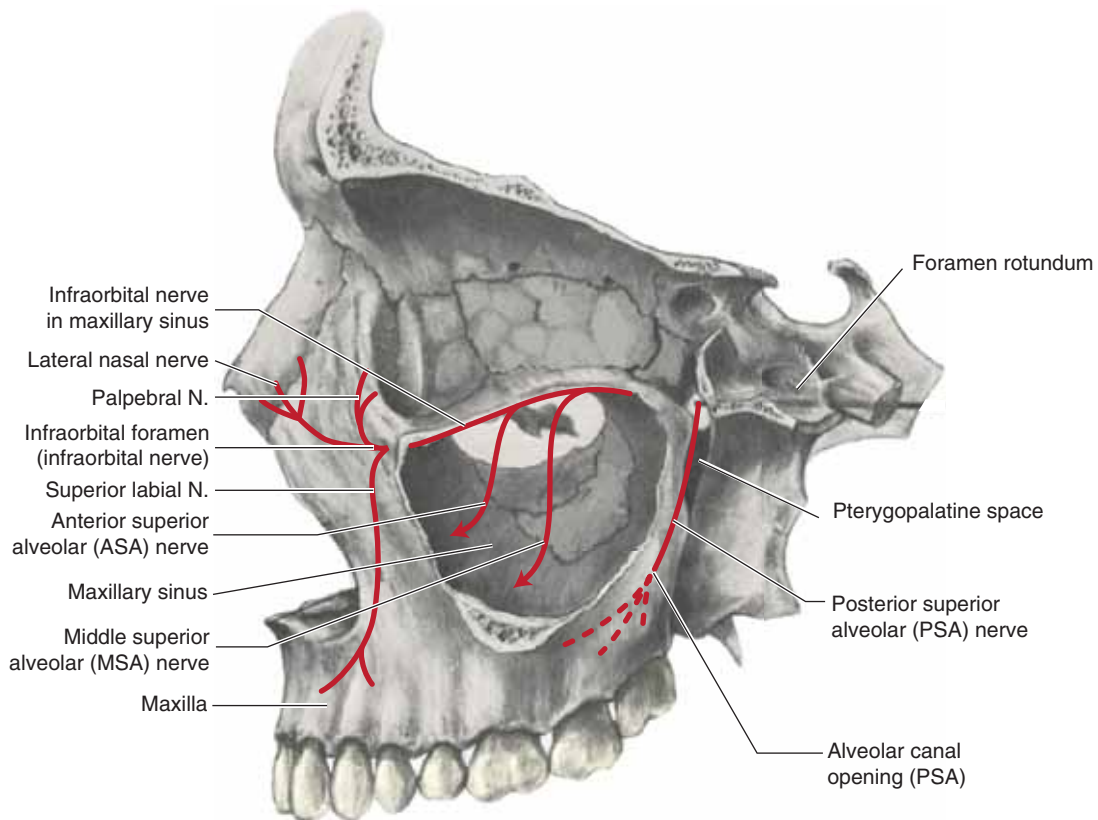
In the pterygopalatine space, a third branch of the maxillary nerve splits off and passes through the inferior orbital fissure on the floor of the orbit and enters the infraorbital canal, where it becomes the **infraorbital nerve** (Fig. 14-40). While within this canal, the infraorbital nerve gives off two branches, the middle superior alveolar (MSA) and the anterior superior alveolar (ASA) nerves (shown in Fig. 14-40).

The **MSA nerve** passes forward along the lining of the maxillary sinus. It gives off small dental branches that enter premolars through their root openings

(apical foramina) to supply the maxillary premolars (and the mesiobuccal root of the maxillary first molar), supporting alveolar bone, periodontal ligaments, and facial gingiva in the maxillary premolar region and part of the maxillary sinus. It is important to realize that the nerve supplying primary teeth is the same as that to the permanent teeth that replace them. Therefore, the nerve branch to the primary molars is the MSA, the same one that supplies their successors, the permanent premolars.

The second branch given off of the infraorbital nerve while in the infraorbital canal is the **ASA nerve**. Its small dental branches supply the pulp, supporting alveolar bone, periodontal ligaments, and facial gingiva of the maxillary anterior teeth and part of the maxillary sinus.

Notice that three branches of the maxillary nerve of CN V innervate all maxillary teeth: the PSA nerve, the MSA nerve, and the ASA nerve. A comparison of the descriptions of these three superior alveolar nerves



**FIGURE 14-40.** **Maxillary division of the trigeminal nerve:** branches that innervate the maxillary teeth. The lateral wall of the left maxilla has been removed exposing the large maxillary sinus. One nerve branch (the *PSA nerve*) exits the **pterygopalatine space** and goes down the posterior surface of the maxilla before entering the maxilla through the **alveolar canals** on its way to most maxillary molar roots. Another branch, the *infraorbital nerve*, passes from the **pterygopalatine space** to the **floor of the eye orbit** (which also forms the roof of the maxillary sinus) where it enters the **infraorbital canal** (not shown). Within the infraorbital canal, two branches split off to pass downward along the walls of the **maxillary sinus** and into the maxilla. The *MSA nerve* passes through the spongy bone of the maxilla to the maxillary premolars (and one first molar root on each side), and the *ASA* passes to the roots of the maxillary anterior teeth. The *infraorbital branch* continues through the infraorbital canal to exit the maxilla through the **infraorbital foramen**, which provides feeling to the skin on the side of the nose, the anterior part of the cheek, and the upper lip on that side.

indicates a great lack of uniformity in their distribution. Sometimes, the MSA nerve is missing, and the function is taken over by the anterior and posterior alveolar nerves.

After exiting from the infraorbital foramen, the **infraorbital nerve** splits into its end (terminal) branches innervating the skin and mucosa of the side of the nose (**nasal nerve**), skin and mucosa of the lower eyelid (**palpebral [PAL pe bral] nerve**), skin and mucosa of the upper lip, facial gingiva of maxillary premolars, and facial gingiva of anterior teeth (**labial [LAY bee al] nerve**) (Fig. 14-40).

#### d. Fourth Branch of the Maxillary Nerve: Zygomatic Nerve

The **zygomatic nerve** arises in the pterygopalatine fossa, enters the orbit via the inferior orbital fissure, and then

divides into the zygomaticotemporal and zygomaticofacial nerves (the upper and lower branches, respectively, of the zygomatic nerve in Fig. 14-37). It supplies the skin of the temporal region and lower part of the orbit.

### 3. DIVISION III (MANDIBULAR NERVE) OF THE TRIGEMINAL NERVE

The **mandibular nerve** is a mixed nerve; that is, it contains both sensory (afferent) and motor (efferent) fibers. It is the only motor portion of the trigeminal nerve. These motor fibers of the mandibular nerve supply the eight muscles of mastication, plus the mylohyoid muscle and the anterior belly of the digastric muscles, which help to retract the mandible. Sensory fibers provide general sensations (of touch, pain, pressure, and temperature) to the skin of the lower third of the face (as seen in Fig. 14-37) and the floor of the mouth and



anterior two thirds of the tongue (not taste). Other branches enter all mandibular teeth.

The mandibular nerve exits the neurocranium through the **foramen ovale** (Fig. 14-38). It passes into a space just medial to the zygomatic arch and mandibular ramus, and inferior to the temporal bone, called the **infratemporal space**. As it passes inferiorly toward the mandibular foramen in the mandible, it divides into four sensory branches: the auriculotemporal, buccal, lingual, and inferior alveolar nerves.

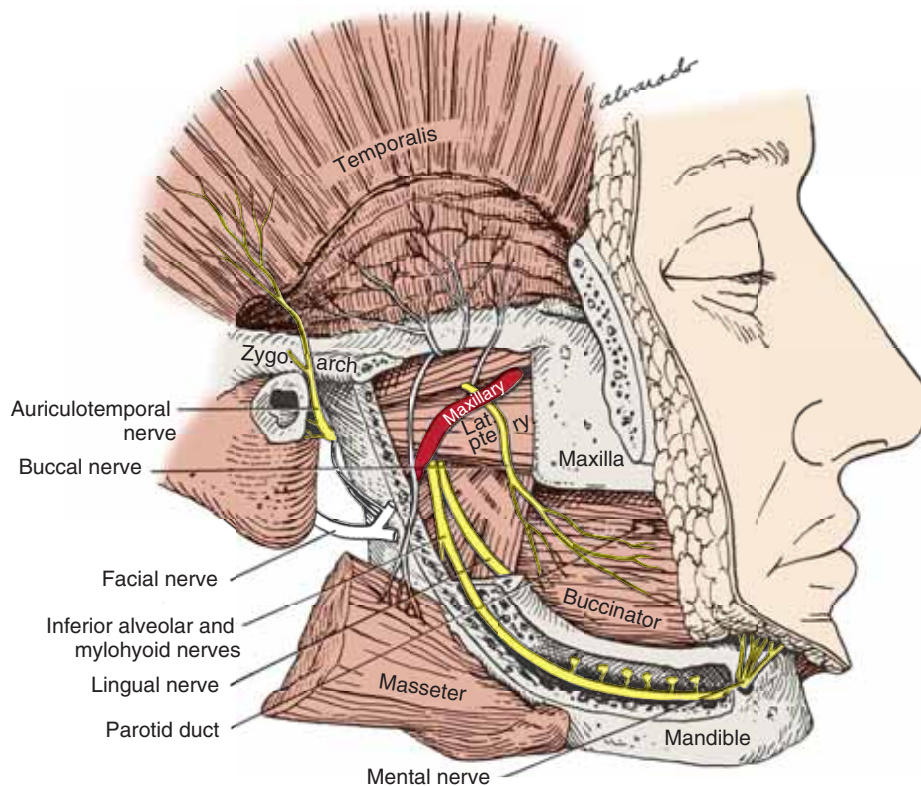
### a. Auriculotemporal Nerve

The first branch of the mandibular division, the **auriculotemporal** [aw RIK u lo TEM po ral] nerve, comes off the main trunk immediately below the base of the skull, turning backward to supply pain and proprioception

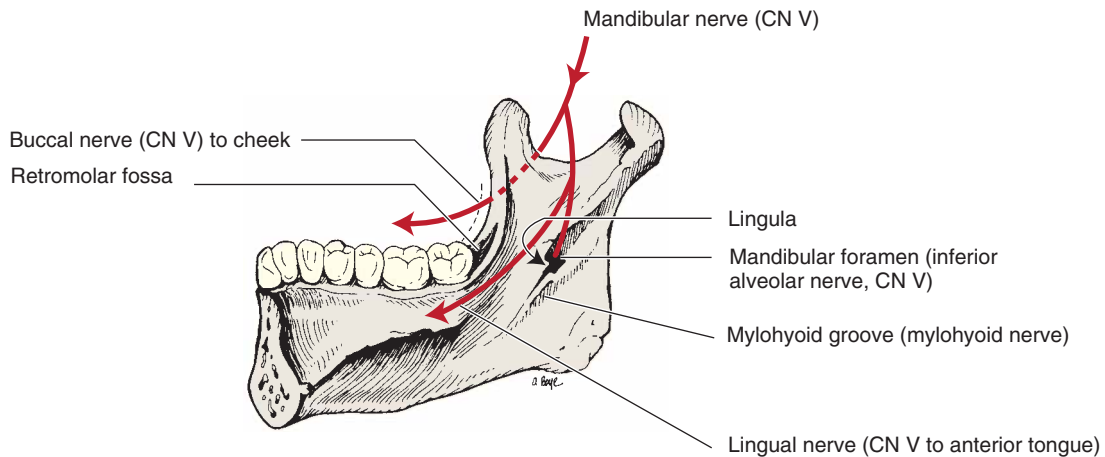
fibers to the TMJ, and to supply the skin of the outer ear and the lateral aspect of the skull and cheek (Fig 14-41).

### b. Buccal (Buccinator) Nerve

Another branch is the **buccal (buccinator [BUCK sin a tor] or long buccal) nerve**, which comes off just below the foramen ovale and passes through the infratemporal space between the two heads of the lateral pterygoid muscles, then down and forward to the buccinator muscle (Fig. 14-41) where it innervates the mucosa and skin of the cheek up to the corner of the mouth, and the buccal gingiva in the area of the mandibular molars and sometimes the second premolars. The best place to anesthetize the tissue supplied by the buccinator nerve is to inject inside the cheek to deposit the anesthetic into the buccinator muscle near the mandibular molars (Fig. 14-42).



**FIGURE 14-41. Mandibular division of the trigeminal nerve branches (yellow)** : The external wall of the right mandible has been removed to expose the inferior alveolar nerve within the mandible, where it gives off the many small branches to each mandibular tooth. (From this view, the buccinator muscle hides the teeth.) Within the mandible near the premolar area, the **inferior alveolar nerve** splits into two end (terminal) branches. One branch, the **mental nerve**, exits through the **mental foramen** to innervate the skin of the chin and lip on that side, while the other branch is really a continuation of the inferior alveolar nerve anteriorly within the mandible where it is called the **incisive nerve** (not visible here). Also, note the other major branches of the mandibular division: the **lingual nerve**, which is in close proximity to the inferior alveolar nerve posteriorly, but then diverges anteriorly to enter the tongue; and the **buccal nerve**, which innervates the cheek and tissue next to mandibular molars. Other nerve branches (not shaded) are motor branches of the mandibular nerve supplying the muscles of mastication. (Motor branches can be seen entering the masseter and temporalis muscles.) (Reproduced from Clemente CD, ed. *Gray's anatomy of the human body*. 30th ed. Philadelphia, PA: Lea & Febiger, 1985:1166, with permission.)



**FIGURE 14-42.** Location of the branches of the **mandibular division of the trigeminal nerve (mandibular nerve)** (in red): As the mandibular nerve passes through the infratemporal space, it gives off the buccal nerve to the cheek (lateral to the ramus). Before entering the mandibular foramen, the mandibular nerve (medial to the ramus) gives off a **lingual nerve** branch that passes to the tongue. The **inferior alveolar nerve** enters the **mandibular foramen** (and canal) where it and its terminal incisal branch give off branches through the spongy bone to all mandibular teeth.

### c. Lingual Nerve

The next branch of the mandibular nerve, given off inferior to the foramen ovale, is the **lingual nerve** branch that goes to the tongue (Figs. 14-41 and 14-42). It passes downward, medial to the ramus but lateral to the medial pterygoid muscle, to the mucous membrane just lingual to the last molar. The lingual nerve provides *general sensation* (touch, pain, pressure, and temperature, but not taste) to the top (dorsal) and bottom (ventral) surfaces of the *anterior two thirds of the tongue* and adjacent tissues. The adjacent tissues include the soft tissue (mucosa) on the floor of the mouth and inner surface of the mandible and the lingual gingiva of the entire mandible.

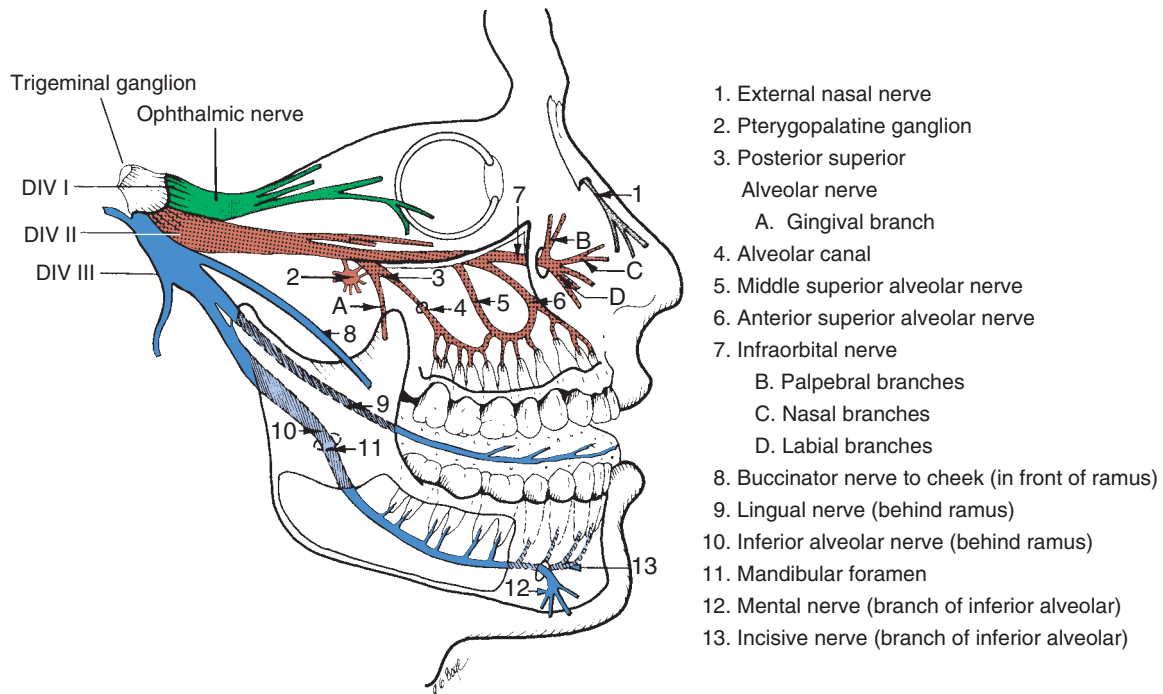
### d. Inferior Alveolar Nerve

Finally, the **inferior alveolar nerve** comes off the mandibular nerve on the medial side of the lateral pterygoid muscle (Figs. 14-41 and 14-42). This large nerve roughly parallels the direction of the lingual nerve to descend between the sphenomandibular ligament and ramus to the mandibular foramen, where it gives off the **mylohyoid nerve** and then enters the mandible through the **mandibular foramen** (represented on the medial surface of the mandible in Fig. 14-42). The **mylohyoid nerve** (efferent) pierces the sphenomandibular ligament and travels forward in the mylohyoid groove to supply the mylohyoid muscle.

Once the inferior alveolar nerve enters the mandible through the mandibular foramen, it is in the **mandibular canal** within the body of the mandible, where it gives

off the many small **dental branches** that spread through trabecular (spongy) bone of the mandible in order to enter the apical foramen of all mandibular molars and premolars. It also innervates the periodontal ligaments and alveolar processes of these teeth. While within the mandibular canal, the inferior alveolar nerve splits near the roots of the premolars to become the mental nerve and the incisive nerve. The **incisive nerve** (Fig. 14-43) branch continues forward within the mandibular canal to supply the mandibular incisor and canine teeth, their periodontal ligaments, and surrounding alveolar process. The **mental nerve** branch of the inferior alveolar nerve exits from the body of the mandible through the **mental foramen** (Fig. 14-41) and supplies the facial gingiva of the mandibular incisors, canines, and premolars and the mucosa and skin of the lower lip and chin on that side up to the midline (Fig. 14-37).

Note that if an anesthetic solution is deposited next to the opening of the **mandibular foramen**, it could block the passage of sensory nerve signals from all mandibular teeth on that side (by blocking the inferior alveolar and its terminal incisive branch) and also the skin of the chin and lip area (because another terminal branch, the mental nerve, has also been blocked). Further, since the lingual nerve is in close proximity to the mandibular foramen, its fibers may also be blocked, causing that side of the floor of the mouth, lingual gingiva, and anterior two thirds of the tongue to lose feeling. The only part of the mandible that would not be numb would be the tissue buccal to the molars, which requires some additional anesthetic solution in the cheek to block the buccal nerve.



**FIGURE 14-43.** Trigeminal nerve distribution of the branches of the *maxillary and mandibular divisions*: The ophthalmic branches are shaded *green*, the maxillary nerve and branches are shaded *red*; the mandibular nerve and branches are *blue*. Note that the buccinator (long buccal) branch (labeled No. 8) of the mandibular division passes superficial to the ramus to enter the cheek, whereas the lingual nerve (labeled No. 9) and inferior alveolar nerve (labeled No. 10) pass medial to the ramus as they go to the tongue and mandible, respectively. Also, note that the infraorbital branch of the maxillary division gives off the MSA (labeled No. 5) and ASA branches (labeled No. 6) while in the infraorbital canal on the floor of the eye orbit (roof of the maxillary sinus).

Figures 14-43 and 14-44, and *Table 14-3* can be used to help summarize the distribution of the mandibular and maxillary sensory nerve branches to all teeth and surrounding tissues of the mouth.

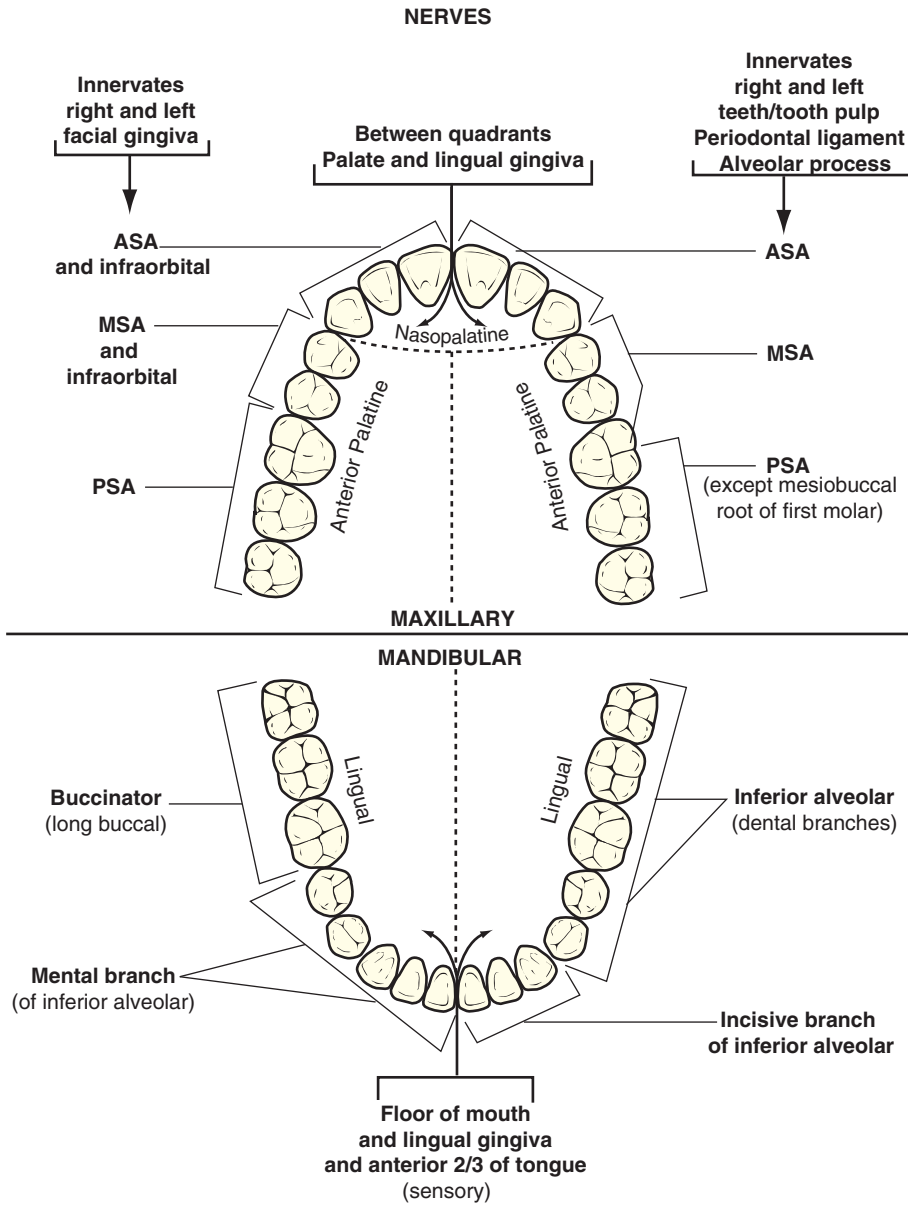
Motor (efferent) branches of the mandibular nerve supply the muscles of mastication: the **masseteric nerve** to the masseter muscle, as well as to the TMJ, the **posterior and anterior temporal nerves** to the temporalis muscle, the **medial pterygoid nerve** to the medial pterygoid muscle, and the **lateral pterygoid nerve** to the lateral pterygoid muscle.

## B. FACIAL NERVE (SEVENTH CN)

The **facial nerve** is a mixed nerve (sensory and motor). From the brain, the facial nerve penetrates the petrous portion of the temporal bone through the **internal acoustic meatus** (*Fig. 14-45*) and exits from the skull between styloid and mastoid processes through the **stylomastoid foramen** (*Fig. 14-46*). It passes through the parotid gland. Efferent motor [EF er ent] fibers innervate muscles of facial expression (including the orbicularis oris) and visual expression of the face and

the scalp. Other muscles supplied by the facial nerve include the posterior belly of the digastric muscle and stylohyoid muscle (*Fig. 14-35*); the platysma muscle (a broad, thin superficial muscle that covers much of the anterior part of the neck, seen in *Fig. 14-36*); and the stapedius muscle (in middle ear cavity). None of these muscles has any influence on moving the mandible. Efferent **secretory fibers** stimulate secretions from two pairs of salivary glands: the **sublingual glands** located just under the mucosa in the floor of the mouth superior to the mylohyoid muscle, and the **submandibular glands** located in the submandibular fossae on the medial surface of the mandible inferior to the mylohyoid muscle.

Afferent sensory [AF er ent] fibers of the facial nerve (**chorda tympani branch**) branch off within the petrous portion of the temporal bone. They course through the tympanic cavity eventually exiting of the skull by way of the **petrotympanic** [PET ro tim PAN ik] **fissure**. These chorda tympani fibers of the facial nerve join with the lingual nerve (branch of the mandibular division of the trigeminal nerve) and supply the *sense of taste* to the *anterior two thirds of the tongue* (the body and the tip of the tongue).



**FIGURE 14-44.** A summary of the distribution of branches of the **trigeminal nerve (CN V)** that innervate the tissues of the mouth: Nerves listed on the left side of the diagram supply *facial gingiva* on both the right and the left side of the face; nerves listed on the right side of the diagram supply the *teeth, tooth pulps, periodontal ligaments, and alveolar processes* on both sides of the face. Nerves listed in those areas innervate the mucosa medial to the teeth.

**Table 14-3** DISTRIBUTION OF BRANCHES OF TRIGEMINAL NERVE TO THE TEETH AND SURROUNDING STRUCTURES

(Carefully study this comprehensive but simple table. Then, covering one column at a time, see how many nerves you can recall. These are the nerves any dental student, dental hygiene student, or graduate of either profession should be most familiar with. You should also be able to determine the location of each nerve.)

TEETH	TOOTH PULP	GINGIVA	PERIODONTAL LIGAMENT AND ALVEOLAR PROCESS	HARD PALATE
<b>MAXILLARY ARCH</b>				
Anterior teeth	ASA nerve	<b>Palatal:</b> Nasopalatine nerve <b>Labial:</b> infraorbital and ASA nerves	ASA nerve*	Nasopalatine nerve

(continued)

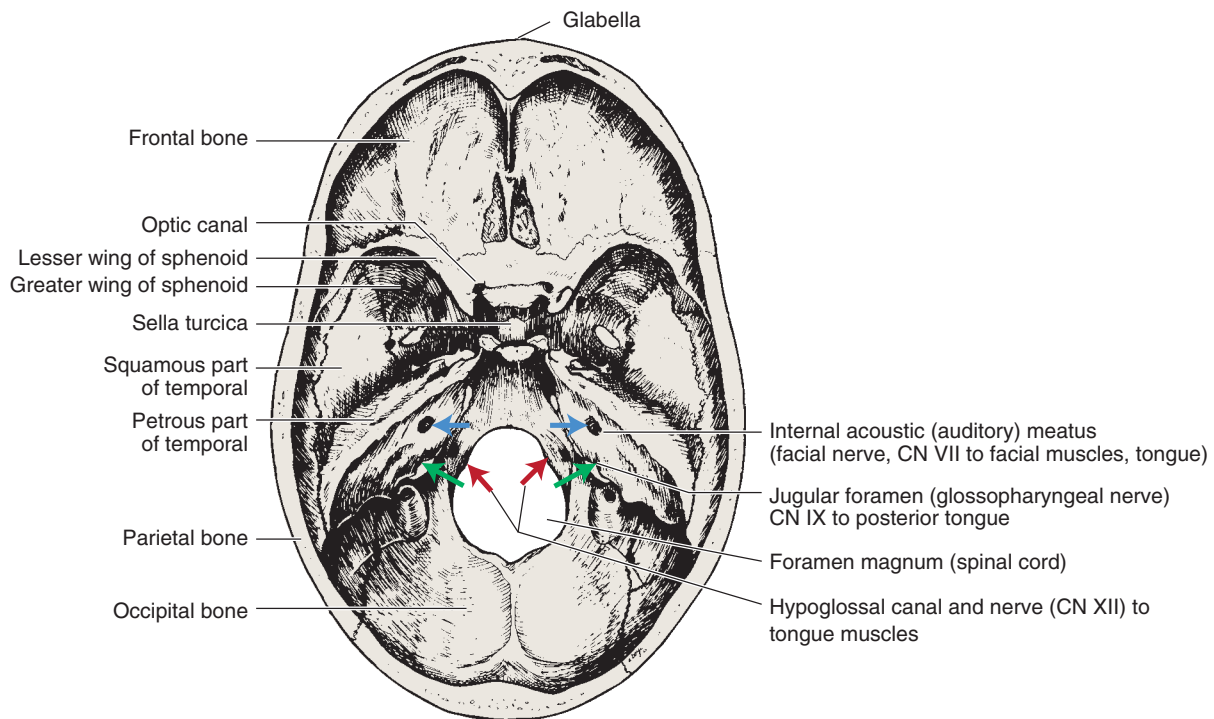


Table 14-3

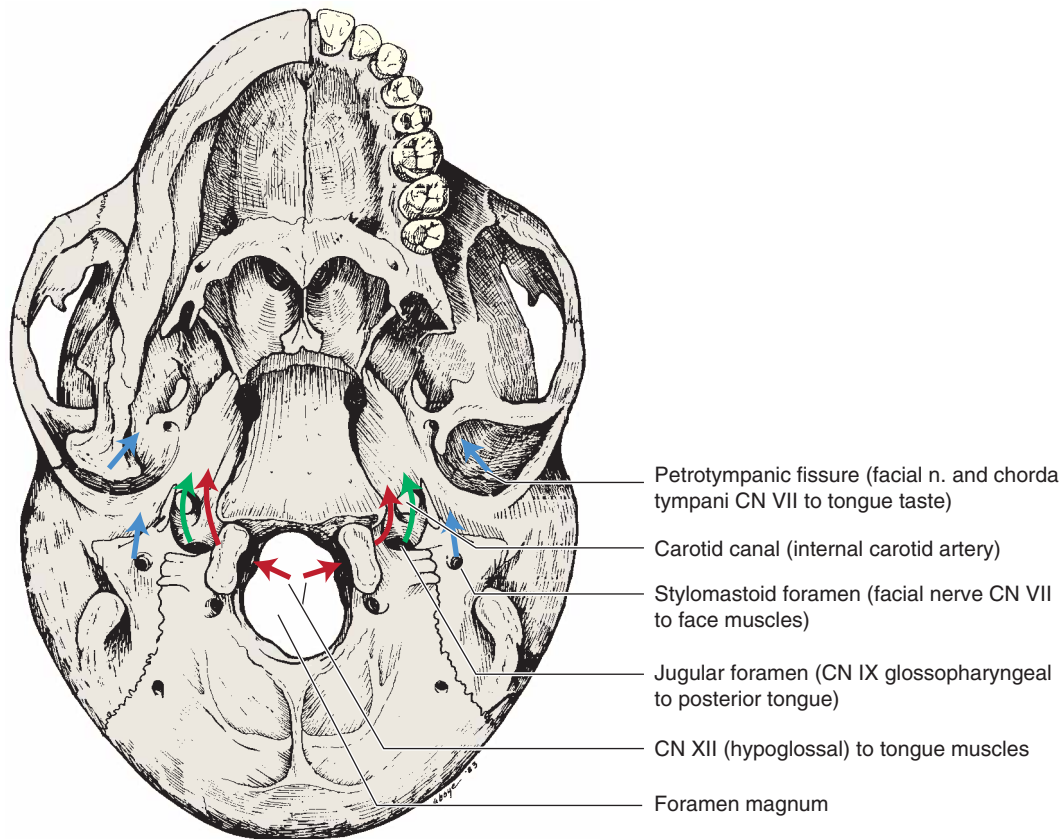
**DISTRIBUTION OF BRANCHES OF TRIGEMINAL NERVE  
TO THE TEETH AND SURROUNDING STRUCTURES (CONTINUED)**

TEETH	TOOTH PULP	GINGIVA	PERIODONTAL LIGAMENT AND ALVEOLAR PROCESS	HARD PALATE
<b>MAXILLARY ARCH</b>				
Premolars	MSA nerve	<b>Palatal:</b> anterior palatine nerve <b>Buccal:</b> MSA and infraorbital nerves	MSA nerve*	Anterior palatine nerve
Molars	PSA nerve except mesiobuccal root of first (supplied by MSA nerve)	<b>Palatal:</b> anterior palatine nerve <b>Buccal:</b> PSA nerve	PSA nerve*	Anterior palatine nerve  <b>Soft palate:</b> middle and posterior palatine nerve
<b>MANDIBULAR ARCH</b>				
Anterior teeth	Incisive branch of the inferior alveolar nerve	<b>Lingual:</b> lingual nerve <b>Labial:</b> mental nerve	Incisive nerve	Lingual nerve
Premolars	Dental branch of inferior alveolar nerve	<b>Lingual:</b> lingual nerve <b>Buccal:</b> mental nerve	Dental branch of inferior alveolar nerve	Lingual nerve
Molars	Dental branch of inferior alveolar nerve	<b>Lingual:</b> lingual nerve <b>Buccal:</b> buccinator nerve (long buccal nerve)	Dental branch of inferior alveolar nerve	Lingual nerve

\*Also supply the maxillary sinus.



**FIGURE 14-45.** Foramen for CNs VII (**facial**), IX (**glossopharyngeal**), and XII (**hypoglossal**) that exit the brain case through bones lining the inside of the neurocranium. *Arrows* indicate the location of the *facial nerve* that passes through the **internal acoustic foramen** (*blue*), the *glossopharyngeal nerve* that passes through the **jugular foramen** (*green*), and the *hypoglossal nerve* branches that pass through the **hypoglossal canals** (*red*) (not visible but on the lateral walls of the foramen magnum).



**FIGURE 14-46.** Foramen for CNs VII (facial), IX (glossopharyngeal), and XII (hypoglossal) viewed on the inferior surface of the neurocranium. One part of the *facial nerve* exits through the **stylomastoid foramen** (blue) and another small branch exits through the **petrotympanic fissure** (blue) where it joins up with the *lingual branch* of the trigeminal nerve to provide the anterior two thirds of the tongue with feeling (trigeminal nerve neurons) and taste (facial nerve neurons). The *glossopharyngeal nerves* exit through the **jugular foramen** (green). The *hypoglossal nerves* exit through the **hypoglossal canals** (red). Also, note the **carotid canal** where the internal *carotid artery* enters the braincase.

**Advanced topics about taste buds:** There are approximately 8000 to 9000 taste buds in the young adult, more in children, and fewer with advancing age. Originally, four primary tastes were identified: sour (acid), sweet, salty, and bitter.<sup>27</sup> Some authors add alkaline and metallic to the taste senses. Others are currently citing a unique taste associated with monosodium glutamate (amino acids) called umami.<sup>28</sup> Early research on taste was interpreted by mapping the tongue for the quality of taste sensed in each area: the tip of the tongue is where one best distinguishes sweet, salty, or alkaline substances, and the sides of the tongue are most sensitive to sour (acidic) substances.<sup>27</sup> However, newer research has shown that cells within each taste bud may respond to multiple tastes, but the sense of taste in each area of the tongue is dependent upon the intensity of each taste. (An excellent discussion of taste is found in the chapter by Travers and Travers in the text edited by Cummings that is cited at the end of this chapter.)

### C. GLOSSOPHARYNGEAL NERVE (NINTH CN)

The **glossopharyngeal** [GLOSS o feh rin JI al] nerve exits from the skull via the **jugular** [JUG yoo lar] foramen (Figs. 14-45 and 14-46). It then passes down and forward to enter the tongue. It is a mixed nerve (sensory and motor) and supplies parts of the tongue and pharynx.

The **afferent** fibers of this nerve supply the sense of taste and sensation of feeling (touch and pain) to the *posterior one third of the tongue* and general sensation to the mucosa of the pharynx and tonsils. (Bitter sensations are prominent on the dorsal [top] surface in the region of the circumvallate papillae on the posterior third of the tongue. Additional taste buds can be found in other structures in the back of the mouth, such as the pillars of the fauces, hard and soft palate, epiglottis, and pharynx.<sup>27,29</sup>) The motor fibers of the glossopharyngeal nerve innervate the stylopharyngeus muscle of the pharynx.

Other secretory fibers innervate the *parotid gland*, influencing secretion. This gland is located in front of each ear lobe in the cheek tissues just inferior to the zygomatic arch (seen later in *Fig. 14-48*). (Hint: Glossopharyngeal means glosso [tongue] + pharyngeal [pharynx or throat]).

## D. HYPOGLOSSAL NERVE (12th CN)

The hypoglossal nerves exit from the skull through the hypoglossal canals just above the occipital condyles near the anterior border of the large **foramen magnum** visible inside the walls of the foramen magnum (*Fig. 14-46*). This motor nerve descends steeply to the muscles that move the tongue. (These are genioglossus, styloglossus, hyoglossus, longitudinal, vertical, and transverse.) If this nerve becomes damaged from injury or tumor, the tongue will deviate noticeably toward the affected side. (Hint: Hypoglossal means hypo [beneath; like a hypodermic needle] + glossal [tongue].)

## E. SUMMARY OF NERVE SUPPLY TO THE TONGUE, SALIVARY GLANDS, FACIAL SKIN, AND FACIAL MUSCLES

### 1. NERVES PROVIDING GENERAL SENSATION (TOUCH AND PAIN) TO THE TONGUE

- The lingual nerve branch of the mandibular division of the trigeminal nerve (fifth CN) provides general sensation of touch and pain to the *anterior two thirds* (body) of the tongue.
- Glossopharyngeal nerve (ninth CN) is responsible for general sensation (touch, pain) in the *posterior one third* (or root) of the tongue.

### 2. NERVES FOR TASTE IN THE TONGUE

- Facial nerves (seventh CN), chorda tympani branches provides taste sensation to *anterior two thirds* (body) of tongue.
- Glossopharyngeal nerve (ninth CN) is responsible for taste in the *posterior one third* (or root) of the tongue.

### 3. NERVES TO THE TONGUE MUSCLES

- Hypoglossal nerve (12th CN) supplies motor fibers to the muscles of the tongue.

### 4. NERVES TO THE MAJOR MUSCLES OF MASTICATION

- The motor branches of the mandibular division of the fifth CN supply the masseter (masseteric nerve),

the temporalis (temporalis nerves), and the medial and lateral pterygoid (pterygoid nerve branches).

## 5. NERVES TO MOST MUSCLES OF FACIAL EXPRESSION

- Facial nerve (seventh CN) supplies most muscles of facial expression.

## 6. SECRETORY FIBERS TO SALIVARY GLANDS

- Facial nerves (seventh CN) supply the submandibular and sublingual salivary glands.
- Glossopharyngeal nerve (ninth CN) supplies the parotid salivary glands.

## 7. NERVES TO THE SKIN OF THE FACE

- CN V supplies all sense of feeling (touch/pain) to the skin of the face through branches of the ophthalmic division (upper face), maxillary division (middle face), and mandibular division (lower face).

## LEARNING EXERCISES

- Describe the pathway of the branches of the **mandibular division** of the fifth CNs as they pass from the brain toward their target organs (especially the teeth and surrounding soft tissue). Name the location where branches split off of the main nerves, and name the foramina through which each branch passes. Then, if it is possible on your study skull, take a pipe cleaner and carefully pass it through the foramina to show the passageway of these nerves. Think about where these nerves might be reached by an anesthetic syringe needle and what structures would be anesthetized if anesthetic deposited in that location blocked nerve impulses from all branches of that nerve that are farther away from the brain.
- Repeat the previous exercise for the branches of the **maxillary division**.
- Sketch the dorsal view of the tongue and label which nerves innervate the anterior two thirds and posterior one third for general sensation, taste, and movement (muscles).
- List all 12 CNs in order and state their functions.
- Review all words in bold that have phonetic spelling to confirm that your pronunciation is correct.

## Review Questions

Select the one best answer.

- The branches of which nerve cause the masseter muscle fibers to contract, thus squeezing the teeth together?
  - CN V: maxillary division
  - CN V: mandibular division
  - CN V: ophthalmic division
  - Facial nerve
  - Lingual nerve
- Which of the following nerve branches does not need to be anesthetized in order to block the sensation of pain to the pulp and all surrounding bone and gingiva of tooth No. 27 prior to an extraction?
  - Buccal nerve
  - Mental nerve
  - Incisive nerve
  - Inferior alveolar nerve
  - Lingual nerve
- Which two nerves branch off the infraorbital nerve while it is in the infraorbital canal?
  - MSA and PSA
  - ASA and MSA
  - PSA and ASA
  - MSA and nasopalatine
  - Nasopalatine and greater palatine
- Anesthetizing nerve fibers of what nerve results in numbness in half of the anterior two thirds of the tongue?
  - Hypoglossal nerve
  - Glossopharyngeal nerve
  - Lingual nerve branch of the trigeminal nerve
  - Lingual nerve branch of the facial nerve
- The nerve branch of the trigeminal that provides pain sensation to the mandibular teeth exits the skull through what foramen?
  - Foramen ovale
  - Foramen rotundum
  - Mandibular foramen
  - Mental foramen
  - Infraorbital foramen

ANSWERS: 1—b, 2—a, 3—b, 4—c, 5—a

## SECTION V

### VESSELS ASSOCIATED WITH THE ORAL CAVITY (ARTERIES, VEINS, AND LYMPHATIC SYSTEM)

#### OBJECTIVES

The objectives for this section are to prepare the reader to perform the following:

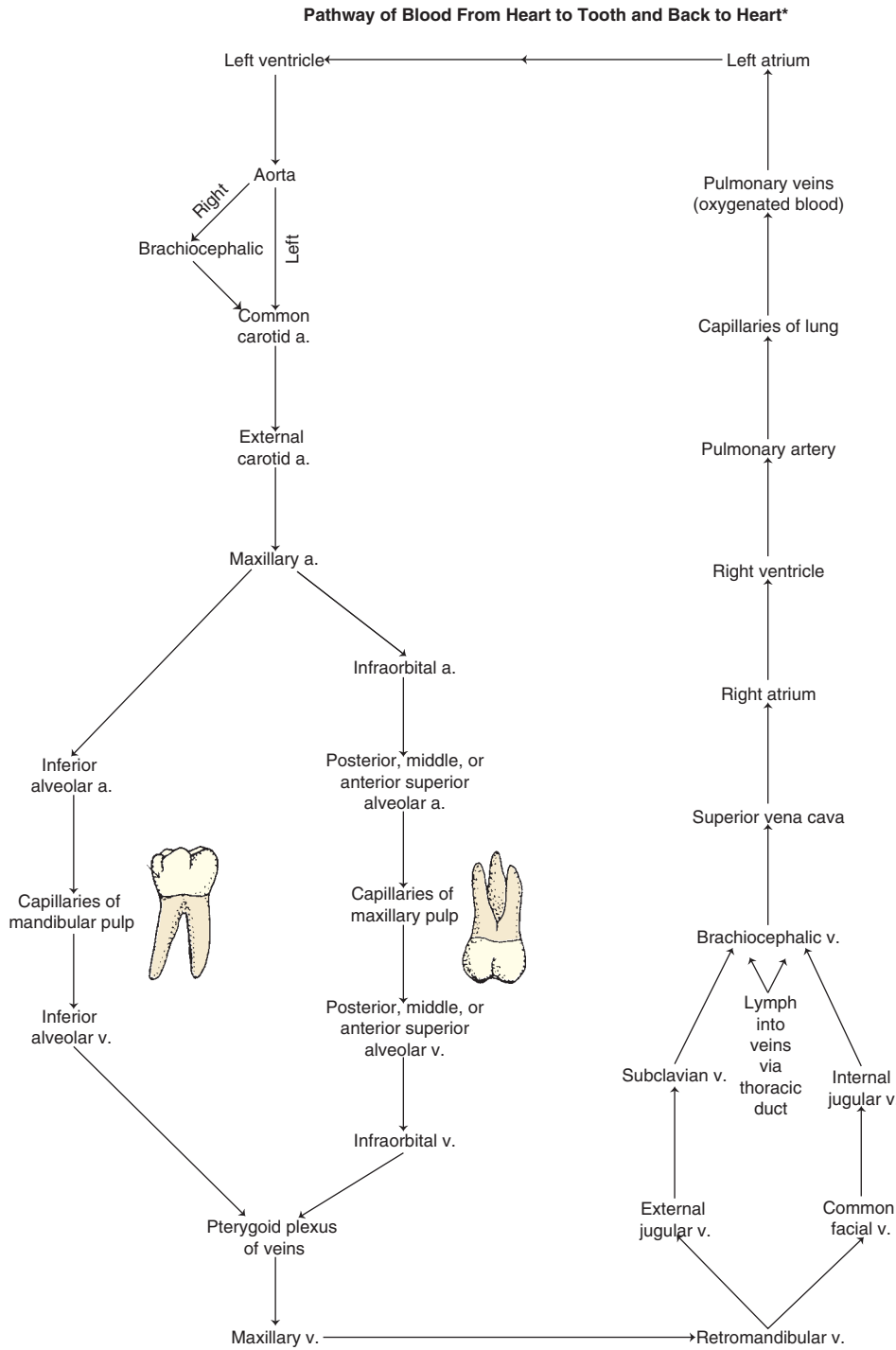
- Trace blood through the major blood vessels (arteries) from the heart to the teeth and back (through major veins) to the heart.
- Describe the pathway (fossa, spaces, etc.) of the key arteries that supply the teeth and, where possible, feel the pulse.
- Trace the route of infection from teeth and associated oral structures as it passes through the lymph system.
- Palpate the location of lymph nodes associated with the spread of infection of the oral cavity.

Arteries that move blood from the heart to the face and oral cavity meet up with nerves from the brain that innervate the face and oral cavity. Arteries and nerves of the same name begin to parallel one another somewhere in the neck or on the face. They may pass through the same foramen and canals within bones after they meet. Generally, arteries of the face and jaw run a more wiggly or corkscrew course than do veins.

#### A. ARTERIES

Refer to the pathway of blood from the heart to the teeth in *Figure 14-47*. Blood courses from the left ventricle of the heart through the aorta to the common carotid artery, which ascends in the neck and divides into the external carotid [kah ROT id] artery (*Fig. 14-48*) and internal carotid artery. The external carotid artery gives off the maxillary branches supplying structures in the





**FIGURE 14-47.** Pathway of blood from the heart to the teeth and back to the heart.

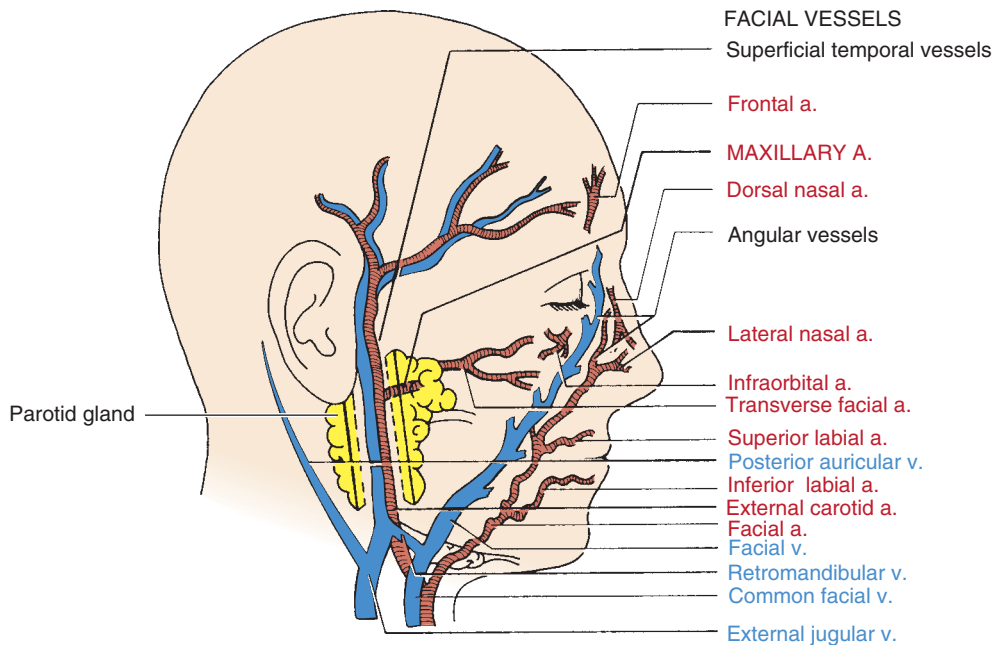
\*Think in terms of a drop of blood making this round trip.

mouth (maxillary and mandibular), and the internal carotid artery enters the skull through the carotid canal and does not supply the mouth. You can feel the pulse of the external carotid just in front of the sternocleidomastoid muscle as required during cardiopulmonary resuscitation training.

As the external carotid passes superiorly, it gives off three important branches to the mouth: the lingual,

facial, and maxillary arteries. First, the **lingual artery** (not seen on Fig. 14-48) comes off near the hyoid bone, and then enters the tongue. Like the *lingual nerve*, this artery supplies the floor of the mouth, adjacent gingiva, and the sublingual gland.

Second, the **facial artery** (Fig. 14-48) comes off just superior or with the lingual artery. It then passes forward obliquely inferior to the submandibular gland,



**FIGURE 14-48.** Facial vessels.

The parotid gland (yellow) is split apart to show the **external carotid artery**, with the **maxillary artery** coming off and passing deep to this gland. Arteries are shaded red; veins are blue.

then laterally around the lower border of the mandible. The facial artery and *facial nerve* pass together through a shallow notch on the inferior border of the mandible just anterior to the insertion of the masseter muscle. This notch is called the **antegonial notch** (recall Fig. 14-14). This is an important landmark to be aware of so that you will be able to stop the flow of blood to the lower part of the face in an emergency. Try to find the facial artery in the antegonial notch with your finger or thumb. You should feel the pulse of the facial artery if you are in the correct spot. From here, the facial artery goes upward over the outer surface of the mandible to the face.

There are four branches of the *facial artery* that will be described here. The **ascending palatine artery** comes off at the highest point of the first bend of the facial artery before it passes onto the face, and it ascends to supply structures adjacent to the pharynx (including the soft palate, the pharyngeal muscles, the mucosa of the pharynx, and the palatine tonsil). The **submental artery**, which converges with the mylohyoid nerve, supplies structures in the floor of the mouth (such as the mylohyoid muscle, anterior belly of the digastric muscle, and lymph nodes inferior to the mylohyoid muscle). After passing onto the face, the **inferior and superior labial arteries** (Fig. 14-48) surround and supply the lips and the orbicularis oris muscle. **Lateral nasal and angular arteries** are the terminal branches of the facial arteries.

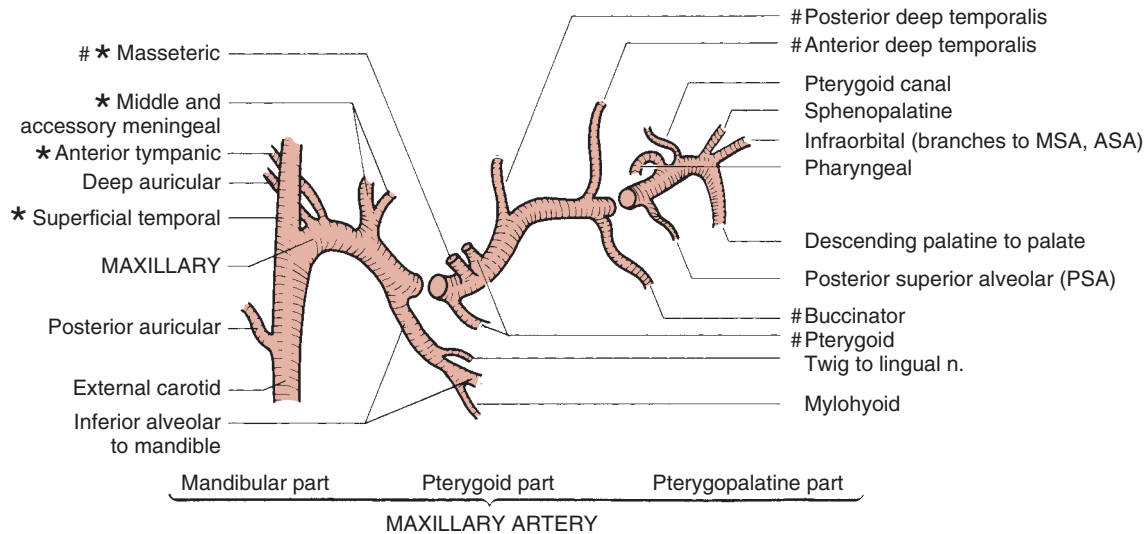
There is considerable merging at the midline of the arteries from both sides of the face, rather than the more conventional system whereby an artery terminates with many small capillaries. This merging of small arteries

from opposite sides is called an end-to-end anastomosis [a NAS te MO sis]. One example is where the right and left superior and inferior labial arteries join at the midline. As one might guess, such an anastomosis can cause problems in arresting hemorrhage on the face.

The third branch of the external carotid artery is the **maxillary artery**, which is probably the most important artery to the dentist and dental hygienist. It arises from the external carotid within the parotid gland (Fig. 14-48). The branches of this artery can be considered in three parts as shown in Figure 14-49. The branches of the *mandibular* and *pterygopalatine part* (or first and third parts) are directly involved with the blood supply to the mandibular and maxillary teeth, respectively. The branches of the *pterygoid part* (or middle part) provide blood to the four pairs of muscles of mastication. Study Figure 14-49 as you read about the following branches of each part of the maxillary artery. Also, notice the similarity between the names of the vessels and the names of the nerves that supply the same structures.

- **Mandibular Part of the Maxillary Artery: Arteries to the Mandible**

Branches coming off of the *mandibular* (or first) part of the maxillary artery supply the mandibular teeth and their periodontal ligaments. You read correctly: branches of the maxillary artery supply the mandible. The **inferior alveolar artery**, which, like the *inferior alveolar nerve*, enters the mandible through the mandibular foramen, supplies branches to the mandibular molars and premolars. It then divides into two branches: the **mental artery**, which exits from the mental foramen to the lower lip



**FIGURE 14-49.** Maxillary artery and the branches of its three major parts: The branches of the *mandibular part* supply blood to the mandible and teeth, the *pterygoid part* supplies the muscles of mastication, and the *pterygopalatine part* supplies the maxillae and teeth. Vessels labeled with (\*) are branches to the TMJ. Branches labeled with (#) supply blood to muscles of mastication.

and chin, and the **incisive artery**, which continues forward within the mandible to supply the anterior teeth (similar to the path of nerves of the same name seen in the mandible in Fig. 14-43).

- **Pterygoid Part of the Maxillary Artery: Arteries to the Muscles**

Branches coming off of the *pterygoid (or second) part* of each maxillary artery are not involved directly with the teeth but supply blood to the muscles of mastication (posterior and anterior deep temporalis, masseteric, and pterygoid branches) and a buccinator branch.

- **Pterygopalatine Part of the Maxillary Artery: Arteries to the Maxillae**

Branches that come off of the *pterygopalatine (or third) part* of the maxillary artery supply the maxillary teeth and their periodontal ligaments. The **PSA artery** traverses the maxillary sinus, and, like the PSA nerve, supplies the maxillary molars. While within the infraorbital canal, the **infraorbital artery**, like the infraorbital nerve, gives off the **MSA artery** that supplies the premolars, and the **ASA artery**, which supplies the anterior teeth. Each **descending palatine** branch of the maxillary artery supplies part of the nasal cavity before it emerges onto the palate through the greater palatine foramen (Fig. 14-39) like the nerves to supply the mucosa of the hard and soft palate and the lingual gingiva. Its terminal part ascends through the incisive canal into the nasal cavity.

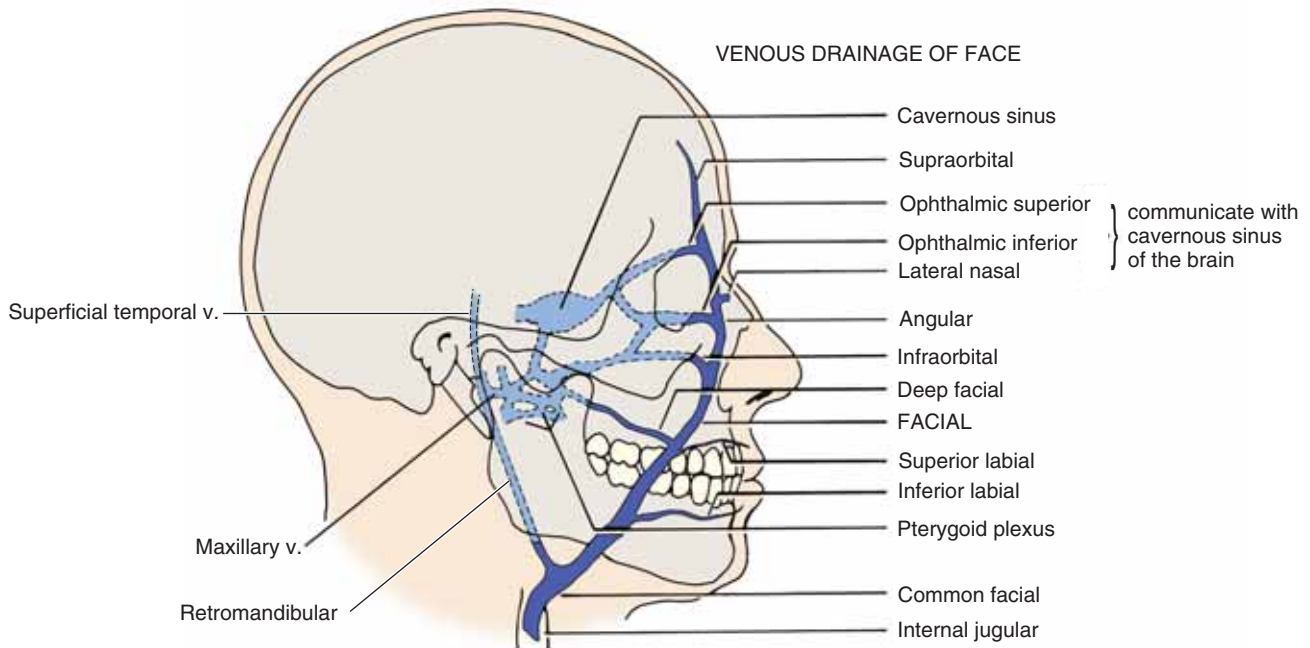
The TMJ is supplied with oxygenated blood from five branches: the ascending pharyngeal (not visible

in figure) and superficial temporal branches of the external carotid artery and by the anterior tympanic, masseteric, and middle meningeal branches of the maxillary artery (Fig. 14-49).

## B. VEINS

Veins tend to be straighter than arteries.<sup>30,31</sup> In many instances, they travel almost the same course as arteries. There are no valves in any of the facial veins. Therefore, an infection in the face can travel through veins in either direction. Veins that drain blood from the face on its way back to the heart are shown in Figure 14-50.

Numerous veins drain blood from the maxillary and mandibular teeth and adjacent tissues into a pterygoid plexus. The **pterygoid [TER i goid] plexus** is a network of veins medial to the upper part of the ramus of the mandible, located between the temporal and lateral pterygoid muscles, or between the lateral and medial pterygoids.<sup>31</sup> This plexus collects blood through deep veins that drain the upper part of the face, the tissue of the lips and muscles around the mouth, the posterior part of the nasal cavity, the palate, the maxillary alveolar process, and maxillary teeth. Also, **inferior alveolar veins** (not visible in Fig. 14-50) carry blood to the pterygoid plexus from the mandible and its teeth, that is, from the area of the oral cavity supplied by the inferior alveolar artery (and the area innervated by the inferior alveolar nerve). The dense venous plexus that surrounds the maxillary artery helps protect it from



**FIGURE 14-50.** Venous drainage of the face: The dotted lines represent deeper (less superficial) vessels. Notice how many veins come together in the **pterygoid plexus** of veins, an area prone to bleeding if the anesthetic syringe cuts any vessel wall within this plexus.

becoming flattened when the masticatory muscles contract. During muscle contractions, however, blood is driven from the veins.<sup>31</sup>

The veins of the pterygoid plexus empty into the short **maxillary vein**.

While within the parotid gland, blood from the maxillary vein (and from the superficial temporal vein) passes into the **retromandibular vein** to drain those areas that had received blood through the maxillary and superficial temporal arteries. The retromandibular vein drains into the facial vein where it becomes the short **common facial vein** that then empties into the **internal jugular vein**.

An important superficial vein that also drains blood from the face is the **facial vein**, which roughly follows the course of the facial artery but, of course, carries blood in the opposite direction. The facial vein receives blood from the area around the eyes and nose (via the angular and lateral nasal veins), and receives blood from the lips (via the superior and inferior labial veins). It can also receive blood from the muscles of mastication. Just like the retromandibular vein, the facial vein empties through the common facial vein into the **internal jugular vein**. Blood from the tongue drains through **lingual veins** (not visible on Fig. 14-50) that also empties into the **internal jugular vein** (possibly via the common facial vein).

Venous drainage of the face becomes even more complex when you consider that there is a **deep facial vein**, which connects the deeper pterygoid plexus with the more superficial facial vein. Since the deep facial vein has no valves, blood from the head can make its way down to the **internal jugular vein** either through the pterygoid plexus and retromandibular vein, or through the facial vein and its branches.

Once blood reaches the **internal jugular vein**, it passes into the brachiocephalic vein, to the superior vena cava, then through the heart and lungs to become oxygenated before being pumped back to the mouth (Fig. 14-47).

## LEARNING EXERCISES

Draw the route of a drop of blood from the heart to both maxillary and mandibular teeth and then back to the heart as shown in Figure 14-47. Name each vessel along the way. Try to visualize this interesting round trip, which takes place about every 10 to 15 seconds. Remember, the maxillary artery and its branches are probably the most important to the dentist or dental hygienist.



### C. LYMPH VESSELS

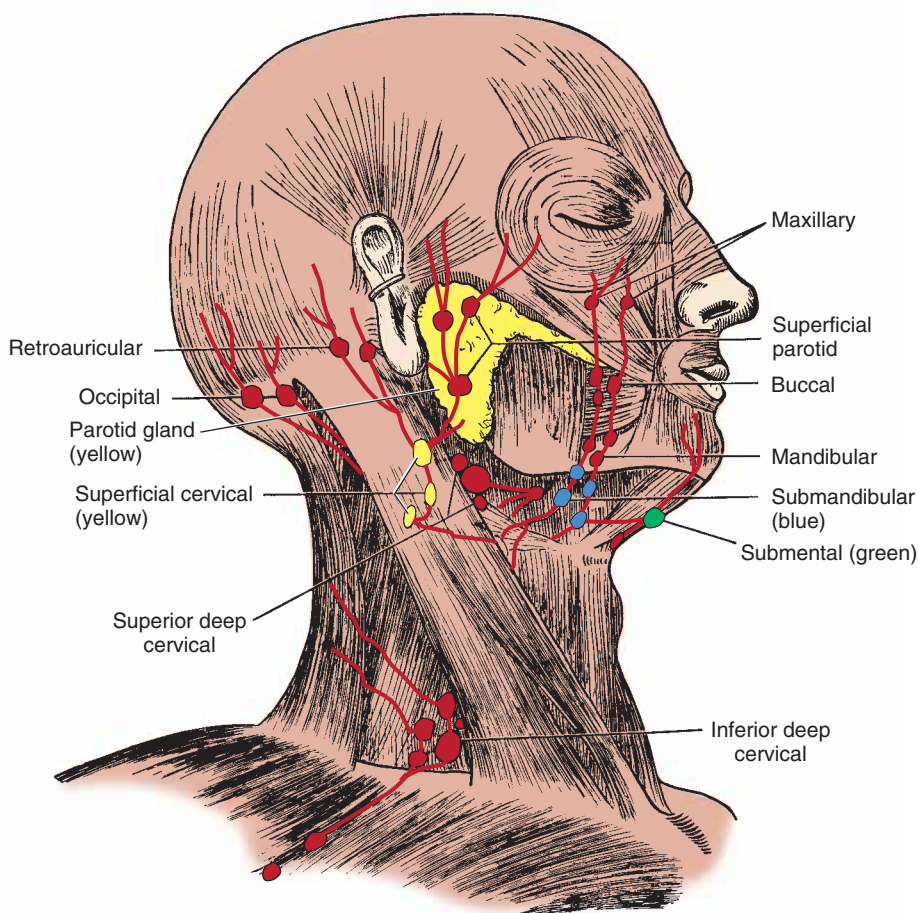
The lymph system is somewhat more complex<sup>32</sup> since it serves to collect tissue fluid that got outside the blood capillary bed and then return this fluid to the vascular system. In the arterial side of a capillary bed, blood pressure exceeds osmotic pressure, so fluid escapes into the tissue spaces. On the venous side of each capillary bed, the blood pressure is lower, and the osmotic pressure becomes higher, forcing 90% of the tissue fluid back into the venous capillary bed.<sup>33</sup> The major bulk of the remaining 10% of the fluid is the lymph, which passes into the lumen of lymph capillaries and is then collected in the nodes (shown in Fig. 14-51) and returned to the blood vascular system.

During times of infection, trauma, or cancerous growth, abnormal amounts of fluids escape (along with specialized cells to fight infection, etc.), and this results in swollen lymph glands. Since lymph nodes form chains that are then connected by lymph vessels,

infection spreads predictably from the site of infection to a specific lymph node, which then drains to another until the lymph system empties back into the veins. The spread pattern is as follows. Refer to Figure 14-51 while reading.

Infection in the area of the chin and adjacent structures including the tip of the tongue and tissues surrounding the mandibular incisors—anterior floor of the mouth, lower lip, and adjacent gingiva (gum tissue)—all drain into the **submental nodes** just lingual to the mandibular symphysis area. When enlarged, these nodes can be palpated just posterior to the symphysis area of the mandible.

The **submandibular chain of nodes** is located over the surface of the submandibular salivary gland and can be palpated medial but anterior to the angle of the mandible, with the most prominent node in this chain located over the facial artery medial to the antegonial notch. The **submental nodes** drain into the subman-



**FIGURE 14-51.** Lymph nodes of the head and neck: These areas should be palpated during a head and neck examination. **Submental** nodes are green, **submandibular** nodes are blue, and **superficial cervical** nodes are yellow. (Reproduced from Clemente CD, ed. Gray's anatomy of the human body. 30th ed. Philadelphia, PA: Lea & Febiger, 1985:880, with permission.)

dibular nodes. Also, the submandibular nodes drain most other intraoral structures, including all maxillary and mandibular teeth, facial and palatal gingiva or gum tissue (except around the mandibular anterior teeth), posterior floor of the mouth, sides of the tongue anteriorly (but not the tip), cheek and side of the nose, and upper lip and lateral lower lip; the maxillary sinus drains into the **submandibular nodes**.

**Parotid** [pa ROT id] (or preauricular) **nodes**, located over the parotid gland in front of the ear, receive lymph from the area around the parotid gland, including the adjacent scalp, ear, prominence of the cheek, and eyelids. The parotid and submandibular nodes, as well as excess lymph resulting from a sore throat (inflamed tonsils and pharynx), drain into the **deep and superficial cervical chain of nodes**. These are located along the large sternocleidomastoid neck muscles. To cite an example of the spread of infection, if an infection like a pimple or aphthous ulcer formed on the lower lip, it would drain into the mental nodes, which would in turn drain into the submandibular nodes, which in turn, along with parotid nodes from the side of the face, would drain into the cervical

nodes. An enlarged cervical node could be the result of the lower lip infection.

From here, the lymph returns via the venous drainage of the cardiovascular system. On the left side, drainage is through the **thoracic** [tho RAS ik] **duct**, which empties into veins at the junction of the **left subclavian** [sub CLAY vi an] **and internal jugular veins**, which ultimately form the **brachiocephalic** [BRAY ki o se FAL ik] **vein**. On the right side, lymph empties into the junction of the **right subclavian and internal jugular veins**.

### LEARNING EXERCISES

- Describe the pathway by which an infection (or cancer cells) might spread from a maxillary tooth to the neck through the lymph system, and then through the venous system.
- Describe the pathway by which an infection might spread from a mandibular anterior tooth to the neck through the lymph system and then through the venous system.

## Review Questions

Select the one best answer.

1. Which node would first show enlargement from an infection of a mandibular incisor?
  - a. Submental
  - b. Submandibular
  - c. Parotid
  - d. Cervical
  - e. Preauricular
2. At what location would you palpate the cervical lymph node chain?
  - a. Around the sternocleidomastoid muscle
  - b. Near the symphysis of the mandible
  - c. Over the submandibular gland
  - d. Behind the ear
  - e. Over the parotid gland
3. Branches of what artery supply blood to the mandibular teeth?
  - a. Maxillary artery
  - b. Masseteric artery
  - c. Pterygoid artery
  - d. Pterygopalatine artery
  - e. Superficial temporal artery
4. Branches of what artery supply blood to the maxillary teeth?
  - a. Maxillary artery
  - b. Masseteric artery
  - c. Pterygoid artery
  - d. Pterygopalatine artery
  - e. Superficial temporal artery

ANSWERS: 1—a, 2—a, 3—d, 4—a

## SECTION VI

## STRUCTURES VISIBLE ON A PANORAMIC RADIOGRAPH

## OBJECTIVES

The objective for this section is to prepare the reader to perform the following:

- Based on relative location and shape, identify key structures already discussed in this text as they appear on a panoramic radiograph.

Now that you have learned the location and shape of many bony structures within the head, it is possible to look at a radiograph and identify many of these structures based on their shape and location. In order to do this, you need to know that the denser structures in the head (especially the bones and teeth) will appear on the radiograph as the lightest (more white or radiopaque). Further, the least dense structures in the head (like foramina passing through bones, sinuses, and nerve

canals) will appear on the radiograph as darker structures (called radiolucent). Finally, a *panoramic radiograph* can be taken with a device that rotates around the jaws so that the operator can view structures from the right, front, and left on one film. It is as though you could take the horseshoe-shaped mandible with its teeth and rami and flatten it out with its inner surface lying flat on a table and the outer (lateral) surface visible as one flat object.

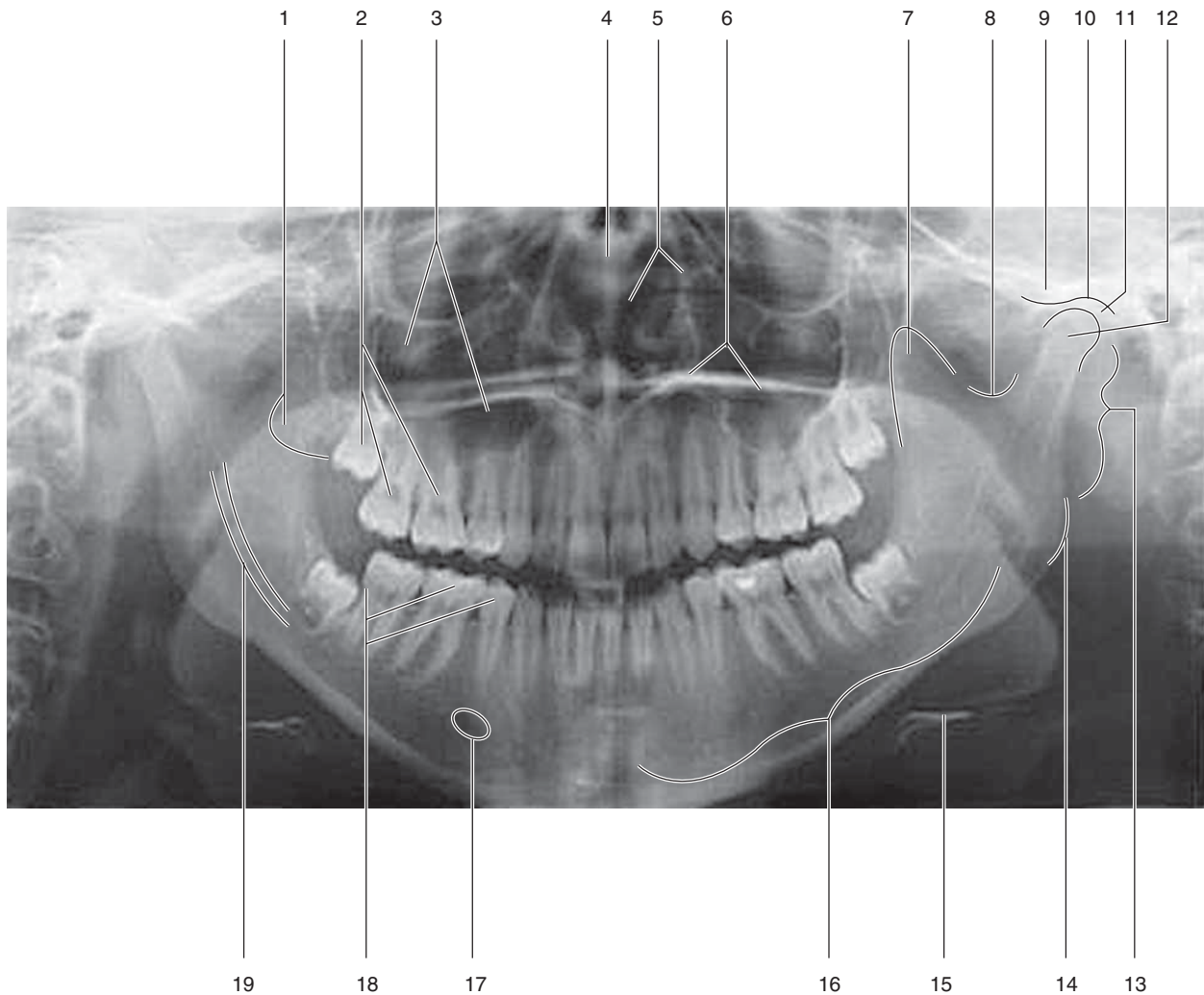
## LEARNING EXERCISE

With this simple background, and your knowledge of the shape and location of structures in the skull, study the radiograph in *Figure 14-52* and see how many of the following structures you can identify without looking at the answers. MATCH the following lettered items with the corresponding number and arrow on the radiograph. Use the clues only if needed.

- A. **Mandibular teeth.** Note that each tooth has one or more roots embedded into the bony (opaque) alveolar processes. How many are there? Can you see the radiolucent, very thin (almost invisible) periodontal ligaments around each root?
- B. **Maxillary teeth.** Note that each tooth has one or more roots embedded into the bony (opaque) alveolar processes. How many are there?
- C. **Body of the mandible**
- D. **Angle of the mandible**  
(Clue: It is the inferior posterior corner of the horizontal body of the mandible where it joins the vertical ramus.)
- E. **Ramus**  
(Clue: It is the vertical part of the mandible.)
- F. **Coronoid process**  
(Clue: It is shaped like the point of a king's crown.)

## Learning Exercise, cont.

- G. **Condylar process**  
(Clue: It articulates within the concavity of the temporal bone called the mandibular [articular] fossa).
- H. **Sigmoid notch**  
(Clue: This notch is between the coronoid and condyloid processes.)
- I. **Mandibular canal**  
(Clue: It is a radiolucent canal with its mandibular foramen where the inferior alveolar nerve enters the mandible.)
- J. **Mental foramen**  
(Clue: It is a radiolucent circle near the ends of the premolar roots where the mental nerve branch of the inferior alveolar nerve splits off and exits the mandible to innervate the lower lip and chin on that side.)
- K. **Maxillary tuberosity**  
(Clue: It is the bump of bone behind the last maxillary molar.)
- L. **Maxillary sinus.** Note its proximity to the roots of the maxillary molars and premolars.
- M. **Hard palate** composed of the palatal processes of maxillae and palatine bones
- N. **Mandibular (articular) fossa**  
(Clue: It is the depression on the base of the cranium in the temporal bone where the condyle of the mandible fits.)



**FIGURE 14-52.** A panoramic radiograph (Panorex) shows many of the structures of the skull. Test your ability to identify these structure based on their shape and relative location by matching the letter of a description (A–S) with the number of each structure (1–19). (Radiograph courtesy of Dr. R. M. Jaynes, DDS, Assistant Professor at Ohio State University.)

#### Learning Exercise, cont.

##### O. Articular eminence

(Clue: It is the opaque bump of temporal bone anterior to the mandibular fossa that deflects the condyles and the mandible downward [opening the mouth] as it moves forward.)

##### P. Articular disc space

(Clue: It is a radiolucency between the condyle and the fossa.)

##### Q. Nasal passageway (also called nasal fossa)

(Clue: This hollow radiolucent space is located superior to the maxillary anterior teeth.)

##### R. Nasal septum: VOMER and vertical plate of ETHMOID bone

#### Learning Exercise, cont.

(Clue: The septum separates the right and left halves of the nasal passageways.)

##### S. Hyoid bone

(Clue: This bone appears to float below the mandible since the infra- and suprahyoid muscles attached to it are radiolucent and are not visible.)

**ANSWERS:** A—18 (there are 14 mandibular teeth; two premolars are missing). B—2 (there are 14 maxillary teeth; two premolars are missing), C—16, D—14, E—13, F—7, G—12, H—8, I—19, J—17, K—1, L—3, M—6, N—10, O—9, P—11, Q—5, R—4, S—15



## REFERENCES

1. Clemente CD, ed. *Gray's anatomy of the human body*. 30th ed. Philadelphia, PA: Lea & Febiger, 1985.
2. Roman-Ruiz LA. The mental foramen: a study of its positional relationship to the lower incisor and premolar teeth [Master's Thesis]. Columbus, OH: Ohio State University, College of Dentistry, 1970.
3. Sicher H, DuBrul EL. *Oral anatomy*. 7th ed. St. Louis, MO: C.V. Mosby, 1975:174–209.
4. Edwards LF, Gaughran GRL. *Concise anatomy*. 3rd ed. New York, NY: McGraw-Hill, 1971.
5. Hickey JC, Allison ML, Woelfel JB, et al. Mandibular movements in three dimensions. *J Prosthet Dent* 1963;13:72–92.
6. Hickey JC, Woelfel JB, et al. Influence of occlusal schemes on the muscular activity of edentulous patients. *J Prosthet Dent* 1963;13:444–451.
7. Woelfel JB, Hickey JC, Rinear L. Electromyographic evidence supporting the mandibular hinge axis theory. *J Prosthet Dent* 1957;7:361–367.
8. Woelfel JB, Hickey JC, Stacy RW. Electromyographic analysis of jaw movements. *J Prosthet Dent* 1960;10:688–697.
9. Woelfel JB, Hickey JC, Allison ML. Effect of posterior tooth form on jaw and denture movement. *J Prosthet Dent* 1962;12:922–939.
10. Melfi RC. *Permar's oral embryology and microscopic anatomy*. 8th ed. Philadelphia, PA: Lea & Febiger, 1988:247–257.
11. Sharry JJ. *Complete denture prosthodontics*. New York, NY: McGraw-Hill, 1962:45–86.
12. Ricketts RM. Abnormal function of the temporomandibular joint. *Am J Orthod* 1955;41:425, 435–441.
13. Burch JG. Activity of the accessory ligaments of the temporomandibular joint. *J Prosthet Dent* 1970;24:621–628.
14. Turell J, Ruiz HG. Normal and abnormal findings in temporomandibular joints in autopsy specimens. *J Craniomandib Disord Facial Oral Pain* 1987;1:257–275.
15. Osborn JW, ed., Armstrong WG, Speirs RL. *Anatomy, biochemistry and physiology*. Oxford: Blackwell Scientific Publications, 1982:324–343.
16. Haines RW. On muscles of full and of short action. *J Anat* 1934;69:20–24.
17. Gionhaku N, Lowe AA. Relationship between jaw muscle volume and craniofacial form. *J Dent Res* 1989;68:805–809.
18. Montgomery RL. *Head and neck anatomy with clinical correlations*. New York, NY: McGraw-Hill, 1981:202–214.
19. Winter CM, Woelfel JB, Igarashi T. Five-year changes in the edentulous mandible as determined on oblique cephalometric radiographs. *J Dent Res* 1974;53(6):1455–1467.
20. Kraus B, Jordan R, Abrams L. *Dental anatomy and occlusion*. Baltimore, MD: Williams & Wilkins, 1969:203–222.
21. Basmajian JV. *Grant's medical method of anatomy*. 9th ed. Baltimore, MD: Williams & Wilkins, 1975.
22. Edwards LF, Gaughran GRL. *Concise anatomy*. 3rd ed. New York, NY: McGraw-Hill, 1971.
23. Sicher H, DuBrul EL. *Oral anatomy*. 6th ed. St. Louis, MO: C.V. Mosby, 1975:344–378.
24. Crum RJ, Loisel RJ. Oral perception and proprioception. A review of the literature and its significance to prosthodontics. *J Prosthet Dent* 1972;28:215–230.
25. Jerge CR. Organization and function of the trigeminal mesencephalic nucleus. *J Neurophysiol* 1963;26:379–392.
26. Renner RP. *An introduction to dental anatomy and esthetics*. Chicago, IL: Quintessence Publishing, 1985:162.
27. Jenkins GN. *The physiology of the mouth*. 3rd ed. Revised reprint. Oxford: Blackwell Scientific Publications, 1970: 310–328.
28. Kawamura Y, Kare MR. *Umami: a basic taste*. New York, NY: Marcel-Dekker, 1987.
29. Osborn JW, ed. *Anatomy, biochemistry and physiology*. Oxford: Blackwell Scientific Publications, 1982:542.
30. Edwards LF, Gaughran GRL. *Concise anatomy*. 3rd ed. New York, NY: McGraw-Hill, 1971.
31. Sicher H, DuBrul EL. *Oral anatomy*. 7th ed. St. Louis, MO: C.V. Mosby, 1980:351–376.
32. Montgomery RL. *Head anatomy with clinical correlations*. New York, NY: McGraw-Hill, 1981:75–82.
33. Paff GH. *Anatomy of the head and neck*. Philadelphia: W.B. Saunders, 1973.
34. Osborn JW, ed. *Dental anatomy and embryology*. Oxford: Blackwell Scientific Publications, 1981.
35. Montgomery RL. *Head and neck anatomy with clinical correlations*. New York, NY: McGraw-Hill, 1981.
36. Brand W, Isselhard B. *Anatomy of orofacial structures*. 5th ed. St. Louis, MO: C.V. Mosby, 1994.
37. Francis CC. *Introduction to human anatomy*. 6th ed. St. Louis, MO: C.V. Mosby, 1973.
38. Osborn JW, ed. *Anatomy, biochemistry and physiology*. Oxford: Blackwell Scientific Publications, 1982.

## GENERAL REFERENCES

- Ash MM. *Wheeler's dental anatomy, physiology and occlusion*. 7th ed. Philadelphia, PA: W.B. Saunders, 1993.
- Clemente CD, ed. *Gray's anatomy of the human body*. 30th ed. Philadelphia, PA: Lea & Febiger, 1994.
- Clemente CD. *Anatomy: a regional atlas of the human body*. 4th ed. Baltimore, MD: Williams & Wilkins, 1997.
- Dorland's illustrated medical dictionary. 28th ed. Philadelphia: W.B. Saunders, 1985.
- Fehrenbach MJ, Herring SW. *Illustrated anatomy of the head and neck*. Philadelphia, PA: W.B. Saunders, 1996.
- Reed GM, Sheppard VF. *Basic structures of the head and neck*. Philadelphia, PA: W.B. Saunders, 1976.
- Travers JB, Travers SP. *Physiology of the oral cavity*. In: Cummings CW, ed. *Otolaryngology head and neck surgery*, vol. 2, 4th ed. Philadelphia, PA: Elsevier Mosby, 2005.
- Web site: <http://education.yahoo.com/reference/gray/>—Bartleby.com edition of *Gray's Anatomy of the Human Body*

# Oral Examination: Normal Anatomy of the Oral Cavity

Topics covered within the two sections of this chapter include the following:

- I. Extraoral examination: normal structures
  - A. General appearance
  - B. Head
  - C. Skin and underlying muscles of mastication
  - D. Eyes
  - E. Temporomandibular joint
  - F. Neck
  - G. Lymph nodes
  - H. Salivary glands (extraoral)
  - I. Lips
- II. Intraoral examination: normal structures as well as landmarks for placing local anesthetic
  - A. Labial and buccal mucosa: vestibule and cheeks
  - B. Palate: roof of the mouth
  - C. Oropharynx: fauces, palatine arches, and tonsils
  - D. Tongue
  - E. Floor of the mouth
  - F. Salivary glands (intraoral)
  - G. Alveolar process
  - H. Gingiva
  - I. Teeth (count them)

## OBJECTIVES

This chapter is designed to prepare the learner to perform the following:

- While systematically following all of the steps suggested for a thorough head and neck (cancer screening) examination, identify and describe all normal structures found during an extraoral and intraoral examination.
- Describe the location and palpate (examine by touching), if possible, the major muscles of mastication.
- Describe the location of the temporomandibular joint, and palpate the joint posteriorly and laterally to the condyles.
- Describe the location of the lymph nodes that drain the face and neck and palpate these areas.
- Describe the location of the major salivary glands, and palpate these areas.
- Describe the location for injecting anesthetic in order to anesthetize the teeth and surrounding structures.

Note: Specific research data and some of Dr. Woelfel's original research findings related to material covered in this chapter are referenced throughout by using superscript letters (like this<sup>A</sup>) and are then presented at the end of the chapter.

**ANATOMIC TERMS:** Familiarize yourself with following anatomic terms before reading this chapter:

**Circumvallate** [sir kum VAL ate]: circum (around), vallate (valley or trench)

**Filiform:** shaped like a thread or filament

**Fornix:** referring to a vault-like space

**Frenum** [FREE num] (also **frenulum**; pl. **frena**): small fold of tissue that limits movement

**Fungiform** [FUN ji form]: shaped like a fungi or mushroom

**Linea alba** [LIN e a AL ba]: the white (alba) line (linea)

**Mastication** [MAS ti KA shen]: chewing food

**Vestibule:** entrance to the mouth; like an anteroom, known as a vestibule in an old house

During a head and neck (cancer screening) examination, the dental professional should evaluate all oral and surrounding structures for evidence of pathology. This examination begins with an evaluation of the patient's general health, and then involves an assessment of extraoral structures of the head and neck, followed by an intraoral examination that includes an evaluation of all structures from the lips to the throat. The purpose of a complete and thorough extraoral and intraoral examination is to identify any areas of pathology that might require follow-up or treatment. The primary purpose of this section is to describe *normal structures* that can be identified within the mouth so that deviations from normal can be distinguished. It should also help the reader describe the location of abnormal lesions relative to the location of normal adjacent structures, which is necessary when following the progression of changes of a lesion, or when referring a patient for a lesion biopsy. A secondary purpose of this chapter is to highlight landmarks that are helpful when injecting local anesthetic prior to dental treatment.

You should try to perform an examination on a partner after studying the description and location of each normal landmark. Keep in mind that soft tissue structures cover the bones of the skull and are supplied

by the nerves and blood vessels that were discussed in Chapter 14. As you study this material and examine the mouth, recall the location of underlying bony landmarks, nerves, and vessels.

## SECTION I

## EXTRAORAL EXAMINATION: NORMAL STRUCTURES

### A. GENERAL APPEARANCE

The first thing to notice during an initial meeting with a patient is his or her general appearance. You can obtain clues regarding possible health problems that have not yet been diagnosed, and you can begin to predict how well the patient will tolerate dental treatment. Notice the posture, gait, breathing, and general well-being during your greeting.

### B. HEAD

A close look at the head may reveal asymmetry of the head or a discrepancy in the relationship of the upper and lower jawbones. This could be important to identify swelling that could be a sign of pathology or infection, and when determining how to identify and treat problems with the occlusion.

### C. SKIN AND UNDERLYING MUSCLES OF MASTICATION

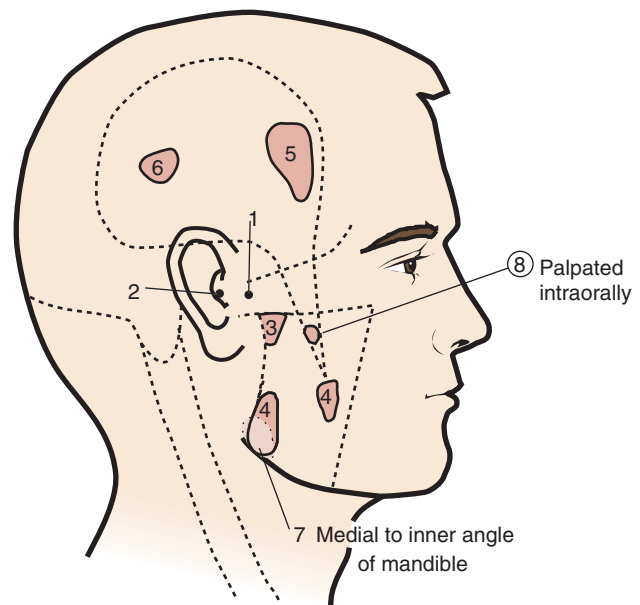
Observe the skin for any unusual lesions, and describe each lesion by location (relative to adjacent normal landmarks), size, and the person's knowledge of its history. The evaluator's knowledge of pathology will be helpful when distinguishing benign lesions from those requiring follow-up pathology consult and/or biopsy.

Muscles of the head and neck may be palpated to identify pain or tenderness that could be related to problems with the temporomandibular joint or an imbalance in the occlusion of the teeth (made worse when the person habitually clenches or squeezes the teeth together). For this reason, it is important to be able to locate and palpate these muscles where possible. You can palpate each muscle pair bilaterally by lightly massaging an area with the middle finger of each hand while using the index and fourth finger to palpate surrounding soft tissue to feel for unusual lumps or tenderness. Palpate these muscles on a partner while using *Figure 15-1* as a guide.

- **Masseter:** Feel the body of the masseter by palpating the bulge over the lateral surface of the mandible near the angle while your partner clenches the jaws

together. Move your finger down toward the angle of the mandible to feel the *insertion* (labeled No. 4 on Fig. 15-1), and move up toward the zygomatic arch (inferior border of the zygomatic bone and zygomatic process of the temporal bone) to feel the *origin* (labeled No. 3)

- **Medial pterygoid:** Feel the bulge when your partner clenches while palpating the medial surface of the angle of the mandible at the *insertion* (labeled No. 7). It may help to have your partner lean the head forward to relax the skin of the neck as you gently palpate upward and outward against the medial surface of the mandible near the angle, using the tips of your middle finger and forefinger. This may cause some discomfort.



**FIGURE 15-1.** Sites for palpation of temporomandibular joint and muscles of mastication (origin and insertion locations). 1. Lateral surface of mandibular condyle. 2. Posterior surface of mandibular condyle. 3. Masseter (origin). 4. Masseter (insertion). 5. Temporalis (anterior vertical fibers that close mandible). 6. Temporalis (posterior horizontal fibers that retract mandible). 7. Medial pterygoid. 8. Lateral pterygoid (palpated intraorally).

- **Temporalis, anterior fibers:** Palpate the *origin* of the *anterior* (vertical) fibers on the forehead just above a line between the eyebrow and superior border of the ear (labeled No. 5). Since these muscle fibers help close the mouth, see if you feel the bulge when your partner clenches the teeth.
- **Temporalis, posterior fibers:** Palpate the *origin* of the *posterior* (horizontal) fibers of the temporalis just above and posterior to the superior border of the ear (labeled No. 6). Since these muscle fibers are involved in retruding the mandible, see if you can feel a bulge when your partner retrudes (pulls back) the mandible.
- **Lateral pterygoid (intraoral palpation):** The lateral pterygoid can only be palpated intraorally. Feel this muscle by placing your little finger in the vestibule of the mouth behind the maxillary tuberosity (labeled No. 8). (Use a skull to see how to reach the lateral plate of the pterygoid process of the sphenoid bone.) With your partner's mouth slightly open and the mandible moved slightly toward the side being palpated, slide your little finger back toward the lateral pterygoid plate for the *origin* of the lateral pterygoid muscle. This may be uncomfortable to a patient even if the muscle is not sore. The anterior surface of the neck of the condyloid process is the location of part of the insertion of this muscle, but it cannot be palpated.

## D. EYES

The normally white part of the eyes (sclera) should be white and clear, not bloodshot, and not yellow (a possible indication of jaundice from liver disease). The thin layer of tissue covering the eyeball and reflected onto the inner surfaces of the eyelids (called the conjunctiva) should appear healthy and not be severely inflamed (red) or irritated (a possible sign of allergy or disease). The pupil (dark center opening surrounded by the colored iris) should not be severely pinpoint or dilated, both of which may be signs of disease or drug use.

## E. TEMPOROMANDIBULAR JOINT

Locate and palpate the *lateral* aspects of both mandibular condyles simultaneously by standing behind your partner and pressing your middle fingers over the skin just anterior to the external opening of the ear and inferior to the zygomatic arch while your partner opens wide and closes (Fig. 15-1, labeled No. 1). Feel the head of the condyle move as your partner opens and closes the mandible and moves the

mandible from side to side. Movement of the condyles during minimal opening of the mandible cannot be felt as easily as when the mouth is opened wide since the condyles and mandible only rotate around a line connecting the condyles (like a swing) during minimal opening, but the condyles and mandible move bodily (translate forward and downward over the articular eminences) when opening wide. Also, feel the condyles during lateral movement to see if you discern differences in movement on the right side versus the left side during movement to the right, then movement to the left. Sometimes you may feel a jerky movement accompanied by a clicking or popping sound. This is likely due to the head of the condyle slipping off of the articular disc.

Palpate the *posterior* surface of the mandibular condyle by placing your little fingers into each external auditory meatus (ear canal openings) and press anteriorly forward (Fig. 15-1, labeled No. 2). Feel the posterior surface of the condyles as your partner opens, closes, and moves the mandible laterally from side to side.

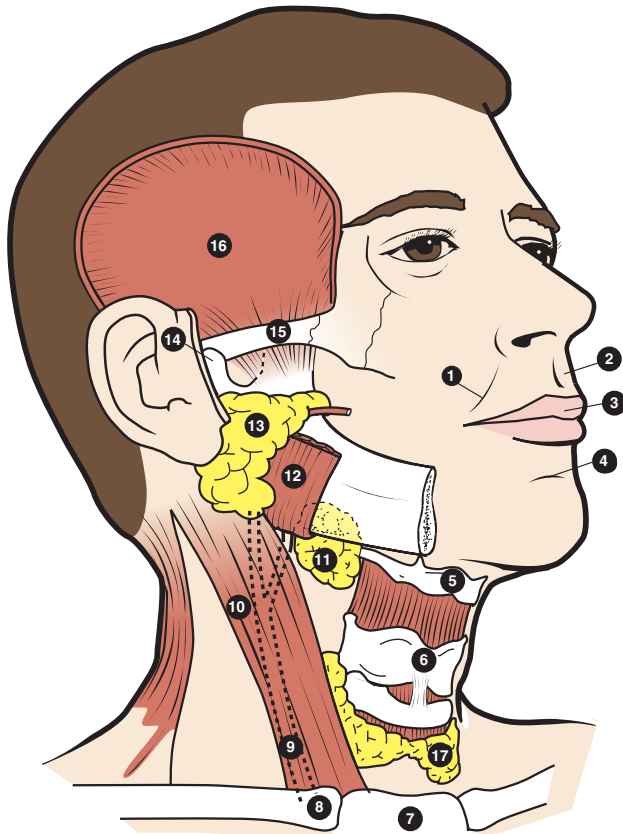
## F. NECK

The neck should be evaluated for symmetry and to confirm that there are no lumps or bumps. The thyroid gland (a major gland that secretes the thyroid hormone, which is responsible for controlling much of the metabolism of the body) is located in the neck. It is just inferior to the voice box (larynx or laryngeal prominence), and it is shaped somewhat like a butterfly with wings extending laterally on either side of the larynx (Fig. 15-2, labeled No. 17). This gland should be evaluated visually and palpated (as in Fig. 15-3) to ensure that there is no swelling (a possible goiter), which could be a sign of dysfunction of this gland and its output of thyroid hormone. Lymph nodes in the neck that are located around the sternocleidomastoid muscles are described next.

## G. LYMPH NODES

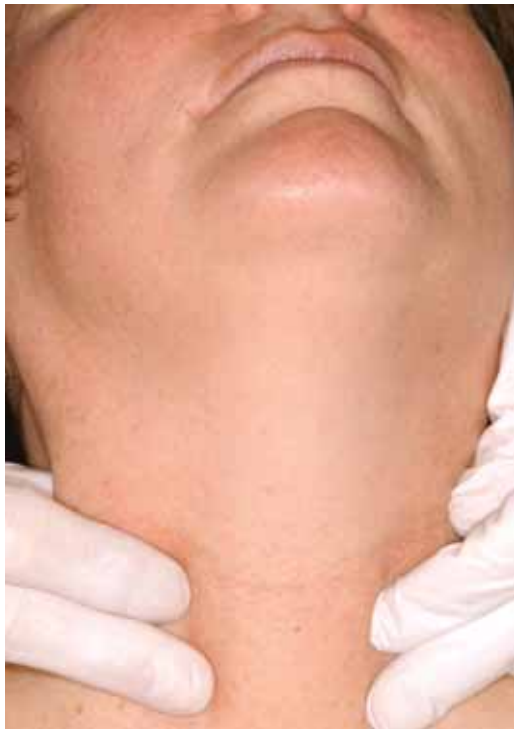The evaluation of lymph nodes during a dental exam is important since enlarged nodes may indicate infection from sites that drain into them or may be an indicator of the spread of cancer. Healthy nodes are normally not palpable, but infection or malignancies may cause them to become enlarged. A node that becomes palpable due to an infection that drains into the node is more likely to be firm, tender, enlarged, and warm, and adjacent skin may be reddened. In this case, look for the site of infection based on your knowledge of the spread





1. Nasolabial groove
2. Philtrum
3. Tubercle (upper lip)
4. Labiomental groove
5. Hyoid bone
6. Laryngeal prominence (Adam's apple)
7. Sternum
8. Clavicle
9. Carotid artery (dotted lines)
10. Sternocleidomastoid muscle
11. Submandibular gland
12. Masseter muscle
13. Parotid gland
14. Head of condyle
15. Zygomatic process
16. Temporalis muscle
17. Thyroid gland

**FIGURE 15-2.** Structures in the head and neck that can be identified (or palpated) during a head and neck examination.



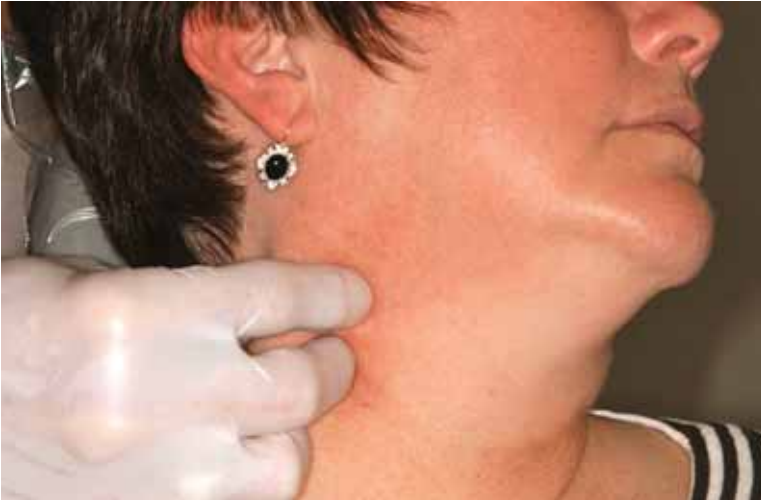**FIGURE 15-3.** Palpation of the tissue in the neck surrounding the **thyroid gland** and laryngeal **prominence**, feeling for asymmetry or swelling.

pattern within the nodes discussed in the previous chapter. Even after the infection is resolved, the nodes may remain enlarged but would be nontender and rubbery in consistency. If a node becomes enlarged due to the effect of a malignancy, it is more likely to feel firm and nontender, but it also feels like it is attached to the underlying tissue, so it is relatively immovable, and it will continue to get larger.

Nodes, when enlarged, can be felt by passing the sensitive fleshy part of the fingertips over the location of each node location. Using Figure 14.51 in the last chapter as your guide, palpate the skin located over the submental nodes (just inferior and posterior to the chin), the submandibular nodes (inside the angle of the mandible and over the submandibular glands), the superficial parotid and the retroauricular nodes (anterior and posterior to the ear, respectively), and the cervical nodes (surrounding the large sternocleidomastoid neck muscle, as demonstrated in Fig. 15-4).

## H. SALIVARY GLANDS (EXTRAORALLY)

Two pairs of major salivary glands can be palpated extraorally: the submandibular glands and the parotid glands. The **submandibular glands** are located just medial to the inferior border of the mandible within



**FIGURE 15-4.** Palpation of tissue of the neck that surrounds the **sternocleidomastoid muscle** in order to detect any enlarged **cervical lymph nodes** that are located around this muscle.

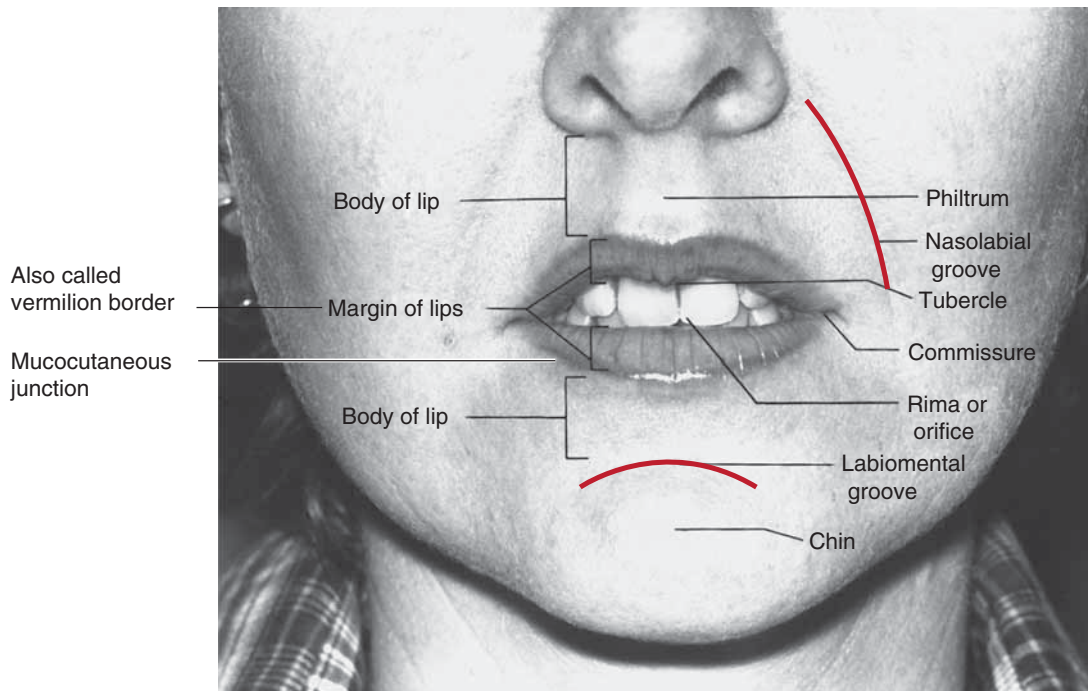
the shallow submandibular fossae (Fig. 15-2, labeled No. 11). They are positioned just anterior to where the facial artery passes over the inferior surface of the mandible on its way from the neck to the face. Palpate this vessel on the inferior border of the mandible (you may feel its pulse) and move medially in order to locate the submandibular gland. These glands produce almost two thirds of our saliva, mostly the thinner (serous) type but also some thicker (mucous) types.<sup>1</sup>

The large four-sided **parotid glands** (labeled No. 13 in Fig. 15-2) are located just anterior and inferior to

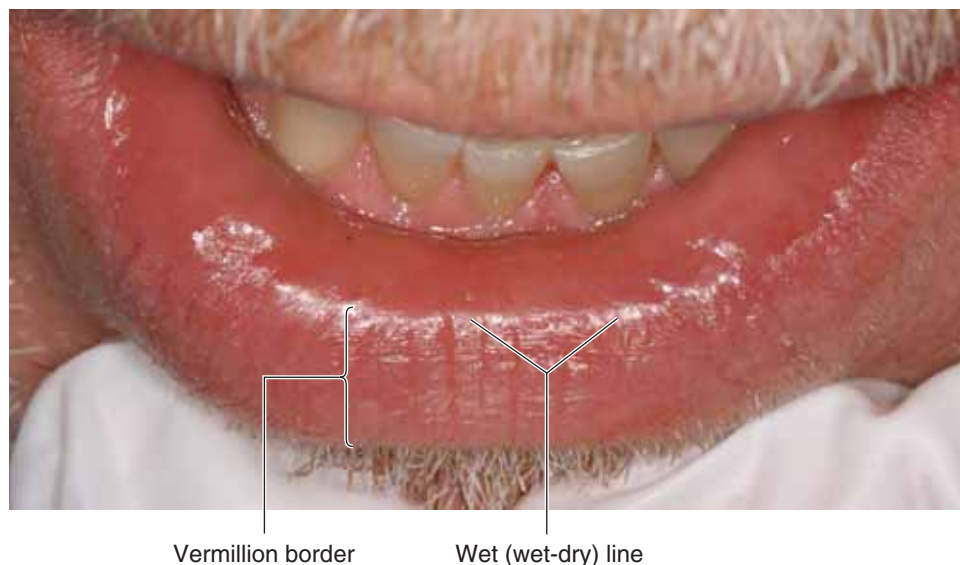
each ear lobe (lateral to the ramus and extending posteriorly to the sternocleidomastoid muscle). They produce 23 to 33% of our saliva (the serous or thinner type).<sup>1</sup> These glands may become enlarged during mumps or a duct blockage.

## I. LIPS

Use *Figure 15-5* as a guide while studying the lips. The lips are the two fleshy borders of the mouth (an upper and a lower) that join at the **labial commissure**.



**FIGURE 15-5.** **Structures of the lips.** The margin of the lips is also called the vermilion zone or border. The **mucocutaneous junction** is the junction of the skin of the face with the vermilion zone.



**FIGURE 15-6.** Lower lip: Vermillion border and wet (wet-dry) line.

The upper lip is bounded laterally by the cheeks at the nasolabial groove and superiorly by the nose. The **nasolabial groove** runs diagonally downward and laterally from the side of the nostrils toward an area near the commissure of the mouth. The lower lip is also bounded laterally by the cheeks and is bounded inferiorly by the chin at a horizontal groove called the **labio-mental groove**. Recall that the underlying orbicularis oris muscle is the muscle within the lips surrounding the mouth opening that permits us to close our lips around a straw. The upper lip has a small rounded nodule of tissue in the center of its lowest part called the **tubercle**, and the skin superior to the tubercle has a broad depression running from the tubercle toward the center of the nose called the a **philtrum** [FIL trum].

The **vermilion border** (also margin or zone) is the red zone of the lips, which is really a transitional zone between the skin of the face and the mucous membrane

or mucosa [mu KO sah] (tissue lining the mouth). It is the area where many women apply lipstick. The lips are redder in younger persons than in older persons, and in some individuals, the lip color is reddish brown due to the presence of brown melanin pigment. The vermilion border is bounded externally on the face by the **mucocutaneous** [MYOO koe kyoo TAY nee us] **junction**, the junction between the skin of the face and the vermilion border of the lips. The vermilion border is bounded internally in the mouth by the wet line where labial mucosa begins. The **wet line** (or **wet-dry line**) is the junction between the outer vermilion border, which is usually dry, and the inner smooth and moist mucosa (Fig. 15-6). The wet line is located about 10 mm back from the skin or mucocutaneous junction. The vermilion border and mucocutaneous junction are important in the head and neck examination because changes here may be caused by exposure to the sun and could lead to skin cancer.

## SECTION II

### INTRAORAL EXAMINATION: NORMAL STRUCTURES AS WELL AS LANDMARKS USED FOR PLACING LOCAL ANESTHETIC

The **oral cavity** is bounded anteriorly by the lips, laterally by the cheeks, superiorly by the palate, and inferiorly by the floor of the mouth. The oral cavity can be divided into two parts: the oral vestibule and the oral cavity proper. The outer **oral vestibule** is the space between the teeth with the supporting alveolar processes, and the lips or cheeks. The inner **oral cavity proper** is the space bounded anteriorly and laterally by the teeth and alveolar processes.

Mucous membrane (mucosa) lines any body cavity opening out to where it joins the skin on the outside of the body. **Oral mucous membrane** lines the oral cavity. It resembles the skin covering the outside of the body, except that it is moist. Some areas subjected to the most wear, such as the roof the mouth (over the hard palate) and the gingiva, are covered by a toughened outer tissue called a **keratin** [KER ah tin] layer. As wear occurs, this portion takes on a grayish appearance and is replaced



by underlying cells. Other areas of the oral mucous membrane have no keratin layer so are more delicate in structure, such as the cheeks and floor of the mouth. This mucosa lining may be so thin that the blood vessels located in the underlying connective tissue may easily be seen, giving it a reddish or bluish color.

Many of the nerves that innervate the teeth and adjacent oral structures can be reached with the anesthetic syringe needle by penetrating the labial and buccal mucosa. The landmarks that are helpful for locating these injection sites will be described throughout this section.

### TECHNIQUE FOR INJECTING LOCAL ANESTHETIC TO NUMB ORAL STRUCTURES: BACKGROUND

In order for you to “feel” pain, the tooth or surrounding tissue that is being stimulated must pass the message to the brain by way of the branches of the cranial nerves. When anesthetic is placed near a nerve, it can spread (or *infiltrate*) through soft tissue or spongy bone to enter the nerve cells with sufficient concentration to reduce pain messages being sent to the brain. Anesthetic, to be effective, must be placed at a location along the nerve between the tissues to be numbed and the brain. Therefore, it is important to recall the passageway of the nerves of the mouth to know where to apply the anesthetic in order to block the pain elicited in the tissues being treated (such as tooth pulps and tissues surrounding the teeth) to keep the message from reaching (and being “felt” by) the brain.

Recall that most nerves parallel arteries and veins. In order to avoid injecting local anesthetic into these vessels where it can produce an exaggerated undesirable effect on the heart (systemic effect), an **aspirating syringe** is used. This type of syringe permits the operator to pull back on the stopper of the anesthetic cartridge and apply a negative pressure through the solution and needle. Therefore, if the needle tip is in a blood vessel, the negative pressure can *aspirate* (suck in) blood into the glass anesthetic cartridge where it can be seen. When blood is observed, the operator can reposition the needle prior to injecting the anesthetic and aspirate again to ensure that the anesthetic will not enter the vessel where it would quickly reach the heart, resulting in an increased chance of undesirable side effects.

In order for the anesthetic to block the signal of tooth pain being sent along the nerve branches that pass from each tooth to the brain, a sufficient concentration of anesthetic must enter the nerve cells along their passageway from the tooth to the brain to *block* the nerve. In order to accomplish this, anesthetic is applied as close as possible to a nerve before it enters the bone, or, if the bone is porous enough or thin enough, it may be applied outside of the bone where it can pass (infiltrate) through the bone directly to the dental nerve branches in the bone before they enter the tooth root. The maxillae bones are less dense than the mandible, permitting anesthetic to infiltrate more readily from adjacent soft tissue into bone and reach nerve branches that enter the tooth pulps. In the mandible, nerves supplying the pulps can be blocked more effectively by applying the anesthetic near the mandibular nerve before it enters the mandible (the inferior alveolar nerve) or into the mental foramen (which permits the solution to enter the mandible and block only the inferior alveolar nerve branches to the premolars and possibly the anterior teeth but not the molars).

### A. LABIAL AND BUCCAL MUCOSA: VESTIBULE AND CHEEKS

The vestibule space between the teeth and the lips or cheeks can be divided into the *labial* vestibule next to the anterior teeth, and the *buccal* vestibule next to the posterior teeth (premolars and molars). It extends superiorly into a mucosa-lined space next to maxillary teeth, and inferiorly next to mandibular teeth. It is covered with dark pink-colored alveolar mucosa and is rich in blood vessels and minor salivary glands. The tip

of your tongue can reach into each vestibule to assist in cleaning the facial surfaces of the teeth, and while chewing, to lift food back for additional chewing. The **vestibular fornix** (seen later in Fig. 15-16) is the lowest part of the vestibule next to the mandible or the highest part next to the maxillae. The vestibular fornix next to the cheeks is where food may collect in patients with nerve damage to the cheek (as with unilateral loss of function of the facial nerve from Bell's palsy or from a stroke).



## INJECTIONS FOR THE POSTERIOR, MIDDLE, AND ASA NERVES

Consider the nerves that must be blocked in order to anesthetize the teeth and surrounding tissues of the upper jaw. These are all branches of the **maxillary division of the fifth cranial (trigeminal) nerve**. In order to anesthetize the pulp of one or two teeth, or the soft tissue in a specified area, it is necessary to block the appropriate individual branches of the posterior superior alveolar (PSA), middle superior alveolar (MSA), or ASA nerve branches that innervate these tissues.

If you want to anesthetize only the maxillary second or third molar and adjacent tissue, you can reach the **PSA** (Fig. 15-7) before it enters the *alveolar canals* (Fig. 15-8) by directing the anesthetic toward the posterior surface of the maxilla, just superior, distal, and slightly medial to the apex of the third molar. Entry to this site is through the mucosa at the height of the buccal vestibule (vestibular fornix) superior to the **maxillary tuberosity** (Fig. 15-9). The cheek can be stretched slightly outward to permit an angle that is directed superiorly and medially. Specific dental branches of the PSA can also be blocked by depositing the anesthetic next to the maxilla as close as possible to the apex of the tooth being anesthetized, and the solution will infiltrate through the maxillary bone to block the dental branches to these molars. When using this technique to anesthetize a maxillary first molar, the anesthetic will not only reach the dental branches of the PSA that enter two of its roots but also the MSA branches that enter the third root.

For all other maxillary teeth and adjacent facial gingiva, you need to block branches of the **MSA or ASA**. Since you cannot easily reach the MSA and ASA nerves as they pass from the brain through the base of the orbit and maxillary sinus, you can deposit the solution in the soft tissue of the *vestibular fornix* adjacent to the maxillae, at a *level of the tooth root tips* of the teeth you want to get numb (Figs. 15-10 for the MSA and 15-11 for the ASA). The anesthetic can infiltrate through the soft tissue and bone to reach dental nerve branches of the ASA (supplying the pulps of anterior teeth, Fig. 15-12) or MSA (supplying the pulps of premolars and one root [mesiobuccal] of the maxillary first molar, Fig. 15-13) in order to block pain. As stated previously, the anesthetic placed to block the MSA nerve branches may also infiltrate through the bone to block some of the PSA nerve branches, thereby numbing the entire first molar.

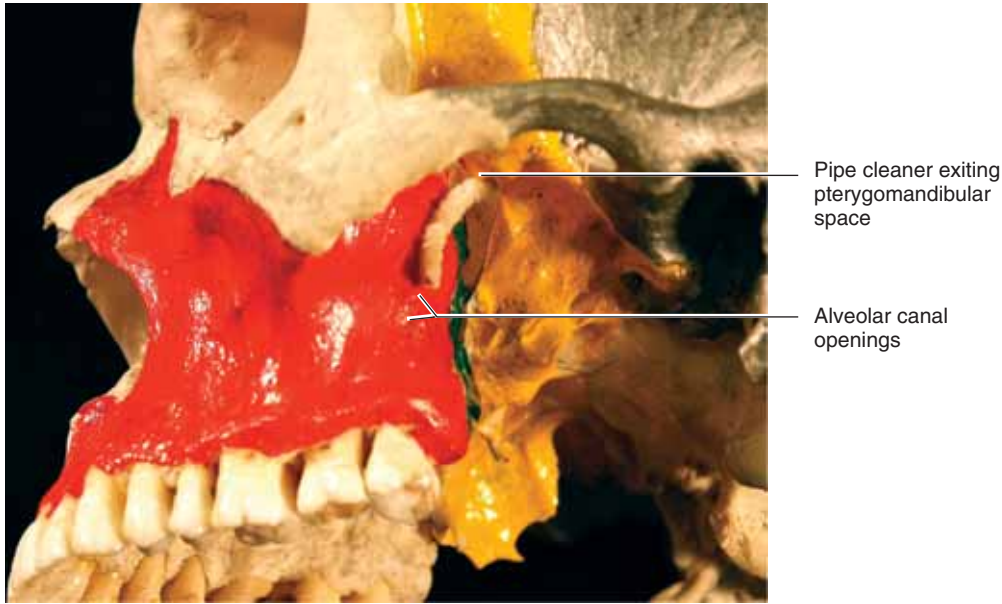
End branches of the **infraorbital nerve** branches that supply the soft tissue facial to premolars and anterior teeth can be anesthetized using the infiltration technique described above. However, blocking all of the terminal branches of the infraorbital nerve may also be helpful. This nerve can be reached by applying the anesthetic near the opening of the *infraorbital foramen* (Fig. 15-14). This foramen may be palpated with the forefinger through the skin just below the inferior border of the eye socket. Then, using the thumb in the facial vestibule to raise the upper lip, you can pass the needle into tissue at the height (*fornix*) of the vestibule near the premolars (similar to the MSA injection) and continue to move the tip parallel to the facial surface of the maxilla until reaching the level of the infraorbital foramen (Fig. 15-15).

Refer to Figure 15-16 as a guide while studying the following structures. The **labial frenum** [FREE num] (plural: frena [FREE nah]) is the thin sheet of tissue at the midline that attaches each lip (upper and lower) to the mucosa covering the maxillae or mandible between the central incisors. The **buccal frenum** loosely attaches the cheek to the mucosa of the jaw in the area of the premolars (maxillary and mandibular). These buccal frena can be seen by pulling the lip and cheek out and upward and the lip and cheek out and downward. Facial muscles move the buccal frena forward and backward and upward and downward during eating to help, along with the tongue, place our food back over the chewing surfaces of our teeth while eating. Movement of these

frena can dislodge complete dentures if the denture border is designed improperly.

Usually 4 to 6 mm posterior to the commissure of the lips, a slight bulge of mucous membrane called the **commissural papule** is commonly seen and may be palpated (Fig. 15-16). The **parotid papilla** [pa ROT id pah PILL e] is a rounded flap of tissue on the mucosa of the cheek next to the maxillary first and second molars at or just superior to the occlusal plane (Fig. 15-16). This papilla covers the **parotid duct** (Stensen's duct) opening.<sup>A</sup>

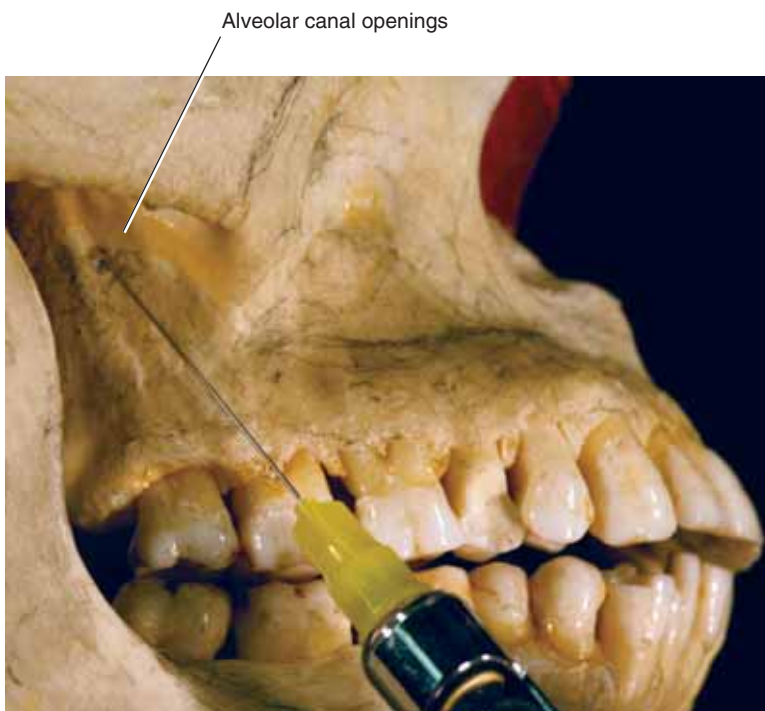
The lining of the **buccal mucosa** on the inside of the cheeks is shiny, but in spots may be rough. Often there is a horizontal white line extending anteroposte-



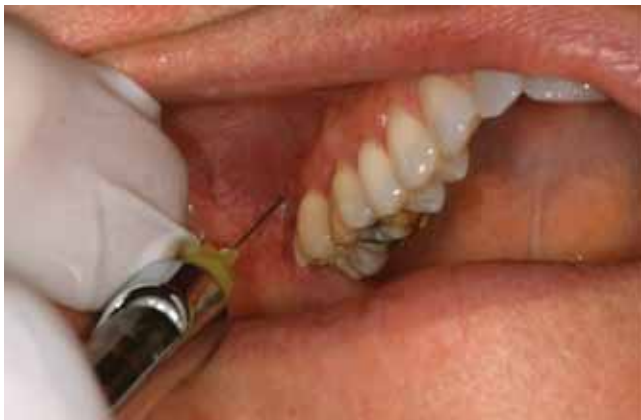**FIGURE 15-7.** Human skull with maxilla painted red, the palatine bone (barely visible) is green, and the sphenoid bone is yellow. A pipe cleaner, representing the **PSA nerve**, passes out of the *pterygomandibular space* superiorly, toward the *alveolar canals* on the posterior surface of the maxilla.

riorly on each side at the level where the upper and lower teeth come together, called the **linea alba** [LIN e ah AL ba] buccalis (Fig. 15-17). (Hint: “Linea” means line; “alba” means white.) It may extend from the commissural area to the third molar region at a level of the occlusal surfaces of the posterior teeth. This area may become irritated by trauma from biting the cheek. **Fordyce’s granules** or spots are small, yellowish irregular areas and may be conspicuous in some persons.

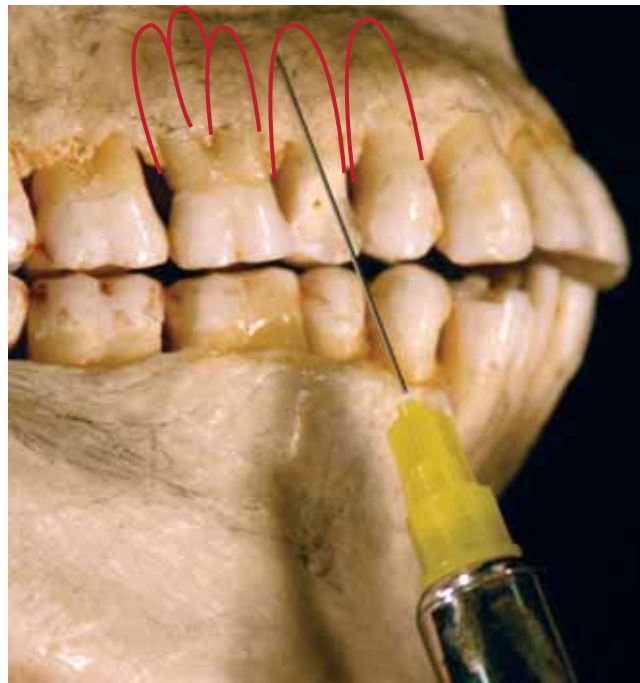
They are most commonly located on the buccal mucosa inside the cheeks posterior to the corner of the mouth (Fig. 15-17). They are really the manifestation of intraoral sebaceous glands—glands normally associated with hair follicles on the skin outside of the mouth. Their presence here may be the result of fusion of the upper and lower parts of the cheek during embryonic development. Such glands have also been found, however, on other parts of the oral mucosa.



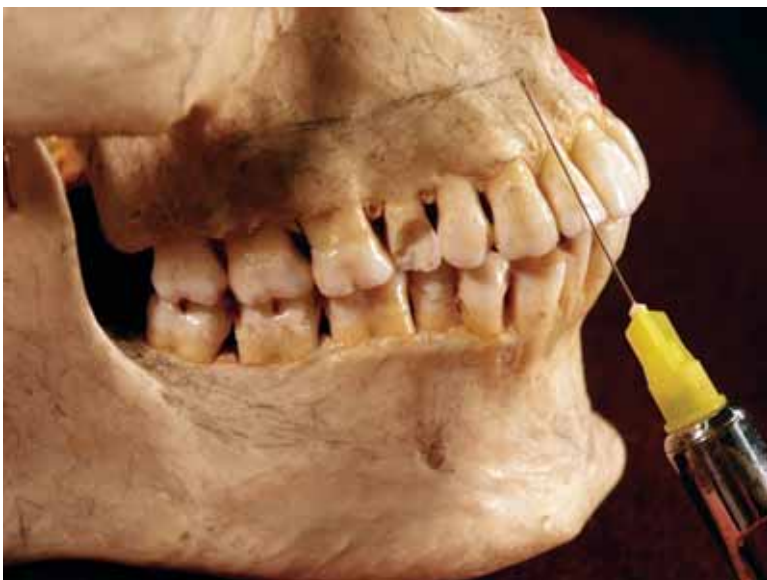**FIGURE 15-8.** Anesthetic syringe needle aimed toward the *alveolar canals* where the **PSA nerve** would enter the maxilla on its way to the maxillary molar roots.



**FIGURE 15-9.** Penetration of the needle through the oral mucosa at the height of the maxillary vestibular fornix just posterior to the maxillary tuberosity is directed medially and superiorly toward the alveolar canals where the **PSA nerve** enters the maxilla. This injection location should reduce pain sensation to the maxillary molars (except the mesiobuccal root of the maxillary first molar) and adjacent facial soft tissue and gingiva.

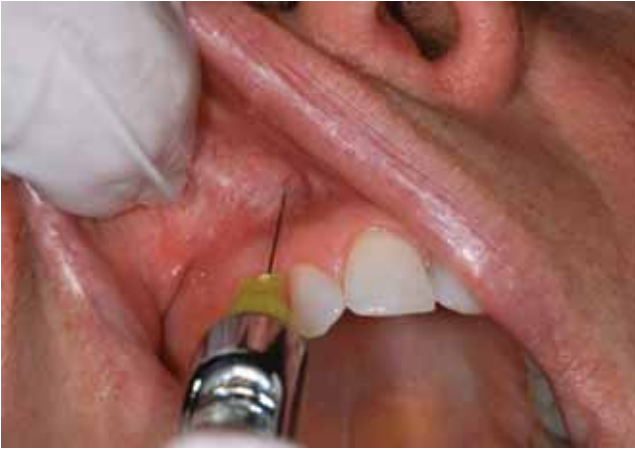

**FIGURE 15-10.** Human maxilla has the location of the maxillary first molar and premolar roots outlined on the maxilla. The anesthetic syringe needle is aimed parallel to the contour of the maxilla to reach the level of the root ends of the maxillary premolar or molar teeth to be anesthetized. The anesthetic can infiltrate through the maxilla to reduce pain sensation to these teeth (and adjacent facial soft tissue and gingiva) by simultaneously blocking the **MSA nerve** and branches of the adjacent **PSA nerve**.

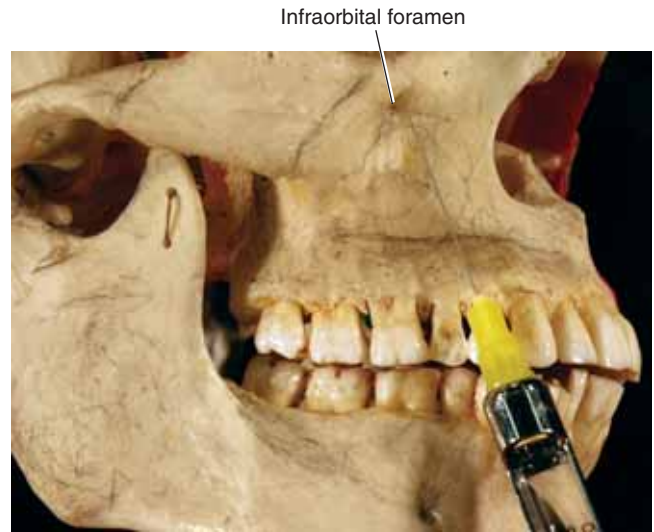


**FIGURE 15-11.** Human maxilla with a pencil line indicating the approximate level of the end of the maxillary tooth roots. The anesthetic syringe needle is aimed parallel to the contour of the maxilla to reach the level of the root ends of the maxillary anterior teeth in order to block the dental branches of the **ASA nerve**.

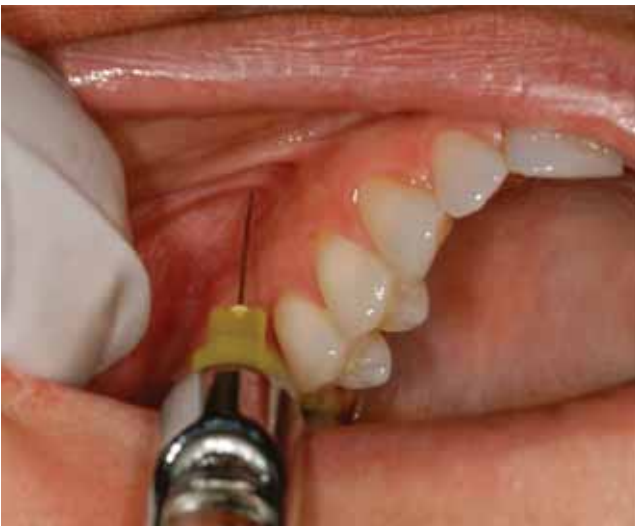



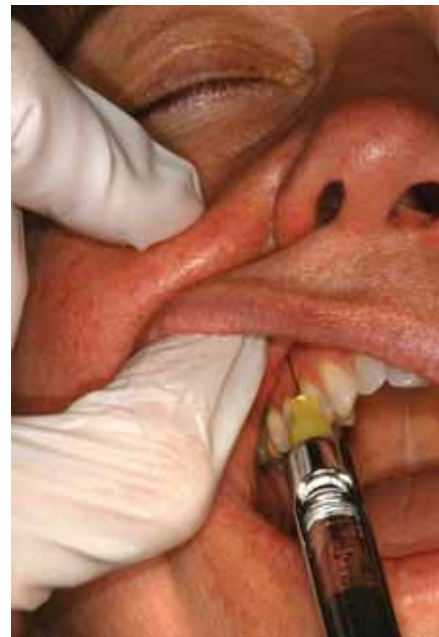**FIGURE 15-12.** The anesthetic syringe needle penetrates through the oral mucosa at the height of the maxillary vestibular fornix adjacent to the maxillary lateral incisor until the needle tip reaches the estimated level of the root tip. This injection location should reduce sensation to the maxillary incisors by infiltrating through the maxilla to block the **ASA nerve**.



**FIGURE 15-14.** The anesthetic syringe needle is aimed parallel to the contour of the maxilla to reach the level of the **infraorbital nerve**. Anesthetic can block the infraorbital nerve where it exits the *infraorbital foramen* to reduce pain sensation in the tissues of the upper lip and facial gingiva (and part of the nose and lower eyelid) that are supplied by the infraorbital nerve branches.

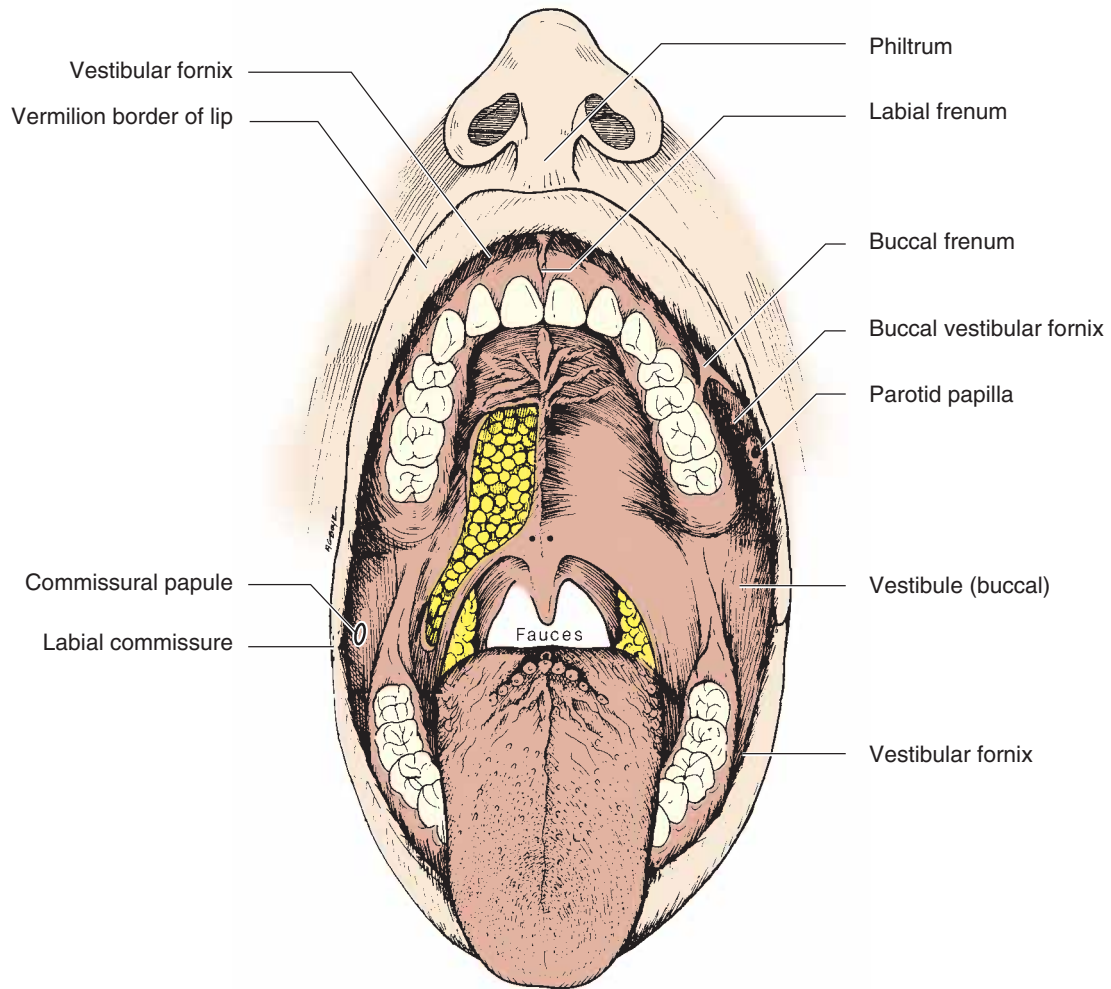


**FIGURE 15-13.** The anesthetic syringe needle penetrates through the oral mucosa at the height of the maxillary vestibular fornix (near the buccal frenum) adjacent to the maxillary premolars until the needle tip reaches the estimated level of the root tips. This injection location should reduce sensation to the maxillary premolars and adjacent first molar by infiltrating through the maxilla to block the **MSA nerve** and the adjacent branches of the **PSA nerve**.

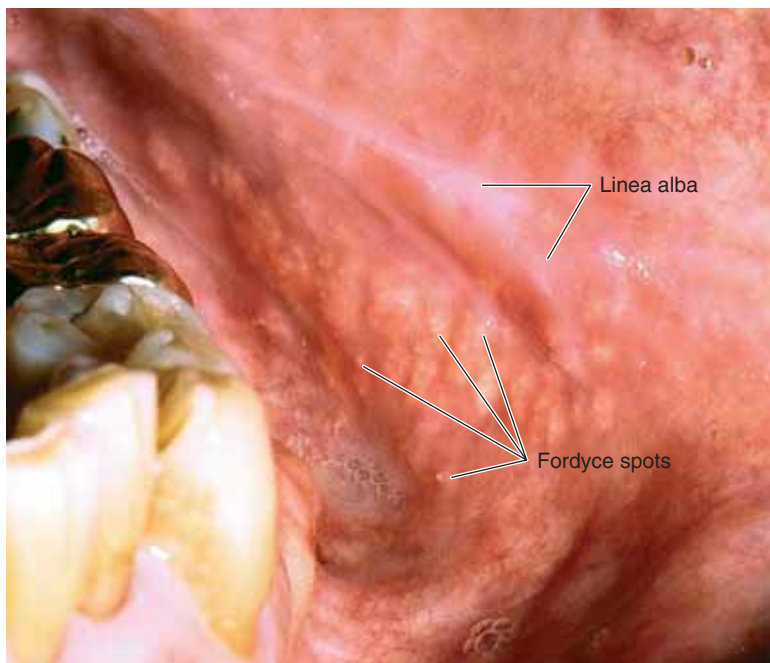


**FIGURE 15-15.** The anesthetic syringe needle penetrates through the oral mucosa at the height of the maxillary vestibular fornix adjacent to the maxillary canine or first premolar (similar in location and syringe angulation to a MSA or an ASA block), but the needle penetrates farther, beyond the level of the root tips, to the level of the **infraorbital nerve** (felt by palpating to find the depression of the infraorbital foramen and marking the level with the finger as in the photograph).





**FIGURE 15-16.** Structures of the vestibule and adjacent cheek mucosa.



**FIGURE 15-17.** Buccal mucosa adjacent to posterior teeth showing a **linea alba** and **Fordyce granules** (spots). (Courtesy of Carl Allen, D.D.S., M.S.D.)

## LONG BUCCAL INJECTION

The **buccinator (long buccal) nerve** is a branch of the **mandibular nerve** that does not pass through the mandibular foramen but is located in the soft tissue of the cheek. The anesthetic can be applied just beneath the buccal mucosa and just superior to the buccal shelf next to the mandibular molars that require facial tissue numbness (Figs. 15-18 and 15-19).

Palpation of the cheeks (or lips) for lumps or bumps can be accomplished by pressing with the thumb on one side against the forefinger on the other side (called **bidigital palpation**), as seen in Figure 15-20.

### B. THE PALATE: ROOF OF THE MOUTH

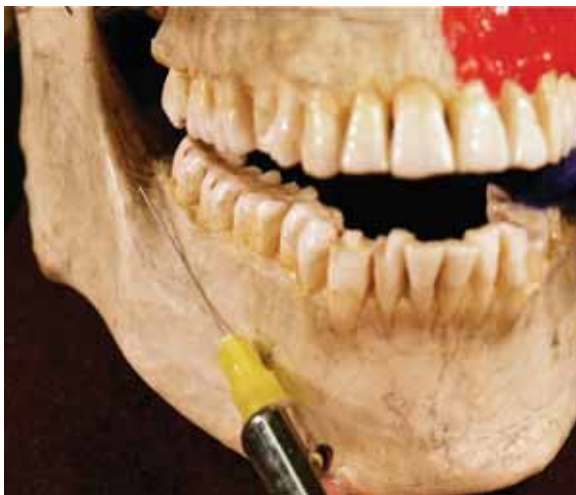The **hard palate** is the firm anterior part of the roof of the mouth with mucosa over the underlying bone (namely, the horizontal plates of the palatine bones and palatine processes of the maxillae). The **soft palate** is the posterior movable part of the roof of the mouth without underlying bony support. The **vibrating line** is the junction between the hard and soft palate (Fig. 15-21).

#### 1. HARD PALATE STRUCTURES

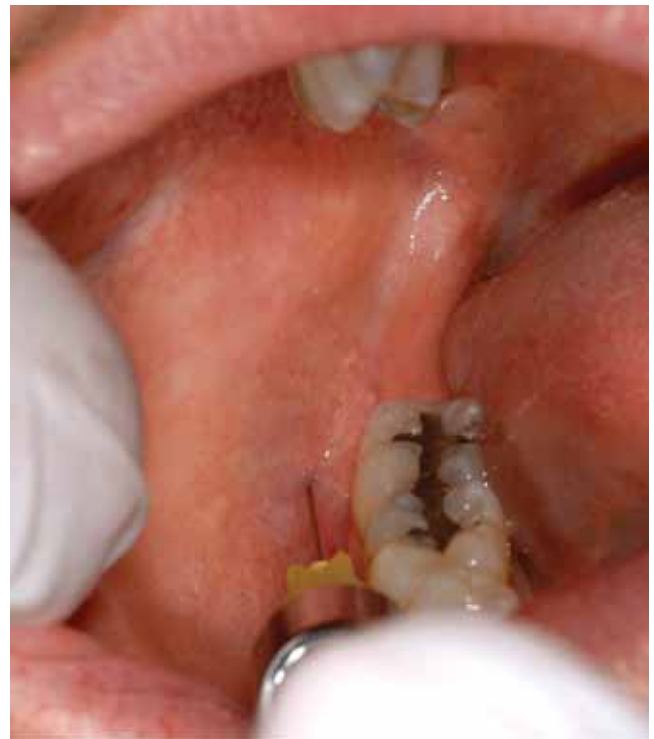Refer to Figures 15-21 and 15-22 while studying the structures of the hard palate. The hard palate is covered by keratinized, grayish red to coral pink tissue. The **incisive papilla** is the small rounded elevation of tissue on the midline of the palate just lingual to the

central incisors. This papilla is located over the *incisive foramen*, where the *nasopalatine nerve* passes from the nasal cavity onto the palate to innervate the anterior portion of the hard palate. It is the location for injecting anesthetic to numb palatal tissue in this area.<sup>B</sup>

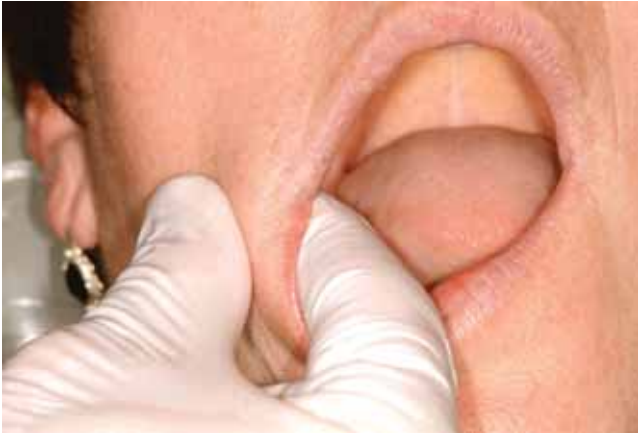The **palatine raphe** [RAY fee] is the slightly elevated ridge of firm tissue running anteroposteriorly along the midline of the hard palate (over the intermaxillary suture attachment between the palatine processes of the right and left maxillae) (Fig. 15-22). The mucosa over the raphe is firmly attached to the underlying bone without intervening fat or gland cells. The rest of the tissue on both sides of the raphe has fat or salivary gland



**FIGURE 15-18.** Location on the skull for blocking the end branches of the (long) **buccal nerve** facial to the mandibular molars and superior to the *buccal shelf*.



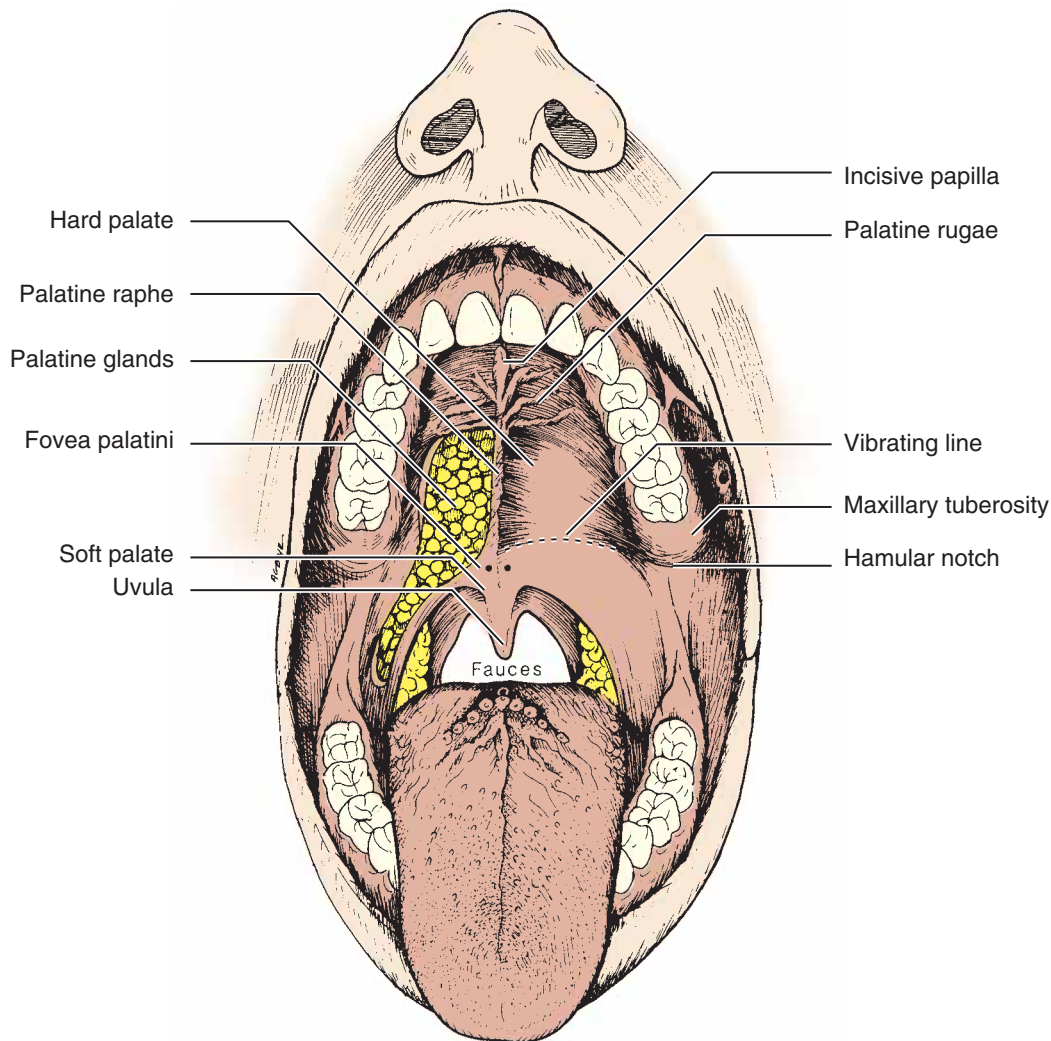
**FIGURE 15-19.** Anesthetic syringe used to block the (long) **buccal nerve** by penetrating the mucosa into the cheek just buccal to the maxillary molars. This anesthetic should reduce pain sensation to the facial soft tissue and gingiva of the mandibular molars.



**FIGURE 15-20.** Bidigital palpation is used to feel for lumps or bumps within the soft tissue of the cheeks by pressing with the thumb on the one of the cheek and forefinger on the other side.

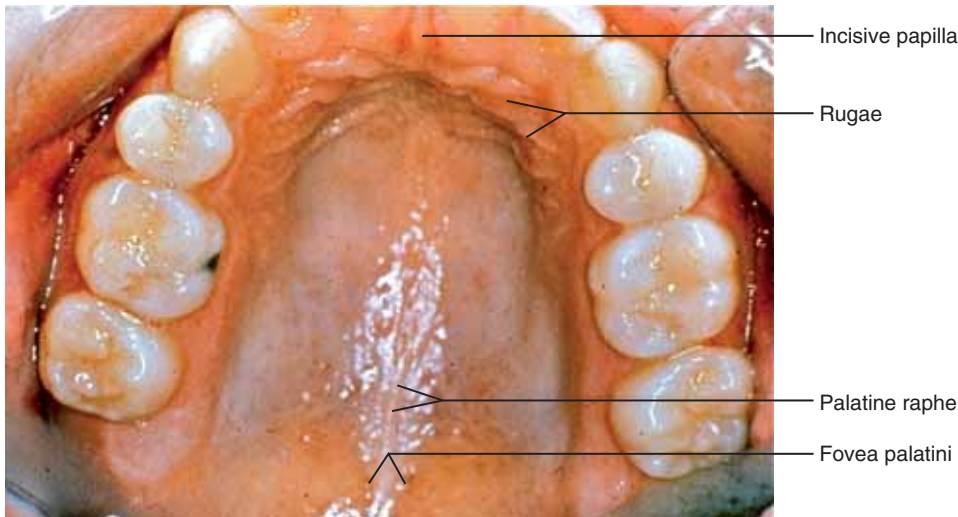
tissue beneath the surface, so it is softer. This spongy tissue at the junction of the hard palate and alveolar process next to premolars and molars is the location of the *greater palatine nerve*. There are more than 350 very small palatine glands in the posterior third of the hard palate.<sup>2</sup> They secrete thick but slippery saliva.

**Palatine rugae** [ROO guy] or [ROO jee] are a series of palatal tissue elevations, or wrinkles, located on the palate just posterior the maxillary anterior teeth (Fig. 15-22). They form a pattern like branches on a tree, coming off of the common midline “trunk,” the palatine raphe.<sup>c</sup> Rugae function in two important ways: in tactilely sensing objects or food position and in aiding the tongue’s proper placement for the production of certain speech sounds.<sup>3</sup> This part of the palate is often burned by eating pizza when it is too hot or becomes abraded from chewing too much popcorn.



**FIGURE 15-21.** Structures of the hard and soft palate.





**FIGURE 15-22.** Structures of the hard palate: Note the prominent palatine rugae (ridges) and incisive papilla (anterior midline), and the palatine raphe, which is located over the intermaxillary suture line between the right and left maxillary palatine processes. The two tiny depressions on either side of the posterior portion of the raphe are called fovea palatini.

### NASOPALATINE NERVE INJECTION

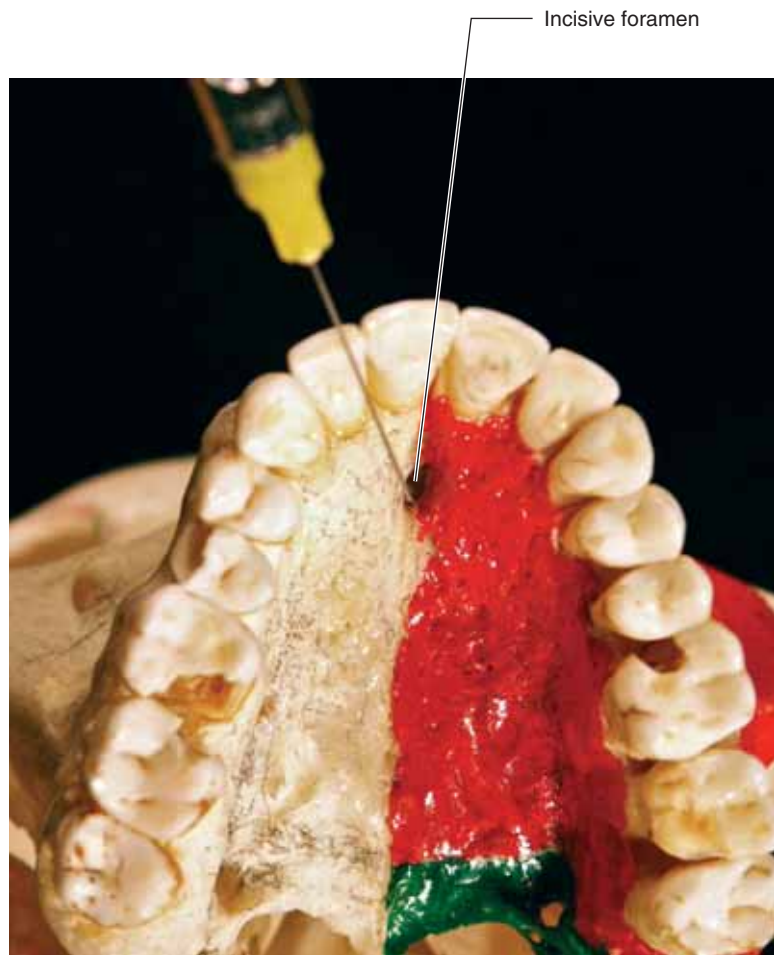
In order to anesthetize the tissues of the palate, you need to block one or two nerves. The **greater (anterior) palatine nerve** innervates most of the palate (all tissue covering the hard palate lingual to molars and premolars) and the **nasopalatine nerve** for tissue lingual to the anterior teeth. Recall that both of these nerve branches split off of the **maxillary nerve** while in the pterygopalatine space, and then pass through the nasal passageways before entering the palatal tissue. The nasopalatine nerve passes from the pterygopalatine space along the nasal septum in the nasal cavity, and into palatal mucosa through the *incisive foramen* (Fig. 15-23), which is located immediately under the bump of very firm tissue called the *incisive papilla* (Fig. 15-24). This papilla is located on the palate just lingual to the midline between the maxillary central incisors. Since this tissue is very firm, only a small amount of anesthetic can be applied into this tissue, and this injection can be most painful. Applying pressure over the injection site with the handle of a mirror or with the end of a cotton-tipped applicator for 15 to 20 seconds prior to injecting can minimize this discomfort.

### GREATER PALATINE NERVE INJECTION

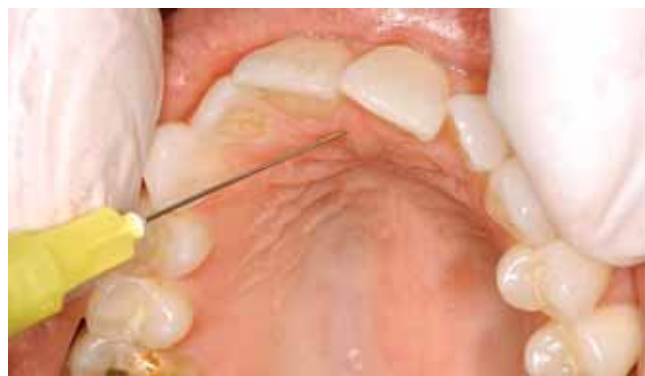The **greater palatine nerve** passes from the nasal cavity to palatal tissue through the *greater palatine foramen* located just lingual to the third molars at the junction of the most posterior part of the horizontal bone of the hard palate and the more vertical alveolar process surrounding the maxillary posterior teeth (Fig. 15-25). The greater palatine nerve spreads anteriorly toward the tissue lingual to the first premolar along the junction of the alveolar process and palate covered by tissue that is softer and more spongy than the tissue covering the midline of the hard palate. When locating or palpating this location, care must be taken to avoid touching the soft plate (posterior to the underlying bones of the palate) since this may elicit a gag reflex causing the patient to vomit. A small amount of anesthetic may be placed into this spongy tissue, resulting in numbness of tissues adjacent to and anterior to the injection site (Fig. 15-26).

Note: It is also possible to reach the **entire maxillary branch of the trigeminal nerve** just after it exits the cranium through the foramen rotundum while it is still within the *pterygopalatine space* and anesthetize all of the maxillary branches (called a *second division block*). This location is superior to the location of the PSA block already discussed. Anesthetic deposited in this location reduces pain to the structures supplied by the PSA, MSA, ASA, greater palatine, and nasopalatine nerves. Caution must be taken in this area because the *pterygoid plexus* of vessels is located here, and cutting a vessel wall could result in bleeding under the skin called a hematoma.





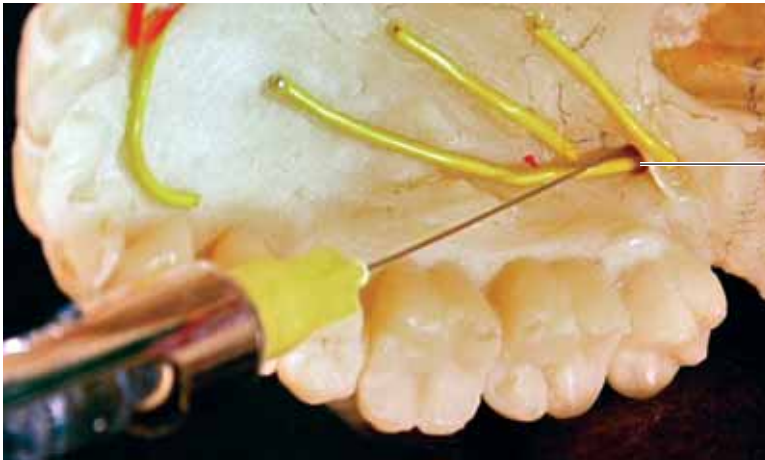**FIGURE 15-23.** The anesthetic syringe needle is directed toward the nasopalatine canal opening (*incisive foramen*) where it can block the **nasopalatine nerve**, which enters the palate at this location. (On this skull, the palatine process of the one maxilla is painted red, and one palatine bone is painted green.)



**FIGURE 15-24.** The anesthetic syringe needle is penetrating the very firm tissue of the *incisive papilla* overlying the opening to the *incisive foramen* in order to block the **nasopalatine nerve**. This should reduce pain sensation to the palatal soft tissues lingual to the anterior teeth. Since this injection site is so sensitive (it has been known to bring tears to the eyes), it is recommended to place pressure over the incisive papilla with a mirror handle or cotton-tip applicator for a brief time prior to injecting with the needle.

## 2. THE SOFT PALATE

The **soft palate** (Fig. 15-27) is located posterior to the hard palate beginning at the vibrating line. Along with the hard palate, it separates the mouth from the nasal passage. It is sometimes redder than the hard palate because of its slightly increased vascularity. Its anterior border extends between the right and left third molars. Unlike the hard palate, there is no bone beneath the surface of the soft palate. If you forcefully say “ah, ah,” you can see the soft palate move (or vibrate) up and down whereas the hard palate does not. The place where you observe the beginning movement of the soft palate is the **vibrating line**. **Fovea palatini** [FO ve ah pal a TEEN ee] are a pair of pits in the soft palate located on either side of the midline, near but just posterior to the vibrating line (Figure 15-22). They are openings of ducts of minor palatine mucous glands.<sup>3</sup> The **uvula** [YOU view la] is a small fleshy structure hanging from the center of the posterior border of the soft palate (Fig. 15-27).



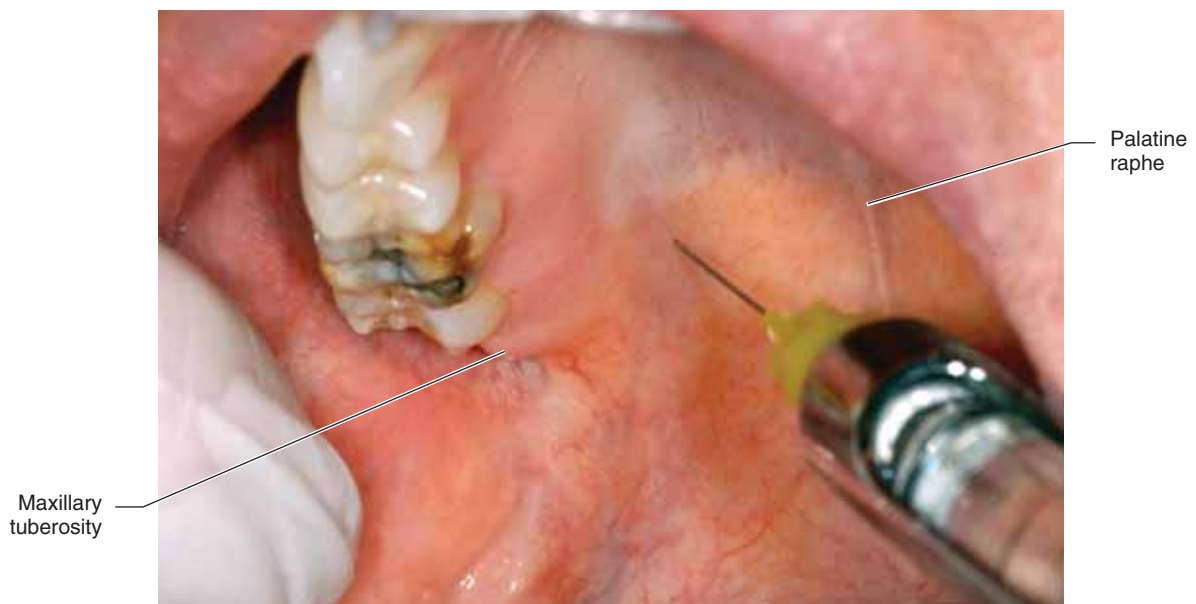Greater palatine foramen

**FIGURE 15-25.** The anesthetic syringe needle is directed toward the *greater palatine foramen* opening where can block the **greater palatine nerve** (represented here by yellow wires), which enters the palate at this location. The branches of this nerve supply half of the hard palate tissue located between the posterior teeth.

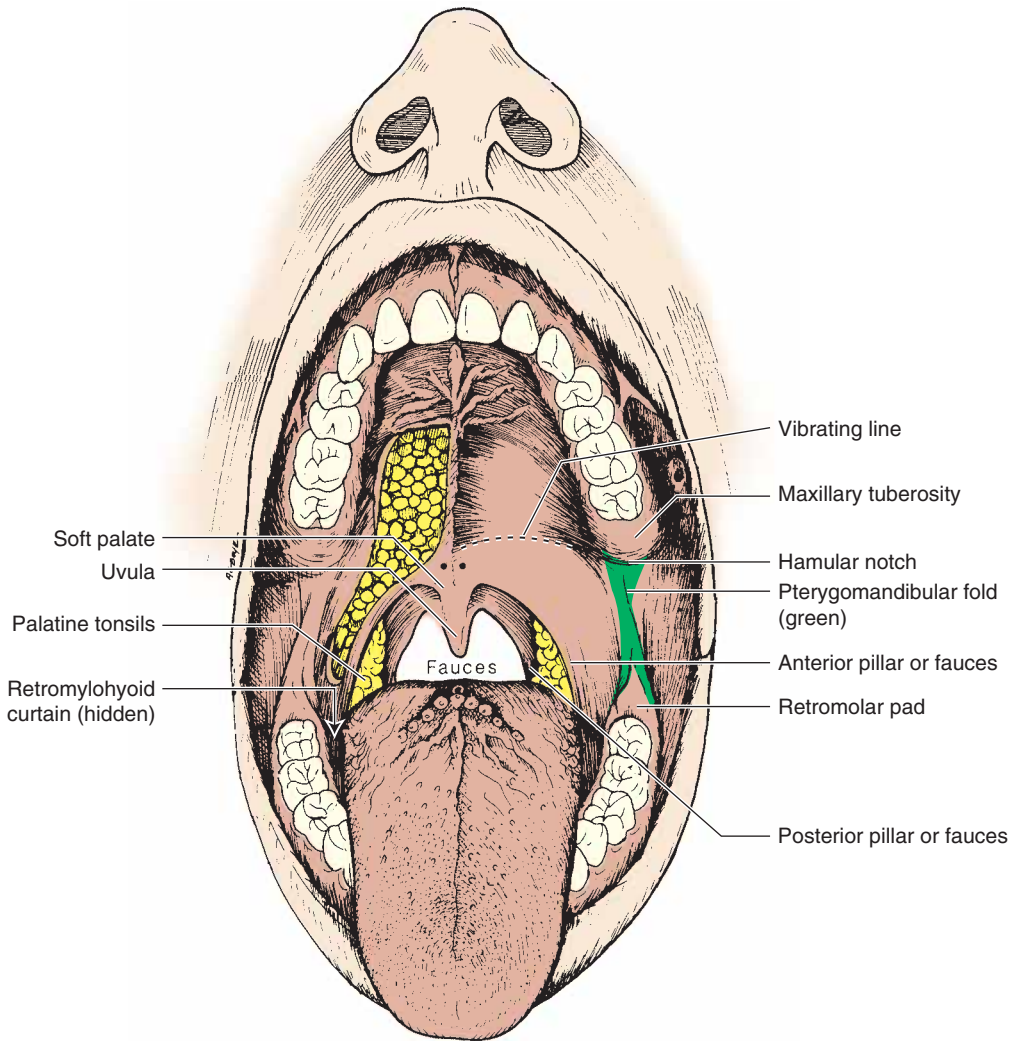
The soft palate functions during swallowing and speech. The **pharynx** [FAR inks] is the superior part of the digestive tube between the nasal passageways, oral cavity, and esophagus. During swallowing, the soft palate moves to close off the nasal portion of the pharynx from the oral pharynx (oropharynx) to prevent upward movement of food into the nasal cavity. The soft palate is raised to seal the oral cavity from the nasal cavity during blowing or when producing explosive consonants (like “b” and “p”).

### C. OROPHARYNX: FAUCES, PALATINE ARCHES, AND TONSILS

Refer to Figure 15-27 while studying the fauces and surrounding structures. The **fauces** [FAW seez] is the posterior boundary of the oral cavity. It is the opening from the mouth into the oropharynx (throat) for air when breathing through the mouth to reach the lungs and for food since the oropharynx leads to the esophagus and stomach. The fauces is bounded inferiorly by



**FIGURE 15-26.** The anesthetic syringe needle is penetrating the relatively spongy palatal mucosa near the junction of the vertical alveolar process and horizontal palatine processes near the third molars to reach the **greater palatine nerve** as it enters the palate through the *greater palatine foramen*. This injection should reduce pain sensation on that side to the palatal soft tissues between the posterior teeth.



**FIGURE 15-27.** Structures surrounding the **fauces** (oropharynx): The pterygomandibular fold is *green*.

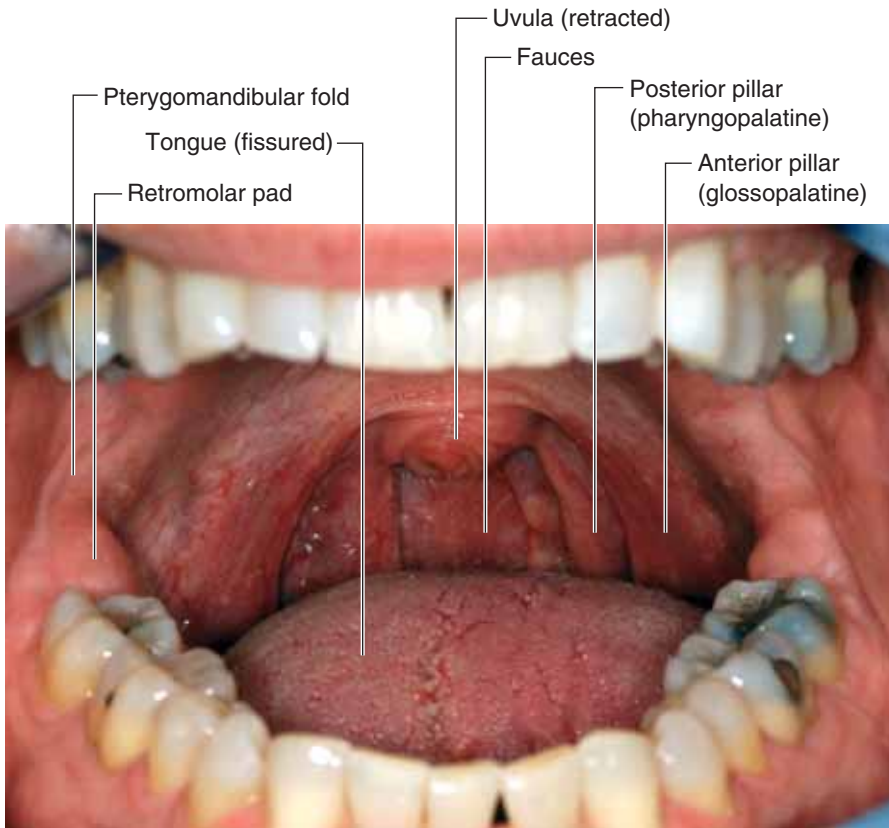
the dorsum (upper surface) of the tongue, laterally by palatal arches or pillars, and superiorly by the soft palate. Examine the fauces and palatine arches by having a partner open wide and say “ahhh...” You may have to gently push the tongue down with a tongue depressor. Be careful: Patients may gag.

Two pillars make up each of the two arches. Identify the anterior palatine arch (two pillars) that descends from the soft palate. The smaller posterior palatine arch is visible behind it. The **anterior arch** is also named the **glossopalatine** [GLOSS o PAL a tine] arch, and the **posterior arch** is also called the **pharyngopalatine** [fah RING go PAL a tine] arch, after the muscles beneath them. (Hint to remember these terms: The arch from the tongue [glosso] to the palate [the glossopalatine anterior arch] is more anterior than the arch from the pharynx or throat posterior to it [pharyngopalatine posterior arch].) (See Fig. 15-28.) The **palatine tonsils**, when present, are located between the anterior and

posterior pillars. These tonsils may become enlarged and inflamed during infections of the respiratory system. Patients may have had these surgically removed.

Although not part of the oropharynx, there are several landmarks just posterior to the last molars that will be presented here. Immediately posterior to the maxillary last molar is a firm tissue bulge over bone of the alveolar ridge called the **maxillary tuberosity** (Fig. 15-27). This tuberosity is present even after all of the teeth have been lost and is included in an impression of the upper arch when constructing a maxillary complete denture. A similar, less prominent elevation of movable tissue distal to the mandibular last molar is the **retromolar pad** (Fig. 15-28). (Hint: “Retro” means behind, or distal, to the last molar). When a person has fully erupted third molars, the maxillary tuberosity and mandibular retromolar pad on each side are small because of the proximity of these adjacent teeth. The **pterygomandibular** [TER i go mand DIB you lar]





**FIGURE 15-28.** Oropharynx showing the retromolar pad and pterygomandibular fold extending upward from the last mandibular molars, as well as structures surrounding the fauces: uvula (retracted), anterior pillars (making up glossopalatine arch), and posterior pillars (making up pharyngopalatine arch).

fold is a fold of tissue that appears to connect the area just distal to the maxillary molars to the area just distal to the mandibular molars. This is easy to see when the mouth is opened wide as this action stretches this fold, extending from the retromolar pad on the mandible to the pterygoid process of the sphenoid bone just behind the maxillary tuberosity (Fig. 15-27). (Hint: The pterygomandibular fold gets its name since it connects the *mandible* with the *pterygoid* process just distal to the maxillae.) This fold is an important landmark for the anesthetic syringe needle to enter when

aiming toward the mandibular foramen in order to block the inferior alveolar nerve just before it enters the mandibular canal. The **retromylohyoid** [REH tro my lo HI oid] **curtain** is a curtain of mucous membrane along the medial, posterior portion of the mandible near the floor of the mouth, extending between the anterior pillar of the fauces and the pterygomandibular fold. An arrow points to the location of this curtain (but it is not visible) in Figure 15-27. It is an important limiting structure when forming the lingual border (flange) of a mandibular complete denture.

### INFERIOR ALVEOLAR INJECTION: ANESTHETIZING MANDIBULAR TEETH, SURROUNDING TISSUE, AND ADJACENT FLOOR OF THE MOUTH AND TONGUE

The nerves being blocked here are branches of the **third division or mandibular branch of the fifth cranial (trigeminal) nerve**. Since the bone of the mandible is more dense than in the maxillae, it is usually more effective to anesthetize mandibular teeth by applying the anesthetic next to the inferior alveolar nerve before it enters the mandible, or, for premolars and anterior teeth, to apply anesthetic into the mandible at the opening of the mental foramen. To reduce pain for all structures supplied by the entire **inferior alveolar nerve**, the anesthetic is deposited next to the mandibular nerve before it enters the mandibular foramen. Recall that the *mandibular foramen* is located on the medial surface of the ramus of the mandible, a little over halfway from the anterior to the posterior border of the ramus (Fig. 15-29). On most adults, the foramen is also located a small distance (on average about 5 mm or 1/4 to 1/2 in.) superior to the level of the chewing

(Continued)



surfaces of the posterior teeth. In order to reach the mandibular foramen, the needle penetrates the mucosa of the *pterygomandibular fold* about 1/2 in. above the occlusal plane (*Fig. 15-30*). (On an edentulous patient, use the landmark of the *retromolar pad* and inject just slightly superior to it.) After penetration into the mucosa, continue moving the needle tip parallel to the medial surface of the ramus until you reach the location of the inferior alveolar nerve, that is, slightly beyond half way from the anterior to the posterior border of the ramus. Recall that the internal surface of each ramus, when viewed from above, diverges wider as it goes posteriorly, so the handle of the syringe must be angled across the premolars on the opposite side in order to parallel the medial surface of the ramus. This angle is evident in *Figure 15-31* and can also be seen in the mouth in *Figure 15-30*. If bone is touched before reaching the estimated depth of the foramen, or if the bone is not reached when you are well beyond the foramen, you need to pull back the needle, re-angle the syringe, and try again. If bone is reached at the estimated location of the inferior alveolar nerve, pull back the needle very slightly to avoid damaging the bone, then aspirate to ensure you are not in a vessel, and inject the anesthetic.

Anesthetic can be placed in small amounts at intervals while entering through the mucosa toward the mandibular foramen (reinspiring each time) in order to reach the **lingual nerve branch**, which is next to the inferior alveolar nerve. Because the lingual nerve is located within the tissue adjacent to the mandibular nerve (*Fig. 15-32*), the anesthetic can infiltrate through tissue to reach the lingual nerve and result in numbness to the anterior half of the tongue and adjacent lingual mucosa of the floor of the mouth on the side being injected. Blocking the inferior alveolar nerve and lingual nerve should reduce pain in all mandibular teeth and almost all surrounding tissues but should also numb half of the tongue and half of the lip on that side. The only area not numb would be the tissue just buccal to the molars, which is innervated by the **buccinator (long buccal) nerve** (described earlier).

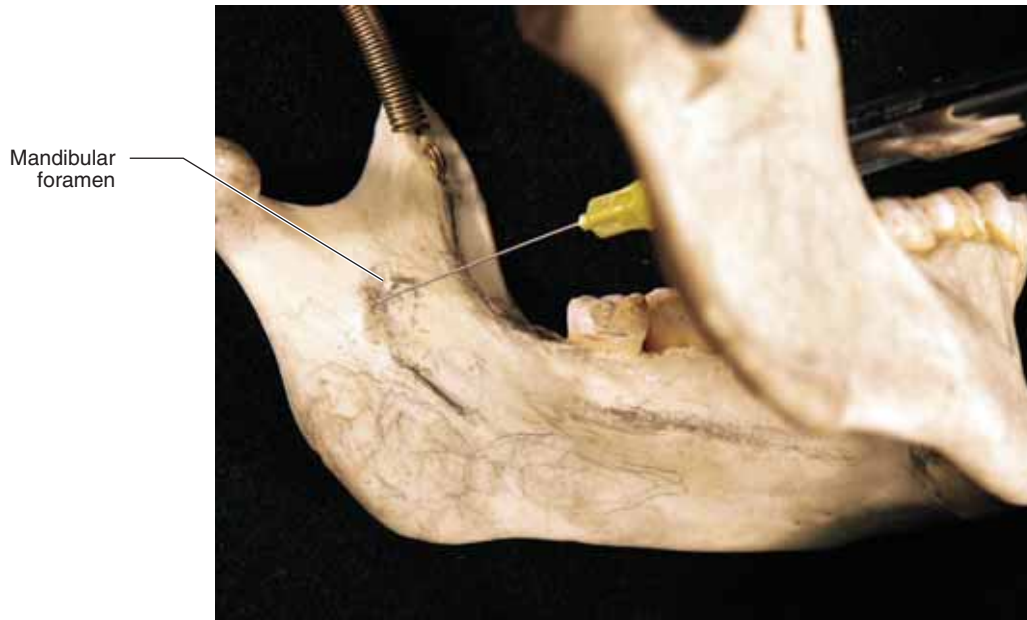
If only tissue or teeth of mandibular premolars or anterior teeth need to be anesthetized, the anesthetic solution can be applied at the location of the *mental foramen* (*Fig. 15-33*). At this location in the mandible, the **mental nerve** branches off the inferior alveolar nerve and exits the mandible to spread anteriorly and innervate the lower lip and adjacent labial tissue. Just inside of this foramen, the inferior alveolar nerve continues forward within the mandible as **incisive branches** to innervate the pulps of anterior teeth. This foramen is normally palpable (and evident on radiographs) at a level between or near the root tips of the mandibular premolars. The injection enters mucosa at the depth (fornix) of the buccal vestibule extending to the level of the palpated foramen. Due to the posterior superior direction of the canal inside of the mental foramen, it is best to direct the needle inferiorly and slightly from the distal (*Fig. 15-33*). An advantage of this injection is that it does not numb any of the tongue, so it does not affect the ability of the person to speak as might occur with an inferior alveolar block that numbs the tongue on the side of the injection.

Note: It may also be possible to anesthetize only mandibular incisors by placing the anesthetic just labial to the alveolar bone facial to the root tips of the mandibular anterior teeth. Even though the mandibular bone is dense, this may be successful *if* the bone overlying these roots is quite thin. Using this technique, one can numb the mandibular facial tissue and anterior teeth, but neither this mandibular facial infiltration technique nor the mental nerve block will numb the lingual tissue or tongue.

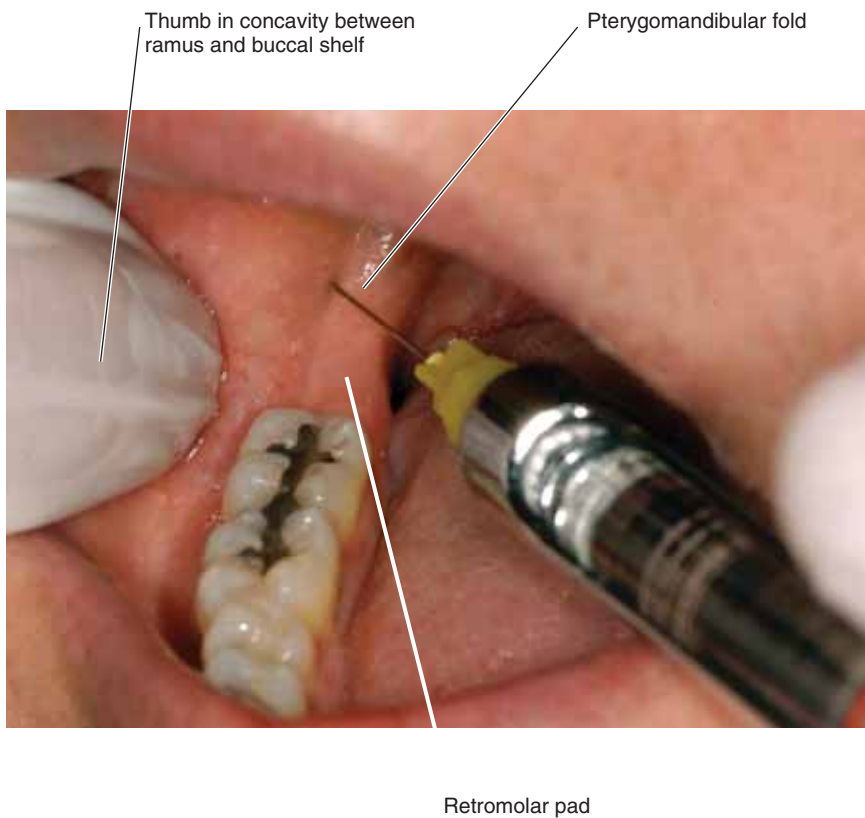
## D. TONGUE

The tongue is a broad, flat organ largely composed of muscle fibers and glands. It rests in the floor of the mouth within the curved body of the mandible. The tongue changes its shape with each functional movement. The anterior two thirds is called the **body** (the part that is most visible during an intraoral examination of the tongue), and the posterior one third is the tongue base or **root** (which is difficult to see in most mouths since it is back so far). Recall that the body of

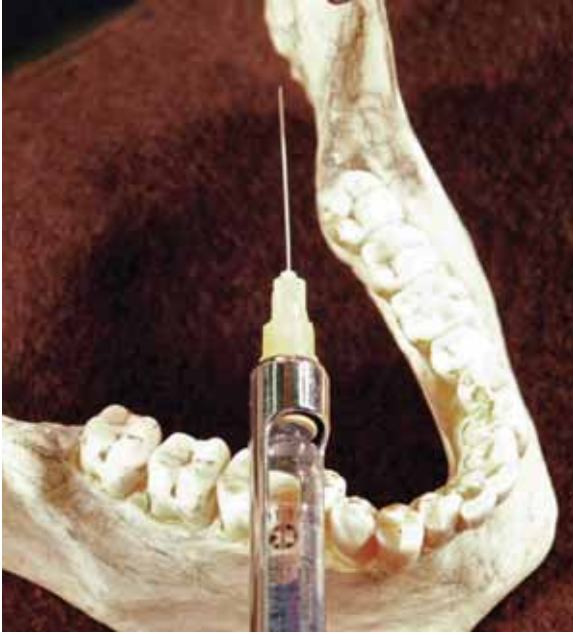
the tongue is innervated for touch and pain by cranial nerve V (the trigeminal nerve) and for taste by cranial nerve VII (chorda tympani branches) of the facial nerve. The base or root of the tongue is innervated for taste *and* feeling by cranial nerve IX (the glossopharyngeal nerve). Examine the tongue by wrapping it in a damp gauze square to grab its slippery surface while gently pulling it first to one side, then to the other. The tongue muscles that may fight you in this endeavor are innervated by cranial nerve XII (hypoglossal nerve).



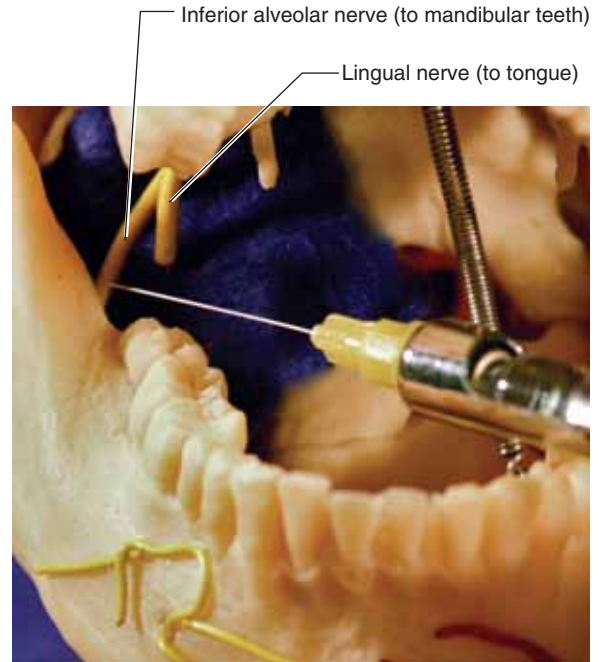
**FIGURE 15-29.** Anesthetic syringe needle tip placed at the location on the mandible for blocking the **inferior alveolar nerve** before it enters the *mandibular foramen* and canal. Note the position of the mandibular foramen about halfway between the anterior and posterior border of the ramus, and the foramen location relative to the occlusal plane of the mandibular teeth (which is slightly superior to the plane by about 5 mm).



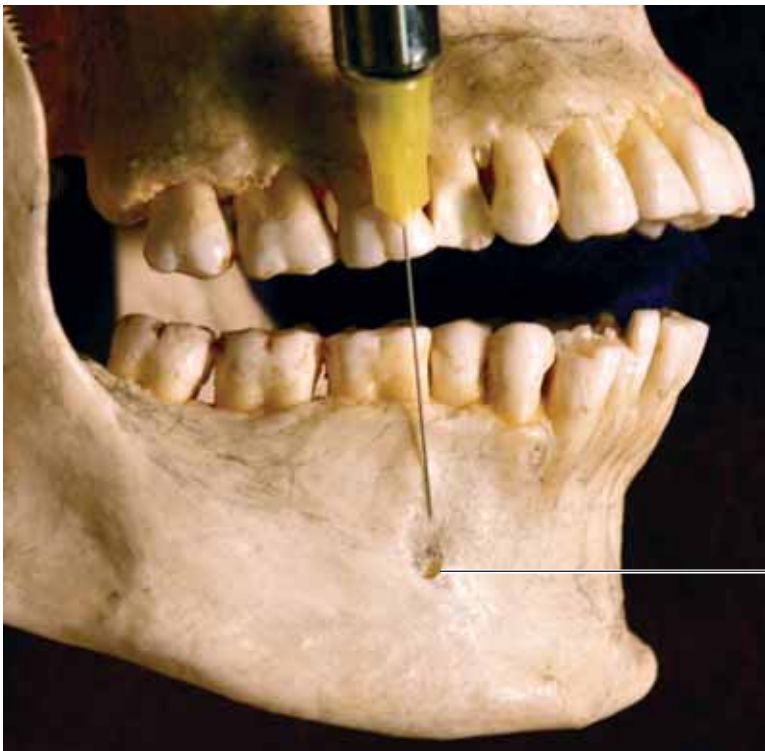
**FIGURE 15-30.** Anesthetic syringe needle tip aiming toward the **inferior alveolar nerve** by penetrating the oral mucosa at the location of the *pterygomandibular fold* just occlusal to the *retromolar pad*. By angling the syringe cartridge over the premolars on the opposite side, the needle can be directed toward the inferior alveolar nerve where it enters the mandible through the mandibular canal. For the average-sized person, a long needle penetrates to about half of its total length in order to reach the ramus and foramen, but this depth may be deeper for a very large-boned person or less deep for a very small-boned person.



**FIGURE 15-31.** A superior view of the **mandible and ramus** showing the angle of the syringe required to reach the opening of the **mandibular canal**. The syringe cartridge must be directed over the premolars on the opposite side in order to parallel the internal surface of the ramus (which diverges considerably posteriorly).



**FIGURE 15-32.** Two wires represent the **inferior alveolar nerve** (touched by the needle), and a cut portion of the **lingual nerve branch** (which goes to the tongue). Notice that the lingual nerve would be anesthetized if some anesthetic were applied prior to reaching the inferior alveolar nerve.



Mental foramen

**FIGURE 15-33.** The syringe needle tip is located adjacent to the **mental foramen**. Note its location near the estimated root tips of the mandibular premolars. Applying anesthetic here can reduce pain to the soft tissue of the chin and lower lip on that side by blocking the **mental nerve**, which splits off the inferior alveolar nerve and exits the mandibular at this location. If enough concentration of anesthetic makes its way into the opening of the mental foramen, it can also reduce pain to premolar teeth and adjacent gingiva (and possibly anterior teeth) by blocking the **incisive branches** of the inferior alveolar nerve that supply the anterior teeth). This injection would *not* numb the tongue.

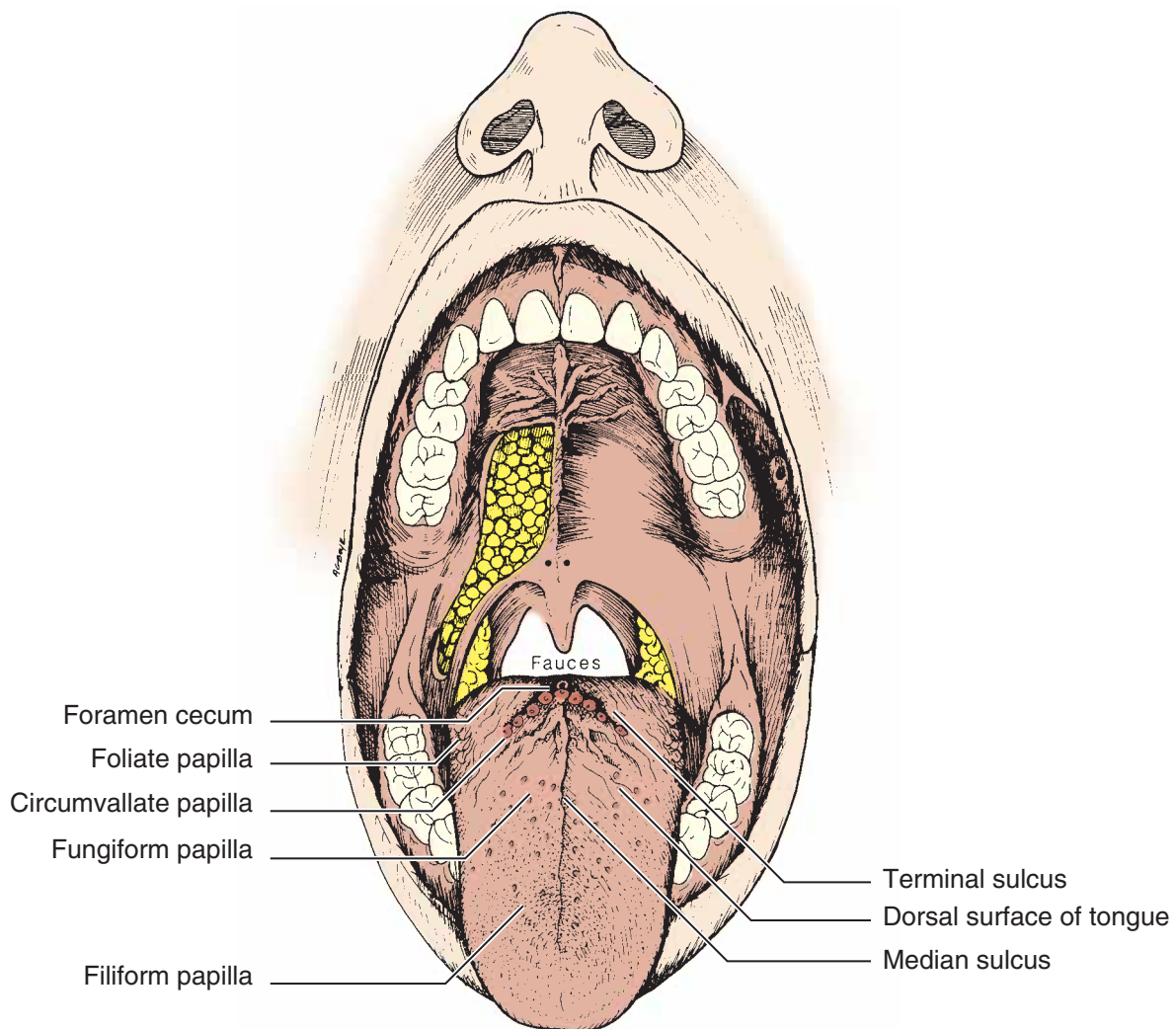


## 1. DORSUM OF THE TONGUE

Use *Figure 15-34* as a guide for landmarks on the **dorsum** (top) of the tongue. However, most people are unable to stick their tongue as far forward as in this illustration. The dorsum (dorsal or superior surface) of the tongue is the principal organ of taste and is invaluable during speech, mastication, and deglutition (swallowing). The dorsum of the tongue is grayish-red and is rough. It is covered by two kinds of papillae [pah PILL e] or projections. The fine hair-like **filiform papillae**, which are quite numerous, cover the anterior two thirds of the dorsal surface of the tongue. The more sparse, scattered, and shorter **fungiform papillae** are easy to identify because of their larger round shape and deep red color (*Fig. 15-35*). Fungiform papillae get their name because they have a mushroom [fungus] shape when viewed in cross section from the side.

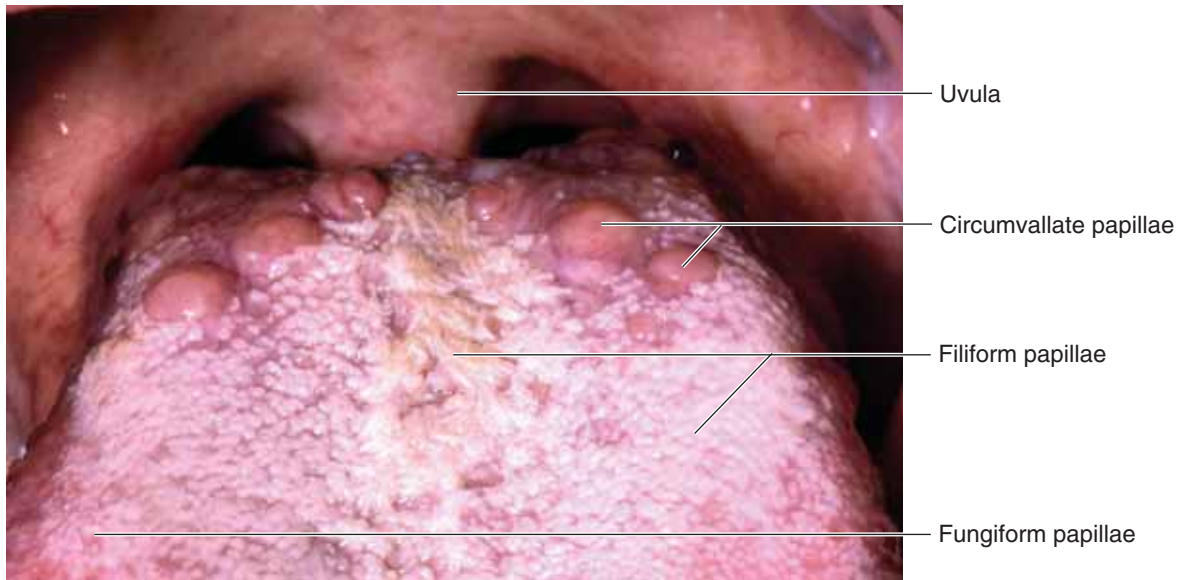
Fungiform papillae are most concentrated near the tip of the tongue.<sup>2</sup>

Another type of papilla is also found near the junction of the anterior two thirds and posterior one third of the tongue. The **circumvallate** [ser kum VAL ate] **papillae** are 8 to 12 prominent, flat, mushroom-shaped papillae forming a V-shaped row on the dorsum near the posterior third of the tongue (*Fig. 15-35*). Their walls contain numerous taste buds. The **terminal sulcus** is a shallow groove located just posterior to the circumvallate papillae, and it separates the body of the tongue from the root of the tongue (*Fig. 15-34*). The **foramen cecum** [SEE kum] is a small circular opening in the center of the terminal sulcus immediately posterior to the circumvallate papillae. This foramen is the remnant of the *thyroglossal duct* from which the thyroid gland developed. It is usually necessary to hold the tongue quite



**FIGURE 15-34.** Structures of the **dorsal (top) surface of the tongue**





**FIGURE 15-35. Dorsal surface of the tongue:** Structures include the row of prominent **circumvallate papillae**, numerous hair-like **filiform papillae** (which are normally not this long), and a few small, round, red **fungiform papillae**. The uvula is above the tongue. (Photo courtesy of Carl Allen, D.D.S., M.S.D.)

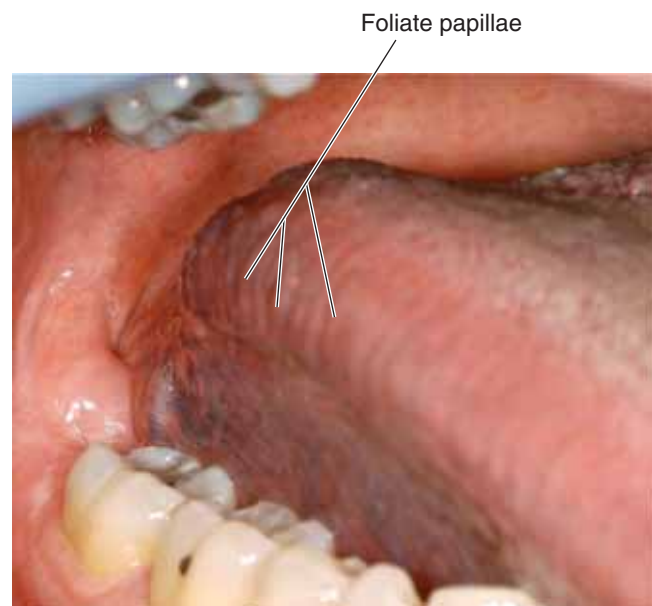
firmly with gauze and pull it forward in order to see the circumvallate papillae and their neighboring structures because of their extremely posterior location. Posterior to the terminal sulcus, the smoother posterior one third of the dorsum contains numerous mucous-producing glands and lymph follicles (or nodules) referred to as the lingual tonsil (not visible on Fig. 15-34).

A fourth type of papillae is visible on the lateral surfaces of the tongue seen when a person sticks out the tongue. It may be necessary to use a dry gauze pad to gently pull the tongue to the side in order to see these large, red, leaf-like projections known as **foliate** [FO li ate] **papillae** (Fig. 15-36). They contain some taste buds.

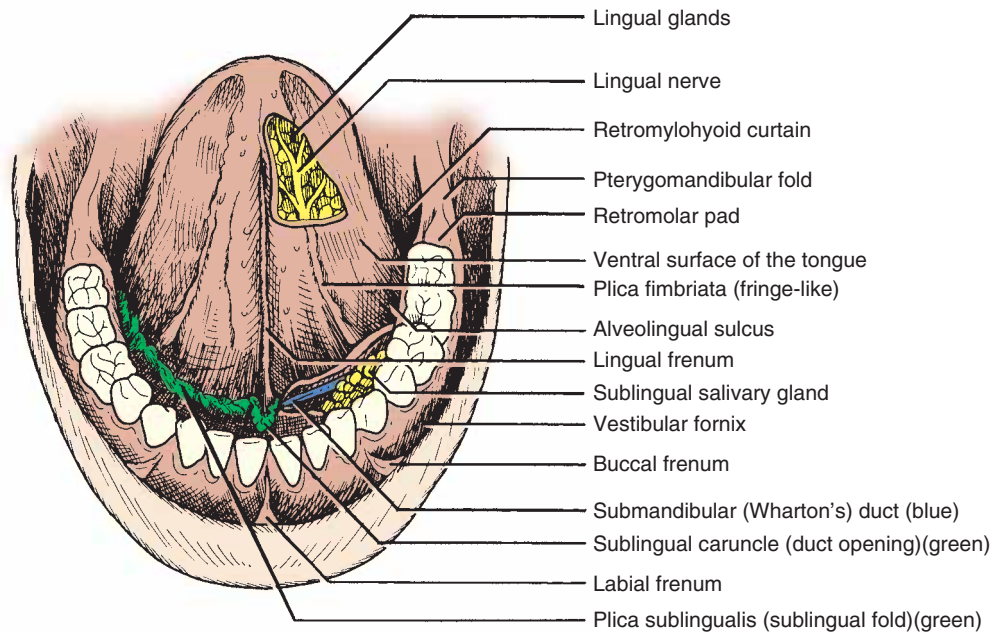
## 2. VENTRAL SURFACE OF THE TONGUE

The **ventral** or undersurface of the tongue is shiny, and blood vessels are visible. Refer to *Figure 15-37*. The **lingual frenum** is a thin sheet of tissue at the midline that attaches the undersurface of the tongue to the floor of the mouth. Look in a mirror and raise your tongue to watch how this tissue fold limits the amount of tongue movement.<sup>D</sup> In a person who is tongue-tied, the lingual frenum is attached to mucosa on the lingual surface of the mandible perhaps only 3 or 4 mm inferior to the gingival margins of the central incisors. Further, as the tongue moves, this frenum could pull on the attached gingiva, contributing to loss of attached gingiva and subsequent periodontal problems. A simple surgical procedure can change this area of attachment.

**Plica fimbriata** [PLY kah fim bri AH tah] (also called **fimbriated folds**) are delicate fringes of mucous membrane on each side of the frenum on the ventral surface of the tongue. The free edge of this fold may have a series of fringe-like processes. These are very delicate



**FIGURE 15-36. Lateral surface of the tongue:** Prominent fold-like foliate papillae must be distinguished from oral cancer that may develop in this area. (Photo courtesy of Carl Allen, D.D.S., M.S.D.)



**FIGURE 15-37.** Structures of the ventral (under) surface of the tongue and floor of the mouth: Some mucosa was dissected away on one side of the tongue and floor of the mouth to reveal the **sublingual salivary gland** (seen on the right side of the drawing in yellow), which is located just beneath the **sublingual fold** (seen intact in green on the left side of the drawing). The **submandibular duct** (blue) passes from the *submandibular gland* (not visible) to the openings on the **sublingual caruncles** (green structures on the midline where the right and left sublingual folds join).

and often difficult to see unless gently moved by a tongue blade or mirror. In some animals, these fringes of tissue serve to keep the teeth clean.

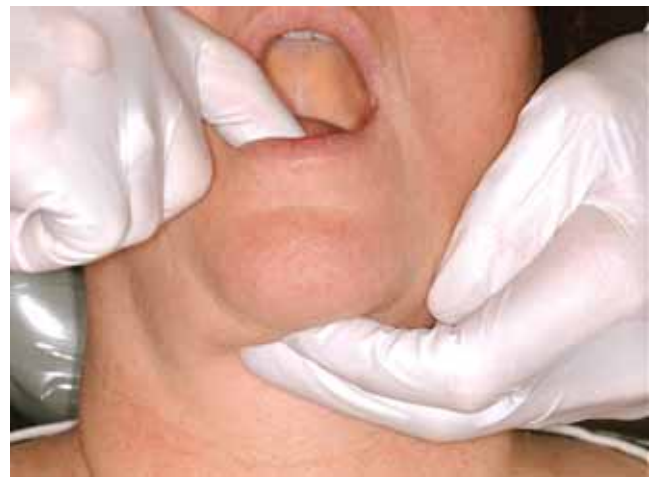### E. FLOOR OF THE MOUTH

Visually examine the floor of the mouth by having a partner raise the tongue. Also, feel for unusual lumps by palpating the floor of the mouth with the forefinger of one hand pressing against the floor and opposed outside of the mouth by a finger of the other hand. This method of palpation is called **bimanual palpation** since it requires two hands (*Fig. 15-38*).

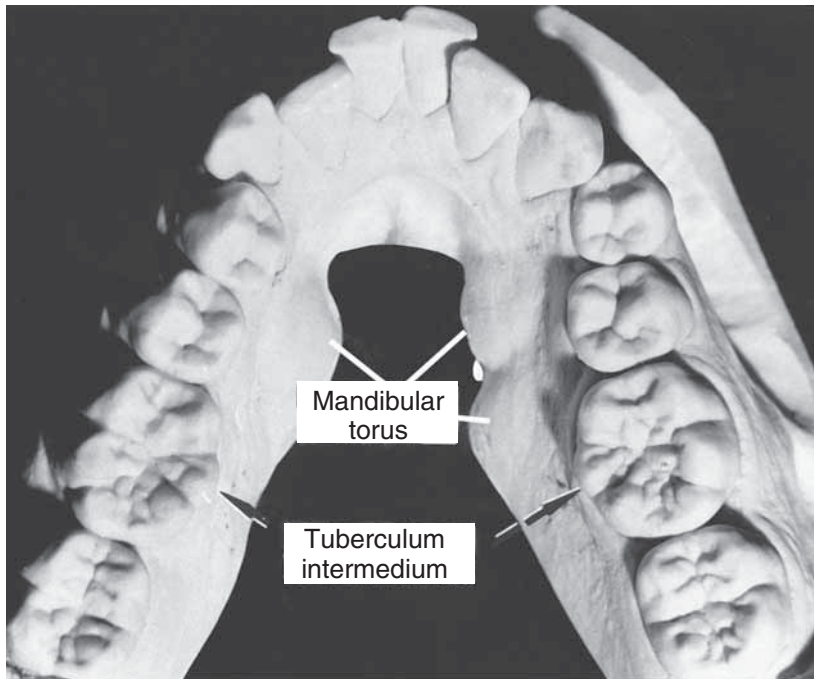
Like the ventral surface of the tongue, the tissues of the floor of the mouth are shiny, and some large blood vessels may be seen near the surface. The **alveololingual sulcus** (*Fig. 15-37*) is the broad, valley-shaped space between the mandibular alveolar bone and the tongue. You can gently place your finger in this broad sulcus and press laterally to confirm whether there are any bony ridges on the medial surface of the mandible. A prominent bump in this area might be a relatively common occurrence: a mandibular torus.

A **mandibular torus** (plural *tori*) (*Fig. 15-39*) is a bulbous protuberance of bone beneath a thin mucous membrane covering on the medial side of the mandible

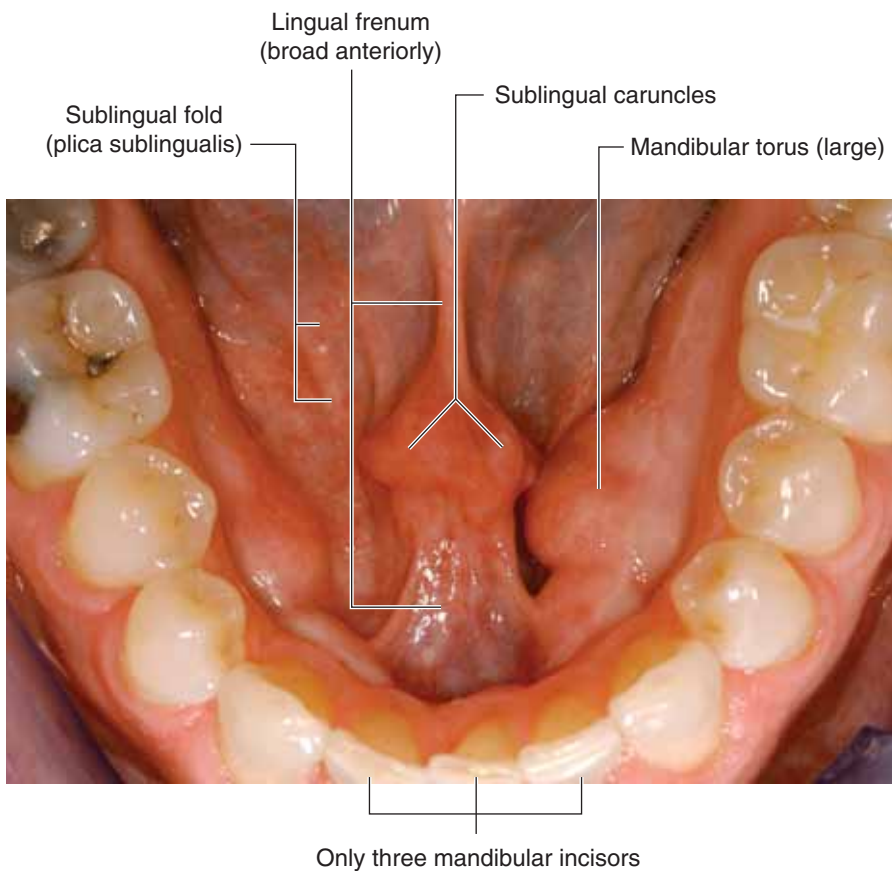
often found in the premolar region (*Fig. 15-40*). Mandibular tori may be inherited as a genetic trait and are not uncommon. They usually cause no problems but may be irritated during chewing of coarse foods, or when mandibular dental impressions are made. After all



**FIGURE 15-38.** Bimanual palpation (using the opposing fingers of two hands) in order to feel for lumps or bumps (like a salivary duct blockage) within the floor of the mouth.

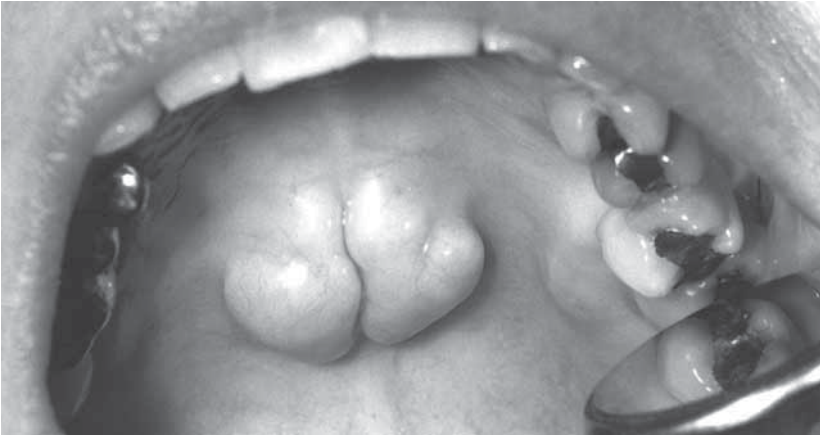

**FIGURE 15-39.** Mandibular tori (bulbous elevations of bone) on the lingual surface of a stone cast of the mandible. (Also, note that the mandibular first molars have six, instead of the usual five, cusps. The extra lingual cusp is called a tuberculum intermedium.)



**FIGURE 15-40.** Floor of the mouth: The sublingual folds (plica sublingualis) lie over the sublingual glands. The sublingual caruncles are located on either side of the lingual frenum where the submandibular gland ducts empty into the mouth (via Wharton's ducts). Also, note the very prominent lingual tori under the mucosa projecting off of the lingual surface of the mandible.





**FIGURE 15-41.** A maxillary torus palatinus or palatal torus.

lower teeth have been lost and removable dentures are to be made, it may be necessary to surgically remove mandibular tori. A similar torus may also occur in the middle of the palate and is called a **palatine torus** or **torus palatinus** (Fig. 15-41). **Exostosis** [ek sos TOE sis, plural is **exostoses**] is the general term used to describe any excess (hyperplastic) bony growth projecting outward from the bone surface, such as a torus palatinus or mandibular torus, but can also be used to describe bony ridges that may form on the facial (cheek) surface of the alveolar processes of the mandible or maxillae.

## F. SALIVARY GLANDS (INTRAORALLY)

Refer to Figure 15-37 while studying these landmarks on the floor of the mouth. On the floor, the **sublingual folds** called the **plica sublingualis** [PLY ka sub ling GWAL is] extend anteriorly on each side of the floor of the mouth from the first molar region to the lingual frenum. Along these folds are many small openings of ducts from underlying **sublingual salivary glands** located in this region. These sublingual glands secrete purely mucous saliva (ropy-type), producing only 5 to 8% of our saliva.<sup>1</sup>

On the midline at the junction between the right and left sublingual folds, on either side of the lingual frenum, is a pair of bulges called **sublingual caruncles** (Fig. 15-40), each with an opening from ducts of the **mandibular salivary glands** (**Wharton's ducts**). Wharton's ducts drain the large submandibular glands located posteriorly on either side in the submandibular fossae of the internal surface of the mandible. These glands produce about two thirds of our saliva.<sup>1</sup> Their secretions are primarily serous (two thirds serous cells, one third mucous cells<sup>4</sup>). A person normally secretes over a pint of saliva during 24 hours.<sup>E</sup>

If you use bimanual palpation and gently move one finger in the floor of the mouth (opposing another

outside of the mouth) from posterior to anterior over the sublingual folds and the underlying submandibular ducts, saliva may flow out of the gland openings in the caruncles. Saliva may even squirt out of the mouth through the openings in the caruncles when the patient opens wide (like when you yawn during a boring lecture) and the surrounding muscles apply pressure to the duct. It is possible for saliva to calcify within the ducts and block the flow of saliva. This could cause symptoms that get worse when eating since the saliva cannot make its way out of the ducts. This calcified blockage (called a **sialolith** [si AL o lith]) may be palpated, confirmed with a radiograph, and surgically removed.

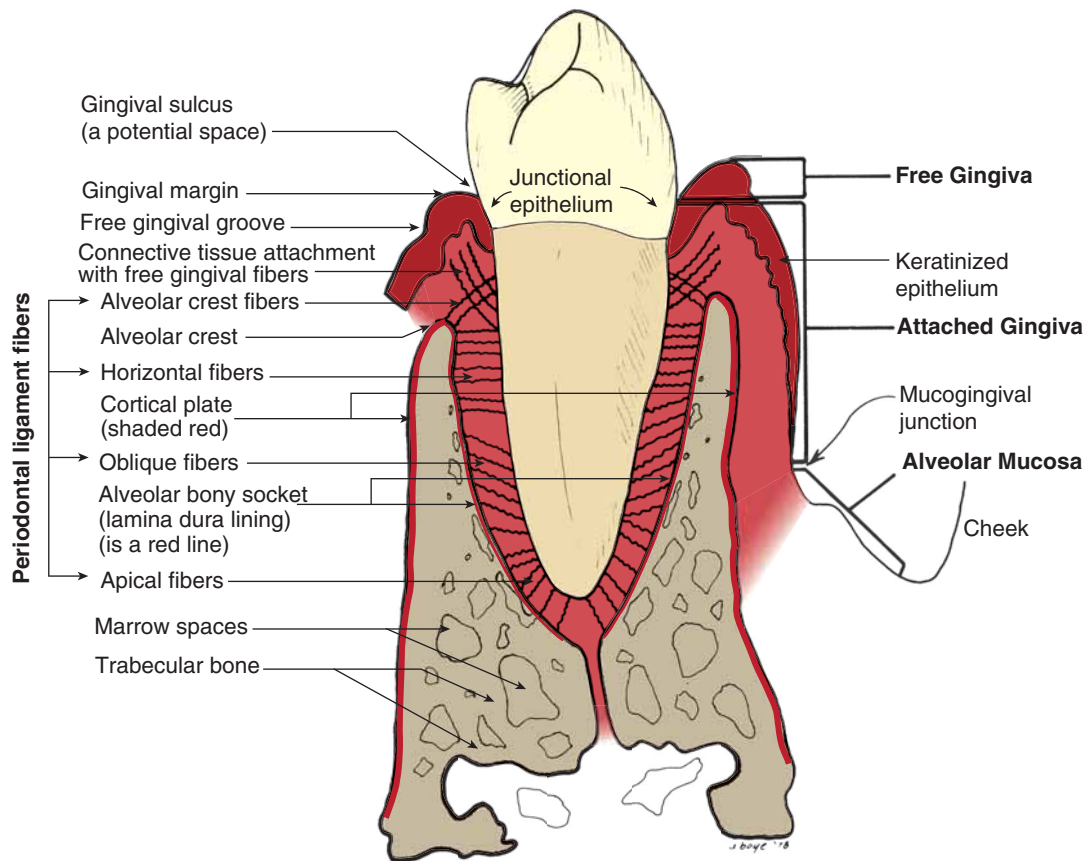
## G. ALVEOLAR PROCESS (OF UNDERLYING BONE)

The bone surrounding the roots of the teeth should be palpated for bony growths (exostosis) or lesions.

## H. GINGIVA

The **periodontium** [per e o DON she um] was discussed in detail in Chapter 7 but is reviewed here in order to emphasize the landmarks that can be identified in the mouth of a healthy person. Recall that the periodontium is comprised of the supporting tissues of the teeth, including surrounding alveolar bone, the gingiva, the periodontal ligaments, and the outer layer of the tooth roots (covered with cementum). Evaluation of the thickness of the periodontal ligament and the amount of alveolar bone surrounding each tooth requires appropriate radiographs. Recall that the **periodontal ligament** is a very thin ligament composed of many fibers that connects the outer layer of the tooth root with the thin layer of dense bone (seen on a radiograph as a white line called **lamina dura**) lining each alveolus or tooth socket seen in Figure 15-42. The fibers



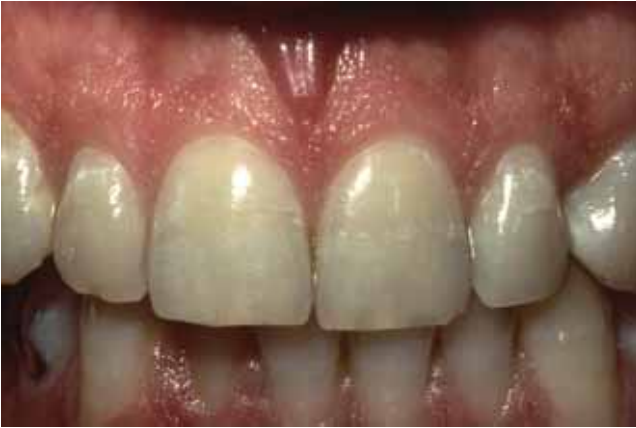

**FIGURE 15-42.** Periodontium including zones of gingiva and periodontal fiber groups: A mandibular left first premolar is suspended in its alveolus by the five groups of periodontal ligament fibers: *apical*, *oblique*, *horizontal*, *alveolar crest*, and *free gingival fibers* are visible. A sixth group, called *transeptal fibers*, not visible in this drawing, attaches from the cementum of one tooth to the cementum of the adjacent tooth at a level between the free gingival and alveolar crest fibers. The fibers of the periodontal ligament are much shorter than depicted here, averaging less than  $\frac{1}{4}$  of a millimeter.

of the periodontal ligament represented in this figure are greatly enlarged; the actual width of this ligament is less than  $\frac{1}{4}$  mm. The periodontal ligament is made up of four groups of fibers with differing directions and attachments and different names. The **apical**, **oblique**, **horizontal**, and **alveolar crest fibers** connect different parts of the tooth root (cementum) to the dense bone lining the tooth socket. The oblique fibers provide the major support to the tooth during function. **Free gingival fibers** are directed from tooth root (cementum) into free gingiva. A sixth group, the **transeptal fibers**, is not seen on Figure 15-42 since these fibers run directly from the root (cementum) of one tooth to the cementum of the adjacent tooth at a level between the free gingival and alveolar crest fibers.

The **gingiva** is the only visible part of the periodontium that is seen in the initial oral examination. It is the part of the **oral mucosa** covered by **keratinized epithelium** that covers the alveolar processes of

the jaws and also surrounds the portions of the teeth near where the root and crown join (cervical portion). As discussed in detail in Chapter 7 (Periodontics), healthy gingiva varies in appearance from individual to individual and in different areas of the same mouth. It should be resilient and firm, *stippled* (that is, textured with many small depressions, like an orange peel, and *coral pink* in persons with light skin pigmentation (Fig. 15-43), or in persons with dark coloring of the hair and skin, the gingiva may be brown or spotted with brown (**melanin pigmentation**). The margins of healthy gingiva are thin in profile and *knife edged*. The shape of the facial gingival margin around each tooth somewhat parallels the CEJ, so it is *shaped like a parabolic arch* (similar in shape to the McDonald's arches). This repeated parabolic arch pattern around each tooth is evident in Figure 15-43. Refer to Table 7-1 in Chapter 7 for a list of all characteristics of healthy gingiva.



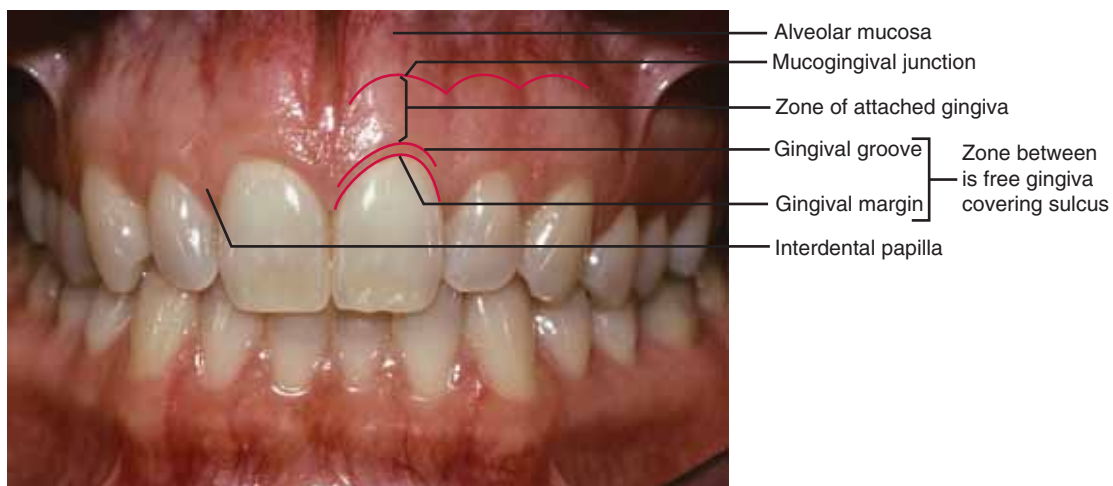
**FIGURE 15-43.** Healthy gingiva, close-up. Note the ideal contours and stippled (orange peel) surface texture that is usually most noticeable on the maxillary labial attached gingiva.

Gingiva can be visually divided into zones as shown in *Figure 15-44*. The zone closest to the tooth crown is **unattached gingiva**, which includes the free gingiva and the interdental papillae. **Free gingiva** (or marginal gingiva) is the tissue that is not attached to the tooth or alveolar bone. It surrounds each tooth to form a collar of tissue with a potential space or **gingival sulcus** (crevice) hidden between it and the tooth. Free gingiva extends from the **free gingival margin** (the edge of gingiva closest to the chewing or incising surfaces of the teeth) to the **free gingival groove** (visible in about one third of adults) that separates free gingiva from attached gingiva. The **interdental papilla** (interproximal papilla) [pah PILL ah] (plural is papillae [pa PILL

ee]) is that part of the unattached gingiva between adjacent teeth. A healthy papilla conforms to the space between two teeth (interproximal space), so from the facial view it comes to a point near where the adjacent teeth contact. The papilla also has the hidden sulcus (potential space) next to each tooth where dental floss can fit once it passes between the teeth.

**Attached gingiva** is a band or zone of gray to light or coral pink (possibly with melanin pigmentation) keratinized masticatory mucosa that is firmly bound to the underlying bone (*Fig. 15-44*). It extends between the free gingiva (at the free gingival groove if present) and the more movable alveolar mucosa. The amount or width of attached gingiva varies normally from 3 to 12 mm.

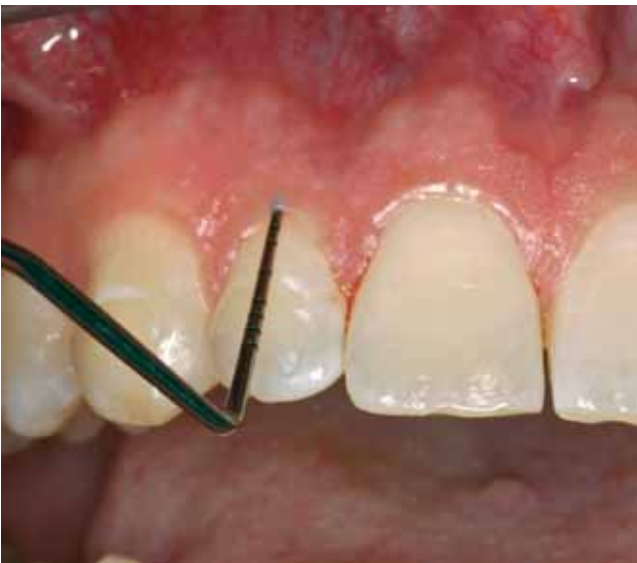The **mucogingival line (junction)** (*Fig. 15-44*) is a scalloped junction between attached gingiva and the looser, redder **alveolar mucosa**. Alveolar mucosa is movable mucosa, dark pink to red, due to increased vascularity and more delicate nonkeratinized tissue just apical to the mucogingival line. It is more delicate and less firmly attached to the underlying bone than the attached gingiva and is more displaceable as well because of the underlying vessels and connective tissue. Palpate these two types of tissues and you will feel the difference in firmness. This movable alveolar mucosa is found in three places: in the maxillary and mandibular facial vestibule and in the mandibular lingual aspects (alveolingual sulcus) but not on the palate, which has firm, attached keratinized tissue for almost the entire surface. Therefore, the mucogingival line is present on the facial aspects of the maxillary and mandibular gingiva but only on the lingual aspect of mandibular gingiva.



**FIGURE 15-44.** Clinical zones of the gingival. (Photo courtesy of Lewis J. Claman, D.D.S., M.S.)

Keratinized gingiva is the general term used to describe both the free and attached gingiva. It is widest on the facial (vestibular) aspect of maxillary anterior teeth and the lingual aspect of mandibular molars. It is narrowest on the facial aspect of mandibular premolars.<sup>5</sup>

The **gingival sulcus** is not seen visually but can be evaluated with a periodontal probe since it is actually a space (or potential space) between the tooth surface and the narrow unattached cervical collar of free gingiva (Fig. 15-45). The gingival sulcus is lined with the sulcular epithelium. It extends from the free gingival margin to the junctional epithelium. Clinically, the healthy gingival sulcus ranges in probing depth from about 1 to 3 mm and should not bleed when correctly probed. *Junctional* (or attached) *epithelium* (seen in cross section in Fig. 15-42) is a band of tissue at the most apical portion of the gingival sulcus that attaches the gingiva to the tooth. It is about 1 mm in width.<sup>6</sup> There is also a 1- to 1.5-mm *connective tissue attachment* to the root above the crest of bone. The periodontal probe usually penetrates into the junctional epithelium, hence the difference between the depth determined through clinical probing and the depth seen on a microscopic cross section.<sup>7, F</sup> Sometimes, during the process of eruption of the mandibular last molar through the mucosa, a flap of tissue may remain over part of the chewing surface called an **operculum** (seen previously in Fig. 7.7). This operculum can easily be irritated during chewing and become infected.



**FIGURE 15-45.** Periodontal probe in place in the gingival sulcus: The end of the probe can actually be seen here through the thin layer of unattached gingiva.

## I. THE TEETH: COUNT THEM

An important part of the oral examination is to determine which teeth are erupted in the mouth, identify them by name or universal number, and determine which teeth are missing. When the number of teeth is fewer than expected for a patient, a careful history can confirm tooth loss by disease or accident or teeth removed prior to orthodontic treatment. When history does not confirm such reasons for tooth loss, radiographs are recommended to rule out the possibility of unerupted (impacted) teeth beneath the mucosa or surrounded by bone (impacted teeth) or to confirm that a tooth never formed. It is also possible for the patient to have extra (supernumerary) teeth or unexpected teeth (such as retained primary teeth in a 30-year-old). These factors impact treatment planning decisions and should be documented.

The total number of teeth depends on the age of the individual and the stage of development of the teeth. Recall that the complete primary dentition consists of 20 teeth. From about 2 years old until almost 6 years old, most children have all 20 primary teeth present in the mouth but no permanent teeth. For the next 6 years, there is normally a mix of some primary and some permanent teeth (called mixed dentition with 24 teeth including the 4 permanent first molars) until about 12 years of age, when all primary teeth have been lost and only permanent teeth are present. At age 12, there would normally be 28 permanent teeth (all but the unerupted third molars). Eventually (by the late teens or early 20s), the complete permanent (or secondary) dentition consists of 32 teeth, including the four third molars that erupt (become visible) into the mouth.

### LEARNING EXERCISE

Examine a partner (using infection control procedures) and identify each of the structures listed on this modified Head and Neck examination form. (The order of structures listed on this form is the same order as that encountered within the chapter, so it should be easy to follow the text as you perform the exam.) Use a tongue depressor or a mouth mirror to retract the lips and cheeks. A good light is needed, and a mouth mirror is useful for reflecting light into remote areas and for holding the tongue or cheek out of the way during your examination.

NORMAL STRUCTURES FOUND  
DURING THE HEAD AND NECK EXAM

(Key: \* = not found on all patients)

Extraoral Examination:

**General appearance:** healthy walk and posture; normal breathing

**Head:** symmetrical (or not); jaw midline symmetrical (or not)

**Skin:** evaluate for lesions, palpate underlying muscles: masseter (origin, insertion); temporalis (anterior and posterior fibers: origin); medial pterygoid (insertion)

**Eyes:** clear sclera; pupil not considerably dilated or constricted

**Temporomandibular joint:** palpate lateral surface of condyle during function; posterior surface of the condyle (in internal auditory meatus)

**Neck:** palpate thyroid gland; submandibular salivary gland

**Nodes:** palpate for submental; submandibular; parotid (preauricular); postauricular; cervical (around sternocleidomastoid muscle)

**Salivary glands:** palpate parotid gland and submandibular gland (bimanual for sublingual [intraoral])

**Lips:** commissure; nasolabial fold; labiomental groove; tubercle; philtrum; vermilion zone; mucocutaneous junction; wet line

Intraoral Examination:

**Mucosa: Labial:** labial frenum; fornix

**Buccal:** buccal frenum; commissural papule; \*linea alba; parotid papilla from parotid gland (Stensen's duct: press along it for saliva); \*Fordyce granules (orange-colored spots)

**Palate: Hard palate:** incisive papilla; palatine raphe; rugae; \*torus palatinus; pterygoid hamulus

**Soft palate:** vibrating line (say "ah"); fovea palatini; uvula

**Tonsils/oropharynx:** fauces; glossopalatine (anterior) arch; pharyngopalatine (posterior) arch; \*palatine tonsils; pterygomandibular fold; retromylohyoid curtain

**Tongue: Dorsum:** filiform, fungiform, and circumvallate papillae (way back); foramen cecum and terminal sulcus (probably too far back to see)

**Lateral:** foliate papillae

**Ventral:** lingual frenum; plica fimbriata (can "separate" from tongue with mirror handle)

**Floor of mouth:** alveololingual sulcus; \*mandibular torus, palpate bimanual: sublingual folds over sublingual glands; sublingual caruncles with Wharton's ducts of submandibular gland (may squirt)

**Salivary glands:** buccal mucosa: parotid papilla ("milk" Stensen's duct to see saliva drip out)

Floor of mouth: sublingual folds over sublingual glands with caruncle and opening to submandibular gland (may squirt)

**Alveolar process:** \*exostosis (particularly on buccal aspect); maxillary tuberosity (pterygoid hamulus)

**Gingiva:** free gingiva (has sulcus; would confirm with probe); \*free gingival groove: interdental papilla; attached (keratinized) gingiva; mucogingival junction; retromolar pad (mandibular), \*tissue overlapping last molar = operculum

**Teeth:** count all erupted teeth; note retained primary teeth: \*impacted (on radiographs), malformations, etc.

**Occlusion (circle one): class I II III:** evaluate first molar and canine relationships



## Review Questions

Test your newly acquired knowledge by matching the forty landmarks with their descriptions. Place the appropriate letter or letters on line on left.

- |  |   |
|--|---|
| <p>___ 1. Dorsum of tongue</p> <p>___ 2. Hard palate</p> <p>___ 3. Pharynx</p> <p>___ 4. Elevated midline of hard palate</p> <p>___ 5. Stensen's duct</p> <p>___ 6. Alveolar mucosa</p> <p>___ 7. Fordyce's spots</p> <p>___ 8. Melanin</p> <p>___ 9. Gingiva between teeth</p> <p>___ 10. Palatal tissue bump between teeth<br/>Numbers 8 and 9</p> <p>___ 11. Vibrating line</p> <p>___ 12. Wharton's duct openings</p> <p>___ 13. Labial frenum</p> <p>___ 14. Ventral surface of tongue</p> <p>___ 15. Oral cavity</p> <p>___ 16. Retromolar pad</p> <p>___ 17. Maxillary tuberosity</p> <p>___ 18. Filiform papillae</p> <p>___ 19. Torus mandibularis</p> <p>___ 20. Attached gingiva</p> <p>___ 21. Fauces</p> <p>___ 22. Nasolabial groove</p> <p>___ 23. Labiomental groove</p> <p>___ 24. Sublingual gland</p> <p>___ 25. Submandibular gland</p> <p>___ 26. Plica sublingualis</p> <p>___ 27. Uvula</p> <p>___ 28. Plica fimbriata</p> <p>___ 29. Foliate papilla</p> <p>___ 30. Circumvallate papillae</p> <p>___ 31. Alveololingual sulcus</p> <p>___ 32. Palatine tonsils</p> <p>___ 33. Retromylohyoid curtain</p> <p>___ 34. Fungiform papillae</p> <p>___ 35. Alveolar mucosa</p> <p>___ 36. Fovea palatini</p> <p>___ 37. Parotid gland</p> <p>___ 38. Philtrum</p> <p>___ 39. Commissure</p> <p>___ 40. Exostosis</p> | <p>a. Mouth</p> <p>b. Dark pigment on attached gingiva</p> <p>c. On the anterior floor of mouth where the plica sublingualis meet</p> <p>d. Underside of tongue</p> <p>e. Hair-like papillae covering two thirds of dorsum of tongue</p> <p>f. Top side of tongue</p> <p>g. Sebaceous glands on inside of cheek</p> <p>h. Interdental papillae</p> <p>i. Opens on inside of cheek near maxillary molars</p> <p>j. Palatine raphe</p> <p>k. Attaches lip to mucosa covering jaw (upper and lower)</p> <p>l. Behind soft palate</p> <p>m. Incisive papilla</p> <p>n. Lines floor of vestibule</p> <p>o. Firm, covered by gingiva, has rugae</p> <p>p. Ridge of bone lingual to mandibular premolars</p> <p>q. Elevation of tissue distal to mandibular last molar</p> <p>r. Elevation of tissue distal to maxillary last molar</p> <p>s. Junction of hard and soft palate</p> <p>t. Tightly attached—pink color</p> <p>u. Mucous salivary glands beneath anterior third of tongue</p> <p>v. Large serous salivary gland beneath posterior third of tongue</p> <p>w. At the corners of mouth where lips join</p> <p>x. Diagonal grooves from nostrils to corner of mouth</p> <p>y. Horizontal depression below lower lip</p> <p>z. Vertical depression on upper lip</p> <p>aa. Opening from oral cavity to pharynx</p> <p>bb. Serous salivary gland just in front of ear</p> <p>cc. Loosely attached</p> <p>dd. Fold in floor of mouth beneath tongue</p> <p>ee. Delicate fold on each side of ventral surface of tongue</p> <p>ff. Hangs downward in center of soft palate</p> <p>gg. On lateral surfaces of tongue near posterior third</p> <p>hh. Space between mandibular teeth and tongue</p> <p>ii. 8 to 12 circular papillae arranged in a "V" shape</p> <p>jj. Mucous membrane between anterior pillar and pterygomandibular fold</p> <p>kk. Located between anterior and posterior pillars in throat</p> <p>ll. Bulbous protuberance on facial side of mandible in premolar region</p> <p>mm. Sparse round mushroom-shaped papillae on dorsum of tongue</p> <p>nn. Located just posterior to vibrating line</p> |
|--|---|

**ANSWERS:** 1—f, 2—o, 3—l, 4—j, 5—i, 6—n or cc, 7—g, 8—b, 9—h, 10—m, 11—s, 12—c, 13—k, 14—d, 15—q, 16—g, 17—r, 18—e, 19—p, 20—t, 21—aa, 22—x, 23—y, 24—u, 25—v, 26—dd, 27—ff, 28—ee, 29—gg, 30—ii, 31—hh, 32—kk, 33—jj, 34—mm, 35—n or cc, 36—n, 37—bb, 38—z, 39—w, 40—ll

## Critical Thinking

- Mrs. Huay requires the extraction of tooth No. 31 due to a severe tooth fracture. A. State each nerve branch that needs to be blocked with anesthetic in order for her not to feel any pain in the tooth or surrounding oral tissues during the extraction. B. Describe in as much detail as possible exactly where the anesthetic should be placed. C. Then trace each nerve branch that supplies this tooth and surrounding structures back to the brain where it exited the brain case.
- Discuss the **tongue**. A. First, list as many structures on it as possible (describing the locations of each). B. List the nerves that innervate the tongue for movement, feeling (pain), and taste; the artery that supplies blood; and the lymph nodes where infections of the tongue would drain. (This requires knowledge obtained when reading Chapter 14 as well as 15.)

### REFERENCES

- Jenkins GN. The physiology of the mouth. 3rd ed. Revised reprint. Oxford: Blackwell Scientific, 1970:310–328.
- Osborn JW, Armstrong WG, Speirs RL, eds. Anatomy, biochemistry and physiology. Oxford: Blackwell Scientific, 1982:535.
- Renner RP. An introduction to dental anatomy and esthetics. Chicago, IL: Quintessence Publishing, 1985.
- Brand RW, Isselhard DE. Anatomy of orofacial structures. 5th ed. St. Louis, MO: C.V. Mosby, 1994.
- Lang N, Loe H. The relationship between the width of keratinized gingiva and gingival health. *J Periodontol* 1972;43:623.
- Gargiulo A, Wentz F, Orban B. Dimensions and relationships of the dentogingival junction in humans. *J Periodontol* 1961;32:261.
- Polson A, Caton J, Yeaple R, et al. Histological determination of probe tip penetration into gingival sulcus of humans using an electronic pressure-sensitive probe. *J Clin Periodontol* 1980;7:479.
- Foley PF, Latta GH. A study of the position of the parotid papillae relative to the occlusal plane. *J Prosthet Dent* 1985;53:124–126.
- Simmons JD, Moore RN, Errickson LC. A longitudinal study of anteroposterior growth changes in the palatine rugae. *J Dent Res* 1987;66:1512–1515.

### GENERAL REFERENCES

- Beck EW. Mosby's atlas of functional human anatomy. St. Louis, MO: C.V. Mosby, 1982.
- Clemente CD. Anatomy: a regional atlas of the human body. 4th ed. Baltimore, MD: Williams & Wilkins, 1997.
- Clemente CD, ed. Gray's anatomy of the human body. 30th ed. Philadelphia, PA: Lea & Febiger, 1985.
- DuBrul EL. Sicher and DuBrul's oral anatomy. St. Louis, MO: C.V. Mosby, 1988.
- Dunn MJ, Shapiro CZ. Dental anatomy/head and neck anatomy. Baltimore, MD: Williams & Wilkins, 1975.
- Montgomery RL. Head and neck anatomy with clinical correlations. New York, NY: McGraw-Hill, 1981:236–240.
- Web site: <http://education.yahoo.com/reference/gray/>



## Dr. Woelfel's Original Research Data

Specific research data and some of Dr. Woelfel's original research findings related to material topics in this chapter were referenced throughout by using superscript letters (like this<sup>A</sup>) and are presented here.

- In 1971 and 1972, Dr. Woelfel and Dr. Igarashi supervised 331 dental students as they recorded the **position of the right and left parotid papilla** on each other. Of 662 parotid papillae, 78% were located between the maxillary first and second molar or by the second molar. Only 22% were by the first molar. In height, 87% of these same papillae

were located level with (34%) or above the level (53%) of the occlusal plane. Only 13% were found below the level of the occlusal plane. The widest variation in location among these dental students was in two men, one having his parotid papilla on each side 11 mm above the occlusal plane and the other man with his 8 mm below the level of the occlusal plane. In a similar study of 293 adult men and 114 adult women (258 white, 11 black, 9 Hispanic), the parotid papilla averaged 3.3 mm above the occlusal plane (right 3.0, left 3.5 mm).<sup>8</sup>

- B. There is a relatively constant 8.5-mm distance from the facial surface of the maxillary central incisors to the center of the **incisive papilla**. On 326 casts measured by Dr. Woelfel, the average distance was 8.4 mm, with a range of 5.5 to 12 mm.
- C. Among casts from 939 hygiene students, **rugae “trees”** had three, four, or five branches on each side in 87% of the students. The first main branch was aligned lingual to the canine in 72%. The rugae were well elevated in 85% of the students and flattened in only 14%. Rugae are more distinct in young persons than in older persons. However, a longitudinal study of 20 females and 21 males, from age 4 to 22 years, indicated a slight but steady growth in the length of rugae during this period (average: 1.4 to 2.3 mm). Rugae growth occurred earlier in females, but the males had more branches.<sup>9</sup>
- D. Measurements on 333 casts by Dr. Woelfel indicated the **frenum attachment** to be  $8.03 \pm 1.5$  mm below the gingival sulcus of the mandibular central incisors; range 5.4 to 11 mm. Assuming an average-length mandibular central incisor (8.8 mm), the lingual frenum attaches about 17 mm below the incisal edge of these teeth.
- E. (not Woelfel research) **Daily saliva secretion:** A person normally secretes an average of 300 mL of saliva between meals, 300 mL while eating, and only 20 mL while sleeping, based on averages from 600 people.<sup>1</sup>
- F. In a survey by Dr. Woelfel, 267 dental hygiene students measured their **gingival sulcus depths** with a calibrated periodontal probe. The average gingival sulcus depths for mandibular first molars midbuccal were  $1.5 \pm 0.5$  mm; midlingual:  $1.7 \pm 0.6$  mm; mesiolingual and distolingual:  $2.5 \pm 0.5$  mm. These measurements indicate that the gingival sulcus is usually deeper interproximally. Similar measurements made on the mesiofacial aspect of mandibular canines ( $1.9 \pm 0.8$  mm), maxillary canines (1.8 mm), maxillary first premolars ( $1.9 \pm 0.7$  mm), and maxillary first molars ( $2.1 \pm 0.7$  mm) indicate sulci slightly deeper on posterior teeth than those on anterior teeth.

## Appendix

This Appendix includes numerous drawings of permanent and primary teeth, which are labeled (with letters) to highlight features of each tooth. Traits represented by each letter are described on the back of each page following the same letter used on the drawings.

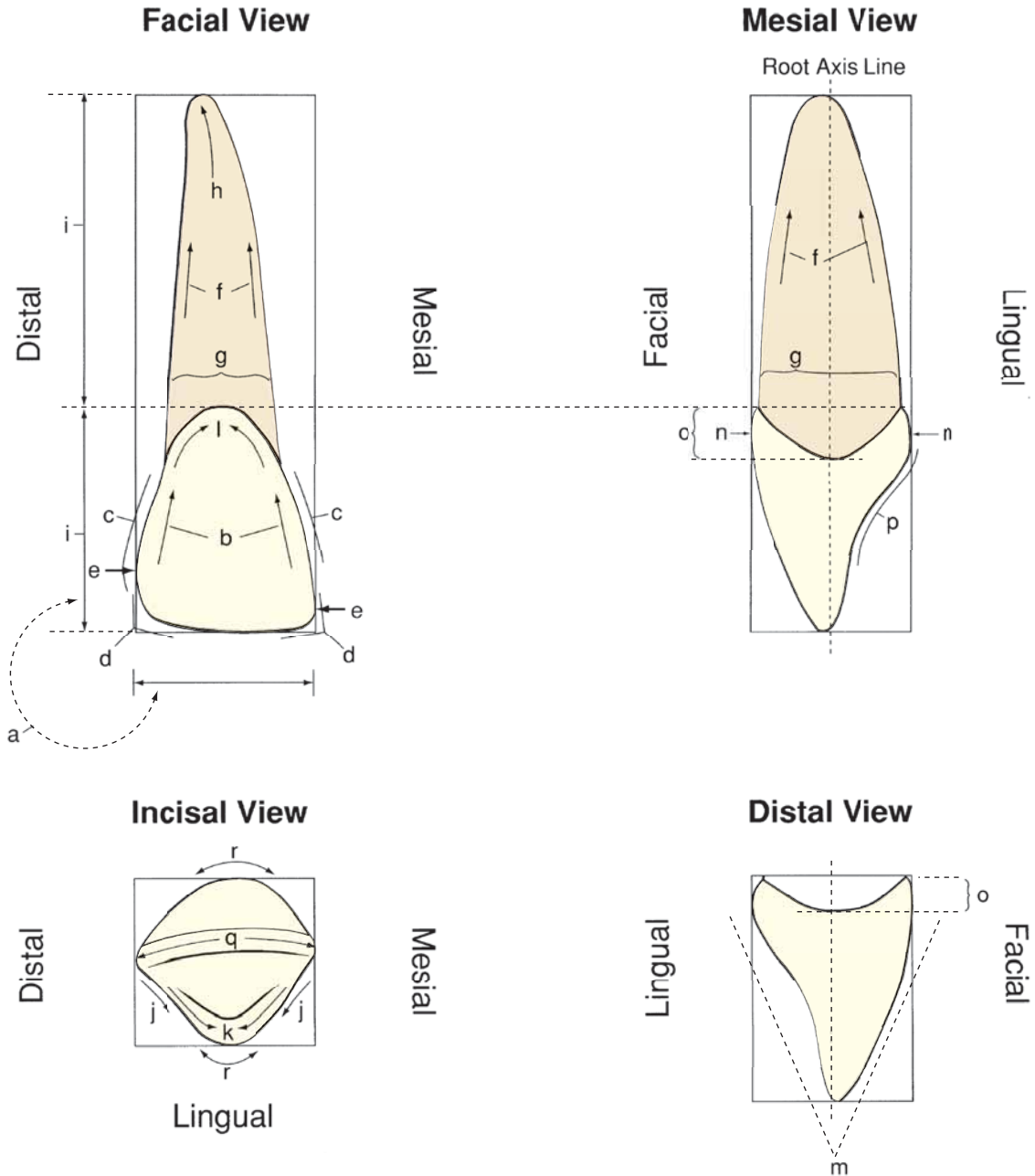
The pages in this Appendix section are perforated, so they can be torn out to facilitate study for Chapters 2 through 6, thus minimizing page turns. For example, while reading about the morphology of incisors in Section I of Chapter 2, when you see the word “Appendix” followed by a number and letter (e.g., Appendix 1a), refer to the appendix page (page 1) and item (letter a). Find that letter on the line drawings, and it will illustrate the concept being described in the text.





**General Class Traits of Most Incisors**  
 (using the maxillary right lateral incisor #7 as an example)

**Class Traits**



Refer to letters a-r on back, which describe these features.

## GENERAL CLASS TRAITS OF MOST PERMANENT INCISORS

- a. Crown shapes are rectangular, longer incisogingivally than mesiodistally (facial views).
- b. Crowns taper from the contact areas to cervical lines (facial views).
- c. Crown outlines on the distal are more convex than on the mesial (facial views) EXCEPT on mandibular central incisors, which are known for their symmetry.
- d. The mesioincisal angles are more square (or acute) than the distoincisal angles, which are more obtuse (facial views) EXCEPT on mandibular central incisors.
- e. Mesial contact areas are in the incisal third; distal contact areas are more cervical than the mesial (facial view) EXCEPT on mandibular central incisors, where mesial and distal contacts are at the same height (facial views).
- f. Roots taper from the cervical line toward the apex (facial and mesial views) and from the facial toward the lingual (best seen on an actual tooth or model).
- g. Roots are wider faciolingually than mesiodistally (comparing proximal to facial view) EXCEPT maxillary central incisors, where dimensions are almost equal.
- h. When bent, roots often bend to the distal in the apical third (facial views).
- i. Roots are slightly to considerably longer than crowns (facial and proximal views).
- j. Crowns taper from proximal contact areas toward the lingual (incisal views).
- k. The mesial and distal marginal ridges converge toward the lingual cingulum (incisal and lingual views).
- l. Cervical lines on the facial (and lingual) surfaces are convex (curve) toward the apex (facial and lingual views).
- m. Proximal outlines are wedge shaped or triangular (proximal views).
- n. Facial and lingual crests of curvature are in the cervical third (proximal views).
- o. Proximal cervical lines are convex (curve) toward the incisal AND curve more so on the mesial than on the distal surfaces (compare mesial to distal views).
- p. Lingual outlines are S-shaped with a concave lingual fossa and convex cingulum, and the lingual outlines of the marginal ridges are more vertical than horizontal (proximal views).
- q. Incisal edges terminate mesially and distally at the widest portion of the tooth crown (incisal views).
- r. Facial outlines are more broadly rounded than lingual outlines due to lingual convergence (incisal views).

# Incisors

## Maxillary

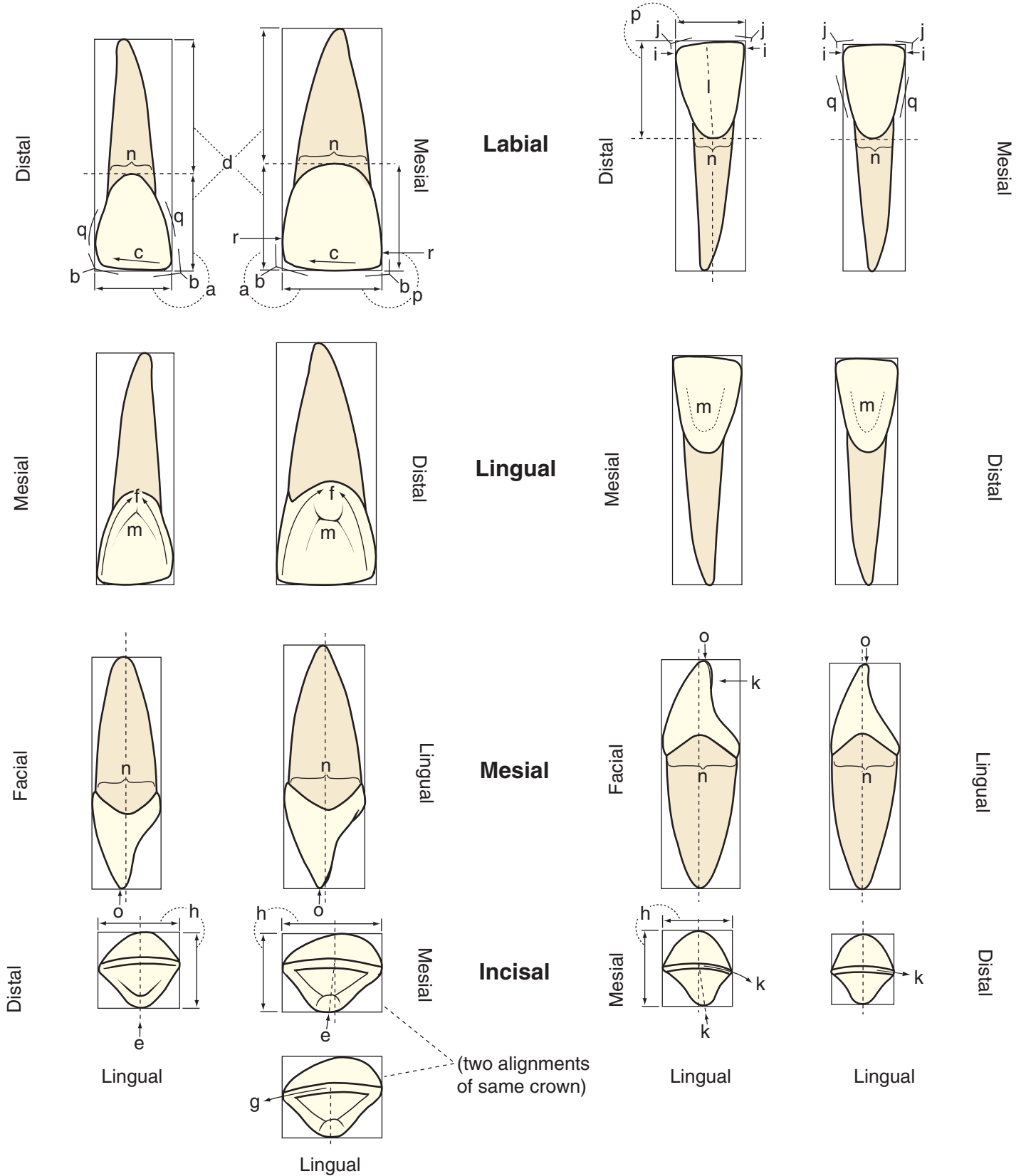
## Mandibular

Lateral (#7)

Central (#8)

Lateral (#26)

Central (#25)



Refer to letters a-r on back, which describe these features.



### **TYPE TRAITS THAT DISTINGUISH THE MAXILLARY CENTRAL INCISOR FROM THE MAXILLARY LATERAL INCISOR**

- a. Although the crowns of both types of maxillary incisors are longer cervicoincisally than mesiodistally, maxillary central incisors are closer to square. Lateral incisors are more oblong cervicoincisally (facial views).
- b. On both maxillary incisors, the mesioincisal angles are close to 90 degrees; the distoincisal angles are more rounded (facial views), but both angles are more rounded on the lateral compared to the central incisor (facial views).
- c. Incisal edges slope cervically toward the distal (facial views), more so on lateral incisors (facial views).
- d. Maxillary central incisors have crowns and roots closer to the same length. Lateral incisors have proportionately longer roots relative to crowns (facial views).
- e. When the incisal edges are aligned horizontally, cingula of maxillary central incisors are off-center to the distal versus cingula of lateral incisors, which are centered (incisal views).
- f. Mesial marginal ridges are longer than the distal marginal ridges (in central incisors due to the distally displaced cingulum and in lateral incisors due to the cervical slope of the incisal edge to the distal) (lingual views).
- g. From the incisal view, when the crest of curvature of the cingulum is positioned directly downward, the incisal edge of maxillary central incisors has a slight distolingual twist with the distoincisal corner more lingual than the mesioincisal corner. The incisal ridges of maxillary lateral incisors run mesiodistally with no twist (incisal and mesial views).
- h. Mesiodistal dimensions on central incisors are considerably wider than faciolingual dimensions (rectangular shaped). On lateral incisors, these dimensions are more nearly equal (closer to square) (incisal views).

### **TYPE TRAITS THAT DISTINGUISH THE MANDIBULAR CENTRAL INCISOR FROM THE MANDIBULAR LATERAL INCISOR**

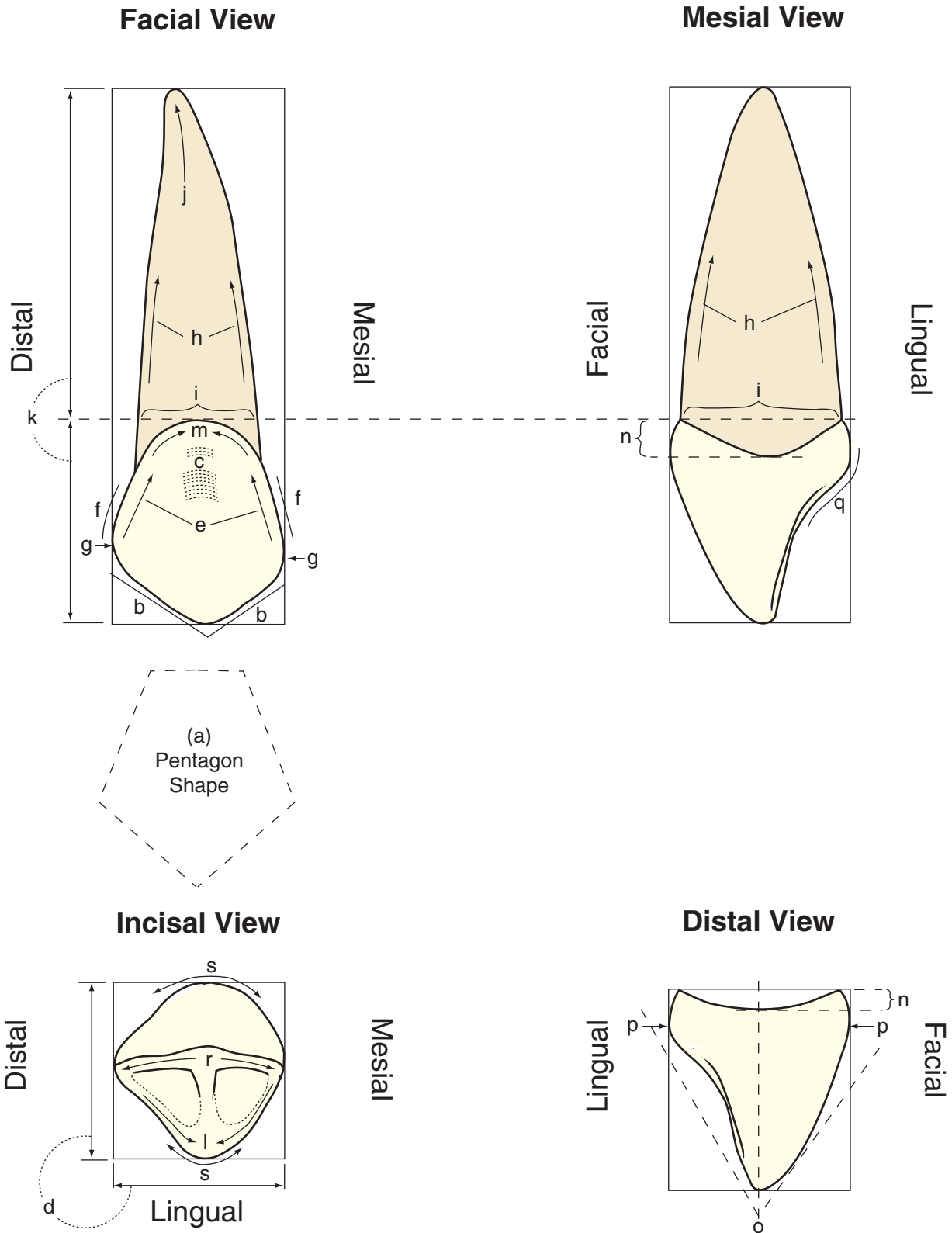
Mandibular central incisors are very symmetrical versus lateral incisors, which are not. The following are examples of the relative lack of symmetry in lateral incisors:

- i. Mandibular lateral incisors have the distal proximal contacts more apical than the mesial contacts. Central incisor contacts are at the same level (facial views).
- j. Lateral incisors have the distoincisal angles more rounded than the mesioincisal angles. On central incisors the mesioincisal and distoincisal angles are quite similar (facial views).
- k. Incisal edges of lateral incisors have a slight distolingual twist (relative to a line bisecting the cingulum). Central incisors have their incisal edges at right angles (with no twist) to this bisecting line (incisal and mesial views).
- l. The crowns of the mandibular lateral incisor tip slightly to the distal relative to the root (facial views).

### **ARCH TRAITS THAT DISTINGUISH MAXILLARY FROM MANDIBULAR INCISORS**

- m. Lingual fossae are more pronounced on maxillary incisors (often with a lingual pit, especially on the maxillary lateral incisor). Mandibular incisors have smoother lingual anatomy without grooves and pits (lingual views).
- n. Maxillary incisors have roots that are closer to round in cross-section. Mandibular incisors have roots that are more ribbon-like (that is, are thin mesiodistally and much wider faciolingually). Compare proximal views to facial views.
- o. Incisal edges of maxillary incisors are often labial to the root axis line. Mandibular incisal edges are often lingual to the root axis line (proximal views).
- p. Mandibular crowns are smaller and narrower mesiodistally relative to the length compared to maxillary incisors, which are relatively wider (facial views).
- q. Mandibular crowns have outlines mesially and distally that are flatter than on maxillary incisors (facial views).
- r. (r compared to i). Proximal contact points (crests of curvature or heights of contact) are closer to the incisal edge on mandibular incisors (i) than on maxillary incisors (r) (although incisor proximal contacts are in or close to the incisal third of the crowns [EXCEPT distal of maxillary laterals which are in the middle third], and distal contacts are more cervically positioned than mesial contacts [EXCEPT mandibular centrals]) (facial views).

**General Class Traits of Most Canines**  
 (using the maxillary right canine #6 as an example)



Refer to letters a-s on back, which describe these features.

## GENERAL CLASS TRAITS OF MOST CANINES

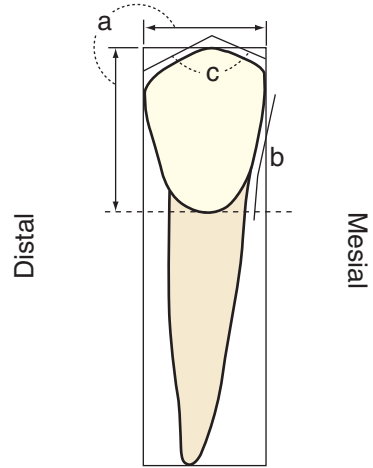
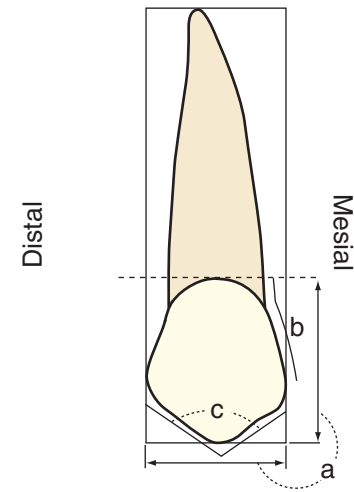
- a. Crowns are pentagon shaped (facial views).
- b. Cusps have mesial cusp ridges shorter than distal cusp ridges (facial views).
- c. Vertical labial ridges are prominent (more so on maxillary canines) (facial views).
- d. Crowns are wider faciolingually than mesiodistally (similar to mandibular incisors) (incisal views).

## GENERAL CANINE CHARACTERISTICS SIMILAR TO INCISORS

- e. Crowns taper from contact areas toward the cervical line (facial views).
- f. Crown outlines are more convex on the distal and less convex (flatter) on the mesial (facial views).
- g. Mesial contact areas are located in the incisal third of the crown (or at the junction of the incisal and middle thirds); distal contact areas are more cervically positioned (facial views).
- h. Roots taper from the cervical line toward the apex (facial and proximal views) and from facial toward lingual (which is best viewed on an actual tooth or model).
- i. Roots are wider faciolingually than mesiodistally (compare proximal to facial views).
- j. If roots are bent, they more often bend toward the distal in the apical third on maxillary canines (facial views), but mandibular canine roots are more likely to be straight.
- k. Roots are considerably longer than crowns (facial views).
- l. Crowns taper from the proximal contacts toward the lingual (incisal views), so the mesial and distal marginal ridges converge toward the cingulum (incisal views).
- m. Cervical lines on the facial (and lingual) surfaces curve toward the apex (facial and lingual views).
- n. Proximal cervical lines curve toward the incisal, more so on the mesial than on the distal surface (compare proximal views).
- o. Canines (like incisors) are wedge shaped (triangular) when viewed from the proximal.
- p. Facial and lingual crests of curvature are in the cervical third (proximal views).
- q. Lingual outlines are S-shaped with a concave lingual fossa and convex cingulum; the marginal ridges are oriented more vertically than horizontally (proximal views).
- r. Incisal edges run from the mesial to the distal contact areas (incisal views).
- s. Facial outlines are more broadly rounded than lingual outlines due to lingual convergence (incisal views).

## Maxillary (#6)

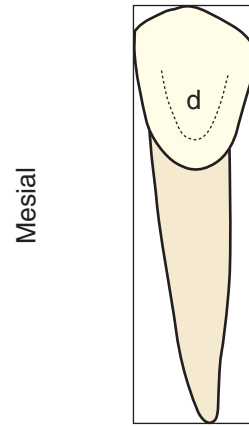
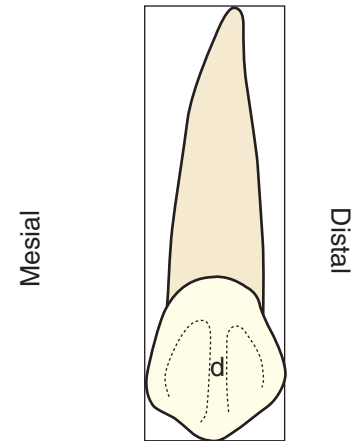
## Mandibular (#27)



**Labial**

Distal

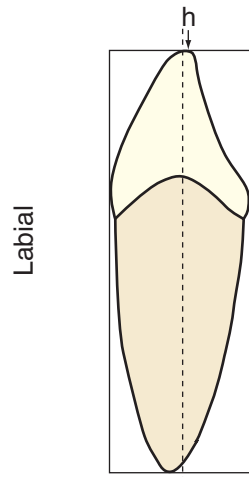
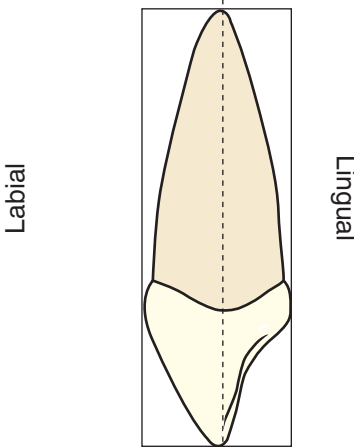
Mesial



**Lingual**

Mesial

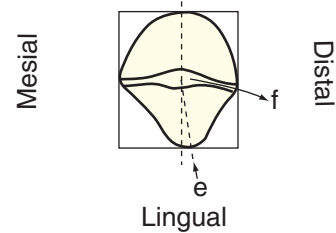
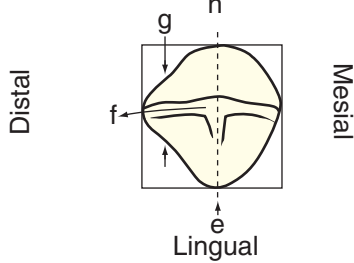
Distal



**Mesial**

Labial

Lingual



**Incisal**

Mesial

Distal

Lingual

Lingual

Refer to letters a–h on back, which describe these features.



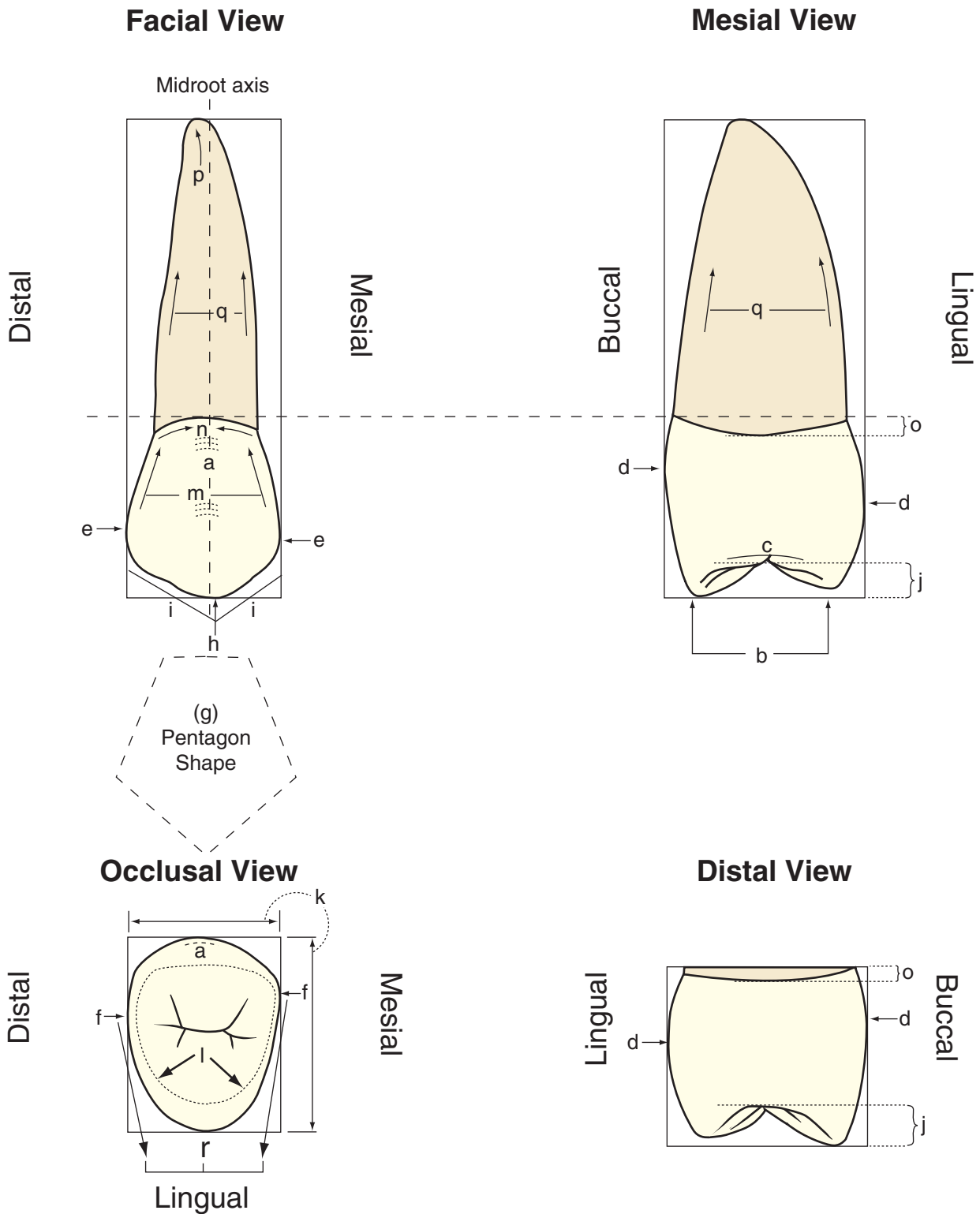
### **TYPE (AND ARCH) TRAITS THAT DISTINGUISH THE MAXILLARY CANINE FROM THE MANDIBULAR CANINE**

---

- a. Both maxillary and mandibular canine crowns are oblong (rectangular) with the mesiodistal dimension less than the incisocervical dimension, but the mesiodistal dimension is narrower on mandibular canines than on maxillary canines (facial views).
- b. Maxillary canines have mesial crown contours convex (to nearly flat cervically) versus mandibular canines, which have mesial crown contours more in line with the contour of the root (facial views).
- c. The angle formed by the cusp ridges (slopes) of maxillary canines is more pointed or acute (averaging about 105 degrees), resulting in a sharper cusp, compared to the broader (less pointed or obtuse) angle on the mandibular canine, which averages 120 degrees (facial views). The mesial cusp ridge of the mandibular canine is often close to horizontal when the tooth is held with the long axis vertically.
- d. Lingual ridges that separate mesial and distal fossae are more prominent on maxillary canines than on mandibular canines (lingual views).
- e. Cingula on maxillary canines are large and centered mesiodistally. On mandibular canines, they are often slightly to the distal (incisal views).
- f. Incisal ridges on maxillary canines are straighter mesiodistally. On mandibular canines, the distal cusp ridge bends distolingually (incisal views).
- g. The distal half of the crown of maxillary canines is compressed (squeezed) faciolingually more than on mandibular canines (incisal views).
- h. The cusp tip of the maxillary canine is on or labial to the root axis line, whereas the mandibular cusp tip is lingual to this line (proximal [and incisal] views).

# General Class Traits of Most Premolars

(using the maxillary right second premolar #4 as an example)



Refer to letters a-r on back, which describe these features.

## GENERAL CLASS TRAITS OF MOST PREMOLARS

---

- a. Buccal ridges are present (similar to canine labial ridges) (facial and occlusal views).
- b. Usually, premolars have two cusps: one buccal and one lingual (EXCEPTION is the mandibular second premolar, which often has three cusps: one buccal and two lingual) (proximal views).
- c. Marginal ridges are aligned relatively horizontally (EXCEPT on mandibular first premolars, where the mesial marginal ridge is closer to a 45-degree angle from horizontal) (proximal views).
- d. Buccal and lingual crests of curvature are more occlusal than on anterior teeth (still in cervical third on the facial but in the middle third on the lingual) (proximal views).
- e. Mesial proximal contacts (heights of contour) are near the junction of the occlusal and middle thirds, and the distal contacts are often slightly more cervical in the middle third (EXCEPT on mandibular first premolars, where mesial contacts are more cervical than the distal contacts) (facial views).
- f. Proximal contacts (crests of curvature) from the occlusal view are buccal to the center faciolingually (occlusal views).
- g. From the facial, premolars are roughly pentagon shaped (similar to canines) (facial view).
- h. The buccal cusp tip is mesial to the midroot axis (EXCEPT on the maxillary first premolar, where the cusp tip is distal to the midroot axis) (facial views).
- i. The mesial cusp ridge of the buccal cusp is shorter than the distal cusp ridge (EXCEPT on the maxillary first premolar, where the mesial cusp ridge is longer) (facial views).
- j. Mesial marginal ridges are generally more occlusal than distal marginal ridges, which are more cervical (EXCEPT on mandibular first premolars, where mesial marginal ridges are in a more cervical position) (compare the proximal views).
- k. Crowns are oblong from the occlusal view, wider faciolingually than mesiodistally relative to anterior teeth (maxillary premolars are decidedly oblong or rectangular, whereas mandibular premolars are closer to square [or round] in shape) (occlusal views).
- l. Cusp ridges (or slopes) and marginal ridges join to form the boundary of the occlusal surface or occlusal table (occlusal views).
- m. Crowns taper from proximal contact areas toward the cervical (facial views).
- n. Cervical lines curve apically on the facial and lingual surfaces (facial and lingual views).
- o. Cervical lines curve occlusally on the proximal surfaces, with the mesial cervical line more convex than the distal (compare mesial to distal proximal views).
- p. The apical third of roots bend distally more often than mesially (facial views).
- q. Roots taper toward the apex (both proximal and facial views).
- r. The crowns taper narrower from the contact areas toward the lingual (occlusal views) EXCEPT three-cusp type mandibular second premolars.

# Premolars

## Maxillary

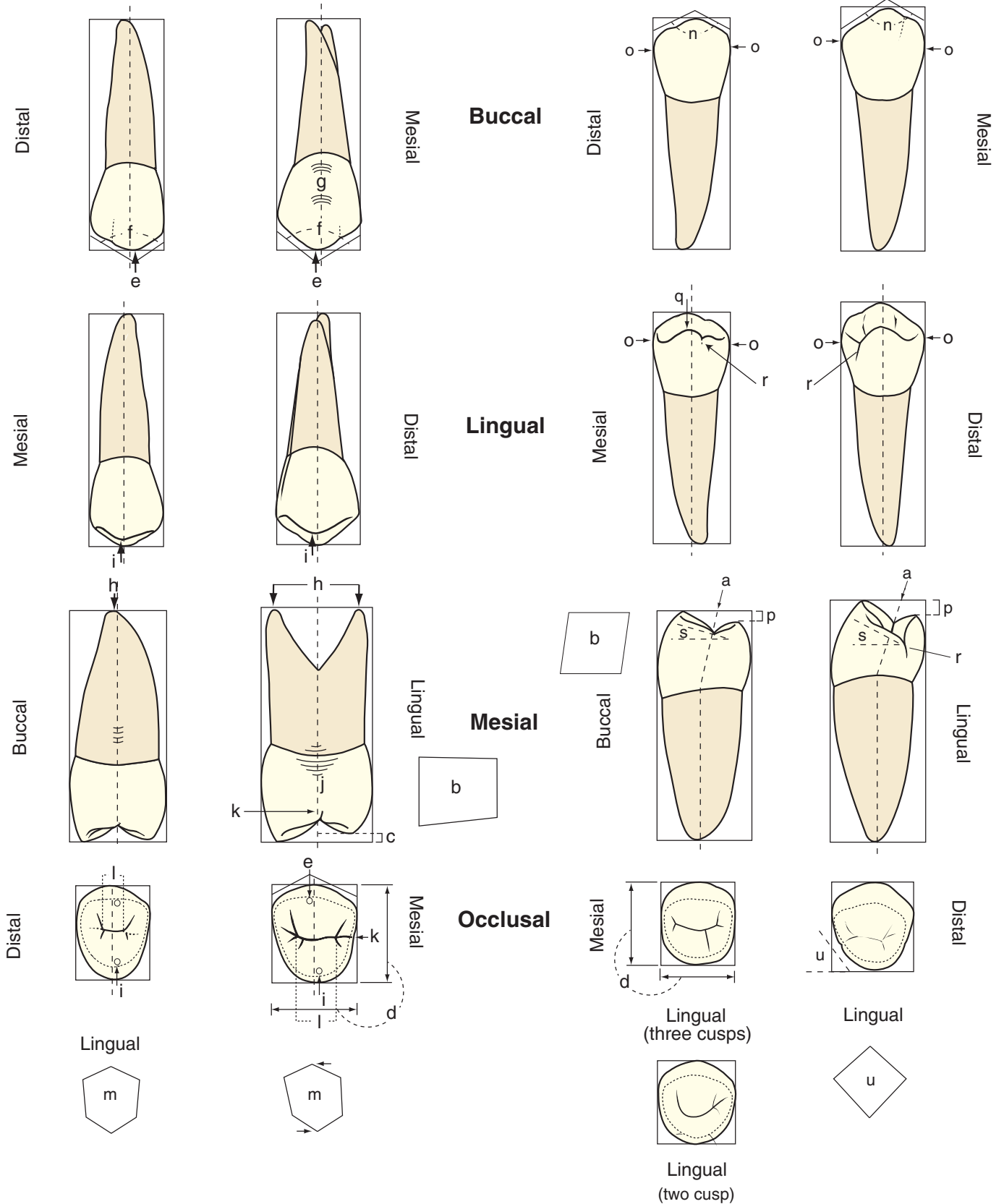
## Mandibular

Second (#4)

First (#5)

Second (#29)

First (#28)



Refer to letters a-u on back, which describe these features (t is not shown).



## ARCH TRAITS OF PREMOLARS THAT DISTINGUISH MAXILLARY FROM MANDIBULAR PREMOLARS

---

- a. Mandibular premolar crowns tilt to the lingual, so mandibular lingual cusp tips may be lingual to the root (proximal views). Maxillary crowns do not tip noticeably.
- b. The outline of the mandibular premolars are rhomboid in shape (four-sided with all opposite sides parallel), and the maxillary premolars are trapezoidal (four-sided with only two opposite walls parallel) (proximal views).
- c. (compared to p). Although lingual cusps are shorter than buccal cusps for all premolars, the mandibular lingual cusps are relatively much shorter than buccal cusps (p) compared to maxillary lingual cusps, which are closer to the same length (c) (maxillary second premolar cusps are almost equal in length) (proximal views).
- d. Mandibular premolars are more square or round from the occlusal view; maxillary premolars are more rectangular or oblong (relatively wider buccolingually) (occlusal views).

## TYPE TRAITS DISTINGUISHING MAXILLARY FIRST FROM MAXILLARY SECOND PREMOLARS

---

- e. Buccal cusp tips of *maxillary first premolars* are positioned more to the distal, and mesial cusp ridges are longer than distal cusp ridges. These are the ONLY type of premolars with this trait (facial and occlusal views).
- f. Buccal cusps of maxillary first premolars are more pointed (average: 105 degrees) than on second premolars, where they are more obtuse (120 degrees) (facial views).
- g. Buccal ridges are more prominent on maxillary first premolars (occlusal and facial views).
- h. Maxillary first premolars are the ONLY type of premolar most likely to have a divided root versus all other types of premolars, which usually have one root (proximal views).
- i. Maxillary premolars have their lingual cusp tips positioned more toward the mesial (lingual and occlusal views).
- j. Both maxillary premolars have mesial and distal root depressions, but ONLY the maxillary first premolars exhibit a mesial crown concavity (mesial views).
- k. Mesial marginal ridge grooves are almost always present on maxillary first premolars and are less common on second premolars (occlusal and mesial views).

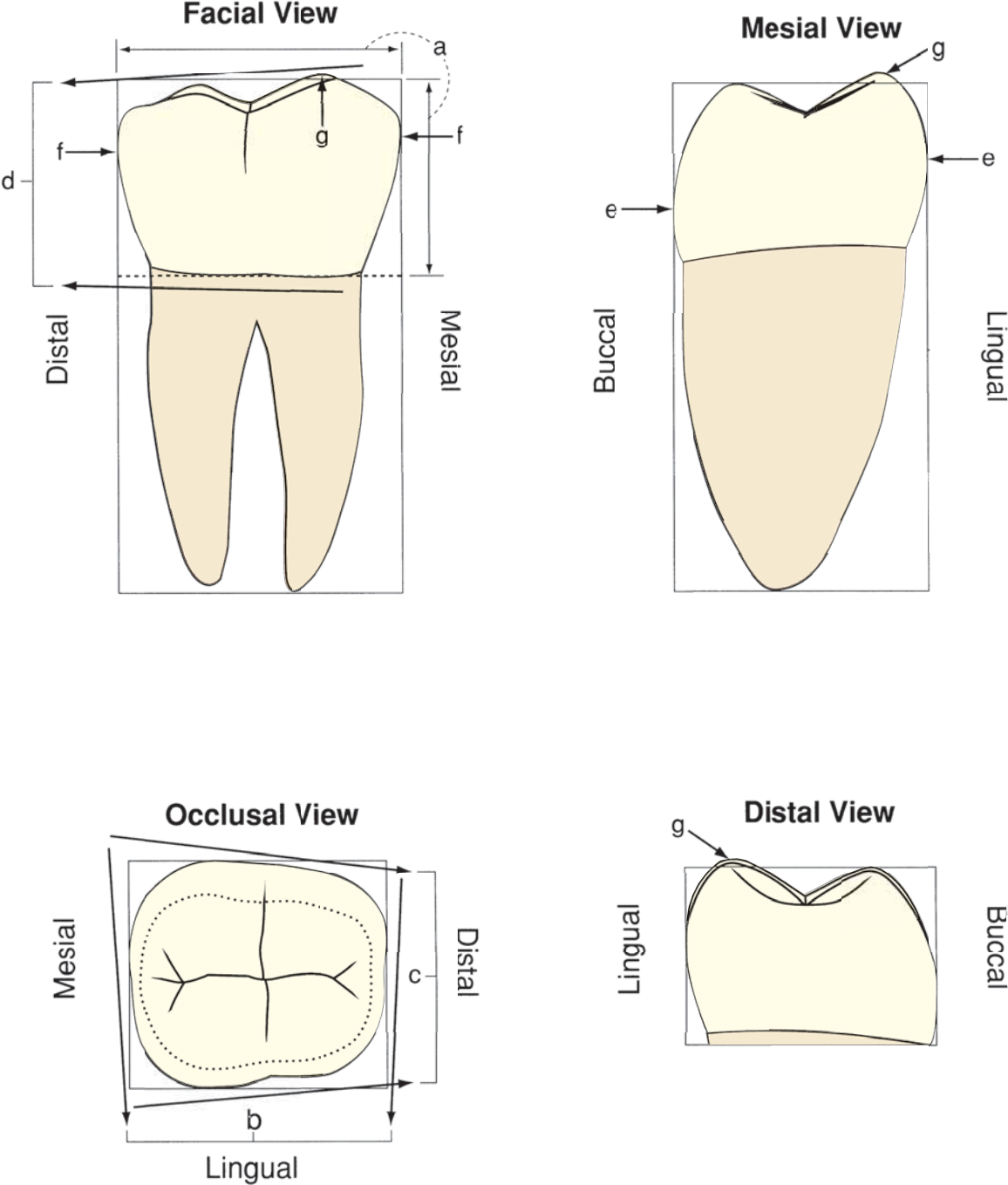
- l. The central developmental grooves on maxillary first premolars are longer (from mesial to distal pit) than those of second premolars, where they are only one third or less of the mesiodistal dimension (occlusal views).
- m. Occlusal outlines of maxillary first premolars are more asymmetrical with the lingual cusp tip positioned more to the mesial and the buccal cusp tip more to the distal, versus second premolars, which are more symmetrical overall (occlusal views).

## TYPE TRAITS DISTINGUISHING MANDIBULAR FIRST FROM MANDIBULAR SECOND PREMOLARS

---

- n. Mandibular first premolar buccal cusps are more pointed (110 degrees) versus on second premolar, where they are more obtuse or blunt (130 degrees) (facial views).
- o. Mesial proximal contacts (and marginal ridges) of mandibular second premolars are more occlusal than distal contacts (following the general rule), whereas the reverse is true on mandibular first premolars (EXCEPTION), where mesial contacts (and marginal ridges) are more cervical (facial views).
- p. Lingual cusps of mandibular first premolars are very small and nonfunctional. On second premolars, the lingual cusps function and are relatively longer (proximal views).
- q. Lingual cusp tips of mandibular second premolars are positioned to the mesial (or, if there are two lingual cusps, the mesiolingual is the more prominent) (lingual views).
- r. Mandibular first premolars have a *mesiolingual groove* separating the mesial marginal ridge from the lingual cusp. Second premolars (three-cusp type) have a *lingual groove* separating the two lingual cusps (lingual and mesial views).
- s. Mesial marginal ridges of first premolars slope cervically toward the lingual at about 45 degrees from horizontal. On second premolars they are more horizontal (mesial views).
- t. The mesial root surfaces of mandibular second premolars are the only premolar root surface (maxillary and mandibular, mesial and distal) not likely to have a midroot depression (best seen on models or actual teeth, not labeled in drawings).
- u. Mandibular first premolars are the only premolars that have the mesiolingual corner, with its mesiolingual groove and low marginal ridge, pinched or squeezed in, forming about a 45-degree angle with the lingual surface. This makes the occlusal outline somewhat diamond shaped (occlusal views).

**General Class Traits of Most Molars**  
(using the right second mandibular molar #31 as an example)



Refer to letters a-g on back, which describe these features.

## GENERAL CLASS TRAITS FOR MOST MOLARS

---

- a. Molar crowns are wider mesiodistally than cervico-occlusally (facial views).
- b. Crowns taper (get narrower) from the buccal to the lingual; that is, the mesiodistal width on the buccal half is wider than on the lingual half (EXCEPT some maxillary first molars with large distolingual cusps, where crowns taper to the buccal so that the mesiodistal dimension on the lingual is greater than on the buccal) (occlusal view).
- c. Crowns taper (get narrower) from the mesial to the distal; that is, the buccolingual width is less on the distal third than on the mesial third (occlusal view).
- d. Crowns taper (get shorter) from mesial to distal; that is, the crown height on the distal half is less than on the mesial half (facial view).
- e. As with premolars, the buccal crests of curvature (heights of contour) of crowns are in the cervical one third, and the lingual crests of curvature are in the middle third (proximal views).
- f. Proximal contacts (heights of contour) on the mesial are at or near the junction of the occlusal and middle thirds, and distal proximal contacts are more cervical, in the middle third near the middle of the tooth (facial views).
- g. Lingual cusps on mandibular molars (and mesiolingual cusps on maxillary molars) are longer than buccal cusps when molars are oriented on a vertical axis (facial, mesial, [and distal] views).

## Maxillary

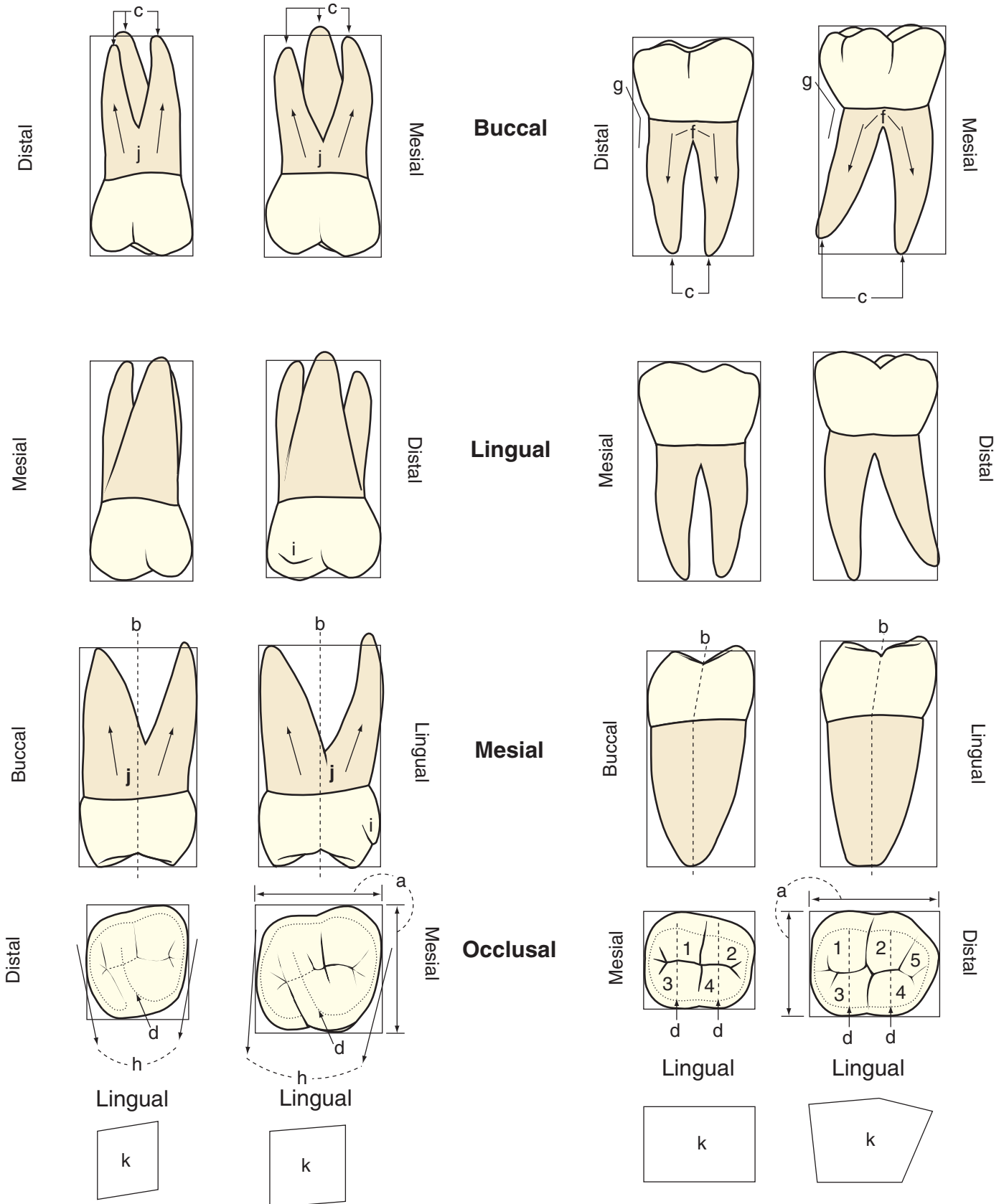
## Mandibular

Second (#2)

First (#3)

Second (#31)

First (#30)



Refer to letters a-k on back, which describe these features.



### **ARCH TRAITS THAT DISTINGUISH MAXILLARY FROM MANDIBULAR MOLARS**

---

- a. Mandibular crowns are wider mesiodistally than faciolingually, resulting in a more rectangular or pentagon outline (k). Maxillary molar crowns have the faciolingual dimension slightly greater than the mesiodistal dimension and are more square or rhomboid in outline (k) (occlusal views).
- b. Mandibular molar crowns tilt lingually at the cervix (like mandibular premolars), whereas maxillary crowns are aligned directly over the roots (proximal views).
- c. Mandibular molars usually have two roots (a longer mesial and a shorter distal root) versus maxillary molars, which have three roots (the longest lingual, the shorter mesiobuccal, and the shortest distobuccal root) (facial or lingual views).
- d. Maxillary molars have oblique ridges that run diagonally across the tooth from the mesiolingual to the distobuccal cusp, compared to mandibular molars, which primarily have two transverse ridges that run directly buccolingually (occlusal views).

### **TYPE TRAITS THAT DISTINGUISH MANDIBULAR FIRST FROM MANDIBULAR SECOND MOLARS**

---

- e. Mandibular second molars have four cusps (mesiobuccal = 1, distobuccal = 2, mesiolingual = 3, and distolingual = 4) with a “cross” pattern of occlusal grooves compared to first molars, which most often have five cusps (the same four cusps as on the second molar, plus a smaller distal cusp = 5) with a more zigzag central groove pattern (facial or

occlusal views; see corresponding numbered cusps, not labeled as “e”).

- f. First molar roots are more divergent and widely separated compared to second molar roots, which are more parallel and closer together (facial and lingual views).
- g. There is more taper (narrowing) from the distal proximal contact to the cervical line on first molars than on second molars due to the presence of the distal cusp on first molars (facial views).

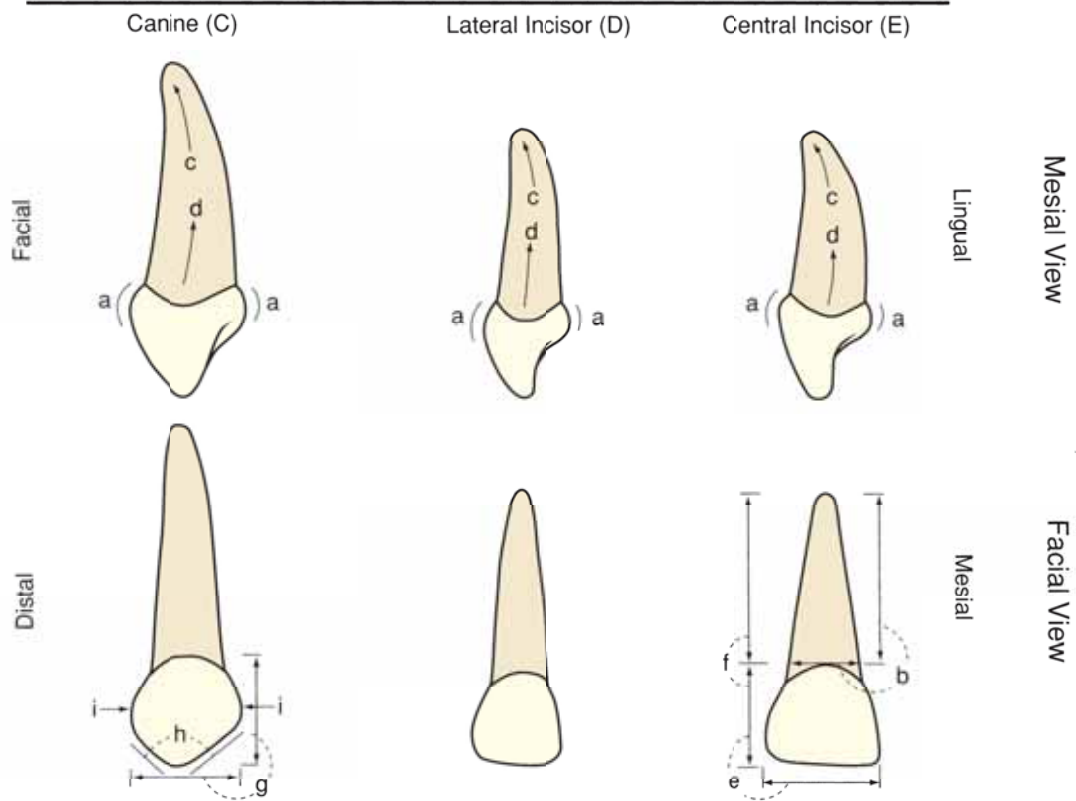
### **TYPE TRAITS THAT DISTINGUISH MAXILLARY FIRST FROM MAXILLARY SECOND MOLARS**

---

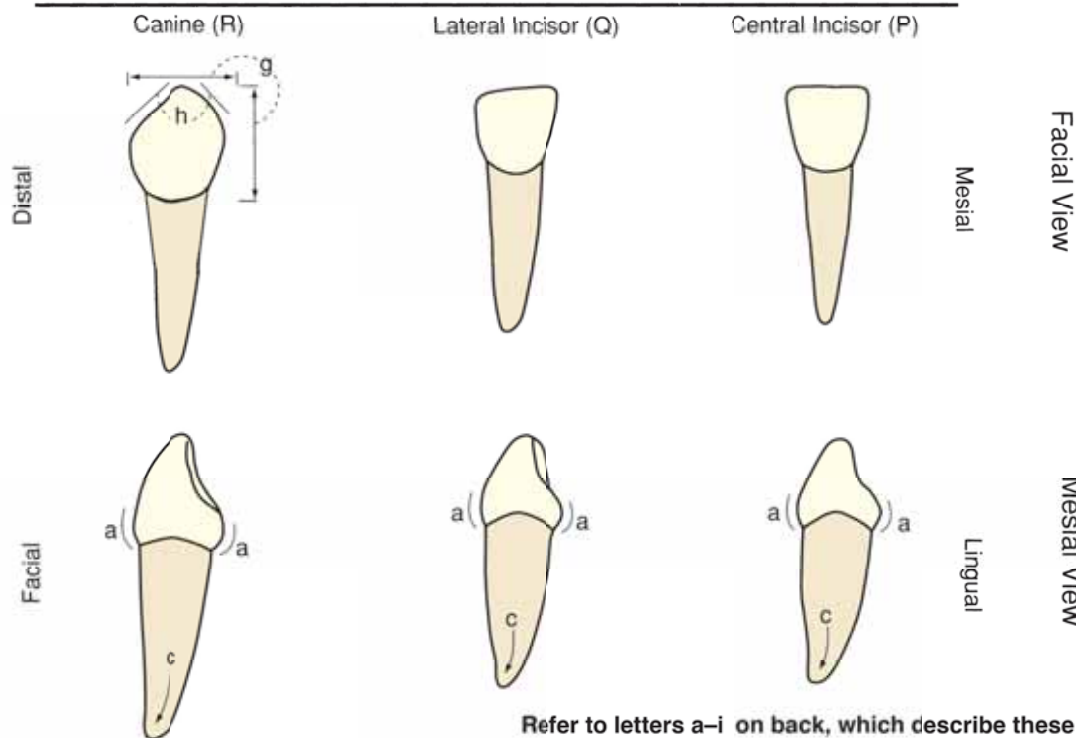
- h. There is more taper (narrowing) from the buccal to lingual on second molars due to their smaller distolingual cusp compared to less taper on maxillary first molars with their wider, prominent distolingual cusps (occlusal views).
- i. First molars are more likely to have a fifth cusp, the cusp of Carabelli (located on the mesiolingual cusp) compared to second molars, which do not normally have a cusp of Carabelli (lingual, mesial, and occlusal views).
- j. Roots of first molars are more spread apart than those of second molars (similar to mandibular molars) (facial and proximal views).
- k. The parallelogram outline shape of maxillary molars (with more acute or sharper mesiobuccal and distolingual angles and more obtuse or less sharp distobuccal and mesiolingual angles) is more twisted on second molars than on first molars (that is, acute angles are more acute and obtuse angles are more obtuse on maxillary second molars) (occlusal views).

## Primary Anterior Teeth

### Maxillary



### Mandibular



Refer to letters a-i on back, which describe these features.

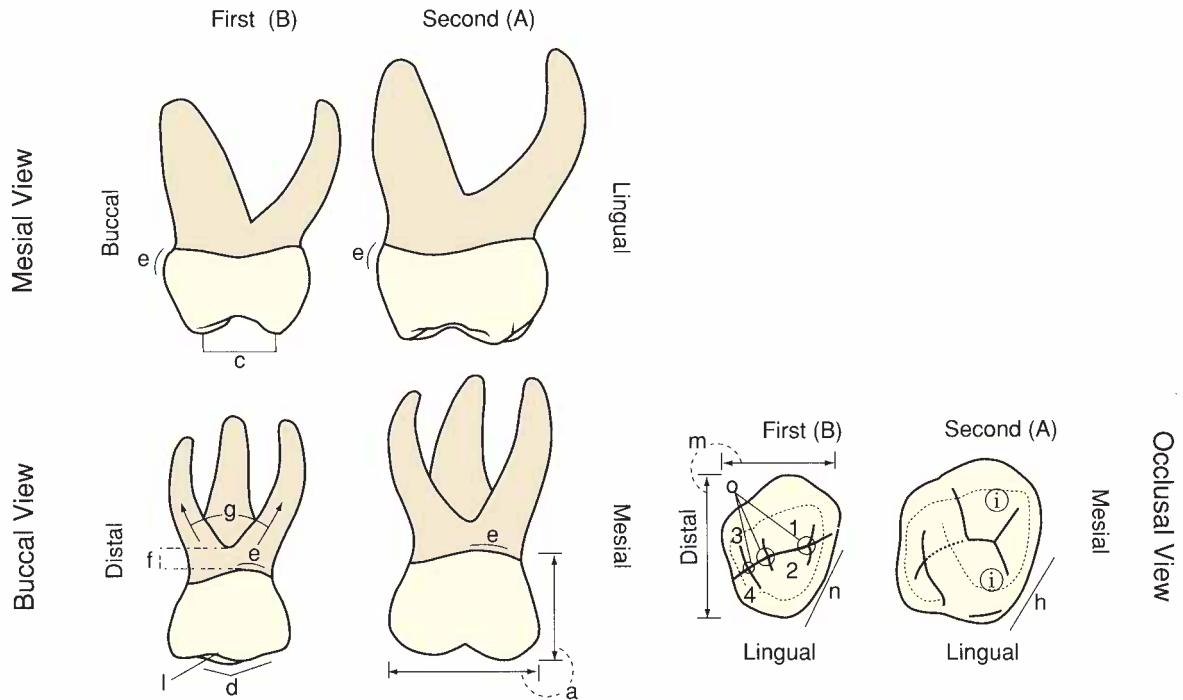
## UNIQUE PROPERTIES OF ANTERIOR PRIMARY TEETH

---

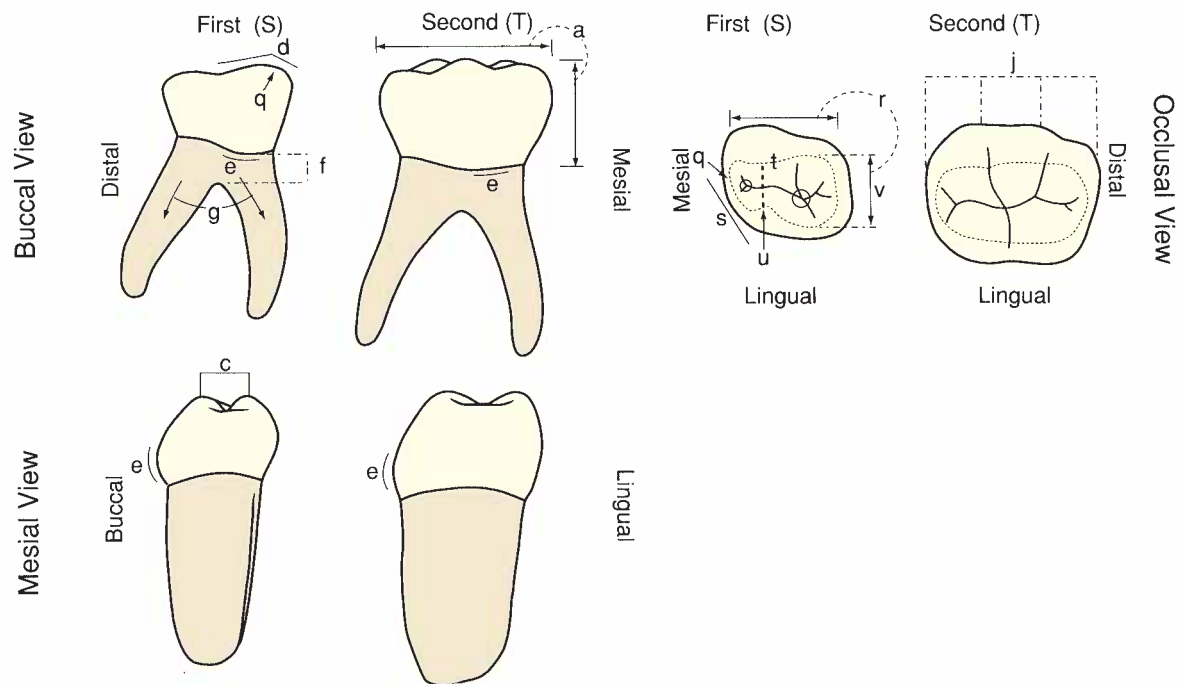
- a. Primary anterior tooth crowns have bulges in the cervical third of the labial and lingual surfaces. The lingual bulge is seen as a relatively large cingulum that occupies up to one third of the cervicoincisal crown length, and the labial bulge is seen as a prominent convex cervical ridge (proximal views).
- b. Roots are long in proportion to crown length and narrower (thinner) mesiodistally than on permanent anterior teeth (facial view).
- c. Roots of maxillary and mandibular primary anterior teeth bend as much as 10 degrees labially in their apical third, less so in mandibular canines (proximal views).
- d. Roots of maxillary incisors bend (bow) lingually in the cervical third to half, whereas the mandibular incisors are straighter in their cervical third (proximal views).
- e. Primary maxillary central incisors are the ONLY type of incisors, primary or permanent, where the crown is wider mesiodistally than incisocervically (facial views).
- f. Primary incisor crowns are shorter relative to the root length compared to permanent teeth (facial views).
- g. Primary maxillary canines are about as wide mesiodistally as they are long incisogingivally. Mandibular canines are longer incisocervically and narrower mesiodistally (facial views).
- h. Primary *mandibular* canines have their distal cusp ridges longer than their mesial cusp ridges (as do all permanent canines and premolars EXCEPT permanent maxillary first premolars) (facial views). Primary *maxillary* canines have their mesial cusp ridges longer than the distal cusp ridges (which is UNIQUE to only this tooth and maxillary first premolars).
- i. Primary maxillary canines have mesial proximal contacts more cervical than the distal (which is UNIQUE to this tooth and permanent mandibular first premolars) (facial views). All other primary and permanent teeth have the distal contact area more cervically located than on the mesial.

# Primary Molars

## Maxillary



## Mandibular



Refer to letters a-v on back, which describe these features.



### **GENERAL CHARACTERISTICS OF ALL PRIMARY MOLARS**

- a. Primary molars crowns are wider mesiodistally and shorter cervico-occlusally, as on permanent molars (buccal views).
- b. Primary first molars are decidedly smaller than primary second molars compared to permanent or secondary molars, where the first molars are larger (compare all views, not labeled as “b”).
- c. Primary molar crowns have a narrow chewing surface, or occlusal table, buccolingually compared to the entire tooth width buccolingually (proximal views).
- d. Buccal cusps are not sharp; cusp ridges meet at a wide (obtuse) angle (buccal views).
- e. Buccal cervical ridges are prominent, especially mesially (proximal views), so the facial cervical lines curve more apically in the mesial half of the buccal surface (buccal views).
- f. Root furcations are nearer to the crown with little or no root trunk compared to secondary molars (buccal views).
- g. Roots are thin, slender, and widely spread (buccal views).

### **ADDITIONAL CHARACTERISTICS UNIQUE TO PRIMARY MAXILLARY SECOND MOLARS (WHICH MOST CLOSELY RESEMBLE THE PERMANENT MAXILLARY FIRST MOLARS)**

- h. Mesiolingual corner of the occlusal surface is compressed toward the distal (occlusal views).
- i. Primary mesiobuccal cusp is about equal in size to the mesiolingual cusp compared to permanent or secondary teeth, where the mesiolingual cusp is larger than the mesiobuccal cusp (occlusal views).

### **ADDITIONAL CHARACTERISTICS UNIQUE TO PRIMARY MANDIBULAR SECOND MOLARS (WHICH MOST CLOSELY RESEMBLE THE PERMANENT MANDIBULAR FIRST MOLARS)**

- j. The three buccal cusps are of nearly equal size versus permanent first molars, where the distal cusp is usually considerably smaller (occlusal views).

### **ADDITIONAL CHARACTERISTICS UNIQUE TO PRIMARY MAXILLARY FIRST MOLARS (WHICH, FROM THE OCCLUSAL VIEW, SOMEWHAT RESEMBLE PERMANENT MAXILLARY PREMOLARS)**

- k. There are often four cusps: two larger cusps (like a maxillary premolar), the mesiobuccal cusp (1) widest and longest and the mesiolingual cusp (2) the smaller but sharpest; and two smaller cusps, the distobuccal (3) and the inconspicuous, sometimes absent, distolingual (4) (occlusal views; see corresponding numbered cusps).
- l. A notch (distal to center) divides the large mesiobuccal cusp from the indistinct distobuccal cusp (buccal views).
- m. The crown is wider faciolingually than mesiodistally like a maxillary premolar (occlusal views).
- n. The mesial marginal ridge is directed distolingually (occlusal views).
- o. There are three fossae: a large mesial triangular fossa, a medium central fossa, and a minute distal fossa (occlusal views).
- p. The grooves form an “H” pattern (somewhat similar to a maxillary premolar) (not labeled with a letter; seen on occlusal views).

### **ADDITIONAL UNIQUE CHARACTERISTICS OF PRIMARY MANDIBULAR FIRST MOLARS (RESEMBLING NO OTHER TOOTH)**

- q. The mesial marginal ridge is overdeveloped, almost resembling a cusp (buccal and occlusal views).
- r. The occlusal table is wider mesiodistally than buccolingually like secondary mandibular molars (occlusal views).
- s. The mesial surface converges to the lingual with an acute and prominent mesiobuccal angle of the occlusal table (occlusal views).
- t. The mesiobuccal cusp is the largest and longest cusp, covering nearly two thirds of the buccal surface (occlusal views), but is not wide buccolingually (occlusal views).
- u. A pronounced transverse ridge runs between the mesiobuccal and mesiolingual cusp (occlusal views).
- v. The occlusal table is larger distal to the transverse ridge with a larger distal fossa and a smaller mesial triangular fossa (no central fossa) (occlusal views).

# Index

Page numbers in *italics* indicate figure and page numbers followed by 't' indicate table.

## A

Abducent nerve, 417t  
Abfraction, 314  
Abnormal crown morphology  
  accessory cusps, 330, 331, 332  
  fusion, 327–329, 328, 329  
  gemination or twinning, 327, 328  
  Hutchinson's incisors, 329, 329, 330  
  peg-shaped lateral incisors, 327, 328  
  shovel-shaped incisors, 332, 332  
  third molar malformations, 327  
  variations, 332, 332  
Abnormal root morphology  
  concrecence, 334, 334  
  dens in dente, 333–334, 334  
  dilaceration, 333, 333, 334  
  dwarfed roots, 334  
  enamel pearls, 332–333, 333  
  extra (accessory) roots, 334–336, 335, 336  
  hypercementosis, 334, 335  
  taurodontia, 333, 333  
Abrasion, 341, 341–342  
Abuse and neglect, forensic dentistry in, 351, 351–352  
Abutment teeth, defined, 319  
Access openings, for endodontics, 242  
Accessory (extra), 334–336, 335f  
Acoustic, defined, 378  
Acoustic meatus  
  external, 424, 426  
  internal, 394, 395  
Adult dentition, 164 (See also Permanent teeth)  
Afferent (sensory) nerves  
  facial nerve, 424  
  glossopharyngeal nerve, 427  
  trigeminal nerve, 418  
Air-abrasion system, 303  
Alveolar artery  
  anterior superior, 420  
  middle superior, 420, 446  
  posterior superior, 446  
Alveolar bone, 13, 13  
Alveolar canals, 419, 421, 447, 448  
Alveolar eminences, 387, 390  
Alveolar mucos, 200, 201, 202, 467  
Alveolar nerve  
  anterior superior, 420, 421  
  inferior alveolar, 422, 423–424, 424, 425, 425t–426t  
  middle superior, 420, 421  
  posterior superior, 419–420, 421  
Alveolar process, 386, 387, 388  
  oral examination, 465  
Alveolar vein, inferior, 432  
Alveolingual sulcus, 463  
Alveolus (alveoli), 199  
Amalgam, restoration materials, 295, 295  
Ameloblasts, 11  
Amelogenesis imperfecta, 338, 338–339  
American Academy of Forensic Sciences (AAFS), 345  
Anatomic crown  
  definition, 12  
  morphology  
    depressions and grooves, 22–25, 24–26  
    elevations and ridges, 18–22, 18–23  
Anatomic root, morphology, 25–27, 26

Anesthetic injections  
  anterior superior alveolar nerve, 446  
  greater palatine nerve, 455  
  inferior alveolar nerve, 459  
  infraorbital nerve, 449  
  long buccal nerve, 451  
  middle superior alveolar nerve, 446  
  nasopalatine nerve, 451, 454  
  posterior superior alveolar nerve, 446  
  technique, 445  
Angle, Edward H, 33, 251  
Angular artery, 431  
Angular spine, 383, 384, 392  
Ankylosis, 336–337  
Anodontia  
  partial, 324, 324–325  
  total, 324  
Anomalies. See also Dental anomalies  
  anodontia, 324–325, 324–325  
  crown  
    fusion, 327, 329, 329  
    Hutchinson's teeth, 329, 329, 330  
    peg-shaped lateral incisor, 327, 328  
    third molar, 327  
    tubercles, 330–332, 331–332  
    twinning (gemination), 327, 328, 329  
  dentin dysplasia, 340, 340  
  enamel dysplasia, 338, 338–340, 339  
  root  
    accessory roots, 334–335, 335, 337  
    concrecence, 334, 334  
    dens in dente, 333–334, 334  
    dilaceration, 333, 333, 334  
    dwarfed, 334  
    hypercementosis, 334, 335  
  supernumerary teeth (extra teeth), 325–326, 325–327  
  in tooth position  
    ankylosis, 336, 338  
    impacted, 336, 337  
    rotation, 336, 338  
    transposition, 336, 338  
  tooth size, 332  
  unusual dentitions, 342, 342  
Antemortem records  
  for human identification, 347–348, 349  
  in mass disasters, 355, 356  
Anterior arch, 456  
Anterior deprogramming, 278, 280  
Anterior fibers (of temporalis muscle), 411  
Anterior guidance, 267  
Anterior protected articulation, 267  
Anterior superior alveolar nerve, 420, 421  
Anterior teeth, 425t, 426t  
Anteroposterior curve, 27, 28  
Anthropology, forensic, 345, 358, 358–359  
Antrum, 385–387, 386  
Aperture, defined, 387  
Apical foramen, 238  
Apical foramina, 25  
Arteries, 429–432, 430–432, 392, 424, 420  
  to mandible, 431  
  to maxillae, 432  
  to muscle, 432  
Articular disc, 400, 401, 401–402  
Articular eminence, 394, 399, 400, 401, 404, 404

Articular fossa, 394, 399, 400, 401, 404, 404  
Articulation, long centric, 280  
Articulator, 264  
Ascending palatine artery, 431  
Aspirating syringe, 445  
Attached gingiva, 13, 13  
Attachment loss  
  defined, 211  
  technique for measuring, 213, 213  
Attrition, 341, 341  
Auditory nerves, 417t  
Auriculotemporal nerve, 422, 422

## B

Behavior therapy, 272  
Bennett's movement, 268  
Bevels, 304  
Bifurcation, root, 128  
Bilaminar zone, 400, 403  
Biofeedback, 272  
Biologic width, of gingiva, 220  
Bite mark analysis, 352  
Black, G.V., 297, 299, 303, 320, 321  
Bleeding on probing (BOP), 205, 213–214  
Bolus, 270  
Bonding agents, 298  
Bones (See Skull)  
BOP (bleeding on probing), 205, 213–214  
Bruxism, 255, 341  
Buccal cusps, 252  
Buccal, defined, 422  
Buccal embrasure, 32  
Buccal frenum, 446, 449  
Buccal mucosa, 446, 447, 450  
Buccal nerve, local anesthetic technique, 422, 422, 423  
Buccal ridge, 91–92, 92, 102  
Buccal shelf, 391  
Buccal surface, 33, 180, 182–184, 252  
Buccinator crest, 392, 414  
Buccinator muscle, 422, 422  
Buccinator nerve, local anesthetic technique, 422, 422–423

## C

Calculus, defined, 198  
Canal orifice, 232  
Canine eminence, 383, 387  
Canine fossa, 387  
Canine guidance angle, 289t  
Canine-protected articulation, 268  
Canine-protected occlusion, 269  
Canines  
  arch traits, 70–73, 70–71, 73t–74t  
  class traits, 68–70  
  crown proportions, 70  
  functions, 68–69  
  general description, 68–80  
  incisal ridges and cusp tips, 69–70, 70  
  incisal view  
    cingulum and marginal ridges, 80  
    crown proportions, 78, 79, 79  
    incisal edge (cusp tip) contour, 79  
    labial contour, 79, 80  
    lingual contour, 80  
  labial contour, 70

- Canines (*Continued*)  
 labial view  
 canine morphology, 71, 72t  
 cusp tip and incisal ridges, 72  
 proximal contact areas, 72, 73t  
 root contour, 74  
 shape and size, 71–72, 71  
 tooth proportions, 72  
 lingual view  
 cingulum, 74  
 marginal ridges, 74–76  
 ridges and fossae, 74  
 roots, 76  
 primary teeth  
 incisal view, 177, 179  
 labial view, 178, 178  
 lingual view, 176, 178  
 proximal views, 177, 178–179  
 proximal views  
 cervical lines, 77–78  
 height of contour, 77, 78  
 incisal ridge and cusp tip, 77  
 root shape and depressions, 78, 78t  
 roots, 69–70, 74, 76, 78, 80  
 size, 69  
 variations in, 80–82  
 Capsular ligament, 402, 402–403, 403  
 Carabelli cusp, 144, 144, 157, 158t, 237, 358, 361  
 Caries (*See* Dental caries)  
 Carotid artery, external, 431  
 Carotid canal, 394  
 Carving teeth  
 advice, 372, 374  
 materials for, 368  
 maxillary central incisor, 369, 369–372, 371–373  
 wax carvings, 369, 369  
 Cast metal restorations, 296, 296–297  
 Cavity  
 preparation  
 adequate access, 298  
 caries, 298–299  
 clean, 299  
 final evaluation, 299  
 prevention, 297–298  
 resistance form, 298  
 retention form, 298, 298  
 sound enamel, 297  
 walls, 299  
 restoration of (*See* Restoration)  
 restoration preparation  
 class I, 302–304, 303, 304  
 class II, 307–309, 307–309  
 class III, 311, 311–312  
 class IV, 313, 313  
 class V, 315, 315–316, 316  
 outline, 297–298  
 resistance form, 298  
 retention form, 298, 298  
 Cavosurface margins, 309, 312  
 Cementoblasts, 11  
 Cementodentinal junction, 12, 242, 243  
 Cementoenamel junction, 11  
 Cementum, 11, 13  
 Centric relation (CR), 262–265, 263–265  
 Centric relation jaw recording, 278–280, 279, 280  
 Ceramic restorations, 297, 318  
 inlay, 297  
 onlay, 297  
 Cervical chain of lymph nodes, 435  
 Cervical curvature, 161t, 162t  
 Cervical line  
 canines, 77–78, 178, 179, 185  
 incisors  
 mandibular, 51, 53, 59  
 maxillary, 51, 53  
 molars, 127, 127, 129, 131, 144  
 premolars, 87, 96, 108  
 primary teeth, 173, 174, 176, 178, 179, 181, 182, 184, 185  
 Cervical ridge, 21  
 Cervix of tooth, 28, 363  
 Chamfer, 317  
 Cheeks, oral examination of, 444, 445, 447, 450  
 Chewing, 407–413 (*See also* Mastication)  
 Cingulum, incisors, 50, 58  
 Circumvallate papilla (papillae), 461, 462, 462  
 definition, 461  
 Civil litigation, forensic dentistry, 351, 351–352  
 Clasps, of dental prosthesis, 320  
 Class III occlusion, 254–257, 256–257  
 Class II occlusion, 255–256, 255–256  
 Class I occlusion, 33, 34, 251–252, 251–252, 256, 269  
 Clavicle, 395, 414  
 Clenching, 271  
 Clinical attachment loss, 213, 213  
 Clinical crown, definition, 12  
 Clinical root, 12, 13  
 Commissural papule, 446  
 Commissure, 443  
 Common facial vein, 433  
 Complete removable dental prosthesis, 295, 320, 320  
 Composite resin, 295  
 Concrecence, 334, 334  
 Condylar subluxation, 262  
 Condyle, defined, 378  
 Condylod process, 392, 393  
 Congenitally absent, 191, 239  
 Connective tissue attachment, 202, 468  
 Conservative resin restoration, 303  
 Contact areas, proximal  
 canines, 70, 72, 178  
 incisors  
 mandibular, 56, 58t  
 maxillary, 50  
 molars  
 mandibular, 125, 127, 133, 135  
 maxillary, 138, 140t  
 premolars, 88, 91, 99, 102, 110  
 Coronal sutures, 379–380  
 Coronoid, defined, 379  
 Coronoid process, 390  
 Corrugator supercilii muscle, 414  
 Cortical plate, 387, 388  
 Cranial nerves  
 abducent, 417t  
 auditory, 417t  
 facial, 417t  
 glossopharyngeal, 417t  
 hypoglossal, 417t  
 oculomotor, 417t  
 olfactory, 417t  
 optic, 417t  
 spinal accessory, 417t  
 trigeminal, 417t (*See also* Trigeminal nerve)  
 trochlear, 417t  
 vagus, 417t  
 Crepitation, 261  
 Crepitus  
 defined, 402  
 prevalence of, 402t  
 Crest, defined, 378  
 Crest of contour (*See* Height of contour)  
 Crest of curvature, 28–31, 29, 30t  
 Cribriform plate, 380, 382  
 Criminalistics, defined, 346  
 Crista galli, 380  
 Crossbite  
 anterior, 254, 254, 257, 257  
 posterior, 254, 254  
 Crown  
 anomalies  
 accessory cusps, 330, 331, 332  
 fusion, 327–329, 328, 329  
 gemination or twinning, 327, 328  
 Hutchinson's incisors, 329, 329, 330  
 peg-shaped lateral incisors, 327, 328  
 shovel-shaped incisors, 332, 332  
 third molar malformations, 327  
 variations, 332, 332  
 primary teeth  
 calcification, 168, 168  
 formation, 169, 171  
 Crown calcification, primary teeth, 168, 168  
 Crown lengthening, 220  
 Curve of Spee, 27, 28, 284  
 Curve of Wilson, 27, 28, 126  
 Cusp of Carabelli, 141, 144, 157  
 Cusp ridges, 18  
 Cusps (buccal), 252  
 Cusp slopes, 69  
**D**  
 Deciduous definition, 164  
 Deciduous teeth, 191 (*See also* Primary teeth)  
 Deep facial vein, 433  
 Definition (buccal), 422  
 Deglutition, 269, 270  
 Dehiscence, root, 207, 208  
 Demineralization, 291  
 Dens in dente, 333–334, 334  
 Dental anomalies. *See also* Anomalies  
 abrasion, 341, 341–342  
 accessory cusps, 330, 331, 332  
 ankylosis, 336–337  
 attrition, 341, 341  
 concrecence, 334, 334  
 dens in dente, 333–334, 334  
 dentin dysplasia  
 dentinogenesis imperfecta, 340, 340  
 tetracycline stain, 340, 340  
 dilaceration, 333, 333, 334  
 dwarfed roots, 334  
 enamel dysplasia  
 amelogenesis imperfecta, 338, 338–339  
 fever, 339, 339  
 fluorosis, 339, 339  
 focal hypoplasia, 339, 339–340  
 enamel pearls, 332–333, 333  
 erosion, 341, 342  
 extra (accessory) roots, 334–336, 335, 336  
 fusion, 327–329, 328, 329  
 gemination or twinning, 327, 328  
 Hutchinson's incisors, 329, 329, 330  
 hypercementosis, 334, 335  
 mandibular premolar area, 326, 327, 327  
 maxillary incisor area, 325, 325–326, 326  
 partial anodontia, 324, 324–325, 325  
 peg-shaped lateral incisors, 327, 328  
 shovel-shaped incisors, 332, 332  
 taurodontia, 333, 333  
 third molar area, 326, 326  
 third molar malformations, 327  
 tooth rotation, 336, 338  
 total anodontia, 324  
 transposition, 336, 338  
 unerupted (impacted) teeth, 336, 337  
 unusual dentitions, 342, 342–343, 343  
 variations, 332, 332  
 Dental calculus (tartar), defined, 223  
 Dental caries  
 class I, 299–304, 300–304  
 class II, 304–309, 305–309  
 class III, 309–311, 309–312  
 class IV, 312, 312–313, 313  
 class V, 313–316, 314–316  
 class VI, 316

- Dental caries, spread pattern, 292  
Dental formulae, 164–165, 165  
Dental implants, 319  
Dental plaque  
  defined, 198  
  in dental caries, 198  
  plaque index, 220  
Dental prosthesis  
  complete removable, 320  
  fixed, 295, 318, 319  
  removable, 319, 320  
Dentin, 11  
Dentin dysplasia  
  dentinogenesis imperfecta, 340, 340  
  tetracycline stain, 340, 340  
Dentinoenamel junction, 12  
Dentinogenesis imperfecta, 340, 340  
Dentistry  
  operative, 294–295  
  restorative, 239–240, 294–295  
Dentition  
  mixed, 166  
  permanent (See Permanent teeth)  
  primary (See Primary teeth)  
Depressor, defined, 406  
Depressor septi nasi muscle, 414  
Descending palatine artery, 389, 432  
Developmental groove, 23, 24  
Developmental lobes, canines, 34–35  
Developmental lobes, incisors, 44  
Developmental lobes, molars, 35  
Development lobes, premolars, 86–87  
Diastema, 31  
Digastric muscles, 414, 416  
Dilaceration, 333, 333, 334  
Disasters, forensic dentistry  
  antemortem records, 355  
  case studies, 359–360, 369–370  
  dental identification, 355–358, 357  
  forensic anthropology, 358, 358–359  
  initial response, 354–355  
  morgue operation, 355–358, 357  
Dislocation, 262  
Distal surface (defined), 28  
Distal views, 363, 364, 364–365  
Distobuccal root, 124, 140, 144, 145, 146, 182, 216, 246  
Distomolar, 326, 326  
DNA analysis for humans, 346  
Dorsum of tongue, 461–462  
Drawing teeth  
  distal views, 363, 364, 364–365  
  facial views, 363, 364  
  incisal view, 364, 365–366  
  lingual views, 364, 364  
  materials needed, 362  
  from memory, 366, 366–368, 368  
  mesial, 363, 364, 364–365  
  outline, 362–363, 363–365  
Dura, defined, 379  
Dwarf root, 332, 334  
Dysplasia  
  dentin dysplasia, 340  
  enamel dysplasia, 338–340
- E**  
Efferent (motor) nerves, 418, 421, 424  
Embrasure (buccal), 32  
Embrasure spaces, 31–32, 32, 33, 203  
Eminence (defined), 378  
Enamel, 11  
Enamel dysplasia  
  amelogenesis imperfecta, 338, 338–339  
  fever, 339, 339  
  fluorosis, 339, 339  
  focal hypoplasia, 339, 339–340  
Enamel extension, 127, 127, 222, 223  
Enamel pearls, 223, 332–333, 333  
Endodontics, 240–244  
Endodontist, 240  
End-to-end occlusion, 254  
Envelope of motion, 276  
Epithelium, 201–203, 334, 466, 468  
Erosion, 274, 291, 296, 314, 315, 341, 341, 342  
Eruption order, 171  
Eruption, timing, 166–168  
Esthetic restorative materials, 295–296, 296  
Ethmoid bone, 380–382, 381–383  
Exfoliation, 168, 169, 171  
Exostosis, 207, 465  
External acoustic meatus, 394, 441  
External carotid artery, 429, 431, 431, 432  
External oblique ridge, 391, 392  
Extraoral examination  
  eyes, 441  
  general appearance, 440  
  head, 440  
  lips, 443, 443–444, 444  
  lymph nodes, 441–442, 443  
  muscles of mastication, 440, 440–441  
  neck, 441, 442, 443  
  salivary glands, 442, 442–443  
  temporomandibular joint, 440, 441  
Extruded, 352  
Eyes, oral examination, 441
- F**  
Facet, 46–47, 70, 131, 253, 255, 271  
Facial artery, 430–431, 433, 434  
Facial bones  
  conchae (inferior nasal), 395  
  hyoid, 395, 414  
  lacrimal, 395  
  mandible, 383, 389–393, 390–392  
  maxillae, 383, 385–388, 386, 388, 389  
  nasal, 395, 396  
  palatine, 386, 388–389, 389  
  vomer, 394, 395, 396  
  zygomatic, 389, 390  
Facial, defined, 15, 28  
Facial expression, muscles of, 413, 415, 424, 428  
Facial nerve, 414, 415, 417t, 424, 426–427, 426, 427  
Facial veins, 432–433  
Facial views, 363, 364  
Fascia, 266, 271, 413  
Fauces, 455–457, 456  
Federation Dentaire Internationale (FDI system), 7  
Fibrous capsule, 259  
Filiform papillae, 461, 462  
Filling materials, 298, 317  
Fissure, 24, 25, 292, 293, 378, 384, 385, 393, 401, 419, 424  
Fixed dental prosthesis, 265, 295, 318, 319  
Flexion, 159, 159  
Floor of mouth, oral examination, 463, 463–465, 464, 465  
Fluoride, 292, 294–297, 295, 306, 314–316, 338, 339  
Fluorosis, 339, 339  
Focal hypoplasia, 339, 339–340  
Foliate papillae, 462  
Foramen cecum, 461  
Foramen magnum, 380, 428  
Foramen ovale, 378, 384, 419, 422  
Foramen rotundum, 378, 384, 419  
Foramen spinosum, 384  
Fordyce granules, 447, 450  
Forensic anthropology, defined, 345–346  
Forensic dentistry  
  bite marks, 352–354, 353  
  civil litigation, 351, 351–352  
  defined, 345–346  
  forensic anthropology, 358, 358–359  
  human identification, 346–350, 347, 348, 349–350  
  importance, 360–361  
  mass disasters  
    case studies, 359, 359–360, 360  
    initial response, 354–355  
    preparation and training, 354  
  morgue operations, 355–358, 356–357  
  forensic engineering, defined, 346  
  forensic jurisprudence, defined, 346  
  forensic odontology, defined, 346  
  forensic pathology, defined, 346  
  forensic psychiatry, defined, 346  
  forensics, general, 346  
  Fornix, defined, 439  
  Fossa (fossae)  
    articular, 393, 399, 400, 401  
    canine, 387  
    defined, 378  
    hypophysial, 381, 384  
    incisive, 387  
    mandibular, 401, 401  
    mandibular molars, 133, 134, 135  
    maxillary molars, 149, 150  
    pterygoid, 383, 384  
    retromolar, 392  
    sublingual, 392–393  
    submandibular, 393  
    of teeth, incisors, 50, 58  
    temporal, 393, 393  
  Fourth molar, 326  
  Fovea, defined, 378  
  Fovea palatini, 453, 454  
  Framework, of dental prosthesis, 320  
  Free gingiva, 13, 13  
  Free gingival groove, 467  
  Free gingiva margin, 13  
  Freeway space, 266  
  Fremitus, 271  
  Frenum (buccal), 446, 449  
  Frenum, defined, 218, 439  
  Frontal bone, 379  
  Frontal envelope, 276, 277  
  Frontal process, 387  
  Full-mouth rehabilitation, 274  
  Functional movements, of temporomandibular joint  
    incising, 269  
    masticating (chewing), 269–270  
    swallowing (deglutition), 270  
  Fungiform papillae, 461  
  Furcal region, 25  
  Furcation involvement, 214–217, 214–217  
  Fusion, 327, 329, 329
- G**  
Gemination, 327–329, 328  
General forensics, 346  
Genial spines, 392, 413  
Geniohyoid muscle, 395, 414  
Gingiva  
  attached, 13, 202, 217–219  
  biologic width, 220  
  keratinized, 202, 203  
  oral examination, 465–468, 466, 467  
  recession, 203, 206–207, 206–207  
  thin tissue, 206  
  Gingival embrasure, 32  
  Gingival margin, 13, 13  
  Gingival recession, 13, 203, 206, 206–208, 211–213, 223, 294, 314  
  Gingival sulcus, 201, 211, 468  
  Gingivitis, 198, 204, 205  
  Ginglymoarthrodial joint, defined, 257  
  Glass ionomer, 296  
  Glass ionomer restorations, 316



- Glenoid, defined, 257, 379, 393, 401  
 Glossopharyngeal nerve, 417t, 426, 427, 427–428, 431  
 Granuloma, 241  
 Greater palatine foramina, 419, 455  
 Greater palatine nerve, 419  
 Grooves  
   molar  
     mandibular, 132–134, 135  
     maxillary, 149–151, 150  
   premolars  
     mandibular, 103, 105  
     maxillary, 96  
 Group function, 269, 289  
 Gutta percha, 242
- H**  
 Hamular notch, 388  
 Hard palate, oral examination, 451–453, 452–455  
 Head, oral examination, 440  
 Height of contour  
   canines, 71, 74t, 77  
   in drawing teeth, 366, 367  
 Incisors  
   mandibular, 61  
   maxillary, 51  
 Molars  
   mandibular, 129, 131  
   maxillary, 140, 144  
 Premolars, mandibular, 106, 107  
 Human identification, forensic dentistry for  
   antemortem records, 346  
   DNA analysis, 346  
   postmortem examination, 346, 347, 348  
   techniques for, 346  
 Hutchinson's incisors, 329, 329, 330  
 Hutchinson's teeth, 329, 329, 330  
 Hyoid bone, 395, 414  
 Hypercementosis, 334, 335  
 Hypoglossal canals, 426, 427, 428  
 Hypoglossal nerve, 380, 427, 428  
 Hypophyseal fossa, 381, 384
- I**  
 Ideal occlusion  
   class I occlusion, 251, 251–252, 252  
   definition, 251  
 Identification of human teeth  
   antemortem records, 346  
   DNA analysis, 346  
   postmortem examination, 346, 347, 348  
   techniques for, 346  
 Impacted (unerupted) tooth, 336, 337  
 Incisal edge, maxillary incisors, 51, 52  
 Incisal embrasure, 32, 32  
 Incisal guidance, 267  
 Incisal view, 364, 365–366  
 Incising, 269  
 Incisive artery, 432  
 Incisive fossa, 387  
 Incisive foramen, 387, 389, 419, 451, 454  
 Incisive nerve, 422, 423  
 Incisive papilla, 451  
 Incisor (incisors)  
   arch traits, 45–48  
   central, 4  
   class traits, 44–45, 45t  
   crowns, 44, 45  
   functions, 43  
   general description, 42–48  
   lateral, 4  
   mandibular  
     incisal view, 61–63  
     labial view, 55–58, 56, 57, 58t  
     lingual view, 58  
     proximal views, 59, 60–62, 62  
   maxillary  
     incisal view, 53–54  
     labial view, 49–50  
     lingual view, 50–51  
     proximal views, 51–55, 52, 54  
   morphology, 43–44  
   primary teeth  
     cervical line, 175, 176  
     crowns, 175, 175, 176  
     incisal view, 177, 177  
     labial view, 175, 175, 176  
     lingual view, 175–176, 176  
     marginal ridges, 176, 176  
     maxillary vs mandibular, 186t–187t  
     proximal views, 175, 177  
     root-to-crown, 175  
   roots, 44, 45  
   variations and differences, 63  
 Index, plaque, 219, 220  
 Inferior alveolar artery, 431  
 Inferior alveolar nerve, 391, 423–424  
 Inferior alveolar vein, 432  
 Inferior, defined, 378  
 Inferior nasal conchae bone, 395  
 Infrahyoid muscle, 395  
 Infraorbital artery, 432  
 Infraorbital canal, 385, 421  
 Infraorbital fissure, 385  
 Infraorbital foramen, 385, 449  
 Infraorbital nerve, 385, 420–421, 449  
 Injections, anesthetic (See Anesthetic injections)  
 Injury, 210  
 Inlay, cast metal restorations, 296–297  
 Insertion, defined, 407, 408  
 Interdental papilla, 13, 13  
 Intermaxillary suture, 453  
 Internal acoustic meatus, 394, 424  
 Internal jugular vein, 380, 433, 435  
 Internal oblique line, 392  
 International numbering system, 7–10  
 Interproximal space, 31, 32  
 Intracoronal restoration, 241  
 Intraoral examination  
   alveolar process, 465  
   floor of mouth, 463–465, 463–465  
   gingiva, 465–468, 466, 467  
   hard palate, 451–453, 452–455  
   oropharynx, 455–458, 456, 457, 459, 460  
   salivary glands, 463, 464, 465  
   soft palate, 454–455, 456  
   teeth, 468  
   tongue, 458, 461–463, 461–463  
   vestibule and cheeks, 445–451, 447–450, 451  
 Irreversible pulpitis, 240  
 Isometric contraction, 406  
 Isotonic contraction, 406
- J**  
 Jaw relation  
   centric relation, 262–265, 263–265  
   horizontal movements  
     mandibular lateral translation, 268, 268–269  
     protrusive, 266–268, 268  
     maximal intercuspal position, 262, 263  
 Jugular foramen, 394, 426  
 Jugular vein, internal, 380, 433, 435  
 Junctional epithelium, 201, 203  
 Jurisprudence, forensic, 346
- K**  
 Keratinized epithelium, 200  
 Keratinized gingiva, 202, 218, 468  
 Keratin layer, 445
- L**  
 Labial arteries, 431  
 Labial, defined, 15  
 Labial embrasure, 31  
 Labial frenum, 446  
 Labial mucosa, oral examination, 444  
 Labial nerve, 421  
 Labiomentalar groove, 444  
 Labioversion, 253  
 Lacrimal bones, 395  
 Lacrimal, defined, 379, 395  
 Lambdoid suture, 380  
 Lamina, defined, 379  
 Lamina dura, 199, 204, 465  
 Laryngeal prominence, oral examination, 442  
 Larynx, oral examination of, 441  
 Lateral ligament, 402, 403  
 Lateral mandibular movement, 268–269  
 Lateral mandibular relation, 268–270  
 Lateral pterygoid muscles, oral examination of, 402, 403, 407, 410, 441  
 Laterotrusion, 268  
 Leaf gauge, 279  
 Leaf wafer, 278  
 Lesser palatine foramina, 389  
 Lesser palatine nerve, 419  
 Levator anguli oris muscles, 414, 415  
 Levator labii muscles, 414  
 Ligaments of temporomandibular joint, 402–404, 402–404  
 Linea alba, 447  
 Line angle, 16, 50  
 Lingual artery, 430  
 Lingual cusps, 252  
 Lingual embrasure, 32, 32  
 Lingual frenum, 464  
 Lingual nerve, 422, 423, 423  
 Lingual root, 246  
 Lingual surface, defined, 15  
 Lingual veins, 433  
 Lingula, 379, 382  
 Linguoversion, 253  
 Lips, oral examination, 443, 443–444, 444  
 Lobes, developmental  
   of incisors, 44, 45t  
   molar, 123, 123t  
 Local anesthetic technique, buccal nerve, 422, 422, 423  
 Long buccal nerve, 422, 451  
 Long centric articulation, 280  
 Luxation, of mandible, 262  
 Lymph nodes, oral examination, 441–442, 443
- M**  
 Macrodonia, 332, 332  
 Major connector, of dental prosthesis, 320, 320  
 Malar, defined, 379  
 Malocclusion  
   anterior crossbite, 254, 254, 257  
   buccoversion, 253  
   class II, 255–256, 256  
   class III, 256, 256–257  
   definition, 251  
   deflective occlusal contacts, 255, 264  
   edge-to-edge bite, 254  
   infraocclusion, 253  
   jaw relation (See Jaw relation)  
   labioversion, 253  
   linguoversion, 253  
   open bite, 254, 255  
   overbite, 252, 252, 254, 255  
   posterior crossbite, 254, 254  
   premature contacts, 255  
   supraeruption, 253, 253  
   teeth poor alignment, 253, 253  
   tooth-to-tooth malocclusion, 253–255  
   treatment  
     occlusal device, 272–273, 273  
     patient education and behavior therapy, 272  
     stress management and muscle relaxation, 272

- teeth shapes, 274
- tooth location, 263, 274, 276, 276
- vs. ideal occlusion, 251–257
- Mamelons, in incisors, 44
- Mandible, 383, 389–393, 390–392
  - angle of, 390
  - body, 391
  - internal surface, 392, 392–393
  - ramus (rami), 390, 392, 392
- Mandibular arch, 85, 86
- Mandibular branch, 385, 418
- Mandibular canine crown, 49
- Mandibular canines, 244
  - facial view, 363
  - incisal view, 365–366
    - cingulum, 80
    - crown proportions, 78
    - incisal edge, 79
    - labial outline, 80
    - lingual ridge, 80
  - labial view
    - canine morphology, 71
    - crown shape and size, 71–72
    - cuspid tip and incisal ridges, 72
    - proximal contact areas, 72
    - root contour, 74
    - tooth proportions, 72
  - lingual view, 364
    - canine roots, 76
    - cingulum, 74
    - lingual ridges and fossae, 74
    - marginal ridges, 74–76
  - mesial and distal view, 364–365
  - proximal view
    - canine outline, 77
    - cervical lines, 77–78
    - height of contour, 77
    - incisal ridge and cuspid tip, 77
    - roots, 78
- Mandibular central and lateral incisors, 244
- Mandibular condyle, 257
- Mandibular deviation, 264
- Mandibular foramen, 392, 392
- Mandibular fossa, 401, 401
- Mandibular incisors
  - incisal view
    - crown outline, 62
    - crown proportions, 61–62
    - incisal ridge contour, 62–63
    - labial contour, 63
  - labial view
    - crown shape, 55–56, 56, 57
    - incisal proximal angles, 56
    - proximal contact area, 56, 58t
    - root shape, 57, 58
    - root-to-crown proportions, 58
  - lingual view
    - cingulum, 58
    - marginal ridges and fossae, 58
    - root shape, 58
  - proximal views
    - cervical line, 59
    - height (crest) of contour, 61
    - incisal edge, 59, 61
- Mandibular lateral translation, 268
- Mandibular molars
  - buccal view
    - cervical lines, 127, 127
    - crown proportions, 126
    - proximal contacts, 125, 127
    - relative number and size, 125, 126, 126, 126–127
    - roots, 125, 128–129
    - taper, 127–128
  - lingual view
    - cervical line, 129
    - narrower lingual crown, 129
    - relative size, 128, 129
- roots, 128, 129
- occlusal view
  - fossae, 133, 134, 135
  - grooves, 132–134, 135
  - numbers and size of cusps, 133, 133
  - outline shape and taper, 132, 133, 133
  - proximal contact areas, 133, 135
  - ridges, 133, 134
- proximal views
  - cervical lines, 131
  - cuspid height, 129–131, 130
  - height (crest) of contour, 129, 131
  - marginal ridges, 131
  - roots and root depressions, 130, 131, 131–132
  - tapers, 130, 131
- Mandibular nerves, 384, 418, 451
  - auriculotemporal nerve, 422, 422
  - buccal nerve, 422, 422, 423
  - distribution of, 425t–426t
  - inferior alveolar nerve, 422, 423, 423–424
  - lingual nerve, 422, 423, 423
- Mandibular premolars
  - buccal view
    - crown size and shape, 100–102, 101
    - cuspid ridge notches and depressions, 103, 103
    - location of, 102, 102t
    - roots, 102
  - lingual view
    - crown shape, 103
    - cusps and grooves, 103, 107
    - grooves, 103, 105
    - marginal ridges, 103, 104
    - roots, 105
  - occlusal view
    - occlusal morphology, 110–113
    - outline shape, 108, 110, 110
  - proximal views
    - cervical lines, 108
    - crown shape, 105, 106, 107
    - height (crest) of contour, 106, 107
    - marginal ridge grooves and mesiolingual grooves, 106, 107
    - ridges, 105–107, 106, 107
    - roots and root depressions, 108, 108t
- Mandibular torus, 463
- Marginal ridges
  - incisors, 50–51, 58
  - molar
    - mandibular, 131
    - maxillary, 143, 144, 145
- Mass disasters, forensic dentistry in
  - antemortem records, 355, 356
  - case studies, 359, 359–360, 360
  - dental identification, 355–358, 356–357
  - forensic anthropology, 358, 358–359
  - initial response, 354–355
  - morgue operations, 355–358, 356–357
  - postmortem examination, 355, 356, 356
  - preparation and training, 354
- Masseter muscle, 407, 407
  - attachments, 389, 390, 408
  - oral examination of, 394
- Masticating (chewing), 269–270
- Mastication
  - defined, 269, 270
  - muscles of
    - lateral pterygoid, 410, 411, 412–413
    - masseter, 407, 407, 408
    - medial pterygoid, 409–411, 409–411
    - oral examination of, 428
    - temporalis, 408, 408, 409
- Mastoid process, 393, 394
- Maxilla (maxillae)
  - body, 383, 385
  - maxillary sinus, 385–387, 386
  - processes of
    - alveolar, 387, 388
    - frontal, 387
    - palatine, 387–388, 389
    - zygomatic, 387
- Maxillary arch, 252, 252
- Maxillary artery, 431–432
- Maxillary canines, 244
  - incisal view
    - cingulum, 80
    - crown proportions, 78
    - incisal edge, 79
    - labial outline, 80
    - lingual ridge, 80
  - labial view
    - canine morphology, 71
    - crown shape and size, 71–72
    - cuspid tip and incisal ridges, 72
    - proximal contact areas, 72
    - root contour, 74
    - tooth proportions, 72
  - lingual view
    - canine roots, 76
    - cingulum, 74
    - lingual ridges and fossae, 74
    - marginal ridges, 74–76
  - proximal view
    - canine outline, 77
    - cervical lines, 77–78
    - height of contour, 77
    - incisal ridge and cuspid tip, 77
    - roots, 78
- Maxillary incisors
  - incisal view
    - crown proportion faciolingually vs. mesiodistally, 53, 54
    - incisal ridge contour, 53–54
    - outline shape and cingulum location, 53, 54
  - labial view
    - crown shape, 49–50
    - incisoproximal line-angle, 50
    - proximal contact areas, 50
    - root shape, 50
    - root-to-crown proportions, 50
  - lingual view
    - cingulum, 50
    - lingual fossae, 50
    - marginal ridges, 50–51
    - pits and accessory ridges, 48, 50–51, 51
    - root shape, 48, 51
  - proximal views
    - cervical line, 51, 53
    - height (crest) of contour, 51
    - incisal edge, 51, 52
    - root shape and root depressions, 51–53, 52
- Maxillary molars
  - buccal view
    - numbers and size of cusps, 138, 140
    - proximal contacts, 138, 140t
    - relative crown size and shape, 138, 139
    - roots, 138–140, 139
  - lingual view
    - molar roots, 142, 142
    - numbers and lingual cusps, 141–142, 142
    - relative size and taper, 141, 142
  - occlusal view
    - fossae, 149, 150
    - grooves, 149–151, 150
    - numbers and cuspid size, 146, 148, 149
    - proximal contacts, 151
    - ridges, 146–148, 147, 148
  - proximal views
    - cervical lines, 144
    - height of contour, 144, 144
    - marginal ridges, 143, 144, 145
    - molar cusps, 143, 144
    - roots, 143, 145–146
    - taper, 143, 144

- Maxillary nerve, 384, 389, 418  
 anterior superior alveolar nerve, 420  
 infraorbital nerve, 420–421, 421  
 middle superior alveolar nerve, 420  
 posterior superior alveolar nerve, 419–420, 421  
 pterygopalatine nerve, 419, 420  
 zygomatic nerve, 418, 421
- Maxillary premolars  
 buccal view  
 buccal cusp shape, 91, 92  
 buccal ridge and adjacent depressions, 91–92, 92  
 location, 91, 92  
 relative size, 91  
 roots, 93  
 lingual view  
 cusp ridges, 94  
 lingual cusp position, 94  
 marginal ridges, 94  
 relative cusp size, 93, 94  
 roots, 94  
 occlusal view  
 contact areas and heights of contour, 99, 99  
 grooves and fossae, 96–98  
 outline, 97, 98, 98  
 relative proportions, 98, 98  
 relative size, 96  
 proximal views  
 cervical lines, 96  
 crown shape and morphology, 94  
 height (crest) of contour, 94, 95  
 marginal ridge grooves, 96  
 relative cusp height, 94  
 roots and root depressions, 96
- Maxillary sinus, 385–387, 386  
 Maxillary tuberosity, 388, 456  
 Maxillary vein, 433  
 Maximal intercusp position (MIP), 262, 263  
 Meatus, defined, 378  
 Medial pterygoid muscles, 409  
 attachments, 384  
 oral examination of, 416  
 Median plane, defined, 378  
 Mediolateral curve, 28, 28  
 Melanin pigmentation, 200, 466  
 Mental artery, 431–432  
 Mental foramen, 391, 422, 422  
 Mentalis muscles, 414, 415  
 Mental nerve, 422, 423  
 Mental protuberance, 390  
 Mental spines, 392  
 Mental tubercles, 391  
 Mesial cusp ridges, 19, 70, 72  
 Mesial root, 131, 159, 181  
 Mesial root depression, 145t  
 Mesial surface, 68  
 Mesiobuccal root, 140, 145, 146, 238, 246, 420  
 Mesiobuccal root, molar, 140, 146  
 Mesiodens, 325  
 Mesio-occlusion, 256  
 Mesognathic occlusion, 252  
 Metal ceramic restorations, 296, 318, 318  
 Microdontia, 332, 332  
 Middle superior alveolar artery, 432  
 Middle superior alveolar nerve, 420, 421  
 Mid-root axis, 28, 29  
 Midsagittal plane, defined, 378  
 Misplaced tooth, 336  
 Mixed dentition  
 defined, 166, 168  
 tooth emerge timing, 169
- Mobility of teeth  
 charting, 208–209  
 functional mobility, 211
- Molars  
 arch traits, 122–124  
 class traits, 122  
 functions, 122
- general description, 121, 121  
 mandibular  
 buccal view, 126–129  
 lingual view, 129  
 occlusal view, 132–135  
 proximal views, 121–132  
 maxillary  
 buccal view, 138–141  
 lingual view, 141–142  
 occlusal view, 146–151  
 proximal views, 142–146  
 molar crowns, 154, 155–156, 156  
 molar roots, 155, 156  
 primary teeth  
 first molar mandibular, 182–184, 185  
 first molar maxillary, 184, 184–185  
 second molar mandibular, 181, 182  
 second molar maxillary, 180, 181–182  
 pulp shape, 236–238, 237, 238  
 size and shape, 155  
 type traits, 153, 153–154  
 variations of, 157–160
- Morgue operation, in mass disaster, 355  
 Mouth, floor of, oral examination, 392  
 Movement of jaw  
 functional of temporomandibular joint, 269–270  
 parafunctional, 270–271
- Mucocutaneous junction, 444  
 Mucogingival defects  
 charting, 208–209  
 circumstances for, 218  
 technique for measuring, 219  
 Mucogingival line, 467  
 Mucosa, 200, 201, 202, 218, 421, 423, 444, 447, 450, 451, 458, 466, 467  
 Mucosa (buccal), 446, 447, 450  
 Mulberry molars, 329
- Muscle(s)  
 affecting mandibular movement, 413  
 of facial expression, 413–415, 415, 428  
 of mastication  
 lateral pterygoid, 410, 411, 412–413  
 masseter, 407, 407, 408  
 medial pterygoid, 409–411, 409–411  
 oral examination of, 428, 440, 440–441  
 temporalis, 408, 408, 409
- mouth  
 buccinator, 414  
 depression of mandible, 416  
 elevation of mandible, 415–416  
 fascia, 413  
 lateral excursion, 416  
 lateral pterygoid muscle, 408–412, 412–413, 414  
 lower oral group, 414  
 masseter muscle, 407, 407, 408  
 medial pterygoid muscle, 409–411, 410, 411  
 occipitofrontalis, 415  
 orbicularis oris, 413  
 platysma, 415  
 protrusion, 416  
 retrusion, 416  
 suprahyoid muscles, 413  
 temporalis muscle, 408, 408, 409  
 upper oral group, 414  
 of the neck, 414
- Muscle relaxation, 272  
 Muscles of mastication, oral examination, 428, 440, 440–441  
 Muscle tone, 406  
 Mylohyoid groove, 392  
 Mylohyoid muscle, 392  
 Mylohyoid nerve, 423  
 Mylohyoid ridge, 392  
 Myofacial trigger points, 271
- N**  
 Nasal artery, 431  
 Nasal bones, 395  
 Nasal conchae bone, inferior, 385, 395  
 Nasal nerve, 421  
 Nasal septum, 382, 383  
 Nasal turbinates, inferior, 385  
 Nasofrontal process, 387  
 Nasolabial groove, 444  
 Nasopalatine nerve, 419, 454  
 Neck  
 lymph nodes of, 413, 414, 434  
 muscles of the, 414  
 oral examination, 441, 442, 443  
 Necrotic pulp, 239  
 Nerves  
 afferent (sensory), 418  
 cranial  
 abducent, 417t  
 auditory, 417t  
 facial, 417t  
 glossopharyngeal, 417t  
 hypoglossal, 417t  
 oculomotor, 417t  
 olfactory, 417t  
 optic, 417t  
 spinal accessory, 417t  
 trigeminal, 417t (*See also* Trigeminal nerve)  
 trochlear, 417t  
 vagus, 417t  
 efferent (motor), 418  
 Neurocranium  
 defined, 379  
 ethmoid bone, 381  
 frontal bones, 380  
 occipital bone, 380  
 parietal bones, 380  
 sphenoid bone, 380, 381  
 temporal bones, 393  
 Neutroclusion, 251  
 Nonworking side, 268–269
- O**  
 Oblique ridge, 19  
 Occipital bone, 380, 380, 381  
 Occipital condyle, 428  
 Occipitofrontalis muscle, 415  
 Occlusal devices, 272, 272  
 Occlusal embrasure, 32, 32  
 Occlusal equilibration, 274  
 Occlusal surface, 15  
 Occlusal trauma, 210  
 Occlusal vertical dimension, 265  
 Occlusion, 33, 33–34, 34 (*See also* Malocclusion)  
 class I occlusion, 34  
 ideal, 33–34, 33–34  
 Oculomotor nerves, 417t  
 Odontoblasts, 11  
 Odontology, forensic, 346  
 Olfactory nerve, 382  
 Omohyoid muscle, 414  
 Onlay  
 cast metal restoration, 296, 296  
 porcelain restoration, 297  
 Open bite, 254, 255  
 Open occlusal relationship, 254  
 Operative dentistry, 294–295  
 Operculum, 153, 153  
 Ophthalmic nerve, 418, 418–419, 419  
 Optic nerves, 417t  
 Oral cavity, 444  
 Oral cavity proper, 444  
 Oral examination  
 extraoral  
 eyes, 441  
 general appearance, 440  
 head, 440

- lips, 443, 443–444, 444
- lymph nodes, 441–442, 443
- muscles of mastication, 440, 440–441
- neck, 441, 442, 443
- temporomandibular joint, 440, 441
- intraoral
  - alveolar process, 465
  - floor of mouth, 463–465, 463–465
  - gingiva, 465–468, 466, 467
  - hard palate, 451–453, 452–455
  - oropharynx, 455–458, 456, 457, 459, 460
  - salivary glands, 463, 464, 465
  - soft palate, 454–455, 456
  - teeth, 468
  - tongue, 458, 461–463, 461–463
  - vestibule and cheeks, 445–451, 447–450, 451
- Oral mucous membrane, 444
- Oral vestibule, 444
- Orbicularis, 414
- Orbicularis oculi muscle, 431
- Orbicularis oris muscle, 431
- Origin, of muscle, 407, 408, 411, 412
- Oris, 413
- Oropharynx, oral examination, 455–458, 456, 457, 459, 460
- Orthodontic treatment, 274
- Orthognathic profile, 251
- Overbite
  - normal, 252, 252, 254
  - severe, 254, 255
- Overjet
  - normal, 252, 252
  - severe, 255, 255
- P**
- Palatal surface, 15
- Palate
  - hard, 387, 451–453, 452–455
  - soft, 454–455, 456
- Palatine arches, oral examination of, 456
- Palatine artery
  - ascending, 431
  - descending, 432
- Palatine bones, 386, 388–389, 389
- Palatine foramina
  - greater, 389
  - lesser, 389
- Palatine nerve
  - greater, 452
  - lesser, 419
- Palatine process, 387–388, 389
- Palatine raphe, 451, 453
- Palatine rugae, 452, 453
- Palatine suture, transverse, 388
- Palatine tonsils, oral examination, 456
- Palatine torus, 465
- Palatomaxillary suture, 388
- Palmer Notation System, 9
- Palpebral, defined, 379
- Palpebral nerve, 421
- Panoramic radiograph, of the mouth, 437
- Panorex, of the mouth, 351, 437
- Papilla
  - circumvallate, 427, 461, 462, 462
  - filiform, 461, 462
  - foliate, 462, 462
  - fungiform, 461, 462
- Parafunctional movement
  - bruxing, 271
  - clenching, 271
  - defined, 270
- Paramolar, 326, 326
- Parietal bones, 379, 380
- Parotid duct, 446
- Parotid glands, oral examination of, 428, 431, 431, 442, 443
- Parotid nodes, 435
- Parotid papilla, 446
- Partial anodontia, 324, 324–325, 325
- Pathology, forensic, 346
- Patient education
  - prevention and, 292
  - related to malocclusion, 272
- Peg-shaped incisors, 327, 328
- Periapical disease, 240, 240–241
- Periapical radiolucency, 241
- Perikymata, 21, 23
- Periodontal anatomy
  - alveolar bone, 199
  - bleeding on probing, 209, 213, 214
  - clinical attachment loss, 213, 213
  - furcation involvement, 214–217, 214–217, 215t, 218t
  - gingiva, 200–204, 200–204, 201t
  - gingival margin level, 212–213
  - gingival recession, 206–207, 206–208
  - gingivitis, 204, 205
  - mucogingival defect, 217–219, 218, 219
  - oral hygiene instruction, 223–227, 224–227
  - periodontal disease, 220, 223
  - periodontal ligament, 199, 199
  - periodontitis, 204–206, 206
  - plaque score, 219, 219–220
  - probe depths, 211, 211–212, 212
  - root anatomy and anomalies, 222, 222–223
  - root morphology, 220–221, 221
  - tooth mobility, 208–211, 210, 210t
  - tooth root surface, 199
  - tooth support, 220–221, 221
- Periodontal disease
  - bone loss and, 204, 205
  - defined, 198
  - gingival recession, 206–207, 206–208
  - gingivitis, 201t, 204, 205
  - periodontitis, 204–206, 206
  - restoration (fillings) and, 220
  - root anatomy and, 222, 222–223
  - root attachment and, 220
- Periodontal ligament, 13, 13
- Periodontal measurements
  - bleeding on probing (BOP), 208–209, 213
  - charting, 208–209
  - clinical attachment loss, 213, 213
  - fremitus
    - charting, 208–209
    - defined, 210
  - furcation involvement
    - categories for, 218t
    - charting, 208–209
    - defined, 214
    - location of, 215t
    - mandibular molar, 214, 216
    - maxillary molar, 216, 216
    - probing for, 214, 215
  - gingival margin position, 206, 212–213
  - charting, 208–209
  - mucogingival defects, 217–219, 219
  - charting, 208–209
  - circumstances for, 218
  - technique for determination, 219
- plaque index
  - charting, 206, 220
  - technique for determination, 206, 220
- probe depths
  - charting, 208–209
  - technique, 212, 212
- tooth mobility
  - charting, 208–209
  - functional mobility, 211
  - technique for determination, 210, 210–211, 210t
- Periodontal pocket, defined, 211, 222
- Periodontal probe, 202, 202, 211, 211
- Periodontics
  - defined, 198
  - root planning, 223, 224
  - surgical procedures, 220
- Periodontist, defined, 198
- Periodontitis
  - aggressive, 205
  - bone loss and, 204
  - chronic, 204–205
  - defined, 198
- Periodontium (*See also* Gingiva)
  - alveolar bone, 199, 199, 203–204
  - cementum, 199, 203–204
  - defined, 13, 198
  - diseased
    - characteristics of, 200, 201t
    - gingival recession, 206–207, 206–208
    - gingivitis, 201t, 204, 205
    - periodontitis, 204–206, 206
    - gingiva zones, 200–202, 201, 202
    - healthy, characteristics of, 200, 201t
    - periodontal ligament, 199, 199, 203–204
- Peristalsis, 270
- Permanent dentition, 5–6, 6
- Permanent incisors (*See* Incisors)
- Permanent teeth (*See also* specific tooth)
  - classes, 5
  - complete, 42
  - crown formation, 169, 171
  - formula for, 5
  - number of, 9
  - primary teeth compared to, 173, 173–174
- Petrotympanic fissure, 393, 394
- Petrous portion, 394, 395
- Pharyngopalatine arch, 457
- Pharynx, 270, 455
- Piriform, defined, 379
- Pit caries, 292, 293, 293
- Pits, maxillary incisors, 48, 51
- Planes of the head, 379
- Plaque, dental
  - defined, 198
  - in dental caries, 219
- Plaque index
  - charting, 206, 220
  - technique for determination, 206, 220
- Platysma muscle, 414, 424
- Plica fimbriata, 462
- Point angles, 16
- Pontic, defined, 319
- Porcelain, 297
- Porcelain restorations, 296, 357
- Porcelain veneer crown, 319
- Post and core restorations, 317
- Posterior arch, 456
- Posterior fibers, temporalis muscle, 408
- Posterior superior alveolar artery, 446
- Posterior superior alveolar nerve, 419–420, 421
- Posterior teeth, 6, 15, 15–16, 16
- Postmortem examination
  - for human identification, 347, 350
  - in mass disasters, 355, 356, 356
- Posture, jaw relation and, 278–280, 279
- Premature contact, 255, 264, 264, 280
- Premaxilla, 388
- Premolars, 34
  - arch traits, 89–90, 90
  - class traits, 86–89
  - functions, 86
  - general description, 85, 86
  - mandibular
    - buccal view, 100–103
    - lingual view, 103–105
    - occlusal view, 108–113
    - proximal views, 105–108
  - maxillary
    - buccal view, 91–93
    - lingual view, 93–94
    - occlusal view, 96–99
    - proximal views, 94–96



- Premolars (*Continued*)  
 orifices, 235–236, 236, 237  
 pulp horns, 234, 235, 236  
 pulp shape, 234, 235–236, 236, 237  
 roots, 87–88, 108t
- Prevention, patient education and, 292
- Preventive resin restoration (PRR), 303
- Primary dentition, 4, 5
- Primary teeth
- canines
    - incisal view, 177, 179
    - labial view, 178, 178
    - lingual view, 176, 178
    - proximal views, 177, 178–179
  - classes
    - primary canine traits, 178–179
    - primary incisor traits, 175–177
    - primary molar traits, 179–185
  - compared to permanent teeth, 173, 173–174
  - crown and root development, 168–172
  - crown calcification, 168, 168
  - definitions, 164
  - dental formulae, 164–165, 165
  - exfoliation, 169, 171, 172
  - first molars
    - mandibular, 182–184, 185
    - maxillary, 184, 184–185
  - formulae, 164–165, 165
  - functions, 165–166, 166
  - general characteristics
    - anterior, 174
    - posterior, 174
  - incisors
    - cervical line, 175, 176
    - crowns, 175, 175, 176
    - incisal view, 177, 177
    - labial view, 175, 175, 176
    - lingual view, 175–176, 176
    - marginal ridges, 176, 176
    - maxillary vs. mandibular, 186t–187t
    - proximal views, 175, 177
    - root-to-crown, 175
    - pulp cavities, 186, 186
    - root development, 168–169, 171
  - second molars
    - mandibular, 181, 182
    - maxillary, 180, 181–182
  - tooth emergence, 168–169, 169t
  - tooth eruption, 166, 168
  - traits of, 172–174
- Primate spaces, defined, 169
- Probing
- for attachment loss, 213
  - bleeding on, 208–209, 213
  - for furcation involvement, 214
  - for gingival recession, 213
  - for mucogingival defects, 218
- Probing depths
- charting, 208–209
  - technique, 212, 212
- Procerus, 414
- Prognathic profile, 256
- Proprioception, 418
- Proprioceptive fibers, 259
- Proprioceptors, 278
- Prosthodontics, 294–295
- Protrusion, 416
- Protrusive movement, 266
- Protuberance, 378
- Proximal contact areas
- canines
    - mandibular, 72
    - maxillary, 72
  - incisors
    - mandibular, 56, 58t
    - maxillary, 50
  - molars
    - mandibular, 125, 127, 133, 135
    - maxillary, 138, 140t
  - premolars
    - mandibular, 102
    - maxillary, 91
- Proximal height of contour, 58t, 74t, 102t, 140t–141t
- Proximal surface, 15, 16, 304, 309
- Pseudopocket, 211
- Psychiatry, forensic, 346
- Pterygoid fossa, 411, 411
- Pterygoid fovea, 392
- Pterygoid hamulus, 384
- Pterygoid muscles
- lateral
    - attachments, 382, 384, 392, 392, 402
    - examination of, 410–412, 412–413
  - medial
    - attachments, 409, 411
    - examination of, 409–411, 410
- Pterygoid plate
- lateral, 382, 384
  - medial, 384
- Pterygoid plexus of veins, 432
- Pterygomandibular fold, 457, 459
- Pterygopalatine nerve, 419
- Pterygopalatine space, 419, 420
- Pulp
- cavity, 12
  - dental pulp functions, 12
- Pulp canal, 231–233, 232, 233 (*See also* Root canal (pulp canal))
- Pulp cap, 239
- Pulp chamber
- canines, 234–235, 235, 236
  - incisors, 234–235, 235, 236
  - molar, 236–238, 237
  - premolar, 235–236, 236
  - primary teeth, 186
- Pulp horns
- canines, 234, 235, 236
  - incisors, 234, 235, 236
  - molar, 236–238, 237, 238
  - premolar, 235, 236
- Pulpitis, irreversible, 240
- Pulp morphology
- endodontics, 240–243, 240–244
  - ethnic variations, 247
  - mandibular
    - canines, 244
    - central and lateral incisors, 244
    - first and second molars, 245
    - first premolars, 245
    - second premolars, 245
  - maxillary
    - canines, 244
    - central incisors, 244
    - first and second molars, 246, 246t
    - first premolars, 245
    - lateral incisors, 244
    - second premolars, 245
  - pulp cavities
    - older teeth, 239
    - shape, 231–238, 232–238, 232t, 239t
  - restorative dentistry, 239–240, 240
- Pupil, of eye, 441
- Q**
- Questioned documents, 346
- R**
- Radiograph, panoramic, of the mouth, 437
- Ramus (rami), 257
- Recession, gingival, 203, 206–208, 206–208
- Rehabilitation, full mouth, 274
- Removable dental prosthesis, 319
- Resin restorations, conservative, 296, 296
- Resistance form
- class I, 304, 304
  - class II, 307, 307–309, 309
- Restoration materials
- amalgam, 295, 295
  - cast metal, 296, 296
  - composite resin, 295
  - glass ionomer, 296
  - porcelain, 297
- Restoration outline, 298
- Restorations
- all ceramic, 318
  - cast restorations, 296, 297, 304, 307
  - cavity preparation
    - outline, 297–298
    - resistance form, 298
    - retention form, 298, 298
  - class I
    - cavity preparation, 302–304, 303, 304
    - indications for, 301
  - class II
    - cavity preparation, 307–309, 307–309
    - indications for, 306
  - class III
    - cavity preparation, 311, 311–312
    - indications for, 309
  - class IV
    - cavity preparation, 313, 313
    - indications for, 312
  - class V
    - cavity preparation, 315, 315–316, 316
    - indications for, 314
  - filling materials
    - amalgam, 295, 295
    - cast metal, 296, 296
    - composite resin, 295
    - glass ionomer, 296
    - porcelain, 297
- Restorative dentistry, 239–240, 241, 294–295 (*See also* Restorations)
- Rest position
- physiologic, 265–266, 266
  - vertical dimension of, 265
- Rest seats, 320
- Rest space, interocclusal, 266
- Retained deciduous teeth, 191
- Retainer, 319
- Retention form
- class I, 304, 304
  - class II, 307–308, 309
  - class III, 311–312
- Retentive grooves, 308
- Retraction, defined, 267
- Retro, defined, 378
- Retrognathic profile, 256
- Retromolar fossa, 392
- Retromolar pad, 456, 457
- Retromolar triangle, 392
- Retromylohyoid curtain, 457
- Retrusion (retraction), defined, 267
- Ridge (buccal), 91–92, 92, 102
- Reverse articulation, defined, 254
- Risorius muscle, 414
- Root (*See also under* specific tooth)
- definition of, 12
  - Root axis line, 28
  - Root canal (pulp canal)
    - accessory canals, 232, 233
    - anterior teeth, 234–235
    - canines, 244
    - incisors, 244
    - molars, 237, 238, 238, 245, 246
    - premolars, 235–236, 236, 245
    - types of, 232, 233
  - Root dehiscence, 207
  - Root depression, 78

- Root planing, 223  
 Root restoration, 293, 315, 347  
 Root surface caries, 294  
 Root-to-crown ratio, 17, 366  
 Root trunk, 25  
 Rotation, tooth, 336
- S**
- Sagittal envelope, 277  
 Sagittal suture, 380  
 Salivary glands, oral examination, 442, 442–443, 463, 464, 465  
 Sclera, 441  
 Sealant, 303  
 Secondary dentition, 4  
 Secretory nerves, 417t, 424, 428  
 Sella turcica, 384  
 Septum, defined, 379  
 Shelf (buccal), 391  
 Shovel-shaped incisors, 51, 63  
 Sigmoid notch, 392  
 Silent period, 289  
 Sinus, maxillary, 382, 387  
 Skull  
   facial bones  
     hyoid, 395, 414  
     inferior nasal conchae, 395  
     lacrimal, 395  
     mandible, 383, 389–393, 390–392  
     maxillae, 383, 385–388, 386, 388, 389  
     nasal, 395, 396  
     palatine, 386, 388–389, 389  
     vomer, 394, 395, 396  
     zygomatic, 389, 390  
   neurocranium  
     ethmoid bone, 381  
     frontal bone, 380  
     occipital bone, 380  
     parietal bones, 380  
     sphenoid bone, 380, 381  
     temporal bones, 393  
 Sliding guide, 280  
 Slot preparation, 307, 308  
 Sluiceways, 269  
 Smooth surface restorations, 295, 299, 309, 313  
 Soft palate, oral examination of, 454–455, 456  
 Sphenoidal spine, 392, 404  
 Sphenoid bone, 382–385, 383  
 Sphenomandibular ligament, 403, 403–404  
 Spillways, 32  
 Spinal accessory nerves, 417t  
 Squamosal suture, 393  
 Stensen's duct, 446  
 Sternocleidomastoid muscle, 394, 443  
 Sternohyoid muscle, 413  
 Sternothyroid muscle, 413  
 Sternum, 413  
 Stress management, 272  
 Stuart groove, 148  
 Stylohyoid muscle, 414, 424  
 Styloid process, 393, 394  
 Stylomandibular ligament, 390  
 Stylomastoid foramen, 424, 427  
 Sublingual caruncles, 463  
 Sublingual fold, 464  
 Sublingual fossa, 392–393  
 Sublingual salivary gland, 393  
 Subluxation, condylar, 262  
 Submandibular chain of nodes, 434  
 Submandibular fossa, 393  
 Submandibular nodes, 434, 434  
 Submandibular salivary glands, oral examination, 393  
 Submental artery, 431  
 Submental nodes, 434–435  
 Succedaneous teeth, 165  
 Sulcular groove, 27
- Sulcus  
   alveolingual, 463, 463, 467  
   gingival, 13, 29, 201, 202, 202, 211, 211, 467, 468, 468  
   terminal, 461, 462  
   of tooth, 22, 23  
 Superficial, defined, 378  
 Superior, defined, 378  
 Superior orbital fissure, 384  
 Superior position, 379–380, 380  
 Supernumerary teeth, 35, 325–327, 325–327  
 Supplemental grooves, 24  
 Supraeruption, 253, 256  
 Suprahyoid muscles, 395  
 Surface (buccal), 33, 180, 182–184, 252  
 Suture line, defined, 379  
 Sutures  
   coronal, 379–380  
   intermaxillary, 388  
   lambdoid, 380  
   palatomaxillary, 388  
   sagittal, 380  
   squamosal, 393  
   transverse palatine, 388  
 Swallowing (deglutition), 270  
 Symphysis, 379  
 Synovial fluid, temporomandibular joint, 259  
 Synovial membrane, 403  
 Syringe, aspirating, 445
- T**
- Talon cusp, 330  
 Tartar, defined, 198  
 Taurodontia, 333, 333  
 Teeth (*See also* specific tooth)  
   carving  
     advice, 372, 374  
     materials for, 368  
     maxillary central incisor, 369, 369–372, 371–373  
     wax carvings, 369, 369  
   counting, 468  
   drawing  
     distal views, 363, 364, 364–365  
     facial views, 363, 364  
     incisal view, 364, 365–366  
     lingual views, 364, 364  
     materials needed, 362  
     measurements for, 362, 363  
     from memory, 366, 366–368, 368  
     mesial views, 363, 364, 364–365  
     occlusal views, 367  
     outline, 362–363, 363–365  
     proximal view, 367  
     oral examination, 468  
   temporal bones, 393–394, 393–395  
 Temporal crest, 392  
 Temporal fossa, 379, 380  
 Temporalis muscle  
   attachments, 384  
   oral examination of, 408–409, 408–409  
 Temporomandibular disorders, 271  
 Temporomandibular joint  
   advanced topics, 404, 404–405  
   articular disc, 259–260, 260, 400, 401, 401–402, 402t  
   articular fossa, 257–259, 258, 399, 400, 401  
   development, 404, 404  
   fibrous capsule, 259–260, 260, 402, 402–403, 403  
   lateral ligament, 402, 403  
   mandible dislocation, 262  
   mandibular condyle, 257, 258, 398–400, 399, 400  
   movements  
     lower joint space, 260–261  
     total, 262  
     upper joint space, 261, 261  
   oral examination, 440, 441  
   sphenomandibular ligament, 403, 403–404  
   stylomandibular ligament, 403, 403
- Temporomandibular ligament, 403  
 Terminal sulcus, 461  
 Tetracycline stain, 340, 340  
 Thyrohyoid muscle, 413  
 Thyroid gland, oral examination of, 442  
 Tinnitus, defined, 271  
 Tongue, oral examination, 458, 461–463, 461–463
- Tooth development  
   permanent  
     crown formation, 169, 171  
     emergence order and timing, 167t  
   primary  
     crown formation, 168, 168  
     eruption, 167t  
     tooth emergence timing, 168–169, 169t  
 Tooth dimension, 16  
 Tooth eruption, 166, 168  
 Tooth identification systems  
   International Numbering System, 7–8  
   Palmer Notation System, 9  
   Universal Numbering System, 7, 10  
 Tooth mobility  
   charting, 208–209  
   functional mobility, 211  
   technique for determination, 210, 210–211, 210t  
 Tooth morphology  
   anatomic vs. clinical crown and root, 12–13  
   cervical line (CEJ) curvature, 27, 27t  
   complete permanent dentition, 4–6, 6  
   complete primary dentition, 4, 5  
   contact areas, 30, 31, 31  
   depressions and grooves, 22–25, 24–26  
   elevations and ridges, 18–22, 18–23  
   embrasure spaces, 31–32, 32  
   heights of contour, 28–31, 29, 30, 30t  
   human vs. animal teeth, 36, 36t  
   ideal occlusion, 33–34, 33–34  
   mid-root axis line, 28, 29  
   periodontium, 13–14, 14  
   relative sizes, 27, 27t, 41t  
   tooth development, lobes, 34–35, 35  
   tooth identification systems, 7–10  
   tooth root external morphology, 25–27, 26  
   tooth surfaces  
     anterior vs. posterior teeth, 15, 15, 15–16  
     approximate surfaces, 15, 15–16  
     crown/root divisions, 16–17, 17  
     junctions/dimensions, 16, 16  
     maxillary vs. mandibular teeth, 15, 15  
     root-to-crown ratio, 17, 17  
   tooth tissues, 11–12  
 Tooth replacement, 317–320, 317–320  
 Tooth rotation, 336, 338  
 Torus palatinus, 465, 465  
 Total anodontia, 324  
 Toxicology, defined, 346  
 Trabecular bone, 387  
 Transillumination, 309  
 Translation, defined, 261  
 Transposition, tooth, 336, 338  
 Transverse palatine suture, 388  
 Transverse ridge, 19  
 Triangular ridges, 19  
 Trifurcation, root, 25  
 Trigeminal nerve  
   mandibular nerve  
     auriculotemporal nerve, 422, 422  
     buccal nerve, 422, 423  
     inferior alveolar nerve, 422–424, 423–424, 425t–426t  
     lingual nerve, 422, 423, 423  
   maxillary nerve  
     infraorbital nerve, 420–421, 421  
     posterior superior alveolar nerve, 419–420, 421

Trigeminal nerve (*Continued*)  
 pterygopalatine, 419, 420  
 zygomatic nerve, 418, 421  
 ophthalmic nerve, 418, 418–419, 419

Trismus, 261

Trochlea, defined, 379

Trochlear nerve, 417t

Trunk, of tooth, 25

Tubercles, 144

Tuberculum intermedium, 157

Tuberculum sextum, 157

Tug-back, 300

Turner's tooth, 339

Twinning, 327, 328, 329

## U

Unerupted tooth, 336, 337

Universal Numbering System

for permanent teeth, 7

for primary teeth, 7

Uvula, 454, 457

## V

Vagus nerve, 417t

Veins, 432–433, 433, 430

of face, 433

flow of blood from teeth, 432

Veneer crown, complete, 319

Vermilion border, 444

Vertical overlap, 33, 238

Vestibular fornix, 445, 450

Vestibule

defined, 444

oral examination, 445–451, 447–450, 451

Vibrating line, 454

Vomer bone, 382, 394, 395, 396

## W

Wet line, 444

Wharton's ducts, 465

WinID program, 355

Wisdom teeth, 153

Working side, 268, 268

World Dental Federation, 7

## X

X-ray, panoramic, of the mouth, 437

## Z

Zygomatic arch, 389, 390, 394

Zygomatic bone, 389, 390

Zygomatic nerve, 418, 421

Zygomatic process, 387

Zygomaticus muscle, 414